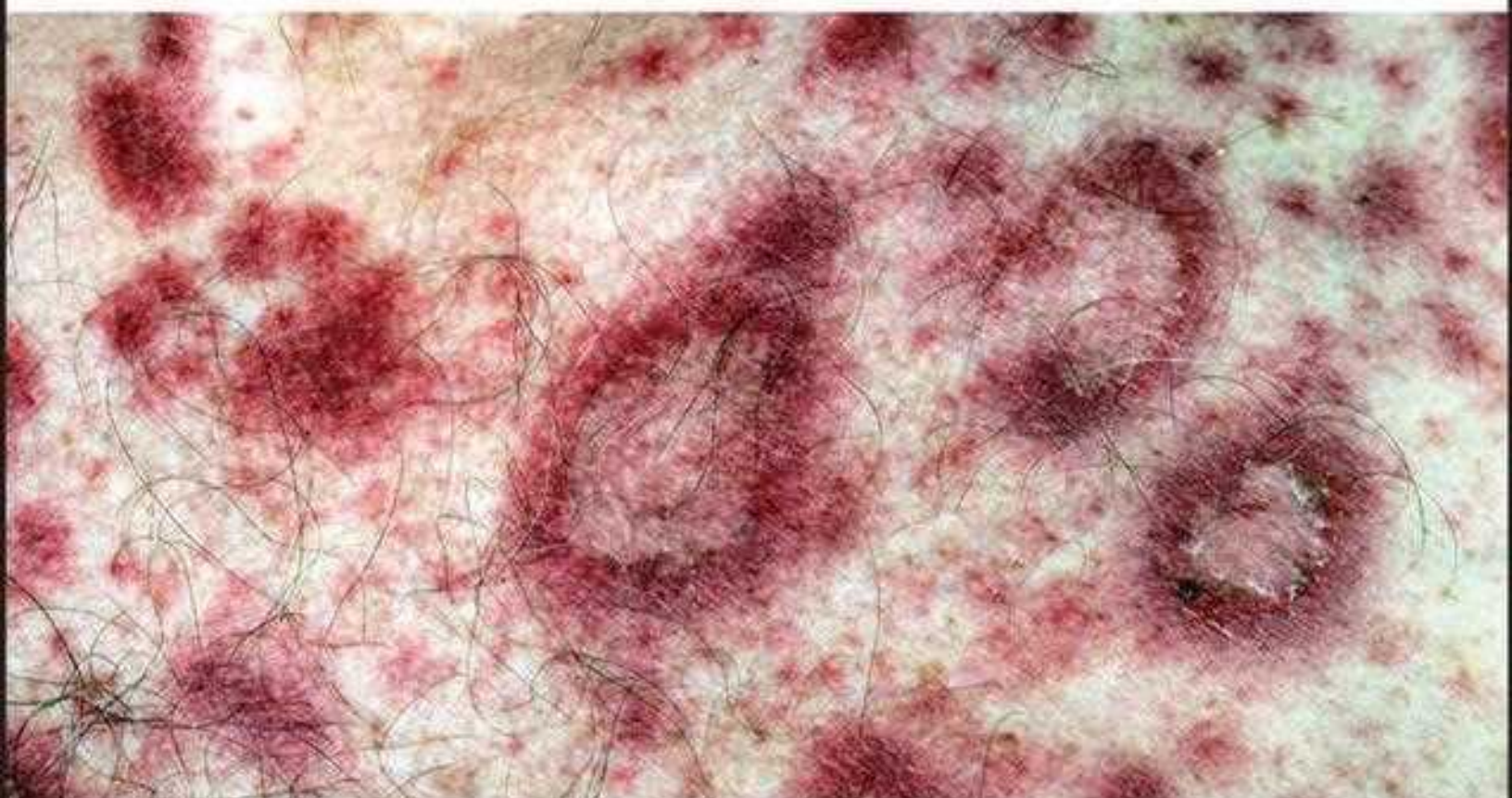

ABC of Dermatology

SEVENTH EDITION

Edited by Rachael Morris-Jones



WILEY Blackwell

Table of Contents

[Cover](#)

[List of Contributors](#)

[Preface](#)

[Acknowledgements](#)

[CHAPTER 1: Introduction](#)

[Introduction](#)

[The significance of skin disease](#)

[Descriptive terms of clinical inspection](#)

[Clinical approach to the diagnosis of rashes](#)

[Symmetry](#)

[Diagnosis](#)

[Distribution](#)

[Morphology](#)

[Assessment of the patient](#)

[Further reading](#)

[CHAPTER 2: Psoriasis](#)

[Introduction](#)

[Clinical appearance](#)

[The typical patient](#)

[Clinical presentation](#)

[Psoriatic arthritis – pathophysiology](#)

[Psoriatic arthritis – clinical presentation](#)

[Psoriasis and systemic disease](#)

[Further reading](#)

[CHAPTER 3: Management of Psoriasis](#)

[Introduction](#)

[Dermatology day treatment units](#)

[Topical treatment](#)

[Scalp psoriasis](#)

[Ultraviolet treatment – phototherapy and photochemotherapy](#)

[Ultraviolet B \(UVB\)](#)

[Ultraviolet A \(UVA\)](#)

[Systemic treatment](#)

[Methotrexate](#)

[Acitretin](#)

[Ciclosporin A](#)

[Mycophenolate mofetil \(MMF\)](#)

[Biological therapy](#)

[Etanercept](#)

[Infliximab](#)

[Adalimumab](#)

[Ustekinumab](#)

[Ixekizumab](#)

[Secukinumab](#)

[Apremilast](#)

[Further reading](#)

[CHAPTER 4: Eczema \(Dermatitis\)](#)

[Clinical features](#)

[Pathophysiology](#)

[Pathology](#)

[Types of eczema](#)

[Classification of eczema](#)

[Clinical features](#)

[Allergic contact dermatitis](#)

[Irritant contact dermatitis](#)

[Photodermatitis](#)

[Occupational dermatitis](#)

[Investigations of contact dermatitis](#)

[Patch testing](#)

[General management of eczema](#)

[Biological treatment for atopic dermatitis](#)

[Pruritus](#)

[Pruritus with skin changes](#)

[Pruritus with normal skin](#)

[Management of pruritus](#)

[Further reading](#)

[CHAPTER 5: Urticaria and Angio-oedema](#)

[Introduction](#)

[Pathophysiology](#)

[Clinical history](#)

[Classification of urticaria](#)

[Ordinary urticaria](#)

[Cholinergic urticaria](#)

[Solar urticaria](#)

[Pressure urticaria](#)

[Angio-oedema](#)

[General investigations](#)

[General management](#)

[Further reading](#)

[CHAPTER 6: Skin and Photosensitivity](#)

[Ultraviolet radiation](#)

[Skin pigmentation and fitzpatrick skin type](#)

[Oculocutaneous albinism](#)

[Xeroderma pigmentosum](#)

[Medications causing photosensitivity](#)

[Photosensitive disorders](#)

[Vitamin D levels and sun protection](#)

[Reference](#)

[Further reading](#)

[CHAPTER 7: Drug Rashes](#)

[Introduction](#)

[History](#)

[Examination](#)

[Investigation of a suspected drug reaction](#)

[Classification of drug reactions in the skin](#)

[Further reading](#)

[CHAPTER 8: Immunobullous and Other Blistering Disorders](#)

[Introduction](#)

[Pathophysiology](#)

[Differential diagnosis](#)

[Clinical features of immunobullous disorders](#)

[Investigation of immunobullous disease](#)

[Management of immunobullous disease](#)

[Further reading](#)

[CHAPTER 9: Connective Tissue Disease, Vasculitis, and Related Disorders](#)

[Introduction](#)

[Connective tissue disease](#)

[Vasculitis](#)

[Polyarteritis nodosa \(PAN\)](#)

[Henoch–schönlein purpura \(IgA vasculitis\)](#)

[Management of cutaneous vasculitis](#)

[Chilblains \(perniosis\)](#)

[Raynaud's phenomenon](#)

[Systemic sclerosis \(SSc\)](#)

[Lichen planus \(LP\)](#)

[Lupus erythematosus \(LE\)](#)

[Dermatomyositis](#)

[Mixed connective tissue disease \(MCTD\)](#)

[Further reading](#)

[CHAPTER 10: The Skin and Systemic Disease](#)

[Introduction](#)

[Skin reactions associated with infections](#)

[Sarcoidosis](#)

[Skin changes associated with hormonal imbalance](#)

[Thyroid disease](#)

[Skin changes associated with disorders of the gastrointestinal system and liver](#)

[Liver disease and the skin](#)

[Pigmentation disorders](#)

[Skin manifestations of underlying malignancy](#)

[Pregnancy and the skin](#)

[Genetics and skin disease](#)

[Single gene disorders](#)

[Further reading](#)

CHAPTER 11: Leg Ulcers

Introduction

Venous ulcers

Arterial ulcers

Diabetic/neuropathic ulcers

Inflammatory conditions

Infectious ulcers

Malignant diseases

Trauma

Further reading

CHAPTER 12: Acne, Rosacea, and Hidradenitis Suppurativa

Introduction

What is acne?

Underlying causes

Diet

Types of acne

Treatment of acne

Rosacea

Management

Further reading

CHAPTER 13: Bacterial Infections

Introduction

Clinical presentation

Bacterial investigations

General approach to management

Superficial infections

Deeper infections

Mycobacterial disease

Other infections

Further reading

CHAPTER 14: Viral Infections

Introduction

Herpes viruses

Treatment

[Viral diseases with rashes](#)

[Further reading](#)

[CHAPTER 15: HIV and the Skin](#)

[Introduction](#)

[Stages of HIV](#)

[Skin disorders in HIV](#)

[Infections](#)

[Further reading](#)

[CHAPTER 16: Fungal Infections](#)

[Introduction](#)

[Investigations](#)

[General features of fungi in the skin](#)

[Yeast infections](#)

[Deep fungal infections](#)

[Systemic antifungal drugs](#)

[Further reading](#)

[CHAPTER 17: Insect Bites and Infestations](#)

[Insect bites and stings](#)

[Delusions of parasitosis \(DoP\)](#)

[Allergic reaction to bites](#)

[Management of bite reactions](#)

[Prevention of bites](#)

[Insect bites transmitting parasites](#)

[Lyme disease](#)

[Spider bites](#)

[Wasp and bee stings](#)

[Treatment](#)

[Infestations](#)

[Cutaneous larva migrans](#)

[Further reading](#)

[CHAPTER 18: Tropical Dermatology](#)

[Introduction](#)

[Bacterial Infections](#)

[Superficial fungal infections](#)

[Deep fungal infections](#)

[Infestations](#)

[Further reading](#)

[CHAPTER 19: Hair and Scalp](#)

[Introduction](#)

[The hair follicle and hair cycle](#)

[Hair loss](#)

[Non-scarring alopecias](#)

[Other non-scarring alopecias](#)

[Tinea capitis](#)

[Scarring alopecias](#)

[Excessive hair](#)

[Skin disease involving the scalp](#)

[Further reading](#)

[CHAPTER 20: Diseases of the Nails](#)

[Introduction](#)

[Changes of shape, surface, and attachment](#)

[Nail bed changes](#)

[Nail plate changes](#)

[Common dermatoses and the nail unit](#)

[Infection](#)

[Trauma](#)

[General diseases affecting the nails](#)

[Treatment of nail conditions](#)

[Further reading](#)

[CHAPTER 21: Genital Dermatoses](#)

[Introduction](#)

[History and examination](#)

[Eczema](#)

[Lichen simplex](#)

[Balanitis and balano-posthitis](#)

[Psoriasis](#)

[Lichen sclerosus](#)

[Lichen planus](#)

[Other inflammatory dermatoses](#)

[Ulcers](#)

[Pigmentation](#)

[Infections](#)

[Intra-epithelial neoplasia](#)

[Extra-mammary paget's disease](#)

[Vulval and penile pain](#)

[Further reading](#)

[CHAPTER 22: Benign Skin Tumours](#)

[Introduction](#)

[Pigmented benign tumours](#)

[Melanocytic naevi](#)

[Dermatofibroma \(benign fibrous histiocytoma\)](#)

[Benign vascular tumours](#)

[Benign tumour papules](#)

[Benign tumour nodules](#)

[Benign tumour plaques](#)

[Further reading](#)

[CHAPTER 23: Premalignant and Malignant Skin Lesions](#)

[Introduction](#)

[Premalignant skin tumours](#)

[Malignant skin tumours](#)

[Moles/naevi: benign or malignant?](#)

[Dysplastic naevi](#)

[Melanoma](#)

[Cutaneous lymphoma](#)

[Other cutaneous malignancies](#)

[Further reading](#)

[CHAPTER 24: Practical Procedures and Skin Surgery](#)

[Introduction](#)

[Application technique](#)

[Risks and precautions](#)

[Skin lesions suitable for freezing](#)

[Electrosurgery](#)

[Curettage](#)

[Diagnostic biopsies](#)

[Incisional biopsy](#)

[Surgical excision](#)

[Mohs micrographic surgery](#)

[Further reading](#)

[CHAPTER 25: Lasers, Intense Pulsed Light, and Photodynamic Therapy](#)

[Lasers in dermatology](#)

[Lasers versus intense pulsed light](#)

[Laser treatment](#)

[Dermabrasion and chemical peels](#)

[Intense pulsed light](#)

[Photodynamic therapy](#)

[Summary](#)

[Further reading](#)

[CHAPTER 26: Cosmetic Dermatology](#)

[Beauty and visible ageing](#)

[The preoperative assessment](#)

[Soft tissue augmentation](#)

[Botulinum toxins](#)

[Chemical peels](#)

[Skin tightening devices](#)

[Further reading](#)

[CHAPTER 27: Wounds, Dressings, and Bandages](#)

[Introduction](#)

[Wounds](#)

[Dressings](#)

[Bandages](#)

[References](#)

[Further reading](#)

[CHAPTER 28: Formulary](#)

[Introduction](#)

[Topical therapy](#)

[Emollients](#)

[Topical immunomodulatory treatments](#)

[Phototherapy](#)

[Systemic therapy](#)

[Biological therapies](#)

[Miscellaneous](#)

[Further reading](#)

[Index](#)

[End User License Agreement](#)

List of Tables

Chapter 3

[Table 3.1 Management of psoriasis.](#)

Chapter 6

[Table 6.1 Common photosensitive drugs and associated features.](#)

Chapter 7

[Table 7.1 Cutaneous reactions and the most commonly implicated drugs.](#)

[Table 7.2 Time from drug commencement to drug rash.](#)

[Table 7.3 SCORTEN parameters.](#)

Chapter 8

[Table 8.1 Differential diagnosis of immunobullous disorders – other causes of...](#)

[Table 8.2 Clinical features of immunobullous disorders.](#)

[Table 8.3 Skin biopsy findings in immunobullous disorders.](#)

Chapter 10

[Table 10.1 Clinical signs of thyroid disease.](#)

[Table 10.2 Abnormality underlying some inherited skin disorders.](#)

Chapter 12

[Table 12.1 Treatment of acne.](#)

Chapter 13

[Table 13.1 Common patterns of bacterial infection in the skin.](#)

Chapter 17

[Table 17.1 Skin lesions associated with insect bites.](#)

Chapter 18

[Table 18.1 Tropical fungal infections of the skin.](#)

Chapter 19

[Table 19.1 Causes of telogen effluvium.](#)

[Table 19.2 Causes of scarring alopecia.](#)

[Table 19.3 Causes of hirsutism.](#)

[Table 19.4 Hypertrichosis due to drugs.](#)

Chapter 21

[Table 21.1 Causes of genital ulceration.](#)

Chapter 22

[Table 22.1 Differential diagnosis of common benign skin tumours.](#)

Chapter 23

[Table 23.1 Prognosis in melanoma according to staging.](#)

Chapter 25

[Table 25.1 Laser indications and selection.](#)

[Table 25.2 Possible complications of laser treatment.](#)

[Table 25.3 Laser selection by colour for tattoo removal.](#)

Chapter 27

[Table 27.1 Wound types and suitable dressings.](#)

[Table 27.2 Wound dressing categories.](#)

Chapter 28

[Table 28.1 Comparison of formulations for topical therapy.](#)

[Table 28.2 Relative potency of topical corticosteroids.](#)

[Table 28.3 Topical antimicrobials used in the treatment of superficial infect...](#)

[Table 28.4 Miscellaneous preparations used in the treatment of psoriasis.](#)

[Table 28.5 Antibiotics used in dermatology, their method of action, indicatio...](#)

[Table 28.6 Side effects of systemic retinoids.](#)

List of Illustrations

Chapter 1

[Figure 1.1 Psoriasis with nail changes.](#)

[Figure 1.2 Erythema nodosum in pregnancy.](#)

[Figure 1.3 Superficial spreading melanoma.](#)

[Figure 1.4 Section through skin.](#)

[Figure 1.5 Erythema due to a drug reaction.](#)

[Figure 1.6 Section through skin with a papule.](#)

[Figure 1.7 Papules in lichen planus.](#)

[Figure 1.8 Nodules in hypertrophic lichen planus.](#)

[Figure 1.9 Section through skin with plaque.](#)

[Figure 1.10 Psoriasis plaques on the knees.](#)

[Figure 1.11 Bullae on the palm from multidermatomal shingles.](#)

[Figure 1.12 Section through skin showing sites of vesicle and bulla.](#)

[Figure 1.13 Lichenification due to chronic eczema in nickel allergy.](#)

[Figure 1.14 Discoid lesions in discoid eczema.](#)

[Figure 1.15 Inflammatory pustules secondary to contact dermatitis with Argon...](#)

[Figure 1.16 Epidermal atrophy in extra-genital lichen sclerosus.](#)

[Figure 1.17 Ulceration in pyoderma gangrenosum.](#)

[Figure 1.18 Erosions \(loss of epidermis\) in paraneoplastic bullous pemphigoi...](#)

[Figure 1.19 Excoriation of epidermis in atopic dermatitis.](#)

[Figure 1.20 Crusted lesions in pemphigus vulgaris.](#)

[Figure 1.21 Desquamation following a severe drug reaction.](#)

[Figure 1.22 Annular \(ring-shaped\) lesions in neonatal lupus.](#)

[Figure 1.23 Reticulate pattern in vasculitis.](#)

[Figure 1.24 Symmetrical hypopigmented plaques of cutaneous T-cell lymphoma....](#)

[Figure 1.25 Irritant eczema on dominant hand of chef.](#)

[Figure 1.26 Bilateral contact dermatitis to cement.](#)

[Figure 1.27 Chronic actinic dermatitis.](#)

[Figure 1.28 Eczema: intraepidermal vesicle \(arrow\).](#)

[Figure 1.29 Vesicles and bullae in erythema multiforme.](#)

[Figure 1.30 Vesicles in herpes simplex.](#)

[Figure 1.31 Vesicles and bullae in bullous pemphigoid.](#)

[Figure 1.32 Bullae in cellulitis on lower leg.](#)

[Figure 1.33 Bullae from insect bite reactions.](#)

[Figure 1.34 Possible precipitating factors in psoriasis.](#)

Chapter 2

[Figure 2.1 Pathophysiological mechanisms involved in the development of psor...](#)

[Figure 2.2 \(Diagram/histology composite\) Increased epidermal proliferation....](#)

[Figure 2.3 \(a\) Pitting and onycholysis of the nails. \(b\) Hyperkeratotic nail...](#)

[Figure 2.4 Multiple small plaques.](#)

[Figure 2.5 Large chronic plaques.](#)

[Figure 2.6 Common patterns of distribution of psoriasis.](#)

[Figure 2.7 Generalised plaques.](#)

[Figure 2.8 Psoriatic plaques on the trunk.](#)

[Figure 2.9 Annular plaques.](#)

[Figure 2.10 Koebner's phenomenon: psoriasis in surgical scar.](#)

[Figure 2.11 Hyperkeratotic palmar psoriasis.](#)

[Figure 2.12 Scalp psoriasis.](#)

[Figure 2.13 Onycholysis in nail psoriasis.](#)

[Figure 2.14 Guttate psoriasis.](#)

[Figure 2.15 Palmar pustular psoriasis.](#)

[Figure 2.16 Acute unstable pustular psoriasis.](#)

[Figure 2.17 Flexural psoriasis.](#)

[Figure 2.18 Napkin psoriasis.](#)

[Figure 2.19 Erythrodermic psoriasis.](#)

[Figure 2.20 Chronic psoriatic arthropathy.](#)

[Figure 2.21 Acute arthropathy X-ray signs.](#)

Chapter 3

[Figure 3.1 Psoriasis suitable for topical dithranol treatment.](#)

[Figure 3.2 Scalp psoriasis.](#)

[Figure 3.3 Thin plaques of psoriasis suitable for TL01.](#)

[Figure 3.4 Psoralen with ultraviolet A \(PUVA\) cabinet.](#)

[Figure 3.5 Psoriasis before phototherapy.](#)

[Figure 3.6 Skin after phototherapy.](#)

[Figure 3.7 \(a, b\) Hand and foot PUVA.](#)

[Figure 3.8 Severe psoriasis suitable for systemic therapy.](#)

[Figure 3.9 Severe unstable pustulating psoriasis suitable for treatment with...](#)

Chapter 4

[Figure 4.1 Chronic atopic dermatitis.](#)

[Figure 4.2 Histology of eczema.](#)

[Figure 4.3 Facial atopic dermatitis.](#)

[Figure 4.4 Chronic lichenified eczema on the legs.](#)

[Figure 4.5 Distribution of atopic dermatitis.](#)

[Figure 4.6 Factors leading to the exacerbation of atopic dermatitis.](#)

[Figure 4.7 Eczema herpeticum.](#)

[Figure 4.8 Plantar dermatitis.](#)

[Figure 4.9 Lichen simplex.](#)

[Figure 4.10 Asteatotic eczema.](#)

[Figure 4.11 Discoid eczema.](#)

[Figure 4.12 Pompholyx eczema.](#)

[Figure 4.13 Varicose eczema.](#)

[Figure 4.14 Infected eczema.](#)

[Figure 4.15 Paget's disease of the nipple – beware unilateral ‘eczema’.](#)

[Figure 4.16 Common sources of contact dermatitis by body site.](#)

[Figure 4.17 Severe contact dermatitis to potassium dichromate in leather sho...](#)

[Figure 4.18 Contact dermatitis to iodine.](#)

[Figure 4.19 Allergic contact dermatitis to melamine formaldehyde resin.](#)

[Figure 4.20 Contact dermatitis to fragrance in facial cream.](#)

[Figure 4.21 \(a\) Contact dermatitis to neomycin cream and \(b\) after stopping ...](#)

[Figure 4.22 Acute PPD allergy in a ‘henna’ tattoo.](#)

[Figure 4.23 Contact allergy to morphine dressing.](#)

[Figure 4.24 Immunological response leading to the development of contact der...](#)

[Figure 4.25 Chronic actinic dermatitis.](#)

[Figure 4.26 Irritant hand eczema in a chef.](#)

[Figure 4.27 Test patches in place.](#)

[Figure 4.28 Patches being removed after 48 hours.](#)

[Figure 4.29 Positive patch test reactions.](#)

Chapter 5

[Figure 5.1 Urticarial vasculitis with bruising.](#)

[Figure 5.2 Ordinary urticaria.](#)

[Figure 5.3 Urticaria from contact with brown caterpillar moths.](#)

[Figure 5.4 Cold-induced urticaria on the cheeks.](#)

[Figure 5.5 Ordinary urticaria with dermatographism.](#)

[Figure 5.6 Annular urticaria.](#)

[Figure 5.7 Angio-oedema of the hand.](#)

[Figure 5.8 Dermatographism.](#)

Chapter 6

[Figure 6.1 Non-ionising, visible, and infrared radiation.](#)

[Figure 6.2 Porphyria cutanea tarda.](#)

[Figure 6.3 Erythropoietic protoporphyria.](#)

[Figure 6.4 Photosensitive drug eruption showing typical 'phototoxic' or exag...](#)

[Figure 6.5 Phytophotodermatitis to lime juice.](#)

[Figure 6.6 \(a\) Polymorphous light eruption \(PMLE\). \(b\) PMLE papular and eryt...](#)

[Figure 6.7 Chronic actinic dermatitis.](#)

Chapter 7

[Figure 7.1 \(a\) Photosensitive eruption. \(b\) Phototoxic eruption.](#)

[Figure 7.2 Diltiazem pigmentation on the face.](#)

[Figure 7.3 Maculopapular exanthem.](#)

[Figure 7.4 Urticaria secondary to penicillin.](#)

[Figure 7.5 Drug-induced lupus.](#)

[Figure 7.6 Drug-induced vasculitis.](#)

[Figure 7.7 \(a\) Lichenoid drug reaction to nifedipine. \(b\) Lichenoid drug rea...](#)

[Figure 7.8 Fixed drug eruption.](#)

[Figure 7.9 \(a\) Toxic epidermal necrolysis on the trunk. \(b\) Toxic epidermal ...](#)

[Figure 7.10 \(a\) DRESS swollen ears. \(b\) DRESS cutaneous eruption.](#)

[Figure 7.11 \(a\) Acute generalised exanthematous pustulosis multiple pustules...](#)

Chapter 8

[Figure 8.1 Section through the skin with \(a\) intraepidermal blister and \(b\) ...](#)

[Figure 8.2 Bullous pemphigoid.](#)

[Figure 8.3 Urticated plaques in pre-bullous pemphigoid.](#)

[Figure 8.4 Bullous pemphigoid: showing mouth erosions.](#)

[Figure 8.5 Pemphigoid gestationis on the abdomen.](#)

[Figure 8.6 Mucous membrane pemphigoid: scarring skin eruption.](#)

[Figure 8.7 Mucous membrane pemphigoid on the scalp.](#)

[Figure 8.8 Mucous membrane pemphigoid: eyes.](#)

[Figure 8.9 Pemphigus vulgaris on the trunk.](#)

[Figure 8.10 Pemphigus vulgaris in the mouth.](#)

[Figure 8.11 Dermatitis herpetiformis on the knees.](#)

[Figure 8.12 Linear IgA on the trunk.](#)

[Figure 8.13 Histopathology of bullous pemphigoid.](#)

[Figure 8.14 Histopathology of pemphigus vulgaris.](#)

[Figure 8.15 Immunofluorescence of bullous pemphigoid.](#)

[Figure 8.16 Immunofluorescence of pemphigus vulgaris.](#)

Chapter 9

[Figure 9.1 Vasculitis.](#)

[Figure 9.2 Bullous vasculitis with necrosis.](#)

[Figure 9.3 Livedo reticularis with skin necrosis in polyarteritis nodosa.](#)

[Figure 9.4 Perniosis on the knees from outdoor work in the winter.](#)

[Figure 9.5 Morphoea seen as hyperpigmented indurated plaques in the torso.](#)

[Figure 9.6 Calcinosis cutis.](#)

[Figure 9.7 CREST syndrome.](#)

[Figure 9.8 Lichen planus on the wrist.](#)

[Figure 9.9 Lichen planus in the mouth.](#)

[Figure 9.10 Bullous lichen planus.](#)

[Figure 9.11 Antiphospholipid syndrome in systemic lupus erythematosus affect...](#)

[Figure 9.12 Systemic lupus erythematosus.](#)

[Figure 9.13 Subacute lupus erythematosus triggered by terbinafine.](#)

[Figure 9.14 \(a\) Discoid lupus erythematosus classically affects the ears. \(b...](#)

[Figure 9.15 Neonatal lupus erythematosus.](#)

[Figure 9.16 Dermatomyositis rash on the 'V' of the neck.](#)

[Figure 9.17 Dermatomyositis of the hands.](#)

[Figure 9.18 Dermatomyositis: ragged cuticles.](#)

Chapter 10

[Figure 10.1 Toxic erythema reactive morbilliform rash.](#)

[Figure 10.2 Erythema multiforme.](#)

[Figure 10.3 Erythema nodosum.](#)

[Figure 10.4 Annular erythema.](#)

[Figure 10.5 Sarcoid.](#)

[Figure 10.6 Melasma.](#)

[Figure 10.7 Acanthosis nigricans.](#)

[Figure 10.8 Necrobiosis lipoidica on the shin.](#)

[Figure 10.9 Granuloma annulare.](#)

[Figure 10.10 Pretibial myxoedema.](#)

[Figure 10.11 Zinc deficiency.](#)

[Figure 10.12 Shiitake mushroom flagellate dermatosis.](#)

[Figure 10.13 Pyoderma gangrenosum.](#)

[Figure 10.14 Dermatitis herpetiformis.](#)

[Figure 10.15 Porphyria cutanea tarda.](#)

[Figure 10.16 Xanthomas in Alagille syndrome.](#)

[Figure 10.17 Piebaldism.](#)

[Figure 10.18 Vitiligo being treated with phototherapy \(TL-01\).](#)

[Figure 10.19 Haemochromatosis.](#)

[Figure 10.20 Sézary syndrome \(erythroderma with abnormal circulating Sézary ...](#)

[Figure 10.21 Cutaneous B-cell lymphoma.](#)

[Figure 10.22 Poikiloderma.](#)

[Figure 10.23 Polymorphous eruption of pregnancy \(PEP\).](#)

[Figure 10.24 Pemphigoid gestationis.](#)

[Figure 10.25 Ichthyosis vulgaris.](#)

[Figure 10.26 Blasenko's lines.](#)

[Figure 10.27 Epidermal naevus following Blasenko's lines.](#)

Chapter 11

[Figure 11.1 Venous leg ulcer.](#)

[Figure 11.2 Healthy valves in legs.](#)

[Figure 11.3 Incompetent valves in legs.](#)

[Figure 11.4 Varicose veins.](#)

[Figure 11.5 Varicose eczema.](#)

[Figure 11.6 Atrophie blanche.](#)

[Figure 11.7 Lymphoedema.](#)

[Figure 11.8 Lipodermatosclerosis.](#)

[Figure 11.9 Compression bandaging.](#)

[Figure 11.10 Cleaning leg ulcers.](#)

[Figure 11.11 Arterial ulcer.](#)

[Figure 11.12 \(a\) Martorell ulcer caused by uncontrolled hypertension. \(b\) He...](#)

[Figure 11.13 Ulcers in diabetic foot.](#)

[Figure 11.14 Vasculitis and perniosis pre-ulceration.](#)

[Figure 11.15 Pyoderma gangrenosum.](#)

[Figure 11.16 Buruli ulcer on the arm.](#)

[Figure 11.17 Squamous cell carcinoma in a chronic diabetic ulcer.](#)

[Figure 11.18 Dermatitis artefacta.](#)

Chapter 12

[Figure 12.1 \(a\) Sebaceous gland: pathology in acne. \(b\) Histology of acne.](#)

[Figure 12.2 Acne with closed comedones.](#)

[Figure 12.3 Acne with open comedones, cysts, and scars.](#)

[Figure 12.4 Perioral dermatitis.](#)

[Figure 12.5 Acne vulgaris with inflammatory papules and pustules.](#)

[Figure 12.6 Acne keloidalis nuchae hypertrophic scarring affecting posterior...](#)

[Figure 12.7 Types of atrophic acne scars \(A, boxcar; B, ice-pick; C, rolling...](#)

[Figure 12.8 'Ice-pick' scars.](#)

[Figure 12.9 \(a\) and \(b\) Keloid scars secondary to acne.](#)

[Figure 12.10 Acne excoriée.](#)

[Figure 12.11 Acne conglobate on the back.](#)

[Figure 12.12 Acne fulminans on the chin.](#)

[Figure 12.13 Dry lips as a result of oral isotretinoin.](#)

[Figure 12.14 Classic xerotic rash on the dorsal hand secondary to taking ora...](#)

[Figure 12.15 Rosacea.](#)

[Figure 12.16 Rosacea localised to the nose.](#)

[Figure 12.17 Rhinophyma.](#)

[Figure 12.18 Blepharitis.](#)

[Figure 12.19 Hidradenitis suppurativa \(Hurley stage III\) affecting the axill...](#)

Chapter 13

[Figure 13.1 Multiple abscesses due to PVL *Staphylococcus aureus* infection.](#)

[Figure 13.2 Impetigo with golden crusting.](#)

[Figure 13.3 Impetigo with bullae and erosions.](#)

[Figure 13.4 Bacterial folliculitis.](#)

[Figure 13.5 Pseudofolliculitis: forehead.](#)

[Figure 13.6 Acne keloidalis.](#)

[Figure 13.7 Erythrasma.](#)

[Figure 13.8 Erysipelas.](#)

[Figure 13.9 Extending cellulitis.](#)

[Figure 13.10 *Staphylococcus* scalded skin syndrome.](#)

[Figure 13.11 Ecthyma.](#)

[Figure 13.12 Lupus vulgaris.](#)

[Figure 13.13 Erythema induratum \(Bazin's disease\).](#)

[Figure 13.14 Sporotrichoid spread of *Mycobacterium marinum*.](#)

[Figure 13.15 Bacillary angiomatosis.](#)

[Figure 13.16 Rocky mountain spotted fever.](#)

[Figure 13.17 Secondary syphilis.](#)

Chapter 14

[Figure 14.1 Inoculation herpes.](#)

[Figure 14.2 Herpes 'cold sore'.](#)

[Figure 14.3 Herpes simplex vesicles on posterior pinna.](#)

[Figure 14.4 Eczema herpeticum.](#)

[Figure 14.5 Varicella zoster virus chickenpox infection in an adult.](#)

[Figure 14.6 Herpes zoster in a dermatome \(shingles\).](#)

[Figure 14.7 Multidermatomal varicella zoster virus \(shingles\).](#)

[Figure 14.8 Mandibular nerve zoster.](#)

[Figure 14.9 \(a\) Herald patch of pityriasis rosea. \(b\) Rash of pityriasis ros...](#)

[Figure 14.10 Molluscum contagiosum.](#)

[Figure 14.11 Histology showing molluscum bodies.](#)

[Figure 14.12 Orf.](#)

[Figure 14.13 Filiform HPV wart.](#)

[Figure 14.14 Periungual hyperkeratotic HPV warts.](#)

[Figure 14.15 Plantar warts \(verrucae\).](#)

[Figure 14.16 Koplick's spots in measles.](#)

[Figure 14.17 Measles rash.](#)

[Figure 14.18 Rubella.](#)

[Figure 14.19 Erythema infectiosum.](#)

[Figure 14.20 Gianotti–Crosti syndrome.](#)

[Figure 14.21 Classic oval blisters in HFMD Coxsackie A16.](#)

[Figure 14.22 \(a and b\) More severe form of HFMD Coxsackie A6.](#)

[Figure 14.23 Onychomadesis \(nail shedding\) one to two months after HFMD](#)

[Coxs...](#)

Chapter 15

[Figure 15.1 Primary HIV infection: seroconversion rash.](#)

[Figure 15.2 Seborrhoeic dermatitis.](#)

[Figure 15.3 Eosinophilic folliculitis.](#)

[Figure 15.4 Nodular prurigo.](#)

[Figure 15.5 Flexural *Candida* infection.](#)

[Figure 15.6 Pseudomembranous *Candida*.](#)

[Figure 15.7 Bacillary angiomatosis.](#)

[Figure 15.8 Secondary syphilis.](#)

[Figure 15.9 \(a\) HSV \(immune reconstitution inflammatory syndrome, IRIS\). \(b\)...](#)

[Figure 15.10 Oral hairy leukoplakia.](#)

[Figure 15.11 Kaposi's sarcoma on the hard palate.](#)

[Figure 15.12 Kaposi's sarcoma nodules.](#)

[Figure 15.13 Molluscum contagiosum.](#)

[Figure 15.14 Human papillomavirus warts: extensive.](#)

[Figure 15.15 Crusted scabies on the hand.](#)

[Figure 15.16 Toxic epidermal necrolysis.](#)

Chapter 16

[Figure 16.1 Animal ringworm.](#)

[Figure 16.2 Tinea capitis: *Microsporum*.](#)

[Figure 16.3 Patchy alopecia in tinea capitis caused by *Trichophyton tonsuran*...](#)

[Figure 16.4 Scaling with alopecia in the scalp and scaly rash on the neck ca...](#)

[Figure 16.5 Kerion in *T. tonsurans* tinea capitis.](#)

[Figure 16.6 'Id reaction' after commencing oral treatment for tinea capitis....](#)

[Figure 16.7 Tinea incognito.](#)

[Figure 16.8 Seborrhoeic dermatitis.](#)

[Figure 16.9 Tinea pedis.](#)

[Figure 16.10 Toeweb tinea pedis.](#)

[Figure 16.11 Tinea corporis.](#)

[Figure 16.12 Tinea cruris.](#)

[Figure 16.13 Pityriasis versicolor with hyperpigmented scaling.](#)

[Figure 16.14 Pityriasis versicolor with hypopigmented scaling.](#)

[Figure 16.15 Onychomycosis caused by *Trichophyton rubrum*.](#)

[Figure 16.16 Candida onychomycosis.](#)

[Figure 16.17 Candida infection in the groin.](#)

[Figure 16.18 *Candida albicans* stomatitis.](#)

[Figure 16.19 Fusarium infection in a bone marrow recipient.](#)

[Figure 16.20 Deep fungal infection.](#)

Chapter 17

[Figure 17.1 Severe bed bug bites.](#)

[Figure 17.2 Linearity of configuration of insect bite reactions.](#)

[Figure 17.3 Bulla bite reaction.](#)

[Figure 17.4 Persistent insect bite reaction.](#)

[Figure 17.5 Parasitophobia specimens.](#)

[Figure 17.6 Tick and bite reaction.](#)

[Figure 17.7 Erythema chronicum migrans in Lyme disease.](#)

[Figure 17.8 Spider bite \(Nigeria\).](#)

[Figure 17.9 Scabies burrows and papules in a child.](#)

[Figure 17.10 Scabies nodules in a child.](#)

[Figure 17.11 Scabies on sole of an infant.](#)

[Figure 17.12 Crusted scabies on buttocks.](#)

[Figure 17.13 Head lice.](#)

[Figure 17.14 Pediculosis \(head lice\) causing an irritant rash on the posteri...](#)

[Figure 17.15 Pubic lice on eyelashes.](#)

[Figure 17.16 Cutaneous larva migrans.](#)

Chapter 18

[Figure 18.1 Spectrum of clinical disease in leprosy. BB, mid-borderline lepr...](#)

[Figure 18.2 Tuberculoid leprosy: hypopigmented patches.](#)

[Figure 18.3 Tuberculoid leprosy.](#)

[Figure 18.4 Lepromatous leprosy.](#)

[Figure 18.5 Borderline leprosy.](#)

[Figure 18.6 Acute leishmaniasis.](#)

[Figure 18.7 Chronic leishmaniasis.](#)

[Figure 18.8 Diffuse cutaneous leishmaniasis.](#)

[Figure 18.9 Superficial fungal infection.](#)

[Figure 18.10 Tinea imbricata.](#)

[Figure 18.11 Madura foot.](#)

[Figure 18.12 Chromoblastomycosis.](#)

[Figure 18.13 *Paracoccidioides brasiliensis* causing disseminated disease in a...](#)

[Figure 18.14 Histoplasmosis in HIV infection.](#)

[Figure 18.15 Tungiasis.](#)

[Figure 18.16 Myiasis: larva.](#)

[Figure 18.17 Lymphoedema of the legs in filariasis.](#)

[Figure 18.18 'Leopard skin' in onchocerciasis.](#)

Chapter 19

[Figure 19.1 \(a\) Diagrammatic cross-section of hair at various growth phases....](#)

[Figure 19.2 Norwood's classification of male pattern balding.](#)

[Figure 19.3 Ludwig patterns of hair loss.](#)

[Figure 19.4 Patterns of hair loss in female pattern hair loss.](#)

[Figure 19.5 Alopecia areata.](#)

[Figure 19.6 Exclamation mark hairs.](#)

[Figure 19.7 Nail pitting associated with alopecia areata.](#)

[Figure 19.8 Tinea capitis.](#)

[Figure 19.9 Kerion.](#)

[Figure 19.10 Discoid lupus erythematosus.](#)

[Figure 19.11 Lichen planopilaris.](#)

[Figure 19.12 Pseudopelade of Brocq.](#)

[Figure 19.13 Folliculitis decalvans.](#)

[Figure 19.14 Hirsutism.](#)

[Figure 19.15 Hypertrichosis.](#)

[Figure 19.16 Scalp psoriasis.](#)

[Figure 19.17 Pityriasis amiantacea.](#)

Chapter 20

[Figure 20.1 Section through finger.](#)

[Figure 20.2 \(a\) Pitting of nail and \(b\) pitting of nail appearance with derm...](#)

[Figure 20.3 Onycholysis due to manicure beneath the nail.](#)

[Figure 20.4 Onycholysis and hyperkeratosis of nail plate in psoriasis.](#)

[Figure 20.5 Longitudinal ridge and partial split termed canaliform dystrophy...](#)

[Figure 20.6 Darier's disease.](#)

[Figure 20.7 Clubbing with loss of the angle between the proximal nail fold a...](#)

[Figure 20.8 Apparent leukonychia.](#)

[Figure 20.9 Yellow nail syndrome.](#)

[Figure 20.10 Linear melanonychia.](#)

[Figure 20.11 Nail psoriasis with onycholysis, pitting, and arthritis of the ...](#)

[Figure 20.12 Eczema causing inflammatory matrix changes and compounded by pi...](#)

[Figure 20.13 Lichen planus.](#)

[Figure 20.14 Nail dystrophy with alopecia areata comprising multiple small, ...](#)

[Figure 20.15 Dystrophy due to lupus.](#)

[Figure 20.16 Pterygium formation with lupus.](#)

[Figure 20.17 Chronic paronychia with alteration of nail plate shape, loss of...](#)

[Figure 20.18 Fungal infection with superficial pattern \(fourth toe\) and dist...](#)

[Figure 20.19 Chronic rubbing trauma to the proximal nail fold leads to a 'ha...](#)

[Figure 20.20 Muroid cyst, also called *myxoid pseudocyst*.](#)

[Figure 20.21 *In situ* melanoma with progressive pigmentation of nail plate.](#)

[Figure 20.22 Subungual exostosis of the big toe.](#)

Chapter 21

[Figure 21.1 Angiokeratomas, multiple small vascular lesions on labia majora...](#)

[Figure 21.2 Extensive erythema in acute allergic contact dermatitis.](#)

[Figure 21.3 Lichen simplex with lichenification and excoriation of labia maj...](#)

[Figure 21.4 Vulval psoriasis with well-defined plaques affecting labia major...](#)

[Figure 21.5 Vulval lichen sclerosus with white sclerotic plaques on inner la...](#)

[Figure 21.6 Vulval lichen sclerosus – architectural change with loss of labi...](#)

[Figure 21.7 Lichen sclerosus affecting the glans penis.](#)

[Figure 21.8 Erosive vulval lichen planus with vestibular erosions and archit...](#)

[Figure 21.9 Erosive lichen planus of glans penis.](#)

[Figure 21.10 Vulval melanosis – irregular pigmentation inner labia.](#)

[Figure 21.11 Vulval intra-epithelial neoplasia with white hyperkeratotic pla...](#)

[Figure 21.12 Perianal HPV-associated intra-epithelial neoplasia.](#)

Chapter 22

[Figure 22.1 Seborrhoeic keratoses on the trunk, there is a melanoma on the r...](#)

[Figure 22.2 Seborrhoeic keratoses.](#)

[Figure 22.3 Dermatitis papulosa nigra.](#)

[Figure 22.4 Skin tags.](#)

[Figure 22.5 Lentigines on upper back.](#)

[Figure 22.6 Congenital melanocytic naevus.](#)

[Figure 22.7 Mongolian blue spot.](#)

[Figure 22.8 Junctional naevus.](#)

[Figure 22.9 Compound naevus.](#)

[Figure 22.10 Intradermal naevus.](#)

[Figure 22.11 Blue naevus.](#)

[Figure 22.12 Spitz naevus.](#)

[Figure 22.13 Halo naevi.](#)

[Figure 22.14 Becker's naevus.](#)

[Figure 22.15 Dermatofibroma.](#)

[Figure 22.16 Naevus flammeus neonatorum.](#)

[Figure 22.17 Sturge–Weber syndrome.](#)

[Figure 22.18 \(a\) Cavernous \(strawberry\) haemangioma and \(b\) ulcerating and b...](#)

[Figure 22.19 Spider telangiectasia.](#)

[Figure 22.20 Campbell de Morgan angiomas.](#)

[Figure 22.21 \(a\) Pyogenic granuloma. \(b\) Multiple eruptive pyogenic granulom...](#)

[Figure 22.22 Syringomas.](#)

[Figure 22.23 Trichoepitheliomas.](#)

[Figure 22.24 Apocrine hidrocystomas.](#)

[Figure 22.25 Milia.](#)

[Figure 22.26 Sebaceous gland hyperplasia.](#)

[Figure 22.27 Lipoma.](#)

[Figure 22.28 Leiomyoma on scalp vertex.](#)

[Figure 22.29 Epidermoid cyst.](#)

[Figure 22.30 Eccrine poroma.](#)

[Figure 22.31 Keloid scar secondary to ear piercing.](#)

[Figure 22.32 Naevus sebaceous.](#)

[Figure 22.33 Epidermal naevus.](#)

[Figure 22.34 Inflammatory linear verrucous epidermal naevus \(ILVEN\).](#)

Chapter 23

[Figure 23.1 Sun-damaged skin with multiple actinic keratoses.](#)

[Figure 23.2 Bowen's disease.](#)

[Figure 23.3 Nodular-type basal cell carcinoma inner canthus of the eye.](#)

[Figure 23.4 Nodular basal cell carcinoma histology.](#)

[Figure 23.5 Recurrent nodular basal cell carcinoma arising in a hypopigmente...](#)

[Figure 23.6 Superficial basal cell carcinoma.](#)

[Figure 23.7 Pigmented basal cell carcinoma.](#)

[Figure 23.8 Morphoeic basal cell carcinoma.](#)

[Figure 23.9 Squamous cell carcinoma: initial stages on the pinna.](#)

[Figure 23.10 Hyperkeratotic rapidly enlarging squamous cell carcinoma on the...](#)

[Figure 23.11 Squamous cell carcinoma histology.](#)

[Figure 23.12 Keratoacanthoma-like squamous cell carcinoma on the lip.](#)

[Figure 23.13 Dysplastic naevus.](#)

[Figure 22.14 Superficial spreading melanoma on the right upper back.](#)

[Figure 23.15 Melanoma with a pale area of regression around it.](#)

[Figure 23.16 \(a\) Lentigo maligna pre-imiquimod treatment and \(b\) lentigo mal...](#)

[Figure 23.17 Lentigo maligna melanoma.](#)

[Figure 23.18 Nodular melanoma.](#)

[Figure 23.19 Acral melanoma.](#)

[Figure 23.20 Amelanotic melanoma.](#)

[Figure 23.21 Desmoplastic melanoma.](#)

[Figure 23.22 Ulcerating melanoma with satellites and in transit metastasis....](#)

[Figure 23.23 Mycosis fungoides.](#)

[Figure 23.24 Primary cutaneous B-cell lymphoma.](#)

[Figure 23.25 Paget's disease of the nipple.](#)

Chapter 24

[Figure 24.1 Cryotherapy.](#)

[Figure 24.2 Electrodesiccation during surgery.](#)

[Figure 24.3 \(a\) Spoon curettage. \(b\) Ring curettage.](#)

[Figure 24.4 Punch biopsy tools.](#)

[Figure 24.5 Punch biopsy: injecting local anaesthetic.](#)

[Figure 24.6 Punch biopsy: tool insertion.](#)

[Figure 24.7 Punch biopsy: plug of skin.](#)

[Figure 24.8 Punch biopsy: raising a plug of skin.](#)

[Figure 24.9 Punch biopsy: specimen taken.](#)

[Figure 24.10 Incisional biopsy: marked area for sampling.](#)

[Figure 24.11 Surgical excision: 'skin wrinkle lines' of the trunk.](#)

[Figure 24.12 Surgical excision: 'skin wrinkle lines' of the limbs.](#)

[Figure 24.13 Surgical excision: 'skin wrinkle lines' of the face.](#)

[Figure 24.14 Surgical excision of BCC from lower back. Ellipse design includ...](#)

[Figure 24.15 Surgical excision of BCC: removal of specimen illustrating the ...](#)

[Figure 24.16 Surgical excision of BCC: after suturing, showing wound eversio...](#)

[Figure 24.17 Placement of epidermal sutures.](#)

[Figure 24.18 Methods of placing buried dermal sutures.](#)

Chapter 25

[Figure 25.1 Port wine stain \(a\) before and \(b\) after treatment with a pulsed...](#)

[Figure 25.2 Bruising following pulsed dye laser treatment.](#)

[Figure 25.3 Café au lait macule \(a\) before and \(b\) after treatment with a Q-...](#)

[Figure 25.4 Tattoo subjected to laser removal. \(a\) Before treatment. \(b\) Fad...](#)

[Figure 25.5 Superficial basal cell carcinoma on the lower back. \(a, b\) Befor...](#)

Chapter 26

[Figure 26.1 Age-related facial changes as a consequence of bone loss, fat pa...](#)

[Figure 26.2 Glogu classification scale for photodamage.](#)

[Figure 26.3 Filling agents should be placed within the skin at a site that b...](#)

[Figure 26.4 \(a and b\) Placement of hyaluronic acid, with a needle, just belo...](#)

[Figure 26.5 \(a and b\) Botulinum toxin injected into the upper forehead to re...](#)

[Figure 26.6 \(a and b\) Botulinum toxin to the platysma muscle and mentalis.](#)

[Figure 26.7 Solar lentigines on the cheek after 35% TCA peel.](#)

[Figure 26.8 Classification of depth of peel penetration and common agents us...](#)

[Figure 26.9 Application of trichloroacetic acid on the cheek. Note frosting ...](#)

[Figure 26.10 Chemical burn as a consequence of accidental spillage of 50% TC...](#)

Chapter 27

[Figure 27.1 Wound assessment.](#)

[Figure 27.2 The wound healing continuum is represented by the colour of the ...](#)

[Figure 27.3 Types of wound dressings.](#)

[Figure 27.4 Larvae dressing in a second toe amputation site.](#)

[Figure 27.5 Negative pressure wound therapy \(NPWT\) dressings applied to a de...](#)

[Figure 27.6 Integra skin substitute applied to lower leg wound.](#)

[Figure 27.7 Example of a four-layer system.](#)

[Figure 27.8 Example of a two-layer system with a foam bandage underneath.](#)

[Figure 27.9 Example of a different two-layer compression system with printed...](#)

Chapter 28

[Figure 28.1 Liberal application of a potent topical steroid resulting in str...](#)

[Figure 28.2 Perioral dermatitis caused by local application of topical stero...](#)

Figure 28.3 Potent topical steroid-induced atrophy and acne.

ABC of Dermatology

Seventh Edition

Rachael Morris-Jones FRCP PhD PCME
Dermatology Consultant
Guy's and St Thomas' NHS Foundation Trust
London, UK

WILEY Blackwell

This edition first published 2019
© 2019 by John Wiley & Sons Ltd

Edition History [6th edition, 2014]

All rights reserved. No part of this publication may be reproduced, stored in a retrieval system, or transmitted, in any form or by any means, electronic, mechanical, photocopying, recording or otherwise, except as permitted by law. Advice on how to obtain permission to reuse material from this title is available at <http://www.wiley.com/go/permissions>.

The right of Rachael Morris-Jones to be identified as the author of editorial in this work has been asserted in accordance with law.

Registered Office(s)

John Wiley & Sons, Inc., 111 River Street, Hoboken, NJ 07030, USA

John Wiley & Sons Ltd, The Atrium, Southern Gate, Chichester, West Sussex, PO19 8SQ, UK

Editorial Office

9600 Garsington Road, Oxford, OX4 2DQ, UK

For details of our global editorial offices, customer services, and more information about Wiley products visit us at www.wiley.com.

Wiley also publishes its books in a variety of electronic formats and by print-on-demand. Some content that appears in standard print versions of this book may not be available in other formats.

Limit of Liability/Disclaimer of Warranty

The contents of this work are intended to further general scientific research, understanding, and discussion only and are not intended and should not be relied upon as recommending or promoting scientific method, diagnosis, or treatment by physicians for any particular patient. In view of ongoing research, equipment modifications, changes in governmental regulations, and the constant flow of information relating to the use of medicines, equipment, and devices, the reader is urged to review and evaluate the information provided in the package insert or instructions for each medicine, equipment, or device for, among other things, any changes in the instructions or indication of usage and for added warnings and precautions. While the publisher and authors have used their best efforts in preparing this work, they make no representations or warranties with respect to the accuracy or completeness of the contents of this work and specifically disclaim all warranties, including without limitation any implied warranties of merchantability or fitness for a particular purpose. No warranty may be created or extended by sales representatives, written sales materials or promotional statements for this work. The fact that an organization, website, or product is referred to in this work as a citation and/or potential source of further information does not mean that the publisher and authors endorse the information or services the organization, website, or product may provide or recommendations it may make. This work is sold with the understanding that the publisher is not engaged in rendering professional services. The advice and strategies contained herein may not be suitable for your situation. You should consult with a specialist where appropriate. Further, readers should be aware that websites listed in this work may have changed or disappeared between when this work was written and when it is read. Neither the publisher nor authors shall be liable for any loss of profit or any other commercial damages, including but not limited to special, incidental, consequential, or other damages.

Library of Congress Cataloging-in-Publication Data

Names: Morris-Jones, Rachael, editor.

Title: ABC of dermatology / [edited by] Rachael Morris-Jones.

Description: Seventh edition. | Hoboken, NJ : Wiley-Blackwell, 2019. | Includes bibliographical references and index. |

Identifiers: LCCN 2019008588 (print) | LCCN 2019011508 (ebook) | ISBN 9781119488996 (Adobe PDF) | ISBN 9781119489009 (ePub) | ISBN 9781119488989 (pbk.)

Subjects: | MESH: Skin Diseases

Classification: LCC RL74 (ebook) | LCC RL74 (print) | NLM WR 140 | DDC 616.5--dc23

LC record available at <https://lccn.loc.gov/2019008588>

Cover Design: Wiley

Cover Image: Courtesy of Dermatology Department, Kings College Hospital, London, UK.

List of Contributors

Dr Saqib J. Bashir

Consultant Dermatologist

Department of Dermatology King's College Hospital, London, UK;

Skin55 Ltd, Harley Street, London, UK

(Lasers, Intense Pulsed Light and Photodynamic Therapy chapter)

Dr David de Berker

Consultant Dermatologist

United Bristol Healthcare Trust

Bristol, UK

(Diseases of the Nails chapter)

Dr Kapil Bhargava

Consultant Dermatologist

St John's Institute of Dermatology

Guy's and St. Thomas' Hospitals

London, UK

(Hair and Scalp chapter)

Nurse Specialist Bernadette Byrne

Tissue Viability, King's College Hospital NHS Trust, London, UK

(Wounds, Dressings, and Bandages chapter)

Dr Emma Craythorne

Consultant Dermatologist

Dermatology Surgery and Laser Unit

St John's Institute of Dermatology

Guy's and St. Thomas' Hospitals, London, UK

(Cosmetic Dermatology chapter)

Dr Alun Evans

Consultant Dermatologist

Princess of Wales Hospital

Bridgend, Wales, UK

(Lasers, Intense Pulsed Light, and Photodynamic Therapy chapter)

Dr David Fenton

Consultant Dermatologist

St John's Institute of Dermatology

Guy's and St. Thomas' Hospitals

London, UK

(Hair and Scalp chapter)

Dr John S. Ferguson

Consultant Dermatologist
St John's Institute of Dermatology
Guy's and St. Thomas' Hospitals
London, UK
(Skin and Photosensitivity chapter)

Dr Fiona Lewis

Consultant Dermatologist
St John's Institute of Dermatology
Guy's and St. Thomas' Hospitals
London, UK
(Genital Dermatology chapter)

Dr Raj Mallipeddi

Consultant Dermatologist
Dermatological Laser and Surgery Unit
St John's Institute of Dermatology
Guy's and St. Thomas' Hospitals
London, UK
(Practical Procedures and Skin Surgery chapter)

Dr Rachael Morris-Jones

Dermatology Consultant
Guy's and St Thomas' NHS Foundation Trust
London, UK

Dr Aisling Ryan

Consultant Dermatologist
Department of Dermatology
King's College Hospital, London, UK
(Formulary chapter)

Dr Sarah Walsh

Consultant Dermatologist
King's College Hospital
London, UK
(Drug Rashes chapter)

Dr Karen Watson

Consultant Dermatologist
Orpington Hospital
Orpington, Kent, UK
(Formulary chapter)

Preface

The 7th edition of the *ABC of Dermatology* incorporates all the latest scientific advances in genetics, pathophysiology, and management strategies whilst at the same time remaining a practical clinical approach to dermatology. There are also additional new chapters to reflect current learning needs around cosmetic dermatology procedures and genital dermatology. The emphasis as always is to produce a valuable resource for any medical and nurse practitioner who is diagnosing and managing skin disease.

As well as a wholly practical approach to clinical dermatology, the 7th edition gives insights into the latest thinking around the pathophysiological processes that explain the characteristic features of skin disease and the current approach to the management of skin disease, including the newer biological agents for treating inflammatory disease and tumours.

The fascination of dermatology lies partly in the visual nature of discipline but also in one's ability to diagnose systemic disease through examination of the skin surface. Manifestations of underlying disease can form specific patterns in the skin which in some instances are pathognomonic. However, where there is any diagnostic doubt a simple skin biopsy for histopathology/immunohistochemistry and/or culture is fantastically helpful in most cases.

For those working in resource-poor settings there may be little access to modern investigations for skin disease patients and therefore the clinical diagnosis will be the benchmark on which skin disease is managed. To this end the 7th edition is full of clinical photographs eliciting the appearances of skin disease in a multitude of different pigmented skin tones and ethnic groups. Descriptions of skin management include simple and relatively cheap interventions as well as sophisticated cutting-edge immunotherapies.

On a global scale the number of people with access to the internet via computers or mobile devices is increasing at a rapid pace. This enables them access to a multitude of resources including those related to the diagnosis and management of human disease. Many patients are increasingly using the internet to attempt to self-diagnose ('Doctor Google') their own skin conditions, identify any known underlying causes and gain some insights into the possible treatment strategies. An informed patient can be hugely beneficial to everyone involved in the provision of healthcare. However, at times this can lead to patients becoming overly anxious or misinformed. There is an increasing use of teledermatology in many parts of the world where populations are a long distance from a skin specialist, where images of the patient's skin complaint are taken and sent to an expert for a 'virtual opinion'. Mobile phone consultations with a remote doctor are also being seen as a way to meet the increasing demand for GP consultations. However, remote dermatology can be tricky as it may be difficult to examine the patient thoroughly and there is no way of feeling the skin texture and induration of rashes/lesions. Remote dermatology can be immensely helpful, but ultimately the gold standard for accurate diagnosis and management of skin disease remains seeing patients in person, preferably by a practitioner with knowledge of skin disease.

We trust the 7th edition of the ABC of Dermatology will not only introduce the reader to a fascinating clinical discipline but will also help them to diagnose and manage skin disease in whichever part of the world they are working.

Rachael Morris-Jones

Acknowledgements

I would very much like to sincerely thank all my co-contributors, whose expertise in specialist areas of dermatology has been invaluable in ensuring that this Seventh Edition is right up to date and written by experts in their field.

Dr Fiona Lewis has written a chapter on genital dermatology, which is a very valuable new edition to the *ABC of Dermatology*; genital disease can be a challenging area even for seasoned dermatologists, so her practical approach to the diagnosis/management of genital disease is hugely welcomed. Cosmetic procedures are increasing globally, with many more women and men undertaking rejuvenation procedures. This area of medicine remains a bit of a mystery to those of us who have only benefited from conventional medical training, so the addition of a chapter dedicated to cosmetic dermatology is fantastically helpful for all of us. Dr Emma Craythorne (alongside her skin cancer surgery work) has expertise in treating scars and performing cosmetic procedures and has written this new chapter on cosmetic procedures to give us an insight into what can be done and what the outcomes and pitfalls might be. Even if we don't practice cosmetic dermatology ourselves, patients may ask for our advice and we may also see patients with complications following procedures, so well informed is hopefully well prepared.

Tissue viability clinical nurse specialist Bernadette Byrne works alongside plastic surgeons, and they have contributed to her wound chapter in this Seventh Edition, so we can understand more about biological dressings, which are being increasingly used in challenging wounds. Bernadette has an impressive depth of knowledge as well as decades of experience managing literally thousands of complex wounds in patients from the outpatient setting to the intensive care unit. Her clinical practical approach is an invaluable guide to wound management in any setting.

Dr Saqib Bashir has taken over writing the chapter on lasers and photodynamic therapy and intense pulsed light from Alun Evans. Saqib has a huge wealth of expertise in using multiple different lasers and light devices. He has great skill in prudently treating patients with a variety of skin tones, and he brings this expertise and his high standards of care to the chapter.

Dr Aisling Ryan is a dedicated dermatology consultant with a wealth of expertise in medical dermatology, specifically in the rapidly expanding field of biological therapies. She has taken over writing the Formulary chapter from Karen Watson. Aisling helps keep us up to date with the new molecular targets for biological therapy, indications, outcomes and adverse events. In the future most of us will all be looking after patients who may be suitable for or already taking biological therapies, so this area is hugely important for all of us to keep us abreast of cutting-edge medicine.

Dr John Ferguson has taken over the Skin and Photosensitivity chapter from me. He has developed an area of expertise in photobiology and had just joined the specialist clinic at St

John's Institute of Dermatology. He has hugely enhanced this chapter with his detailed knowledge of how UV light can affect the skin.

A large proportion of the illustrations in the Seventh Edition of the *ABC of Dermatology* comes from King's College Hospital, London, UK. I am indebted to the medical photography department at King's for their very professional, high-quality clinical images, without which this book would be of little use. Many of the images in the hair and scalp, genital and cosmetic chapters have been provided by the St John's Institute of Dermatology, St Thomas' Hospital, London, UK. Dr Stephen Morris-Jones, consultant in Infectious Diseases, University College Hospital, London, UK, provided some of the cutaneous infection images and we have retained some of Dr Barbara Leppard's photographs in the tropical dermatology chapter that she took whilst working in Africa. Bernadette Byrne and the Plastics Team at King's College Hospital, London, UK, have provided the wound chapter photos in addition to some photographs retained from previous editions which come from the Victoria Hospital, Kirkcaldy and Queen Margaret Hospital, Dunfermline, Fife, the Royal Infirmary, Edinburgh and from Paul Buxton's own collection. Dr Jon Salisbury, a consultant histopathologist at King's College Hospital, London, UK, provided all the histopathology images to demonstrate cutaneous disease at the cellular level and Dr Edward Davies, consultant immunologist at King's College Hospital, London, UK, provided the direct immunofluorescence images of the skin in immunobullous disease.

I owe a huge debt of gratitude to all my Dermatology colleagues at King's College Hospital who diagnosed and managed many of the patients you will see in the illustrations in this Seventh Edition. I would specifically like to thank Dr Daniel Creamer, Dr Sarah Walsh, Dr Saqib Bashir and Prof Roderick Hay and Dr Tanya Basu.

I am especially indebted to all the patients for consenting to include their clinical images in the *ABC of Dermatology* to help us to demonstrate the features presenting in a multitude of skin/nail and hair disorders far better than any written description would do.

Dr Rachael Morris-Jones

CHAPTER 1

Introduction

Rachael Morris-Jones

Guy's and St Thomas' NHS Foundation Trust, London, UK

OVERVIEW

- The clinical features of skin lesions are related to the underlying pathological processes.
- Skin conditions broadly fall into three clinical groups: (i) those with a well-defined appearance and distribution; (ii) those with a characteristic pattern but with a variety of underlying clinical conditions; (iii) those with a variable presentation and no constant association with underlying conditions.
- Skin lesions may be the presenting feature of serious systemic disease, and a significant proportion of skin conditions threaten the health, well-being, and even the life of the patient.
- Clinical descriptive terms such as macule, papule, nodule, plaque, induration, atrophy, bulla, and erythema relate to what is observed at the skin surface and reflect the pathological processes underlying the affected skin.
- The significance of morphology and distribution of skin lesions in different clinical conditions are discussed.

Introduction

The aim of this book is to provide an insight for the non-dermatologist into the pathological processes, diagnosis, and management of skin conditions. Dermatology is a broad specialty, with over 2000 different skin diseases, the most common of which are introduced here.

Pattern recognition is key to successful history-taking and examination of the skin by experts, usually without the need for complex investigations. However, for those with less dermatological experience, working from first principles can go a long way in determining the diagnosis and management of patients with less severe skin disease. Although dermatology is a clinically oriented subject, an understanding of the cellular changes underlying the skin disease can give helpful insights into the pathological processes. This understanding aids the interpretation of clinical signs and overall management of cutaneous disease. Skin biopsies can be a useful adjuvant to reaching a diagnosis; however, clinico-pathological correlation is essential in order that interpretation of the clinical and pathological patterns is put into the context of the patient.

Interpretation of clinical signs on the skin in the context of underlying pathological processes is a theme running through the chapters. This helps the reader develop a deeper understanding of the subject and should form some guiding principles that can be used as tools to help assess almost any skin eruption.

Clinically, cutaneous disorders fall into three main groups.

1. Those that generally present with a characteristic distribution and morphology that leads to a specific diagnosis – such as chronic plaque psoriasis ([Figure 1.1](#)), basal cell carcinoma, and atopic dermatitis.
2. A characteristic pattern of skin lesions with variable underlying causes – such as erythema nodosum ([Figure 1.2](#)) and erythema multiforme.
3. Skin rashes that can be variable in their presentation and/or underlying causes – such as lichen planus and urticaria.

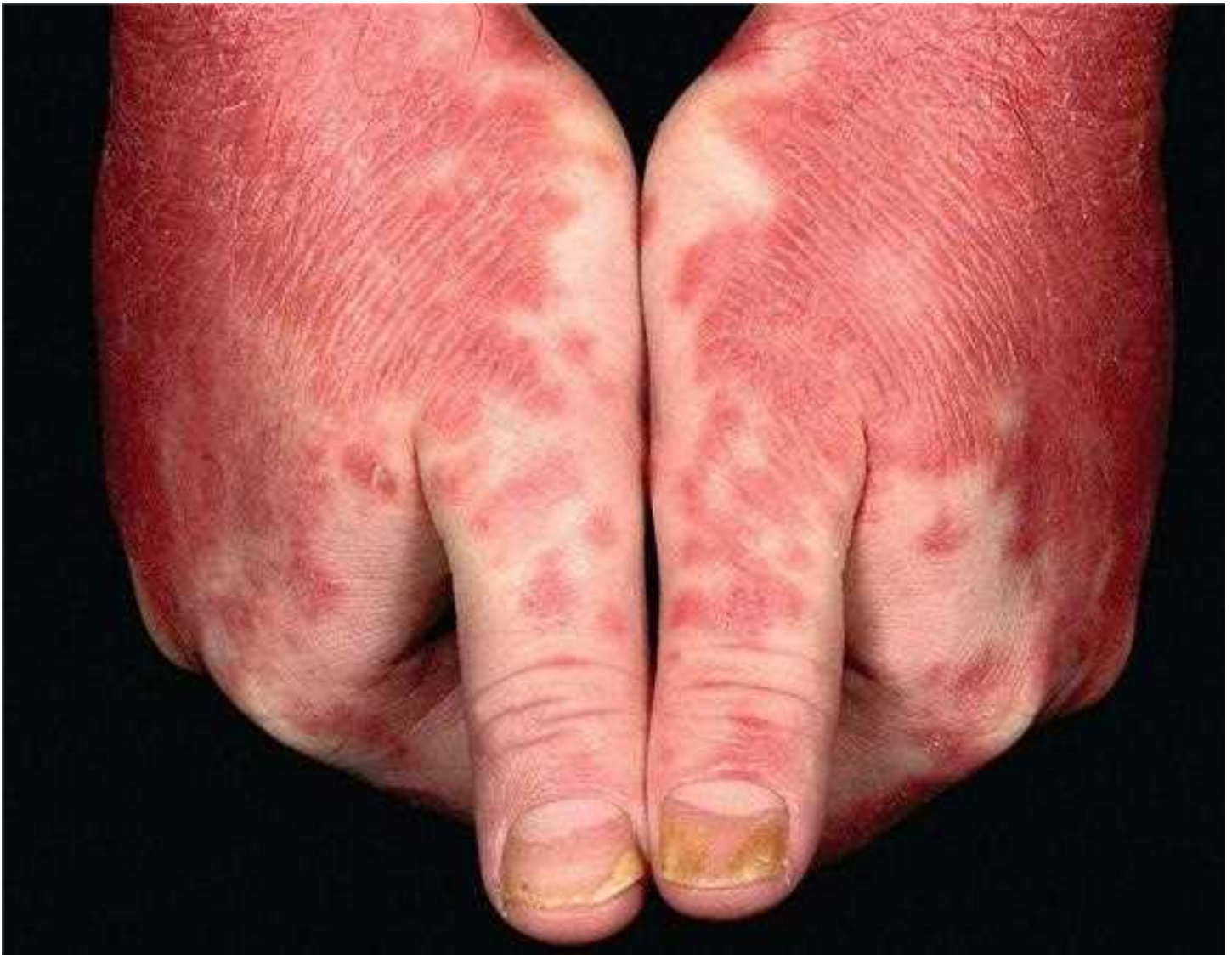

Figure 1.1 Psoriasis with nail changes.

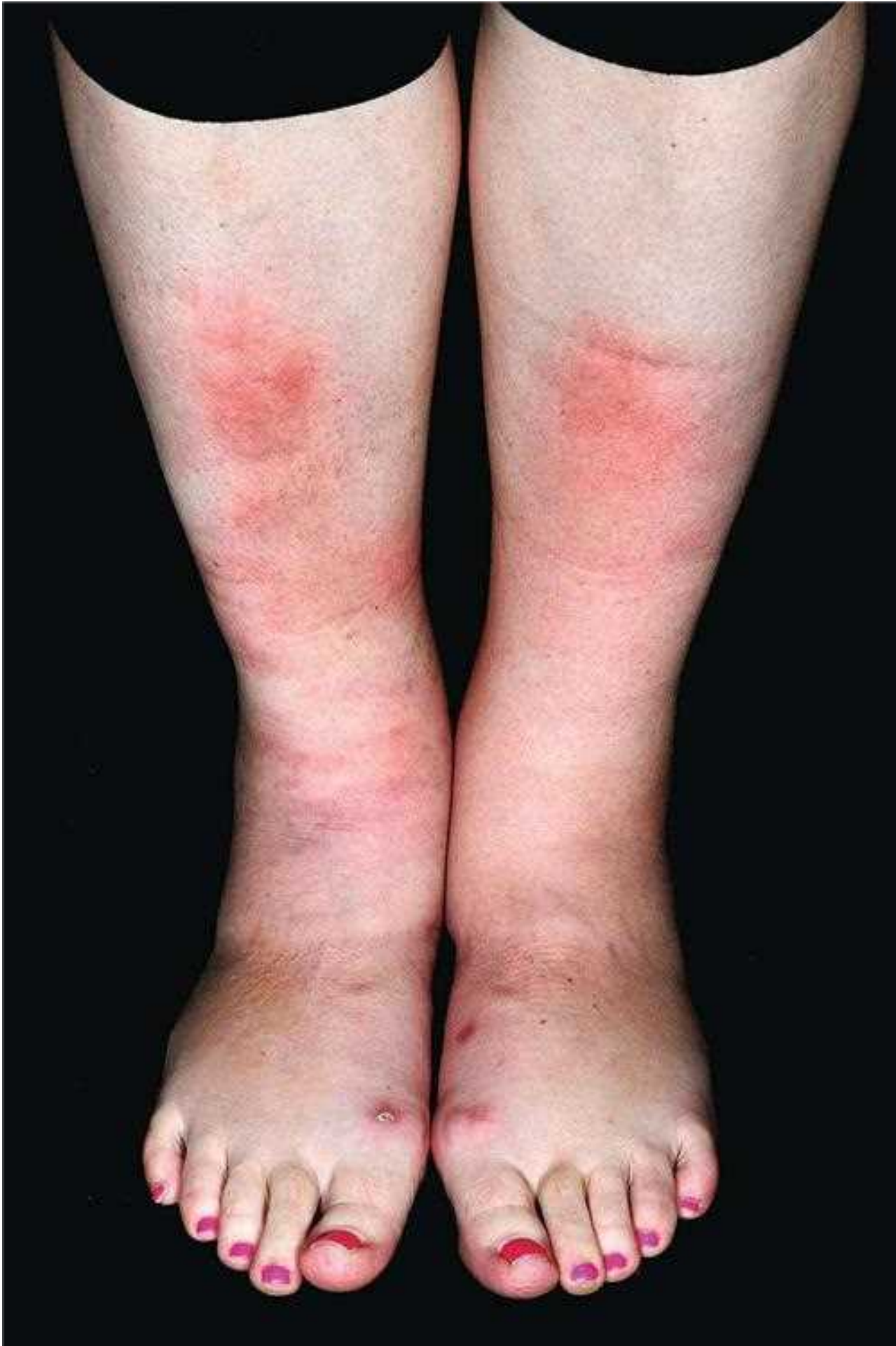

Figure 1.2 Erythema nodosum in pregnancy.

A holistic approach in dermatology is essential as cutaneous eruptions may be the first indicator of an underlying internal disease. Patients may, for example, first present with a photosensitive rash on the face, but deeper probing may reveal symptoms of joint pains etc. leading to the diagnosis of systemic lupus erythematosus. Similarly, a patient with underlying coeliac disease may first present with blistering on the elbows (dermatitis herpetiformis). It is therefore important not only to take a thorough history ([Box 1.1](#)) of the skin complaint but in addition to ask about any other symptoms the patient may have and examine the entire patient carefully.

Box 1.1 Dermatology history-taking

- Where – site of initial lesion(s) and subsequent distribution
- How long – continuous or intermittent?
- Trend – better or worse?
- Previous episodes – timing? Similar/dissimilar? Other skin conditions?
- Who else – Family members/work colleagues/school friends affected?
- Symptoms – Itching, burning, scaling, or blisters? Any medication or other illnesses?
- Treatment – prescription or over-the-counter? Frequency/time course/compliance?

The significance of skin disease

Seventy per cent of the people in developing countries suffer skin disease at some point in their lives, but of these, 3 billion people in 127 countries do not have access to even basic skin services. In developed countries the prevalence of skin disease is also high; up to 15% of general practice consultations in the United Kingdom are concerned with skin complaints. Many patients never seek medical advice and will use the internet to self-diagnose and self-treat using over-the-counter preparations.

The skin is the largest organ of the body; it provides an essential living biological barrier and is the aspect of ourselves that we present to the outside world. It is therefore not surprising that there is great interest in ‘skin care’ and ‘skin problems’, with an associated ever-expanding cosmetics industry and so-called cosmeceuticals. At the other end of the spectrum, impairment of the normal functions of the skin can lead to acute and chronic illness with considerable disability and sometimes the need for hospital treatment.

Malignant change can occur in any cell in the skin, resulting in a wide variety of different

tumours, the majority of which are benign. Recognition of typical benign tumours saves the patient unnecessary investigations and the anxiety involved in waiting to see a specialist or waiting for biopsy results. Malignant skin cancers are usually only locally invasive, but distant metastases can occur. It is important therefore to recognise the early features of lesions such as melanoma ([Figure 1.3](#)) and squamous cell carcinoma before they disseminate.

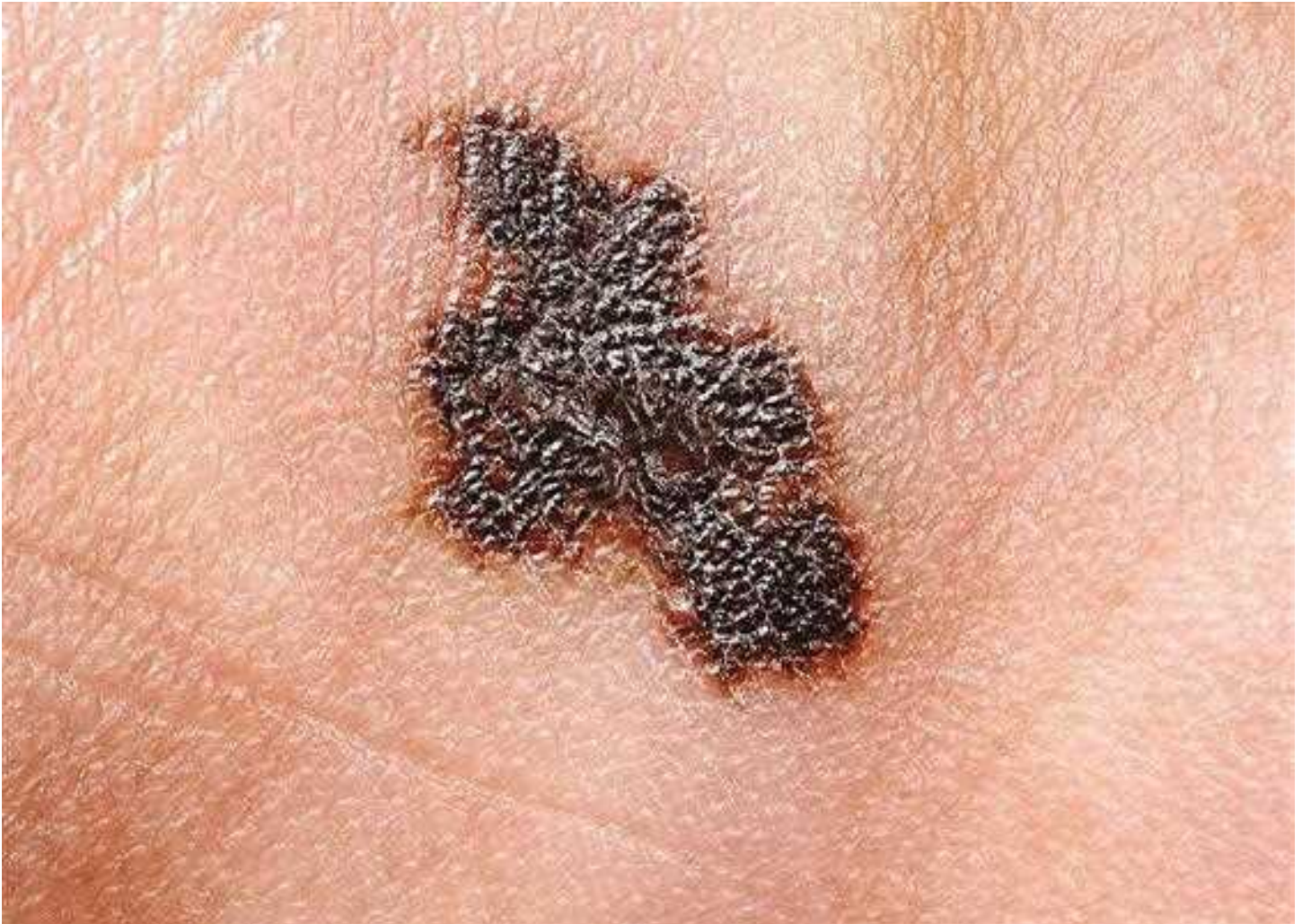

Figure 1.3 Superficial spreading melanoma.

Underlying systemic disease can be heralded by changes on the skin surface, the significance of which can be easily missed by the unprepared mind. So, in addition to concentrating on the skin changes, the overall health and demeanour of the patient should be assessed. Close inspection of the whole skin, nails, and mucous membranes should be the basis of routine skin examination. The general physical condition of the patient should also be determined as indicated.

Most skin diseases, however, do not signify any systemic disease and are often considered 'harmless' in medical terms. However, due to the very visual nature of skin disorders, they can cause a great deal of psychological distress, social isolation, and occupational difficulties, which should not be underestimated. A validated measure of how much skin disease affects patients' lives can be made using the Dermatology Life Quality Index (DLQI). A holistic

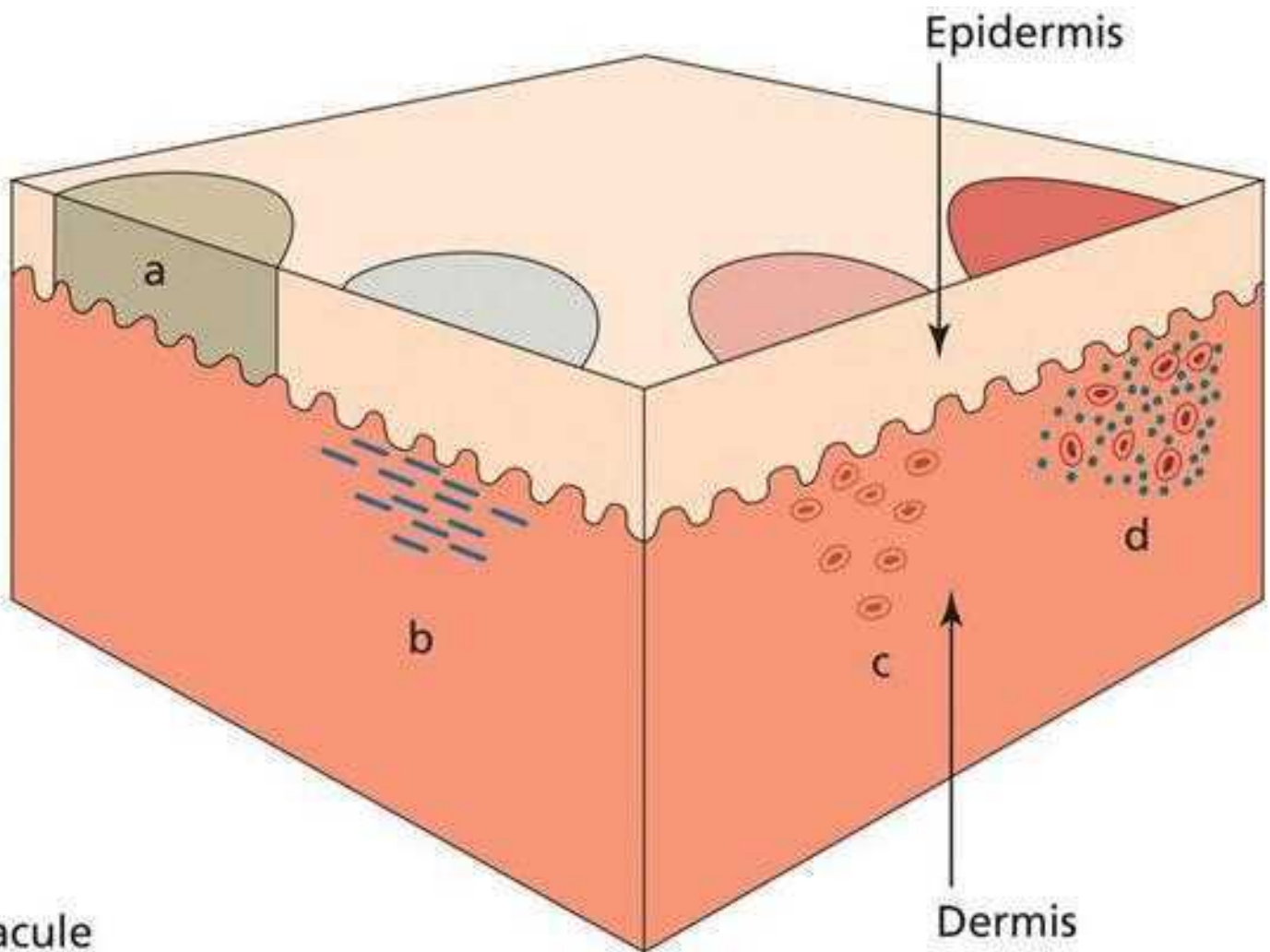
approach to the patient both physically and psychologically is therefore highly desirable.

Descriptive terms of clinical inspection

All specialties have their own common terms, and familiarity with a few of those used in dermatology aids with diagnostic skills as they relate to the underlying pathology. The most important are defined below.

- *Macule* ([Figure 1.4](#)). Derived from the Latin for a stain, the term *macule* is used to describe changes in colour ([Figure 1.5](#)) without any elevation above the surface of the surrounding skin. There may be an increase in pigments such as melanin, giving a black or brown colour. Loss of melanin leads to a white macule. Vascular dilatation and inflammation produce erythema. A macule with a diameter greater than 2 cm is called a *patch*.
- *Papules and nodules* ([Figure 1.6](#)). A *papule* is a circumscribed, raised lesion, of epidermal or dermal origin, 0.5–1.0 cm in diameter ([Figure 1.7](#)). A *nodule* ([Figure 1.8](#)) is similar to a papule but greater than 1.0 cm in diameter. A vascular papule or nodule is known as a *haemangioma*.
- A *plaque* ([Figure 1.9](#)) is a circumscribed, superficial, elevated plateau area 1.0–2.0 cm in diameter ([Figure 1.10](#)).
- *Vesicles and bullae* ([Figure 1.11](#)) are raised lesions that contain clear fluid (blisters) ([Figure 1.12](#)). A *bulla* is a vesicle larger than 0.5 cm. They may be superficial within the epidermis or situated in the dermis below it. The more superficial the vesicles/bullae, the more likely they are to break open.
- *Lichenification* is a hard thickening of the skin with accentuated skin markings ([Figure 1.13](#)). It commonly results from chronic inflammation and rubbing of the skin.
- *Discoid lesions*. These are ‘coin-shaped’ lesions ([Figure 1.14](#)).
- *Pustules*. The term *pustule* is applied to lesions containing purulent material – which may be due to infection – or sterile pustules (inflammatory polymorphs) ([Figure 1.15](#)) that are seen in pustular psoriasis and pustular drug reactions.
- *Atrophy* refers to loss of tissue, which may affect the epidermis, dermis, or subcutaneous fat. Thinning of the epidermis is characterised by loss of normal skin markings; there may be fine wrinkles, loss of pigment and a translucent appearance ([Figure 1.16](#)). In addition, sclerosis of the underlying connective tissue, telangiectasia or evidence of diminished blood supply may be present.
- *Ulceration* results from the loss of the whole thickness of the epidermis and upper dermis ([Figure 1.17](#)). Healing results in a scar.
- *Erosion*. An erosion is a superficial loss of epidermis that generally heals without scarring ([Figure 1.18](#)).

- *Excoriation* is the partial or complete loss of epidermis as a result of scratching ([Figure 1.19](#)).
- *Crusted*. Dry serous fluid forming a crust (underlying epidermis or dermis is usually disrupted) ([Figure 1.20](#)).
- *Fissuring*. Fissures are slits through the whole thickness of the skin.
- *Desquamation* is the peeling of superficial scales, often following acute inflammation ([Figure 1.21](#)).
- *Annular lesions* are ring-shaped ([Figure 1.22](#)).
- *Reticulate*. The term *reticulate* means ‘net-like’. It is most commonly seen when the pattern of subcutaneous blood vessels becomes visible ([Figure 1.23](#)).



Macule

- Melanin pigment *in* epidermis
- Melanin pigment *below* epidermis
- Erythema due to dilated dermal blood vessels
- Inflammation in dermis

Figure 1.4 Section through skin.

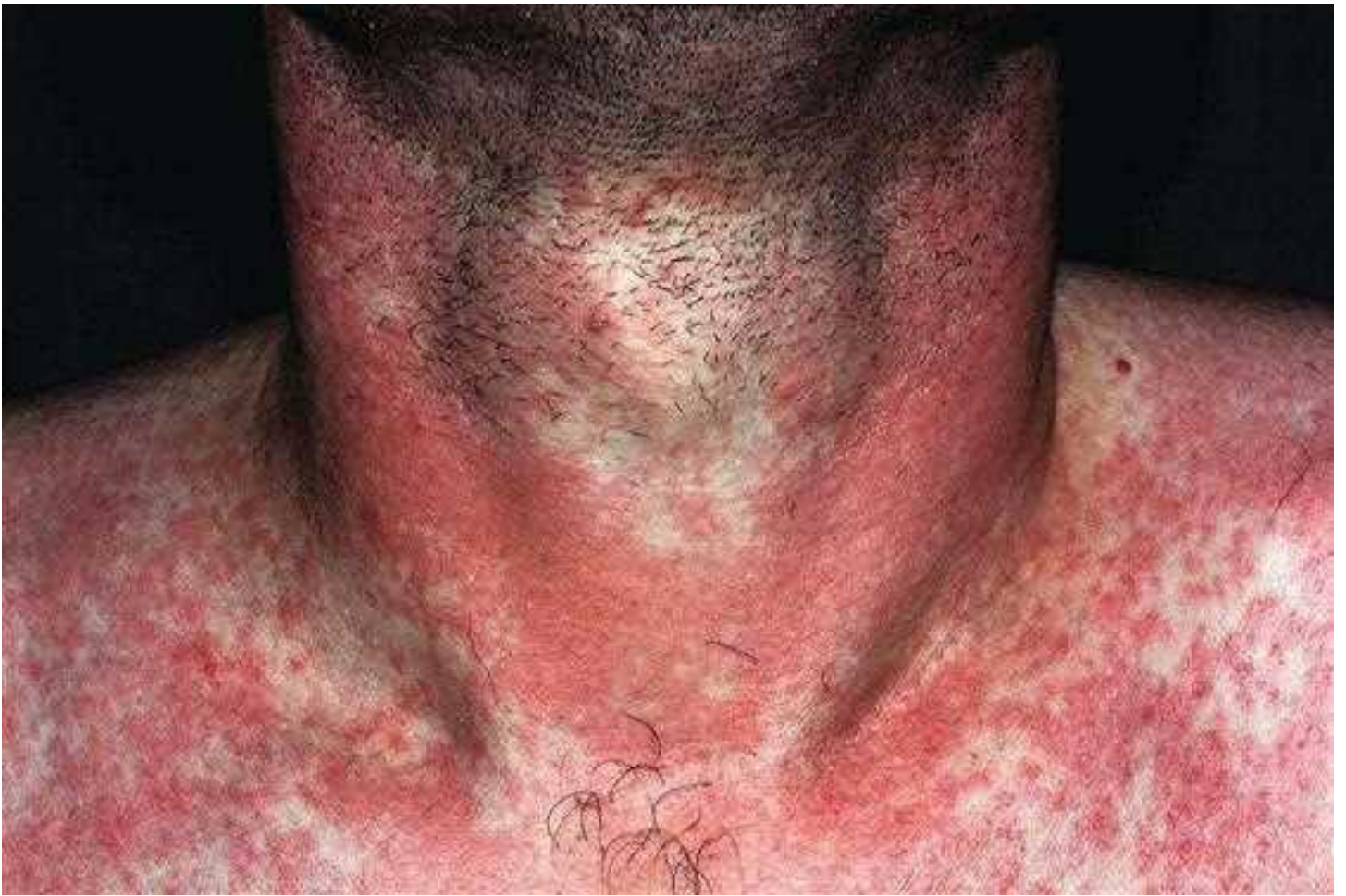

Figure 1.5 Erythema due to a drug reaction.

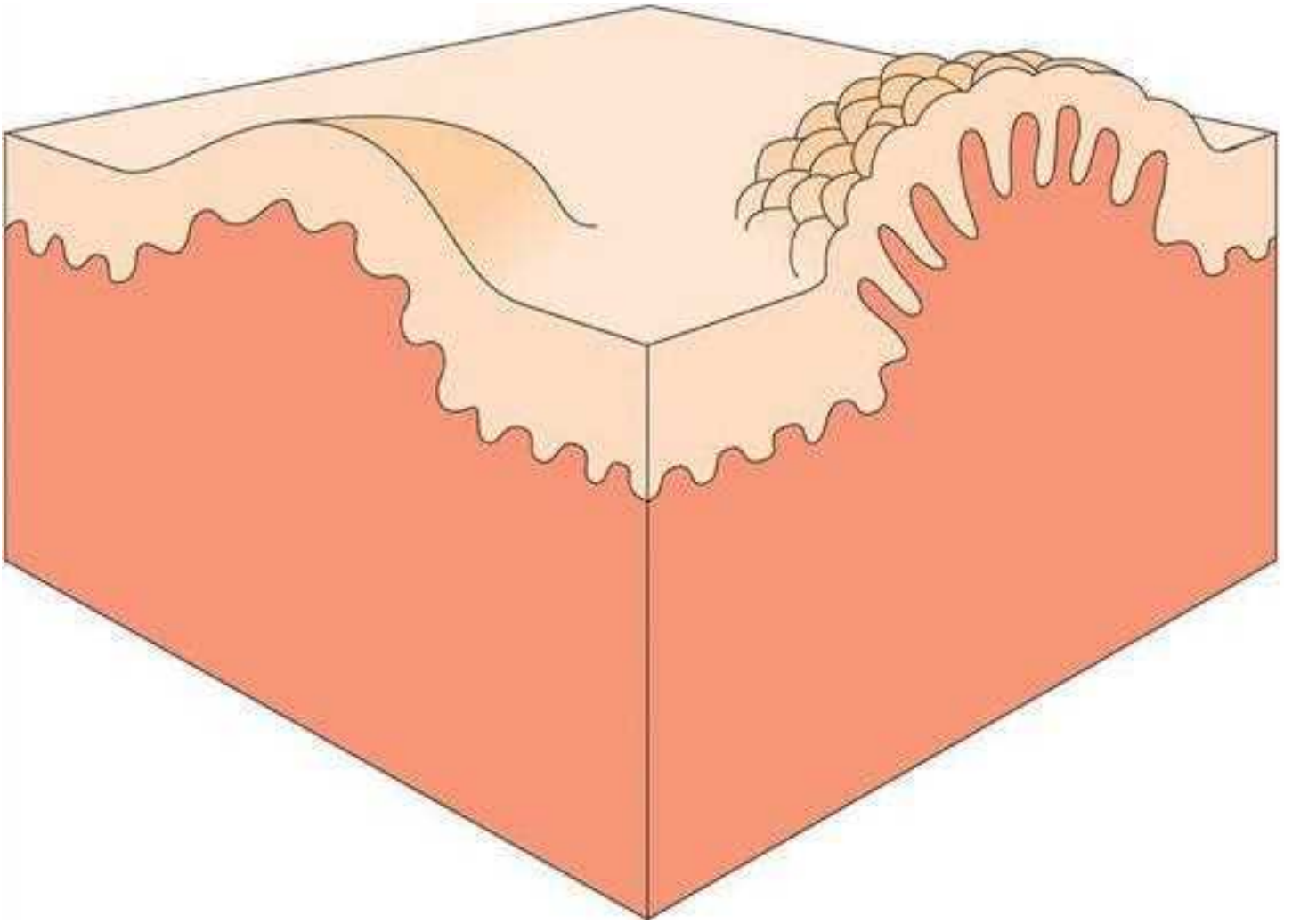


Figure 1.6 Section through skin with a papule.

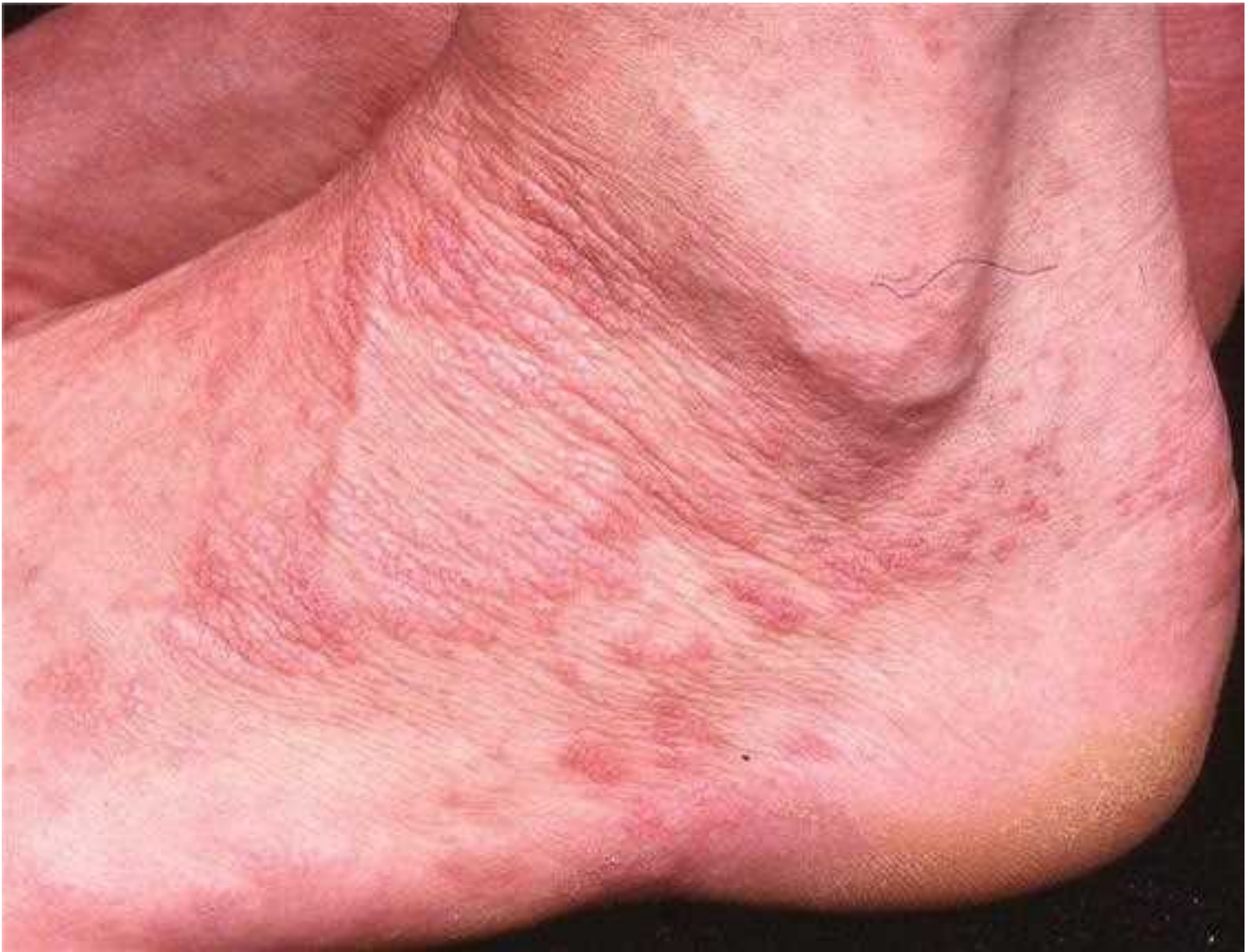

Figure 1.7 Papules in lichen planus.

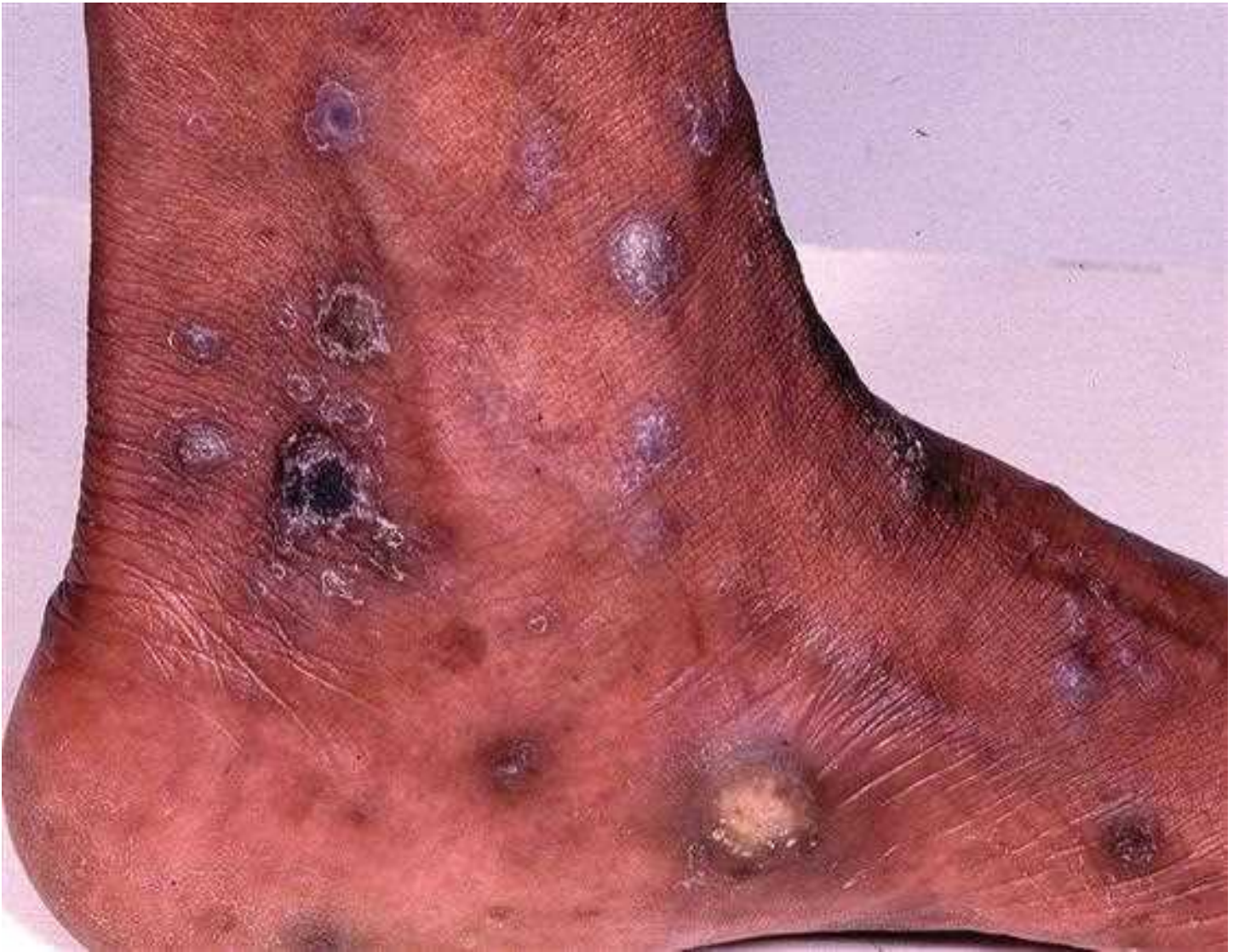

Figure 1.8 Nodules in hypertrophic lichen planus.

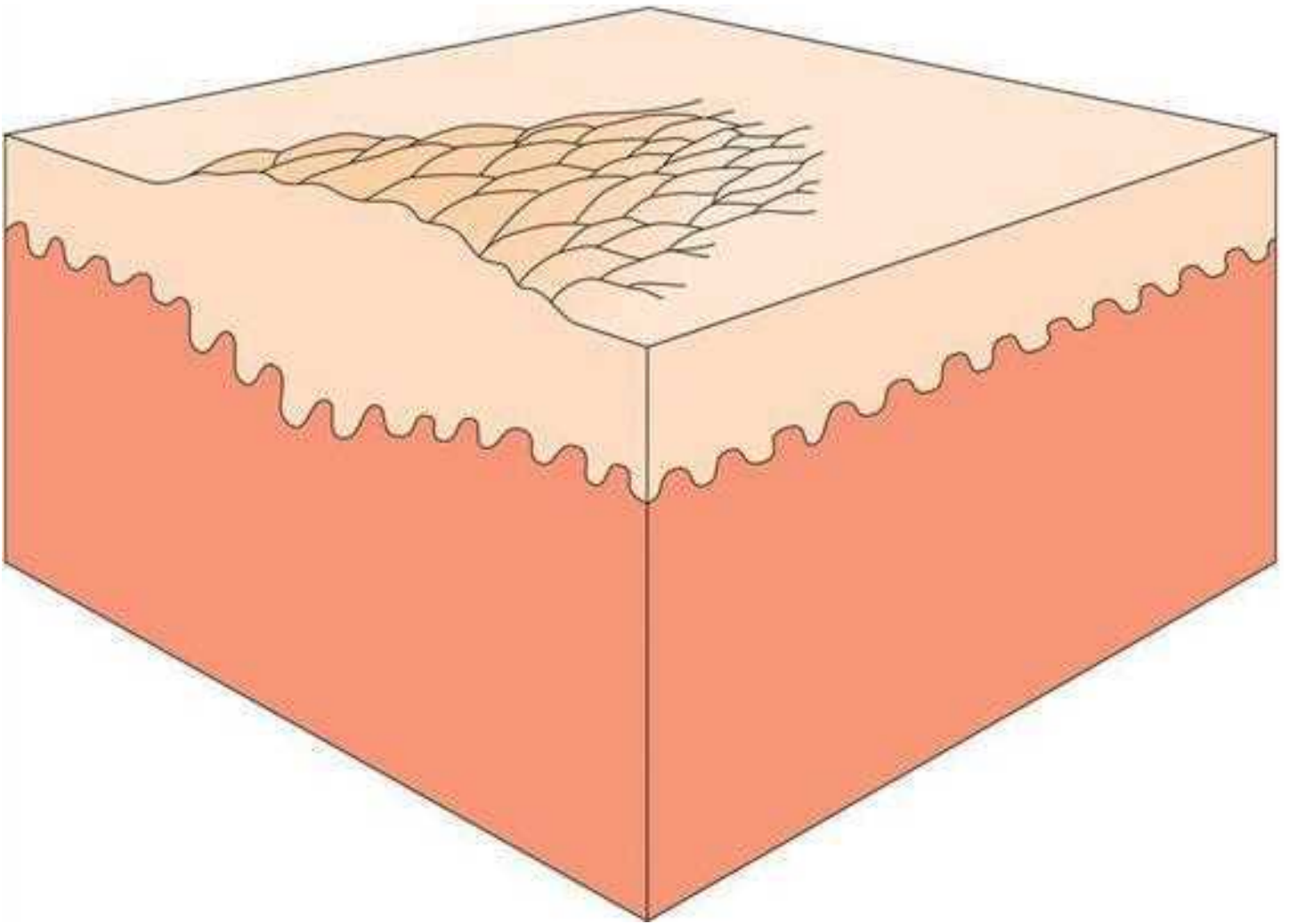


Figure 1.9 Section through skin with plaque.

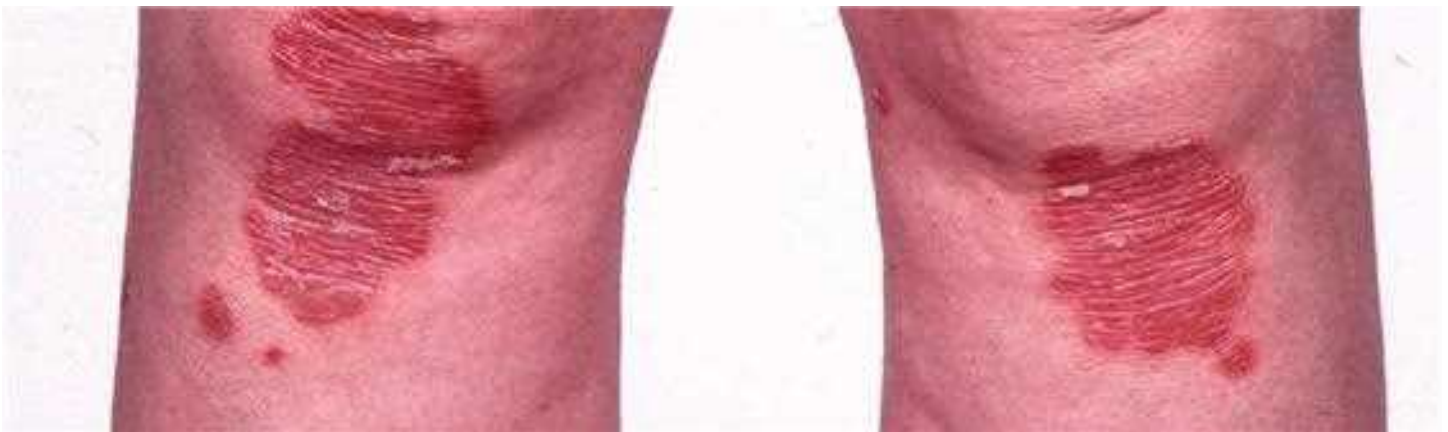

Figure 1.10 Psoriasis plaques on the knees.

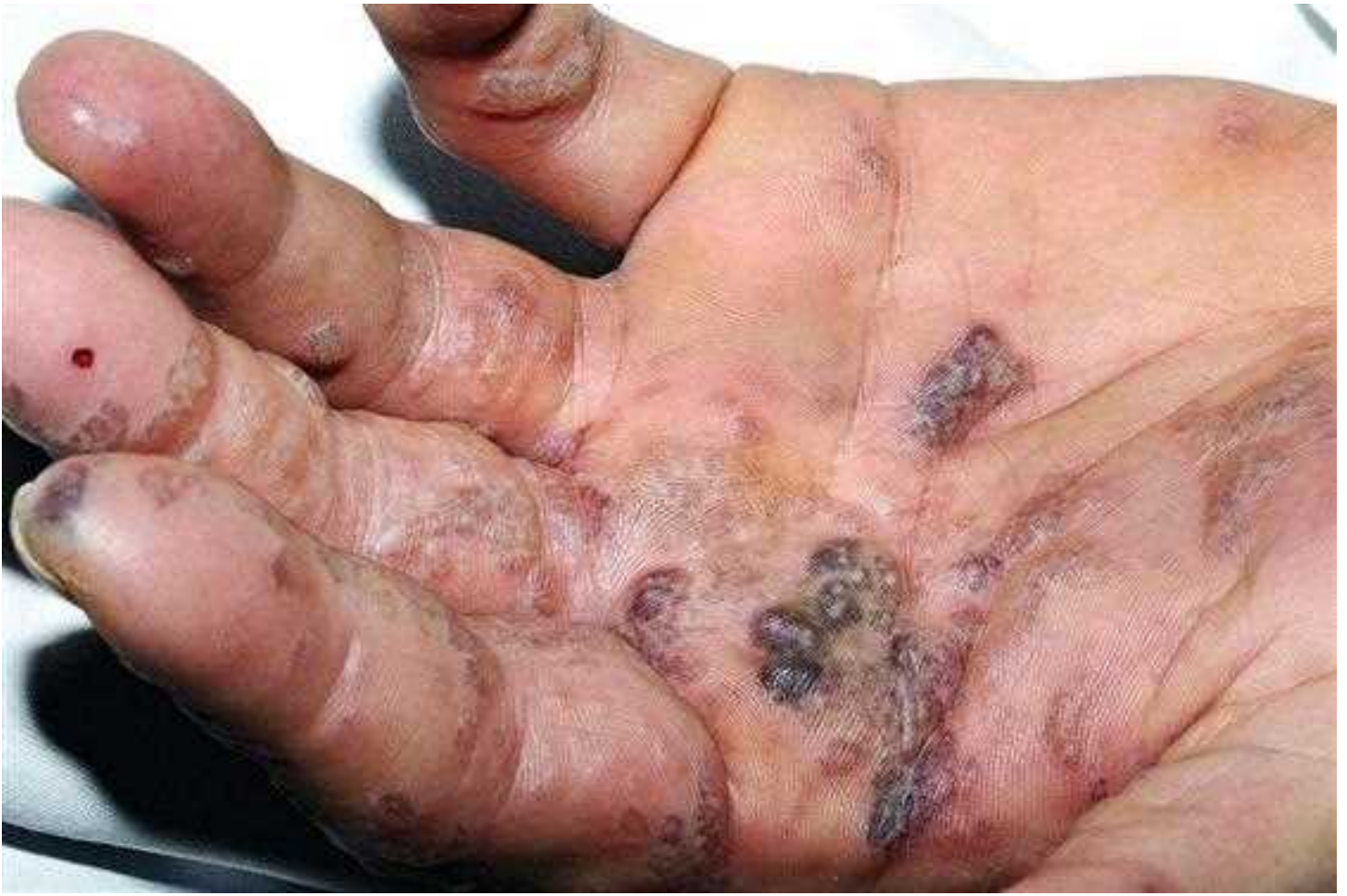

Figure 1.11 Bullae on the palm from multidermatomal shingles.

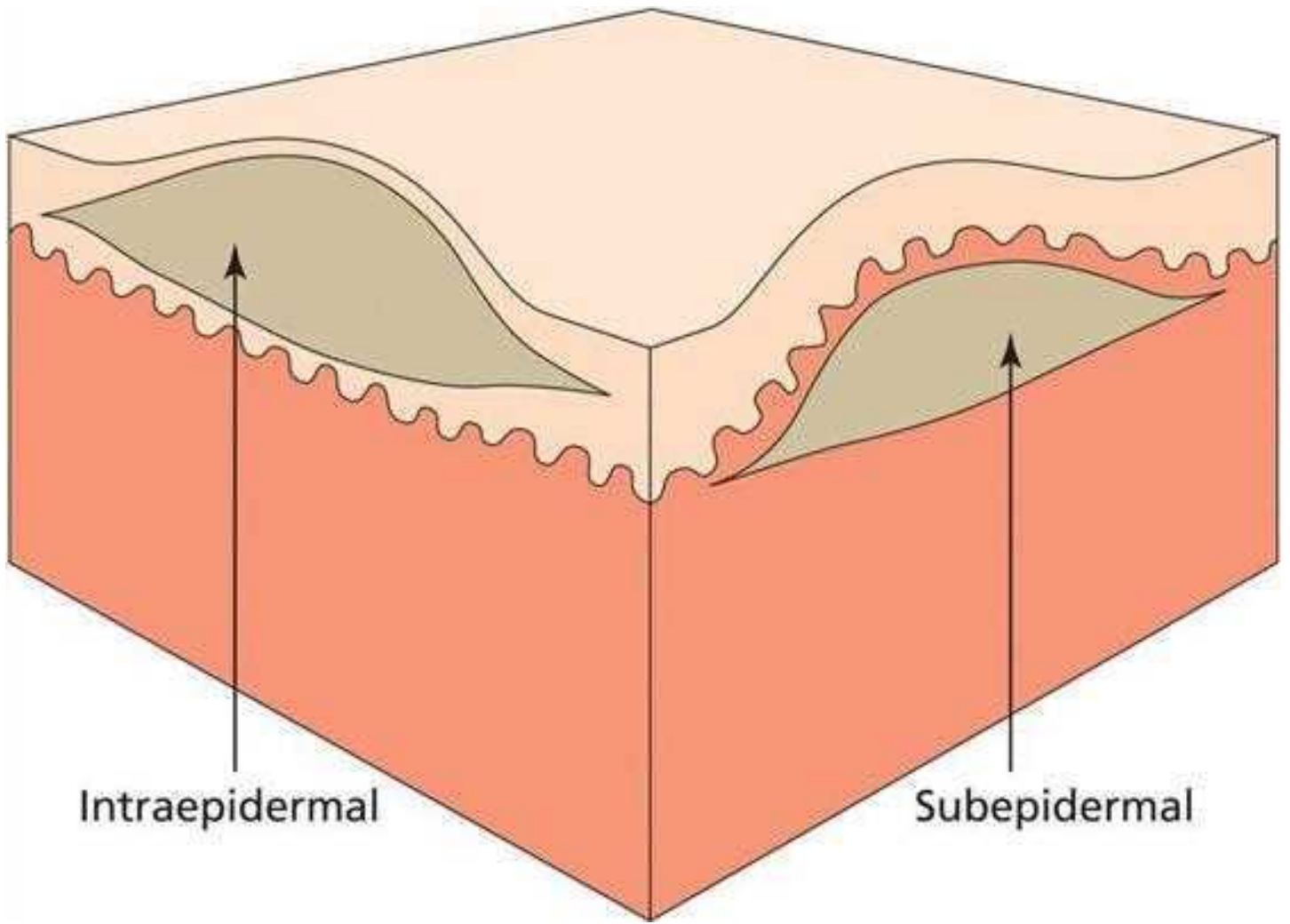


Figure 1.12 Section through skin showing sites of vesicle and bulla.

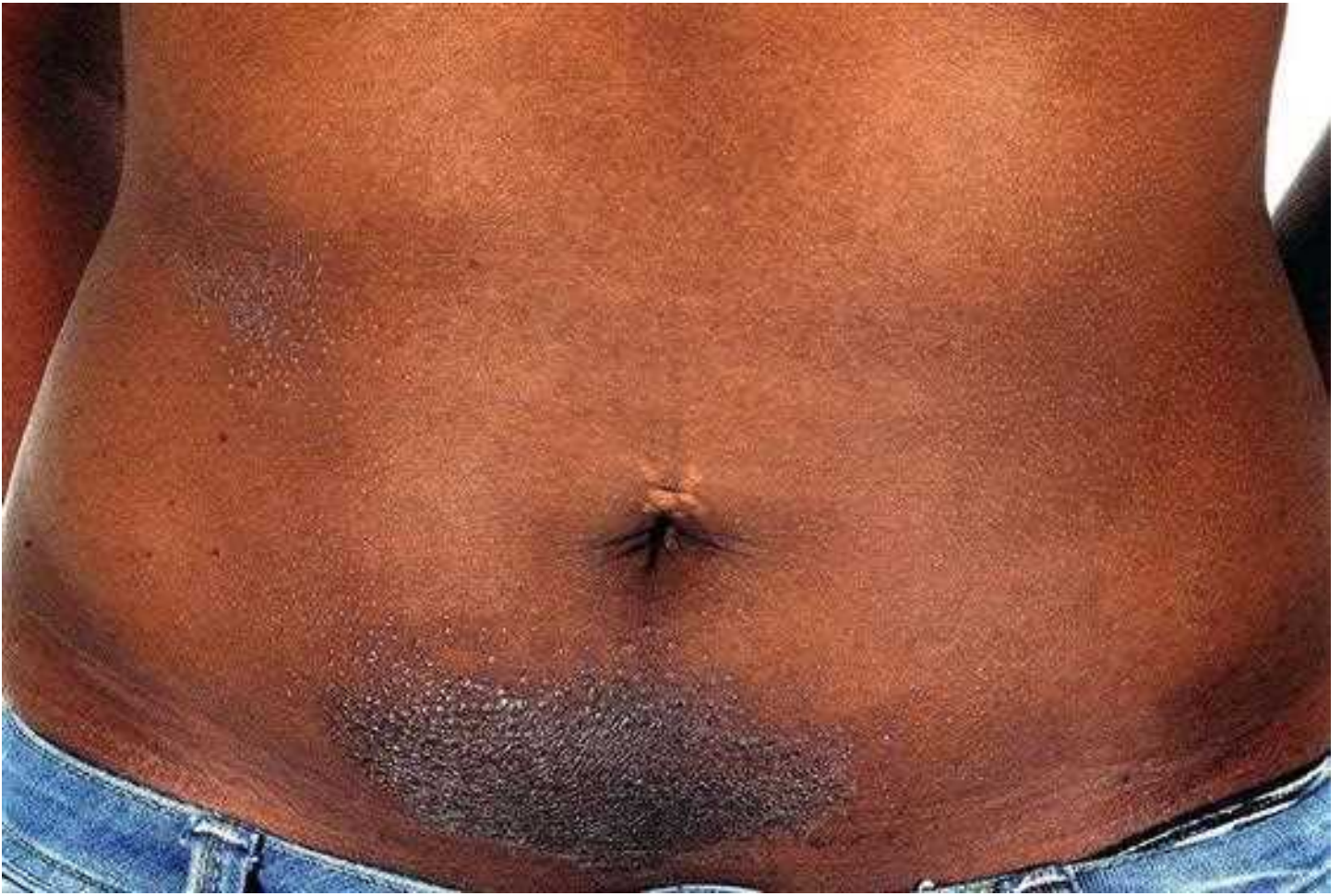

Figure 1.13 Lichenification due to chronic eczema in nickel allergy.

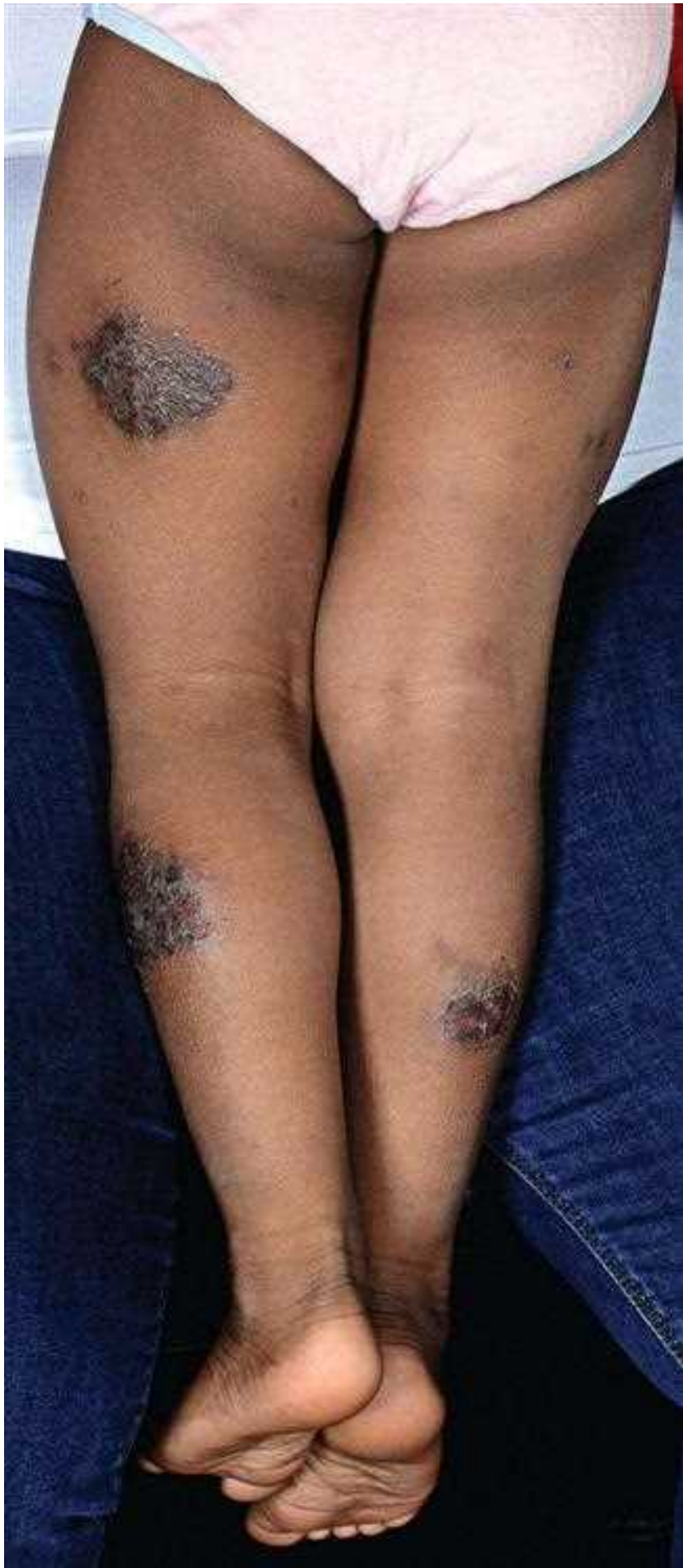

Figure 1.14 Discoid lesions in discoid eczema.

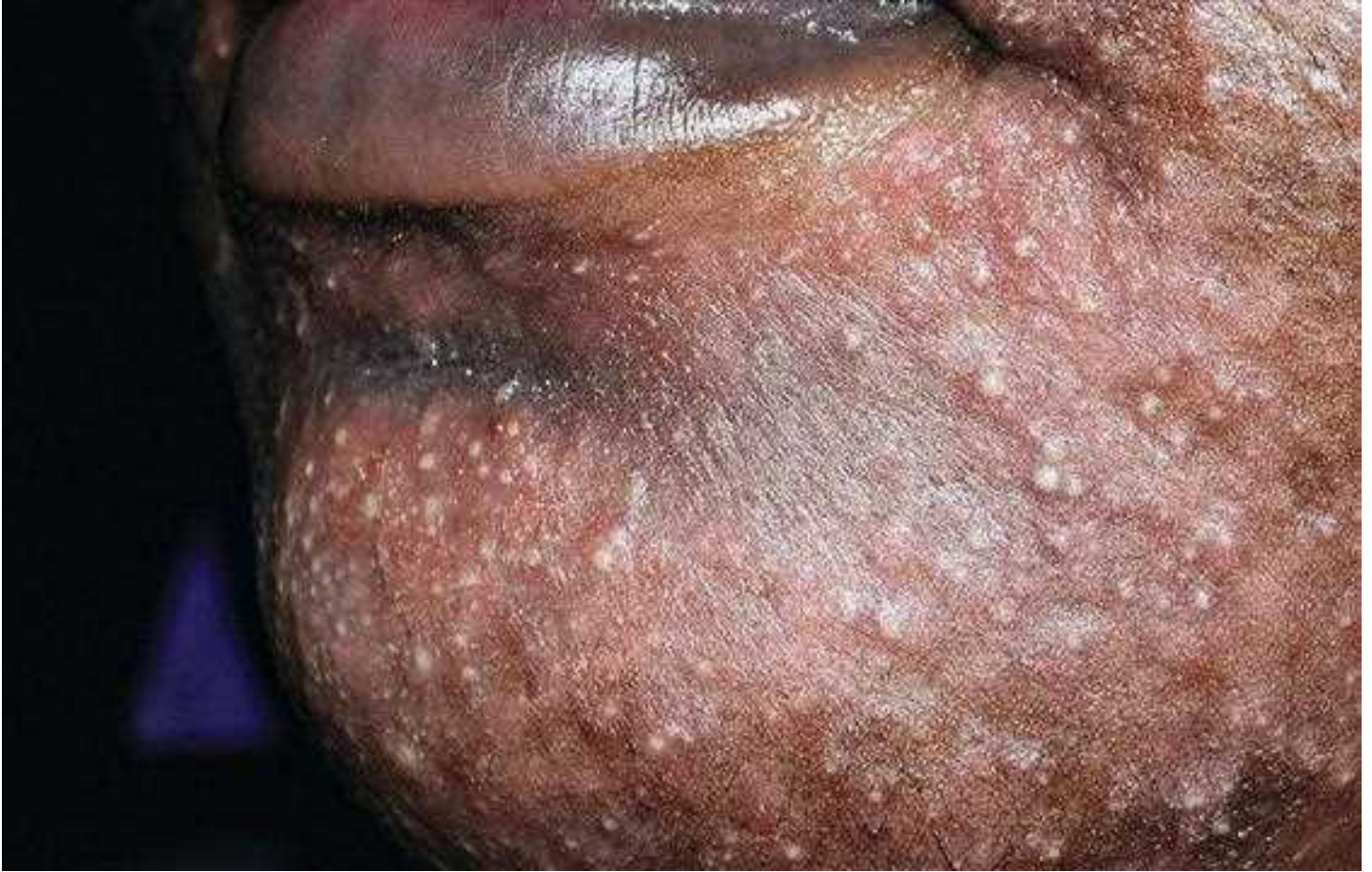

Figure 1.15 Inflammatory pustules secondary to contact dermatitis with Argon oil.

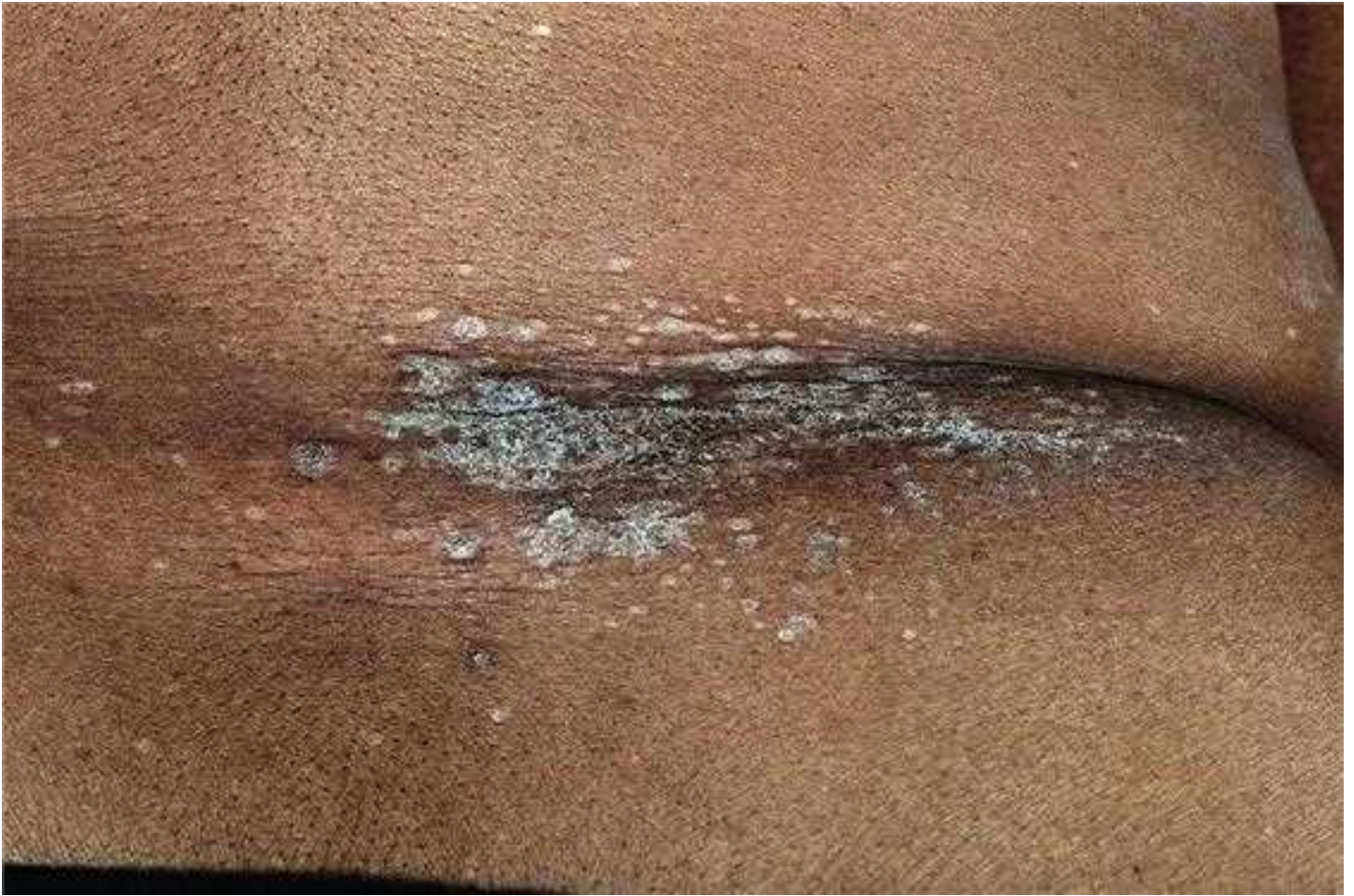

Figure 1.16 Epidermal atrophy in extra-genital lichen sclerosus.

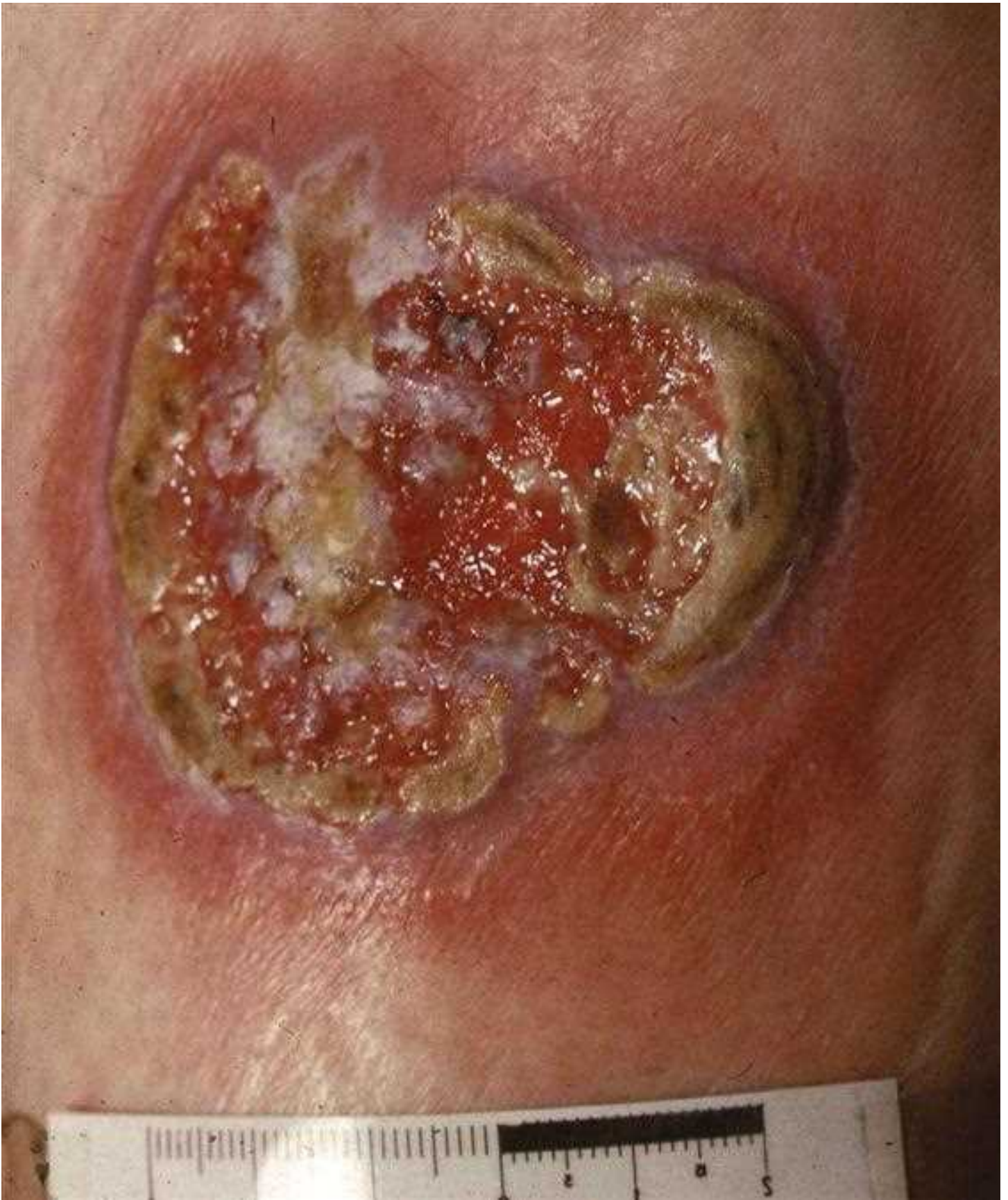

Figure 1.17 Ulceration in pyoderma gangrenosum.

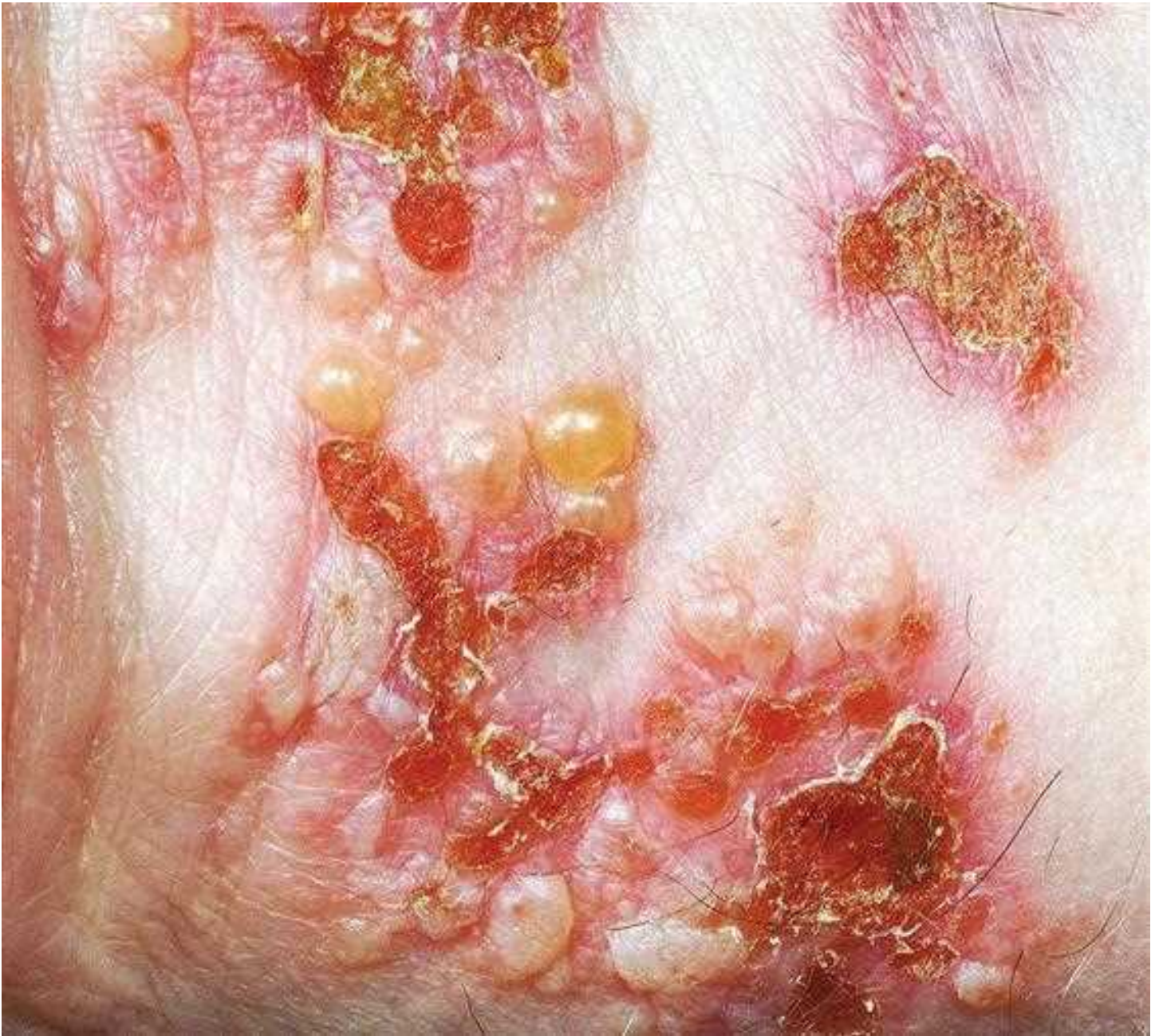
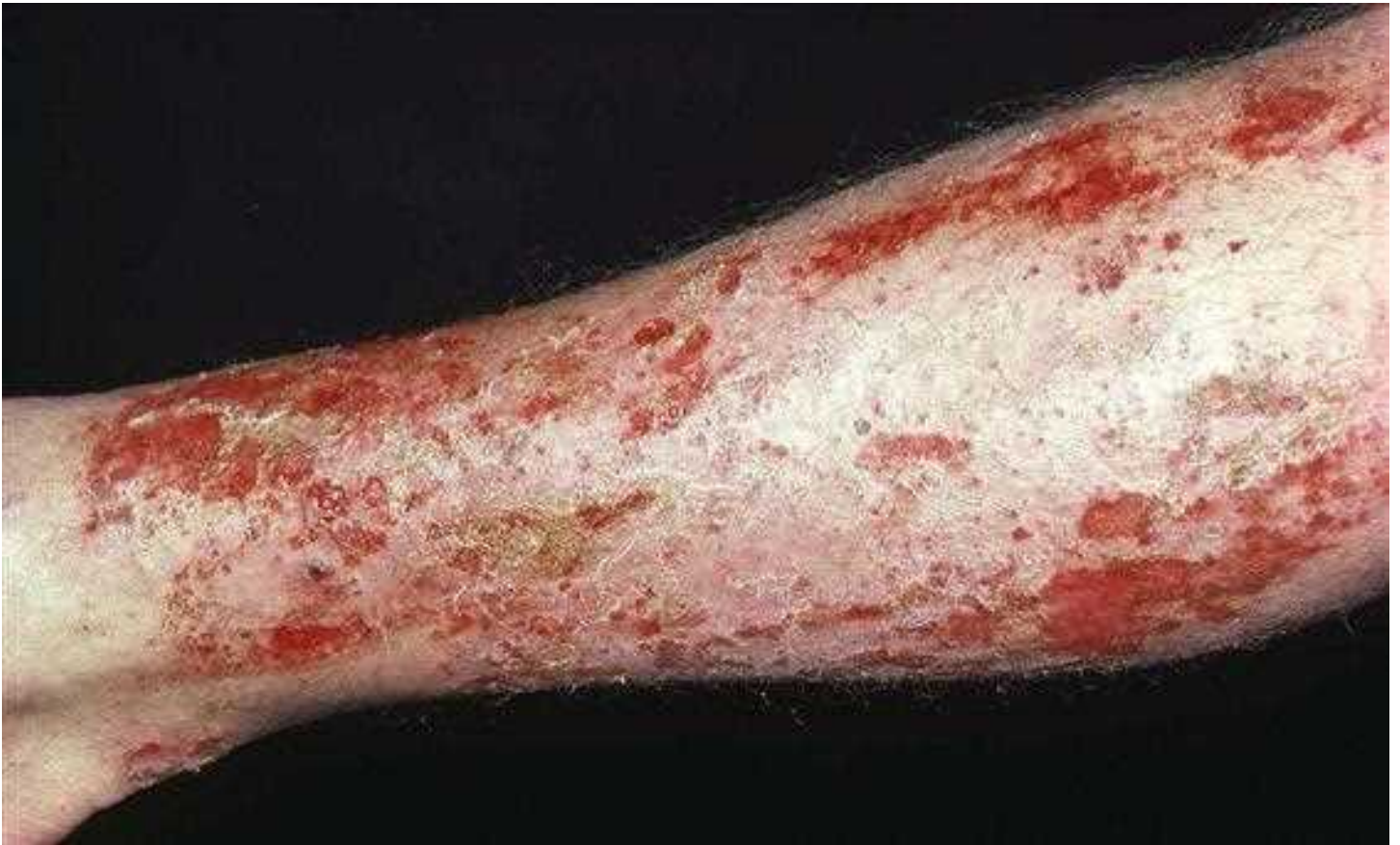
Figure 1.18 Erosions (loss of epidermis) in paraneoplastic bullous pemphigoid.



[Figure 1.19](#) Excoriation of epidermis in atopic dermatitis.

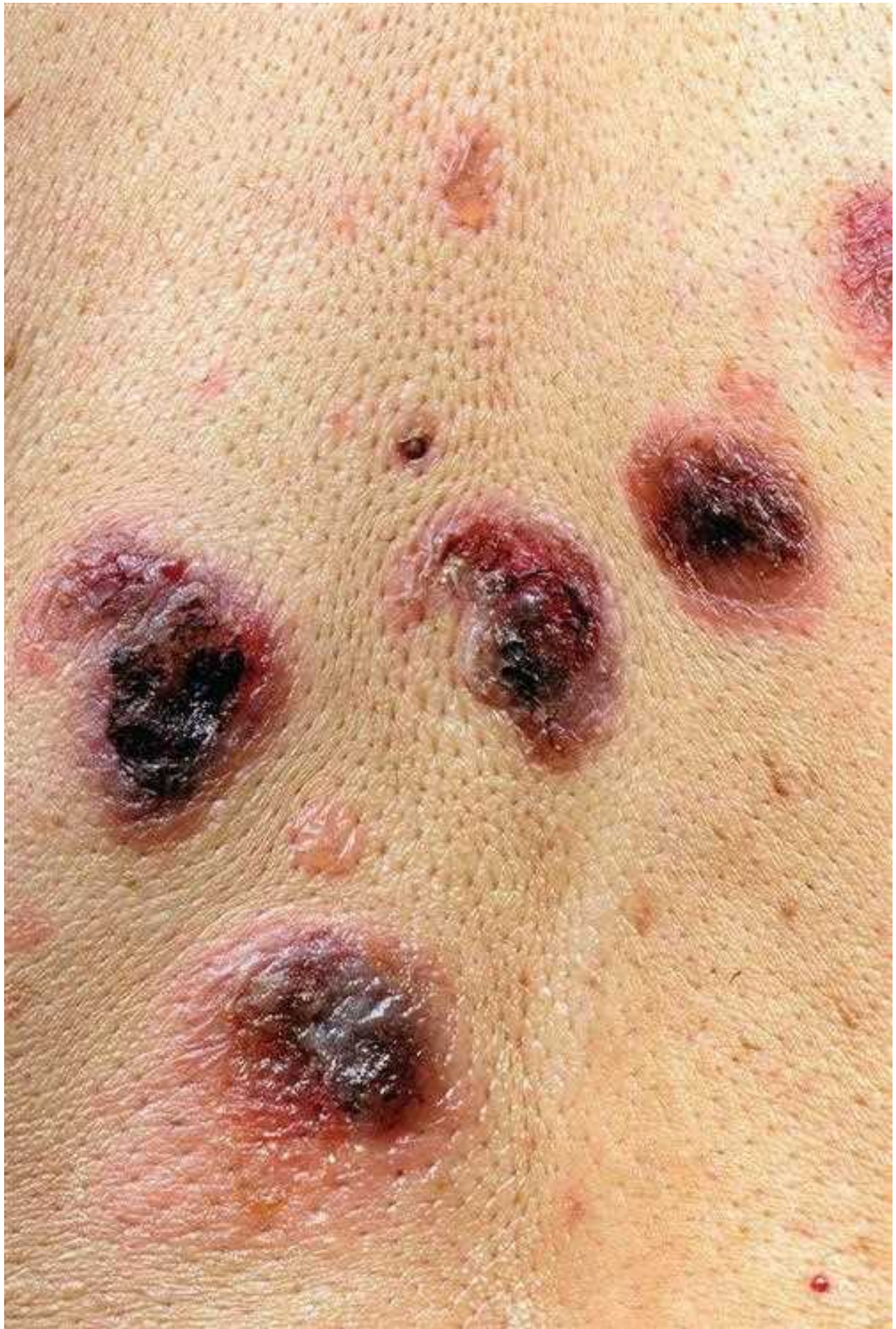

Figure 1.20 Crusted lesions in pemphigus vulgaris.

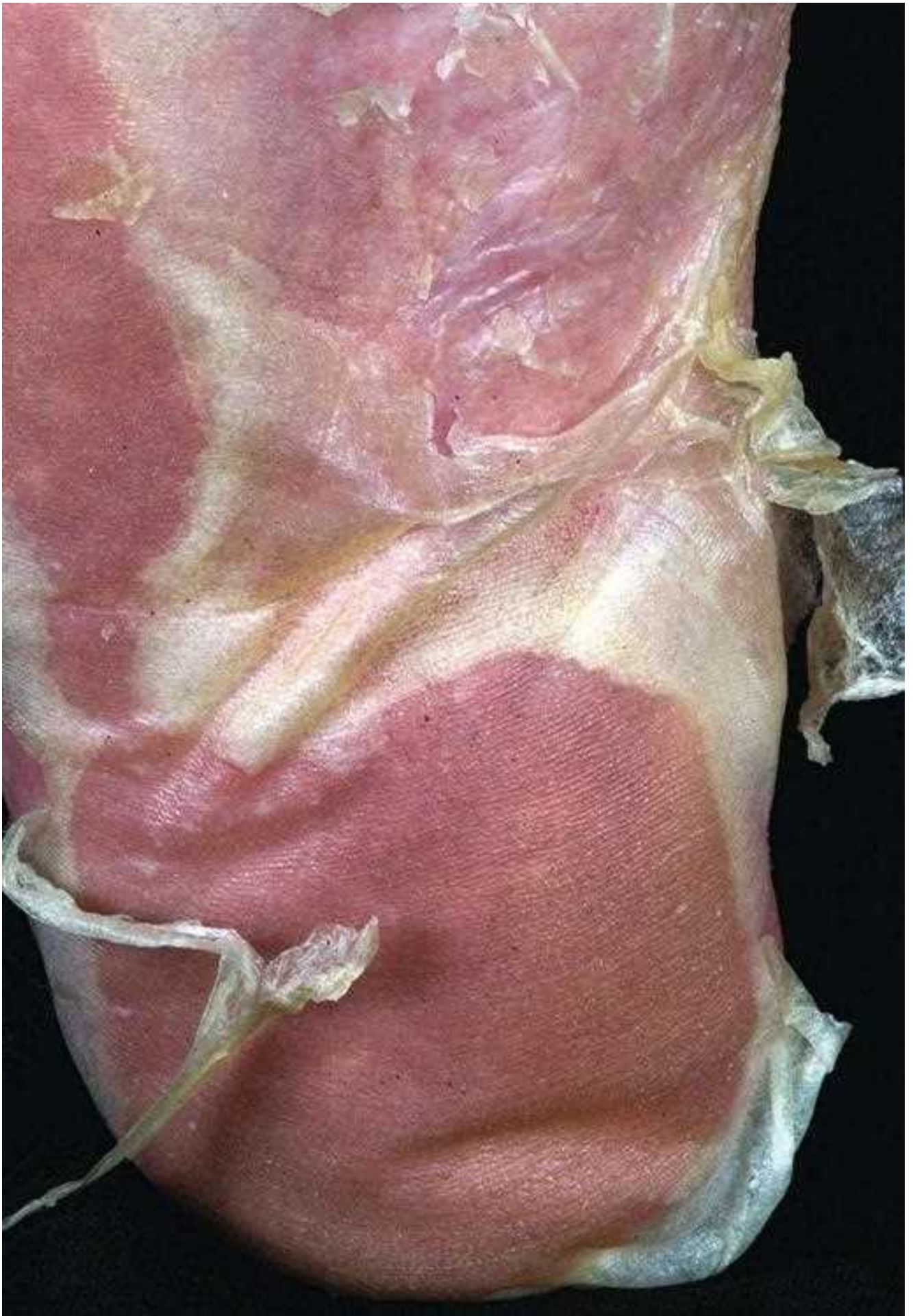

Figure 1.21 Desquamation following a severe drug reaction.

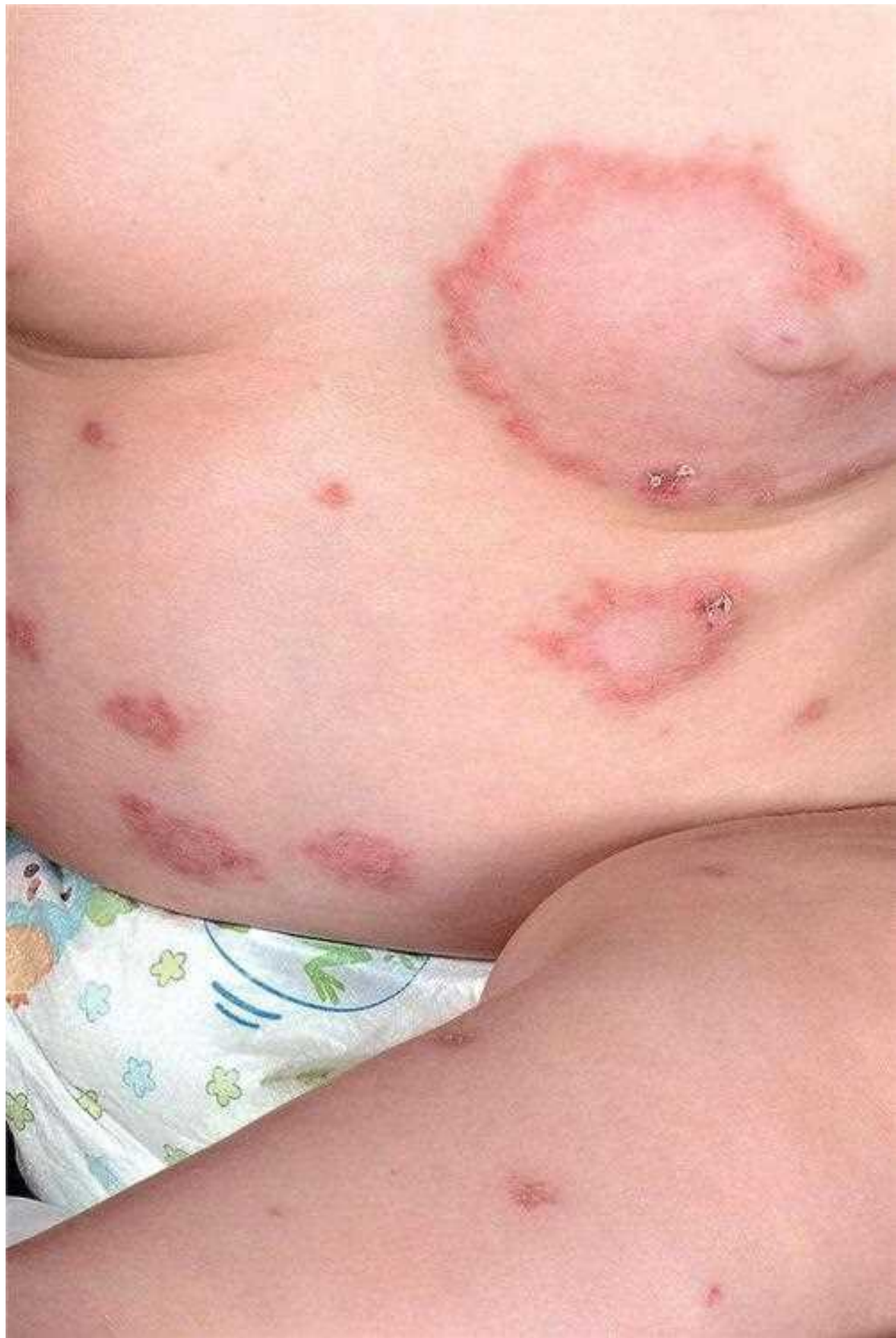

Figure 1.22 Annular (ring-shaped) lesions in neonatal lupus.

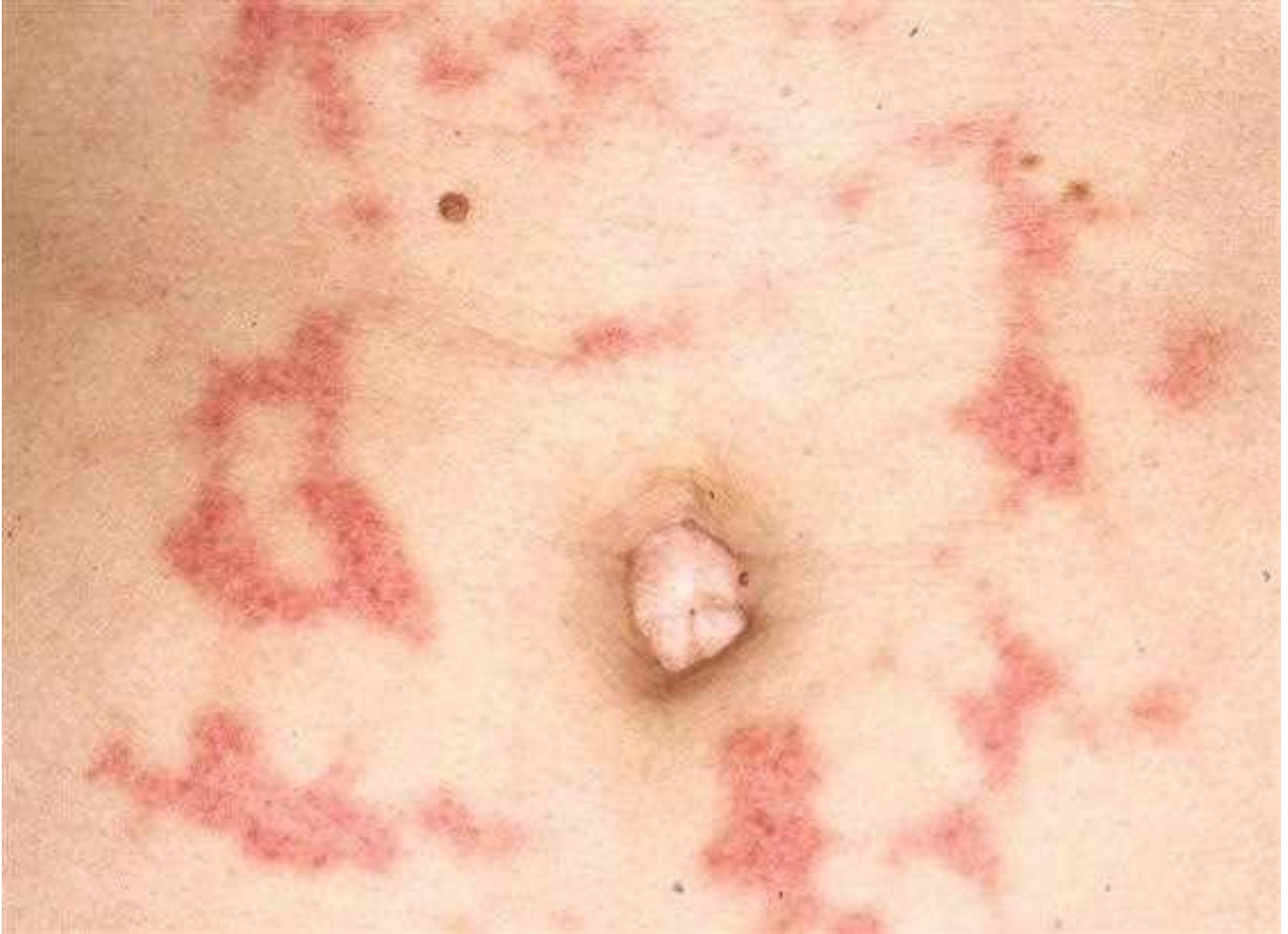

Figure 1.23 Reticulate pattern in vasculitis.

Clinical approach to the diagnosis of rashes

A skin rash generally poses more problems in diagnosis than a single, well-defined skin lesion such as a wart or tumour. As in all branches of medicine, a reasonable diagnosis is more likely to be reached by thinking firstly in terms of broad diagnostic categories rather than specific conditions.

There may be a history of recurrent episodes such as occurs in atopic eczema due to the patient's constitutional tendency. In the case of contact dermatitis, regular exposure to a causative agent leads to recurrences that fit from the history with exposure times. Endogenous conditions such as psoriasis can appear in adults who have had no previous episodes. If several members of the same family are affected by a skin rash simultaneously then a contagious condition, such as scabies, should be considered. A common condition with a familial tendency, such as atopic eczema, may affect several family members at different times.

A simplistic approach to rashes is to classify them as being from the ‘inside’ or ‘outside’. Examples of ‘inside’ or endogenous rashes are atopic eczema or drug rashes, whereas fungal infection or contact dermatitis are ‘outside’ or exogenous rashes.

Symmetry

As a general rule, most endogenous rashes affect both sides of the body, as in the atopic child, psoriasis on the legs or cutaneous T-cell lymphoma ([Figure 1.24](#)). Of course, not all exogenous rashes are asymmetrical. Chefs who hold the knife in their dominant hand can have unilateral disease ([Figure 1.25](#)) from metal allergy whereas a hairdresser or nurse may develop contact dermatitis on both hands, and a builder bilateral contact dermatitis from kneeling in cement ([Figure 1.26](#)).

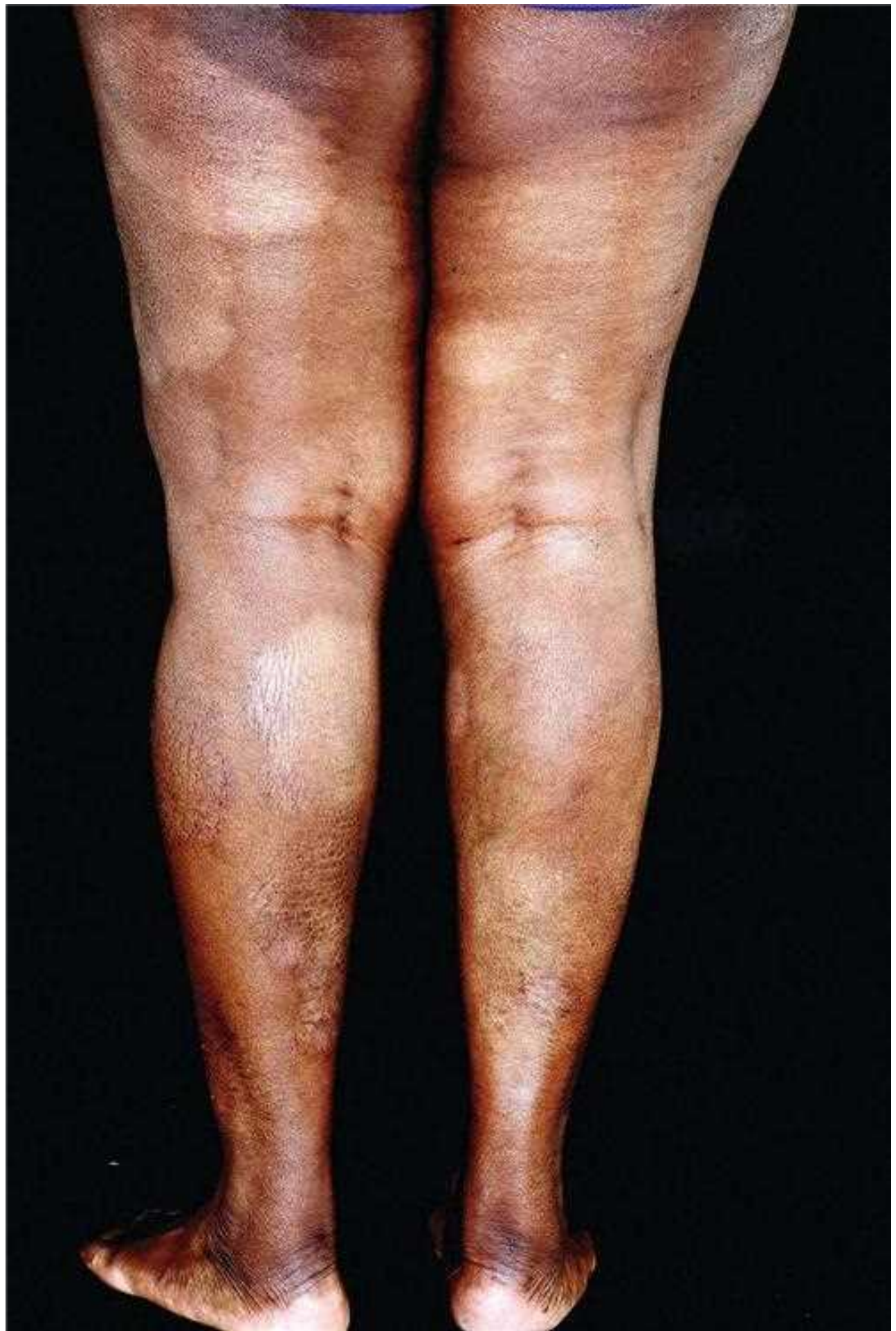
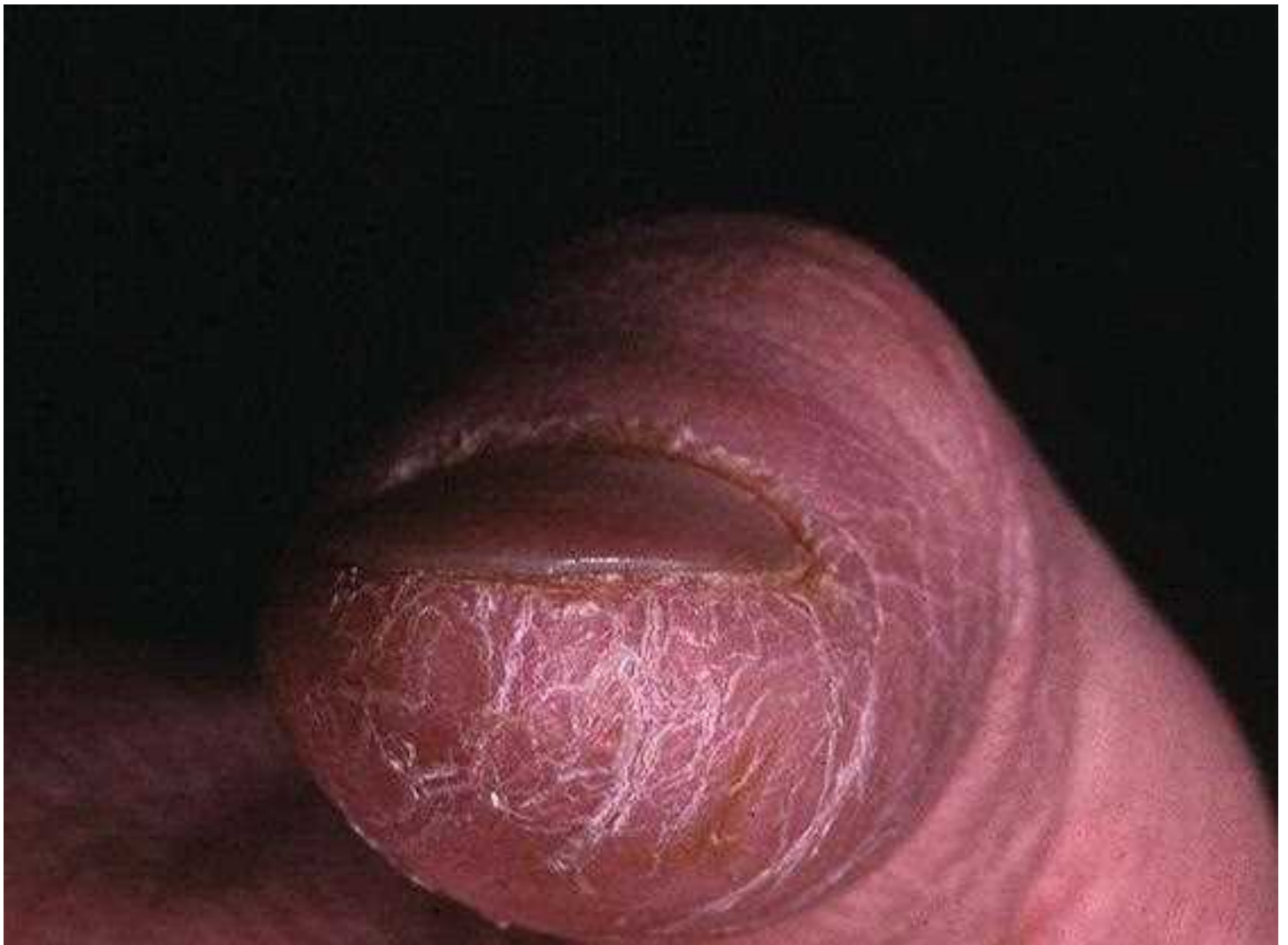
Figure 1.24 Symmetrical hypopigmented plaques of cutaneous T-cell lymphoma.



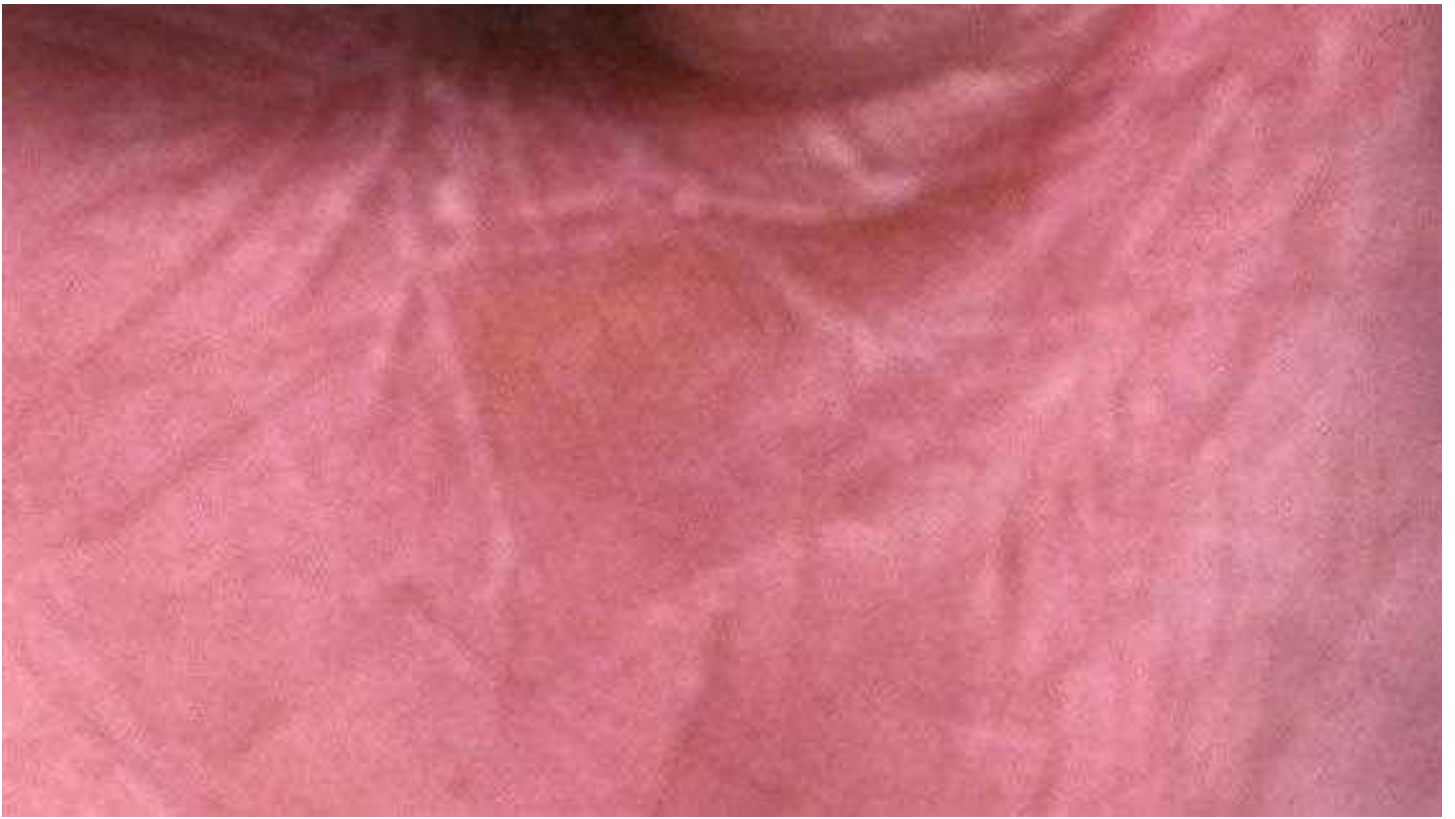

Figure 1.25 Irritant eczema on dominant hand of chef.

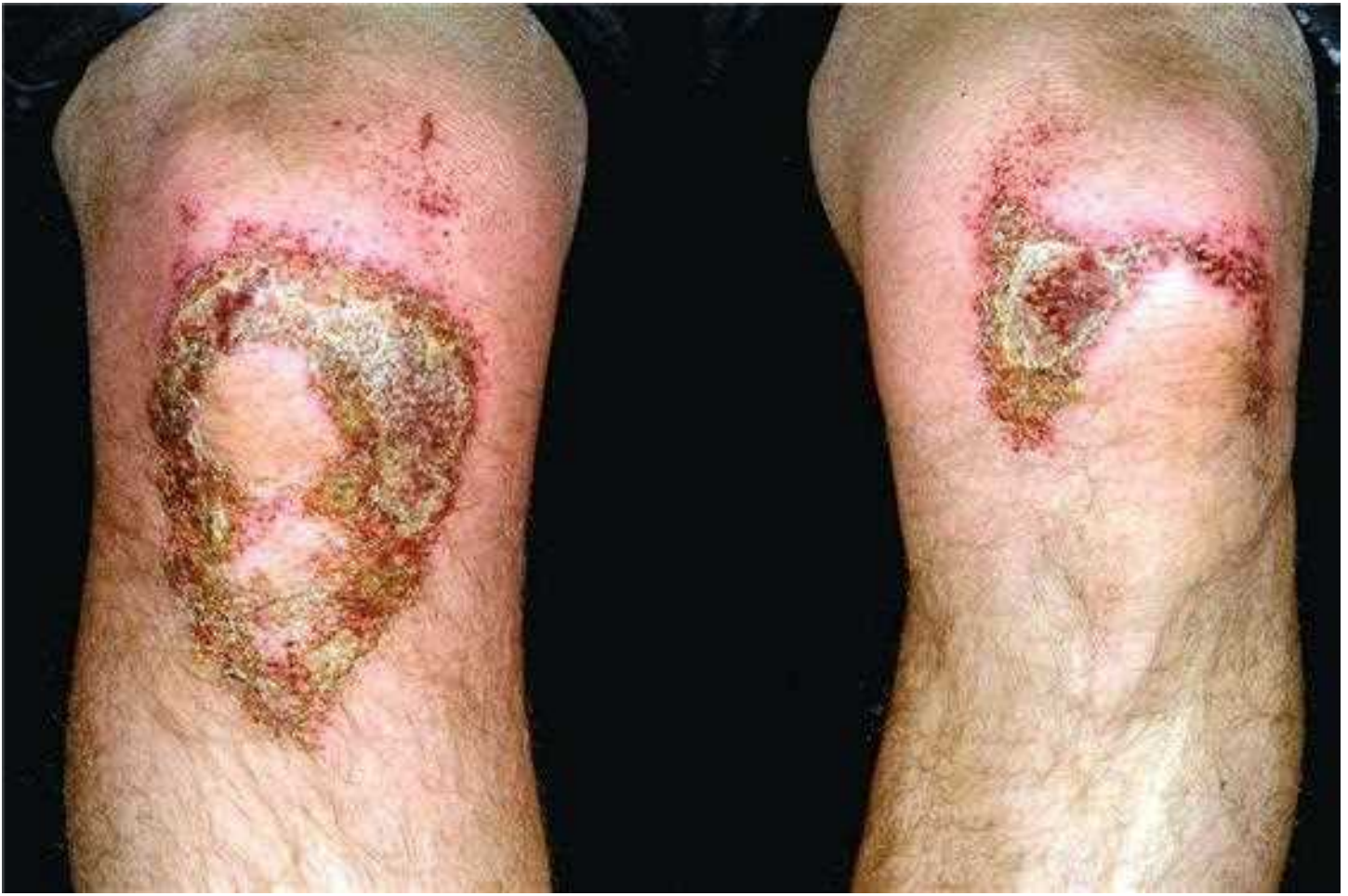
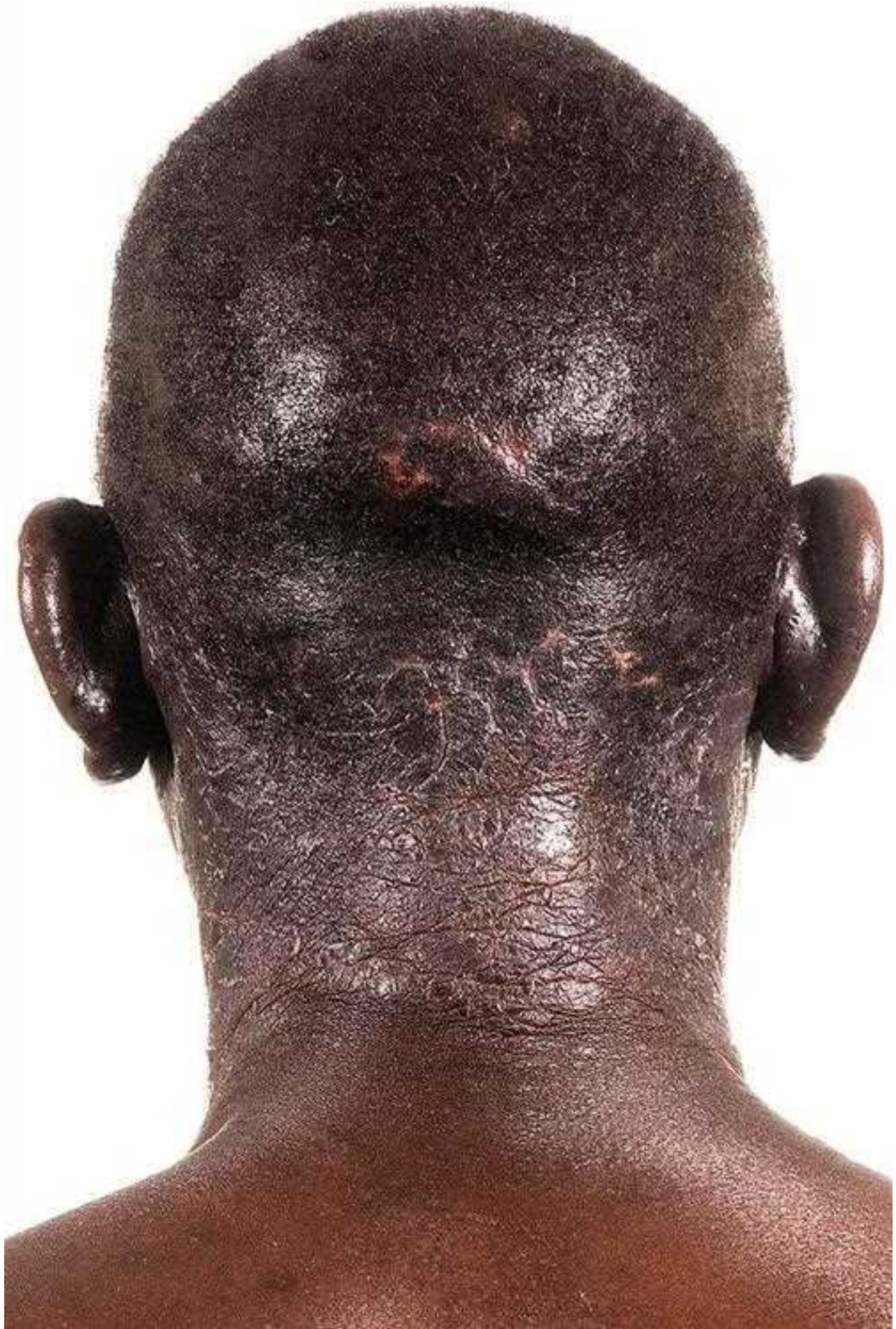
Figure 1.26 Bilateral contact dermatitis to cement.

Diagnosis

- Previous episodes of the rash, particularly in childhood, suggest a constitutional condition such as atopic dermatitis.
- Recurrences of the rash, particularly in specific situations, suggest a contact dermatitis. Similarly, a rash that only occurs on photo-exposed skin is highly suggestive of UV-driven skin disease ([Figure 1.27](#)) such as chronic actinic dermatitis.
- If other members of the family are affected, particularly without any previous history, there may well be a transmissible condition such as scabies.



[Figure 1.27](#) Chronic actinic dermatitis.

Distribution

It is useful to be aware of the usual sites of common skin conditions. These are shown in the appropriate chapters. Eruptions that appear only on areas exposed to sun may be entirely or partially due to sunlight. Some are due to sensitivity to sunlight alone, such as polymorphic light eruption, or a photosensitive allergy to topically applied substances or drugs taken internally.

Morphology

The appearance of the skin lesion may give clues to the underlying pathological process.

Changes at the *skin surface* (epidermis) are characterised by a change in texture when the skin is palpated. Visually one may see scaling, thickening, increased skin markings, small vesicles, crusting, erosions, or desquamation. In contrast, changes in the *deeper tissues* (dermis) can be associated with a normal overlying skin. Examples of changes in the deeper tissues include erythema (dilated blood vessels, or inflammation), induration (an infiltrated firm area under the skin surface), ulceration (that involves surface and deeper tissues), hot tender skin (such as in cellulitis or abscess formation), and changes in adnexal structures and adipose tissue.

The *margin* or border of some lesions is very well defined, as in psoriasis or lichen planus, but in eczema it is ill-defined and merges into normal skin.

Blisters or vesicles occur as a result of

- oedema (fluid) between the epidermal cells ([Figure 1.28](#))
- destruction/death of epidermal cells
- separation of the epidermis from the deeper tissues.

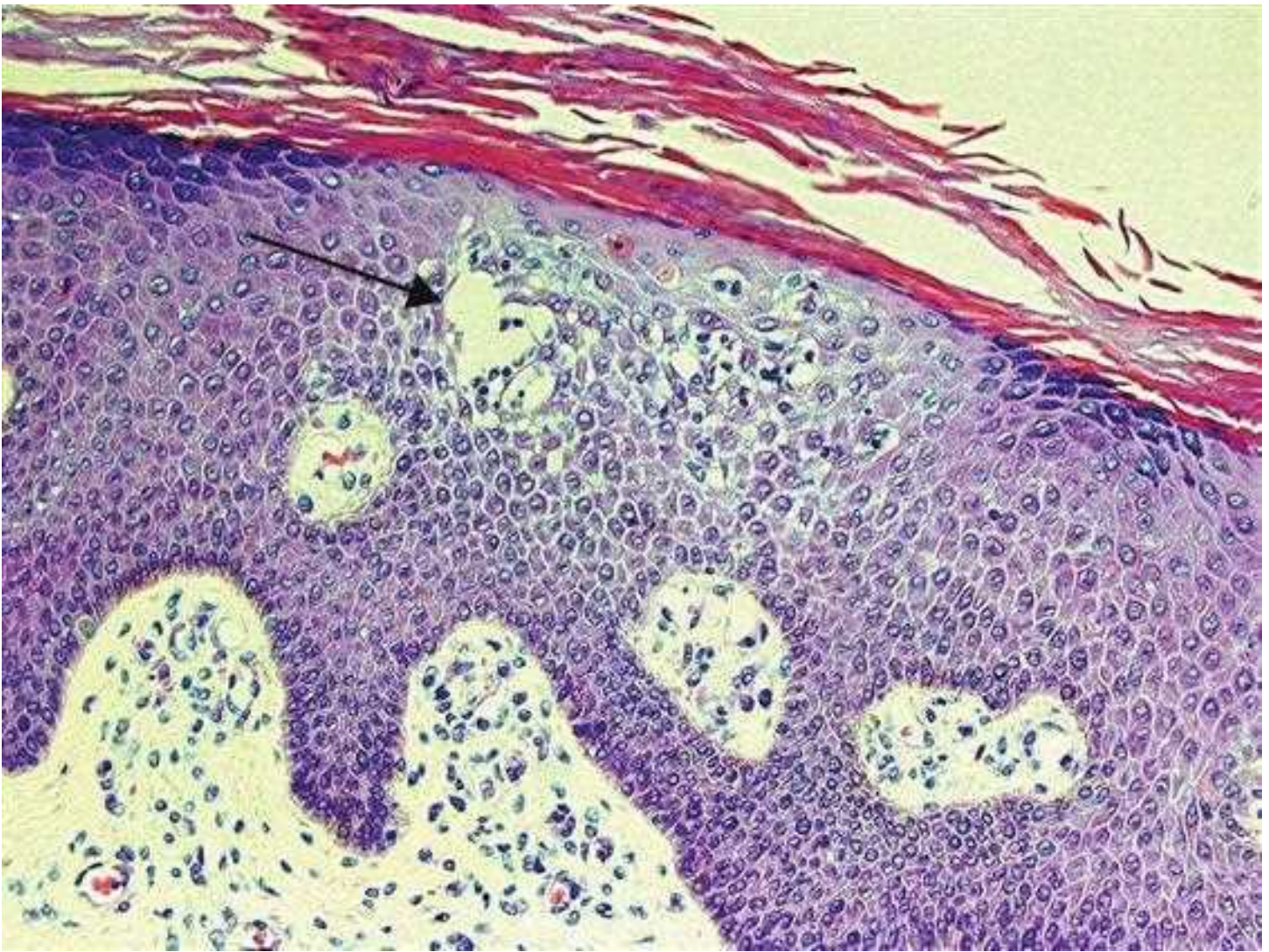


Figure 1.28 Eczema: intraepidermal vesicle (arrow).

There may be more than one mechanism involved simultaneously. *Blisters or vesicles* ([Figures 1.29–1.33](#)) occur in

- *viral* diseases such as chickenpox, hand, foot and mouth disease, and herpes simplex
- *bacterial infections* such as impetigo or acute cellulitis
- *inflammatory disorders* such as eczema, contact dermatitis, and insect bite reactions
- *immunological disorders* such as dermatitis herpetiformis, pemphigus, and pemphigoid and erythema multiforme
- *metabolic disorders* such as porphyria.

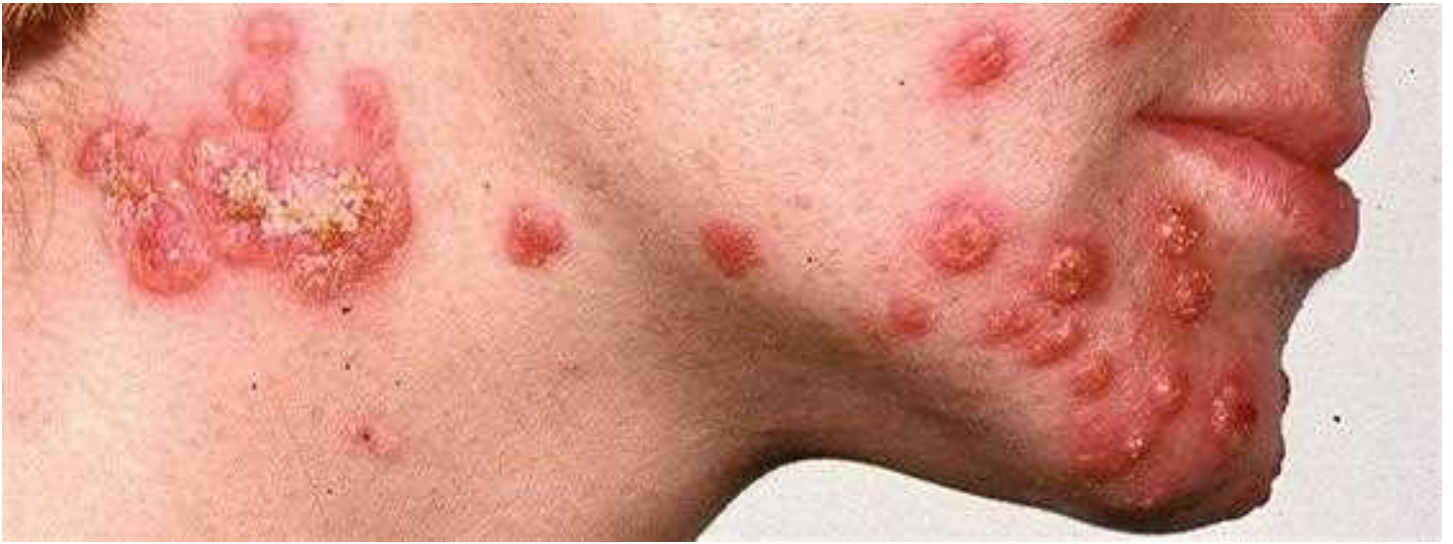
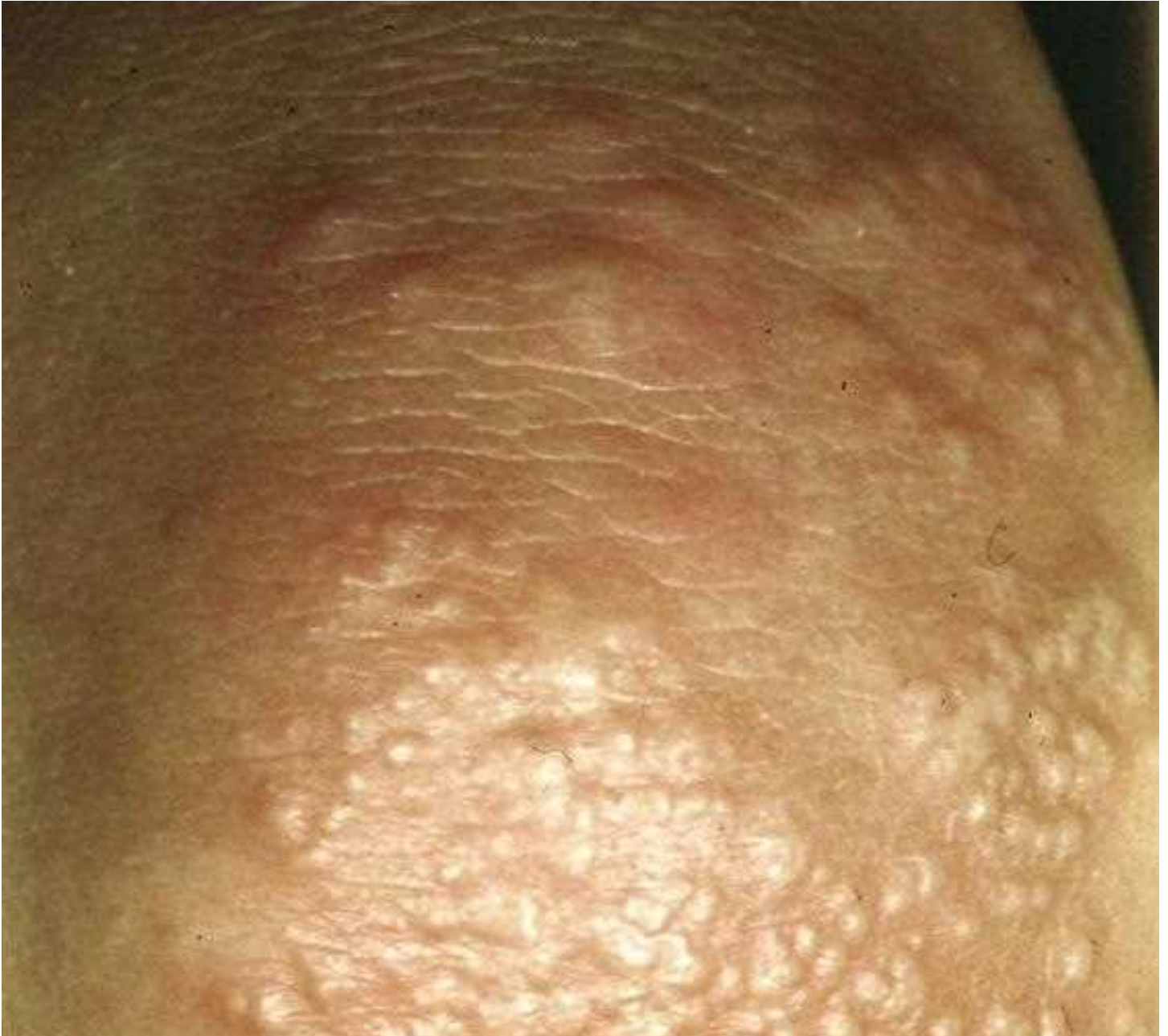
Figure 1.29 Vesicles and bullae in erythema multiforme.



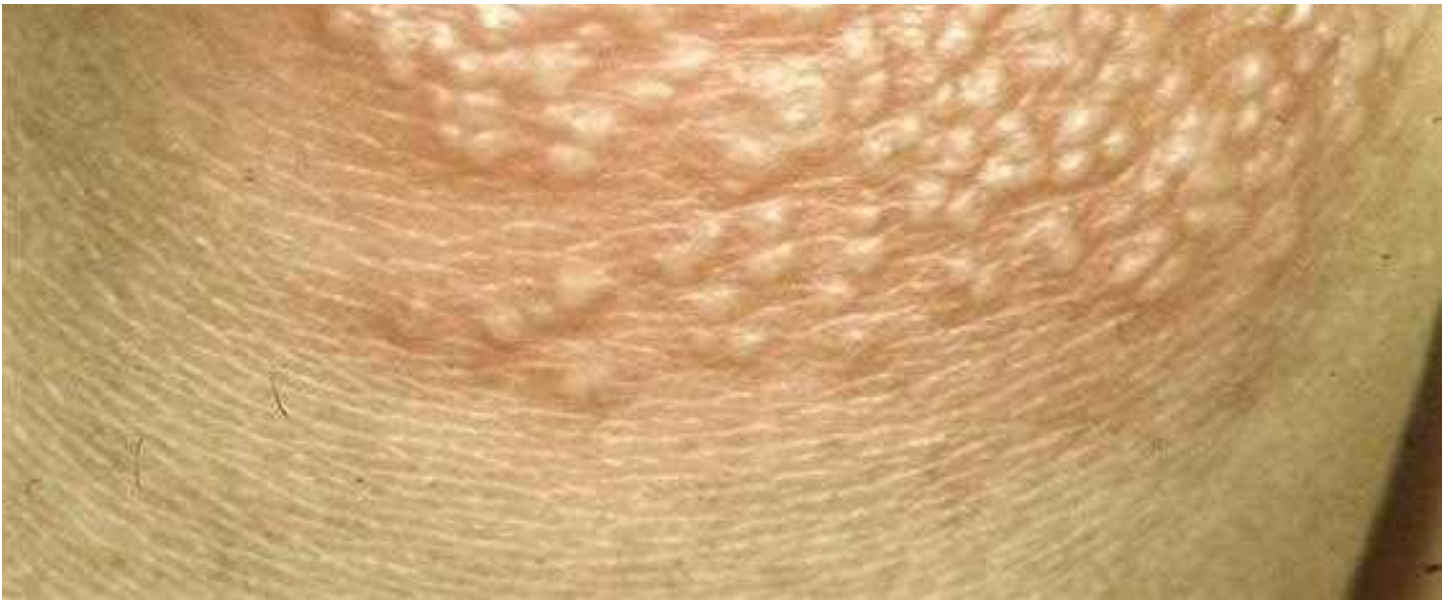

Figure 1.30 Vesicles in herpes simplex.

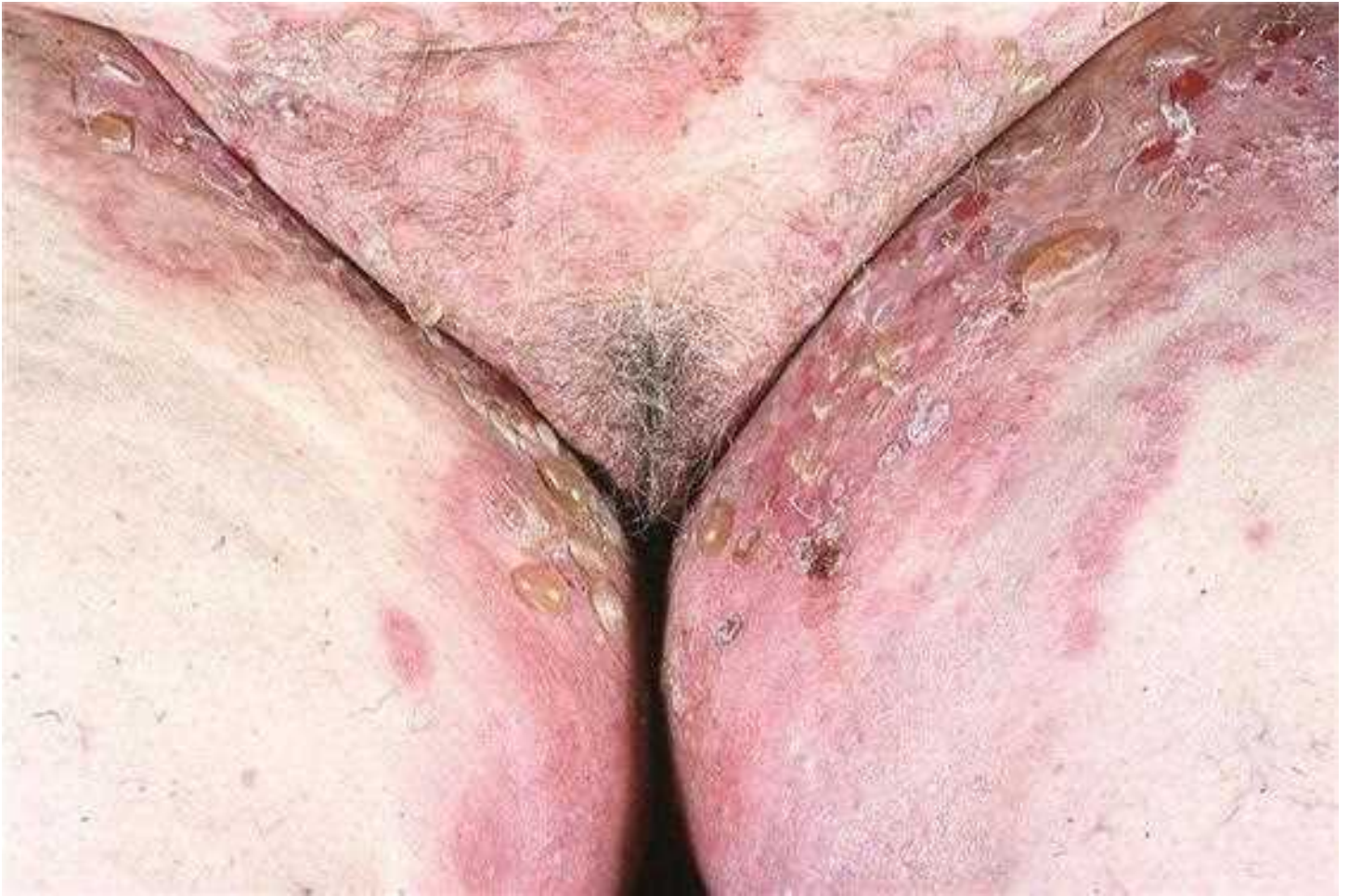

Figure 1.31 Vesicles and bullae in bullous pemphigoid.

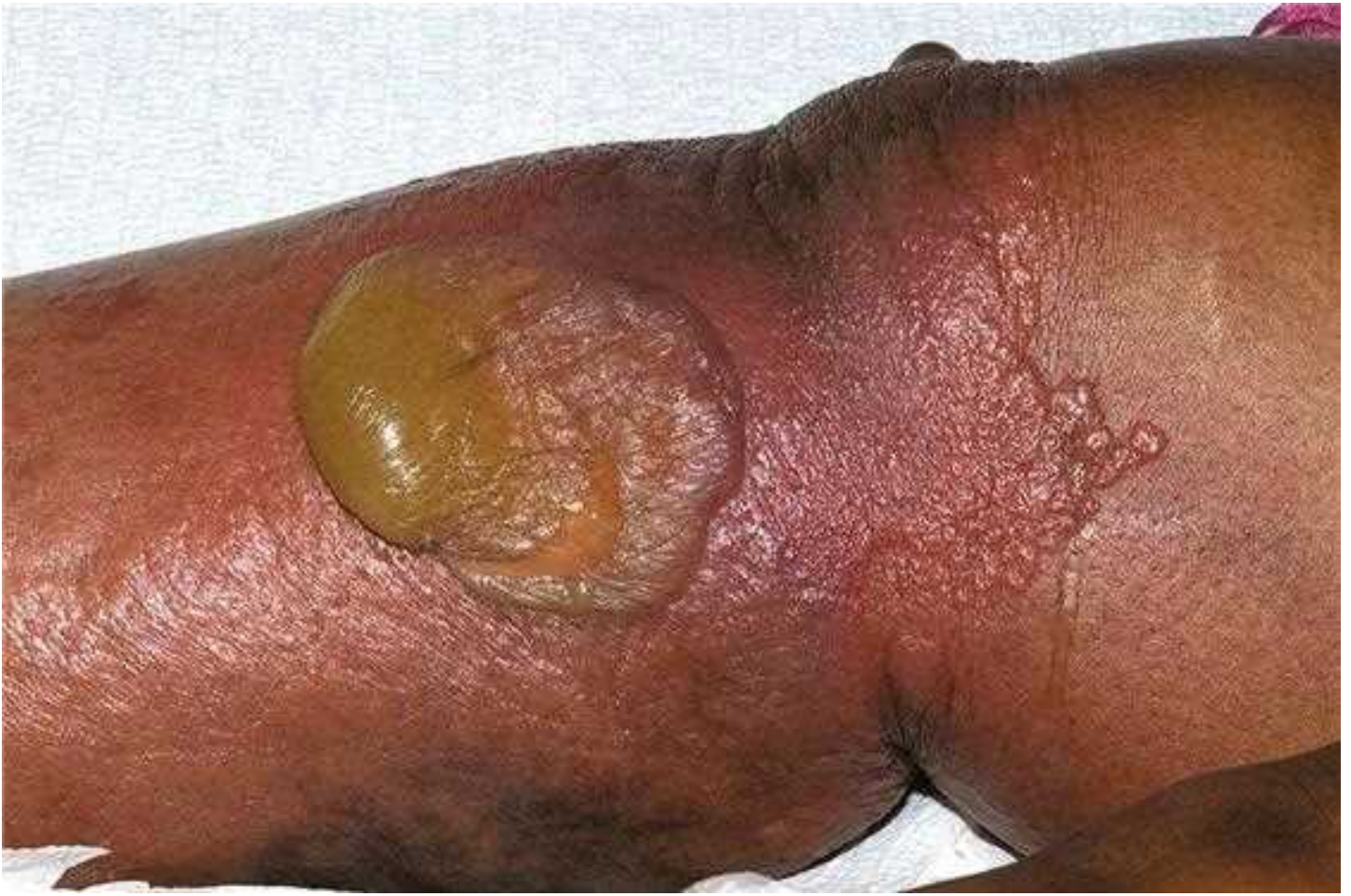

Figure 1.32 Bullae in cellulitis on lower leg.

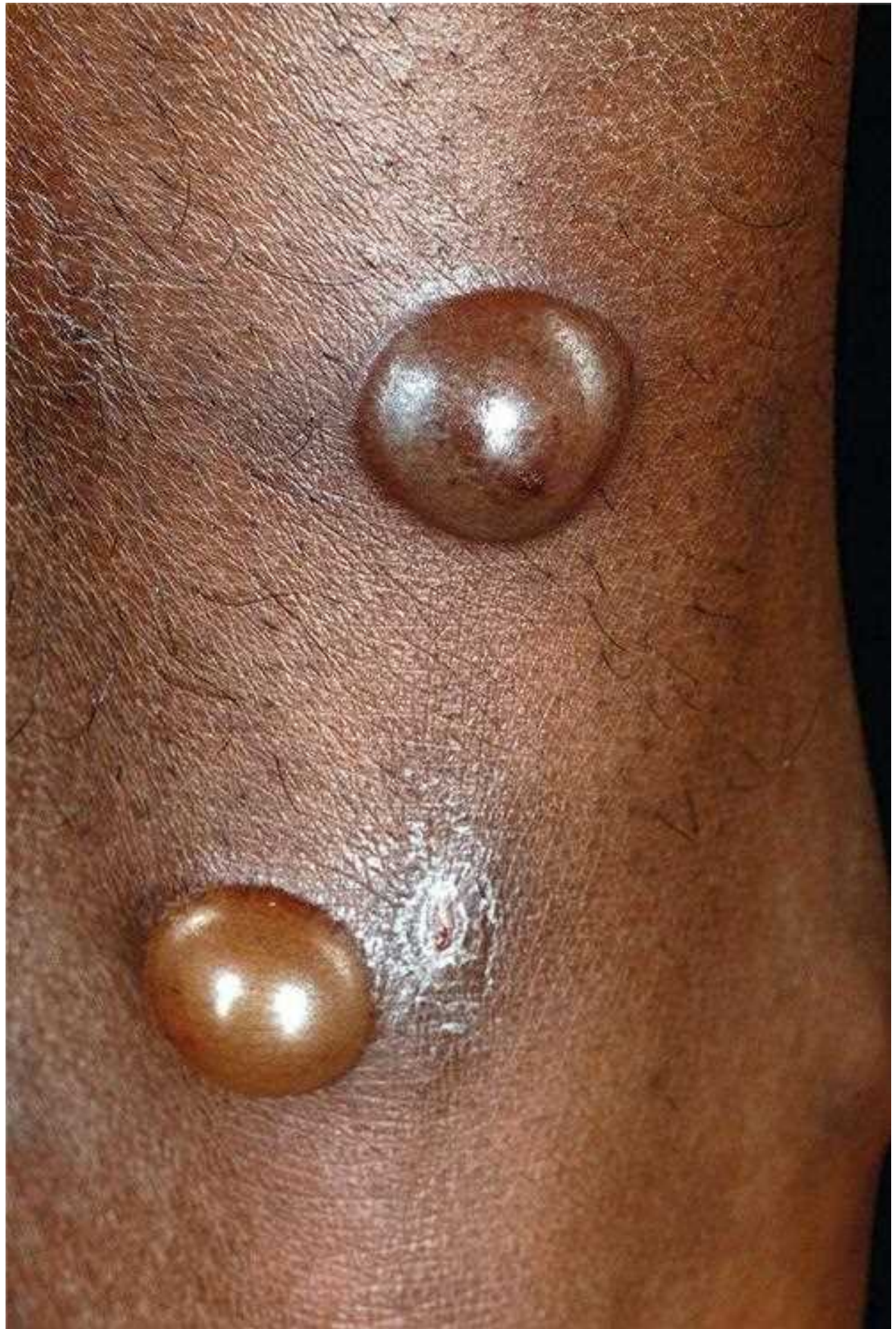

Figure 1.33 Bullae from insect bite reactions.

Bullae (blisters more than 0.5 cm in diameter) may occur in congenital conditions (such as epidermolysis bullosa), in trauma, and as a result of oedema without much inflammation. However, those forming as a result of vasculitis, sunburn, or an allergic reaction may be associated with pronounced inflammation. Adverse reactions to medications can also result in a bullous eruption.

Induration is the thickening of the dermis due to infiltration of cells, granuloma formation, or deposits of mucin, fat, or amyloid.

Inflammation is indicated by erythema, which can be acute or chronic. Acute inflammation can be associated with increased skin temperature such as occurs in cellulitis and erythema nodosum. Chronic inflammatory cell infiltrates occur in conditions such as lichen planus and lupus erythematosus.

Assessment of the patient

A full assessment should include not only the effect the skin condition has on the patients' lives but also their attitude to it. For example, some patients with quite extensive psoriasis are unbothered while others with very mild localised disease just on the elbows may be very distressed. Management of the skin disease should take into account the patients' expectation as to what would be acceptable to them.

Fear that a skin condition may be due to cancer or infection is often present and reassurance should always be given to allay any hidden fears. If there is the possibility of a serious underlying disease that requires further investigation, then it is important to explain fully to the patient that the skin problems may be a sign of an internal disease.

The significance of occupational factors must be considered. In some cases, such as an allergy to hair dyes in a hairdresser, it may be impossible for the patient to continue his or her job. In other situations, the allergen can be easily avoided.

Patients often want to know why they have developed a particular skin problem and whether it can be cured. In many skin diseases these questions are difficult to answer. Patients with psoriasis, for example, can be told that it is part of their inherent constitution but that additional factors can trigger clinical lesions ([Figure 1.34](#)). Known trigger factors for psoriasis include emotional stress, local trauma to the skin (Koebner's phenomenon), infection (guttate psoriasis), and drugs (β -blockers, lithium, antimalarials).

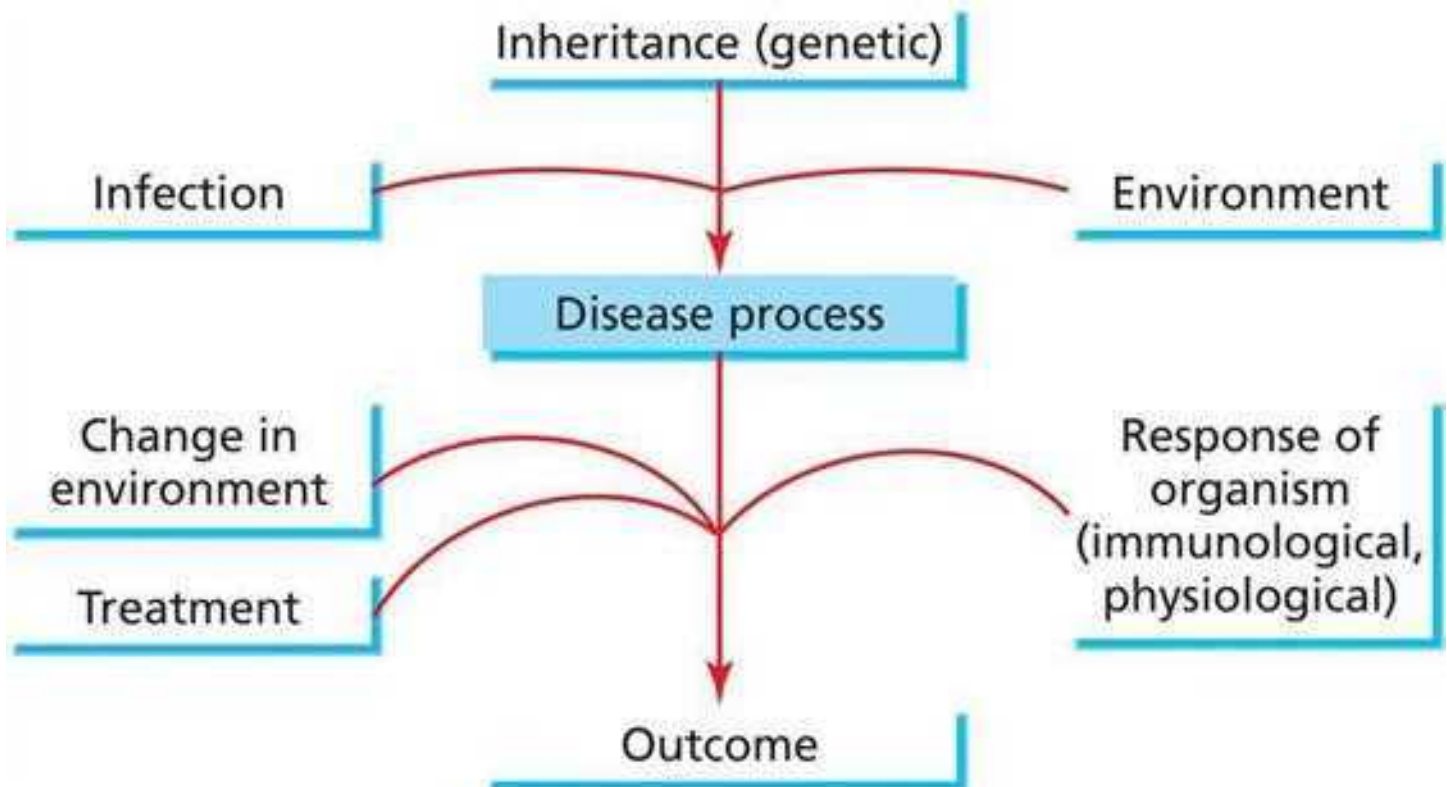


Figure 1.34 Possible precipitating factors in psoriasis.

Skill in recognition of skin conditions will evolve and develop with increased clinical experience. Seeing and feeling skin rashes ‘in the flesh’ is the best way to improve clinical dermatological acumen ([Box 1.2](#)).

Box 1.2 Examination of skin lesions – key points

Distribution

Examine all the skin for clues. For example, there are many possible causes for dry thickened skin on the palms, and finding typical psoriasis on the elbows, knees, and soles may give the diagnosis.

Morphology

Are the lesions dermal or epidermal? Macular (flat) or forming papules? Indurated or forming plaques? Well defined or indistinct? Forming crusts, scabs, or vesicles?

Pattern

The overall morphology and distribution of the rash – for example, an indeterminate rash may be revealed as pityriasis rosea when the ‘herald patch’ is found.

Further reading

Graham-Brown, R., Harman, K., and Johnson, G. (2016). *Lecture Notes: Dermatology*, 11e. New York: Wiley-Blackwell.

Wolff, K., Johnson, R.A., and Saavedra, A.P. (2013). *Fitzpatrick's Colour Atlas and Synopsis of Clinical Dermatology*, 7e. Oxford: McGraw-Hill Medical.

CHAPTER 2

Psoriasis

Rachael Morris-Jones

Guy's and St Thomas' NHS Foundation Trust, London, UK

OVERVIEW

- Psoriasis is a complex immune-mediated disease that manifests with chronic inflammatory lesions in the skin and systemic manifestations.
- Psoriasis has been shown to be an independent risk factor for cardiovascular disease.
- Specific biological therapies are transforming the management of psoriasis and psoriatic arthropathy.
- Clinical presentations can be variable, from chronic stable plaques, to pustules on the hands and feet, to unstable erythroderma.

Introduction

Psoriasis is now considered to be a genetically determined inflammatory systemic autoimmune disease. It is characterised by plaques of diseased skin often at sites of minor friction (elbows/knees), which occur next to areas of clear 'normal' skin. Plaques of psoriasis are clinically well-demarcated and are erythematous (dilated dermal blood vessels) with white surface scale (rapid keratinocyte proliferation). Psoriasis not only affects the skin but can also lead to seronegative arthritis in approximately 8–30% of patients. However, there is an increasing body of evidence that psoriasis is also associated with other important comorbidities such as type 2 diabetes (1.4-fold increased risk), cardiovascular disease (CVD), metabolic syndrome, obesity, non-alcoholic fatty liver disease (NAFLD), depression, and reduced quality of life.

The pathogenesis of psoriasis is complex; nonetheless, it is largely accepted that the disease is mediated by the dysregulation of T-helper lymphocytes (Th1/Th17). The development of psoriasis is multifactorial, with multiple potential susceptibility factors in a genetically at-risk individual. This combination of susceptibility factors and genetic predisposition results in an interactive web of immune cells/chemical cytokines impacting on skin cells and leading to disease. Increased understanding of these complex cellular changes has led to the introduction of multiple targeted biological therapies that are now used to manage severe psoriasis and psoriatic arthritis (PA).

Globally 1–2% of the population is affected by psoriasis (125 million people in

UK/USA/Japan alone). A child who has one parent with psoriasis has a one in four chance of developing the disease. If one identical twin has psoriasis, there is a 70% chance that the other will also be affected; however, only a 20% chance exists in dizygotic twins. Linkage and genome-wide association studies have started identifying some of the important susceptibility factors leading to the inheritance of psoriasis and psoriatic arthropathy. The first and arguably one of the most important psoriasis susceptibility loci identified is the so-called *PSORS1* found on chromosome 6p21.3. This region of the chromosome contains several genes which may be important in the inheritance of psoriasis, including HLA-C (human leukocyte antigen-C), CCHCR1 (coiled-coil α -helical rod protein 1), and CDSN (corneodesmosin). Subsequently, multiple susceptibility loci on several chromosomes have now been identified including 1q21, 3q21, 4q, 7p, 8, 11, 16q, 17q, and 20p. Recently, a loss of function mutation in a gene encoding an IL-36 receptor antagonist has been shown to be associated with the development of palmo-plantar pustular psoriasis.

Plaques of psoriasis are highly infiltrated with CD3⁺ T-cells and CD11c⁺ dendritic cells which produce pro-inflammatory cytokines including tumour necrosis factor alpha (TNF- α), interferon gamma (INF- γ), and interleukin 17 (IL-17), IL-22/23/12/1 β , which activate keratinocytes and other skin cells. Keratinocytes are the skin cells that predominate in the epidermis; they grow from the basal layer and slowly migrate to the surface ([Figures 2.1](#) and [2.2](#)). In normal skin, this process of cell turnover takes about 23 days; however, in psoriasis cell turnover is rapidly accelerated, taking only three to five days for cells to reach the surface and accumulate in large numbers (hyperkeratosis). Keratinocytes normally lose their nuclei as they move to the skin surface; however, in psoriasis they move so quickly that the cells retain their nuclei throughout the epidermis, seen as parakeratosis histologically. This rapid turnover and failure of proper maturation result in defective keratinocytes, which are poorly adherent and easily scraped off ('Auspitz sign') revealing underlying dilated blood vessels.

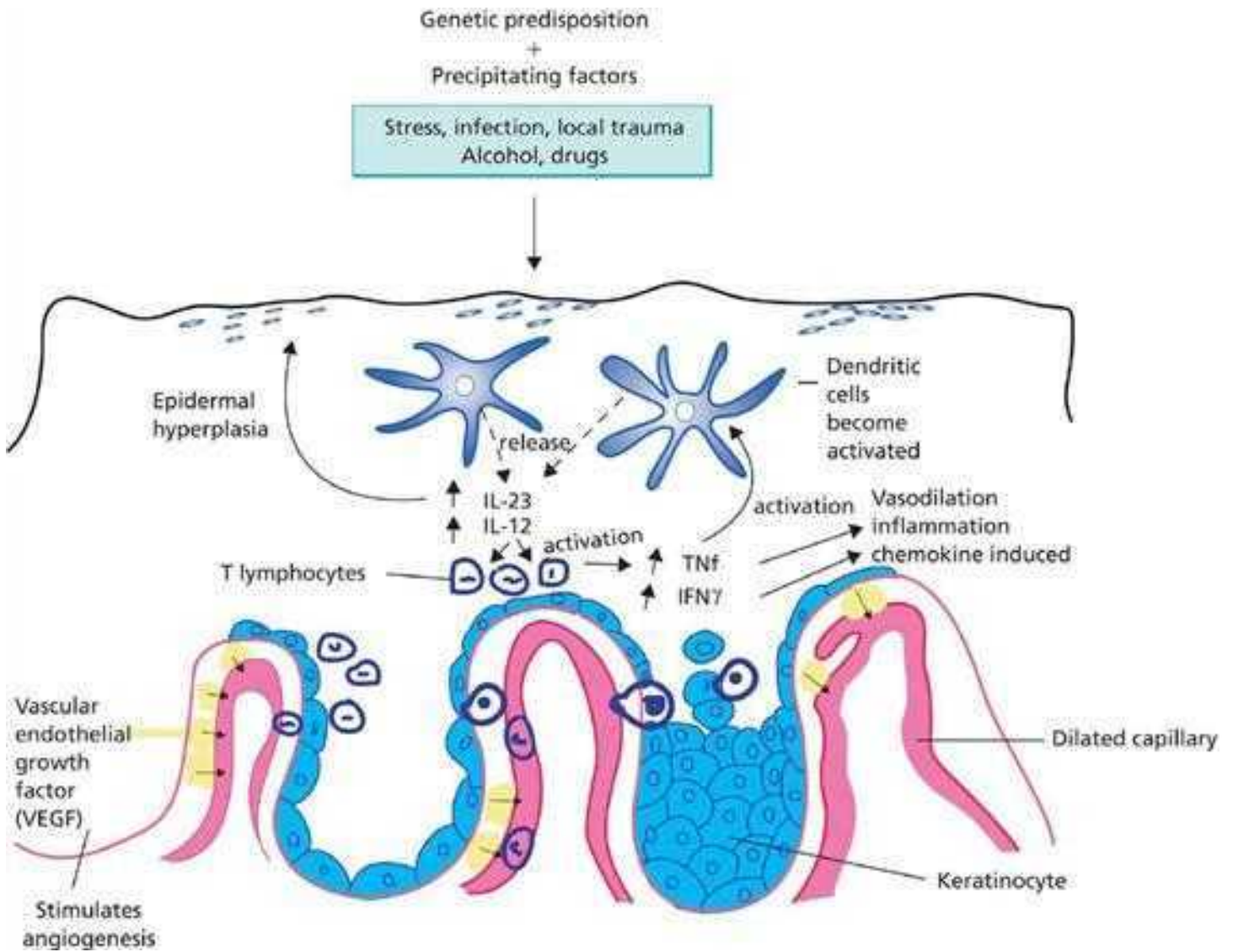


Figure 2.1 Pathophysiological mechanisms involved in the development of psoriasis.

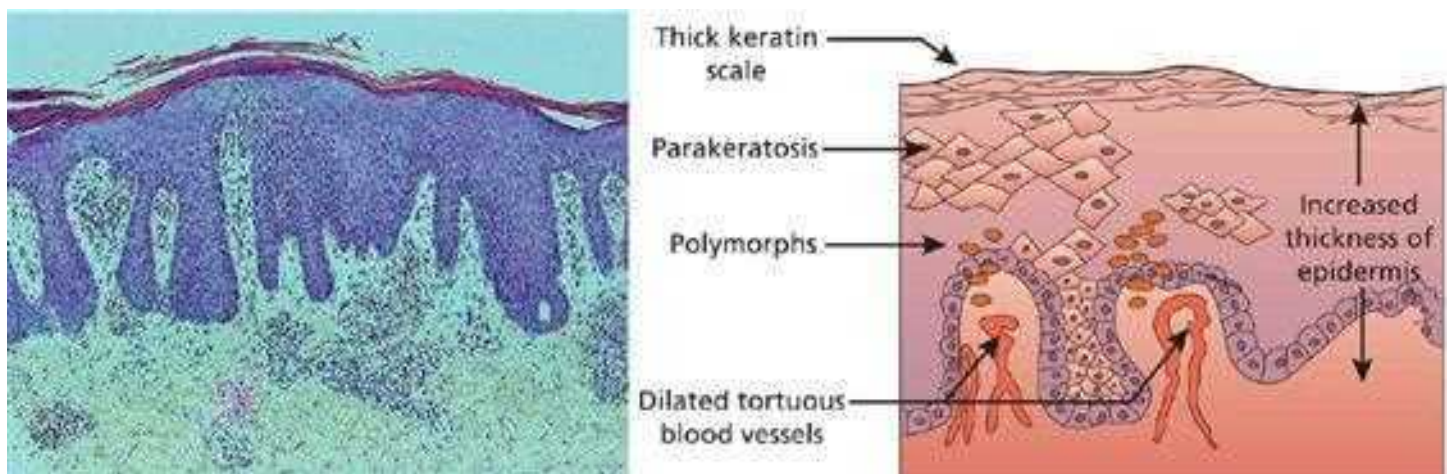


Figure 2.2 (Diagram/histology composite) Increased epidermal proliferation.

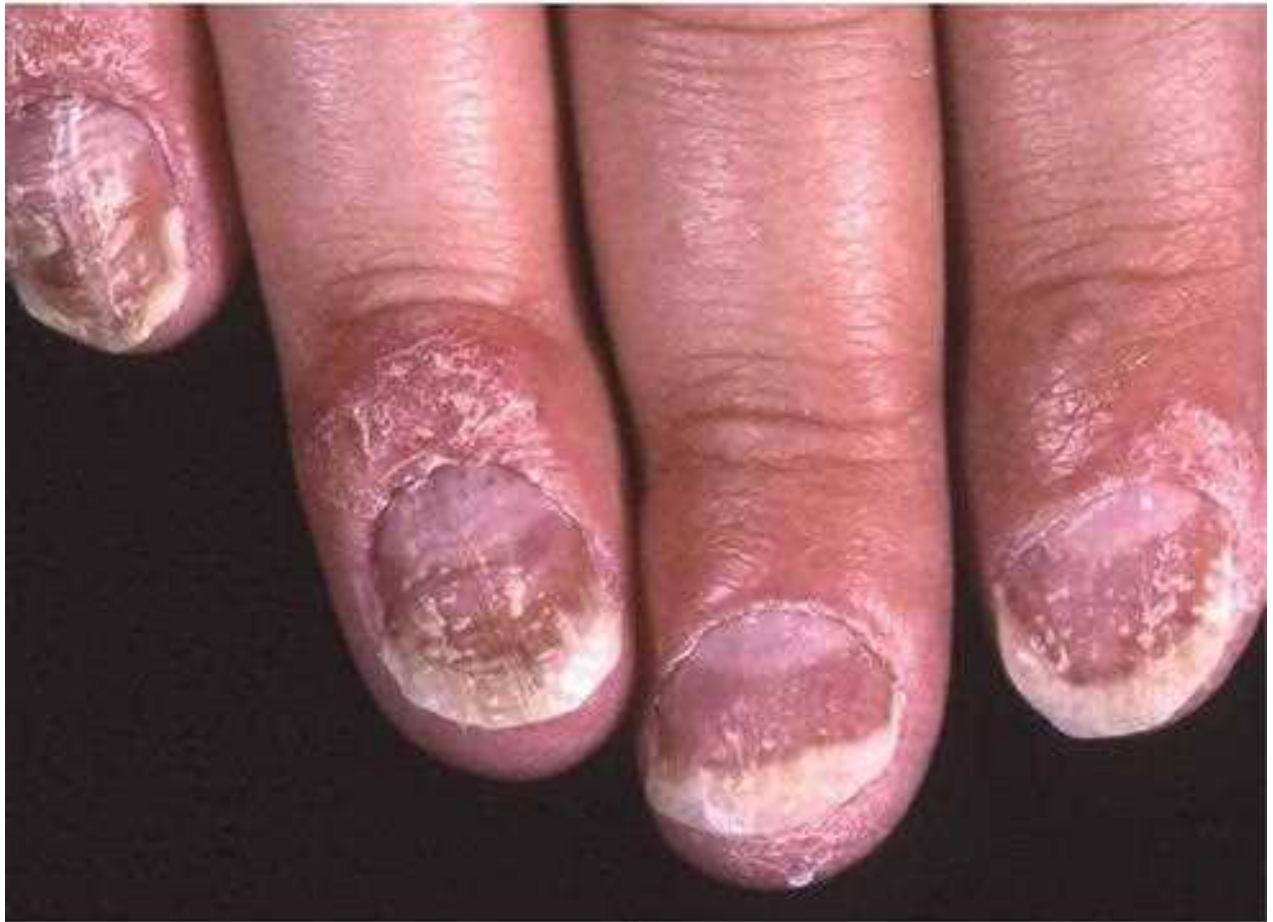In addition, inflammatory polymorphs infiltrating the epidermis lead to swelling (oedema), inflammation, and erythema. These inflammatory cells may occur in such large numbers that they form collections of sterile pustules at the skin surface. These are most commonly seen in

palmo-plantar pustulosis, a variant of psoriasis affecting the palms and soles.

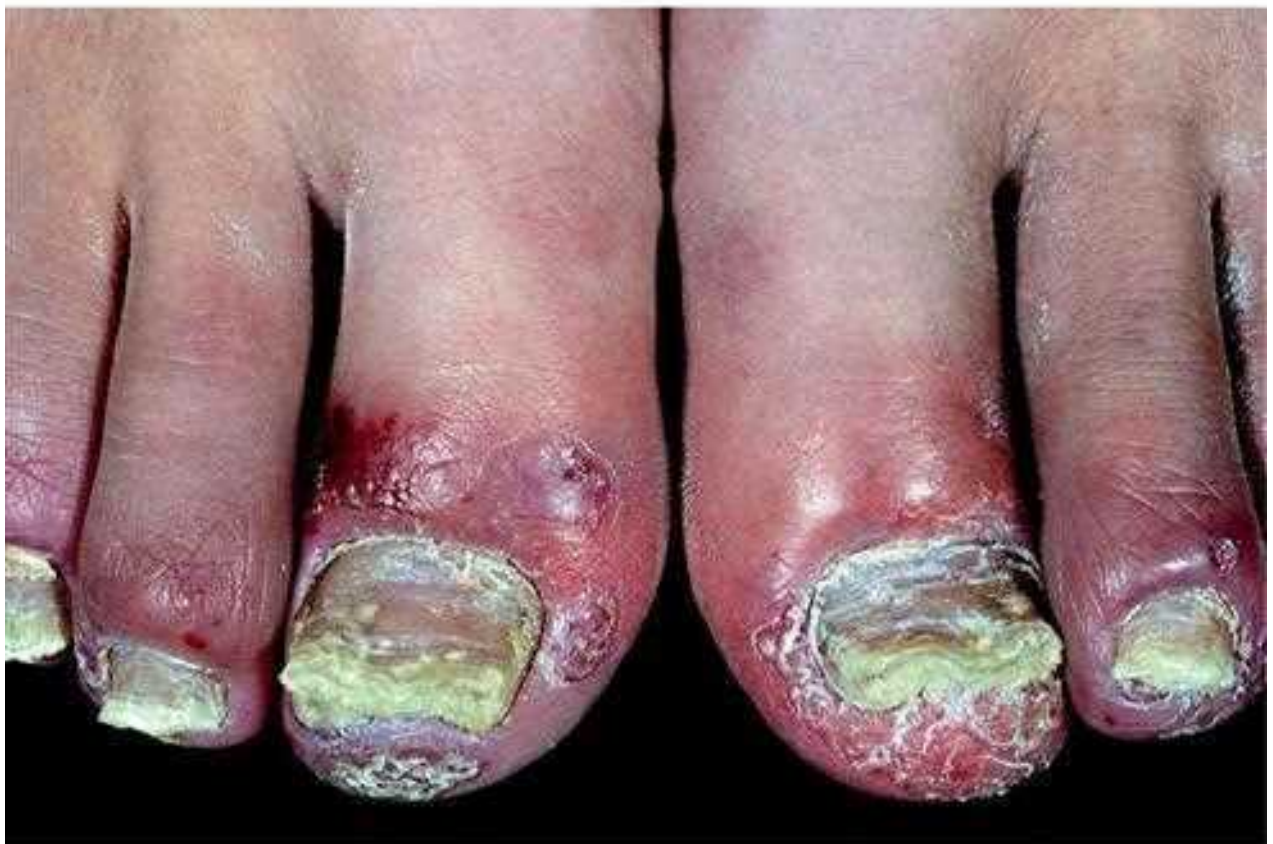The cellular abnormalities in the skin of patients with psoriasis can occur in the nails, and many patients will therefore have additional nail changes.

Psoriatic nail dystrophy is characterised by:

- *onycholysis* (lifting of the nail plate off the nail bed) due to abnormal cell adhesion; this usually manifests as a white or salmon patch on the nail plate ([Figure 2.3a](#) pitting and onycholysis of nails)
- *subungal hyperkeratosis* ([Figure 2.3b](#)) (accumulation of chalky looking material under the nail) due to excessive proliferation of the nail bed that can ultimately lead to onycholysis
- *pitting* (very small depressions in the nail plate) which result from parakeratotic (nucleated) cells being lost from the nail surface
- *Beau's lines* (transverse lines on the nail plate) due to intermittent inflammation of the nail bed, leading to transient arrest in nail growth
- *splinter haemorrhages* (which clinically look like minute longitudinal black lines) due to leakage of blood from dilated tortuous capillaries.



(a)



(b)

Figure 2.3 (a) Pitting and onycholysis of the nails. (b) Hyperkeratotic nail plates in psoriasis.

Clinical appearance

The main clinical features of psoriasis reflect the underlying pathological processes (as described above). Patients characteristically have the following:

- *Plaques* which are well-defined raised areas of psoriasis. These may be large or small, few or numerous and scattered over the trunk and limbs ([Figures 2.4](#) and [2.5](#)).
- *Scaling* may be very prominent causing plaques to appear thickened with masses of adherent and shedding white scales. Scratching the surface produces a waxy appearance – the ‘tache de bougie’ (literally ‘a line of candle wax’).
- *Erythema* or redness of the affected skin may be very marked, especially in the flexures. Erythema is a prominent feature in patients with erythrodermic psoriasis (who have >90% of their body surface involved).
- *Pustules* are commonly seen in *palmo-plantar pustulosis*, where deep-seated yellowish sterile pustules are often the dominant feature of this chronic condition. However, if pustules develop around the periphery of chronic plaques of psoriasis or sheets of monomorphic pustules appear more generally in the context of psoriasis, this is a sign of unstable disease – a dermatological emergency.

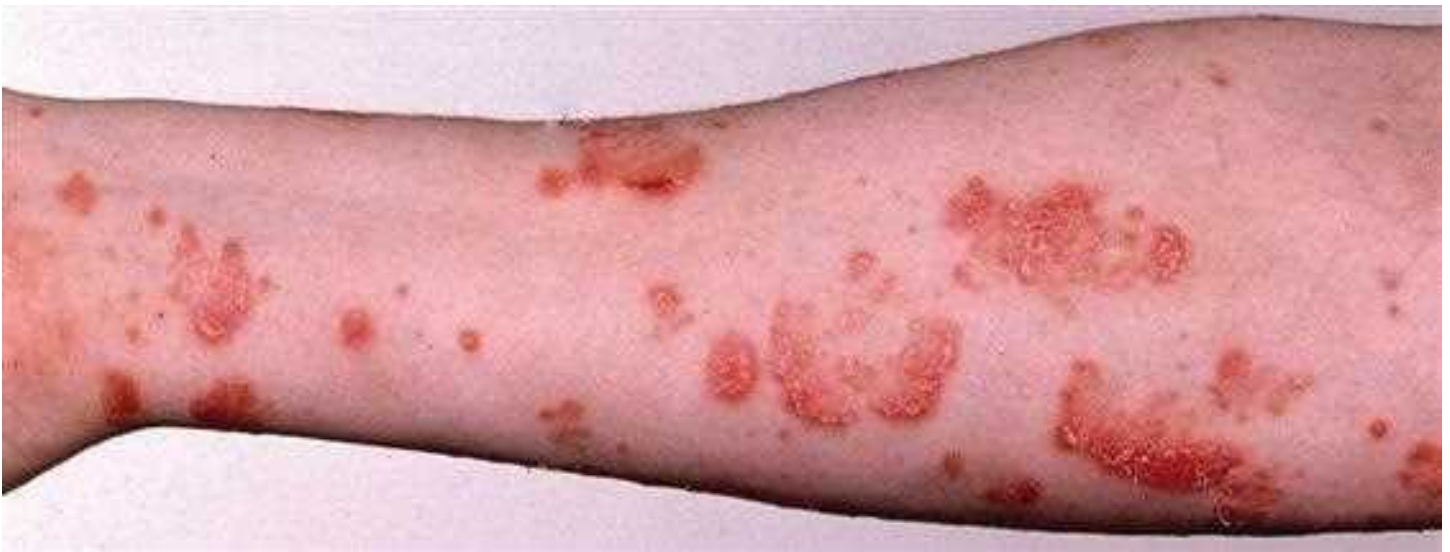

Figure 2.4 Multiple small plaques.

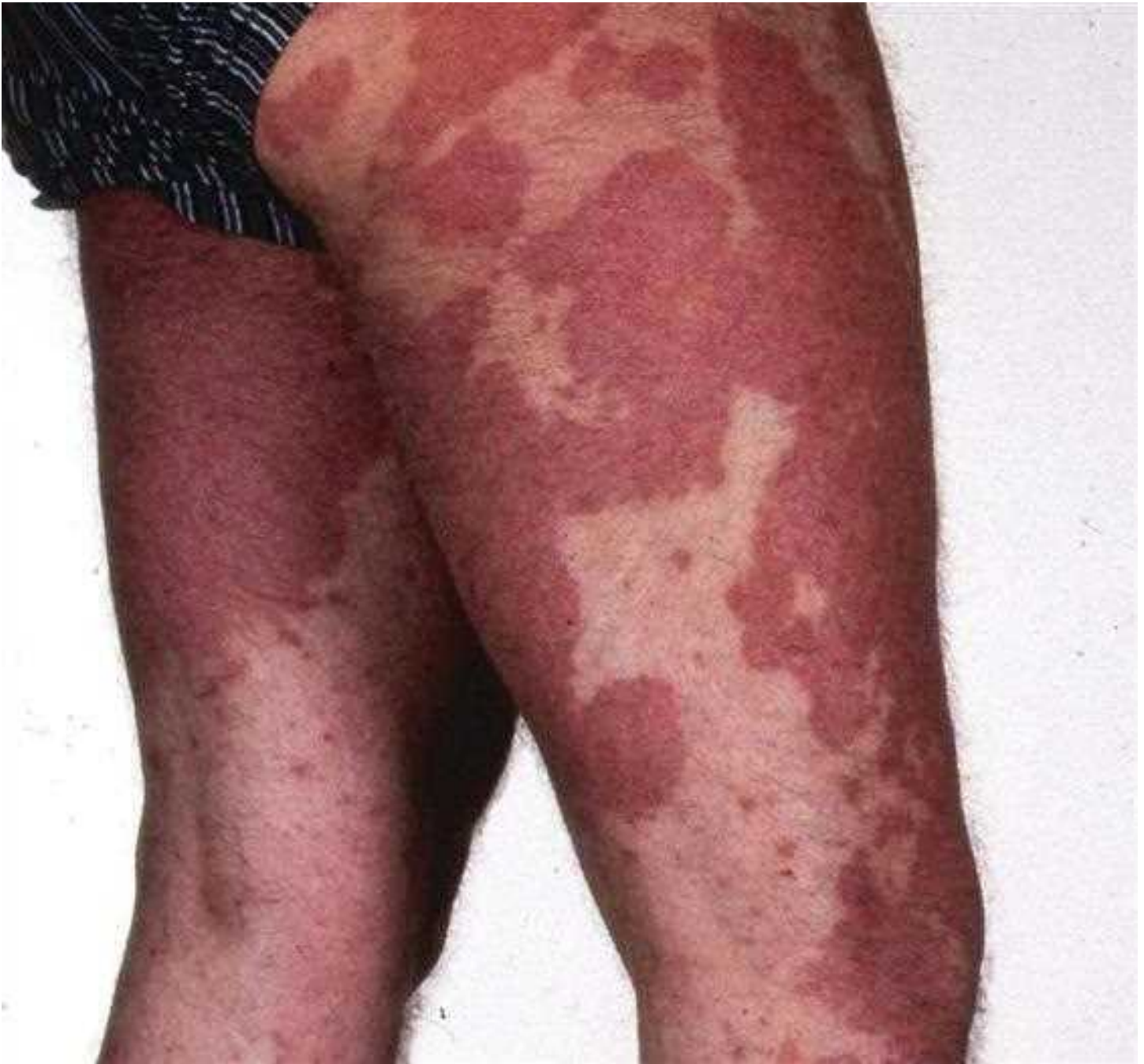

Figure 2.5 Large chronic plaques.

The typical patient

Psoriasis is reported to affect approximately 2% of the US population. The median age of onset is 28 years; however, it can present from infancy to old age, when the appearance may be atypical.

The following factors in the history may help in making a diagnosis:

- Family history of psoriasis; 16% of children will have psoriasis if a single parent is affected and 50% if both parents are affected.

- Trigger factors include stress, infections, trauma, or childbirth.
- Lesions may first appear at sites of minor skin trauma – Koebner's phenomenon.
- Lesions usually improve in the sun.
- Psoriasis is usually only mildly itchy.
- Arthropathy may be associated.

Clinical presentation

Classically psoriasis patients present with plaques on the elbows, knees, and scalp ([Figure 2.6](#)). Lesions on the trunk are variable in size and are often annular ([Figures 2.7–2.9](#)). Psoriasis may develop in scars and areas of minor skin trauma – the so-called Koebner's phenomenon ([Figure 2.10](#)). This may manifest as hyperkeratosis on the palms, associated with repetitive trauma from manual labour ([Figure 2.11](#)). Scalp scaling, which affects 50% of patients, can be very thick, especially around the hairline, but may be more confluent, forming a virtual 'skull cap' ([Figure 2.12](#)). Erythema often extends beyond the hair margin. The nails show 'pits' and also thickening with separation of the nail from the nail bed (onycholysis) ([Figure 2.13](#)).

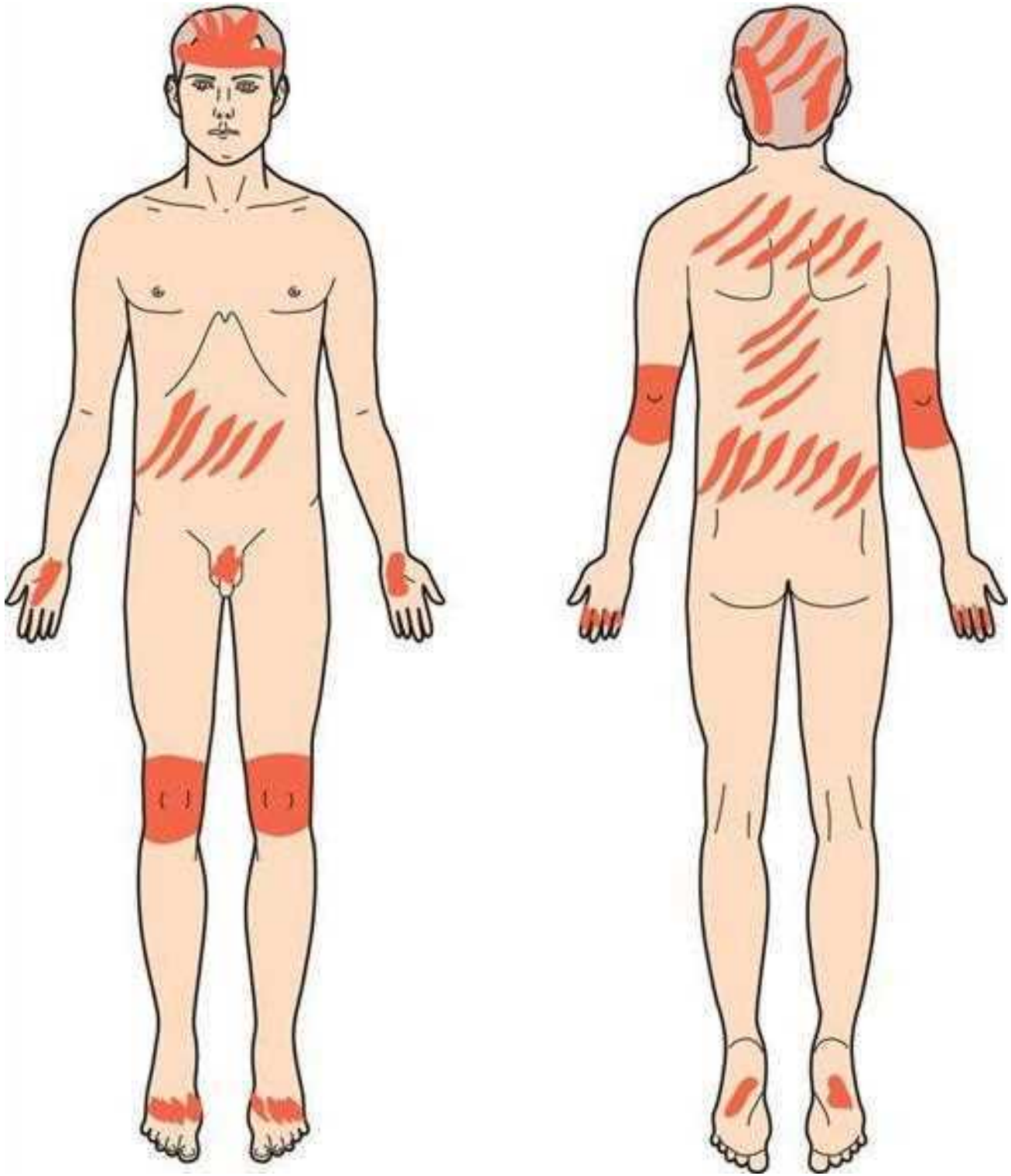


Figure 2.6 Common patterns of distribution of psoriasis.

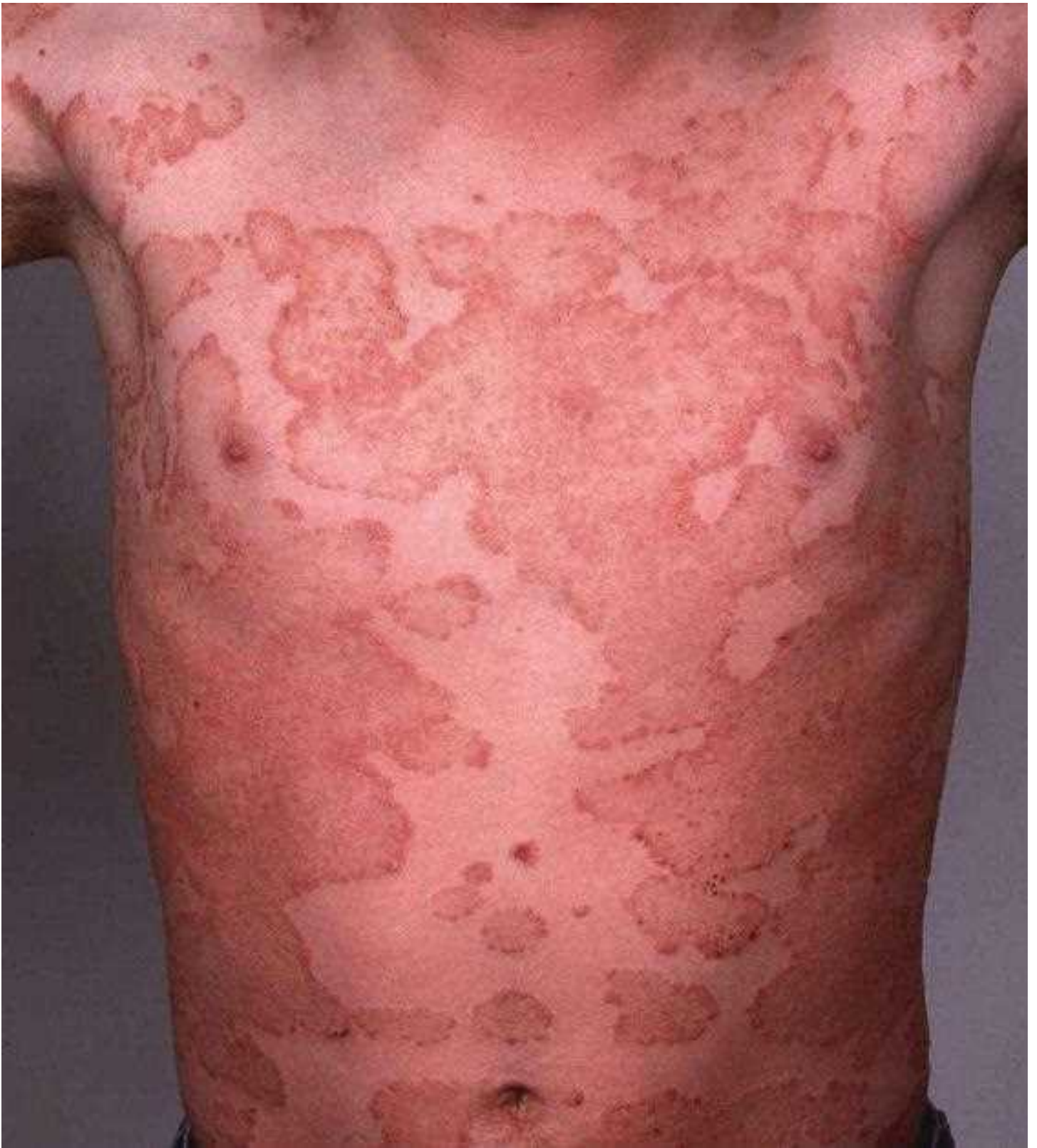

Figure 2.7 Generalised plaques.

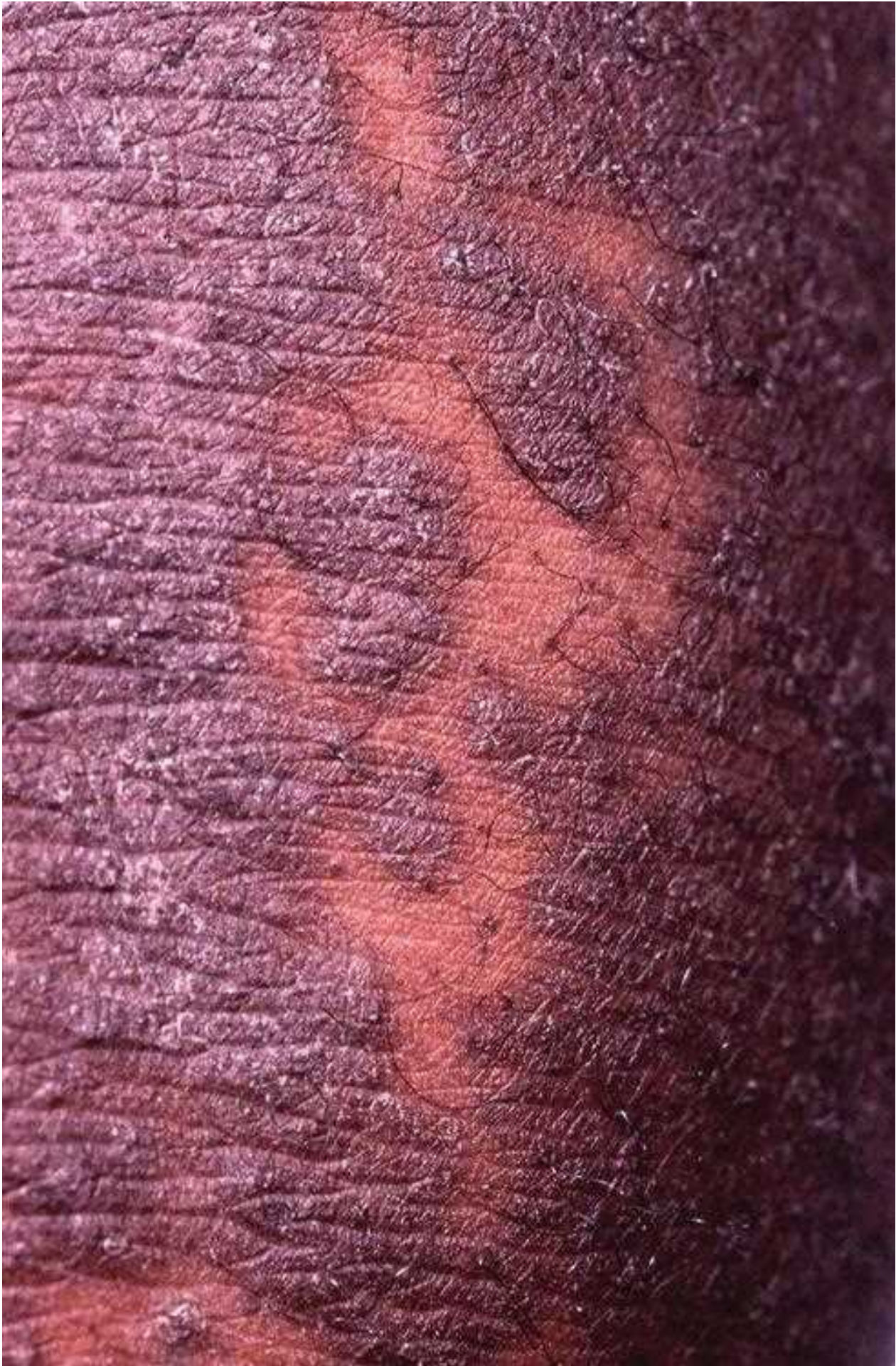

Figure 2.08 Psoriatic plaques on the trunk.

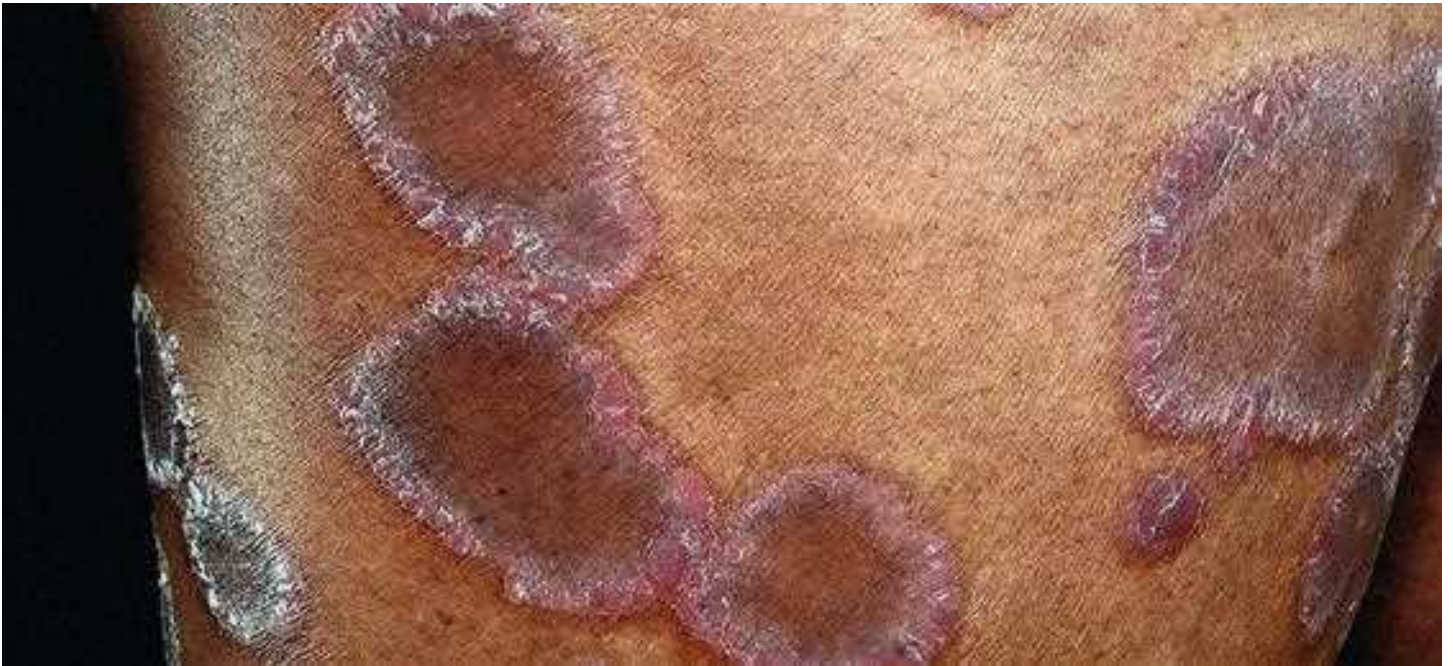

Figure 2.9 Annular plaques.

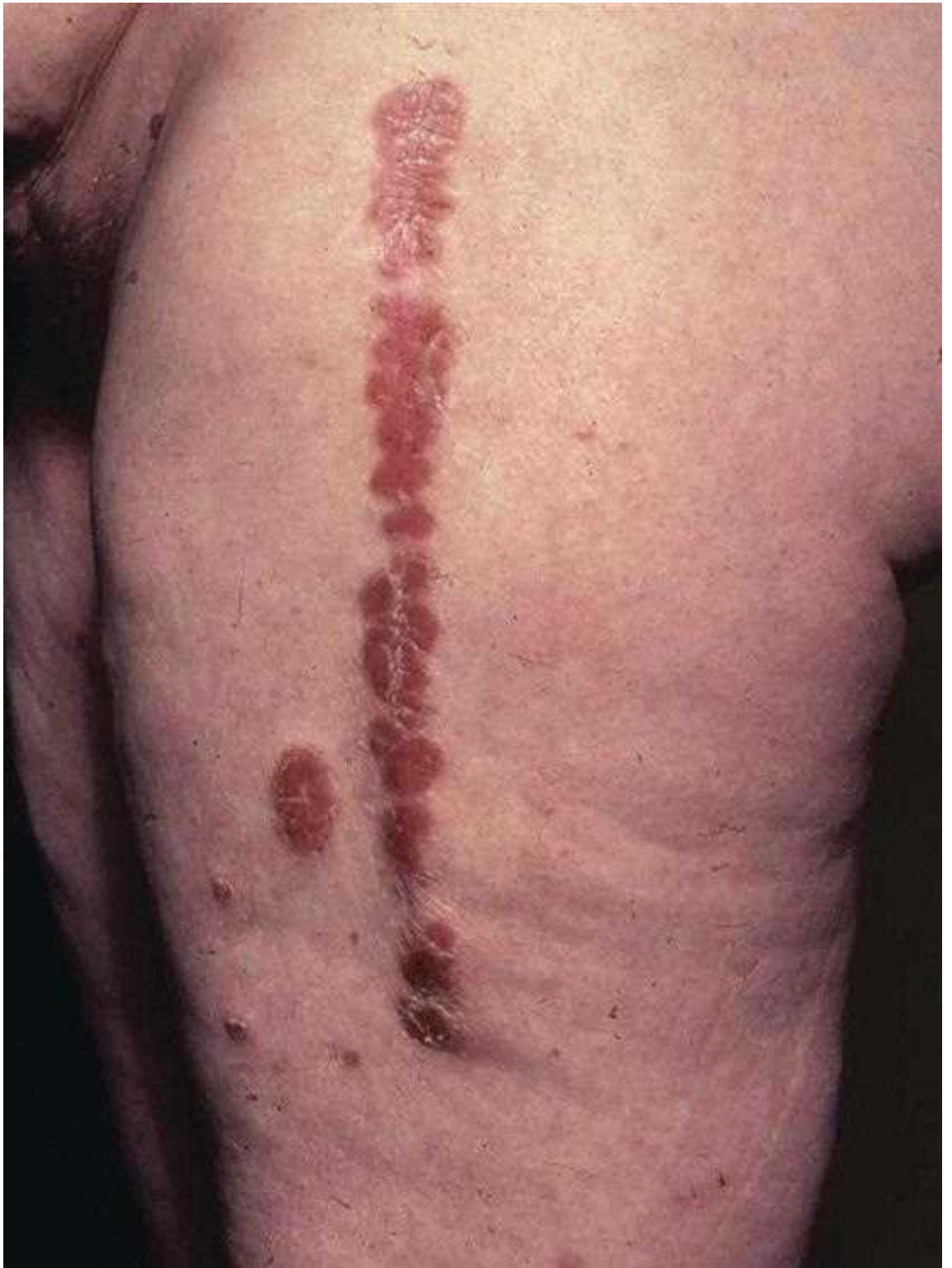

Figure 2.10 Koebner's phenomenon: psoriasis in surgical scar.

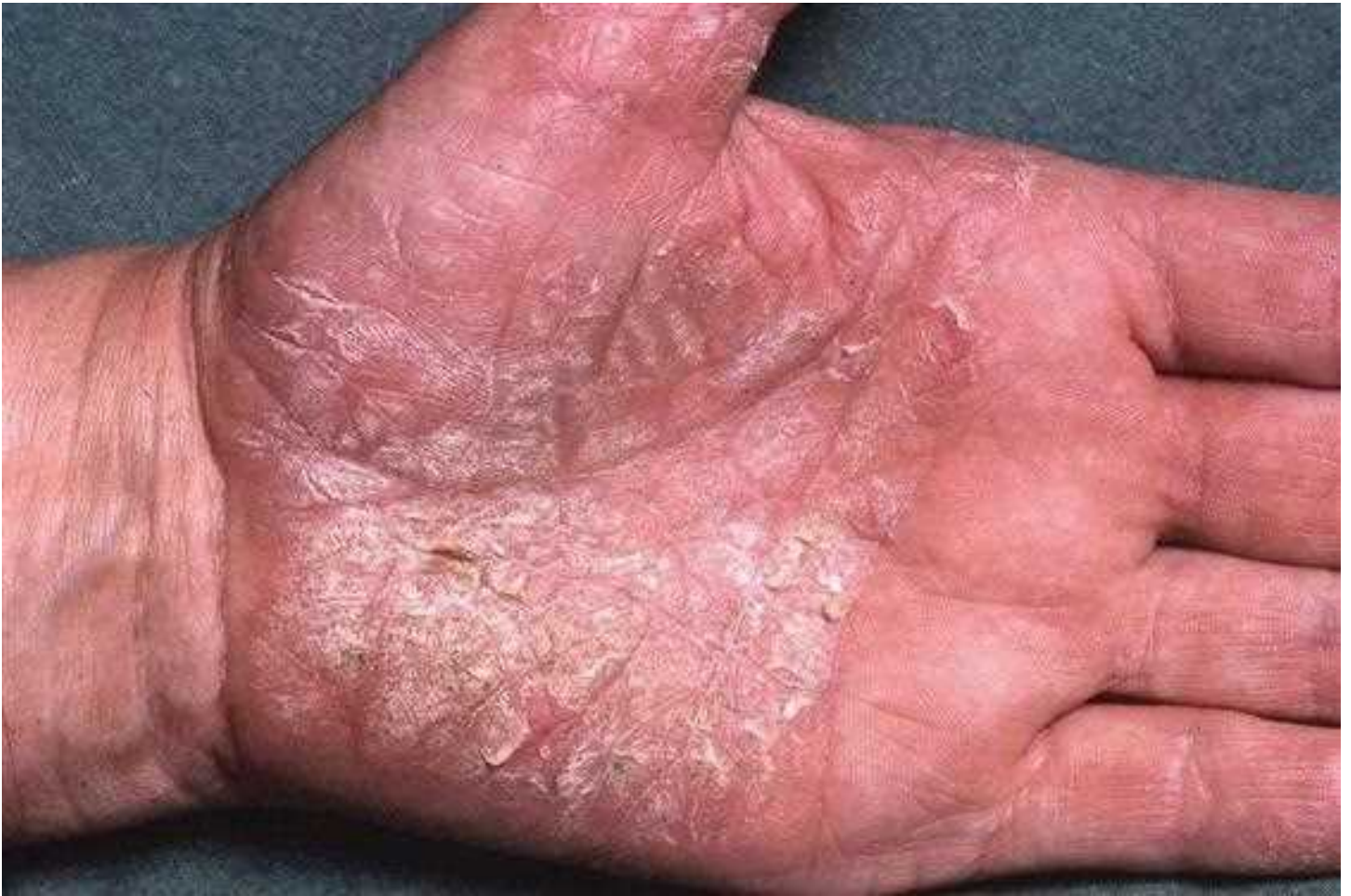

Figure 2.11 Hyperkeratotic palmar psoriasis.

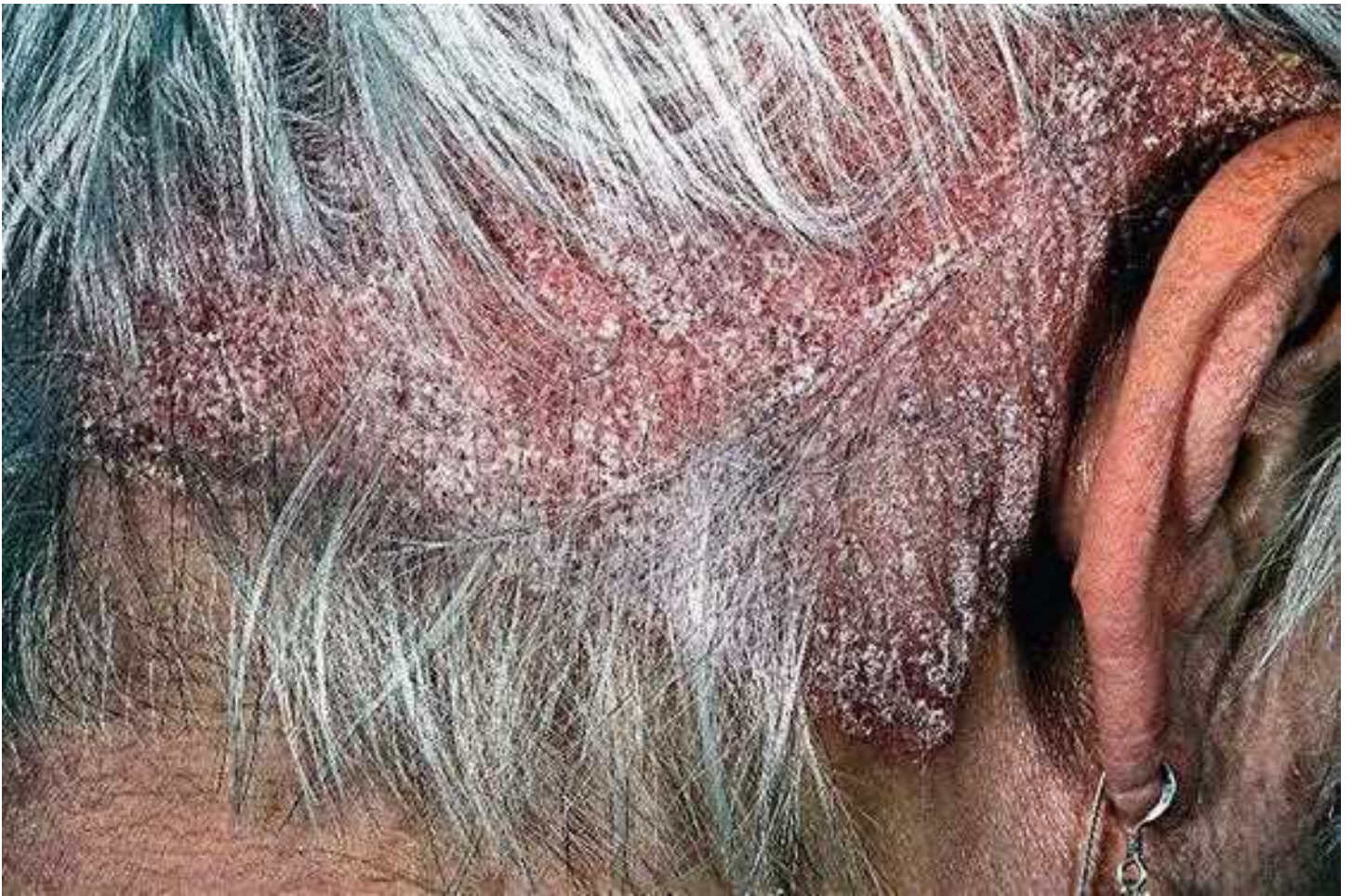

Figure 2.12 Scalp psoriasis.

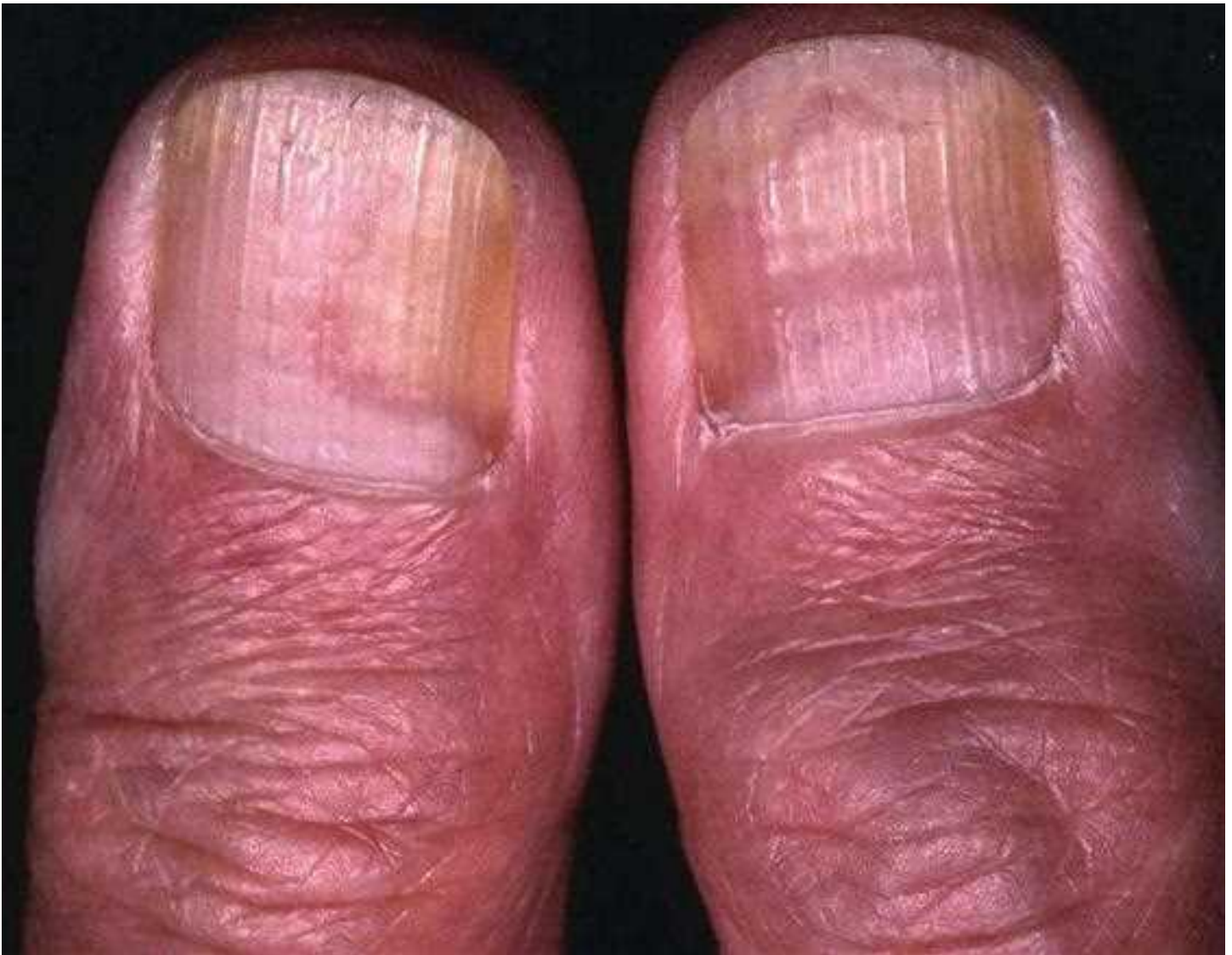

Figure 2.13 Onycholysis in nail psoriasis.

Guttate psoriasis – from the Latin *gutta*, a drop – consists of widespread small plaques scattered on the trunk and limbs ([Figure 2.14](#)). Adolescents are most commonly affected and there is often a preceding sore throat with associated group β -haemolytic streptococcus. There is frequently a family history of psoriasis. The sudden onset and widespread nature of guttate psoriasis can be very alarming for patients, fortunately it usually resolves completely, but can be recurrent or herald the onset of chronic plaque psoriasis.

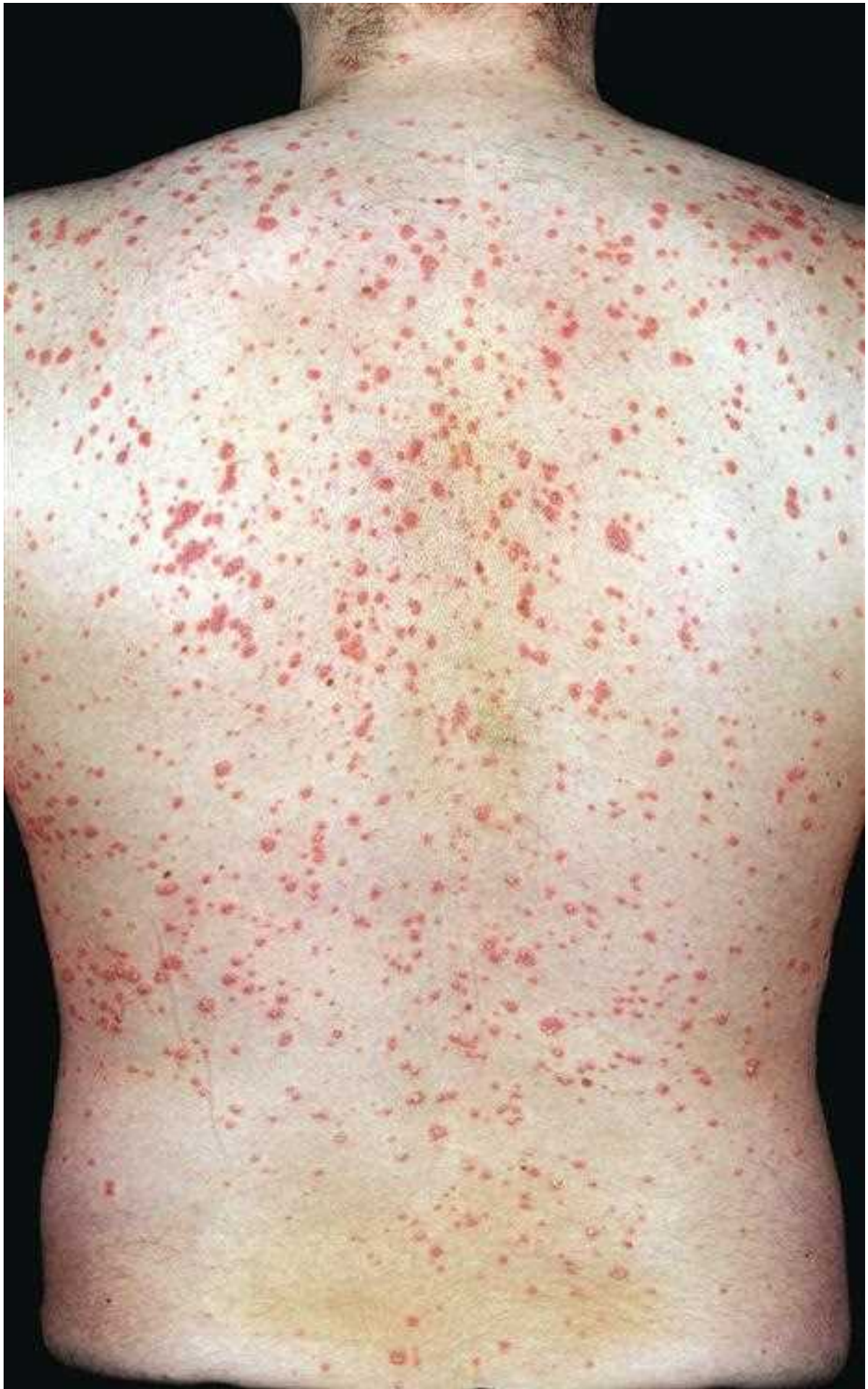

Figure 2.14 Guttate psoriasis.

Palmo-plantar pustular psoriasis (PPPP) is characterised by multiple sterile pustules on the palms and soles. Pustules first appear as yellowish monomorphic lesions that turn a brown colour with chronicity ([Figure 2.15](#)) and associated scaling. Most patients with PPPP are smokers.

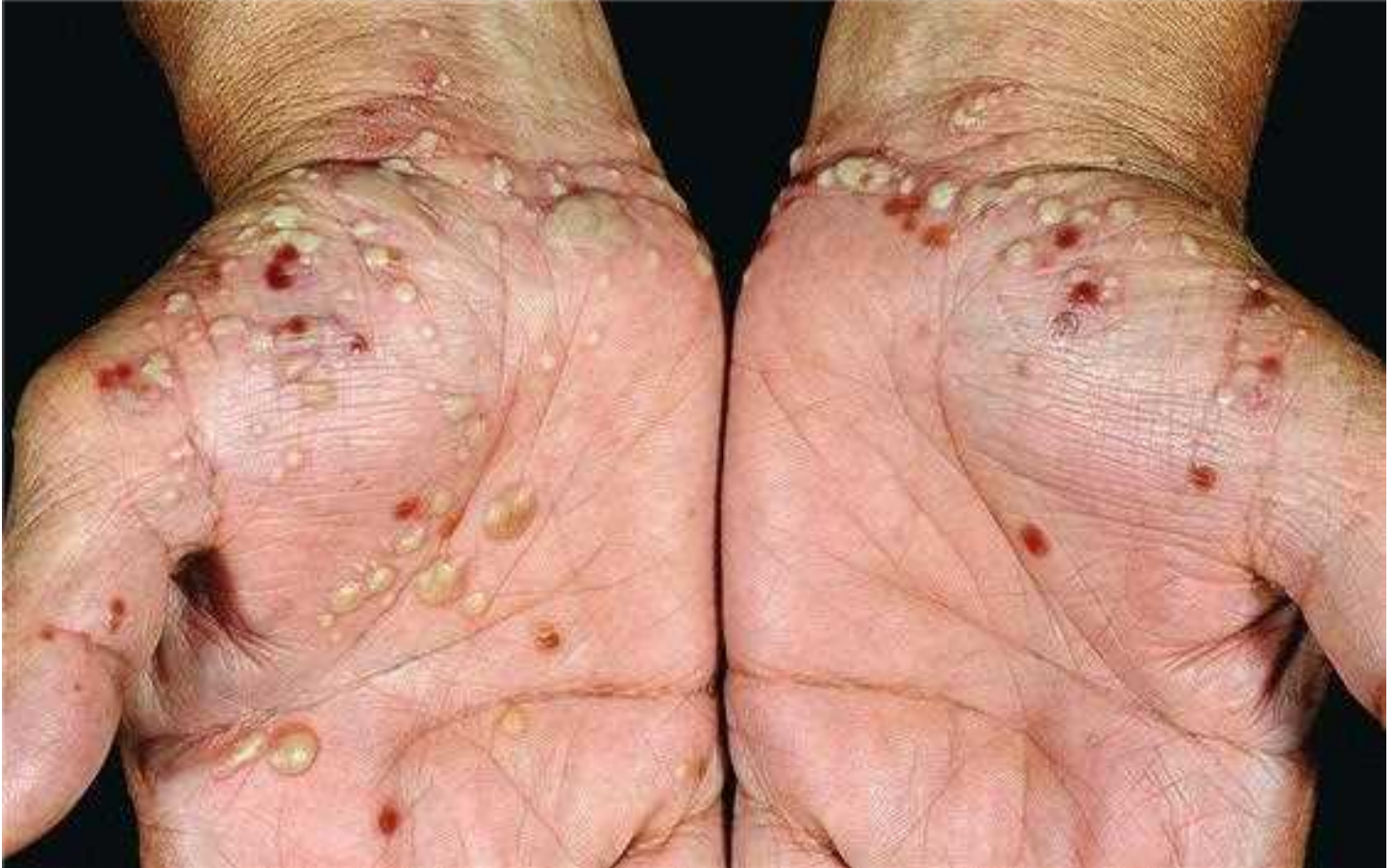

Figure 2.15 Palmar pustular psoriasis.

Generalised pustular psoriasis (GPP) is uncommon as it is usually an indicator of severe and unstable psoriasis ([Figure 2.16](#)). Mutations in IL36RN gene that encodes IL-36Ra have recently been identified in a proportion of patients with GPP. Clinically the skin becomes acutely erythematous and tender, with sheets of monomorphic sterile pustules, which can develop over a few hours/days. It may be precipitated by the patient taking systemic steroids or using potent topical steroids. The pustules usually occur initially at the peripheral margin of plaques, which are often sore and erythematous. Pustules eventually dry and the skin desquamates.

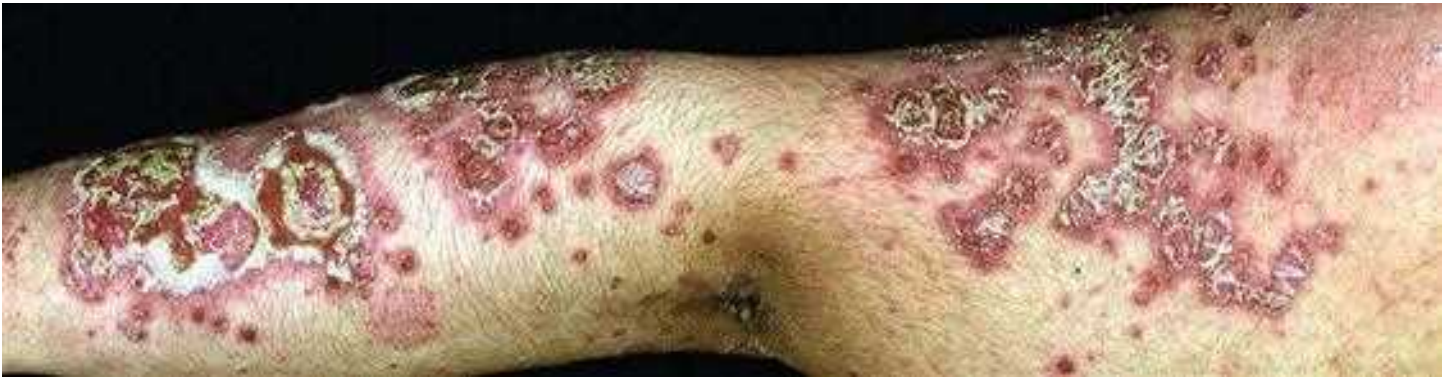

Figure 2.16 Acute unstable pustular psoriasis.

Acropustulosis is a rare variant of psoriasis that usually occurs in young children. Here pustules appear around the nails and the fingertips, associated with brisk inflammation.

Flexural psoriasis produces well-defined erythematous areas in the axillae, groin, natal cleft, beneath the breasts, and in skin folds. Scaling is minimal or absent ([Figure 2.17](#)). It should be distinguished from a fungal infection and if there is any doubt a specimen for mycology should be taken.

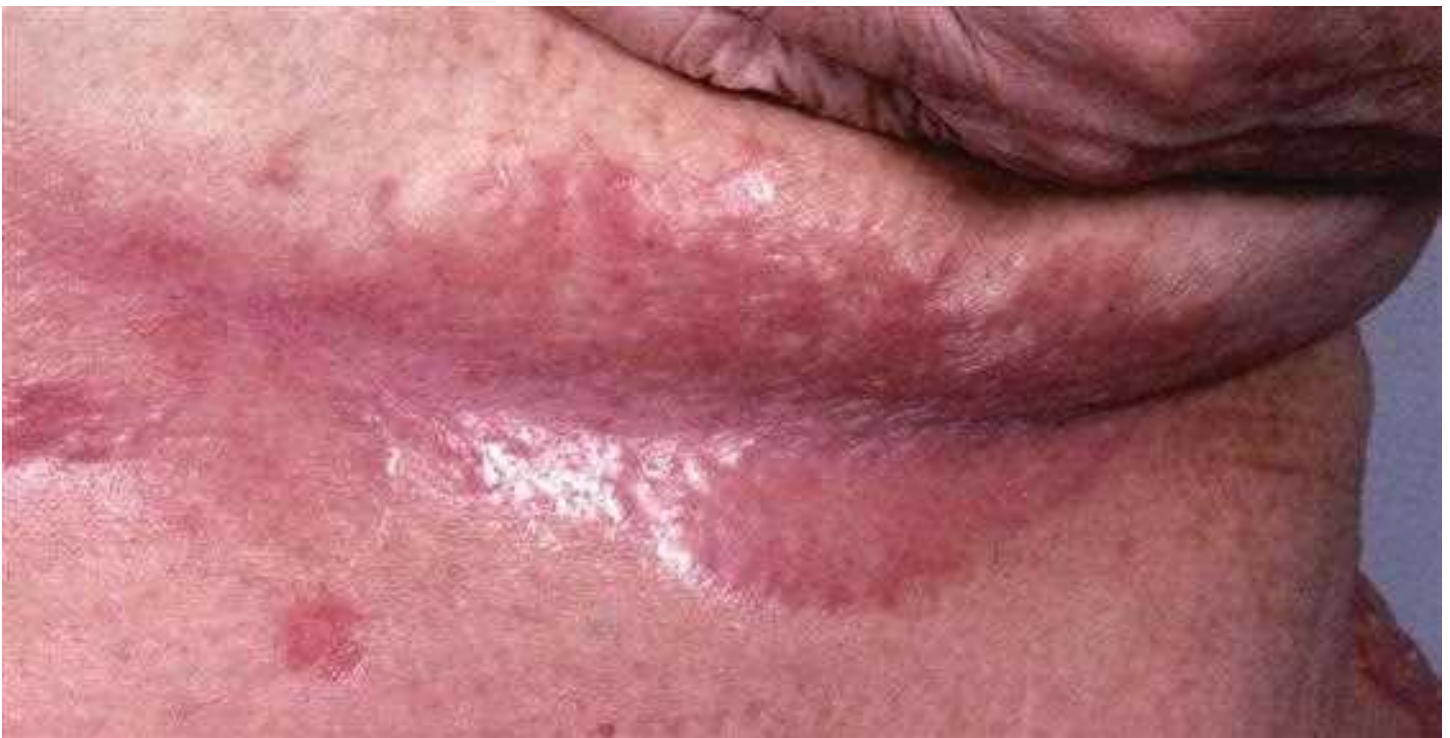

Figure 2.17 Flexural psoriasis.

Napkin psoriasis in children may present with typical psoriatic lesions or a more diffuse erythematous eruption with exudative rather than scaling lesions ([Figure 2.18](#)).

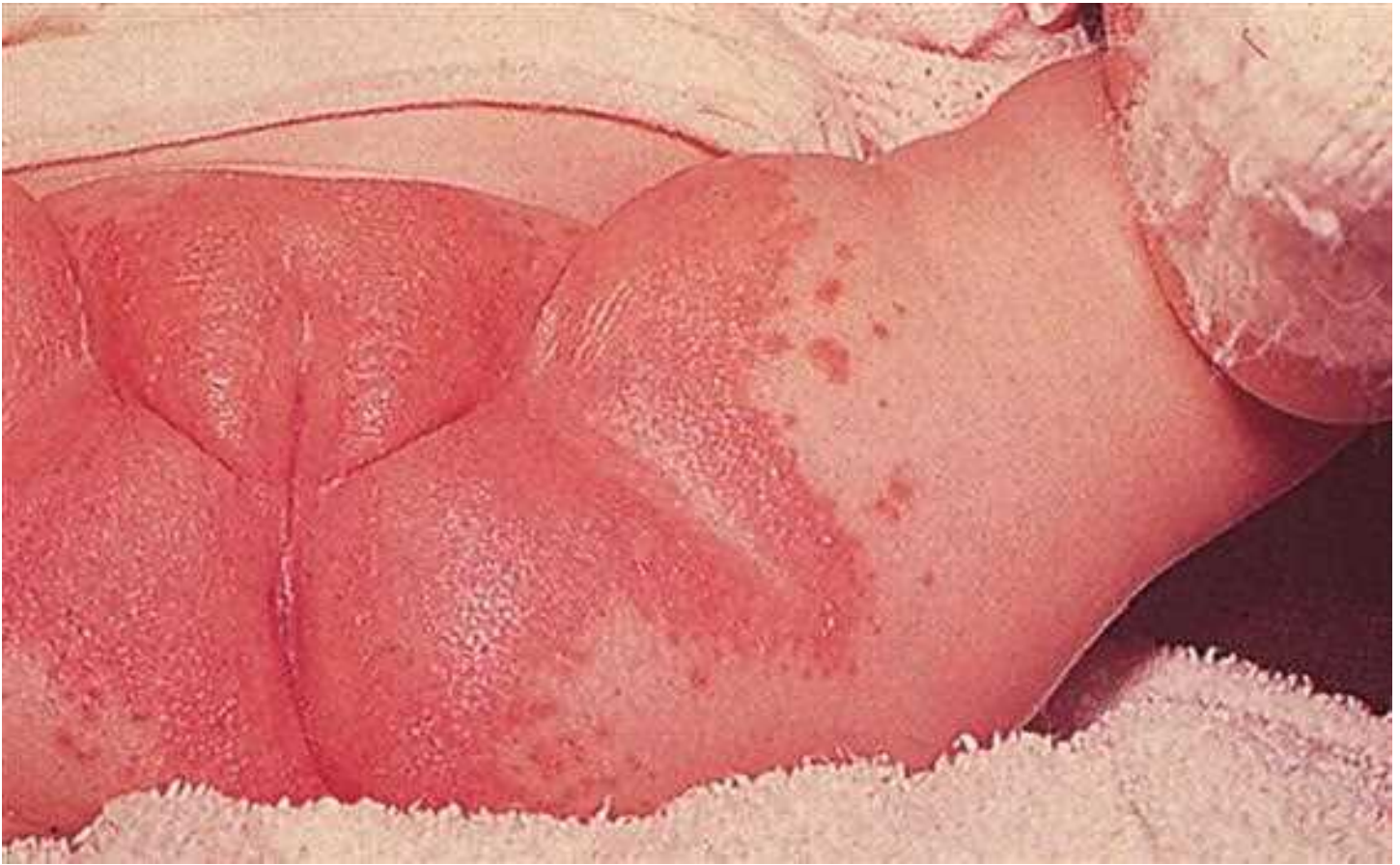
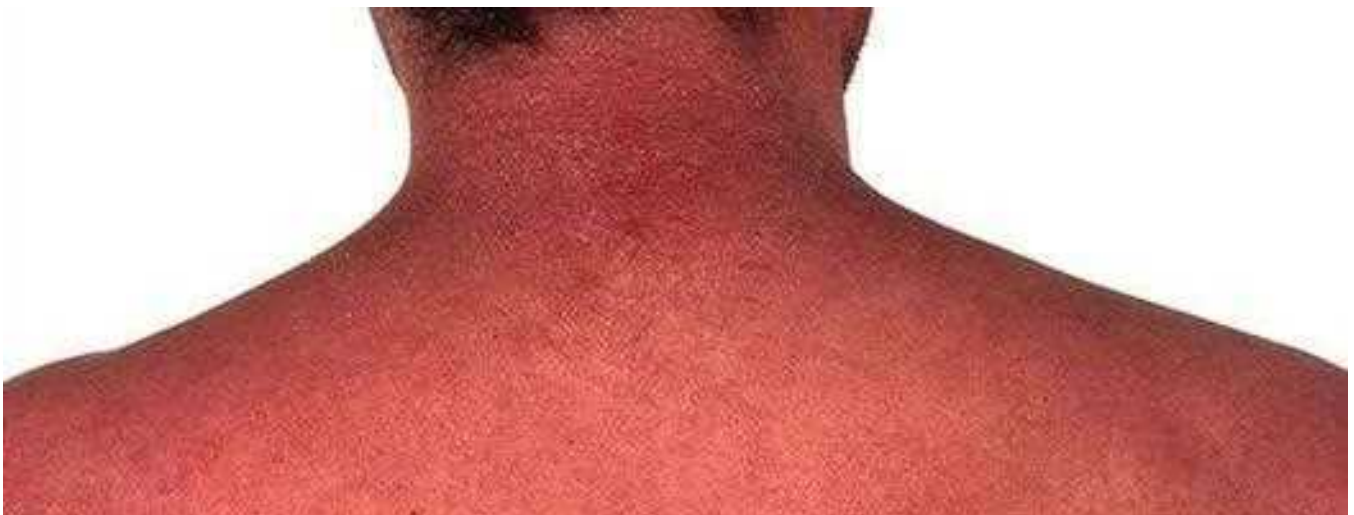
Figure 2.18 Napkin psoriasis.

Erythrodermic psoriasis is a serious, even life-threatening condition, with confluent erythema affecting nearly all of the skin ([Figure 2.19](#)). Diagnosis may not be easy as the characteristic scaling of psoriasis is absent. Chronic plaque psoriasis usually, but not always, precedes the erythroderma. Triggers for erythrodermic psoriasis include withdrawal of systemic steroids, infections, excessive alcohol intake, antimalarials, lithium, and low calcium. Complications of erythrodermic psoriasis result from increased cutaneous blood flow and fluid loss, including heart failure, hypothermia, dehydration, low protein and consequent oedema, secondary infection, and death. Patients should be managed in hospital under the care of a dermatology specialist.



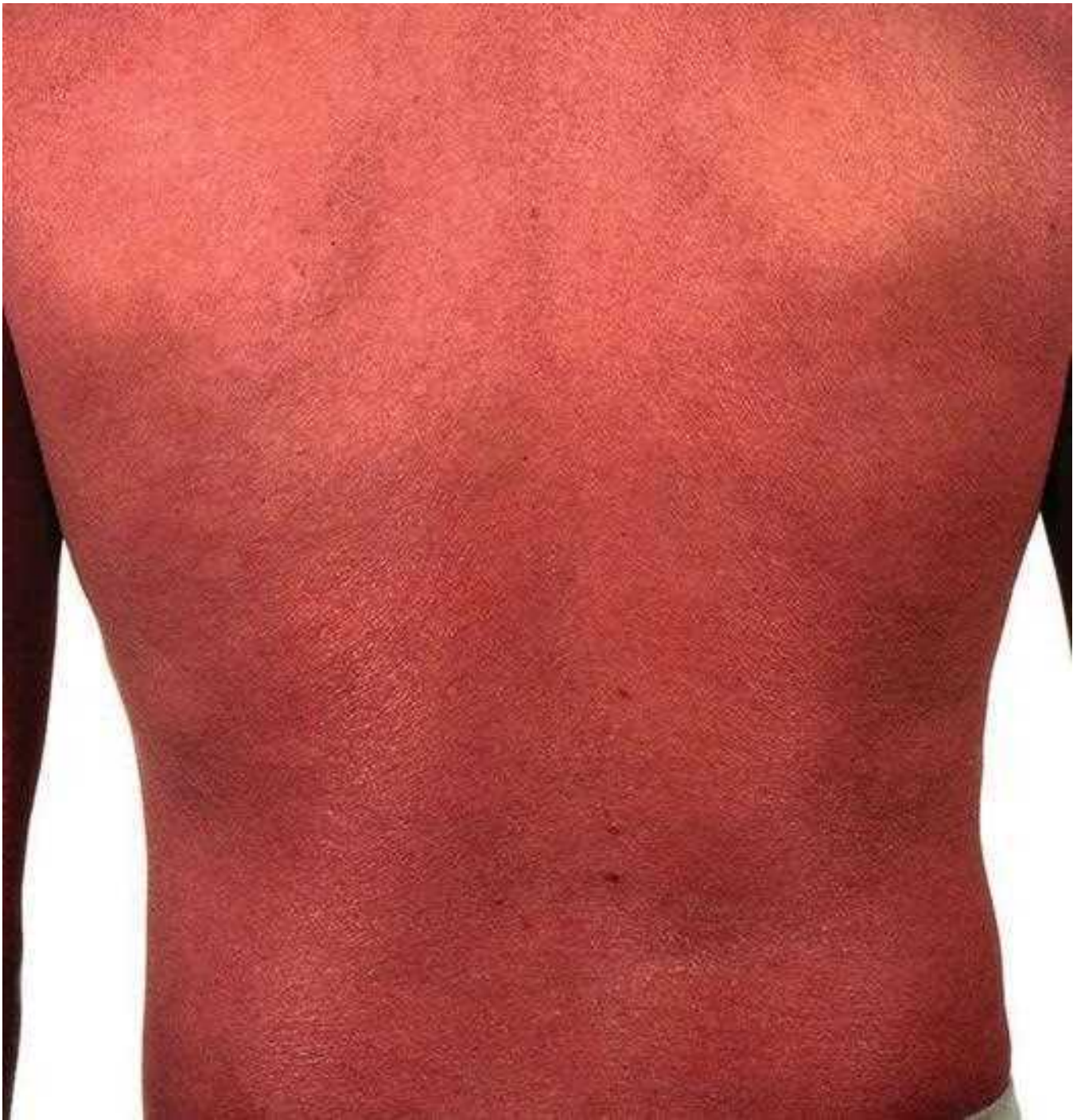

Figure 2.19 Erythrodermic psoriasis.

Psoriatic arthritis – pathophysiology

PA is an inflammatory arthritis which may be associated with psoriasis; there is genetic predisposition plus immunological/environmental triggers. PA is primarily a disease involving activated CD8 T-memory cells. Genetic susceptibility loci identified as playing a role in PA include HLA-B7, -B27, -B17, -CW6, -DR4, and -DR7, and linkage studies point to the short arm of chromosome 6. Recent studies have shown that gene polymorphisms associated with TNF- α are also important in the development of PA. Immunological stimuli

are thought to include complement activation and an increase in T-helper cell cytokine activity including TNF- α , IL-10, and IL-1 β , which in turn stimulates increased fibroblast proliferation and activity in the synovium of affected joints. Environmental factors such as infections, superantigens, and trauma have also been associated with the onset of PA but the exact mechanisms are poorly understood. Examination of the affected joints at the cellular level shows an increase in tortuous blood vessels within the synovium, which is thought to result from over-expression of angiogenic growth factors (vascular endothelial growth factor (VEGF) and transforming growth factor beta (TGF- β)). Erosions and osteolysis result from osteoclast proliferation and activation which is triggered by cytokine activity.

Psoriatic arthritis – clinical presentation

Psoriatic arthropathy is reported to affect 5–10% of patients with psoriasis ([Figure 2.20](#)), and of these 40% have a family history of psoriasis. Usually seronegative, this type of arthritis in the context of psoriasis is thought to be human leukocyte antigen (HLA) linked. Characteristically, patients develop skin manifestations of psoriasis prior to joint involvement, but in 15% of patients this is reversed. There are five recognised patterns of arthropathy associated with psoriasis. The distal interphalangeal (DIP) joints are most commonly affected (metacarpophalangeal joints are spared), which helps distinguish PA from rheumatoid arthritis. The arthropathy is usually asymmetrical. The sex ratio is equal; however, there is male predominance in the spondylitic form and female predominance in the rheumatoid form. Arthritis mutilans is a rarer form, where there is considerable bone resorption, leading to ‘telescoping’ of the fingers. Radiological changes include a destructive arthropathy with deformity ([Figure 2.21](#)). Recent magnetic resonance imaging (MRI) studies have shown that the joint inflammation in PA results from extensor tendon enthesitis (sites where tendons insert into bones) at the nail bed in DIP joint disease rather than intra-articular joint synovitis.

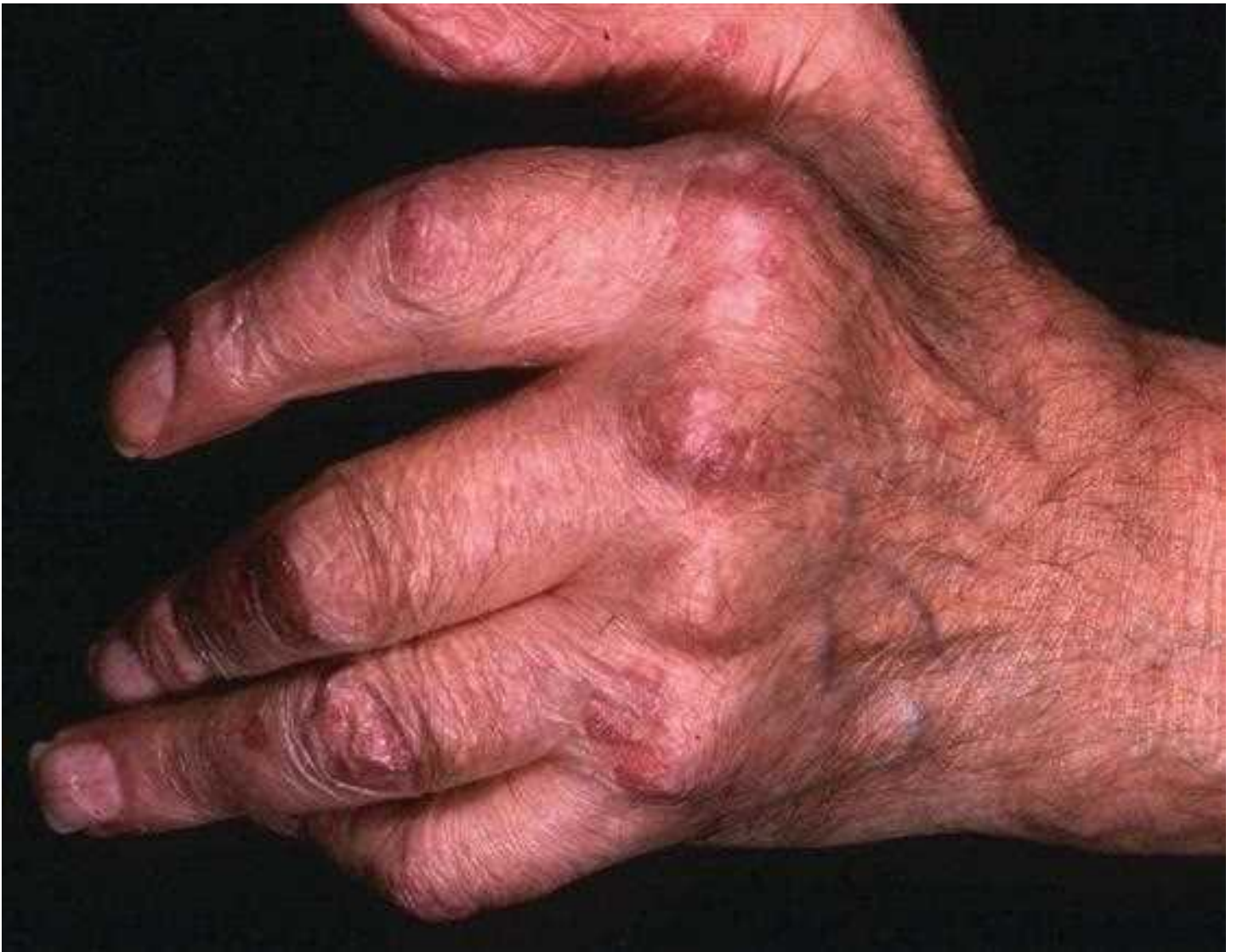

Figure 2.20 Chronic psoriatic arthropathy.

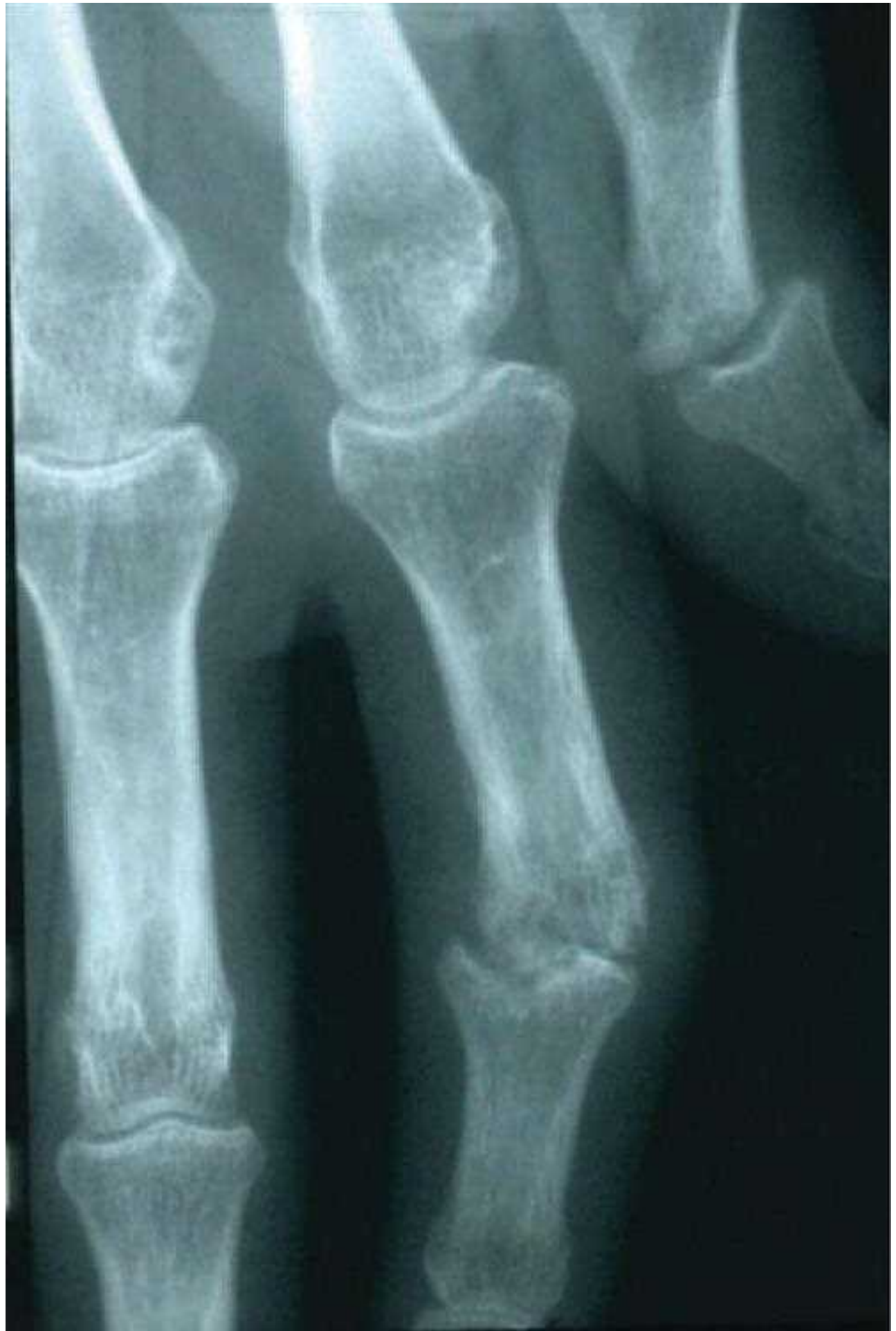

Figure 2.21 Acute arthropathy X-ray signs.

Psoriatic arthropathy usually waxes and wanes but can be severe enough to cause significant functional disabilities. Stiffness, pain, and joint deformity are the most common manifestations.

Five types of psoriatic arthropathy:

- *DIP joints* (80% have associated nail changes)
- *asymmetrical oligoarticular* arthropathy (hands and feet, 'sausage-shaped' digits)
- *symmetrical polyarthritits* (hands, wrists, ankles, 'rheumatoid pattern')
- *arthritis mutilans* (digits, resorption of bone, resultant 'telescoping' of redundant skin)
- *spondylitis* (asymmetrical vertebral involvement, male preponderance) HLA-B27 associated.

Psoriasis and systemic disease

Psoriasis and cardiovascular disease (CVD)

Psoriasis has recently been shown to be an independent risk factor for CVD such as myocardial infarction, stroke, cardiovascular death, and arrhythmias. Psoriasis is a chronic inflammatory disease and we know that inflammation is critical to atherogenesis. The spleen is thought to play a role in atherosclerosis-associated immunity which in turn affects inflammation in the great vessels such as the aorta. Patients with psoriasis have been shown to have systemic inflammation in the spleen-atherosclerosis axis. In addition, a mouse model of psoriasis showed macrophages had a proatherosclerotic phenotype with increased lipid uptake and a sixfold increase in cholesterol crystal formation. Studies have shown patients with psoriasis often have untreated cardiovascular risk factors such as hypertension and dyslipidaemia, so we need to bear this in mind when managing psoriasis patients in the clinic. Indeed, immunobiological therapies (such as interleukin-23/IL-17 antagonists) to treat psoriasis not only clear inflammation in the skin but also in the internal organs, in other words they modify the systemic components of the disease as well as clearing visible skin plaques. This inflammatory burden suffered by patients with psoriasis will have profound implications for their holistic management in the future.

Psoriasis and non-alcoholic fatty liver disease (NAFLD)

Psoriasis patients are at increased risk of NAFLD and more severe NAFLD than the general population. NAFLD is a precursor to the development of type II diabetes and the metabolic syndrome. Studies have shown that early onset of psoriasis (age < 40 years) was independently associated with a greater risk of developing NAFLD, hypertriglyceridemia, hyperuricemia, and a lower risk of developing diabetes compared to late onset psoriasis. Psoriasis and NAFLD are both characterised by chronic low-grade inflammation that can

lead to increased levels of pro-inflammatory adipokines (TNF- α and IL-6), and hepatokines, and decreased levels of adiponectin, an anti-inflammatory adipokine. This imbalance is thought to lead to peripheral insulin resistance and the development of NAFLD. Diagnosing NAFLD is complex and usually made by hepatologists using non-invasive tests, rather than liver biopsy if possible. Probability of NAFLD can be made using a combination of the best validated tests: transient elastography, FIB-4 (calculated from Age \times AST/platelet count \times \sqrt ALT) and the NAFLD fibrosis score.

Further reading

Adebajo, A., Boehncke, W.H., Gladman, D.D., and Mease, P.J. (2016). *Psoriatic Arthritis and Psoriasis: Pathology and Clinical Aspects*. Springer.

Ahmad, P.S. and Hussan, I. (2016). *A Comprehensive Textbook of Psoriasis*. Jaypee Med Pub.

www.bad.org.uk/heathcare/guidelines

CHAPTER 3

Management of Psoriasis

Rachael Morris-Jones

Guy's and St Thomas' NHS Foundation Trust, London, UK

OVERVIEW

- Management of psoriasis is related not only to the severity of the disease but also to patient expectation.
- The treatment ladder usually starts with topical therapy, phototherapy, and finally systemic medication.
- New biological agents are transforming the management of patients with severe disease who have failed on conventional therapies.
- Evidence suggests that psoriasis is a multiorgan disease, so treating early with systemic therapy may become the new 'norm' to modify the internal components such as heart disease.
- Encouraging patients to stop smoking, lose weight, and reduce alcohol consumption is important to reduce their risk of cardiovascular disease/metabolic syndrome associated with psoriasis.

Introduction

When considering treatment options for patients with psoriasis it is important to assess the extent and severity of the disease and how much the condition is impacting the patient's life. Psoriasis area and severity index (PASI) should be used to quantify the extent and severity of the skin involvement. The impact of the disease on the patient's quality of life should be measured using a validated questionnaire such as the Dermatology Life Quality Index (DLQI) score or the psoriasis disability index (PDI). The questionnaires embrace all aspects of life including work, personal relationships, domestic situation, and recreational activities.

Patients often wish to know what has caused their psoriasis and are keen for a cure. However, our current understanding of psoriasis is that it is an inherited autoimmune disease that can be suppressed by current therapies rather than cured. Management comprises avoidance of known exacerbating factors (smoking, alcohol), using topical preparations, undertaking phototherapy or photochemotherapy and taking systemic therapy (tablet, S/C, IV). Selection of the most appropriate treatment for each patient should be tailored to the type of psoriasis, their age, comorbidities, social and occupational factors, quality of life, and patient acceptability. Patients with mild disease usually start with topical therapy and/or ultraviolet

treatment, if the disease becomes more extensive/recalcitrant they may switch to more potent systemic agents (see [Table 3.1](#) for management options).

Table 3.1 Management of psoriasis.

| Type of psoriasis | First line | Second line | Review patient |
|---|--|---|---|
| Localised stable plaques | Tar preparations Vitamin D analogues Salicylic acid preparations Topical steroids | Dithranol/ichthammol TL01 (UVB) | Initial review after 4–6 wk, once established 3–4 mo |
| Extensive stable plaques (usually more than 10% body surface area affected) | TL01 (UVB) PUVA Acitretin PUVA + Acitretin | Methotrexate Ciclosporin A Hydroxyurea Biological agents | Initially review after 2–4 wk, once established 3–4 mo |
| Widespread small plaque | TL01 (UVB) | Steroid with LPC | 4–6 wk |
| Guttate psoriasis | Moderate-potency topical steroids TL01 (UVB) | Steroid with LPC | 4–6 wk |
| Facial psoriasis | Mild–moderate potency topical steroid | Steroid with LPC | 4–6 wk |
| Flexural psoriasis | Mild–moderate potency topical steroid + antifungal | Methotrexate | 4–6 wk then 3–4 mo |
| Pustular psoriasis of hands and feet | Moderate-potency topical steroids Potent topical steroid + propylene glycol ± occlusion | Acitretin Methotrexate Hand and foot PUVA | 4–6 wk initial review and then 3–4 mo into phototherapy or systemic therapy |
| Acute erythrodermic, unstable/generalised pustular psoriasis | In-patient management Short-term mild topical steroids | Methotrexate Ciclosporin Biological therapy | Daily review initially then weekly |

Key: PUVA, psoralen with ultraviolet A; TL01, narrow-band ultraviolet B; UVB broad band ultraviolet B; LPC, Liquor Picis Carbonis.

Dermatology day treatment units

Dermatology day treatment units (DDTUs) facilitate the management of psoriasis, particularly in relation to topical therapy, phototherapy, and administration of intravenous or subcutaneous injections. Benefits of the DDTU include compliance, monitoring, education, counselling/support and an overall reduction in the patients' stress levels. Less commonly now short-contact dithranol and crude coal tar that can be applied to psoriatic plaques by specialist nurses. Phototherapy is delivered in custom-built cabinets and regular administration of biological therapy can be given by specialist nurses in IV suites. These day units have almost completely excluded the need for in-patient admissions except for unstable/erythrodermic disease.

National Institute for Health and Care Excellence (NICE) Guidelines on the management of psoriasis can be found online. The principles of treatment are to discuss the diagnosis and treatment options with the patients. Use the Physicians/Patients Global Assessment scores, or PASI/DLQI (as outlined below) to give a measure of disease severity, to assist in deciding on the best treatment option for the patient and to assess efficacy of treatments given. NICE recommend reviewing adults after four weeks and children after two weeks of initiating treatment.

Psoriasis Area and Severity Index (PASI) Score is a validated tool for assessing and documenting the extent and severity of a patient's psoriasis. This can be calculated prior to and following treatments. The full PASI scoring system can be accessed online and in mobile phone apps. But the basic principle is to assess the erythema, scaling and thickness of plaques and the % involvement of each site (head, upper limbs, trunk, lower limbs) to generate a total score. To qualify for systemic/biological therapy most patients would need to have a PASI score of 10 or greater.

Dermatology Life Quality Index (DLQI) Score is a validated questionnaire developed in 1994 at Cardiff university for assessing the impact of skin conditions on a patient's quality of life. A copy can be assessed online with instructions and conditions of use. The questionnaire consists of 10 questions relating to how the patient's skin condition is affecting their activities of daily living, psychological well-being, treatment issues etc. The higher the score, the more the skin condition is adversely affecting the patient's quality of life. It is a very useful tool to use in addition to the PGA/PASI for assessing management needs and outcomes.

Topical treatment

Topical treatments are those applied directly to the skin surface, including ointments, creams, gels, tars, lotions, pastes, and shampoo. The topical approach to therapy results in changes at and just below the skin surface (epidermis and dermis). Conventionally, topical medicaments are applied directly to the diseased skin only, in contrast to moisturisers (emollients), which are usually applied more freely. In general, combination therapy is more effective than monotherapy, and change of therapy is superior to continuous usage. The following are the *advantages* of topical treatments:

- local effects only

- self-application
- safe for long-term use
- relatively cheap.

The following are the *disadvantages* of topical treatments:

- time consuming in extensive disease
- poor compliance (insufficient amounts and frequency)
- messy and may affect clothing/bedding/hair
- no benefit for associated joint disease
- tachyphylaxis (become less effective with continuous use).

The majority of psoriasis patients with mild to moderate disease can be managed in the community by their general practitioner. Patients should be reviewed after four to six weeks of treatment to assess efficacy, if progress is insufficient despite concordance then second line treatment should be considered. Patients with very extensive, recalcitrant, or unstable psoriasis and associated severe arthritis are usually managed in specialist dermatology centres.

Emollients act as a barrier to cutaneous fluid loss, relieve itching, and help replace water and lipids and therefore restore the barrier function of dry skin. Patients can purchase these over the counter, and personal preference/acceptability usually guide their choice. Regular application of emollients should be encouraged in all patients with dry/flaky skin.

Coal tar (produced by distillation of bituminous coal) preparations are available for purchase over the counter and include ointments, pastes, paints, soaps, solutions, and shampoo. Coal tar is keratoplastic (normalises keratinocyte growth patterns), antipruritic (reduces itch), and antimicrobial. It can be used on stable chronic plaque psoriasis but will irritate acute, inflamed skin. Coal tar in combination with salicylic acid may be more effective for very thick plaques.

Ichthammol (ammonium bituminosulfonate) is a distillation of sulfur-rich oil shale. It has anti-inflammatory properties and is therefore suitable to be used on ‘unstable’ or inflamed psoriasis. Various preparations can be purchased over the counter including ichthammol ointment.

Dithranol (anthralin, Goa powder), originally derived from araroba trees, is now produced synthetically. Irritation and burning can occur if applied to normal skin; therefore, careful application to psoriatic plaques is needed ([Figure 3.1](#)). Normal skin can be protected with petroleum. Dithranol short/long contact temporarily stains the skin/hair a purple-brown colour. Dithranol creams can be applied to plaques for 30 minutes and then washed off. The strength is gradually increased from 0.1% to 3% as necessary. Strengths up to 1% can be purchased over the counter, whereas higher concentrations are available by prescription only.

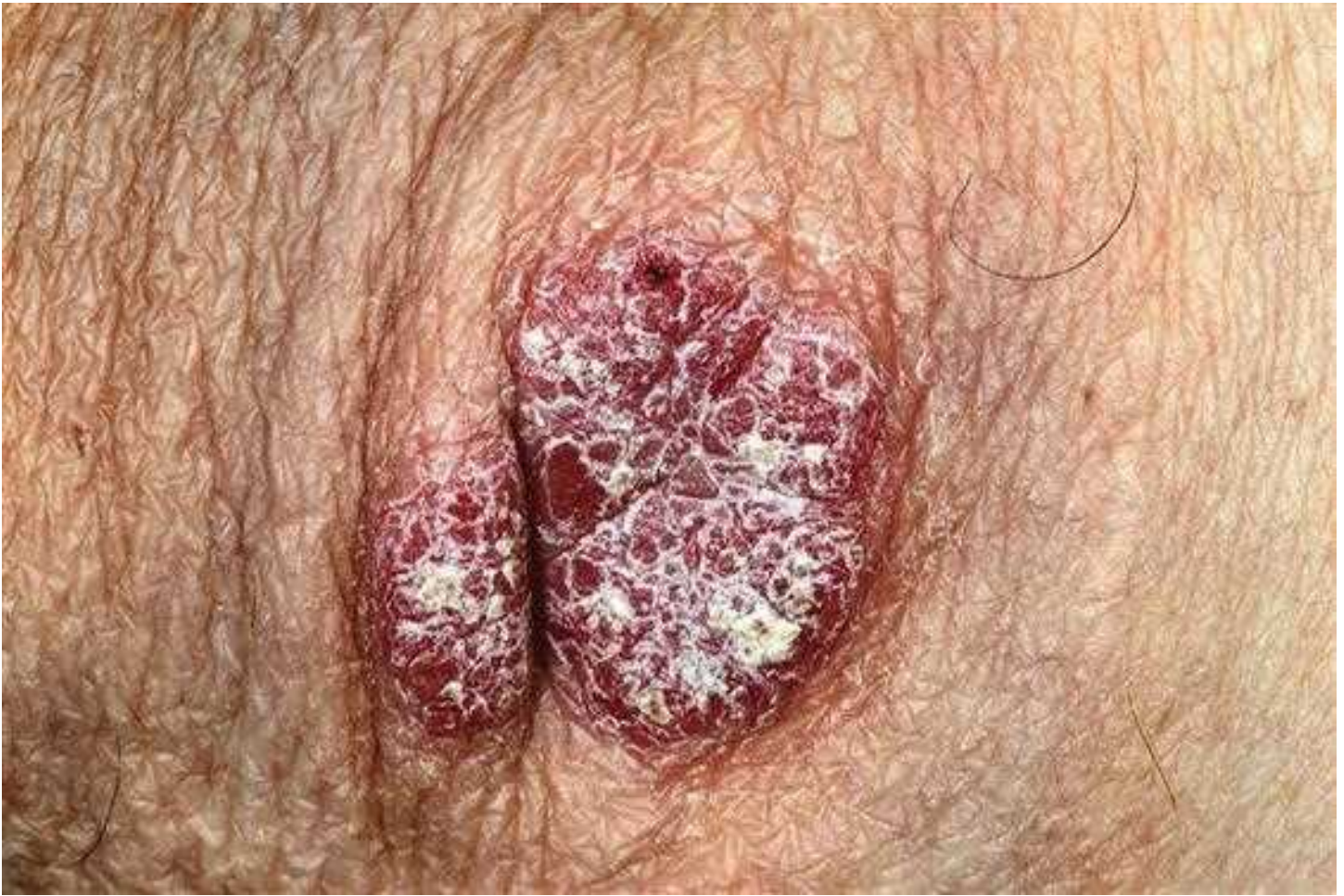

Figure 3.1 Psoriasis suitable for topical dithranol treatment.

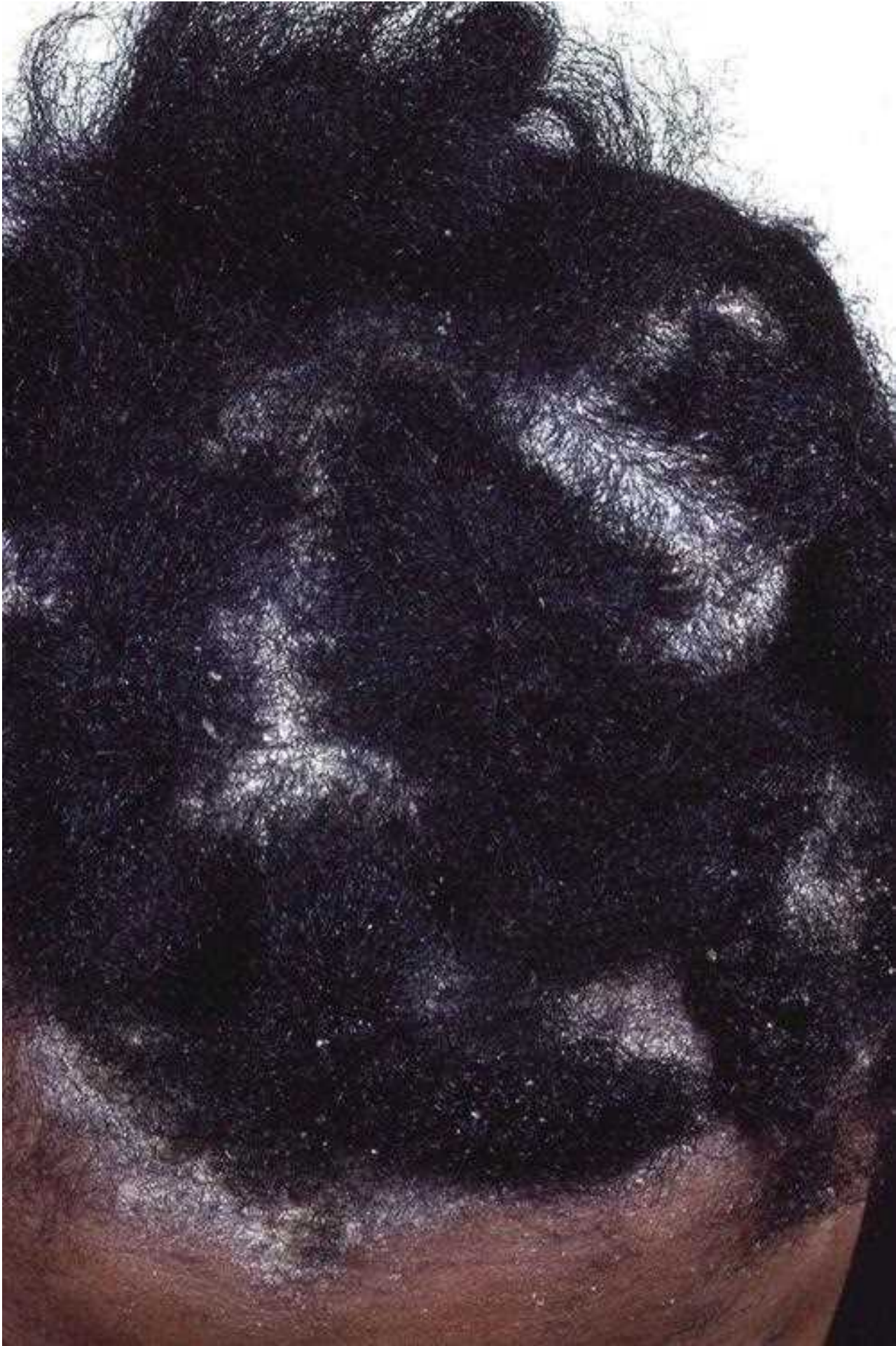Calcipotriol and *tacalcitol*, vitamin D analogues, are calmodulin inhibitors used topically for mild or moderate plaque psoriasis. Mild irritation can be experienced and after continuous use, a plateau effect may be encountered with the treatment becoming less effective after an initial response. These preparations are therefore best used in combination with other topical agents. It is important not to exceed the maximum recommended dose as there is a risk of altering calcium metabolism.

Corticosteroids in topical formulations are an important adjuvant to the management of patients with psoriasis; these are prescription-only preparations (except very mild steroids) and can be supervised by the general medical practitioner. Corticosteroids help reduce the superficial inflammation within the plaques. However, relapse usually occurs on cessation and tachyphylaxis is observed. Tachyphylaxis is thought to result from tolerance to the vasoconstrictive action of corticosteroids on cutaneous capillaries. Topical steroids should be applied to the affected areas of skin only once or twice daily. Manufacturers suggest topical steroids should be applied sparingly but this is difficult for patients to quantify; therefore, practitioners advise the use of finger-tip units (FTUs) as a guide. When the steroid ointment/cream is squeezed out from a tube, it comes out in a line, and the quantity between the finger-tip and the first skin crease is 1 FTU (approximately 500 mg) enough to cover a hand-sized area of skin (back and front of the hand).

The strength of topical steroids is graded from mild to very potent. Prolonged use of very potent topical steroids should generally be avoided in the treatment of chronic skin diseases such as psoriasis. Mild/moderate topical steroids are safe to use on the face and flexural skin, and in erythrodermic disease. Moderate or potent preparations can be used on chronic stable plaques on the body. Combination products seem to be among the most effective in the treatment of psoriasis, especially those containing salicylic acid, vitamin D, tar, and antibiotics. Systemic corticosteroids should not be used to treat psoriasis.

Scalp psoriasis

Scalp psoriasis affects approximately 50% of patients; it can be one of the earliest skin sites affected. Scalp psoriasis is often difficult to treat because of the thick nature of the scales, inaccessibility of the skin (owing to hair getting in the way) and the difficulty of self-application of treatment ([Figure 3.2](#)). Most patients need to treat the scalp regularly. Initially, products are rubbed into the affected scalp skin and left on overnight (combinations of tar, salicylic acid, sulfur, and emollient are used), and then washed out with tar-based shampoos; then steroid/salicylic acid/vitamin D-containing scalp applications/gels are applied to the underlying inflamed skin. This sequential and combination approach to scalp treatment is often successful if maintained. Treatment in the DDTU can be immensely helpful in the management of severe scalp psoriasis for patients who find it difficult to undertake this treatment themselves at home.



[Figure 3.2](#) Scalp psoriasis.

Ultraviolet treatment – phototherapy and photochemotherapy

The mechanisms of action of phototherapy are complex. Evidence suggests that phototherapy reduces the antigen-presenting capacity of dendritic cells, induces apoptosis of immune cells and inhibits synthesis and release of pro-inflammatory cytokines. The resultant cutaneous effects are those of topical immunosuppression and a reduction in dermal inflammation and epidermal cell turnover.

Phototherapy and photochemotherapy should be delivered in specialist dermatology units. It is suitable for psoriasis patients with extensive disease that has not cleared with topical therapy ([Figure 3.3](#)). Patients must be able to attend the phototherapy suite two to three times weekly on a regular basis for approximately six to eight weeks. Contraindications to treatment include a history of previous skin malignancy and photosensitive diseases such as lupus, porphyria, albinism, and xeroderma pigmentosum. A full drug history should be taken to ascertain whether the patient is taking any photosensitising medication.

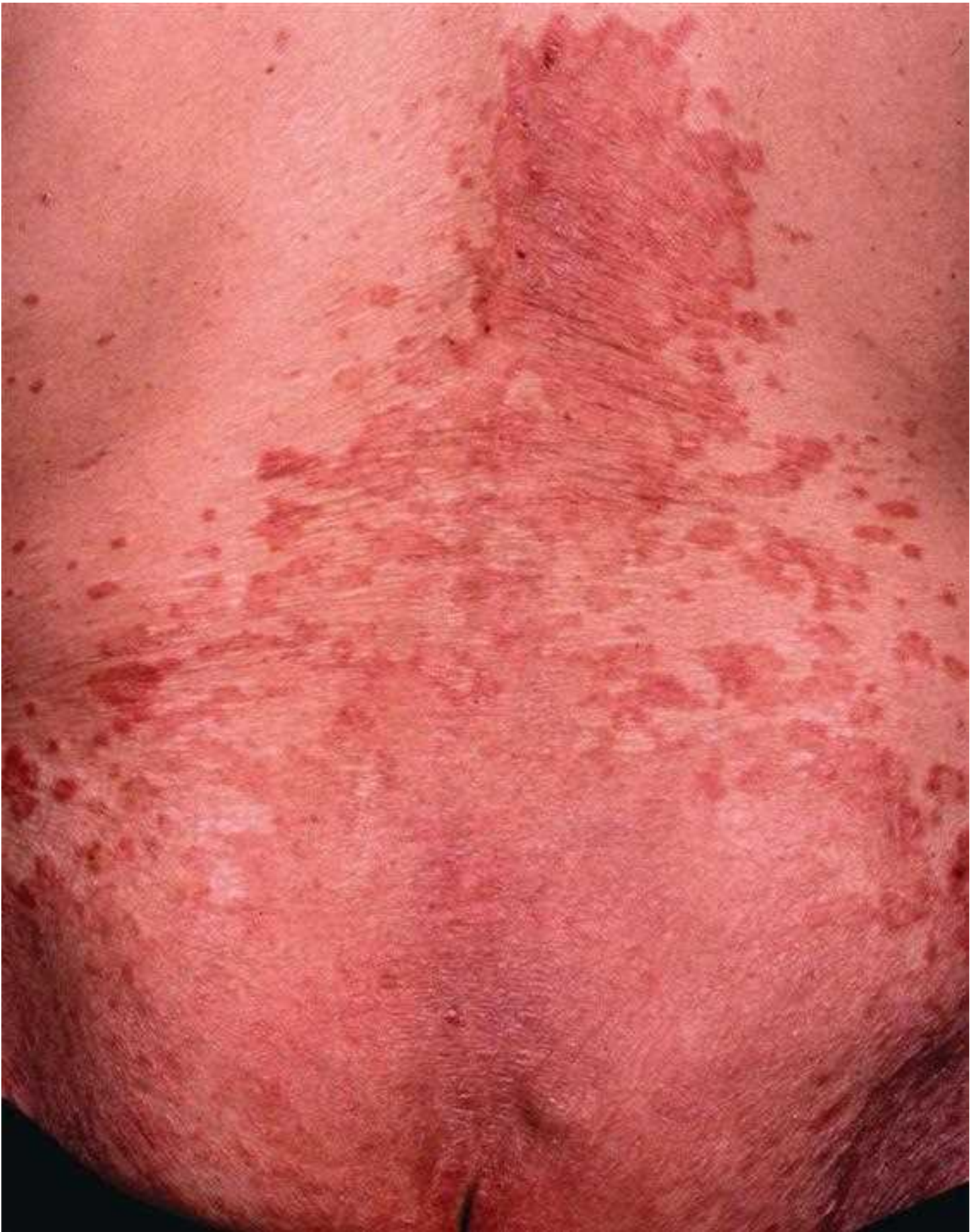
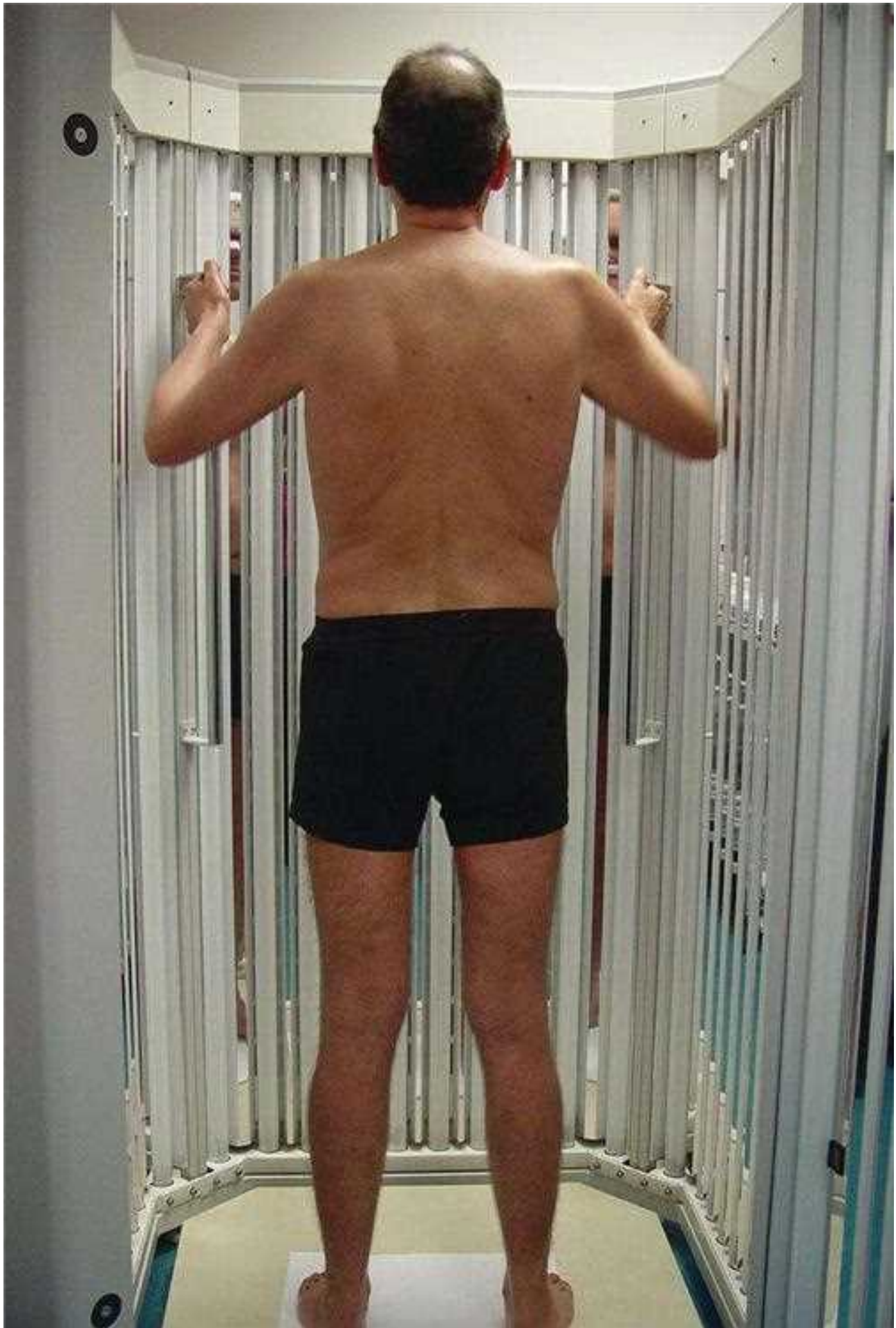
Figure 3.3 Thin plaques of psoriasis suitable for TL01.

Phototherapy is usually delivered in vertical irradiation units ([Figure 3.4](#)). The dose and time of exposure to light is gradually increased as the treatment progresses. Patients apply a layer of emollient to their skin before standing inside the cabinet (this helps remove surface scale and aids UV penetration), they wear UV protective goggles (to protect against corneal keratitis and cataract formation) and 'sanctuary sites' (genitals) are covered.



[Figure 3.4](#) Psoralen with ultraviolet A (PUVA) cabinet.

There is an increased risk of developing cutaneous malignancies with increasing cumulative doses of phototherapy. How much phototherapy can be given safely will depend on the patient's skin type and cumulative dose of UV received. In addition to the increased risk of cutaneous malignancy, premature ageing of the skin and multiple lentigines can result.

Current estimates suggest that patients can be given approximately 200 individual treatments (<1000 J) of light safely within their lifetime. Consequently, an individual patient's light 'quota' can soon be used up with a standard course comprising 20–30 treatments ([Figures 3.5](#) and [3.6](#)). Maintenance treatment with phototherapy is rarely now given for psoriasis. The total cumulative dosage is carefully monitored and kept as low as possible to reduce the risk of side effects.

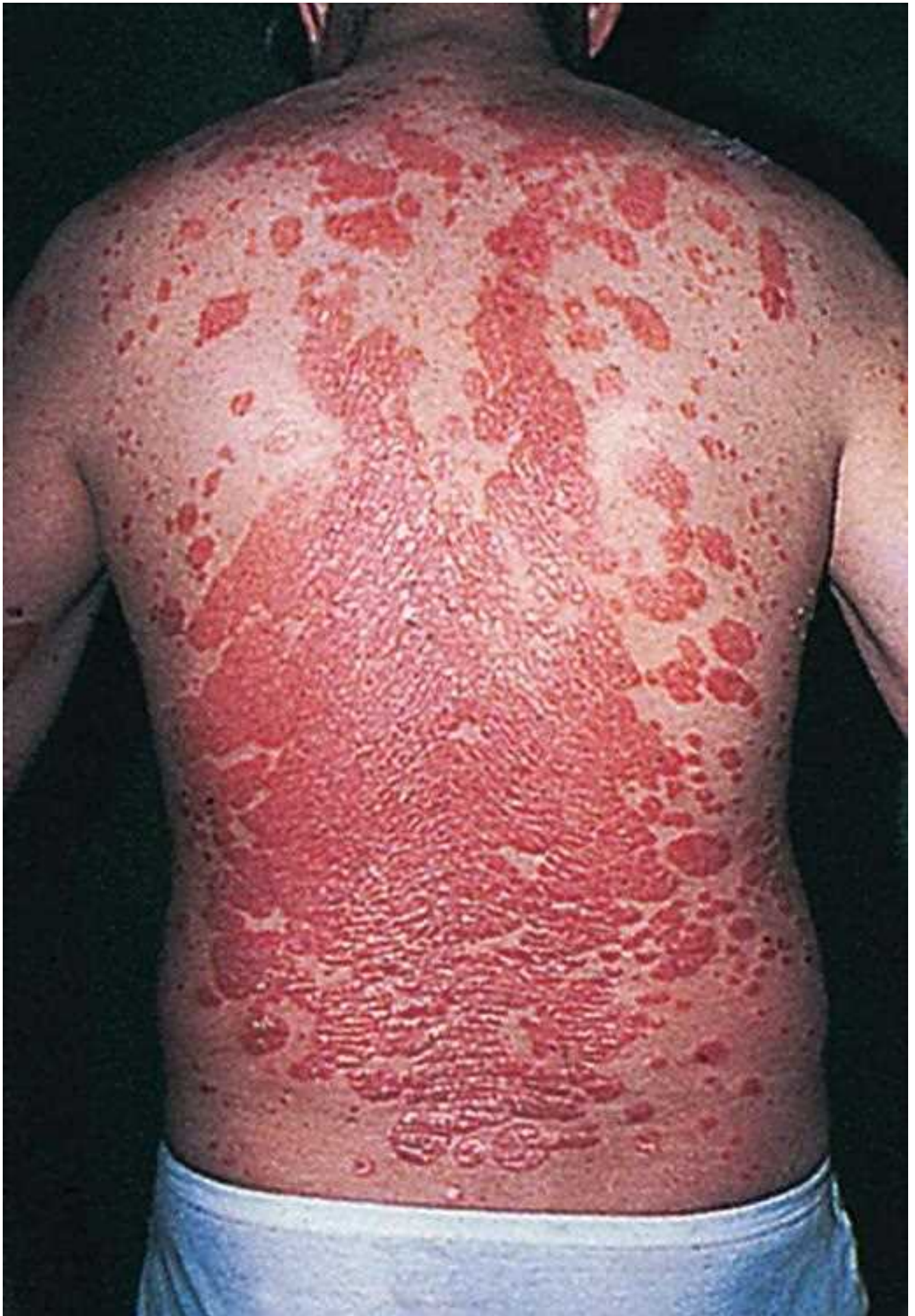
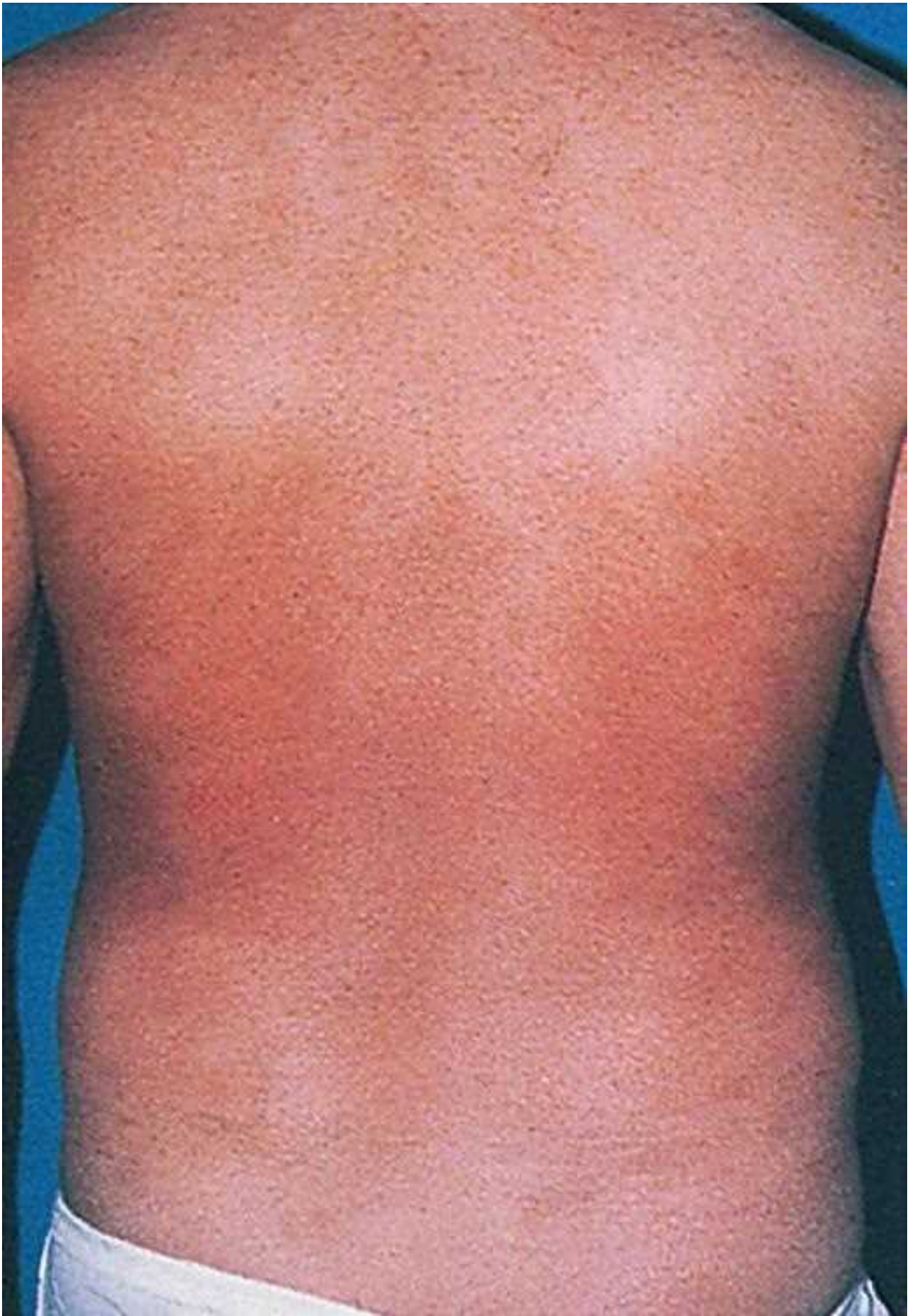
Figure 3.5 Psoriasis before phototherapy.



[Figure 3.6](#) Skin after phototherapy.

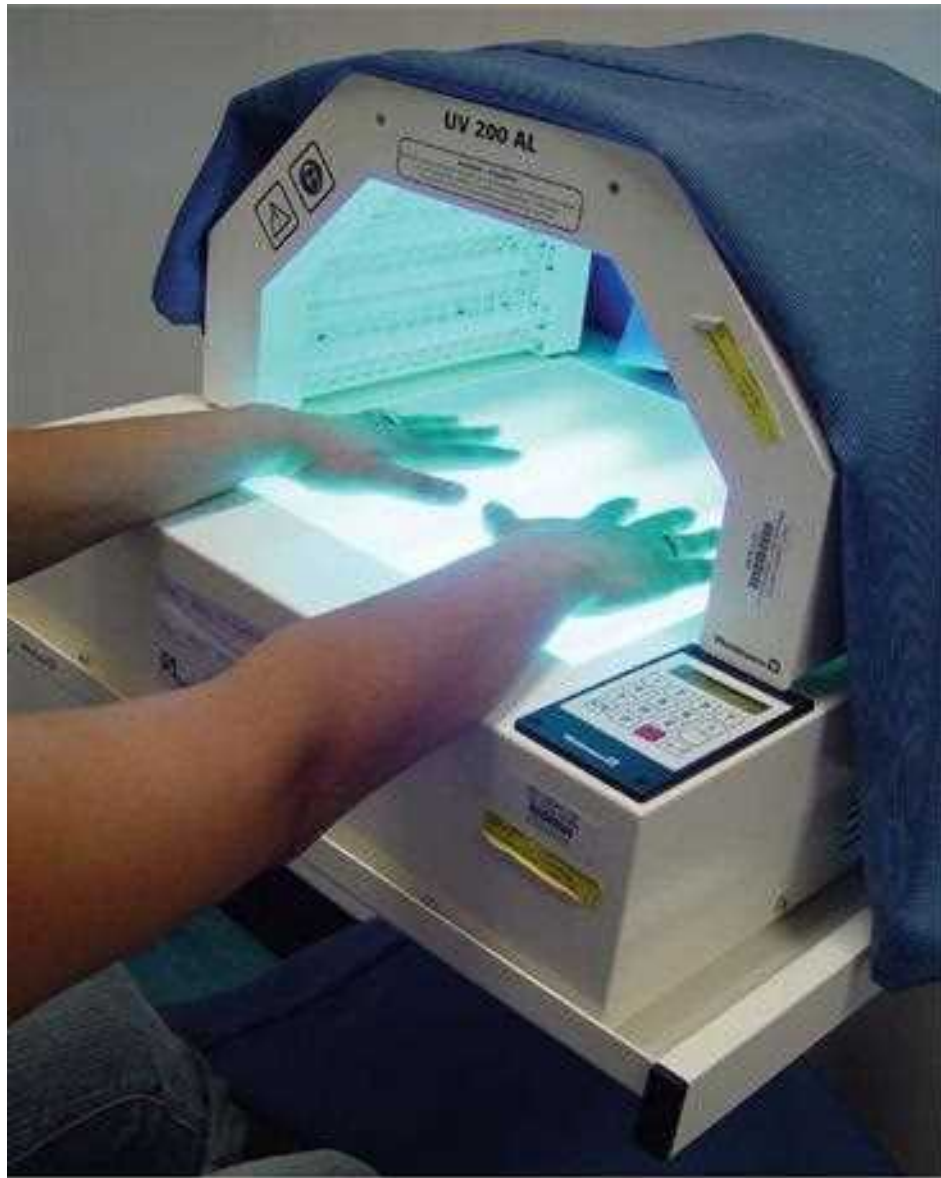Two main types of phototherapy are currently available, broadband ultraviolet B (UVB) and narrow-band ultraviolet B (TL01) and photochemotherapy ultraviolet A plus psoralen (PUVA). UVB phototherapy has advantages over PUVA as it can be used in children, during pregnancy and does not require the wearing of UV-blocking glasses pre/post-treatment.

Ultraviolet B (UVB)

UVB is short wavelength ultraviolet light and is administered three times weekly, (20–30 treatments) for widespread psoriasis. Conventional broadband UVB lamps emit wavelengths from 280 to 330 nm; these machines are largely being superseded by TL01 devices which emit ultraviolet light at 311 nm. TL01 is more effective than broadband UVB and there is a reduced risk of burning. The starting dose and subsequent increments (mJ/cm^2) for patients is usually based on measuring the MED (minimal erythema dose), which is the dose of UVB just sufficient to cause erythema (the patients starting dose will then commence at 70% of the MED for psoriasis). UVB can be given in combination with tar (Goeckerman regimen) or dithranol (Ingram regimen) for chronic thick plaques of psoriasis. UVB in combination with oral acitretin can also increase the efficacy.

Ultraviolet A (UVA)

UVA is long-wavelength ultraviolet light (320–400 nm) and is given in combination with oral or topical psoralen (PUVA) twice weekly (20–30 treatments) for recalcitrant widespread thick plaque psoriasis. There are two types of psoralen tablets: 8-methoxypsoralen (8MOP) 0.6 mg/kg body weight and 5-methoxypsoralen (5MOP) 1.2 mg/kg taken two hours before treatment. 8-MOP is associated with a higher incidence of side effects such as nausea, vomiting, pruritus, and erythema and is consequently less commonly used than 5MOP. The MPD (minimum phototoxic dose) or skin phototype is used to determine the starting dose of UVA and the subsequent increments used (J/cm^2). Protective goggles are worn during UVA exposure and sunglasses for 24 hours post oral psoralen ingestion. Topical psoralen (bath PUVA) is less frequently delivered than oral psoralen. Localised PUVA (using psoralen gel) can be used to treat palmo-plantar psoriasis ([Figure 3.7](#)).



(a)



(b)

[Figure 3.7](#) (a, b) Hand and foot PUVA.

Systemic treatment

Systemic therapy for severe psoriasis should ideally be managed by experienced specialist dermatologists. Candidates for systemic therapy include patients with unstable inflamed psoriasis, those with widespread disease ([Figure 3.8](#)) that have failed to respond to topical/phototherapy regimens and concomitant psoriatic arthropathy. The first-line systemic agents in most dermatology centres are acitretin, ciclosporin, and methotrexate. Alternatives include hydroxyurea, azathioprine, and mycophenolate mofetil (MMF). Biological therapies (infliximab, etanercept, ustekinumab, adalimumab, secukinumab, ixekizumab) can be considered if patients have failed to respond to first-line agents or suffered side effects precluding the continued use of at least two systemic agents (UK guidelines).

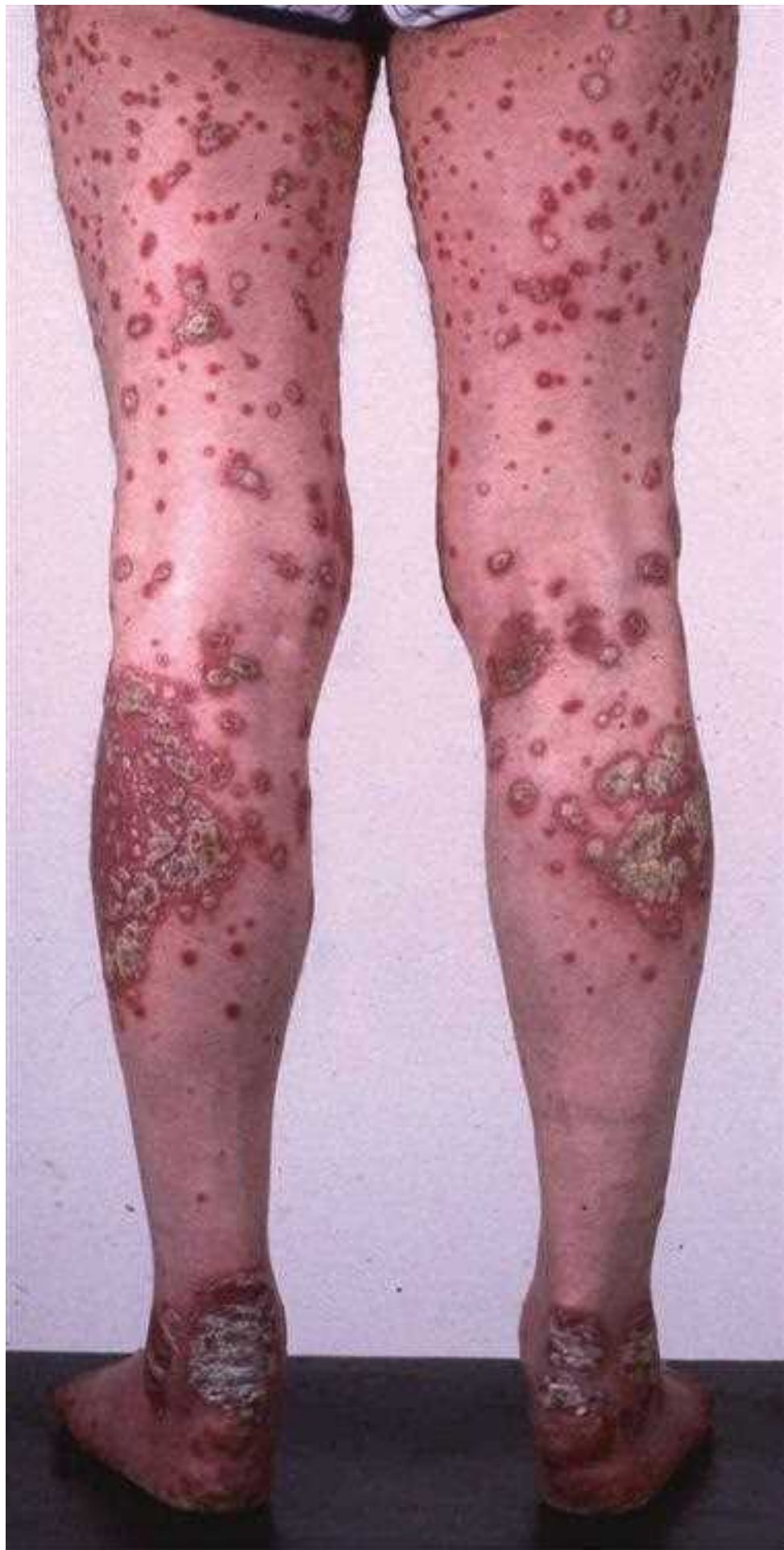

Figure 3.8 Severe psoriasis suitable for systemic therapy.

Methotrexate

Methotrexate may be suitable to treat unstable erythrodermic/pustular psoriasis in the acute setting (but onset of action is slow) and is usually used to treat chronic stable plaque disease and psoriatic arthritis. Methotrexate reduces epidermal cell turnover by the inhibition of folic acid synthesis during the S phase of mitosis. Methotrexate is given once weekly as a tablet or injection. Conventionally, patients are started on low doses that are then increased until the psoriasis is ‘sufficiently controlled’ rather than cleared. Maintenance doses of 7.5–25 mg weekly are usually adequate.

Adverse effects – Methotrexate can be hepatotoxic; therefore, liver function tests must be done prior to and during therapy. Once patients are established on a dose, blood monitoring can be done every 8–12 weeks. Routine liver biopsies for monitoring potential liver fibrosis are no longer indicated. Serum levels of procollagen III (an indirect marker of liver fibrosis) is being superseded by a non-invasive transient elastography (FibroScan®) of the liver which assesses hepatic stiffness and hence the degree of liver fibrosis. It is likely that FibroScan will become more widely available and used first line for liver assessment in patients with psoriasis taking methotrexate

Myelosuppression can occur in patients taking methotrexate, and its onset may be rapid or insidious. Patients should be monitored with regular full blood counts (FBCs). An initial test dose of 5 mg should be given on commencement of methotrexate followed by a FBC one week later to ensure that there is no idiosyncratic marrow suppression. Folic acid supplements should be given (at least 5 mg weekly, taken on a different day to the methotrexate). Methotrexate is excreted in the urine; therefore, the dose must be reduced in renal impairment. Aspirin and sulfonamides diminish plasma binding. Interactions occur with several drugs including barbiturates, phenytoin, oral contraceptives, and colchicine.

Acitretin

Acitretin is a vitamin A derivative that is effective in treating chronic plaque psoriasis with approximately 70% clearance in eight weeks. A synergistic effect has been observed with concomitant PUVA, when patients require less UV exposure to clear their psoriasis.

Adverse effects – most patients experience mucocutaneous symptoms including drying of the mucous membranes, crusting in the nose, itching, thinning of the hair, and erythema of the palms and nail folds. These are usually not severe and settle when treatment stops.

Hepatotoxicity and raised lipid concentrations occur in 20–30% of patients. Liver function tests and cholesterol/triglyceride concentrations should be carefully monitored every three months once patients are established on the treatment. Acitretin can be metabolised to etretinate (half-life 70–100 days) which is teratogenic and therefore women during

reproductive years must use effective contraception during treatment and for three years afterwards.

Ciclosporin A

Ciclosporin A is an immunosuppressant widely used following organ transplantation. It is effective and suitable for the treatment of inflammatory types of psoriasis because of its rapid onset of action. Patients are given 3–5 mg/kg/day in two divided doses either for short courses or continuous use up to two years maximum. The minimum dose required to control the psoriasis should be used.

Adverse effects – include renal impairment and hypertension. Baseline blood tests should include serum creatinine, urea, electrolytes and glomerular filtration rate, and urine analysis. Monitoring of bloods/urine should then be undertaken every 4–12 weeks. Hypertension may be managed by reducing the dose of ciclosporin or by giving the patient nifedipine. Transient nausea, headaches, gum hypertrophy, and hypertrichosis may also be observed. Hepatic metabolism of ciclosporin (via cytochrome P450) can be inhibited or induced by many different drugs. Medications inhibiting ciclosporin metabolism include erythromycin, itraconazole, verapamil, and diltiazem. Medications increasing ciclosporin metabolism include rifampicin, phenytoin, and carbamazepine.

Mycophenolate mofetil (MMF)

MMF is usually used as a second line systemic agent for treating psoriasis and psoriatic arthritis. It is an immunosuppressant medication that selectively inhibits activated lymphocytes. Studies have shown that about two-thirds of patients taking MMF (2–3 g/day for 12 weeks) have a significant reduction (50%) in their PASI score by 12 weeks.

Adverse effects include gastrointestinal upset and myelosuppression, haematological malignancies, and opportunistic infections. Blood testing for FBC should be undertaken every one to two months for the first year, then every three to four months once established.

Biological therapy

Biological therapy refers to substances originally derived from living organisms such as proteins or antibodies that are designed to block particular molecular steps in the biological pathway that leads to psoriasis. Our greater understanding of the pathophysiology of psoriasis has been exploited to direct treatments against specific cytokine/cell pathways dysregulated in disease. Psoriasis is a T-cell mediated disease and cytokines such as tumour necrosis factor alpha (TNF- α) and interferon gamma (INF- γ) play a role. Biological therapies are currently directed against T-cells or specific inflammatory mediators such as TNF.

The main biological agents currently used to treat severe psoriasis are infliximab, etanercept and adalimumab, ixekizumab, secukinumab, and ustekinumab. Clinical guidelines (NICE –

National Institute of Clinical Excellence (UK)) exist in most countries to direct the usage of biological agents in patients with psoriasis. These novel agents are expensive and can result in chronic immunosuppression, leading to fatal infections or tumours, and therefore their usage should be managed in specialist units by experienced practitioners. Biological agents are usually administered S/C or IV by injection/infusions, with frequencies varying from twice weekly to once per month, in either continuous or intermittent regimes. Biological treatments are delivered either at home by the patients themselves/visiting practitioner or are delivered in IV suites based in the community/local hospitals.

NICE guidelines (UK) for the use of biological agents for psoriasis indicate that biological therapies can only be considered in patients with a PASI score of greater than 10 (or significant localised disease at high-impact sites – hands/genitals/scalp) *and* a DLQI score >10, *plus* the patient has failed to respond to two conventional systemic agents/phototherapy (contraindicated, non-response or stopped due to unacceptable side effects) or have severe/unstable/life-threatening disease. Biological therapy can also be very useful in treating acute unstable pustulating psoriasis ([Figure 3.9](#)).

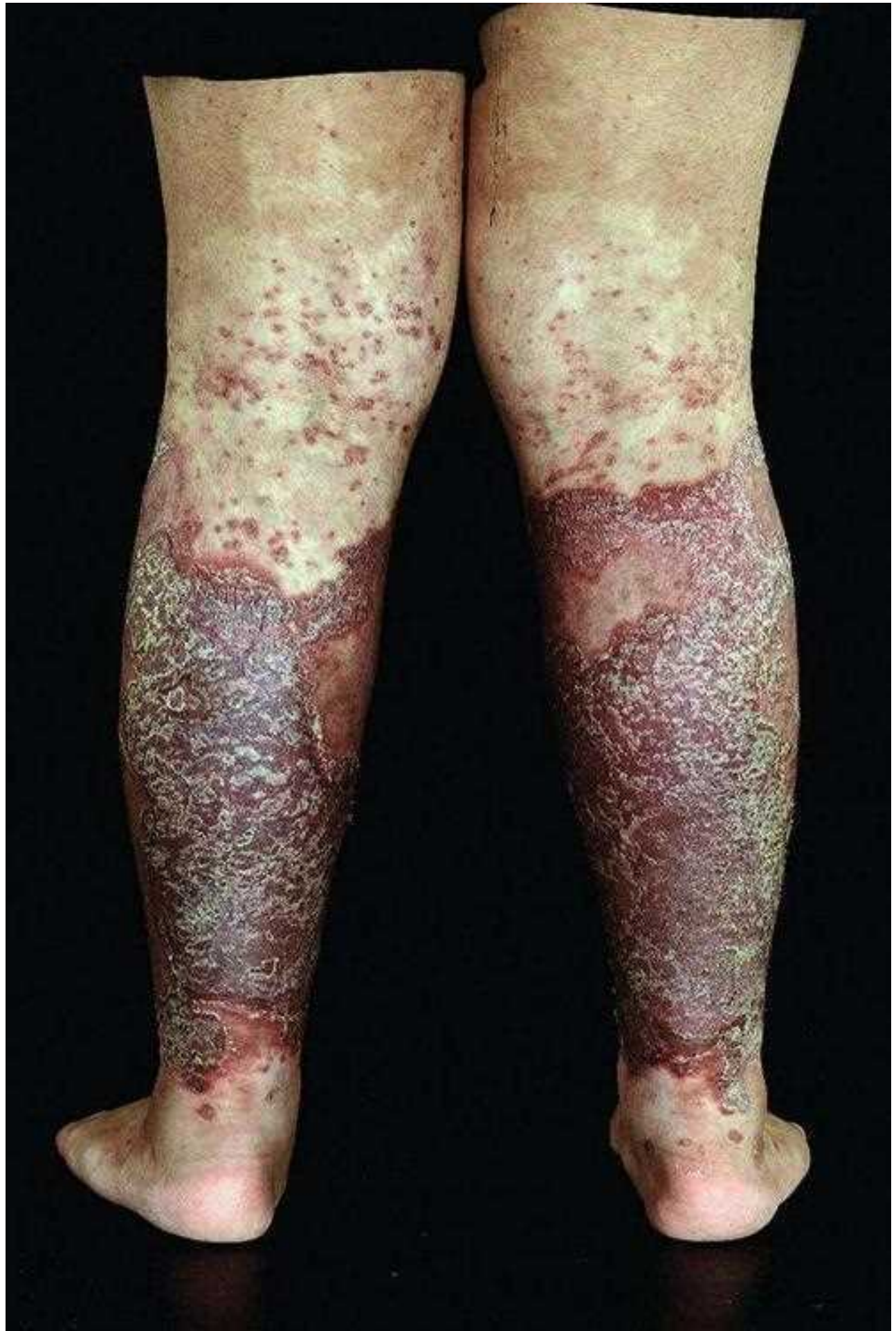

Figure 3.9 Severe unstable pustulating psoriasis suitable for treatment with biological therapy.

NICE guidelines (UK) for use of biological agents for psoriatic arthritis indicate that they can be used in severe active disease in patients with at least three tender joints and three swollen joints who have not responded sufficiently to two other disease-modifying drugs.

Many patients starting biological therapy have experienced significant, extensive and recalcitrant psoriasis/psoriatic arthritis for many years prior to their disease being controlled with a biological agent, and consequently they find disease relapse on stopping biologics more unacceptable than ever, as their expectation has now shifted to virtually clear skin and no joint pains. Many studies now are aiming for PASI 90/100 as the criteria for 'disease response' so both patient and physician expectations of biological agents are increasing.

Etanercept

Etanercept (Enbrel®) is a genetically engineered anti-tumour necrosis factor receptor (anti-sTNF) biological agent. Dosing is twice weekly with either 25 or 50 mg given by S/C injection. The higher dose seems to be more effective than lower doses, especially in patients who weigh more than 70 kg. Onset of action is relatively slow, with clinical improvement being observed in the majority of patients between four and eight weeks. Patients may initially have courses of treatment lasting 12 weeks; at that stage an assessment of efficacy should be made (as judged by a reduction in the patient's PASI and DLQI scores); however, continuous therapy may ultimately be needed due to significant disease relapse within three months of stopping treatment. The cost of twice weekly 25 mg or once weekly 50 mg etanercept/patient/year is about £7500 (2017). However, with the introduction of 'Biosimilars' competition is starting to drive prices down.

Adverse effects associated with etanercept include an increased risk of infections, particularly latent TB, and hepatitis B and septicaemia, gastrointestinal symptoms, hypersensitivity and injection site reactions, blood disorders, and a lupus-like antibody-driven syndrome.

Infliximab

Infliximab (Remicade®) is an anti-TNF human-murine monoclonal antibody for the treatment of severe psoriasis/psoriatic arthritis. Infliximab has a rapid onset of action – usually within two weeks in the majority of patients. Doses are calculated according to the patient's weight, 5 mg/kg given by an intravenous infusion at weeks 0, 2, 6, and then every 8 weeks. Nearly 80% of patients experience significant improvement in the extent and severity of their disease (reduced PASI and DLQI scores) by 10 weeks, which is usually maintained for at least 6 months. There is evidence from studies (data up to one year) that continuous therapy is superior to intermittent treatment. Almost 20% of patients develop antibodies to infliximab (possibly due to the presence of murine proteins), which is clinically associated

with reduced efficacy. However, the risk of antibody development seems to be reduced when infliximab is given continuously and when it is given with methotrexate in patients with psoriatic arthritis. The total cost of infliximab maintenance treatment for 1 year/patient in the United Kingdom is about £12 500 (2017).

Adverse effects – as above for etanercept; however, in addition, chest pain, dyspnoea, arrhythmias, demyelinating disorders, sleep disturbance, skin pigmentation, gastrointestinal haemorrhage, seizures, and transverse myelitis have been reported, among others.

Adalimumab

Adalimumab (Humira®) is a human anti-TNF monoclonal antibody used to treat severe psoriasis and psoriatic arthritis. It has a fast onset of activity, usually within two weeks and is highly effective in 60–70% of patients. The majority of patients receive 40 mg of adalimumab fortnightly by S/C injection (following a loading dose of 80 mg at week 0). Efficacy is assessed at 16 weeks before deciding whether to continue with the treatment; however, a small cohort of patients with slow/partial response may receive weekly injections, rather than discontinuation. There is some evidence to suggest that continuous therapy is more effective than intermittent therapy. Anti-adalimumab antibodies develop in about 8% of patients, which correlates with reduced efficacy. Some patients with psoriatic arthritis take methotrexate plus adalimumab, which seems to be more effective than adalimumab alone. The cost of fortnightly adalimumab/patient/year was about £9300 in the United Kingdom (2017) and £3000 in 2019 (since the introduction of biosimilars).

Adverse effects – as for etanercept, plus stomatitis, cough, paraesthesia, rash/pruritus, arrhythmias, chest pain, flushing, flu-like symptoms, sleep disturbance, electrolyte disturbances, alopecia, and demyelinating disorders among others.

Ustekinumab

Ustekinumab (Stelara®) is a human monoclonal antibody that targets the p40 subunit of interleukin-12 (IL-12) and IL-23, which prevents them from binding to T-cells and therefore impairs the inflammatory cascade in psoriasis. Because Ustekinumab has only been in clinical use for a few years there is less long-term safety and efficacy data than the other biologic agents. The recommended dose of Ustekinumab is 45 mg (patient weighs < 100 kg) or 90 mg (patient weighs > 100 kg) by S/C injection at weeks 0, 4, and then every 12 weeks. Efficacy should be assessed at 16 weeks and only continued in those who have achieved a 75% reduction in their PASI score or 50% reduction in PASI plus 5 point reduction in DLQI scores. The cost of 45 or 90 mg for any individual patient is the same in the United Kingdom as supplied by the manufacturer. Nonetheless, the total cost of Ustekinumab/patient/year in the United Kingdom is around £9300 (based on 4.3 injections/year in 2017).

Adverse effects – as for etanercept, plus allergic reactions (urticarial, angioedema, difficulty breathing), infections, mouth ulcers, haematuria, gastrointestinal symptoms, cough, chest

pains, seizures, and visual disturbance.

Ixekizumab

Ixekizumab targets interleukin-17A, a cytokine that promotes keratinocyte proliferation and activation. It is licensed for the treatment of moderate/severe psoriasis (PASI >10, DLQI >10) that has not responded to conventional treatments. The first dose is usually given as 160 mg, (two 80 mg pre-filled 'Pen-syringes'), then 80 mg every other week, at weeks 2, 4, 6, 8, 10, and 12. Treatment efficacy is usually assessed at 12 weeks and if deemed effective (>PASI 75 improvement) then patients usually have one 80 mg injection every four weeks. 78–90% of patients treated with the monoclonal antibody either every four weeks or every two weeks achieved at least a 75% reduction in PASI score at 12 weeks. Adverse effect profile is similar to the other biologics in terms of immunosuppression. Ixekizumab is known to exacerbate inflammatory bowel disease, may cause angioedema and antibodies can develop to the drug. The white cell and the platelet counts need careful monitoring. The annual cost of treatment is estimated to be £17 500.

Secukinumab

Secukinumab is a recombinant human monoclonal antibody that selectively binds to cytokine interleukin-17A and inhibits the release of pro-inflammatory cytokines and chemokines. It is licensed to treat moderate to severe psoriasis (PASI >10, DLQI >10). The usual dose is secukinumab 300 mg (two 150 mg injections) given by subcutaneous injection at weeks 0, 1, 2, 3, and 4, then once/month maintenance. The most common adverse events in studies were upper respiratory tract infections or rhinitis and reactivation of herpes simplex virus. Annual cost for the first year of treatment would be around £30 000, then for maintenance around £25 000/year (2017). Costs may vary according to locally negotiated procurement discounts.

Apremilast

This is a relatively new oral medication for treating moderate to severe psoriasis in patients who have failed to respond to conventional systemic treatment such as methotrexate/ciclosporin and where appropriate acitretin. Apremilast inhibits phosphodiesterase 4 (PDE4) which down-regulates the expression of cytokines and mediators associated with psoriasis (including TNF and interleukin -23). Patients initially start with 10 mg daily and titrate up to 30 mg BD over five days, they then stay on this dose. Cost of the medication is about £6500/year. Studies show that just over 50% of patients achieve a PASI 50 by four months. Main side effects include diarrhoea, nausea, and headache.

Further reading

www.bad.org.uk/healthcare/guidelines London, UK.

www.nice.org.uk/guidance/cg153/chapter/1-guidance#topical-therapy

<http://sites.cardiff.ac.uk/dermatology/quality-of-life/dermatology-quality-of-life-index-dlqi>

Thomas, J. (2016). *Textbook of Psoriasis*. Jaypee Brothers Medical Publishers.

Sterry, W., Sabat, R., and Phillip, S. (2014). *Psoriasis: Diagnosis and Management*. Wiley-Blackwell.

CHAPTER 4

Eczema (Dermatitis)

Rachael Morris-Jones

Guy's and St Thomas' NHS Foundation Trust, London, UK

OVERVIEW

- Eczema describes a pattern of inflammation in the skin.
- Eczema includes atopic dermatitis, contact dermatitis, irritant dermatitis, varicose, pompholyx, and discoid eczema.
- Atopic dermatitis affects about 5–25% of infants and can lead to considerable morbidity for the child and the family.
- Management relies on regular applications of emollients and topical steroids.

Eczema and dermatitis are terms used to describe the characteristic clinical appearance of inflamed, dry, occasionally scaly, and vesicular skin rashes associated with divergent underlying causes. The word *eczema* is derived from Greek, meaning ‘to boil over’, which aptly describes the microscopic blisters occurring in the epidermis at the cellular level. *Dermatitis*, as the term suggests, implies inflammation of the skin which relates to the underlying pathophysiology. The terms *eczema* and *dermatitis* encompass a wide variety of skin conditions usually classified by their characteristic distribution, morphology, and any trigger factors involved.

Clinical features

Eczema is an inflammatory condition that may be acute or chronic. Acute eruptions are characterised by erythema, vesicular/bullous lesions and exudates. Secondary bacterial infection (staphylococcus and streptococcus) heralded by golden crusting may exacerbate acute eczema. Chronicity of inflammation leads to increased scaling, xerosis (dryness) and lichenification (thickening of the skin where surface markings become more prominent). Eczema is characteristically itchy and subsequent scratching may also modify the clinical appearance, leading to excoriation marks, loss of skin surface, secondary infection, exudates, and ultimately marked lichenification ([Figure 4.1.](#)). Inflammation in the skin can result in disruption of skin pigmentation causing post-inflammatory hyper/hypopigmentation. Patients often fear that loss of pigment is due to the application of topical steroids but in the majority of cases it is due to chronic inflammation.

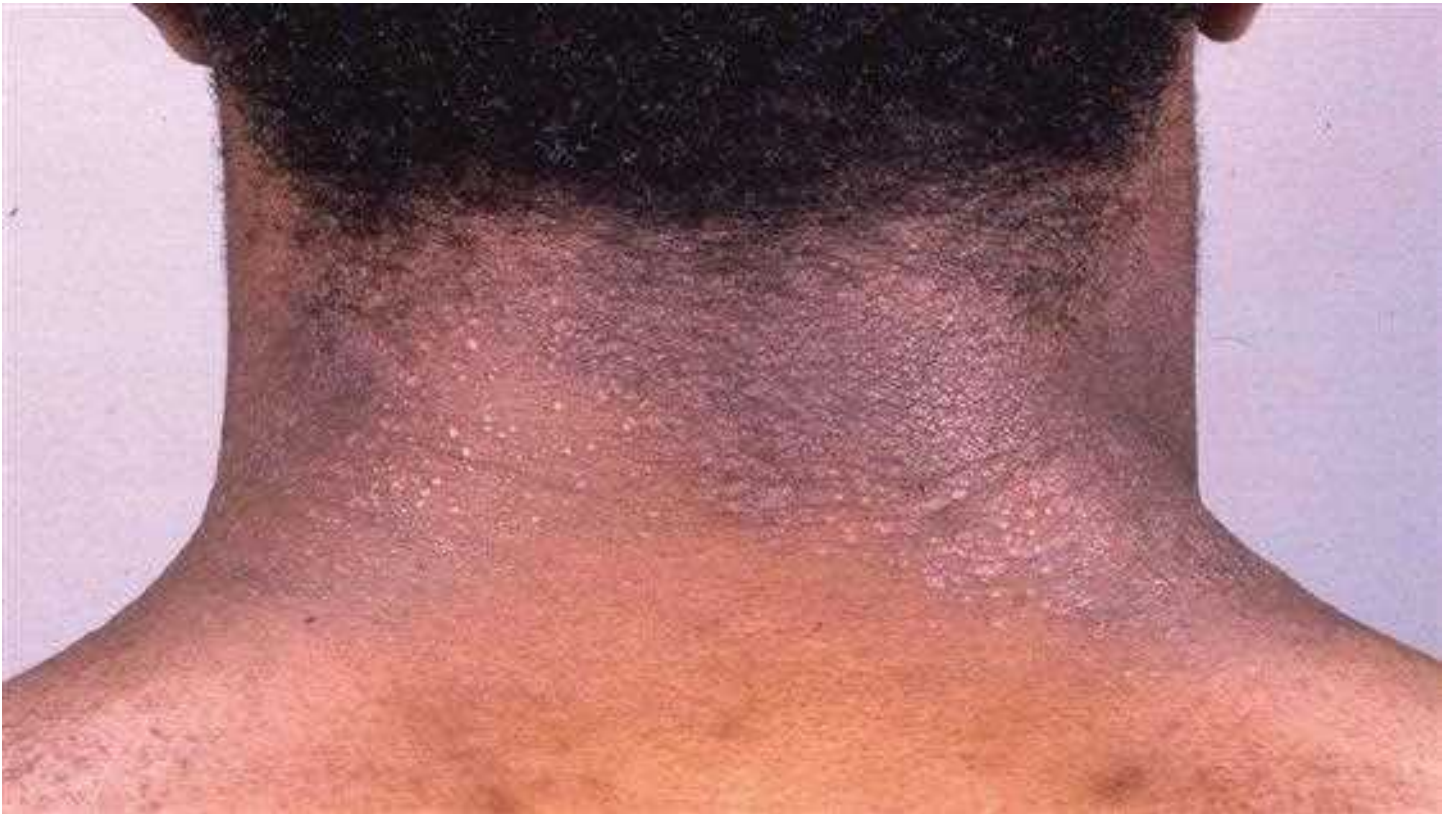

Figure 4.1 Chronic atopic dermatitis.

Pathophysiology

The underlying driver for atopic dermatitis (AD) is genetic predisposition (personal/family history of atopy). In those with AD there is an imbalance of T-helper lymphocytes, leading to increasing numbers of Th-2 cells compared to Th-1 and Th-17. The abnormal Th-2 cells interact with Langerhans cells, causing raised levels of interleukins/immunoglobulin E (IgE) and a reduction in gamma interferon with resultant upregulation of pro-inflammatory cells. In addition to this, immune dysregulation gene defects have been identified in large cohorts of patients with AD including filaggrin gene defects which lead to impaired skin barrier function. This impaired barrier leads to increased transepidermal water loss and increased risk of antigens and infective organisms entering the skin.

Pathology

The clinical changes associated with dermatitis are reflected accurately at the cellular level. There is oedema in the epidermis, leading to spongiosis (separation of keratinocytes) and vesicle formation. The epidermis is hyperkeratotic (thickened) with dilated blood vessels and an inflammatory (eosinophil) cell infiltrate in the dermis ([Figure 4.2](#)).

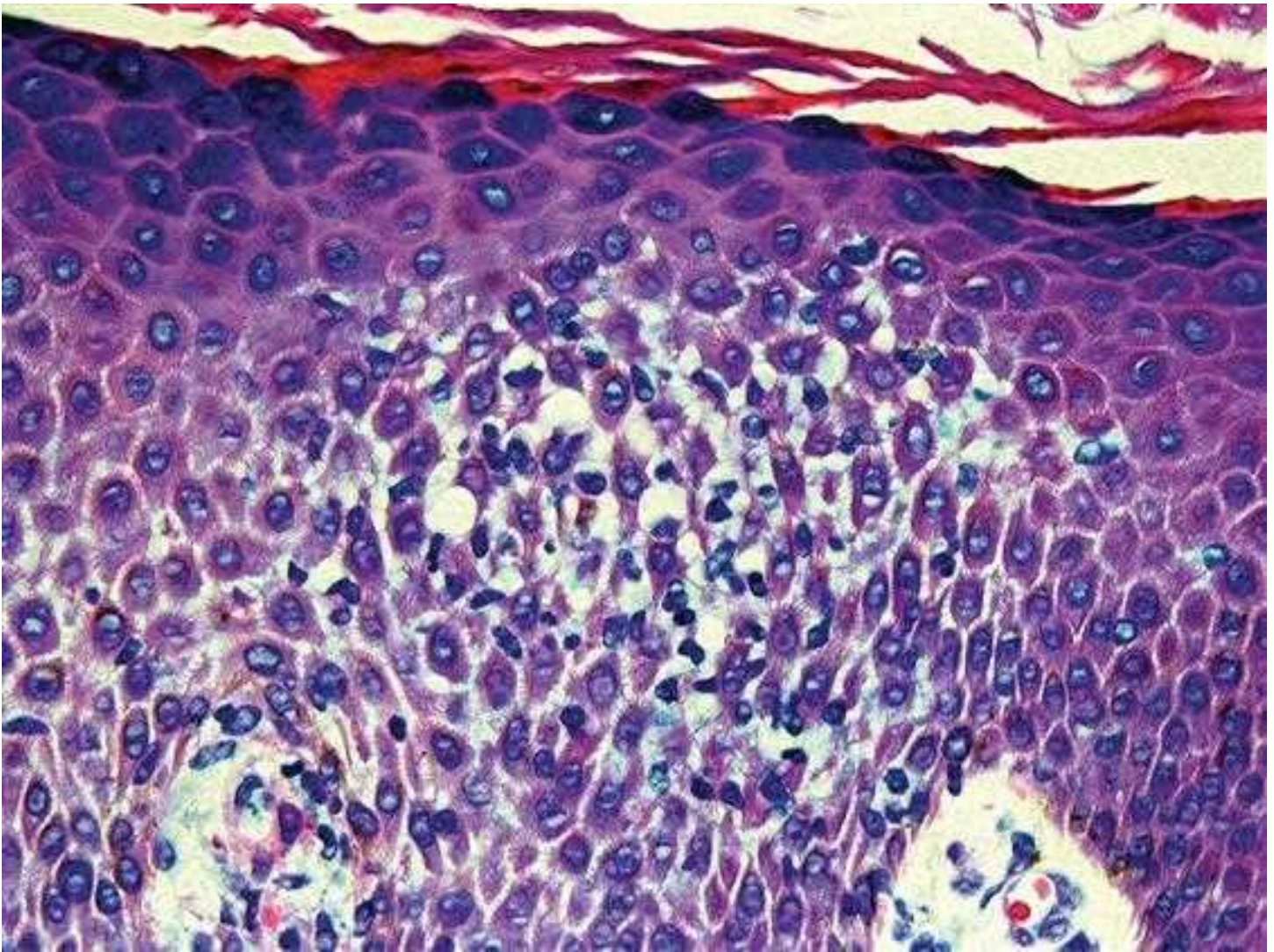


Figure 4.2 Histology of eczema.

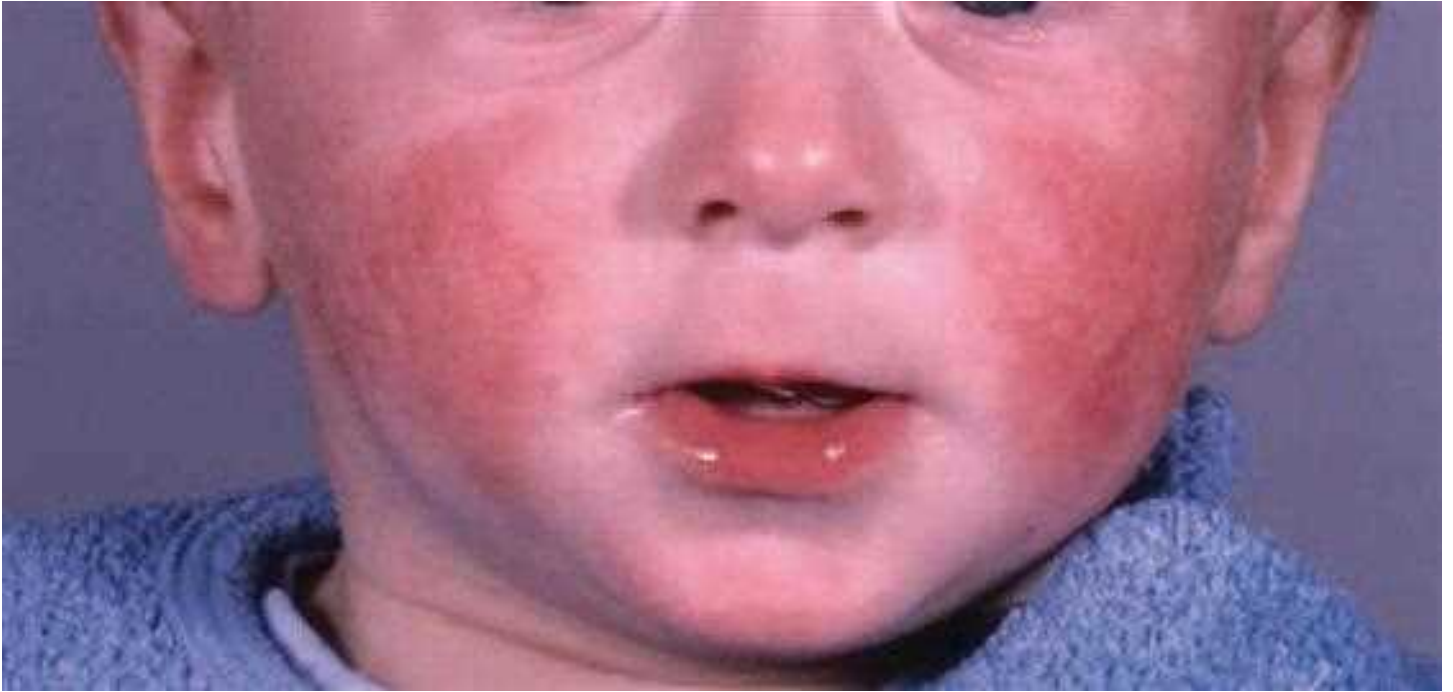Types of eczema

Eczema is classified broadly into endogenous (constitutional) and exogenous (induced by an external factor).

Endogenous eczema

AD typically presents in infancy or early childhood, initially with facial ([Figure 4.3](#)) and subsequently flexural limb involvement ([Figures 4.4](#) and [4.5](#)). AD is intensely itchy, and even young babies become highly proficient at scratching, which can lead to disrupted sleep (both patient and family), poor feeding, and irritability. The usual pattern is one of flare-ups followed by remissions, exacerbations being associated with inter-current infections, teething, and food allergies. In severely affected babies failure to thrive may result. In older children or adults, AD may become chronic and widespread and is frequently exacerbated by stress. AD is common, affecting 3% of infants; nonetheless, 90% of the patients spontaneously remit by puberty. Patients likely to suffer from chronic AD in adult life are

those who have a strong family history of eczema, present at a very young age with extensive disease and have associated asthma/multiple food allergies ([Figure 4.6](#)).



[Figure 4.3](#) Facial atopic dermatitis.

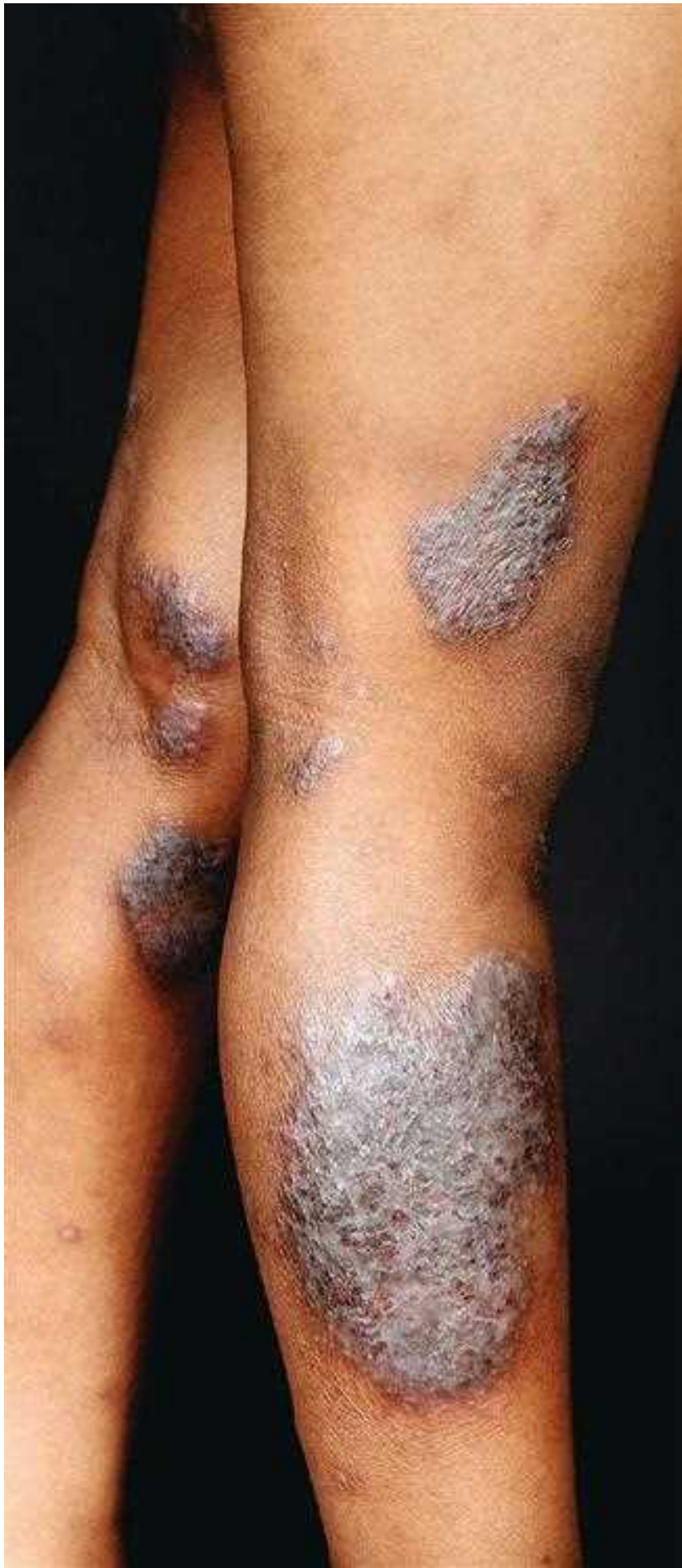

Figure 4.4 Chronic lichenified eczema on the legs.

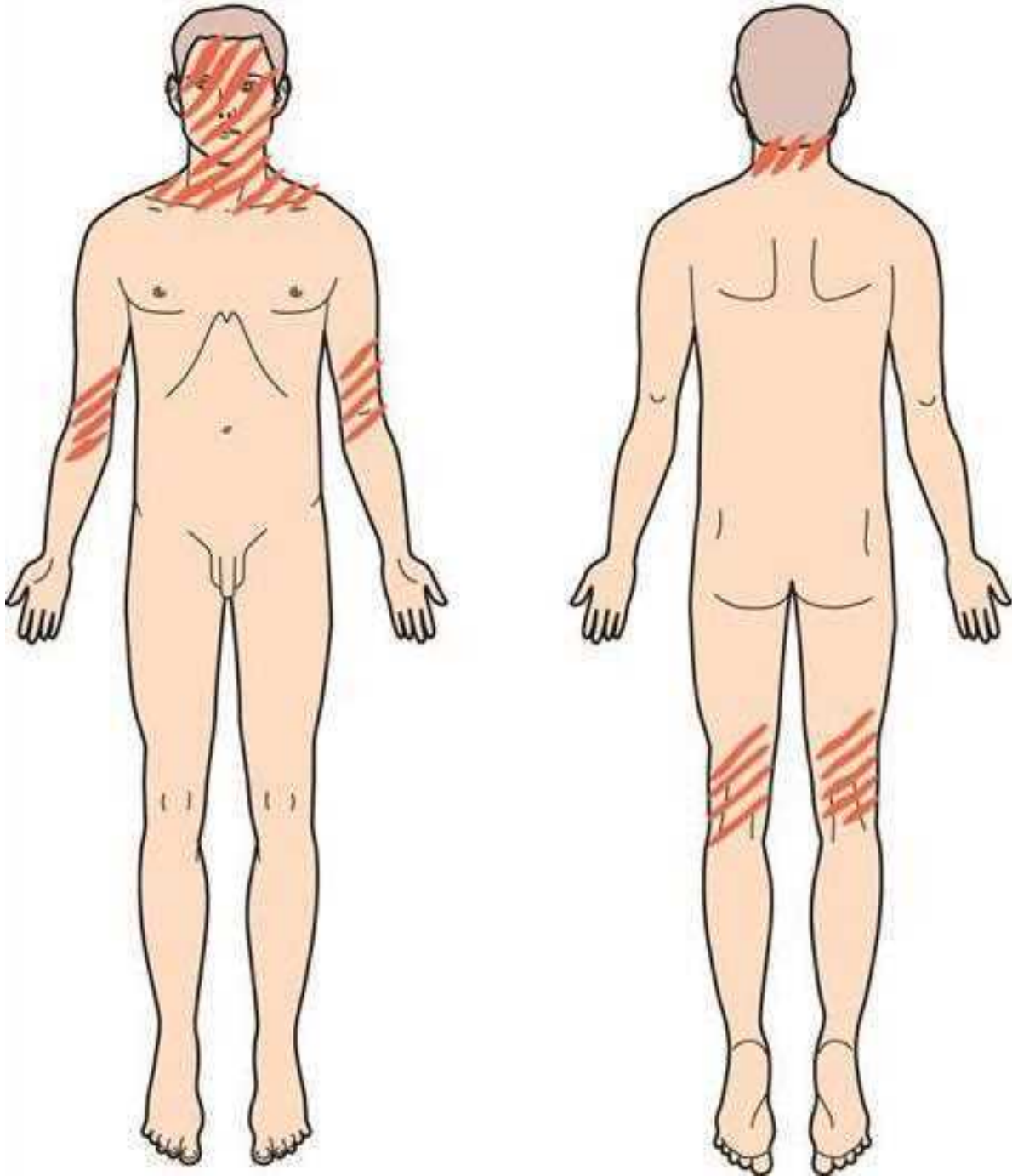


Figure 4.5 Distribution of atopic dermatitis.

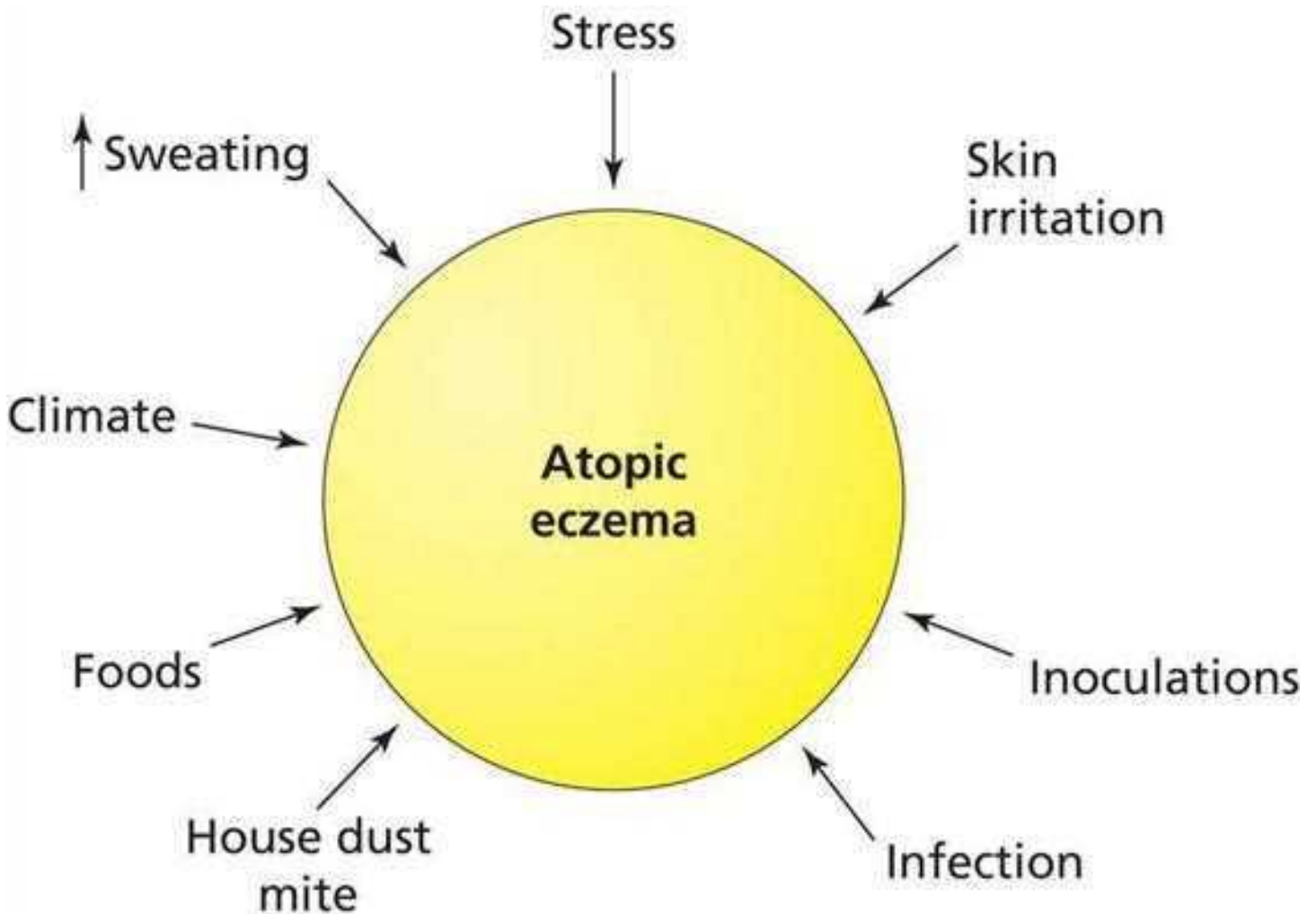


Figure 4.6 Factors leading to the exacerbation of atopic dermatitis.

Food allergy in atopic dermatitis

IgE mediated food allergy occurs between 30% and 60% of patients with AD. If the onset of the AD occurs before the age of three months then there is a higher risk of cow's milk/egg/peanut allergy. A raised total IgE is a known risk factor for AD in children and persistent AD in adults. Evidence of sensitisation to an individual allergen does not necessarily mean it is clinically relevant. Food allergy in the context of AD can lead to urticaria or exacerbation of the eczema. The severity of the AD does seem to directly correlate with the likelihood of developing food allergy. Studies show that 1–3% of children with mild AD have food-induced AD; this increases to 5–10% with moderate AD, and 20–33% with severe AD. In addition, it is estimated that 10–20% of those with AD will have at least one episode of food-induced urticaria/anaphylaxis compared with 1–3% of the general population. Food allergy leading to an exacerbation of AD usually occurs within hours/few days in IgE mediated food allergy but may take several days in non-IgE mediated food allergy, this may mean it is difficult to identify the culprit food.

There is evidence that children with mutation in their filaggrin gene have an impaired barrier function and that this leaves them more susceptible to developing peanut allergy due to contact with peanut protein dust in the home environment, e.g. transcutaneous sensitisation.

Consequently, some allergists are advocating early introduction of peanut in the diet of babies with AD, to ensure that first exposures to peanut protein are via the gut rather than via the skin. Weaning babies with smooth peanut butter three times per week from the age of five months is being advocated in some clinics to help prevent peanut allergy developing. The most common fatal food reactions are caused by peanut and tree nuts (usually through accidental exposure in an individual known to be allergic to the ingested allergen).

Eczema herpeticum is herpes simplex viral (HSV) infection superimposed onto eczema skin in patients with AD. It usually affects the face/neck. Children may have had contact with an adult who has herpes labialis (cold sore), i.e. primary HSV infection, or may occur from reactivation of their own HSV. Clinically, there are multiple small 'punched-out' looking ulcers, especially around the neck and eyes ([Figure 4.7](#)). Eczema herpeticum is a serious complication of eczema that may be life/sight threatening, and therefore early intervention with systemic aciclovir is essential under the guidance of a dermatology specialist.

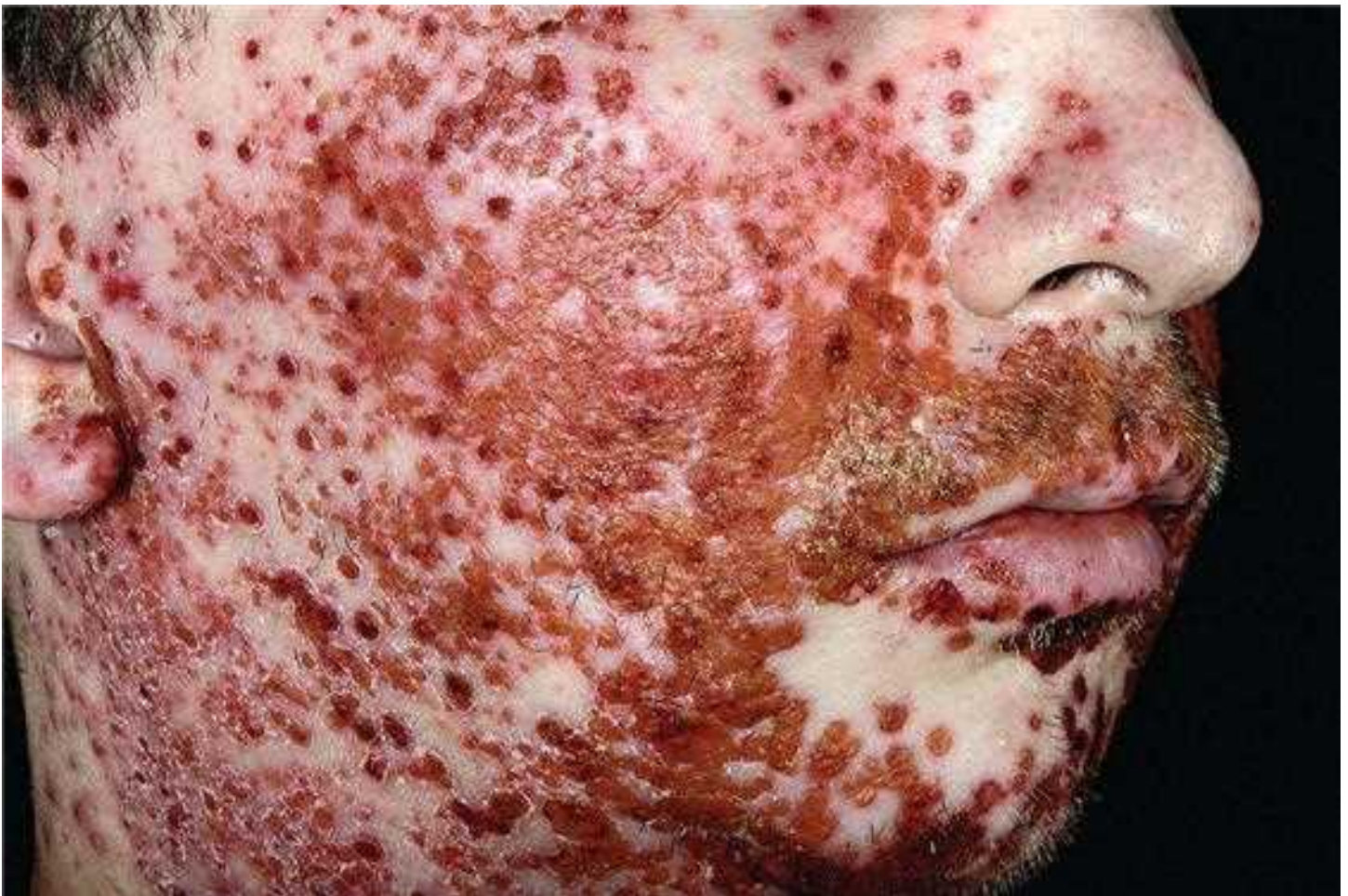

Figure 4.7 Eczema herpeticum.

Pityriasis alba is a variant of atopic eczema in which pale patches of hypopigmentation develop on the face of children. Juvenile plantar dermatosis is another variant of atopic eczema in which there is dry cracked skin on the forefoot in children ([Figure 4.8](#)).

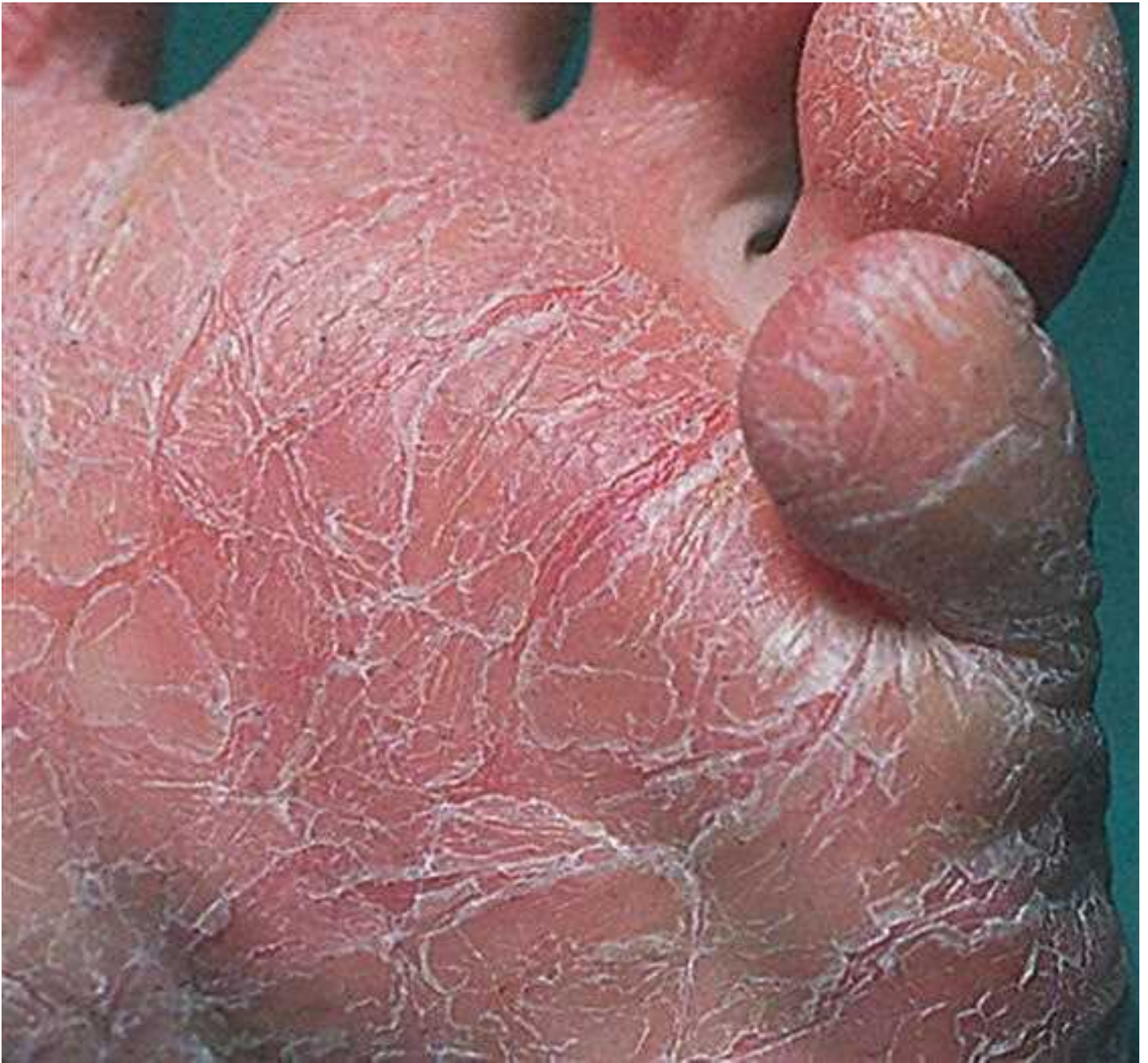

Figure 4.8 Plantar dermatitis.

Lichen simplex is a localised area of lichenification produced by rubbing ([Figure 4.9](#)).

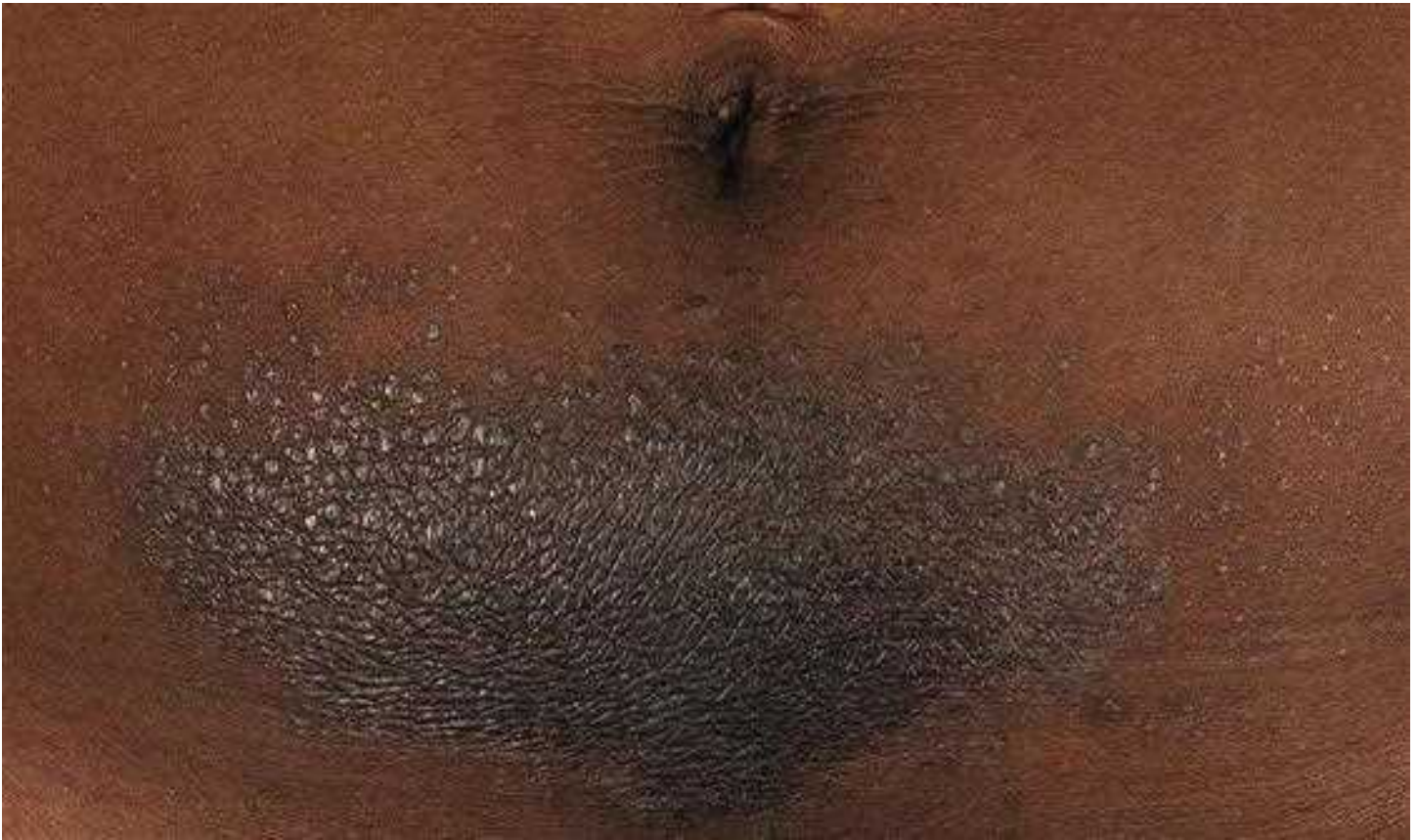

Figure 4.9 Lichen simplex.

Asteatotic eczema occurs in older people with dry skin, particularly on the lower legs. The pattern on the skin resembles a dry river-bed or 'crazy paving' ([Figure 4.10](#)).

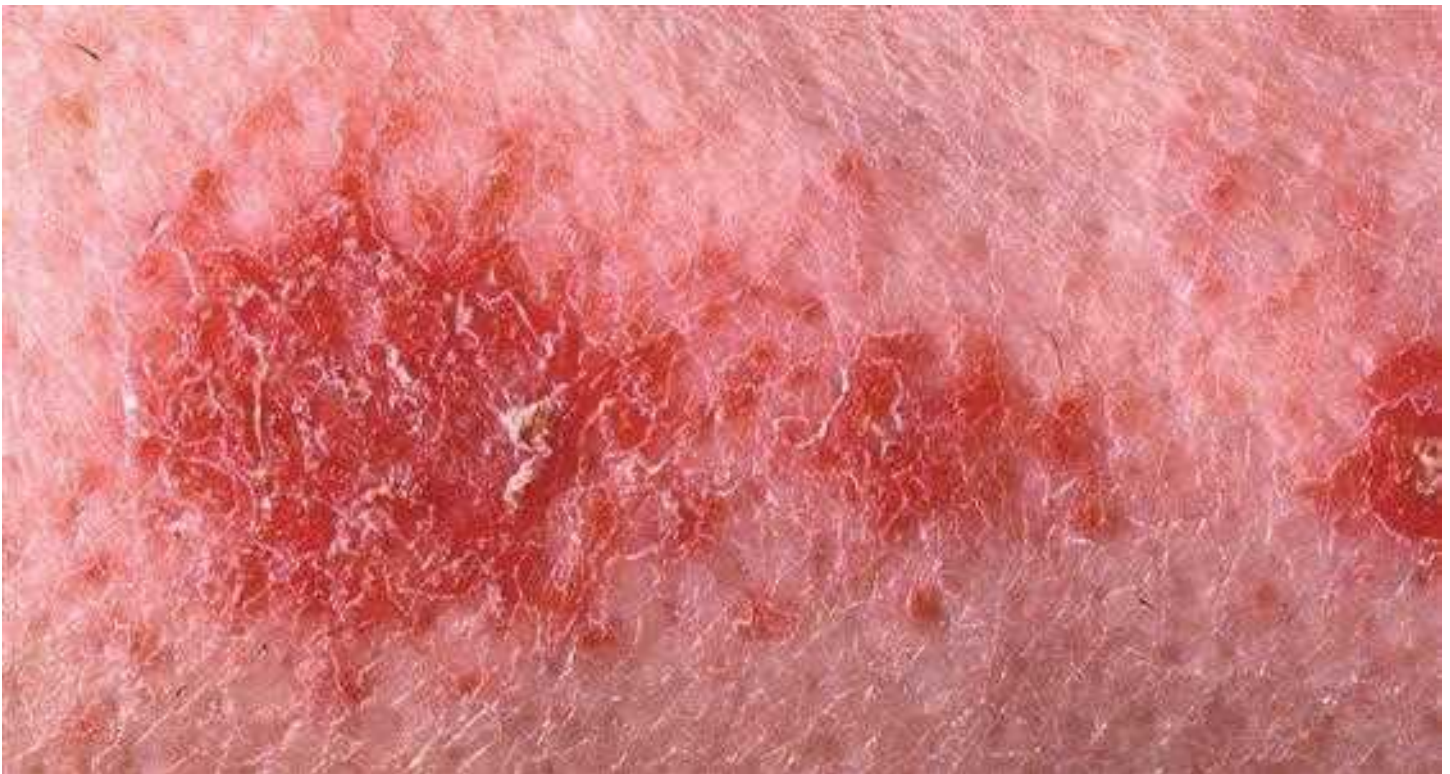

Figure 4.10 Asteatotic eczema.

Discoid eczema appears as intensely pruritic coin-shaped lesions most commonly on the limbs ([Figure 4.11](#)). Lesions may be vesicular and are frequently colonised by *Staphylococcus aureus*. Males are more frequently affected than females.

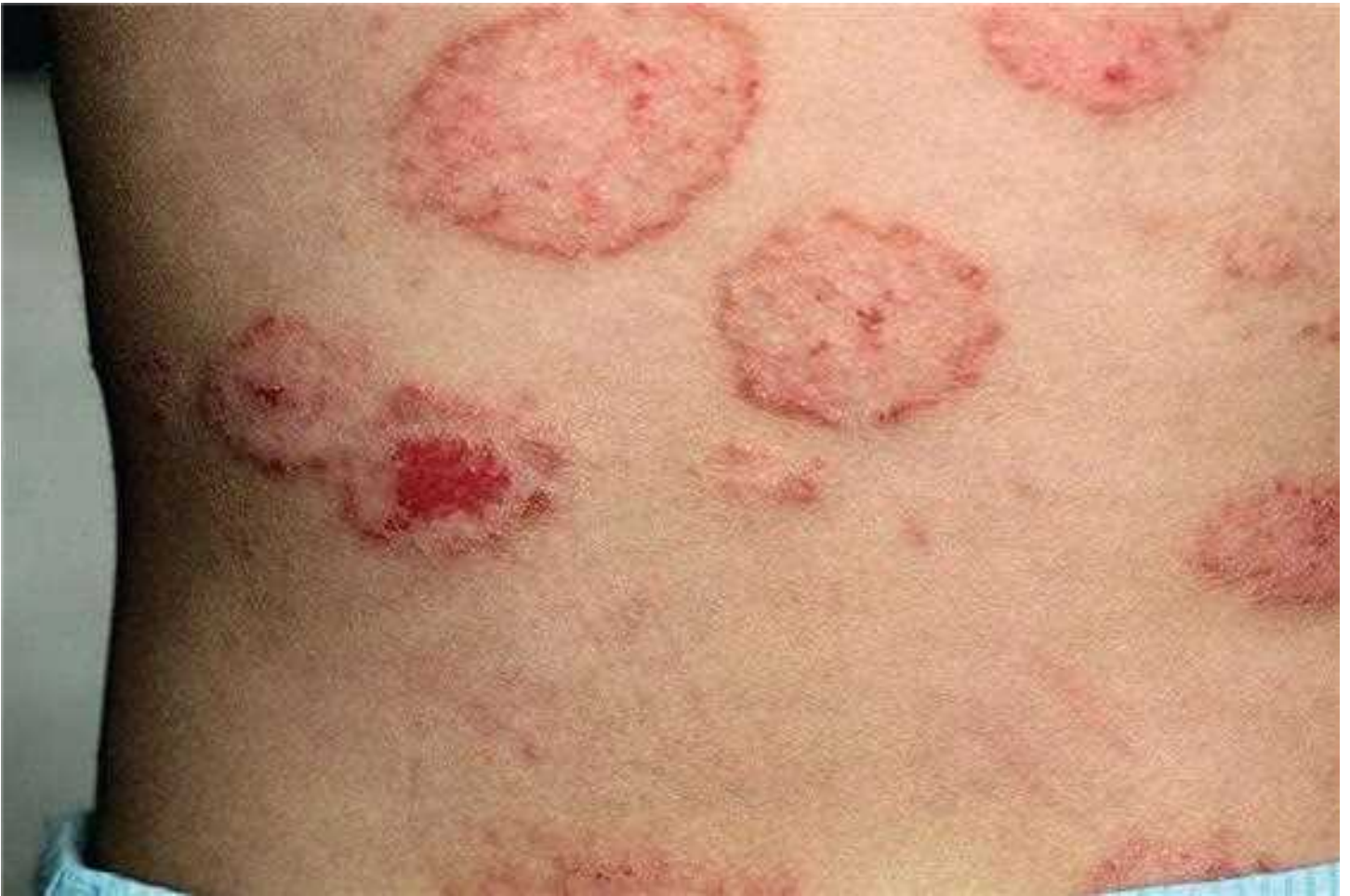

Figure 4.11 Discoid eczema.

Pompholyx eczema is itching vesicles on the fingers, palms, and soles. The blisters are small, firm, intensely itchy, and occasionally painful ([Figure 4.12](#)). The condition is more common in patients with nickel allergy.

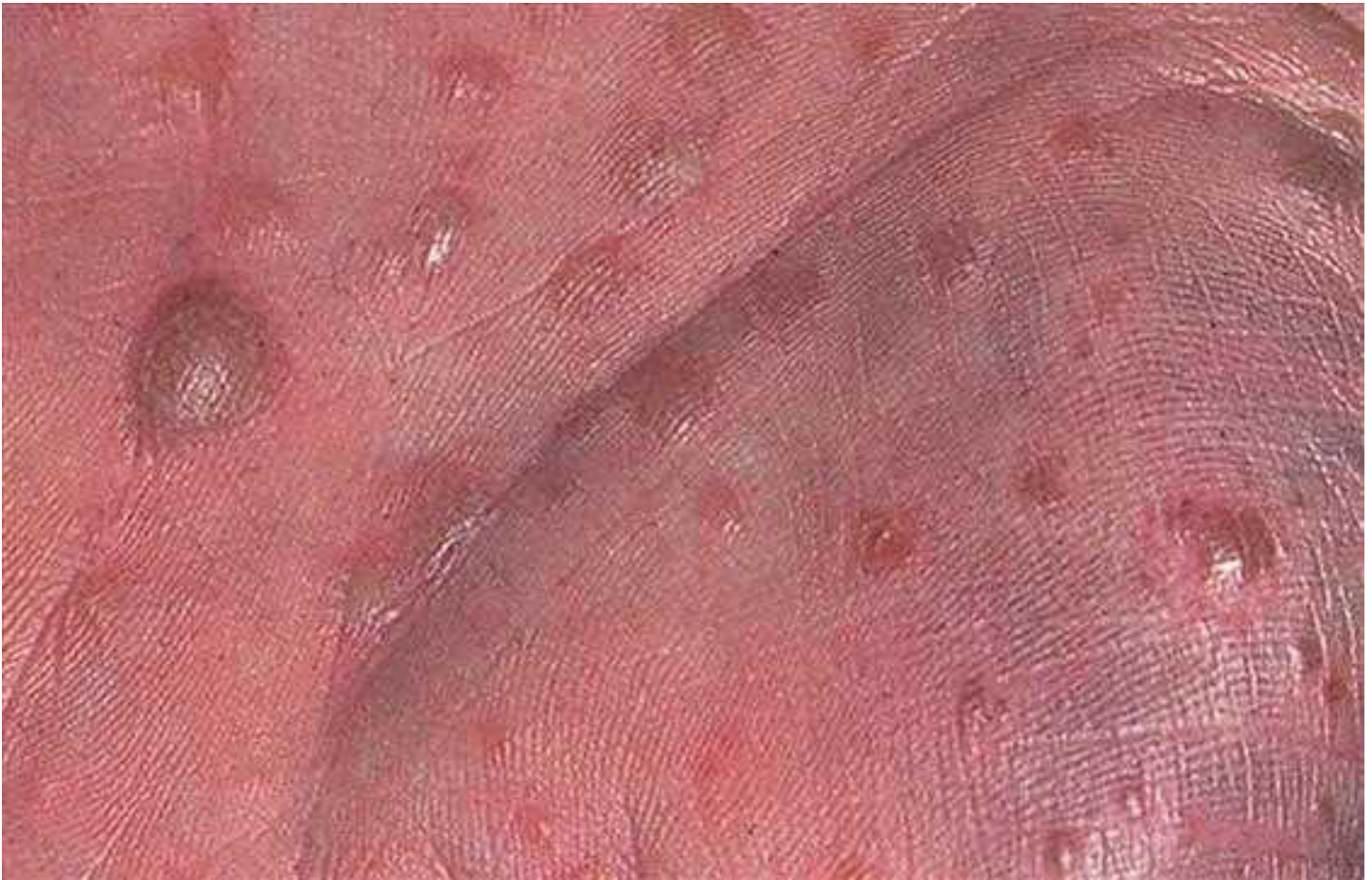

Figure 4.12 Pompholyx eczema.

Venous (stasis) eczema is a common insidious dermatitis that occurs on the lower legs of patients with venous insufficiency. These patients have back flow of blood from the deep to the superficial veins, leading to venous hypertension. In the early stages, there is brown haemosiderin pigmentation of the skin, especially on the medial ankle, but as the disease progresses skin changes can extend up to the knee ([Figure 4.13](#)). Patients typically have peripheral oedema, and ulceration may result. The mainstay of management is compression (see [Chapter 11](#)).

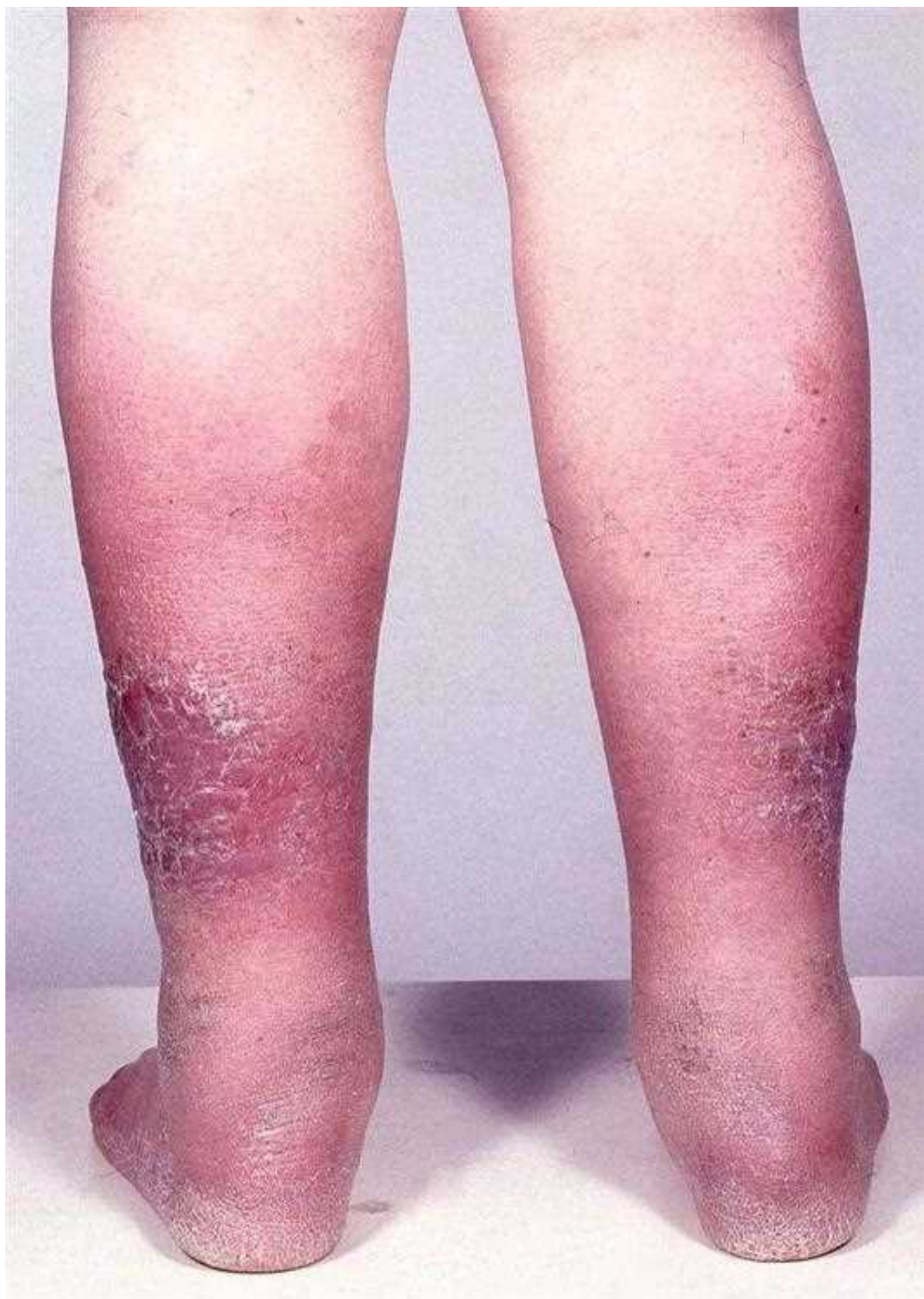

Figure 4.13 Varicose eczema.

Investigations of eczema

Skin swabs should be taken from the skin if secondary bacterial ([Figure 4.14](#)) or viral infection is suspected. The swab should be moistened in the transport medium before being rolled thoroughly on the affected skin, coating all sides of the swab to ensure that an adequate sample is sent to the laboratory. A significant growth of bacteria reported with its sensitivity and resistance pattern can be useful in guiding antibiotic usage. Nasal swabs should be performed in older children and adults with persistent infected facial eczema to check for nasal *Staphylococcus* carriage. If a secondary fungal infection is suspected then scrapings or brushings can be taken for mycological analysis.

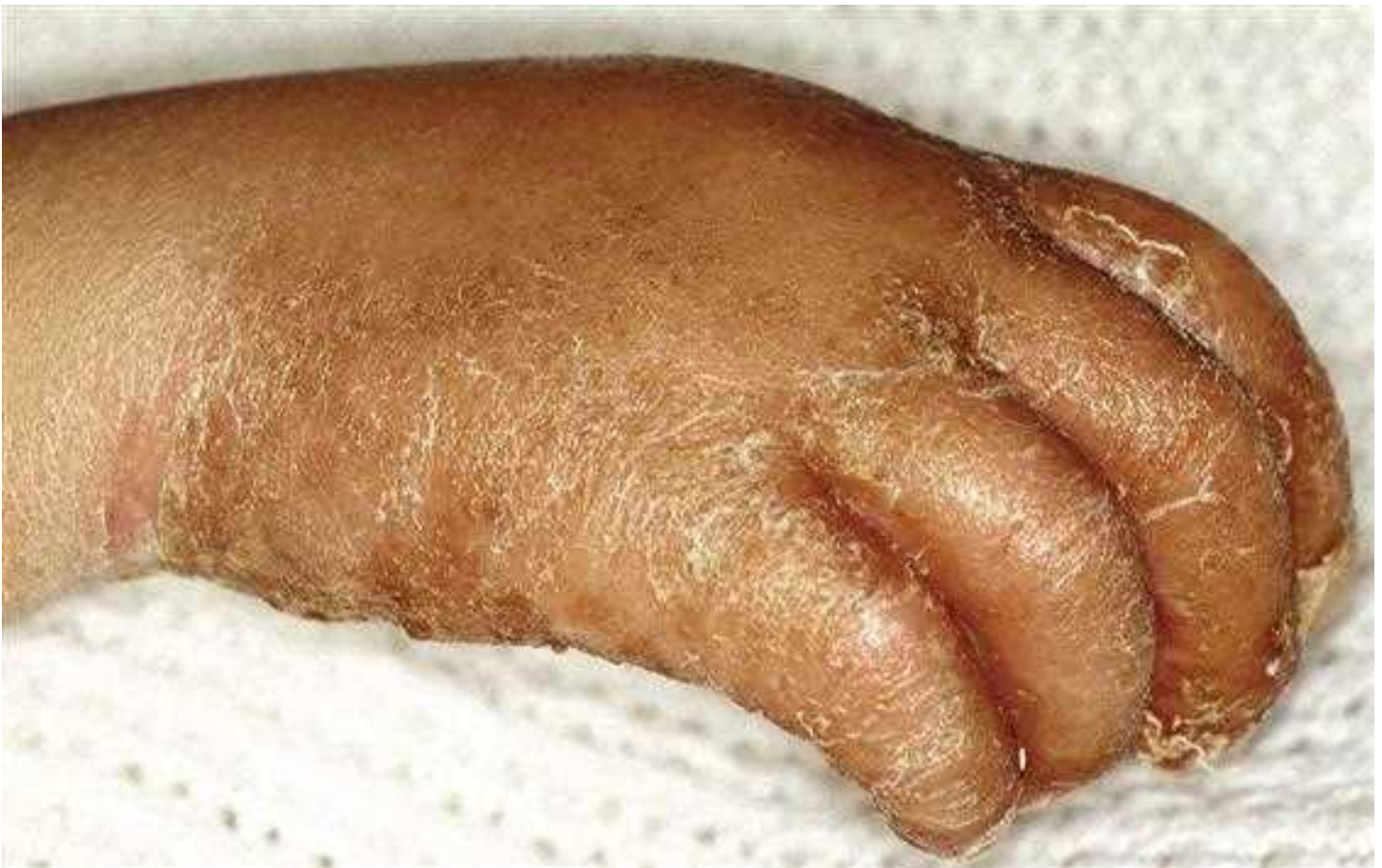

Figure 4.14 Infected eczema.

Routine blood tests are not necessary; however, an eosinophilia and raised IgE level may be seen. CAP RAST (ImmunoCAP specific IgE blood test) can be conducted against suspected allergens such as aeroallergens (pollens, house dust mite and animal dander) and foods (egg, cow's milk, wheat, fish, nuts, and soya proteins). Skin prick testing may also be used to determine any specific allergies to aeroallergens or foods. Ultimately food challenge may be needed.

Skin biopsy (usually a punch biopsy) for histological analysis may be performed if the

diagnosis is uncertain. Beware unilateral eczema of the areola, which could be Paget's disease of the nipple ([Figure 4.15](#)).

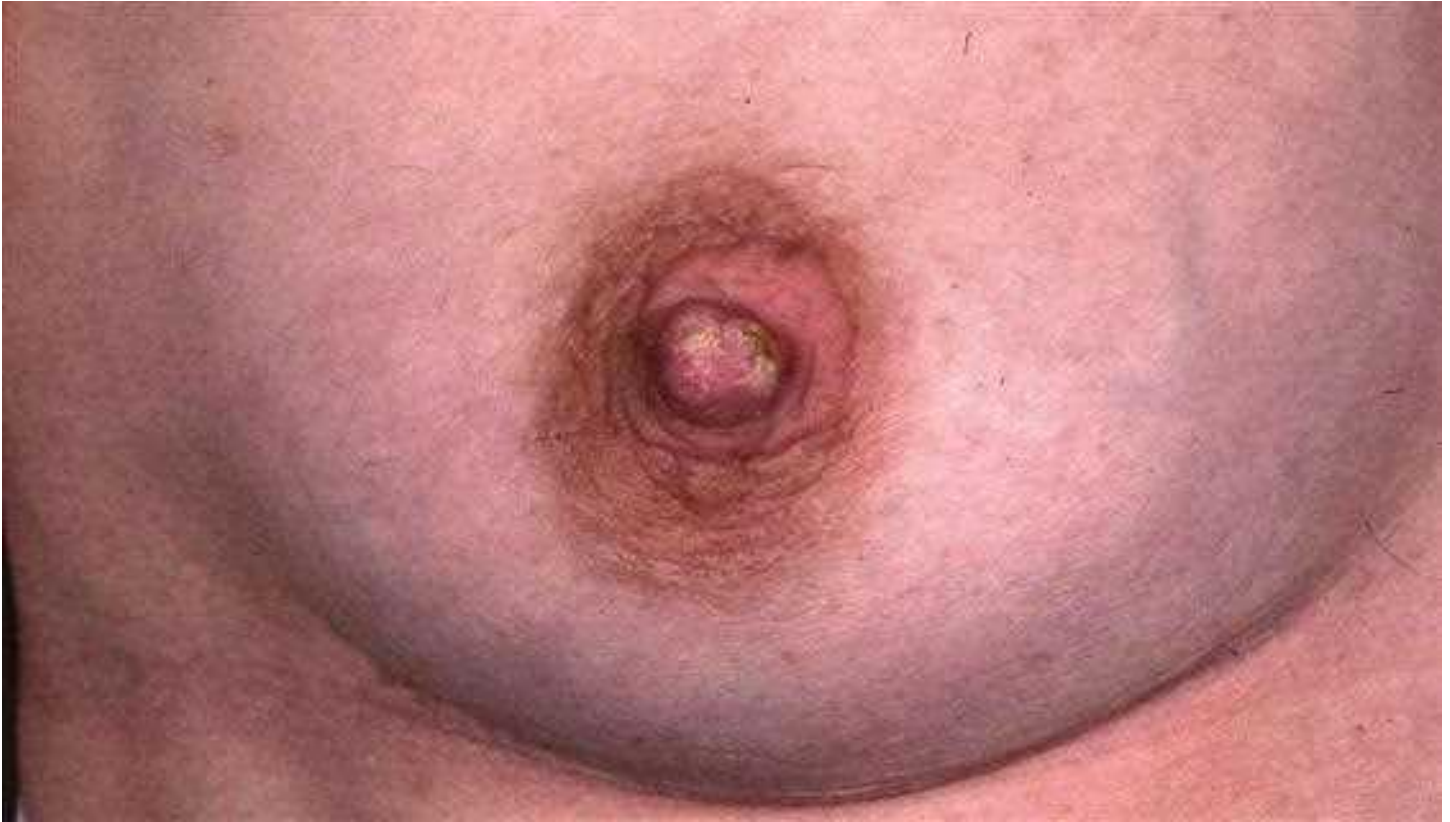

Figure 4.15 Paget's disease of the nipple – beware unilateral ‘eczema’.

Varicose eczema (leg ulcer) patients should have their ABPI (ankle brachial pressure index) measured before compressing their legs with bandages. ABPI is the ratio of their arm:ankle systolic blood pressure.

Classification of eczema

| Endogenous (constitutional) eczema | Exogenous (contact) eczema | Secondary changes |
|------------------------------------|----------------------------|-------------------|
| Atopic | Irritant | Lichen simplex |
| Discoid | Allergic | Asteatotic |
| Pompholyx | Photodermatitis | Pompholyx |
| Varicose | | Infection |
| Seborrhoeic | | |

Exogenous eczema

Contact dermatitis

Contact dermatitis can result from irritant or allergic reactions in the skin. Cutaneous contact

allergy is not inherent but acquired as a result of exposure to environmental or occupational allergens ([Box 4.1](#)). In general, the more a person is exposed to a potential allergen (quantity and frequency), the more likely they are to develop an allergy. Patients with abnormal skin barrier function (e.g. those with eczema) are more likely to develop contact dermatitis and suffer from irritant reactions than those with normal skin. Patients develop an allergic skin reaction at the site of sensitisation to an allergen, and then on subsequent exposure at a distant skin site develop eczema simultaneously at previous sites of allergy.

Box 4.1 Common contact allergens

- Nickel/cobalt (jewellery, clothing, wristwatch, scissors, and cooking utensils).
- Potassium dichromate (chemical used to tan leather; [Figure 4.17](#)).
- Perfumes, *Myroxylon pereirae* (balsam of Peru, fragrances; [Figure 4.20](#)), limonene, oxidised linalool.
- Formaldehyde, parabens, quaternium, methylchloroisothiazolinone, methylisothiazolinone (MCI/MI) (preservatives).
- Paraphenylenediamine (PPD) (permanent hair dyes, temporary tattoos, and textiles; [Figure 4.22](#)).
- Ethylenediamine (adhesives and medications).
- Chromates (cement and leather).
- Mercaptobenzothiazole, thiurams (rubber gloves and shoes).
- Neomycin, benzocaine (medicated ointments; [Figure 4.21](#)).
- Lanolin (wool alcohol, emollients, and mediated ointments).

Clinical features

The clinical appearance of both allergic and irritant contact dermatitis may be similar, but there are specific changes that help in differentiating them. An acute allergic reaction tends to be intensely itchy and results in erythema, oedema and vesicles. The more chronic lesions are often lichenified. Irritant dermatitis may be itchy or sore and presents as slight scaling, erythema, and fissuring.

The distribution of the skin changes is often helpful in identifying the underlying cause ([Figure 4.16](#)). For example, an itchy rash on the foot may indicate allergy to footwear ([Figure 4.17](#)) such as allergy to potassium dichromate, a chemical used to tan leather. An allergy to medications used for treating leg ulcers is a common cause of persistent dermatitis on the lower leg, or iodine used to clean the skin pre-operatively ([Figure 4.18](#)). Hand dermatitis can

result from glove allergies (rubber and latex) or contact with an occupational exposure such as melamine formaldehyde resin ([Figure 4.19](#)) or irritation from sweat under gloves. Fragrance allergy is common and can cause reactions to cosmetic products ([Figure 4.20](#)). Patients can develop allergies to medicaments such as those containing neomycin ([Figure 4.21](#)). Allergy to PPD in a tattoo causes a very brisk vesicular reaction ([Figure 4.22](#)). Patients may also develop contact allergies to dressings/plasters/transepidermal medications applied to the skin ([Figure 4.23](#)). An irritant substance may produce a more diffuse eruption such as physical irritation to the skin caused by air conditioning.

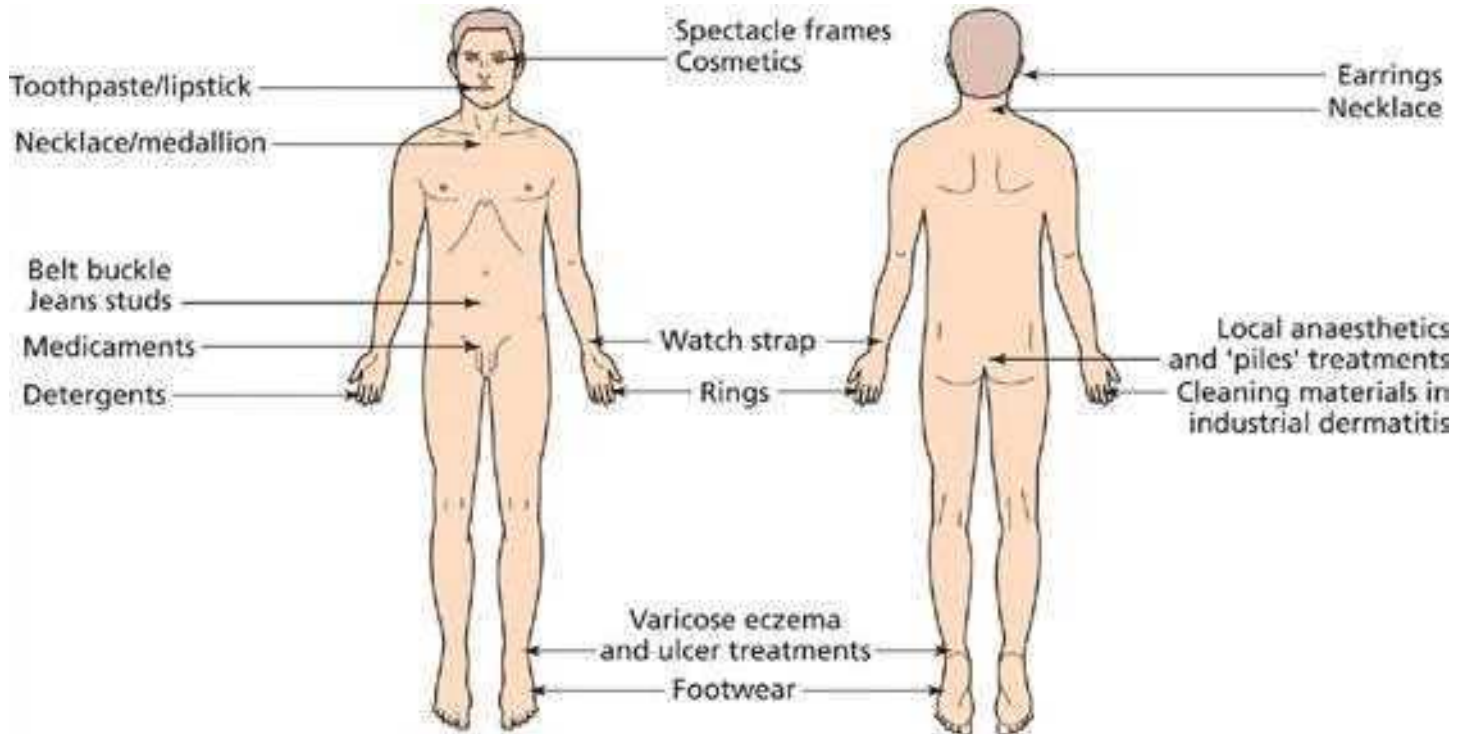


Figure 4.16 Common sources of contact dermatitis by body site.

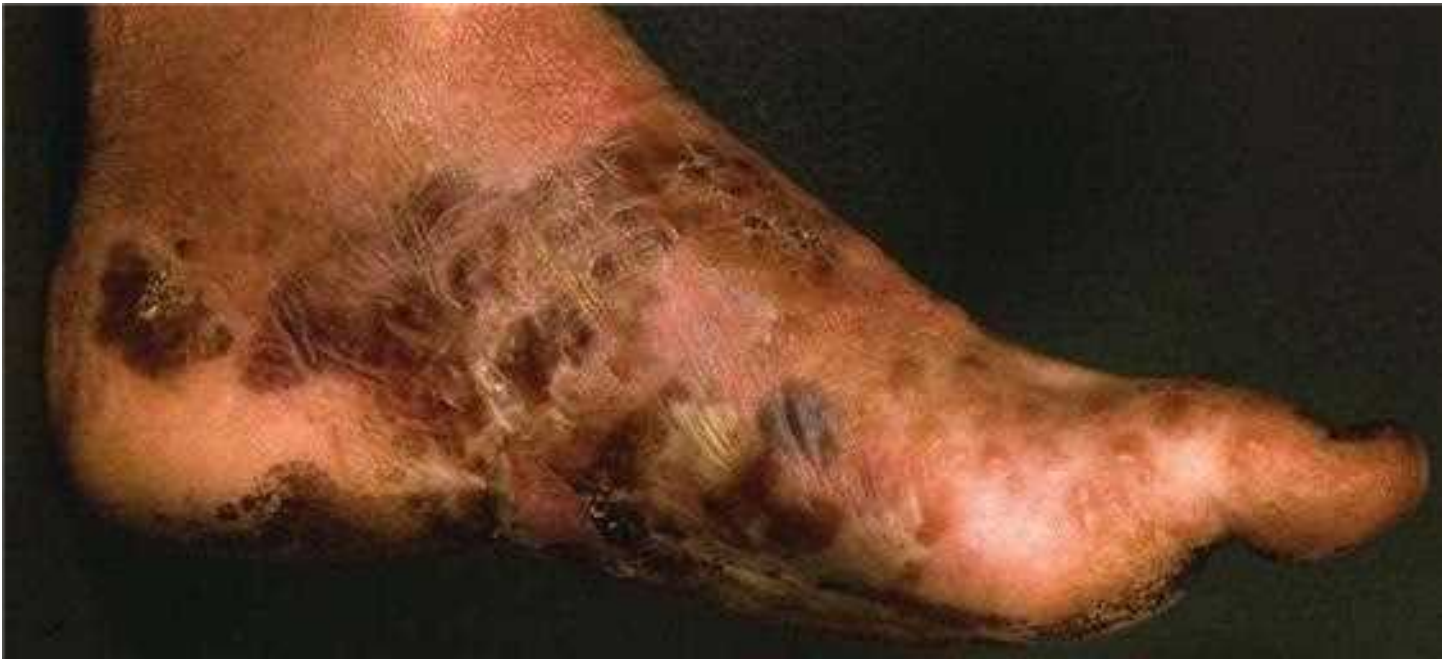

Figure 4.17 Severe contact dermatitis to potassium dichromate in leather shoes.

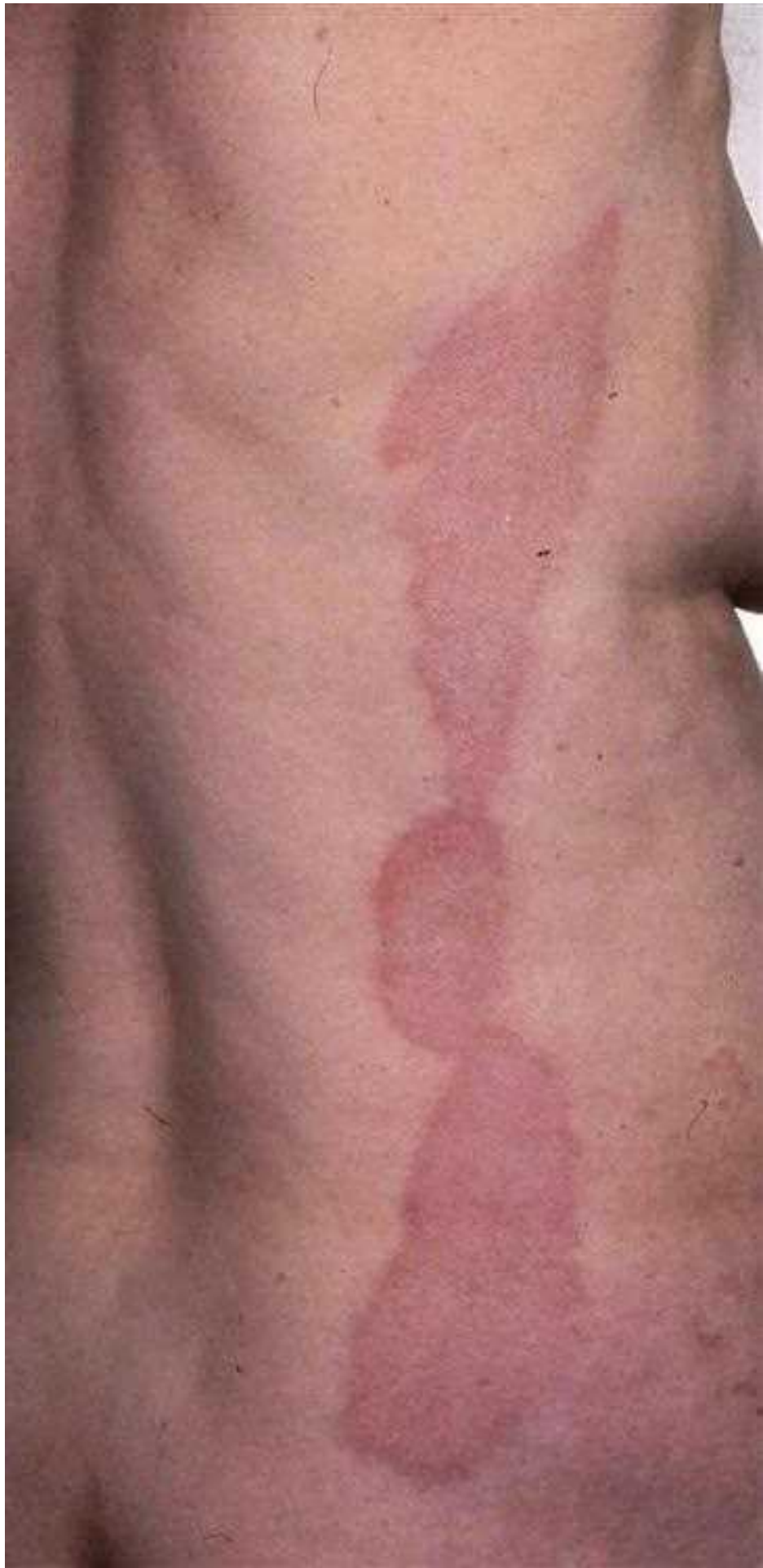

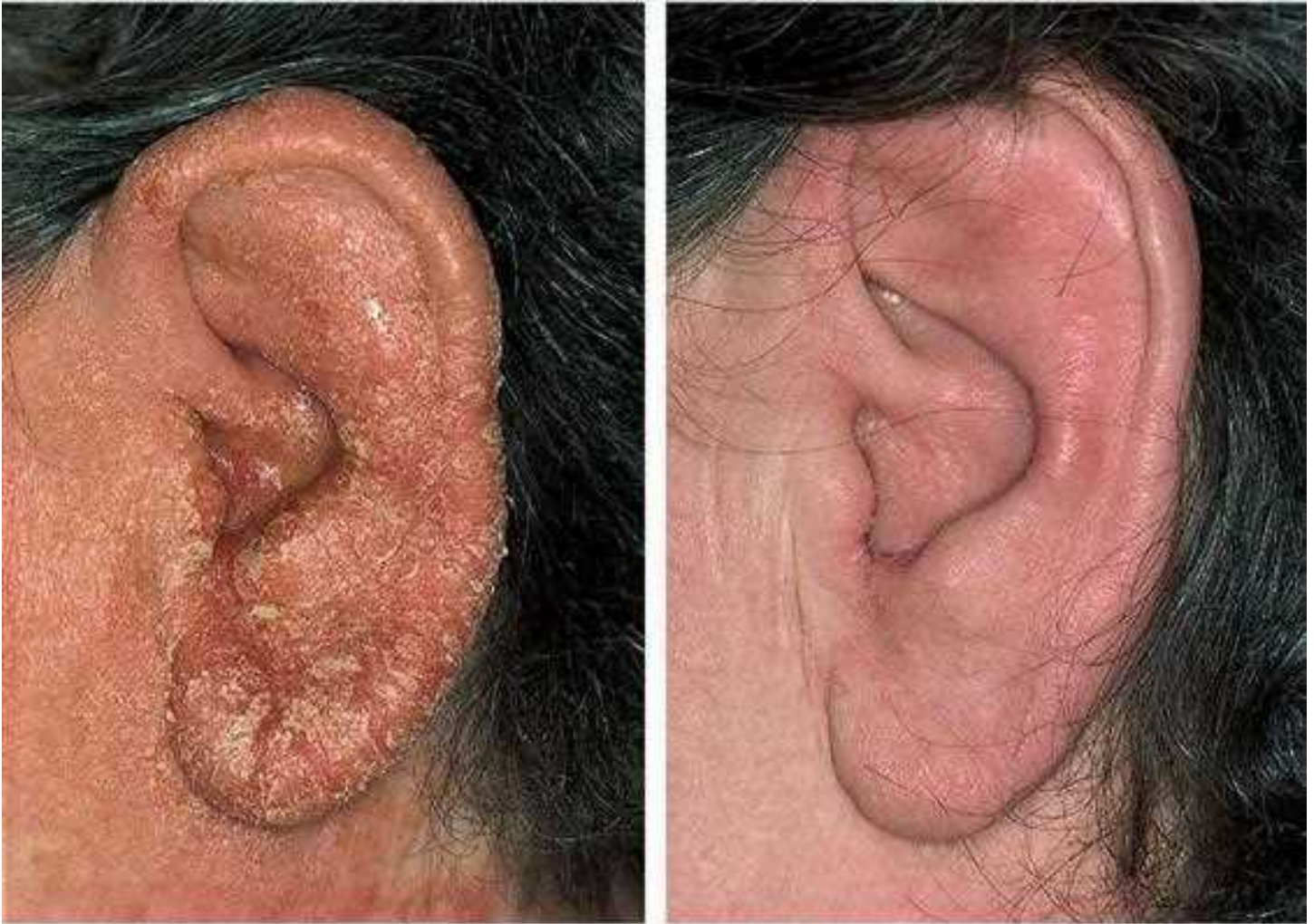
Figure 4.18 Contact dermatitis to iodine.

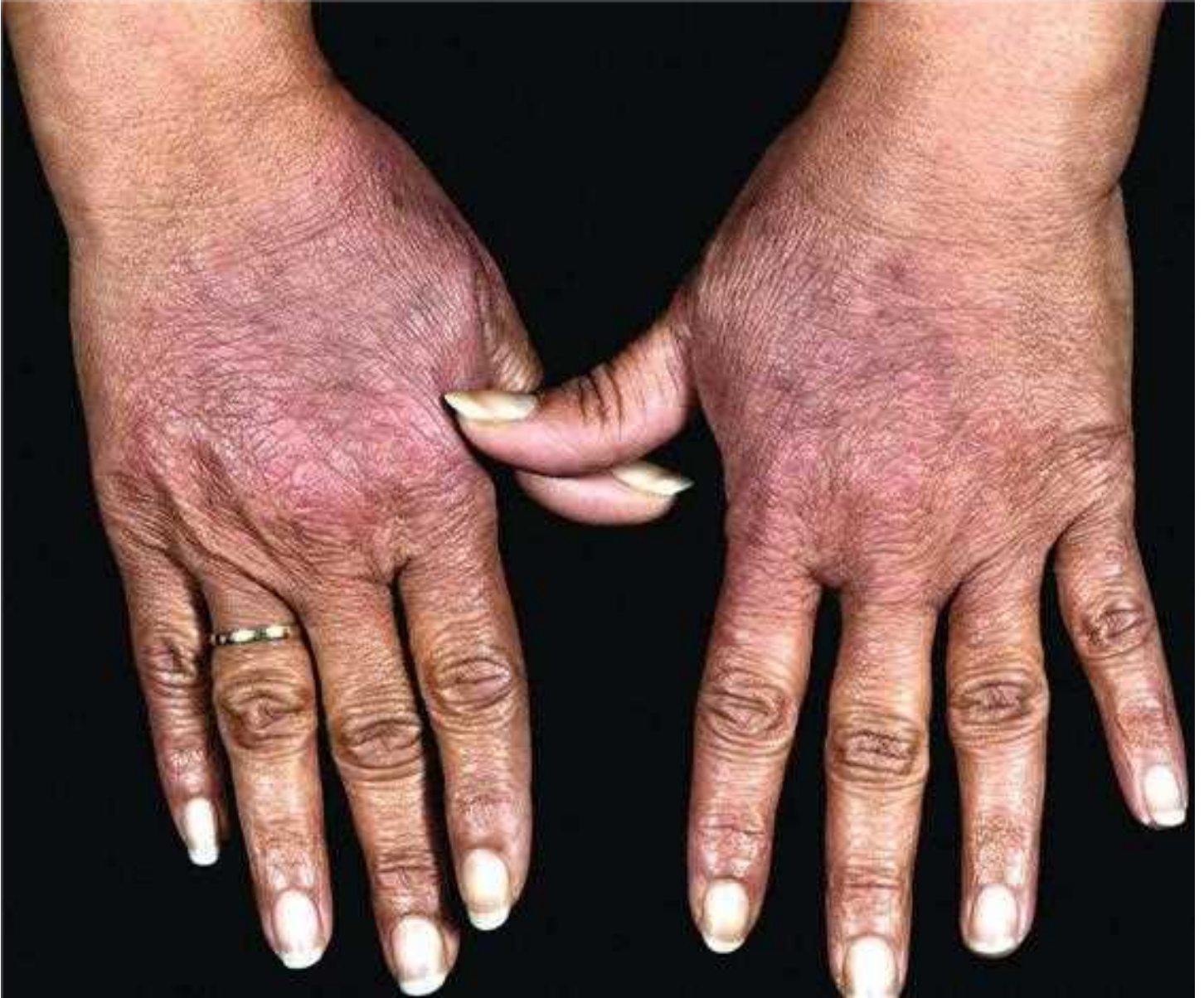

Figure 4.19 Allergic contact dermatitis to melamine formaldehyde resin.

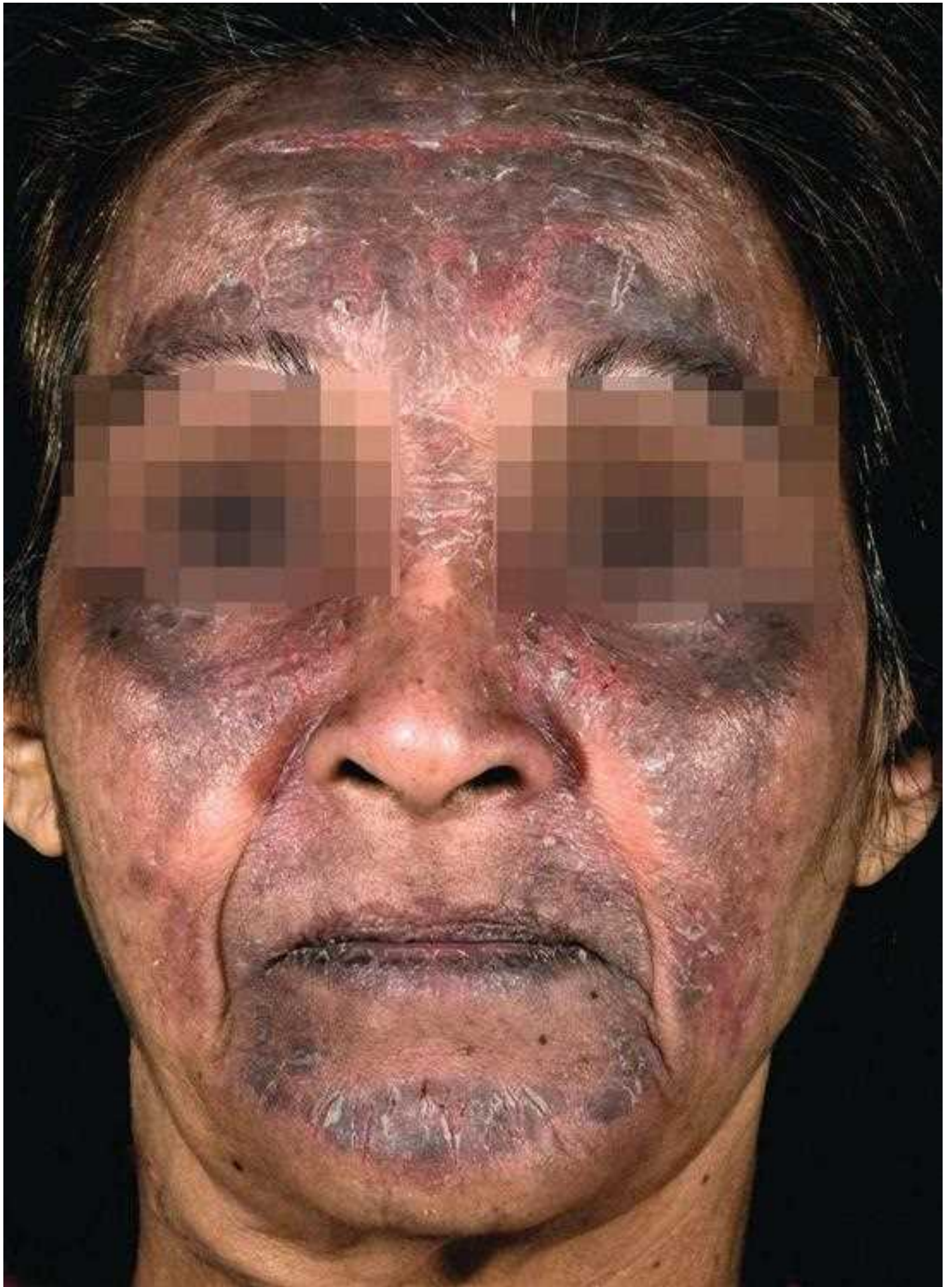

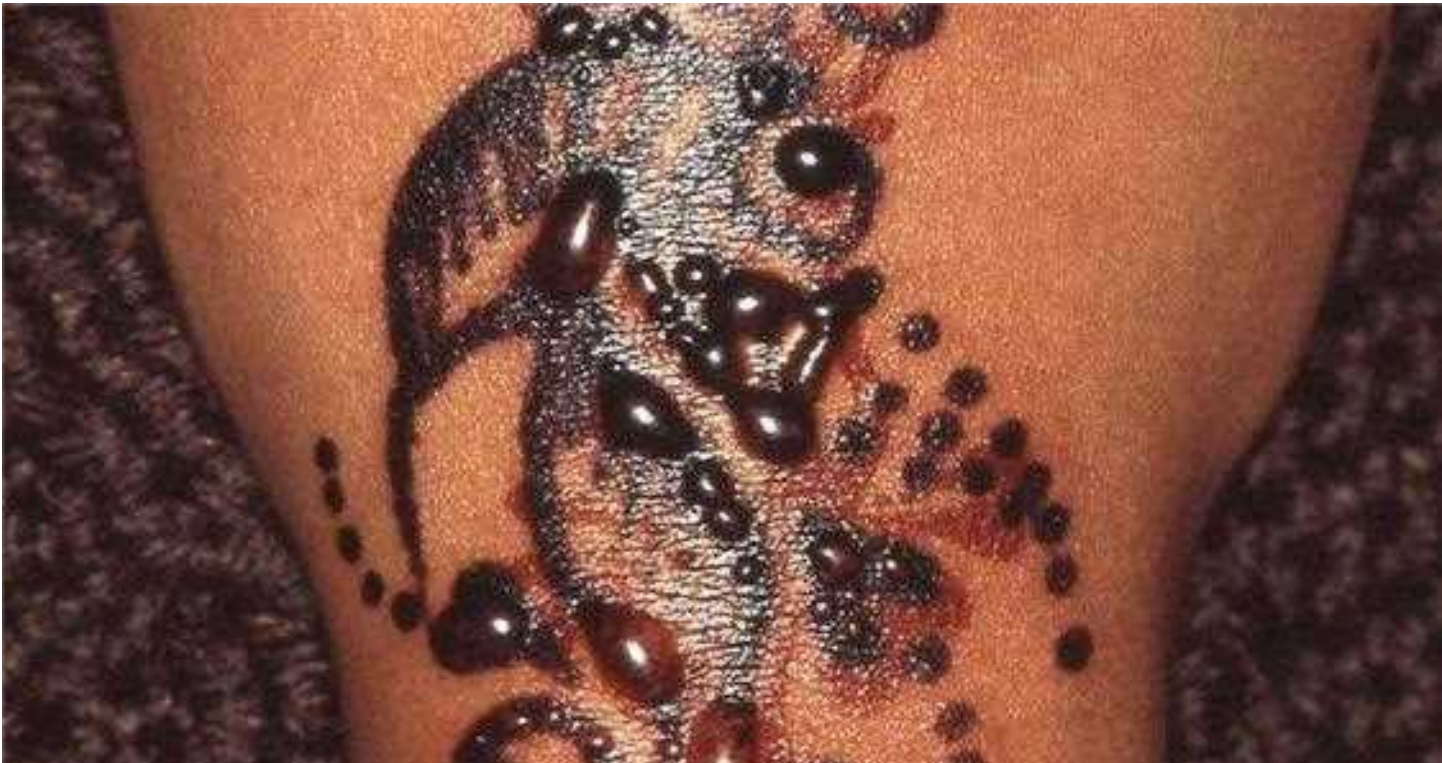Figure 4.20 Contact dermatitis to fragrance in facial cream.



(a)

(b)

Figure 4.21 (a) Contact dermatitis to neomycin cream and (b) after stopping the treatment.



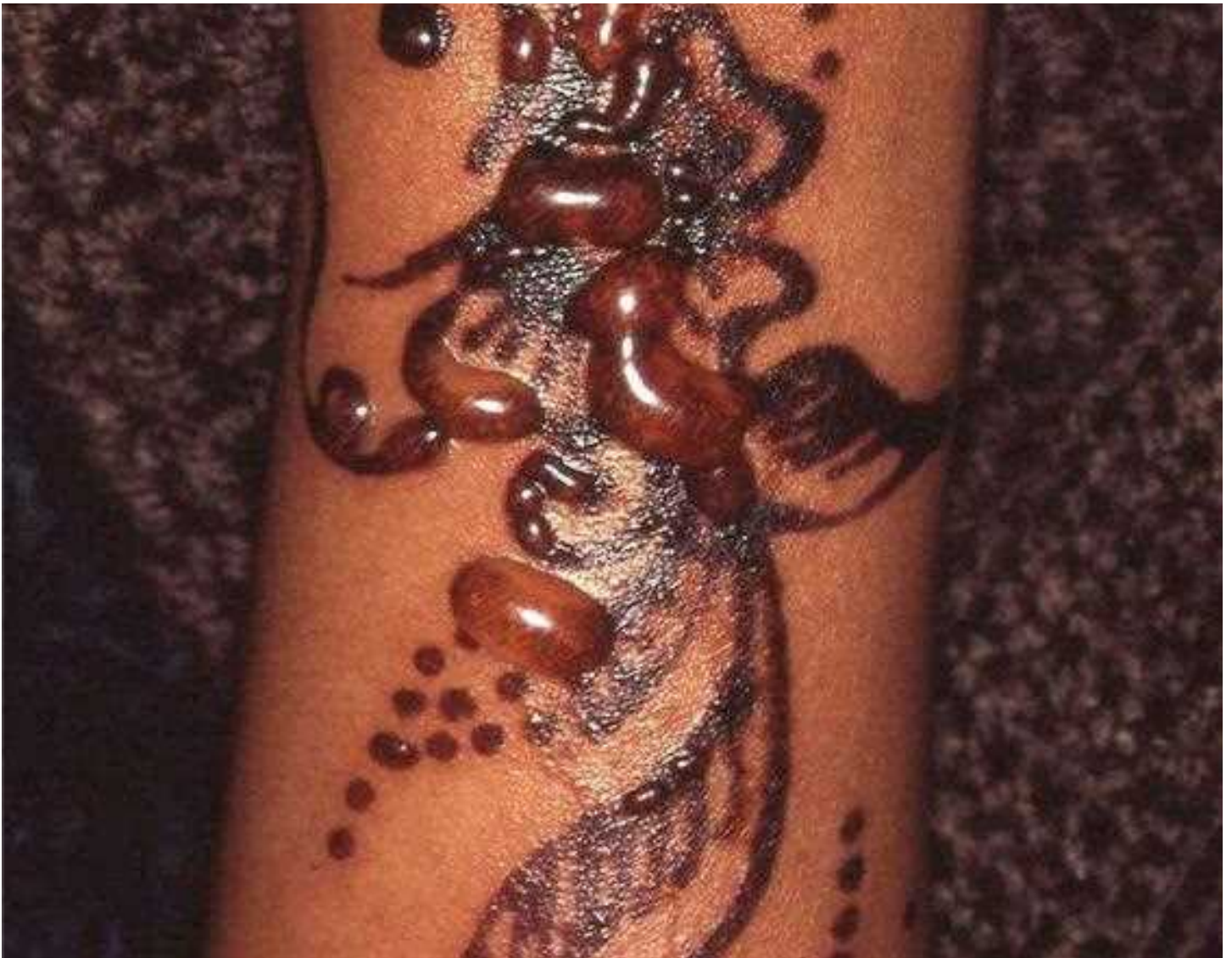
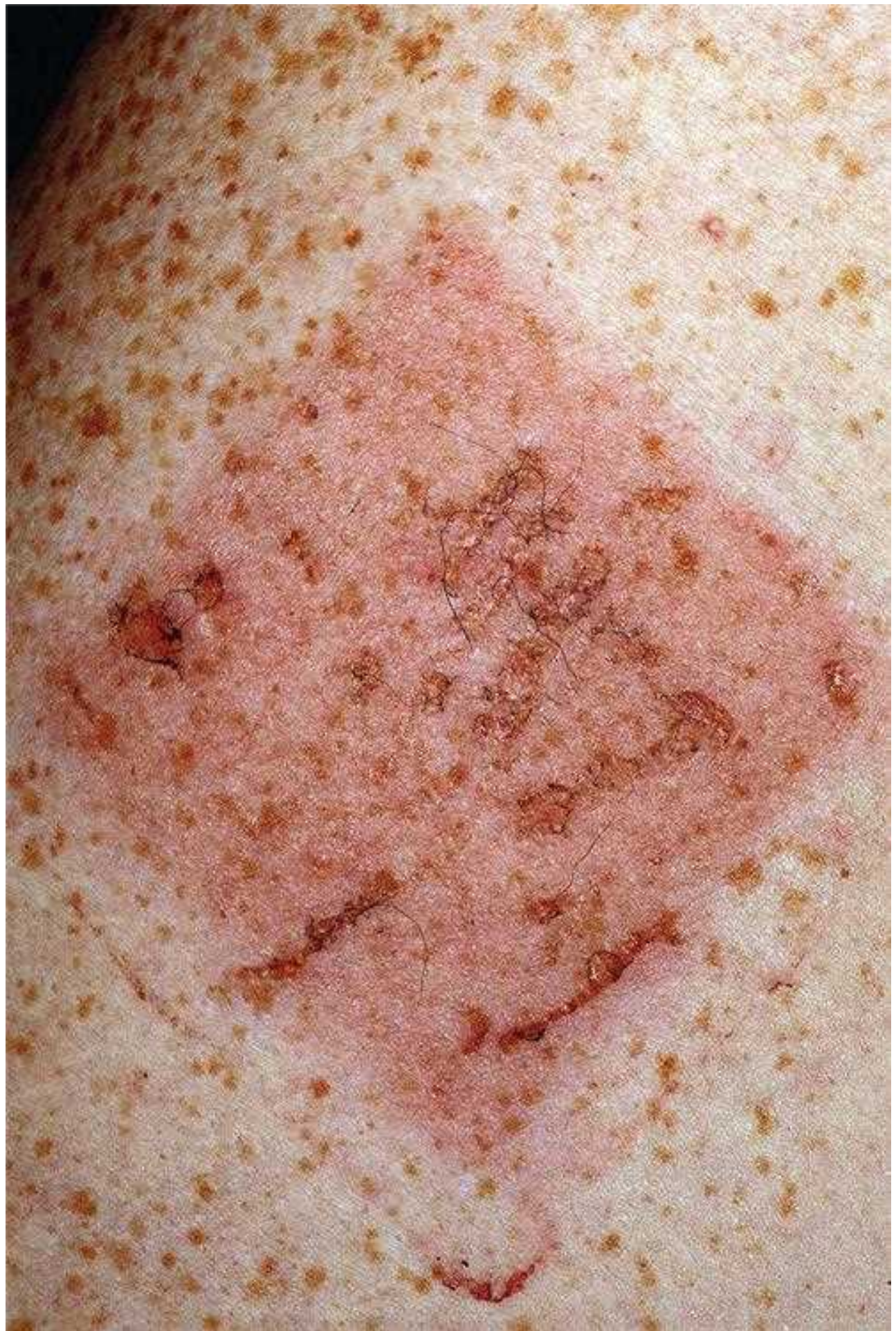
Figure 4.22 Acute PPD allergy in a 'henna' tattoo.



[Figure 4.23](#) Contact allergy to morphine dressing.

Allergic contact dermatitis

The characteristics of allergic dermatitis are as follows:

- Previous exposure to the substance concerned.
- 48–96 hours between contact and the development of changes in the skin.
- Activation of previously sensitised sites by contact with an allergen at a distant skin site.
- Persistence of the allergy for many years.

Immune mechanisms

Allergic dermatitis results from a type IV delayed hypersensitivity reaction in the skin. Specific antigens (usually proteins) penetrate the epidermis, combine with a protein mediator and are then picked up by Langerhans cells. This causes T-lymphocytes in regional lymph nodes to become sensitised to the antigen. On subsequent exposure to the antigen, an allergic reaction occurs because of the accumulation of sensitised T-lymphocytes at the site of the antigen with a resultant inflammatory response. This takes 48 hours and is amplified by interleukins that provide a positive feedback stimulus to the production of further sensitised T-lymphocytes ([Figure 4.24](#)).

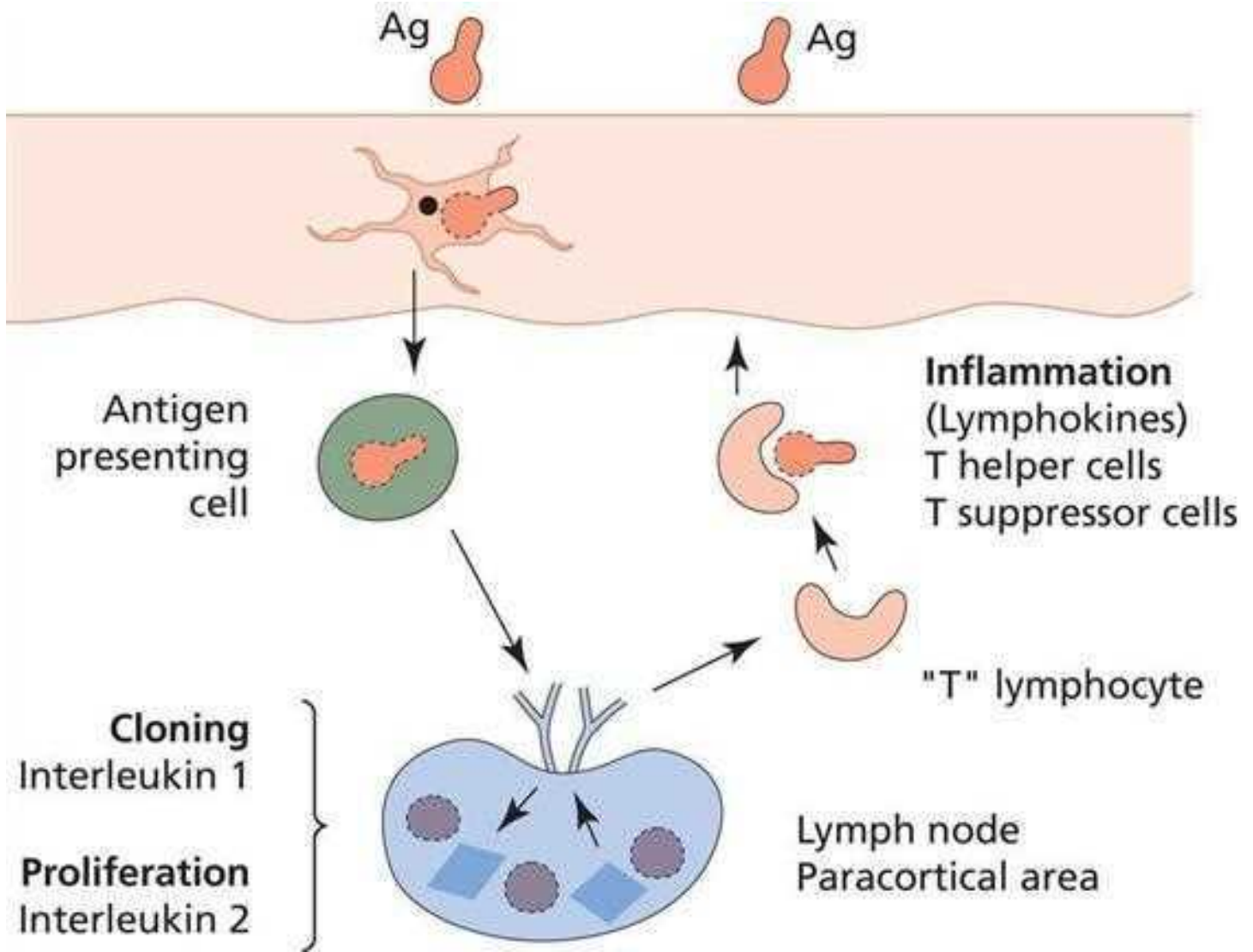


Figure 4.24 Immunological response leading to the development of contact dermatitis.

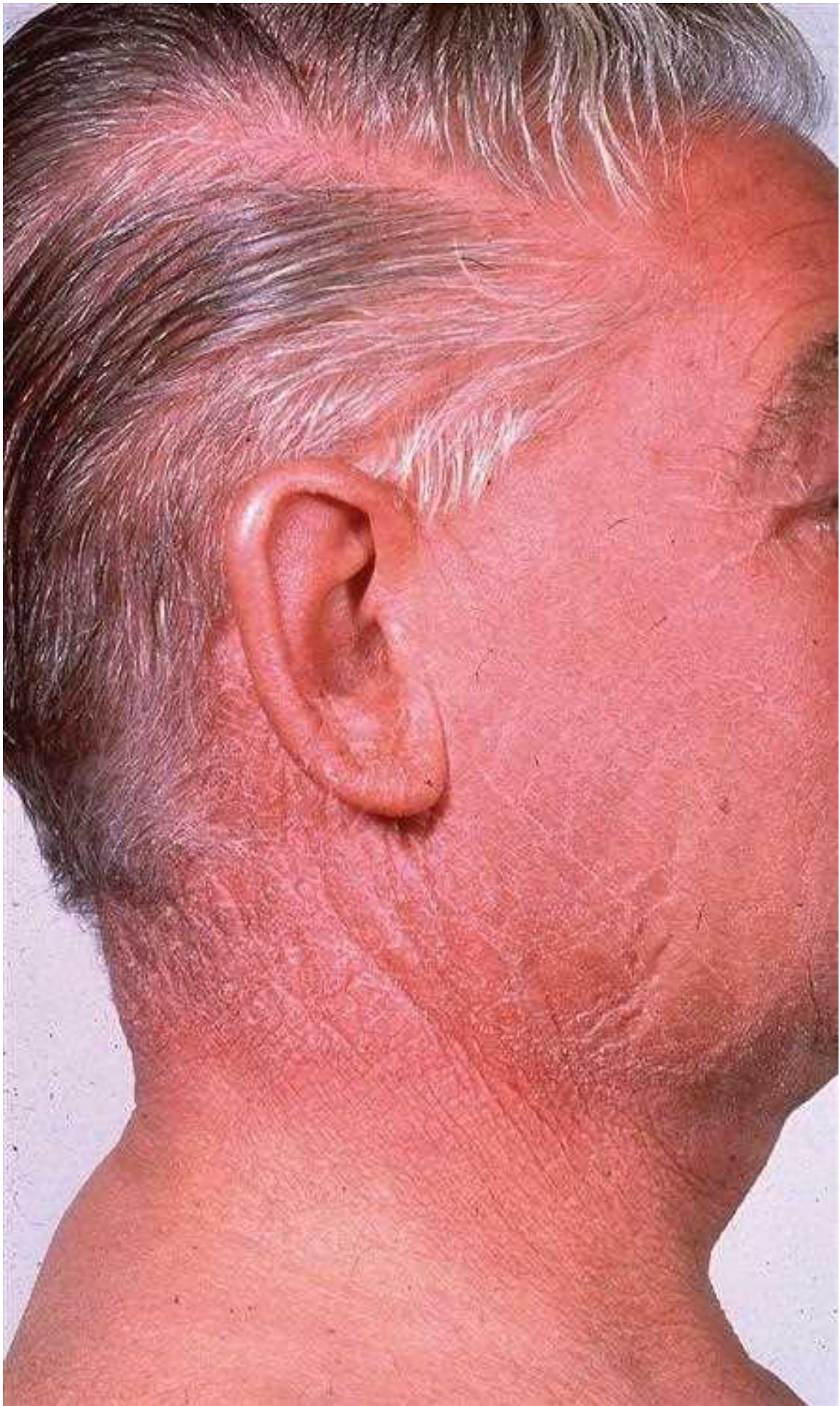
Irritant contact dermatitis

This may be chemical or physical, has a less defined clinical course and is caused by a wide variety of substances with no predictable time interval between contact and the appearance of the rash. Physical irritants include air conditioning, prosthetic limbs, personnel protective clothing, and repetitive mechanical trauma. Chemical irritants include detergents, solvents, and acids. Dermatitis occurs soon after exposure and the severity varies with the quantity, concentration, and length of exposure to the substance concerned. Previous contact is not required, unlike allergic dermatitis where previous sensitisation is necessary.

Photodermatitis

Photodermatitis is caused by the interaction of light and chemicals absorbed by the skin. It can result from (i) drugs taken internally, such as sulfonamides, phenothiazines, tetracycline, and voriconazole or (ii) substances in contact with the skin, such as topical antihistamines,

local anaesthetics, cosmetics, and antibacterials. Phytophotodermatitis is due to contact with plant material, often containing forms of psoralens (poison oak, common rue, lime juice, and celery) and sunlight causing an allergic contact dermatitis. Patients with chronic actinic dermatitis ([Figure 4.25](#)) (chronic eczema on sun-exposed skin) are allergic to sunlight but in addition they may be allergic to Compositae plants (daisy and sunflower family).



[Figure 4.25](#) Chronic actinic dermatitis.

Occupational dermatitis

In the workplace, employees may have contact with allergens or irritants that can result in dermatitis. If an individual has an atopic tendency to develop eczema he or she is at increased risk of developing occupational dermatitis. Secondary bacterial infection can play a role once dermatitis has occurred. Therefore, contact dermatitis, atopic eczema and infection may all be superimposed – for example, a nurse or hairdresser who is exposed to water, detergents, and other factors that will exacerbate any pre-existing eczema. The skin then becomes broken because of scratching, and secondary infection occurs. The frequent use of alcohol-based hand gel in hospitals by health care professionals is leading to an increased frequency of irritant hand dermatitis which has implications for infection control.

An occupational dermatitis is likely if

- the dermatitis first occurred during a specific employment and had not been present before;
- the condition generally improves or clears when away from the workplace and
- there is exposure to known irritant/allergic substances and personnel protective measures are inadequate.

Persistence of dermatitis away from the workplace may occur in occupational dermatitis if the allergen is also present at home (e.g. rubber in gloves), if there is secondary infection and if there are chronic skin changes. The morphology of the skin eruption itself will be indistinguishable whatever the cause of the eczema.

Occupational irritant contact dermatitis can be acute or chronic. Acute reactions are usually associated with a clear history of exposure to a chemical or physical irritant. Chronic irritant dermatitis can be harder to assess as it develops insidiously in many cases. Individuals involved in frequent ‘wet work’ such as nurses, cleaners, chefs, and those looking after small children can develop irritant hand dermatitis from repeated exposure to water ([Figure 4.26](#)). Initially, transient inflammation may clear; however, with each successive episode the damage becomes worse with an escalation of inflammatory changes that eventually become chronic and fixed. Once chronic damage has occurred the skin is vulnerable to any further irritation; therefore, the condition may flare up in the future even after removal of the causative factors. Individuals with atopic eczema are particularly liable to develop chronic irritant dermatitis, and secondary infection is an additional factor.

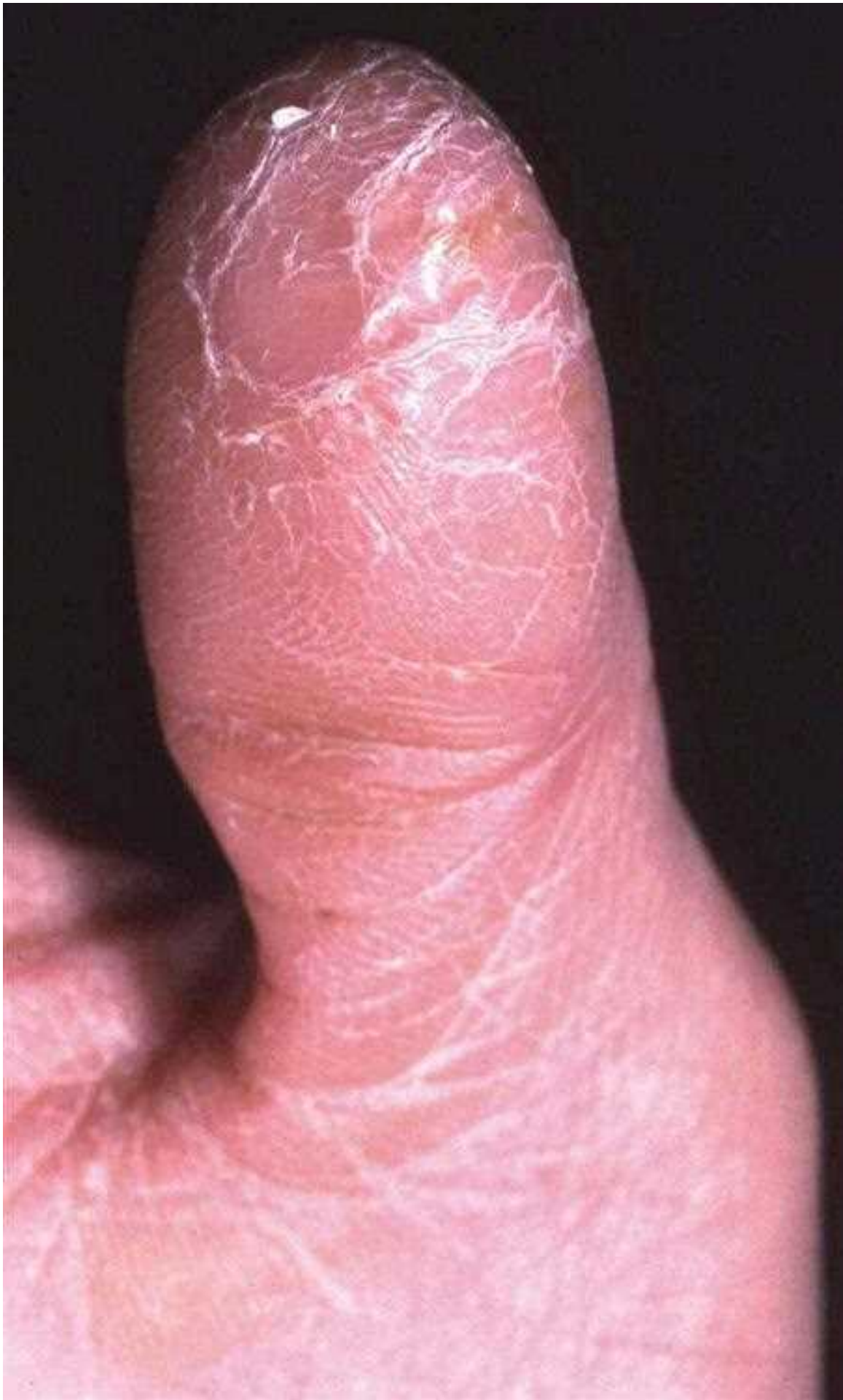

Figure 4.26 Irritant hand eczema in a chef.

Occupational allergic contact dermatitis occurs as an allergic reaction to specific substances. There is no immediate reaction on first exposure; however, after repeated exposure a cell-mediated inflammatory response develops. Some substances are highly sensitising such as epoxy resin, whereas others such as cement need prolonged exposure over many years to trigger allergy. In addition to the capacity of the substance to produce an allergic reaction, individuals also vary considerably in the capacity to develop allergies.

Contact urticaria is an immediate-type sensitivity reaction that can occur to certain food proteins and latex glove allergy. Chefs may develop allergies to foods proteins (usually on their non-dominant hand as knives are usually held in the dominant hand) that can result in contact urticaria, or a more chronic irritant contact dermatitis.

Investigations of contact dermatitis

A full-detailed history is essential if the potential irritant or allergen is to be identified. Dermatology specialists should particularly assess those with a suspected occupational dermatitis as the investigations and subsequent results could affect the patients' future employment and possible compensation claims.

In relation to suspected occupational dermatitis, the exact details of the patient's job should be taken in careful detail. Occasionally, an 'on-site' visit to the work place may be required; for example, a worker in a plastics factory had severe hand dermatitis but the only positive result on patch testing was to nickel. On visiting the factory it became clear that the cause was a nickel-plated handle that he used several thousand times a day. It is also important to assess the working environment because exposure to dampness (on an oil rig) and irritants (dry air in aircraft cabins) can result in skin irritation.

Patch testing

Patch testing is used to determine the substances that cause contact dermatitis. The concentration used is critical to ensure a low false negative/positive rate. The optimum concentration and best vehicle have been ascertained for most common allergens. The standard series contains a 'battery' of tests that encompasses the most common allergens encountered. Additional specialist 'batteries' (dental, medicaments, metals, perfumes, etc.) may also be available in some specialist dermatology centres. It is important that patch testing is managed by experienced dermatologists to ensure that the most appropriate tests are performed, in the correct manner (timings and dilutions), interpreted correctly (irritant or allergic reactions) and then any relevance sought.

The test patches are usually placed on the upper back (sites marked) and left in place for 48 hours, then removed and any positive reactions noted ([Figures 4.27](#) and [4.28](#)). A further examination is carried out at 96 hours to detect any late reactions ([Figure 4.29](#)). Patients need

to visit the unit three times in one week, be off systemic immunosuppressants and have an area of clear skin (usually the upper back) on which to perform the tests. Although rare, sensitisation may occur as a consequence of exposure to an allergen through patch testing.

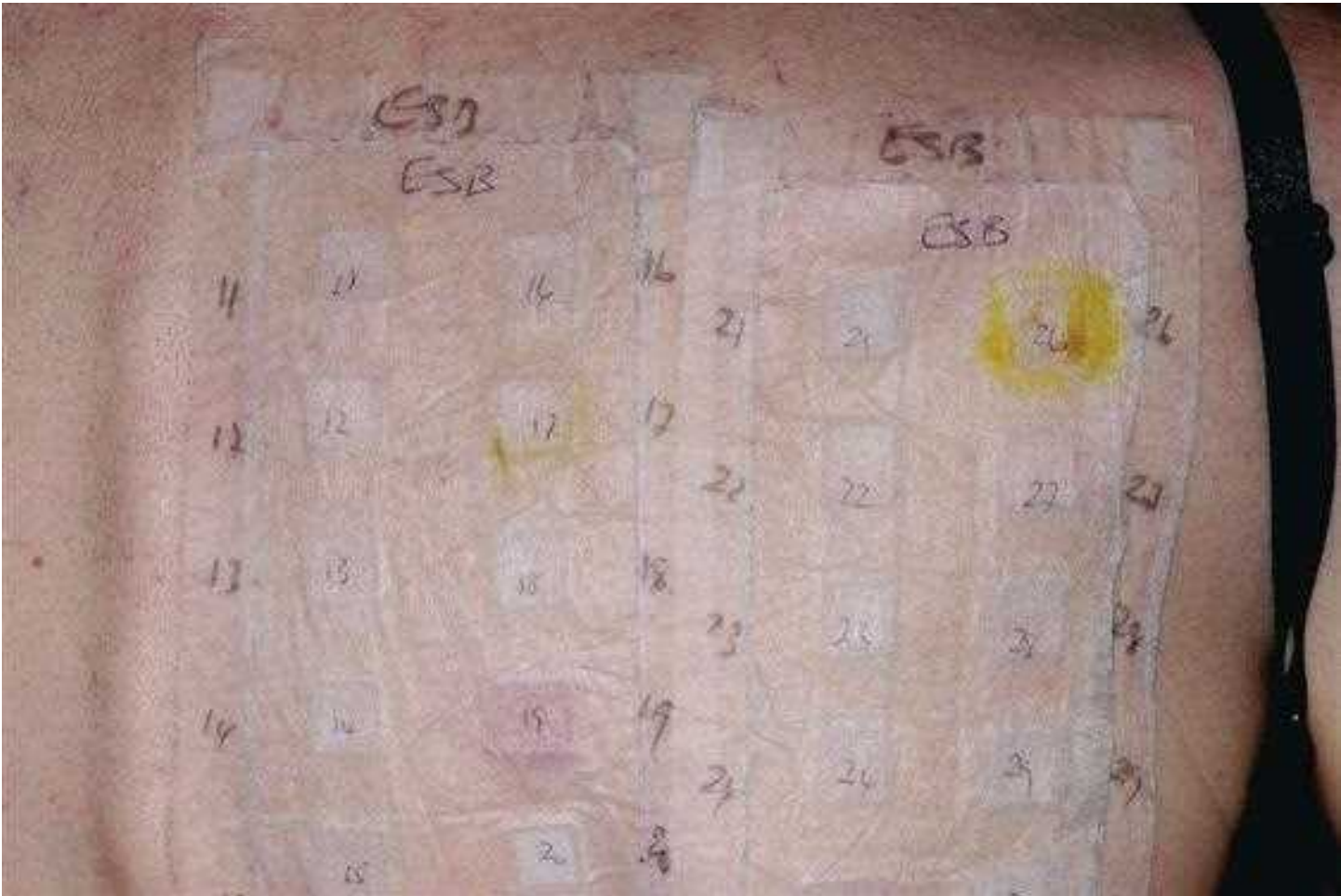

Figure 4.27 Test patches in place.

ESR

1

2

4

8

6

7

8

5

5

2

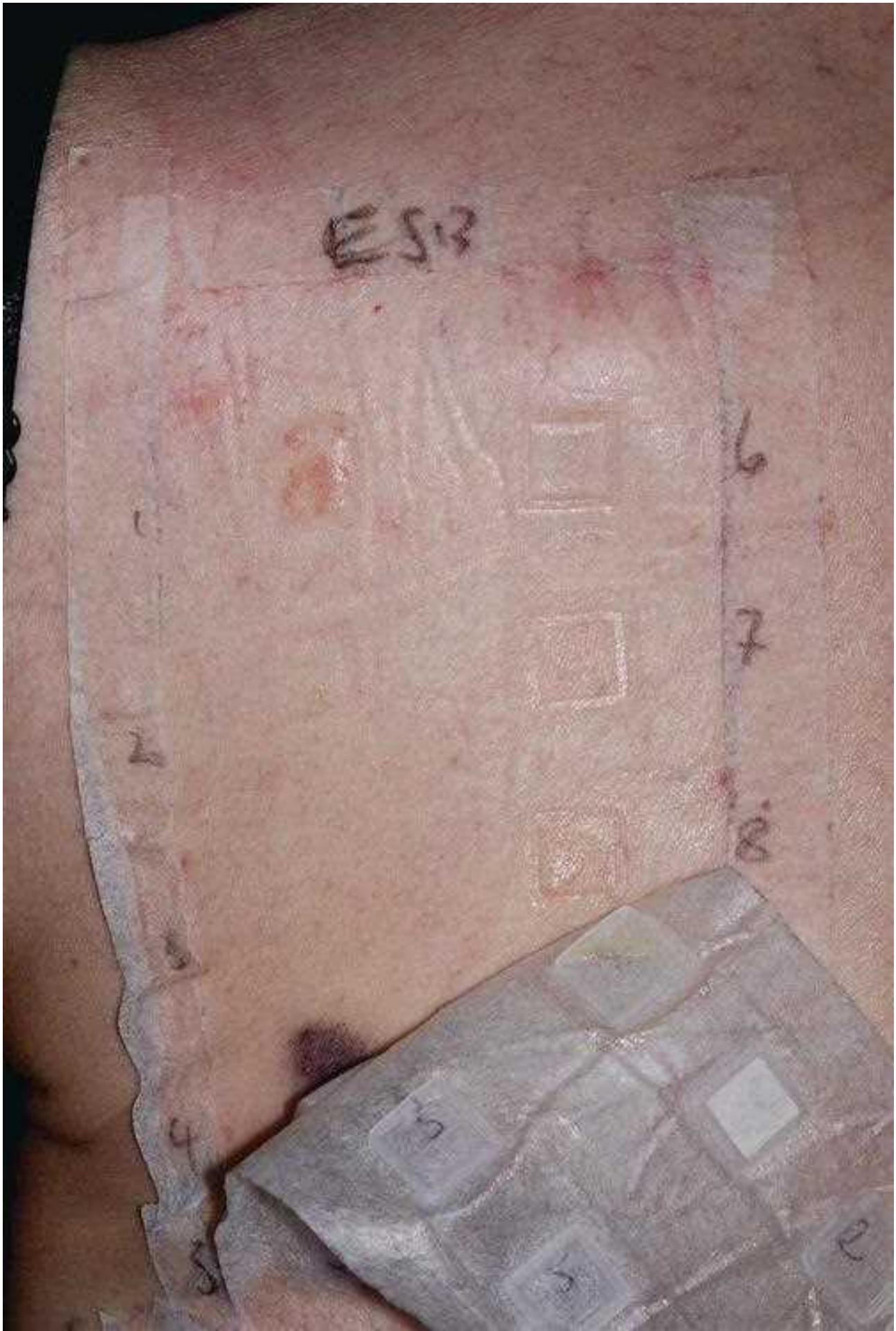

Figure 4.28 Patches being removed after 48 hours.



Figure 4.29 Positive patch test reactions.

General management of eczema

Holistic care of the patient is paramount in the context of eczema. Management of AD patients should include adequate time to discuss the genetic aetiology the condition, the aims of therapy (suppression rather than cure) and how to apply the treatment (a demonstration/educational session with specialist nurses can be very helpful). Exogenous eczema may be transient and 'cured' after identification and avoidance of trigger factors.

Practitioners need to have realistic expectations about what patients can tolerate in terms of acceptability of topical formulations as some are greasy and smelly. Patients need to be physically capable and able to find the time to apply their own creams.

Many simple treatments can be purchased and applied by the individuals themselves without the need to consult a medical practitioner. Treatments usually start with simple emollients and mild topical steroids but with increasingly recalcitrant disease stronger topical steroids and even systemic immunosuppressants may be needed.

- *Emollients*. Patients with dry skin conditions have ready access to a wide range of

emollients (moisturising creams) over the counter. In general, the oilier the cream the better its emollient properties; however, patients tend to prefer lighter creams. Moisturisers should be applied repeatedly throughout the day in generous amounts. Emollients help to restore barrier function and reduce itching.

- *Cleansers.* Normal soap contains surfactants which disrupt the lipid barrier and cause drying of the skin. Emulsifying ointments/emollient washes are useful soap substitutes. Antibacterial moisturising washes have been shown to be very useful in those prone to infected eczema. The emollient wash should be applied directly to the skin and then rinsed off (bath/shower), there is no need to pour emollient wash into bath water. Soothing and de-scaling shampoos can be useful for dry, flaky, and itchy scalps.
- *Topical steroids – frequency and quantity.* Topical steroids continue to be the mainstay of treatment for active eczema. Many patients are wary of using topical steroids as they are worried about skin thinning. We need to reassure patients that under careful medical supervision steroids should be safe and are highly effective. Ointments rather than creams should be used whenever possible (creams are more likely to cause irritation and have a higher risk of inducing contact allergies). Steroid should be applied once or twice daily to the affected skin only. One finger-tip-unit (a line of ointment from the tip of the finger to the first skin crease) is a sufficient amount to treat a hand-sized (palmar and dorsal surface) area of affected skin. Strength and frequency should be tailored to the severity and skin sites affected.
- *Topical steroids – potency.* Very low potency steroids (such as hydrocortisone and clobetasone butyrate) may be purchased over the counter and used to treat mild eczema. For moderate to severe disease, the current approach is to prescribe potent topical steroids (mometasone, betamethasone, and fluocinolone acetonide) for short periods followed by steroid ‘holidays’ rather than using daily low potency steroids, which rarely clear the eczema. For acute dermatitis start with a potent topical steroid and apply daily until the eczema clears, try to use a lower strength topical steroid for flare-ups. Lower potency topical steroids should be used on the face and groin areas (hydrocortisone and clobetasone butyrate).
- *Immunomodulators.* These are useful topical preparations to control mild eczema and are usually prescribed and supervised by an experienced dermatological practitioner. Tacrolimus (0.03% – children aged 2–15 years, 0.1% – adults) and pimecrolimus (1%) are applied twice daily to the affected skin. They can be useful on areas such as the face/around the eyes where steroid-sparing treatment is desirable.
- *Occlusion.* Covering topical therapy with bandages, body suits, ‘wet wraps’ and dressings can be very helpful in the management of chronic eczema (see [Chapter 25](#)). Prior to occlusion, the practitioner should ensure that the eczema is not infected. Patients and their carers should be taught how to apply these occlusive aids which are generally worn overnight. Occlusive therapy helps relieve symptoms of itch, keep emollient creams on the skin and ‘drive’ topical therapy through the epidermis. The potency of topical steroids is enhanced 100-fold by occlusion; therefore, care should be

taken.

- **Antibiotics.** Occasionally, antibiotics are needed to treat infected eczema; they may be given topically or systemically. Topical antibiotics used include fusidic acid, silver sulfadiazine, polymyxins, neomycin, and mupirocin. Formulations of antibiotics combined with topical steroids are available. It is recommended that topical antibiotics should be used for a maximum of two weeks continuously to try to reduce the risk of developing resistant bacteria. Systemic antibiotics used include flucloxacillin (amoxicillin and penicillin) erythromycin (clarithromycin and azithromycin) and ciprofloxacin (levofloxacin and ofloxacin). Antibacterial emollient washes can be useful in managing active cutaneous infections as well as preventing them by daily use.
- **Phototherapy.** Light treatment with narrow-band UVB (TL-01) or PUVA (psoralen with ultraviolet A) can be highly effective for generalised eczema. Each course of phototherapy lasts six to eight weeks with patients attending two to three times per week. There is, however, a limit to the number of courses (cumulative dose) of phototherapy that any individual patient (particularly with pale skin) may receive before there is an increased risk of skin cancer.
- **Systemic therapy.** Severe widespread disease not controlled with topical therapy may require systemic immunosuppressants. Occasionally, dermatology specialists may prescribe a rapidly reducing course of oral prednisolone (30 mg for 5 days, then reducing by 5 mg every 5–7 days) to control very severe generalised acute eczema. However, long-term oral steroids should not be used to control eczema. Rather, azathioprine, ciclosporin, mycophenolate mofetil, and methotrexate can be used for long-term management. If available, levels of thiopurine methyl transferase (TPMT) should be checked prior to initiation of azathioprine.

Biological treatment for atopic dermatitis

Dupilumab a human monoclonal antibody targeting the IL-4 R α subunit (which blocks signalling of both IL-4 and IL-13), is the first biologic to be approved for the treatment of moderate to severe AD in adult patients. The biologic is given by subcutaneous injection starting with 600 mg and then 300 mg alternate weeks. Most studies quote 40–60% of patients having a 75% improvement in disease severity scores at 16 weeks of treatment. The most common adverse events include injection site reactions, eye/eyelid inflammation and reactivation of herpes simplex virus. The estimated cost per patient in the USA is \$30 000/year, the cost in the UK has been negotiated with the NHS but has not been published.

Nemolizumab is a newer biological agent that is still undergoing phase III clinical trials, but early results are promising for the treatment of moderate to severe AD. Its mode of action is to block interleukin-31, preliminary studies show a rapid onset of action with a reduction in pruritus score of 30% within one week and 80% reduction by week 64. The optimal dose appears to be 0.5 mg/kg every four weeks in adults. The price is currently not known but estimates are that it will cost around £30 000/year.

Oral JAK inhibitors are in phase III studies but initial results look promising. Upadacitinib 30 mg OD leading to 70% achieved an EASI 75% score at 16 weeks, with a significant reduction in pruritus. *Topical JAK inhibitor* Tofacitinib reduced EASI scores by 82% at week 4 (vs 30% placebo). These preparations were very well tolerated.

Oral apremilast (PDE4 inhibitor) in phase II studies initial results are disappointing with about 40% reduction in EASI at 12 weeks.

Pruritus

Pruritus is a term used to describe itching of the skin that is an unpleasant sensation that triggers rubbing or scratching. The sensation of pruritus can be extremely disturbing, leading to disrupted sleep and even depression. Pruritus may be localised/generalised and may be associated with skin changes or with normal skin.

Pruritus with skin changes

Pruritus may be localised or generalised.

Causes of localised pruritus with skin changes include eczema, psoriasis, lichen planus (flat-topped itchy papules of unknown cause), dermatitis herpetiformis (gluten allergy with rash, characteristically on elbows and buttocks), insect bites/stings (nodular prurigo may develop after insect bites and is characterised by persistent itching, lichenified papules and nodules), head lice, contact dermatitis, polymorphic light eruption (an acute allergy to sunlight on sun-exposed skin), urticaria or angioedema ('hives' with swelling, especially of the face), fungal infections (particularly tinea pedis of the feet), pruritus ani (perianal itching, a common condition that may result from anal leakage, skin tags, haemorrhoids, thread worms, excessive washing, the use of medicated wipes or allergy to haemorrhoid creams containing Balsam of Peru), and pruritus vulvae (intense itching may result from lichen sclerosus et atrophicus, *Candida* infections or eczema).

Generalised pruritus with skin changes occurs in more widespread inflammatory skin diseases such as widespread eczema/psoriasis, scabies, allergic drug eruptions (antibiotics and anticonvulsants), graft versus host disease (following bone marrow transplantation), pre-bullous pemphigoid (dermatitic eruption before blisters appear), cutaneous lymphoma (may start over the buttocks as more localised disease), parasitophobia (belief that there are parasites under the skin, excoriations are seen), body lice or pubic lice (body lice live in the clothing), viral exanthems (rashes associated with systemic viral illness), urticaria (generalised 'hives') and xerosis (dry skin, especially in the elderly).

Investigation and management of pruritus with skin changes should be directed at the suspected underlying cause.

Pruritus with normal skin

Medical practitioners need to be alert to the patient with generalised pruritus and normal skin as itching may be the first symptom of a systemic disorder such as Hodgkin's disease, chronic renal failure and diabetes, or may be a side effect of medication.

Systemic Causes

- Endocrine – diabetes, myxoedema, hyperthyroidism, menopause, and pregnancy.
- Metabolic – hepatic failure, biliary obstruction, and chronic renal failure.
- Haematological – polycythaemia and iron deficiency anaemia.
- Malignancy – lymphoma, leukaemia, myeloma, and carcinomatosis.
- Neurological/psychological – neuropathic pruritus, multiple sclerosis, and anxiety.
- Infection – filariasis, hookworm, and human immunodeficiency virus (HIV).
- Drugs – opioids.

Investigations (Pruritus with Normal Skin)

- Full blood count, erythrocyte sedimentation rate, liver, and renal function.
- Serum iron, ferritin, and total-iron binding capacity.
- Thyroid function and fasting glucose.
- Serum protein electrophoresis.
- HIV antibody.
- Urine analysis.
- Stools for blood and parasites/ova.
- Chest X-ray.
- Skin biopsy for direct immunofluorescence.

Management of pruritus

Identifying and treating the underlying cause of the pruritus is obviously desirable whenever possible. Patients themselves will find some short-term relief by scratching the skin, but this ultimately leads to further itching and scratching, the so-called 'itch-scratch cycle'. To break this cycle the sensation of itch needs to be suppressed, or the patient's behaviour changed by habit reversal techniques.

Individuals can purchase simple soothing emollients over the counter and apply these frequently to the pruritic areas. The soothing effect can be enhanced by storing the cream in the fridge and applying them cold. Menthol 1–2% in emollient cream and calamine possess

cooling and antipruritic properties. Camphor-containing preparations and crotamiton (Eurax) and topical doxepin hydrochloride applied thinly three to four times daily to localised areas may provide relief from itching.

Topical local anaesthetics (containing benzocaine, lidocaine, or tetracaine) on sale to the public may give some temporary relief but intolerance may develop and allergic reactions can occur.

Topical and systemic antihistamines can provide relief from itching. Topical antihistamines (mepyramine and antazoline) are on sale to the public in various formulations which may give temporary relief to localised areas. Generally, non-sedating oral antihistamines are given during the day and sedating ones at night. Cutaneous itch responds readily to the histamine H1 blockers cetirizine, levocetirizine, desloratadine, and fexofenadine during the day and hydroxyzine at night. H2 blockers (ranitidine and cimetidine) may be used in addition to H1 blockers in resistant cases.

Pruritus ani/vulvae

The affected area should be washed once daily; excessive washing should be avoided. Emulsifying ointments can be used as a soap substitute. Patients should avoid perfumed/coloured/medicated toilet tissue or wipes. Simple paraffin or zinc cream can be used as a barrier ointment to prevent skin irritation from anal leakage/vaginal discharge. Weak topical steroids can help reduce inflammation and itching. If symptoms persist, patients should see a dermatology specialist who may do patch testing (contact dermatitis) or perform a skin biopsy (neoplasia, lichen sclerosus, or lichen planus).

Further reading

Rudikoff, D., Cohen, S.R., and Scheinfeld, N. (2014). *Atopic Dermatitis and Eczematous Disorders*. CRC Press.

CHAPTER 5

Urticaria and Angio-oedema

Rachael Morris-Jones

Guy's and St Thomas' NHS Foundation Trust, London, UK

OVERVIEW

- Definition and pathophysiology; the role of vasodilators.
- Classification.
- Clinical presentation of different types of urticaria.
- Causes and investigation of non-physical urticarias.
- Management and treatment.

Introduction

Urticaria describes transient pruritic swellings of the skin, often referred to as wheals, hives, or nettle rash by the patient. Urticaria results from oedema in the superficial layers of the skin causing well-demarcated erythematous lesions. It may be associated with allergic reactions, infections, or physical stimuli, but in most patients no cause can be found. Similar lesions may precede or be associated with vasculitis (urticarial vasculitis), pemphigoid, or dermatitis herpetiformis.

Angio-oedema in contrast is usually painful rather than itchy and appears as a diffuse swelling that affects the deeper layers of the skin; it can occur rapidly and may involve the mucous membranes. Laryngeal oedema is the most serious complication and can be life-threatening. Hereditary angio-oedema is a rare form with recurrent severe episodes of subcutaneous oedema, swelling of the mucous membranes, and systemic symptoms.

Urticaria is a common skin disorder that affects 20% of the population at some point in their lives. Urticaria may occur as a single episode or be chronically recurrent. It is often self-limiting and is controlled with antihistamine. The prognosis is varied depending on the underlying cause, but in chronic spontaneous urticaria (CSU) symptoms may persist for several years.

Pathophysiology

Urticaria results from histamine, bradykinin, and pro-inflammatory mediators being released from basophils and mast cells in response to various trigger factors. The chemicals released

by degranulation cause capillaries and venules to leak causing tissue oedema. Urticaria may be immunoglobulin E (IgE) mediated with cross-linking of two adjacent IgE receptors, or complement-mediated (causing direct degranulation of mast cells), or mast cells may be directly stimulated by an exogenous or unknown substance. In patients with chronic urticaria, histamine can be released spontaneously or in response to non-specific stimuli and their vasculature is more sensitive to histamines.

Clinical history

Careful history-taking is of great importance in diagnosing patients with urticaria and/or angio-oedema because frequently there are no clinical signs for the medical practitioner to see. Ask about the onset, duration, and course of lesions, rashes, and swelling. Urticaria is very itchy and angio-oedema usually painful. Patients with urticaria complain of itchy spots or rashes lasting minutes or hours (usually less than 24 hours) that resolve leaving no marks on the skin. Patients may complain of swelling (angio-oedema) of their face, particularly eyelids, lips, and tongue, which may last hours or days.

If the skin eruption lasts for more than 24 hours, is painful and resolves with bruising then urticarial vasculitis ([Figure 5.1](#)) is more likely than ordinary urticaria ([Figure 5.2](#)).

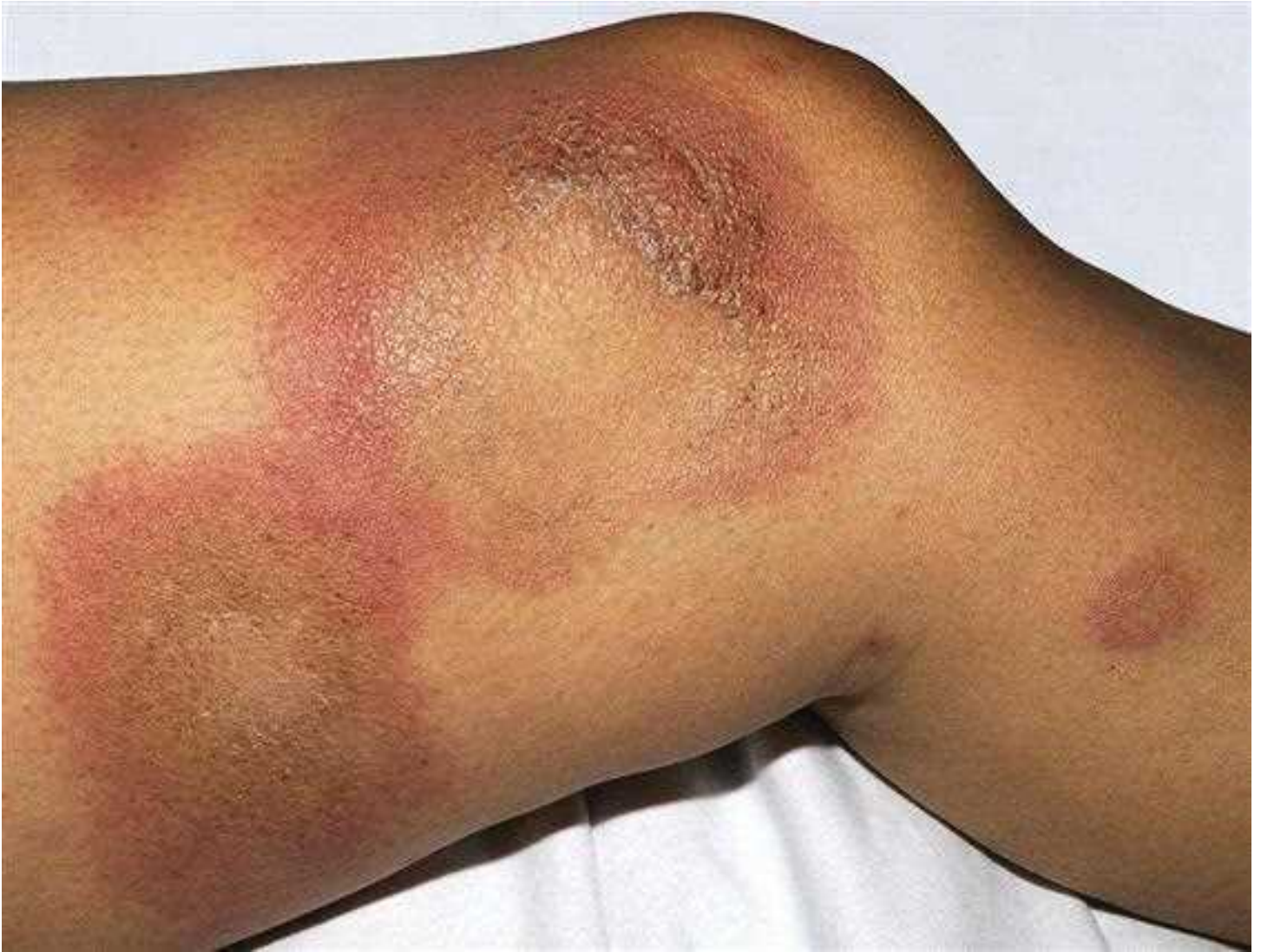

Figure 5.1 Urticarial vasculitis with bruising.

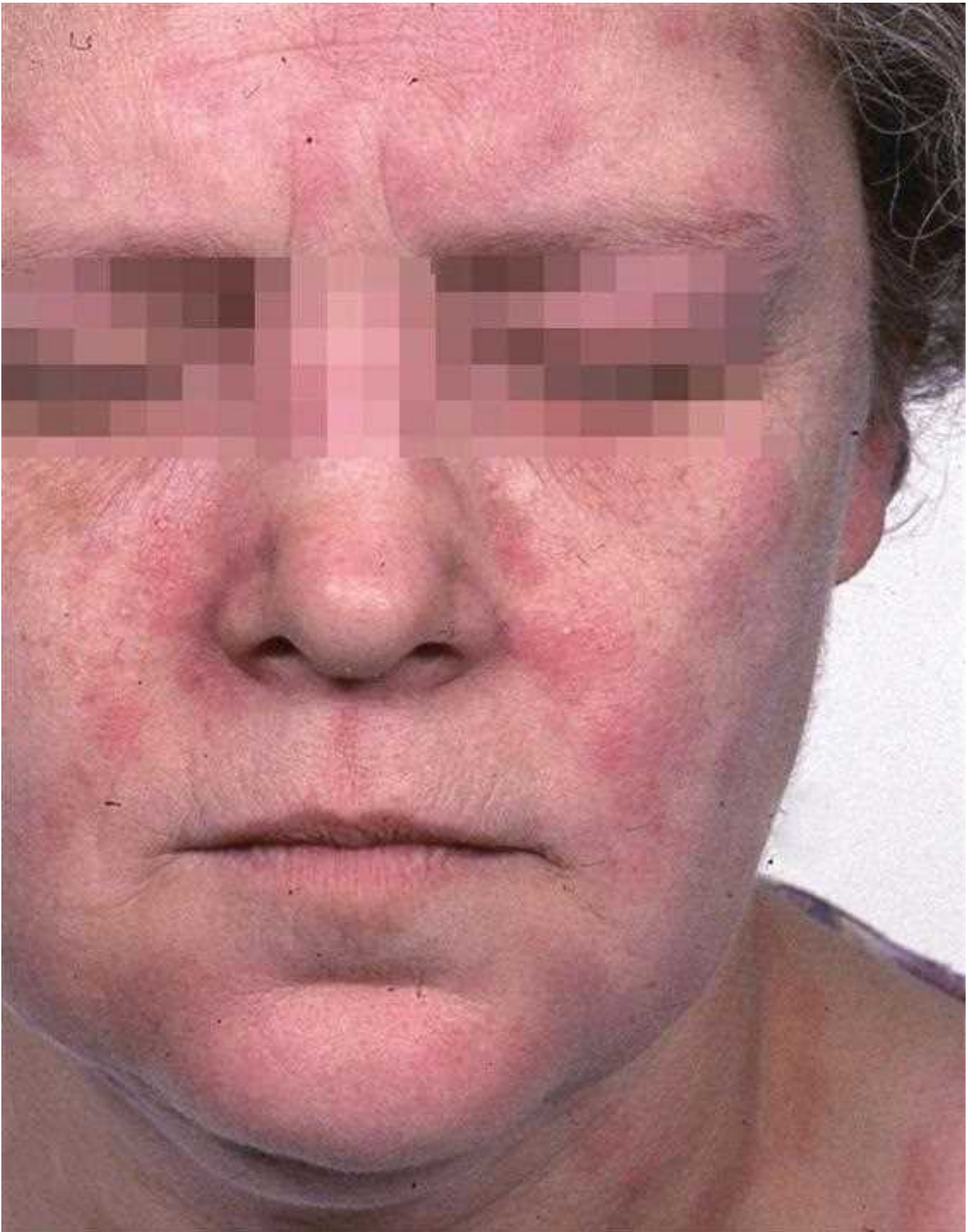

Figure 5.2 Ordinary urticaria.

Patients may feel unwell before the onset of the rash or swelling and rarely in severe reactions anaphylaxis can occur. You should always ask about any associated respiratory distress. An attempt to identify possible triggers before the onset of symptoms is important. In particular, ask about any food eaten (nausea/vomiting), exercise, heat/cold, sun, medications/infusions, latex exposure, insect stings, animal contact, physical stimuli, infections, family history, and any known medical conditions ([Figures 5.3](#) and [5.4](#)).

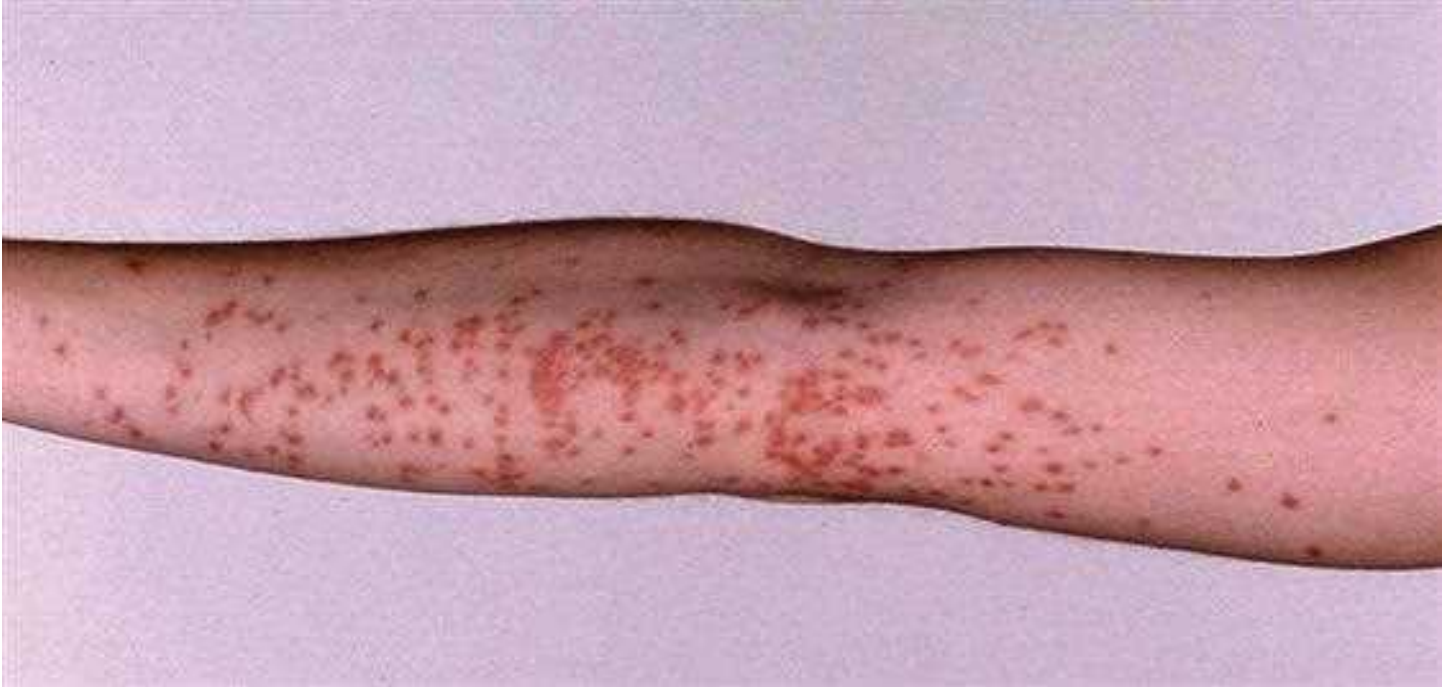

Figure 5.3 Urticaria from contact with brown caterpillar moths.

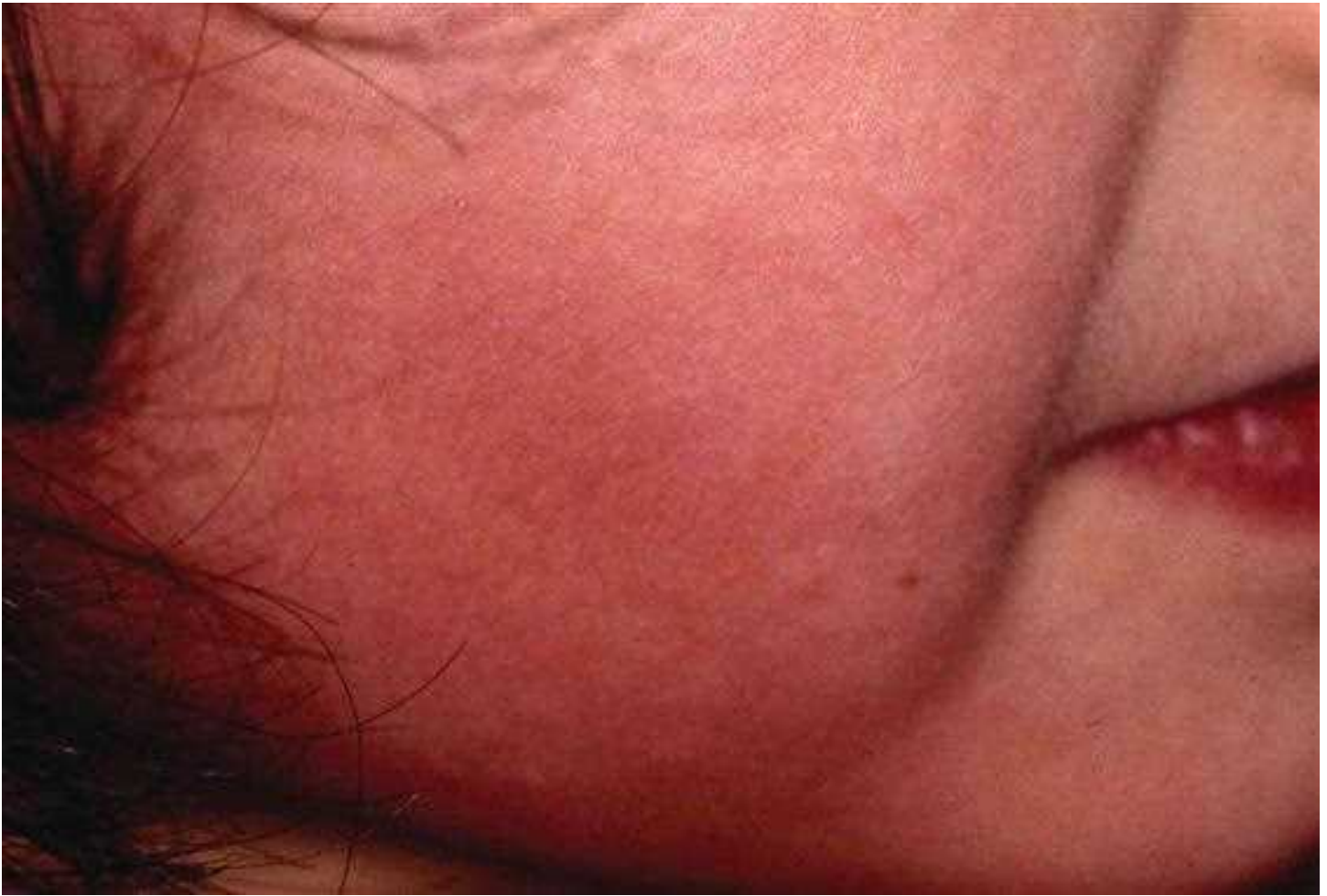

Figure 5.4 Cold-induced urticaria on the cheeks.

Classification of urticaria

Urticaria is traditionally classified as acute or chronic depending on whether symptoms last for less or more than six weeks. Another approach is to classify urticaria according to the underlying cause, but in 50% of cases no cause is identified (idiopathic). Urticaria can therefore broadly be divided into ordinary/idiopathic (acute/chronic), contact allergic, cholinergic, physical, or urticarial vasculitis. See [Boxes 5.1](#) and [5.2](#).

Box 5.1 Causes of non-physical urticaria

- Food allergies: fish, eggs, dairy products, nuts, and strawberries
- Food additives: tartrazine dyes and sodium benzoates
- Salicylates: medication and foods
- Infections: viral, bacterial, and protozoal
- Systemic disorders: autoimmune, connective tissue disease, and carcinoma
- Contact urticaria: meat, fish, vegetables, and plants
- Papular urticaria: persistent urticaria often secondary to insect bites
- Aeroallergens: pollens, house dust mite, and animal dander

Box 5.2 Causes of physical urticaria

- Heat
- Sunlight
- Cold
- Pressure
- Water

Ordinary urticaria

This is the most common form of urticaria, characterised by intermittent fleeting wheals at any skin site, with or without angioedema ([Figures 5.2](#) and [5.5](#)). Lesions may be papular, annular ([Figure 5.6](#)) and even serpiginous. The urticarial lesions themselves last minutes to hours only and may recur over <6 weeks – acute urticaria, or attacks may become chronic (>6 weeks). In 50% of patients with ordinary urticaria no underlying cause is found. Possible triggers of acute urticaria include infections, vaccinations, medications, and food. Generally, the more persistent the attacks of urticaria, the less likely that an underlying cause is identified; this is termed *chronic spontaneous urticaria*.

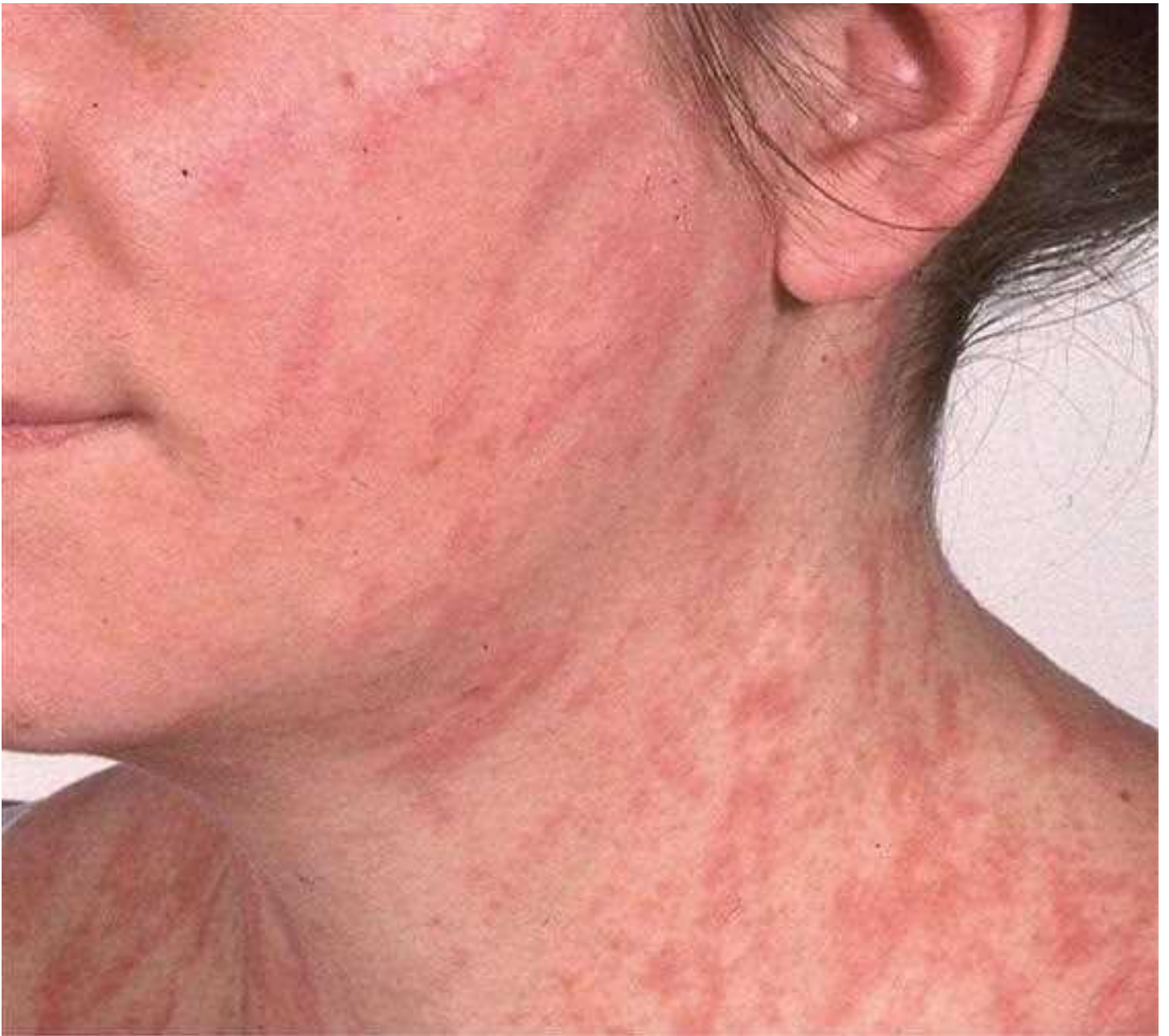

Figure 5.5 Ordinary urticaria with dermatographism.

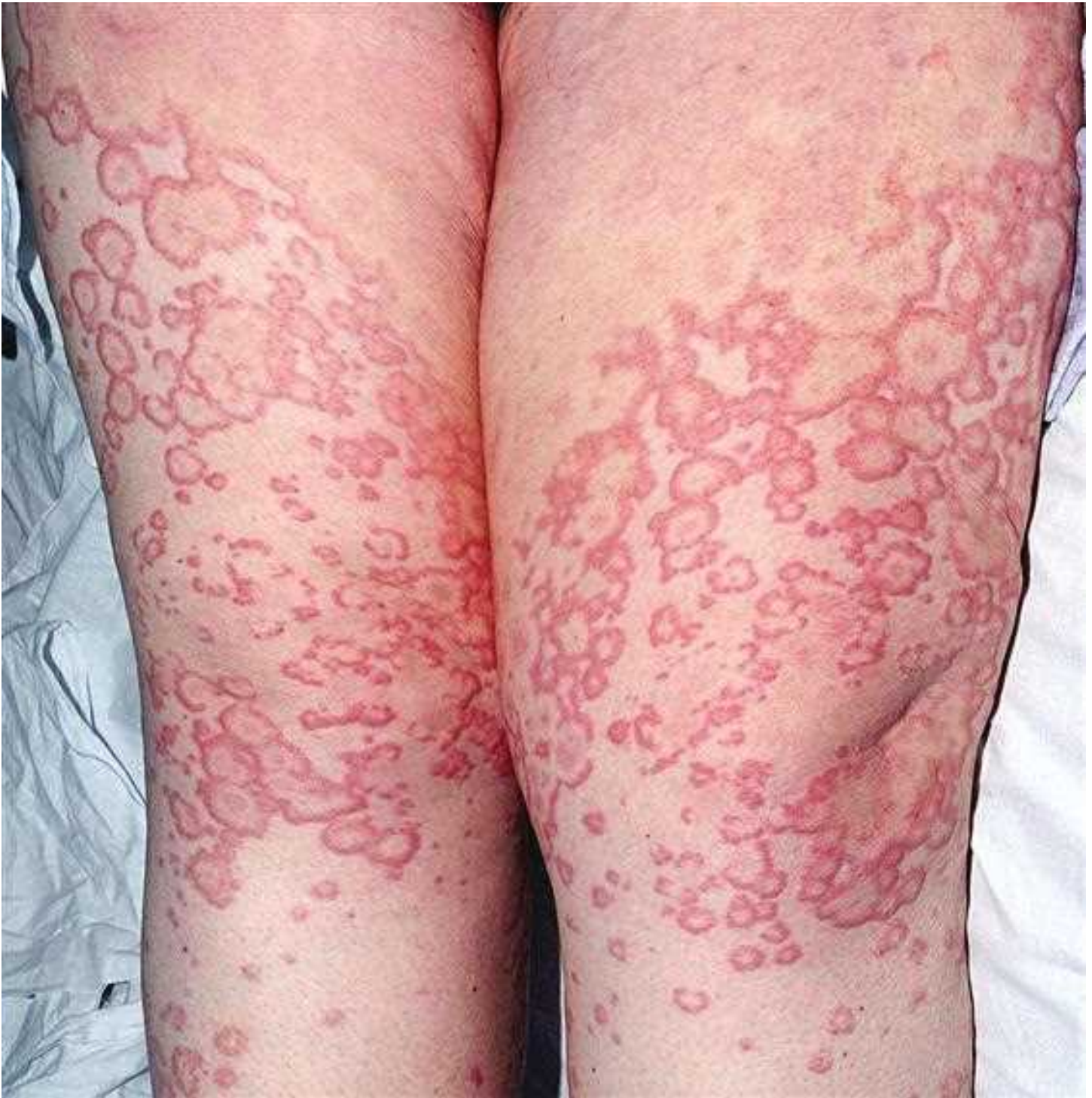

Figure 5.6 Annular urticaria.

Cholinergic urticaria

Patients are usually aged 10–30 years and typically experience urticaria following a warm shower/bath, or after exercise. Patients report erythema and burning pruritus followed by extensive urticaria. The lesions consist of pinhead-sized wheals with a red flare around them. The underlying trigger is not fully understood, but deficiency in α_1 -antitrypsin may predispose to urticaria in which sweat has been shown to play a role and where serum

histamine levels are raised following exertion. Avoidance of heat usually helps reduce the frequency and severity of symptoms.

A rarer form of cholinergic urticaria can result from exposure to the cold. Patients report urticaria on exposed skin during cold weather, lip/tongue/hand swelling following the holding and ingestion of cold beverages and a more generalised reaction following swimming in an outdoor pool. Affected individuals should avoid swimming in cold water and ingestion of ice-cold drinks as anaphylaxis and death have been reported.

Solar urticaria

Solar urticaria is a rare condition in which sunlight causes an acute urticarial eruption. Patients complain of stinging, burning, and itching at exposed skin sites within 30 minutes of ultraviolet or artificial light source exposure. Lesions resolve rapidly (minutes to hours) when light exposure ceases. Photosensitive drug eruptions can present in a similar manner; so, a detailed drug history is important. Differential diagnosis may include porphyria (lesions resolve with scarring) and polymorphic light eruption (lesions take days to weeks to resolve). The pathophysiology is poorly understood but is thought to be mediated by antigen production as serum transfer can induce similar symptoms in asymptomatic controls. Light-testing confirms the diagnosis. Management can be challenging but avoidance of sunlight is helpful.

Pressure urticaria

Urticarial wheals occur at the site of pressure on the skin, characteristically around the waistband area (from clothing), shoulders (from carrying a backpack), soles of feet (from walking), hands (using tools or weight lifting), buttocks (from sitting), and genitals (sexual intercourse). The urticarial rash may occur immediately but a delay of up to six hours can occur (delayed pressure urticaria), and lesions resolve over several days. Symptoms are usually recurrent over many years. The cause is unknown and although histamine is thought to play a role, patients are less likely to respond to antihistamines than in other forms of urticaria. Eosinophils and interleukin are thought to play a role. Investigation can include pressure challenge testing. Patients may respond to dapsone or montelukast.

Angio-oedema

Patients present with swelling plus or minus urticaria that develops over hours and resolves over days. Angio-oedema causes well-demarcated swelling of the subcutaneous tissues ([Figure 5.7](#)) and/or mucous membranes, from increased vascular permeability. A detailed drug history should be taken because allergy to medication (angiotensin-converting enzyme inhibitors, non-steroidal anti-inflammatory drugs, bupropion, statins, or proton pump inhibitors) may be the cause. Laryngeal swelling is the most serious complication and should ideally be managed by emergency medicine specialists.

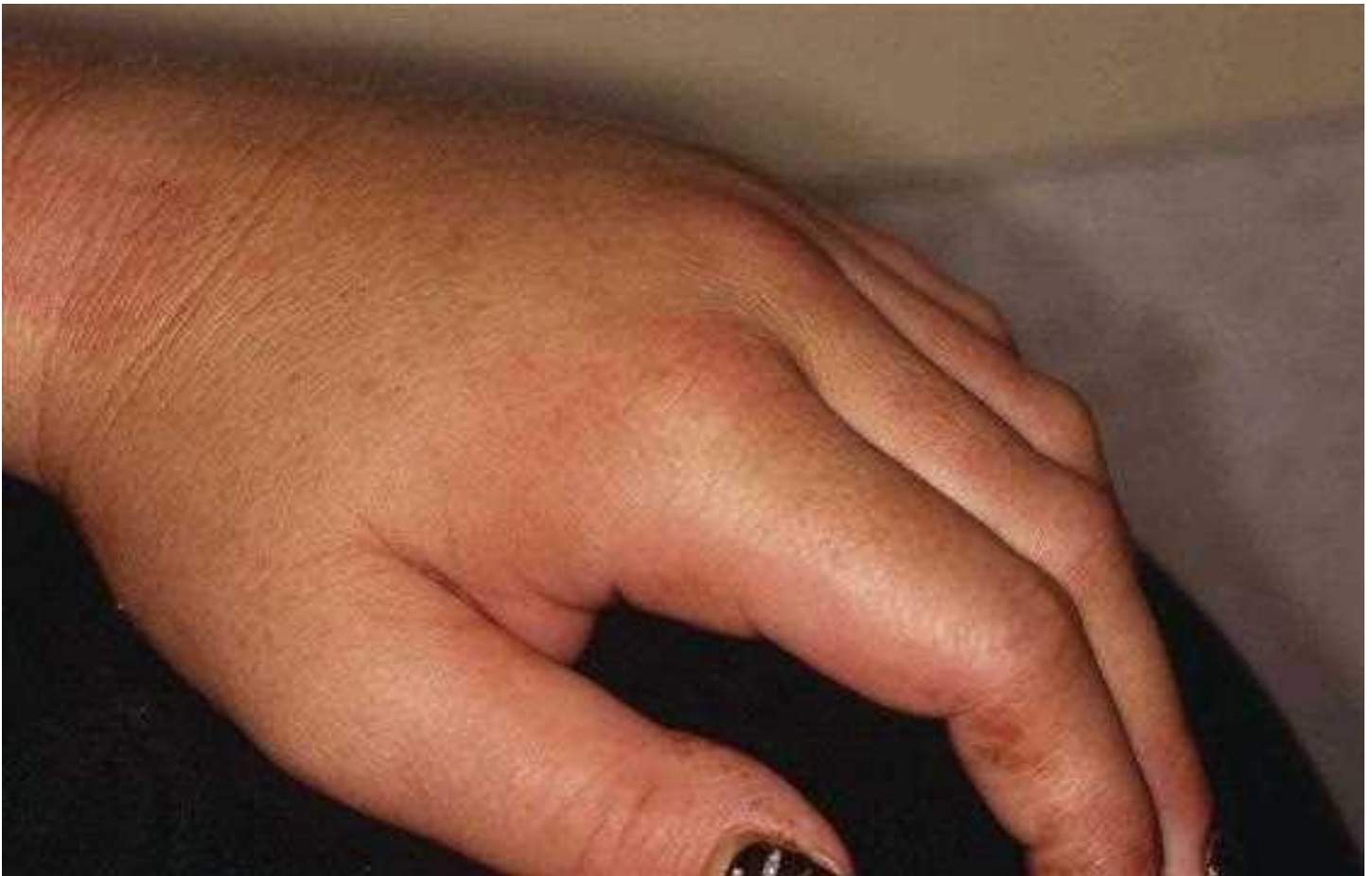

Figure 5.7 Angio-oedema of the hand.

A hereditary form of angio-oedema presents in young persons as recurrent severe attacks affecting the skin and mucous membranes. Tingling, tightness, and pain are the main symptoms associated with the oedema. Patients may suffer associated gastrointestinal symptoms and life-threatening laryngeal oedema. Hereditary angio-oedema is caused by a deficiency in C1 (esterase) inhibitor. Serum complement C4 levels are low following attacks. Danazol can be used to reduce the frequency and severity of attacks and fresh frozen plasma can be used before elective surgery.

General investigations

Apart from a detailed history and examination most patients need no further investigations. If food allergy is suspected, patients can be asked to keep a food diary, particularly if their urticaria is recurrent and episodic. An attempt to elicit dermatographism (exaggerated release of histamine causing wheal and flare) should be made by firmly stroking the skin with a hard object such as the end of a pen; this is usually positive in physical urticaria ([Figure 5.8](#)).

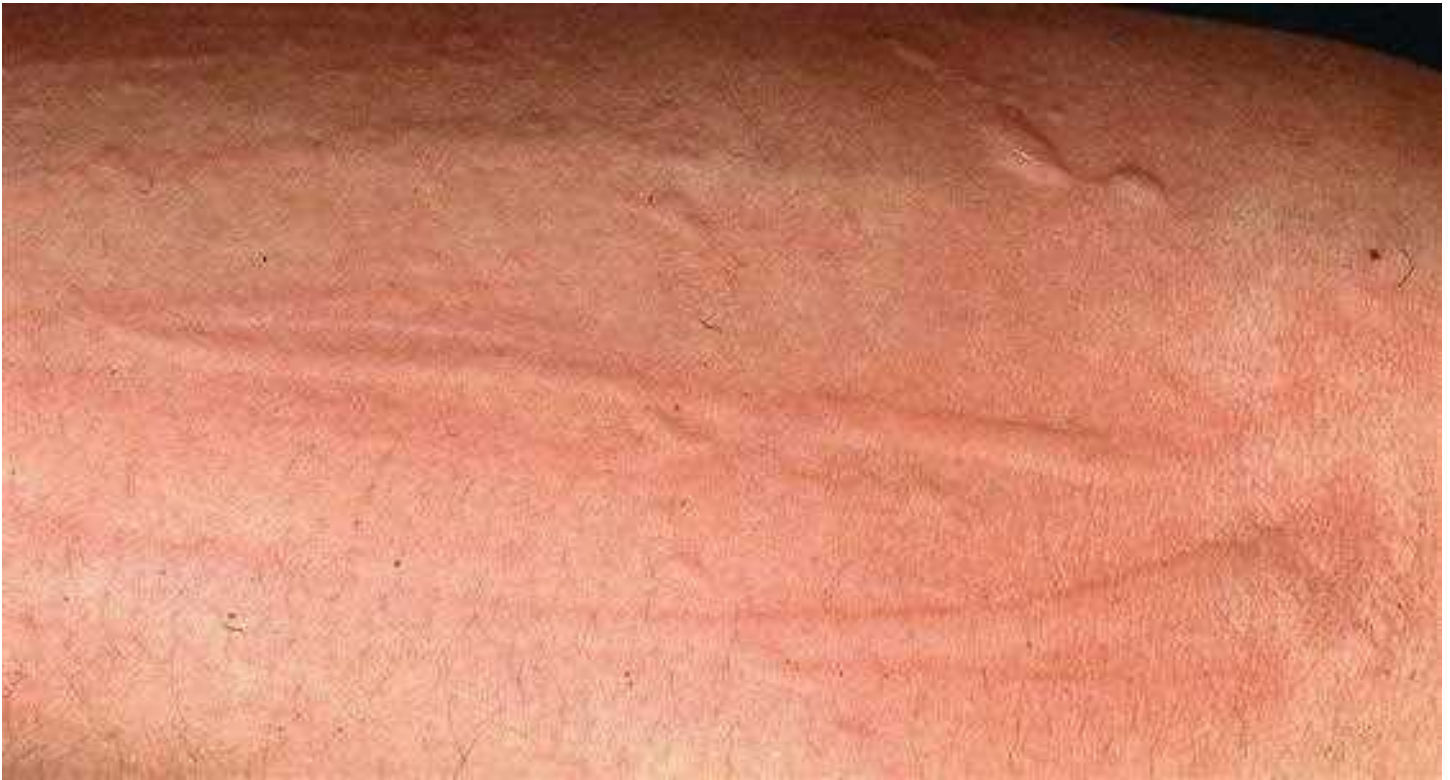

Figure 5.8 Dermatographism.

A skin biopsy can be useful if urticarial vasculitis is suspected; plain lidocaine should be used for the local anaesthetic (as adrenaline causes release of histamine from mast cells). Histology from urticaria may show dermal oedema and vasodilatation. In urticarial vasculitis, there is a cellular infiltrate of lymphocytes, polymorphs, and histiocytes.

In patients with more severe reactions to e.g. suspected foods then allergen-specific IgE antibodies should be checked or skin prick testing (although not in patients with anaphylaxis) may help identify specific allergies. In addition, immediate type I hypersensitivity patch testing to identify contact urticaria can be undertaken in specialist centres.

If you suspect hereditary angio-oedema, check the complement C3 level and C1 esterase which are usually low.

If heat or cold are the possible precipitants then exercising for 5 minutes or placing an ice-cube on the skin for 20 minutes may be diagnostic. Physical urticaria can be elicited by firm pressure on the skin (dermographism/dermatographism). Solar urticaria can be assessed in specialist centres using a solar simulator.

General management

Patients often make their own observations concerning trigger factors, especially food, medication and insect stings, and know what they should try to avoid. Treatment of any underlying medical condition identified should help settle the urticaria. Oral antihistamines are the mainstay of treatment/prevention of urticaria and angio-oedema. Patients can manage their own symptoms by purchasing antihistamines (cetirizine, loratadine, or chlorphenamine)

over the counter.

In severe recalcitrant cases, physicians may need to prescribe high doses (two to four times the usual dose) of a single agent such as fexofenadine 180 mg (age 11 years and above, age 2–11 years 30 mg twice daily) or synergistic combinations of H1-receptor blockers (as above plus desloratadine, levocetirizine, terfenadine, or hydroxyzine) plus H2 blockade (ranitidine or cimetidine) and leukotriene receptor antagonists (montelukast or zafirlukast) to control symptoms. Depending on the frequency of symptoms, antihistamines may be taken prophylactically daily or intermittently to treat symptoms.

During pregnancy chlorpheniramine, loratadine, or cetirizine are thought to be safe.

Oral corticosteroids may be indicated in very severe eruptions, particularly those associated with urticarial vasculitis or angioedema. However, in studies, oral prednisolone did not add any benefit to antihistamines in reducing the duration of the urticaria.

Patients known to be at risk of severe life-threatening urticaria/angio-oedema with respiratory distress may be asked to carry with them a pre-assembled syringe and needle (EpiPen® or Anapen®) to inject adrenaline intramuscularly (300–500 µg). Management of the patient's airway is critical and once secured, oxygen and if necessary further intramuscular/intravenous adrenaline can then be administered by medical professionals.

Phase III clinical trials of 150 mg subcutaneous injection of omalizumab every 2–4 weeks for 9–12 months have shown encouraging results in patients whose urticaria is recalcitrant to the effects of H1-blockers. For both CSU and chronic inducible urticaria (CindU) the drug appears to be effective. Omalizumab treatment led to complete remission in 83% of CSU and 70% of CindU) at about nine months, some patients symptoms stopped after the first dose and some patients were found to be in remission when the drug was stopped.

Further reading

<http://www.allergy-clinic.co.uk/urticaria>

Kartal, S.P. and Kutlubay, Z. (2017). *A Comprehensive Review of Urticaria and Angioedema*. InTechOpen.

Zuberbier, T., Grattan, C., and Maurer, M. (2010). *Urticaria and Angioedema*. Heidelberg: Springer.

CHAPTER 6

Skin and Photosensitivity

John S. Ferguson

St John's Institute of Dermatology, Guy's and St. Thomas' Hospitals, London, UK

OVERVIEW

- The study of the effects of non-ionising radiation on the skin is called Photodermatology.
- Ultraviolet wavelength photons damage DNA directly and generate 'reactive oxygen species' which do indirect damage to DNA, RNA, amino acids, protein, and lipids. This damage provokes both acute and chronic changes in the skin.
- Less pigmented skin types are more susceptible to sunburn, but any individual can be sunburnt if exposed to enough UV.
- Chronic sun exposure leads to 'sun damage' and sometimes skin cancer ([Chapters 22 and 23](#)).
- Genetic disorders: albinism and xeroderma pigmentosum patients are particularly vulnerable to UV light.
- Photoprotection: behaviour, clothing, and sunscreen are of particular importance for individuals with photosensitive and photoaggravated cutaneous disease.

Ultraviolet radiation

Ultraviolet radiation (UV) comprises 5% of all light penetrating the earth's atmosphere; 95% is visible and infrared ([Figure 6.1](#)). Ultraviolet A (UVA) and ultraviolet B (UVB) wavelengths are known to play a role in sun-induced skin damage. UVC is filtered out by the ozone layer. UV intensity is greatest near the equator and at high altitudes. Other environmental factors such as the season, weather, and time of day also influence intensity. UV is reflected by water (15%), snow (80%), and sand (25%).

Ultraviolet makes up 5% of sunlight

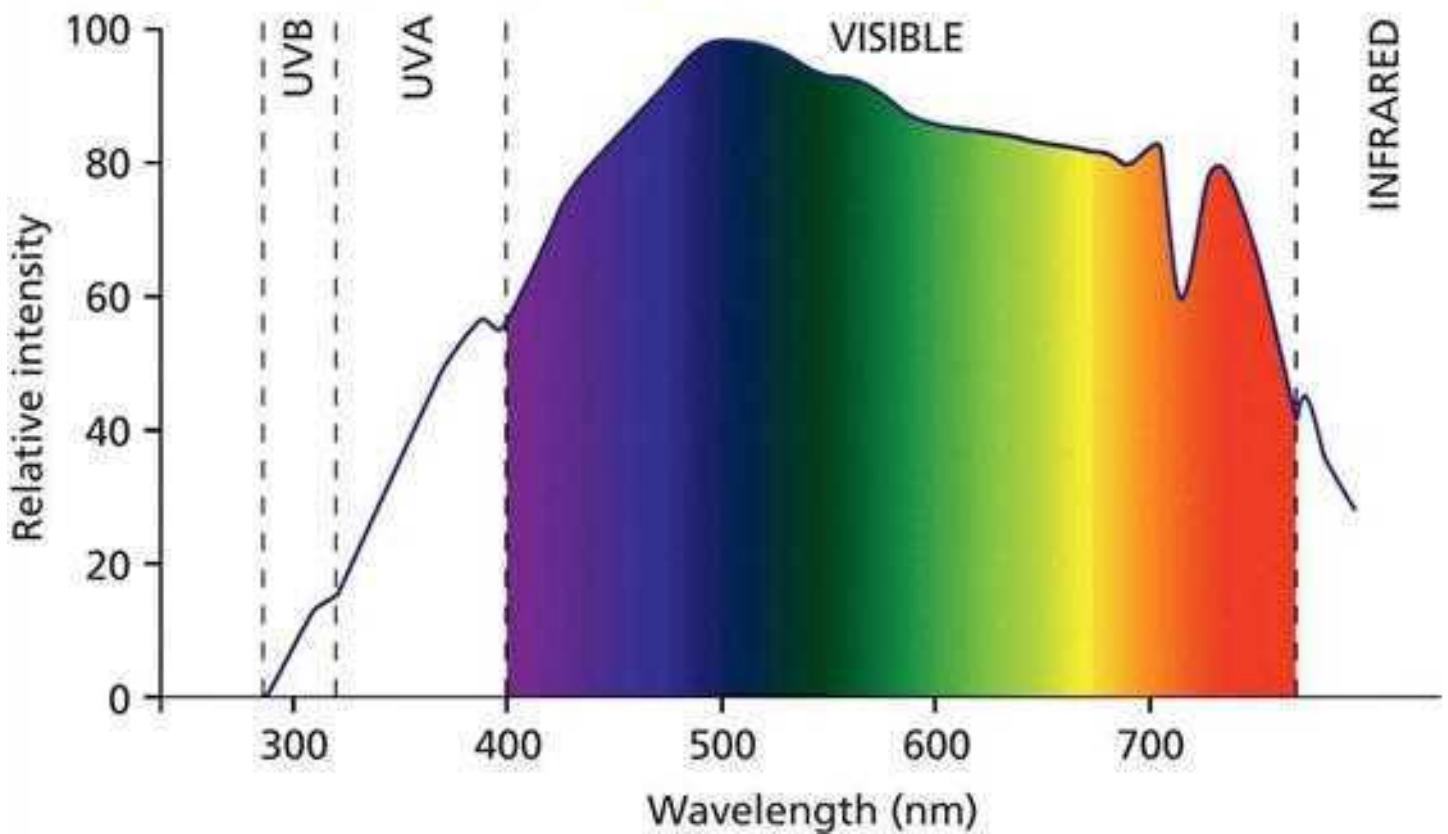


Figure 6.1 Non-ionising, visible, and infrared radiation.

Source: Reprinted with permission (R. Sarkany [2017](#)).

UVA photons have a longer wavelength (315–400 nm) and a lower energy. They can penetrate more deeply into skin. UVA is present all year round and throughout the day at constant levels. UVA can pass through glass and is important in skin tanning responses. UVA can produce ‘reactive oxygen species’ which cause DNA, RNA, amino acid, protein, and lipid damage.

UVB photons have a shorter wavelength (280–315 nm) and carry a high energy. When UVB hits the DNA it causes mutations which can lead to keratinocyte apoptosis. When this occurs in multiple keratinocytes at the same time we call the ensuing inflammation ‘sunburn’. Some UVB-induced damage will be repaired, but ultimately the accumulated mutations in cutaneous stem cells are the main cause for skin cancer.

UVC (100–280 nm) photons don't occur naturally on the earth's surface but they have a very short wavelength and are highly damaging to all cellular life, including human skin.

UV A and B wavelength light is used therapeutically for many common skin problems such as psoriasis and eczema. This is because of cutaneous immunosuppression caused by UVB and UVA light. UVC is also used in the sterilisation of water and other cleaning techniques.

Skin pigmentation and fitzpatrick skin type

Our skins' physiological tolerance of UV light depends on several factors, including UV intensity, skin colour, and previous skin hardening. Fitzpatrick skin type was developed in 1975 by Thomas Fitzpatrick as a way of categorising the variance in normal cutaneous responses to light among Caucasian and Hispanic patients. It relies upon assessing the related tendencies of patients to burn and tan. Initially, only four lighter skin types were included, but later darker skin types – 5 and 6 – were added. It has been shown that dermatologist assessed Fitzpatrick skin type corresponds to pigmentation in the skin and tendency to burn. Skin type also correlates with skin cancer risk and can be used to determine starting doses for patients having phototherapy. Patients with red hair almost always have skin type 1; skin type 6 is usually a dark shade of brown. The redder pigment, pheomelanin, is less good at absorbing UVB radiation and free radicals than the browner eumelanin. Type 1 skin patients are at a much higher risk of skin cancer than patients with darker skin types. Skin type 6 gives protection from UVB equivalent to a Sun Protection factor (SPF) of 14.

Box 6.1 Determining skin type: questions to ask patients in clinic

Question 1: If after several months of not being in the sun, you stayed outdoors for about one hour at noon for the first time in the summer without sunscreen, what would happen to your skin? Would it become pink/red, irritated, tender, or itchy?

Question 2: Over the next seven days, would you develop a tan or notice your skin becoming darker?

| Skin Type | Reaction | Typical Responses to Q1 and 2 |
|-----------|--|--|
| I | Always burns, never develops a tan | Painful burn at 24 h and no tan at 7 d |
| II | Slightly tender, easily burns, then develops a light tan | Painful burn at 24 h and a light tan at 7 d |
| III | Mild burning, skin irritation, tenderness, or itching in sun-exposed skin, then develops a medium tan or skin becomes slightly darker in sun-exposed sites | Itching at 24 h, moderate tan or slightly darker at 7 d |
| IV | Minimal skin irritation, tenderness, or itching in sun-exposed skin, then develops a deep tan or skin becomes darker in sun-exposed sites | No skin irritation, tenderness, or itching at 24 h and a tan or darker skin at 7 d |
| V | Occasional skin irritation, tenderness, or itching in sun-exposed skin, then develops darker skin in sun-exposed sites in temperate climates | <i>a</i> |
| VI | No skin irritation, tenderness, or itching in sun-exposed skin, no noticeable change in skin in sun-exposed sites in temperate climates | <i>a</i> |

*a*Further close questioning is required to discriminate between darker skin types.

Oculocutaneous albinism

Genetic mutations that control melanin synthesis, distribution, and degradation result in a group of inherited disorders that lead to loss of skin/hair/eye pigment. Oculocutaneous albinism is an autosomal recessive condition characterised by little or absent melanin pigment at birth. Oculocutaneous albinism affects skin, hair, and ocular pigmentation,

resulting in sun-induced skin changes, photophobia, nystagmus, and reduced visual acuity.

Oculocutaneous albinism is traditionally classified into two groups – tyrosinase positive or negative – depending on whether the enzyme is absent or dysfunctional; however, there are numerous subtypes depending on the specific genetic mutation. Affected individuals should be assessed in the neonatal period by a dermatologist and an ophthalmologist. The family may wish to consult a geneticist. Protective clothing and sun avoidance behaviour is vital. A sunscreen blocking UVA and UVB light (broad-spectrum) should be applied to the skin daily lifelong. Vitamin D replacement will probably be necessary. Skin checks for evidence of sun-damage or skin cancer should be undertaken regularly.

Other genetic conditions associated with loss of skin pigment include piebaldism, phenylketonuria, tuberous sclerosis, and Waardenburg and Apert syndromes.

The photodermatoses

The photodermatoses comprise photosensitive and photoaggravated conditions. Both can cause abnormal responses to ultraviolet, and sometimes visible, wavelengths of light. Most photosensitive dermatoses are abnormal immune responses triggered by UV and sometimes visible light. They include polymorphous light eruption (PMLE), actinic prurigo, chronic actinic dermatitis (CAD), solar urticaria, and hydroa vacciniforme. Some photosensitive reactions are caused by phototoxicity from, drugs, plants, or metabolites, as in porphyria. Some photodermatoses are caused directly by genetic defects as in xeroderma pigmentosum. Others are photoallergic, as in photo-contact dermatitis.

Photoaggravated dermatoses are skin conditions that can be made worse by the exposure of skin to UV light. e.g. cutaneous lupus erythematosus, dermatomyositis, herpes simplex, Darier's disease, pellagra, and some cases of rosacea and eczema. Some of these conditions are mentioned elsewhere in this book. Although precancerous and cancerous skin lesions are also caused by UV light these are discussed in detail in other chapters ([Chapters 22](#) and [23](#)).

History and clinical examination

If a patient is suspected of having a photodermatosis it is important to take a history of the problem and its relationship to sun exposure. Patients may not develop symptoms unless they are exposed to intense sun while others may be affected even on days with a low UV index. Ask about seasonal variation and whether they get symptoms through window glass. Try and elicit the time to onset of symptoms following UV exposure, their duration and frequency. It is important to ask whether any scarring or surface change are left behind following the acute phase. Is their skin painful, burning, or itchy? Do they have a background of previous skin disease?

On examination, usually sun-exposed skin is predominately affected, particularly the face, neck, dorsi of arms and hands and, the lower legs. There is often, but not always, sparing of sun-protected sites, particularly the buttocks, behind the ears, and under the chin. A classically spared site, suggestive of a photo dermatosis, is beneath a watch strap.

Xeroderma pigmentosum

Xeroderma pigmentosum (XP) comprises a group of autosomal recessive conditions resulting in dysfunctional nucleotide excision repair proteins. These highly conserved genes are present in all living cells. The proteins they code for facilitate the repair of our genetic code.

Xeroderma pigmentosum patients usually present in the first two years of life with delayed onset but persistent and severe sunburn responses. The patients quickly start to show signs of accelerated cutaneous UV damage characterised initially by premature freckling, then later poikiloderma, skin ageing, and early tumour formation. Sometimes skin cancers begin to develop in the first decade of life and as affected patients age they often develop multiple skin cancers, including melanomas, squamous, and basal cell carcinomas. Life expectancy is reduced. Ophthalmic problems include photophobia, keratitis, xerosis, corneal opacification, and pterygium formation. Neurological features can include mental retardation deafness and ataxia. XP is rare, affecting around 1 in 250 000 people.

Management for these patients remains focused on early diagnosis and strict sun avoidance. Photoprotective clothing, broad-rimmed hats, sunglasses, and broad-spectrum sunscreens should be regularly used. Support for the patient's parents and advice on how they should engage with schools is vital. The XP website can be a useful source of information and community for XP sufferers (<http://xpsupportgroup.org.uk>).

In the future, it may be possible to correct DNA damage through gene therapy.

Variant xeroderma pigmentosum

This 'forme fruste' of xeroderma pigmentosum presents in later life without exaggerated sunburn responses or neurological involvement. Patients do get multiple skin tumours but develop them much later than in classic type XP. The disease is caused by a mutation in the POLH gene which is not a nucleotide excision repair gene but rather it is a 'translesion synthesis' gene. Unlike NER proteins, the POLH protein repairs DNA damaged by UV light *during* replication.

Cockayne syndrome and *trichothiodystrophy* also result from autosomal recessive DNA repair defects. Cockayne syndrome is characterised by photosensitivity, short stature learning difficulties, ocular, and nervous system abnormalities. Trichothiodystrophy is associated with chronic photosensitivity and ichthyosis. Their brittle hair shows characteristic 'tiger tail' banding on light microscopy.

The porphyrias

The porphyrias are a group of disorders associated with the accumulation of intermediate molecules called porphyrins in the metabolic pathway of heme synthesis. These accumulating porphyrin molecules result in cutaneous, hepatic, and neurovisceral problems. Depending on where in the pathway a defect has developed, symptoms vary. All porphyrias except acute intermittent porphyria show cutaneous involvement. Most are genetic, and

present early in life, but the commonest type of porphyria is triggered later by liver damage, although sometimes there is an underlying genetic predisposition. Porphyria patients are sensitive to violet light (400–440 nm): for this reason, conventional sunscreens are ineffective in preventing flares. Most porphyrins fluoresce orange or red, a fact which is exploited to allow discrimination between different types of porphyria in the laboratory.

Porphyria cutanea tarda (PCT) is the commonest form of the disease in Europe. Patients manifest a typical pattern of photosensitivity ([Figure 6.2](#)). They develop cutaneous fragility and blisters that heal with scarring, pigment changes, and milia on sun-exposed skin, particularly the face and dorsi of hands. Patients may develop facial hypertrichosis and onycholysis. Most PCT patients are not aware that their symptoms are caused by light. Men over 40 with excessive alcohol intake are most frequently affected. PCT patients are at increased risk of hepatocellular carcinoma. Urine samples will fluoresce red on examination with a woods lamp.

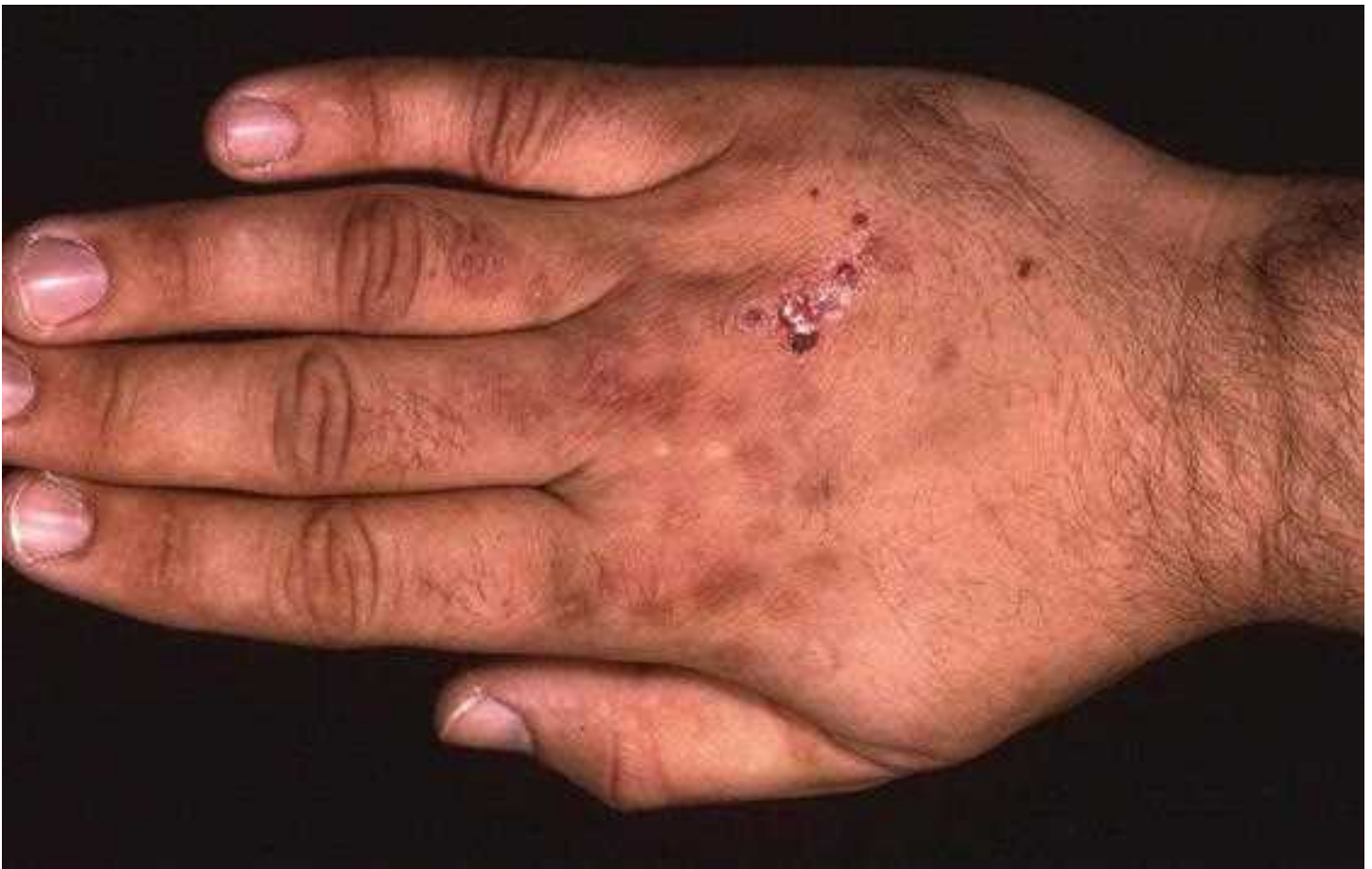

Figure 6.2 Porphyria cutanea tarda.

Erythropoietic protoporphyria (EPP) is the commonest of the inherited forms of the disease. The main feature of this is pain, often a burning or prickling sensation, after just a few minutes of intense sunlight. The pain can be severe. The disease usually presents in childhood with a parental history of a baby crying when exposed to bright light outdoors or through window glass. Over time thickened skin over knuckles and linear scars can develop on patients' cheeks ([Figure 6.3](#)).

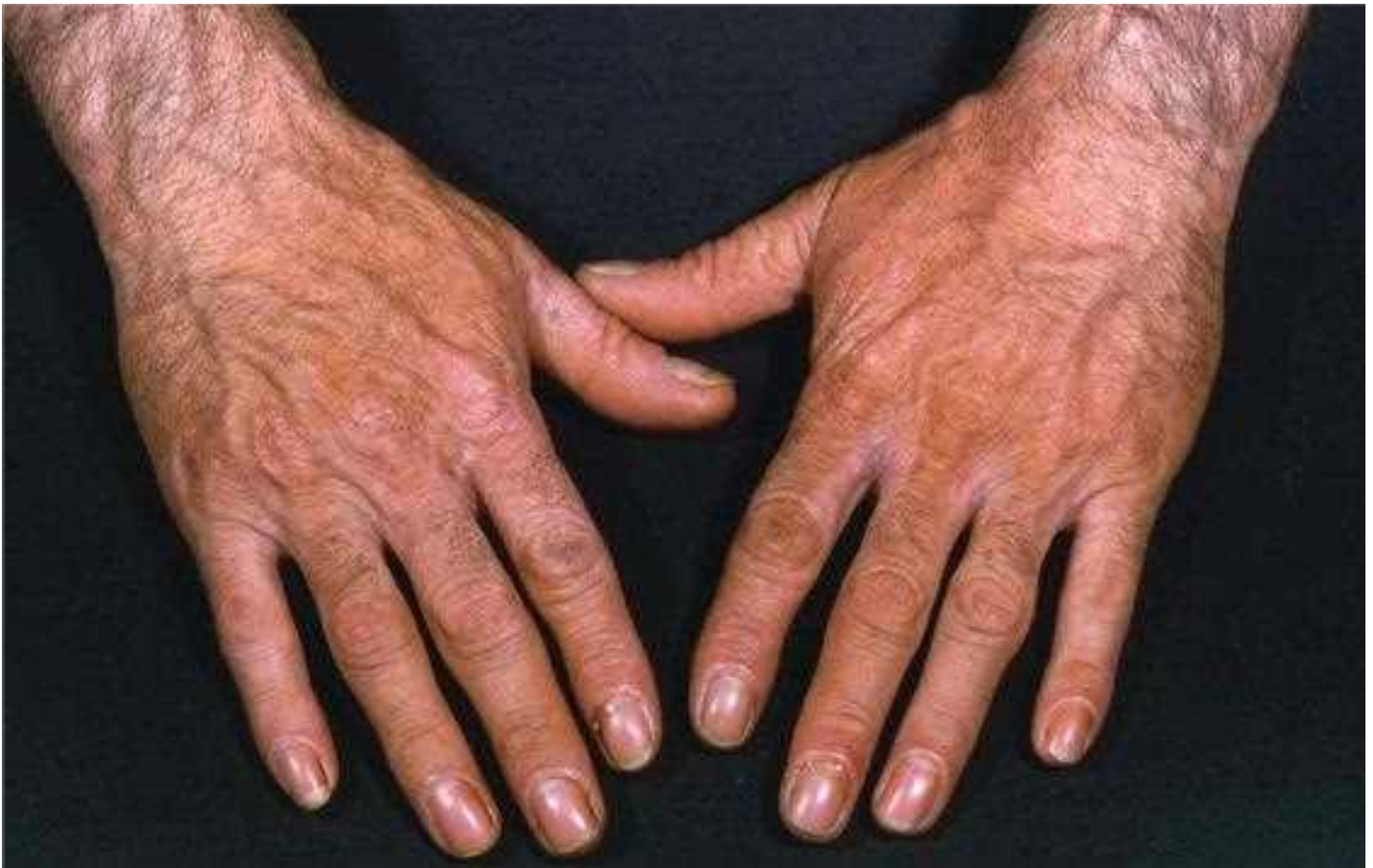

Figure 6.3 Erythropoietic protoporphyria.

All cutaneous porphyria patients should be given sun avoidance and protective clothing advice. Visible light reflecting sunscreens ('Dundee cream') and tinted films for windows can be prescribed. For PCT patients it is particularly important to avoid precipitating flares. For haemochromatosis patients with PCT, venesection can be useful; avoiding alcohol and the oral contraceptive pill or hormone replacement therapy (HRT) can be important. In EPP, UVB phototherapy is sometimes used for skin hardening. Melanotide is a new therapy which may prove valuable to EPP patients. Referral of any suspected porphyria patient to a national centre for diagnosis and treatment is worthwhile.

Medications causing photosensitivity

Both topical and systemic medications can lead to photosensitive eruptions (see [Chapter 7](#)) ([Figure 6.4](#)). The combination of UV or visible light and the chemicals result in a skin reaction. Although most drugs absorb in the ultraviolet range, only a few produce damaging cutaneous effects.

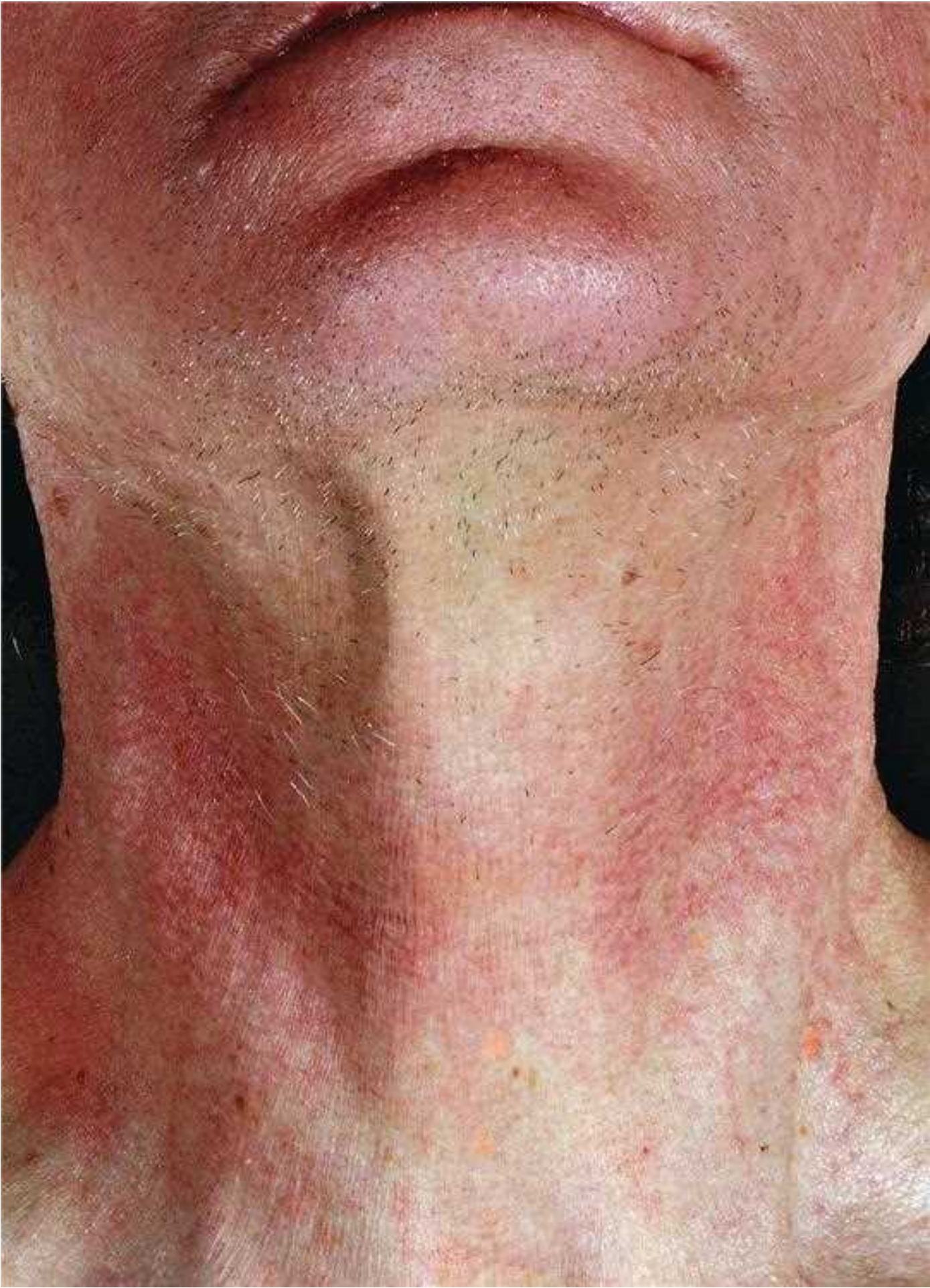

Figure 6.4 Photosensitive drug eruption showing typical ‘phototoxic’ or exaggerated sunburn response with sparing under the chin.

Possible reactions include: phototoxic – resembling sunburn; photoallergic – dermatitis; pseudo porphyria – blistering and skin fragility, subacute lupus erythematosus – erythema and scale; erythema multiforme – targetoid inflammation; lichenoid reaction – erythematous papules and post-inflammatory pigmentation and pellagra – pigmentation and scale. Of these mechanisms, by far the most common is phototoxicity, which makes up 90% of photosensitive drug reactions. Phototoxicity occurs in many forms and is drug-specific in terms of wavelength, timing of onset, and clinical appearance. The commonest wavelength implicated in drug phototoxicity is UVA but UVB and visible wavelengths can be responsible.

Photo allergy is an uncommon presentation, usually due to topical preparations applied directly to the skin in the presence of UV light. The most common photo-allergens are sunscreens and fragrances. A photoallergic reaction is found when a patient develops a positive patch testing response *only* in the presence of UVA light.

In all cases of severe photosensitive drug reactions, the medication should be stopped if possible and a non-phototoxic alternative found. Where this is not possible meticulous photoprotection must be adopted ([Table 6.1](#)).

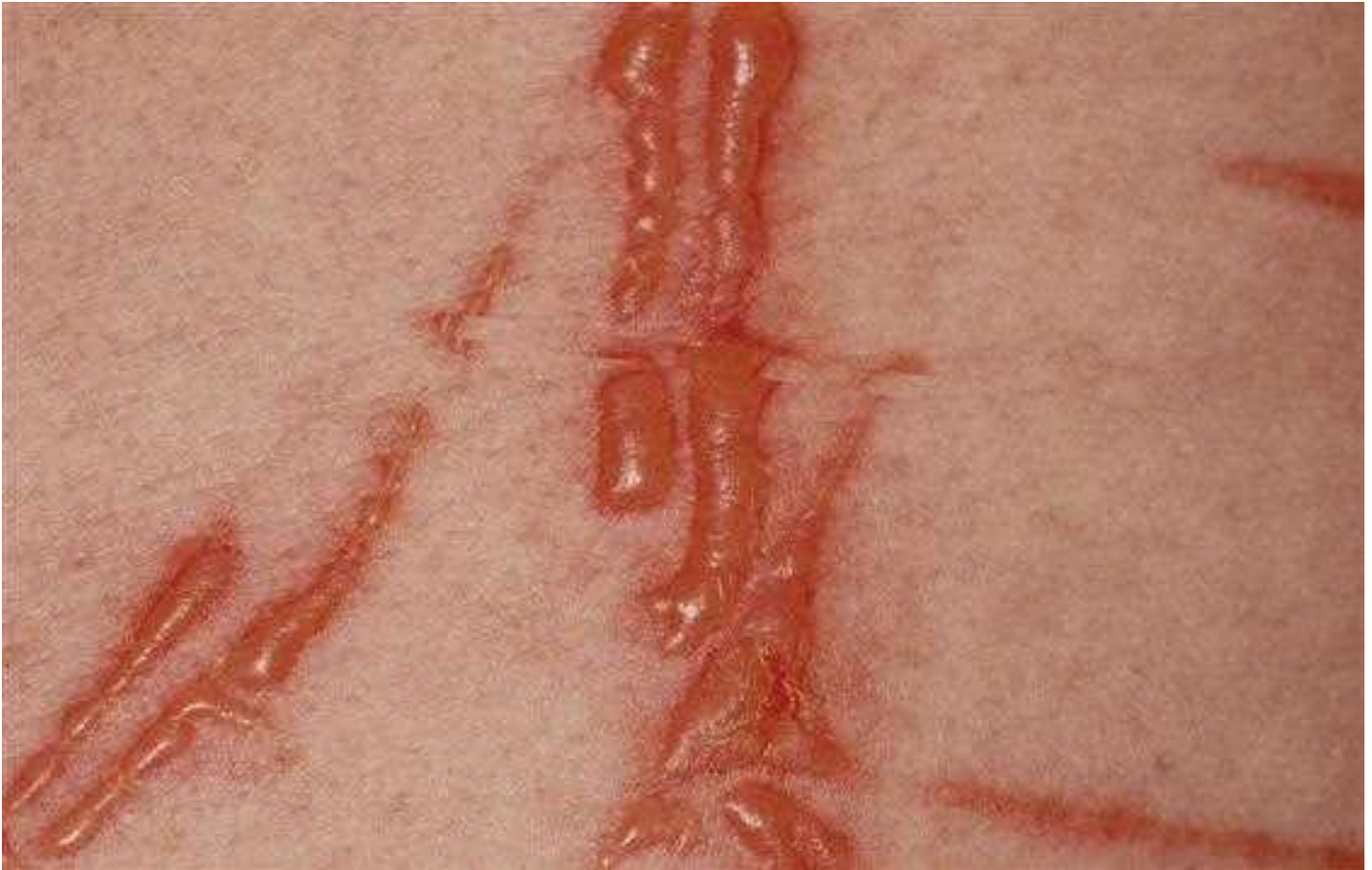Table 6.1 Common photosensitive drugs and associated features.

| Medication | Initial reaction | Notes |
|--|---|---|
| Thiazides | Exaggerated sunburn | Acute sunburn which develops into a photo-exposed dermatitis. Lupus-like reactions and pseudo porphyria can occur |
| Amiodarone | Immediate prickling, delayed erythema | Sometimes resolves into golden brown/slate grey discolouration. Can cause pseudo porphyria |
| Quinine | Exaggerated sunburn | May develop subacute cutaneous lupus (SCLE); depigmentation |
| Non-steroidal anti-inflammatory drugs (NSAIDs) | Immediate prickling, delayed erythema | Sometimes patient will develop a pseudo porphyria-like response, particularly to naproxen |
| Carbamazepine | Exaggerated sunburn | |
| Retinoids | Exaggerated sunburn | Phototoxicity usually normalises after a few weeks |
| Tetracyclines (doxycycline) | Exaggerated sunburn | Can cause grey pigmentation and pseudo porphyria |
| Calcium channel blockers (nifedipine) | | Exposed site telangiectasia |
| Chlorpromazine | Exaggerated sunburn | Can cause slate-grey pigmentation. Rarely used antipsychotic. |
| BRaf inhibitors (vemurafenib) | Exaggerated sunburn | Photoprotection appropriate or switch to dabrafenib |
| Furosemide | Exaggerated sunburn | Can cause pseudo porphyria |
| Voriconazole | Exaggerated sunburn | Chronic use associated with squamous cell skin cancers |
| Psoralens | Delayed (3–5 d) erythema. Sometimes blisters and pigmentation | Used in ‘PUVA’ phototherapy |
| Photofrin/foscan | Immediate prickling, delayed erythema | Used for photodynamic therapy, visible wavelengths cause an acute pseudoporphyria |

Phytophotodermatitis

Phytophotodermatitis is an acute-onset blistering rash resulting from photosensitizing plant

material in contact with the skin plus UVA light ([Figure 6.5](#)). This is a phototoxic reaction not requiring any previous exposure to the plant. Children and agricultural workers are often affected because of their outdoor activities. Implicated plants include meadow grass, common rue, poison ivy/oak, celery, cow parsley, giant hogweed, bergamot, lime, and other citrus fruits. The rash usually appears within hours of exposure to the plant. Patients present with blisters on an erythematous background. The rash usually looks exogenous with bizarre linear streaks on the legs or 'drip marks' down the arms. Phytophotodermatitis should be treated with a potent topical steroid and the causative plant material subsequently avoided.

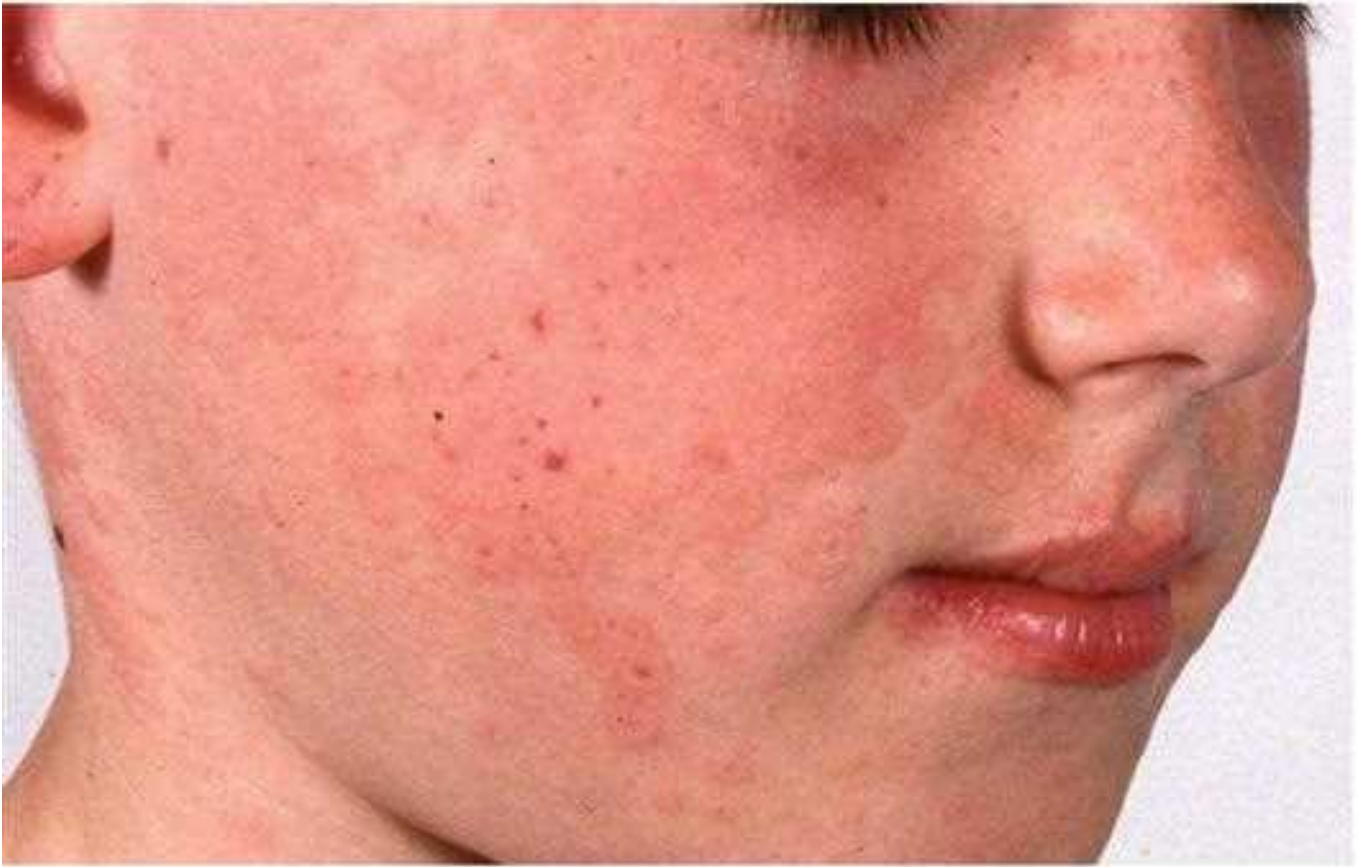

[Figure 6.5](#) Phytophotodermatitis to lime juice.

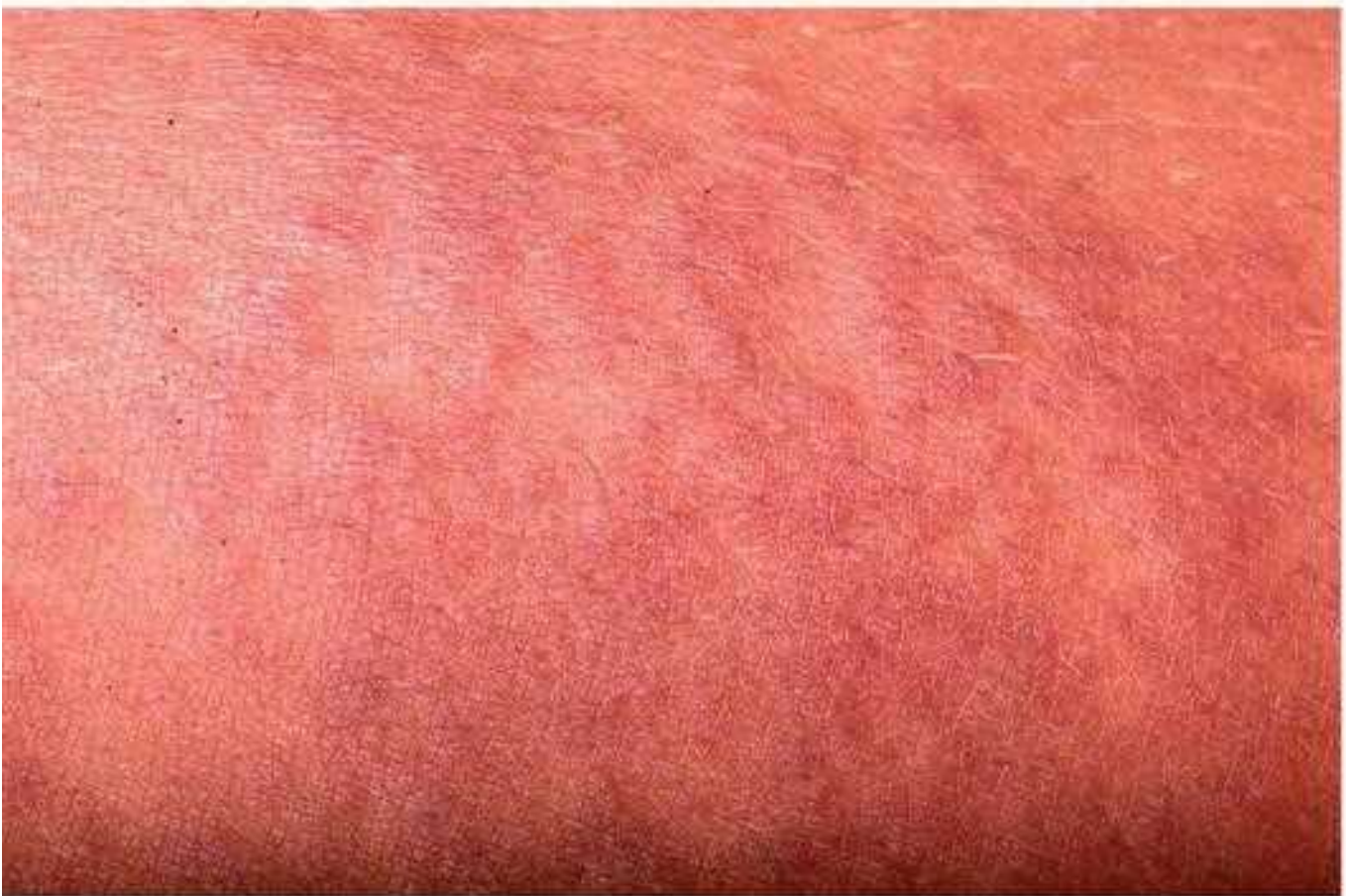Photosensitive disorders

Polymorphous light eruption (PMLE)

PMLE presents as a pruritic erythematous papular rash on exposed sites after sunlight exposure in the early spring/summer. The rash is sometimes preceded by a burning sensation and usually affects sites exposed by summer dress such as the neck, forearms, and legs. Except in children, perennially exposed sites are usually spared. Morphology varies but the rash of PMLE can be papular, in plaques, vesicular, oedematous, erythema multiforme-like, even haemorrhagic ([Figure 6.6a, b](#)). The rash develops between 30 minutes to several hours after sun exposure and resolves without scarring over between 1 and 14 days.



(a)



(b)

Figure 6.6 (a) Polymorphous light eruption (PMLE). (b) PMLE papular and erythematous eruption.

The disorder is commoner in women than men and in the first three decades of life. It is more prevalent in latitudes further from the equator, and it can affect any skin type.

It has been suggested that the mechanism of PMLE may be cutaneous allergy to an endogenous allergen produced in sun-exposed skin. In normal subjects UVB damage produces a latent immune-suppressive response as well as a sunburn but in PMLE this immune-suppressive response is absent. PMLE has an association with lupus erythematosus and some PMLE patients will have a positive antinuclear antibodies (ANAs).

Management includes sun avoidance, sunscreens, and topical or oral corticosteroids when severe. A course of desensitising TL-01 (narrow-band UVB) or psoralen with ultraviolet A (PUVA) (oral psoralen plus UVA) prior to sun exposure the following year can be effective.

Solar urticaria

This relatively rare photoallergic skin condition presents with rapid onset of an itchy, stinging erythema and urticaria following between a few seconds to a maximum of around 15 minutes of sun or artificial light exposure. Often patients can recall the exact date and time of the onset of solar urticaria. The rash is transient, resolving within minutes or hours after retreating from the light. UVA and visible wavelengths commonly trigger the reaction but UVB can be responsible too. The reaction is thought to be mediated by a photo-modified cutaneous antigen. Solar simulator and monochromator light tests confirm the diagnosis. Solar urticaria can be debilitating and difficult to manage. Patients often avoid sunlight and can become reclusive. Sun avoidance, sunscreens with UVA protection, antihistamine, and TL-01 narrow-band UVB phototherapy may be helpful. Where conventional treatment has been unsuccessful, anti IgE drugs like omalizumab have been trialled with success.

Chronic actinic dermatitis (CAD)

Middle-aged or elderly men are most commonly affected by this itchy, flaky, erythematous rash that typically affects the face, posterior and 'V' of neck, and the dorsi of hands ([Figure 6.7](#)). CAD is worse in summer but often persists throughout winter too. Monochromator testing can implicate UVB, UVA, and visible light. Patch and photo patch testing often identify multiple associated contact allergies, especially to Compositae plants (daisy family), perfumes, sunscreen, and colophony (pine trees and Elastoplast). Except in cases of allergy, sunscreen, and sun avoidance behaviour should be encouraged all year round. Aside from good sun-protective measures, patients should be managed like eczema, with topical steroids and emollients. Some may require systemic corticosteroids. Methotrexate, azathioprine, and ciclosporin are sometimes useful too.

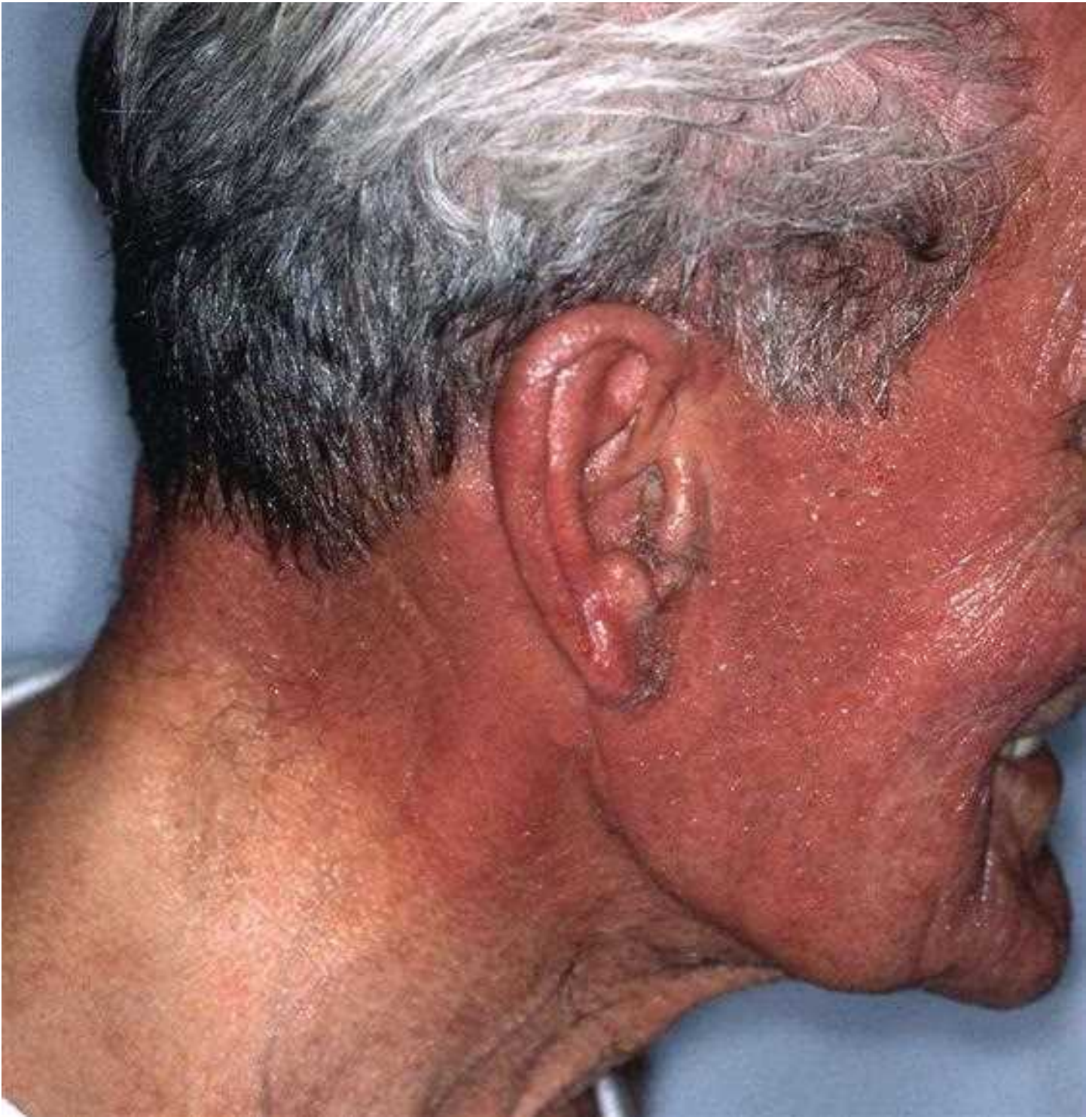


Figure 6.7 Chronic actinic dermatitis.

Sunprotection behaviour and sunscreens

A patient-centred approach to sun protection, considering Fitzpatrick skin type, personal skin cancer history, and relevant diagnoses, is crucial. Those with type I and II skin are more at risk of burning and skin cancer than those with type V or VI. Patients with multiple naevi, previous cancers, and photodermatoses need pay even greater attention.

Sun protection is more about behaviour than sunscreens. Good sun protection habits include

avoidance of direct sun exposure between 11 a.m. and 3 p.m., sitting in the shade, wearing protective clothing (tighter weaves and darker colours give greater protection), and wearing broad brimmed hats and eye protection. Nevertheless, regular sunscreen use has been shown to reduce the incidence of actinic keratoses, squamous, and melanoma skin cancers in at risk individuals.

On most sunscreen packaging the amount of protection offered against UVB radiation is indicated by the SPF. This is defined as the factor by which the amount of UVB needed to burn an individual's skin is increased by application of 2 mg/cm² of the sunscreen. For example, SPF30 enables a person to stay 30 times longer in the sun without burning compared to if they were wearing no sunscreen. SPFs are rated on a scale of 2–50. UVA protection is indicated using the 'star rating'. Protection level is indicated on a scale of 0–5 stars, with 5 providing the highest and 0 the lowest protection. Stars correspond to the percentage of UVA radiation absorbed by the sunscreen in comparison to UVB. A sunscreen with an SPF of 30 and a UVA rating of 4 or 5 stars is sensible.

There are two main types of sunscreen – inorganic and organic. Inorganic sunscreens can look opaque when applied to the skin and are less cosmetically acceptable; however, they are highly effective and are hypoallergenic. Inorganic sunscreens work by reflecting and scattering UV light. They contain minute particles of titanium dioxide for UVB and zinc oxide for UVA. Organic sunscreens are more likely to cause skin irritation and allergy but are less visible. Traditional organic sunscreens often contain combinations of cinnamates and *p*-amino benzoic acid (PABA) which absorb predominantly UVB and give a high SPF. Newer, broad-spectrum organics such as avobenzene (*Parsol*) and bis-ethylehexyloxyphenol methoxyphenol triazine (Tinosorb S) absorb both in the UVB and the UVA parts of the spectrum.

Patients should be advised to apply sunscreens thickly and frequently (around two-hourly is good). Although manufacturers recommend application of around 2 mg/cm², in practice, most of us apply as little as a quarter of this. Furthermore, we find it hard to apply sunscreen often or evenly enough. Sunscreens can be washed off or wiped off by clothes. Despite their limitations, sunscreens remain part of our defence against the skin cancer epidemic and are vital for patients with photodermatoses. Particularly in at risk individuals, they should be encouraged as an important part of a wider strategy of sun-protective behaviour.

Vitamin D levels and sun protection

Over the past decade, there has been concern among physicians that Vitamin D3 deficiency may be linked to diseases such as multiple sclerosis, asthma, type I diabetes and malignancies, including melanoma. It is also well known to be associated with rickets in children and osteoporosis in older patients. Some physicians also claim UV may confer other benefits too, such as improved blood pressure. Because 90% of human vitamin D3 is produced in the skin only in the presence of UVB there has been debate about whether dermatologists should rethink their advice on sun protection. How should we balance

avoiding the risks of sun burn and skin cancer with ensuring that patients achieve healthy levels of vitamin D?

Although concern about the need to maintain a normal vitamin D is understandable, the data suggest that 25(OH) vitamin D reaches adequate levels after relatively short sun exposures. Cohort studies of patients on holiday in resorts in the Canary Islands and Spain have demonstrated that although sunscreens reduce vitamin D levels, the reduction is not significant and healthy levels are easily reached. Although truly obsessive sun avoidance and sunscreen use can limit vitamin D production, such meticulous behaviour is unusual; indeed, partial, and inconsistent sun protection behaviour is much more common. Although in winter months oral vitamin D3 supplements may be necessary and low vitamin D common, in summer sunscreens are unlikely to impede vitamin D production and should continue to be encouraged as part of good sun protection behaviour. When sun avoidance is imperative (for example in patients with XP), and patients do develop perennial low vitamin D, supplementation is an easy alternative to sun exposure.

Reference

Sarkany, R. (2017). Sun protection strategies. *Medicine* 45 (7): 444–447.
<https://doi.org/10.1016/j.mpmed.2017.04.009>.

Further reading

Collignon, L.N. and Normand, C.B. (2010). *Photobiology: Principles, Applications and Effects*. New York: Nova Science Publishers.

Ferguson, J. and Dover, J.S. (2006). *Photodermatology*. London: Taylor & Francis.

Lim, H.W., Honigsmann, H., and Hawk, J.L.M. (2007). *Photodermatology (Basic and Clinical Dermatology)*. New York: Informa Healthcare.

Sarkany, R.P. (2008). Making sense of the porphyrias. *Photodermatology, Photoimmunology and Photomedicine* 24 (2): 102–108. <https://doi.org/10.1111/j.1600-0781.2008.00336.x>.

CHAPTER 7

Drug Rashes

Sarah Walsh

Dermatology Department, King's College Hospital, London, UK

OVERVIEW

- Drug reactions in the skin are common. Cutaneous adverse reactions account for a third of all adverse reactions to drugs.
- Drugs can cause adverse reactions in several ways: by changing normal skin function, by exacerbating an existing dermatosis, by causing an idiopathic dermatosis such as urticaria, by causing a specific drug eruption (lichenoid drug rashes), or by precipitating a severe drug reaction (toxic epidermal necrolysis).
- Identifying the culprit drug requires careful history-taking and knowledge of the notoriety of certain drugs in the causation of certain reactions.
- Careful skin examination is required to identify the morphology of the rash and the correct classification of the drug reaction.
- The most important step in management of drug rashes is identification and withdrawal of the culprit medication.
- Some drug reactions are mild and resolve quickly (maculopapular exanthems); others are more severe and carry considerable morbidity and mortality (Stevens–Johnson syndrome and toxic epidermal necrolysis).

Introduction

Adverse reactions in the skin to medications are very common and are an important cause of iatrogenic illness. Drug rashes are usually self-limiting and resolve completely upon withdrawal of the culprit medication, but a small number (<2%) can cause serious morbidity and mortality. This may not only have medicolegal and economic implications but may undermine the patient's confidence in the prescriber and affect future adherence. Diagnosis of drug-induced skin disease may be difficult for a number of reasons:

- Almost any drug can cause any rash.
- Unrelated drugs can cause similar reactions.
- The same medication can cause a different rash in different individuals.
- Patients may not volunteer information about medicines that they have taken, which

they deem not to be relevant (over-the-counter [OTC] preparations and complementary medicines).

History

It is imperative to take a thorough history from patients in whom a drug reaction is suspected. Eliciting the temporal association of the ingestion of the drug and the onset of the eruption is key. Apart from noting any medications taken for the first time in the three months prior to the appearance of the rash, patients should be specifically asked about any recent changes to brand, dosing, or preparation of long-term medications. Patients may not volunteer information about drugs they have taken that they assume are not relevant, such as paracetamol taken for a headache, or an antihistamine taken for hayfever. Direct questioning about OTC preparations should always form part of a thorough drug history. Medications recommended by alternative/complementary health practitioners may not be revealed spontaneously and should be asked about directly. Both generic and brand names of all drugs should be recorded, and the patient should be asked about any history of sensitivity to medications. Knowledge of whether the patient has been previously exposed to suspected culprit drugs is also relevant.

Examination

The patient should be exposed fully to allow complete examination of the skin. The morphology of the rash should be described – for example, lichenoid, urticated, vasculitic, maculopapular, or bullous. The distribution of the rash should be noted: Is it widespread? Limited? Acral (hands and feet)? Photo-distributed? These features will help to classify the eruption and may give a pointer as to the causative drug. Special attention should be paid to the mucosal sites – eyes, mouth, genitalia – as involvement at these sites can indicate one of the severe cutaneous adverse reaction (SCAR) syndromes. Early diagnosis of these syndromes is crucial as patients may become unwell and deteriorate quickly. Careful examination of the appendageal structures such as hair, nails, and teeth should also be carried out as these can be affected by certain medications.

Investigation of a suspected drug reaction

In most cases, careful history and examination will provide all the necessary clues to make a confident diagnosis of a drug rash. A skin biopsy can be helpful to confirm the diagnosis, but the result of this is likely to be delayed following an acute presentation, and so action based on clinical assessment will usually precede this. Exclusion of differential diagnoses such as infection may require other investigations such as blood tests (white cell counts and CRP levels).

There are no consistently reproducible diagnostic tests which confirm specific drug allergy in the convalescent period; however, certain investigations such as measurement of specific

immunoglobulin E (IgE), patch testing, intradermal testing, and in vitro tests such as lymphocyte transformation tests and cytokine release assays may be helpful. However, these investigations should be carried out by experts as their interpretation is highly specialised. Testing should also be carried out with great caution following an episode of one of the SCARs such as toxic epidermal necrolysis (TEN).

Patch testing

In this method of skin testing, an amount of the medication is applied to the skin in a suitable vehicle such as petrolatum. This is best performed at least six weeks post-resolution of the eruption. The best positive predictive value has been observed when testing for allergy to abacavir, anticonvulsants, and beta-lactam antibiotics. However, the sensitivity of patch testing alone is not great enough to conclusively exclude reactions.

Intradermal testing

Injection of the suspected culprit agent into the dermis in the convalescent period is sometimes performed as an adjunct to patch testing. Using both modalities may improve sensitivity in confirming a causative agent.

In vitro testing

In experimental settings, a blood sample may be taken from a patient who is experiencing a drug reaction – the patient's lymphocytes are incubated with a series of suspected culprit drugs. Markers of activation of those lymphocytes are then measured, and this has been used as a testing modality in the investigation of drug reactions (lymphocyte transformation test). Measurement of cytokines such as IFN- γ , IL4, tumour necrosis factor (TNF), and granulysin released by patient lymphocytes in response to in vitro exposure to suspected culprit drugs have also been used to confirm causality (cytokine release assays). Blood samples are best taken as early as possible in the course of the illness. No standardised, commercially available in vitro testing is currently available in the UK.

Classification of drug reactions in the skin

Cutaneous reactions to medications are extremely varied. They may be classified in a number of ways. Pathogenetically, drug reactions in the skin may be classified as *immune-mediated* or *non-immune-mediated*. *Immune-mediated* rashes are the most common and include hypersensitivity reactions from types I to IV. Type I reactions (immediate reactions, usually mediated by IgE or drug-specific receptors bound to mast cells and other immune cell membranes) tend to manifest in the skin as urticaria or angio-oedema. Type II reactions (cytotoxic reactions) result in cutaneous purpura. Type III (immune complex mediated) reactions lead to cutaneous vasculitis. Type IV delayed hypersensitivity reactions are by far the most common group of drug rashes resulting in generalised exanthems, phototoxic rashes, and severe drug reactions such as TEN.

Non-immune-mediated rashes include accumulation of medications in the skin (causing pigment changes), instability of mast cells (causing histamine release), slow acetylators (metabolism of drugs affected) and photosensitivity reactions (increased susceptibility to ultraviolet [UV] light).

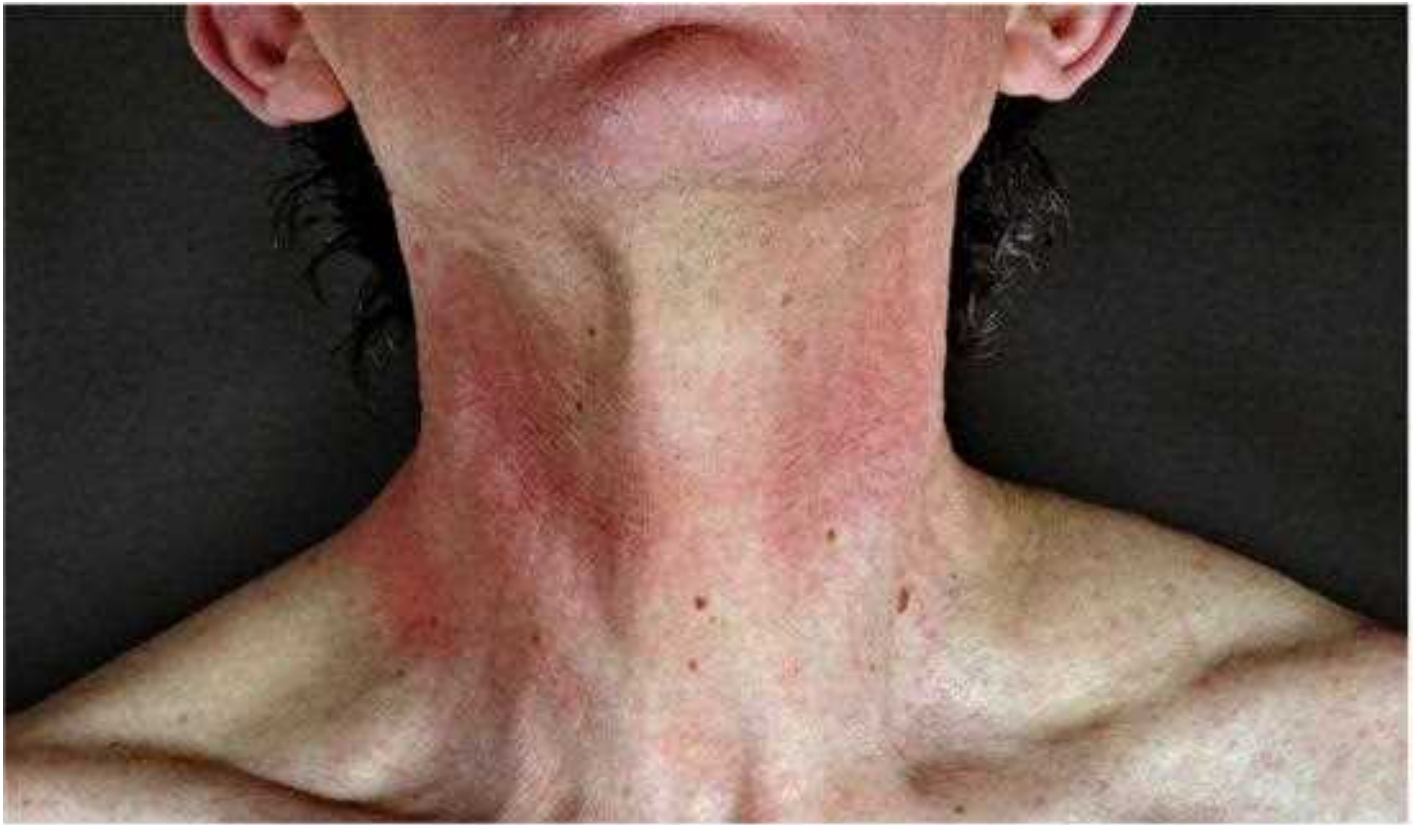However, drug reactions in the skin may also be classified clinically, and this is the approach adopted here. Drug reactions in the skin are discussed under the following headings:

1. Drugs which alter normal skin function.
2. Drugs which exacerbate an existing dermatosis.
3. Common drug-induced rashes – maculopapular exanthem, urticaria, vasculitis, lichenoid drug reaction, and fixed drug eruption.
4. Severe drug-induced rashes – Stevens–Johnson syndrome (SJS) and TEN, acute generalised exanthematous pustulosis (AGEP) and drug reaction with eosinophilia and systemic symptoms (DRESS).

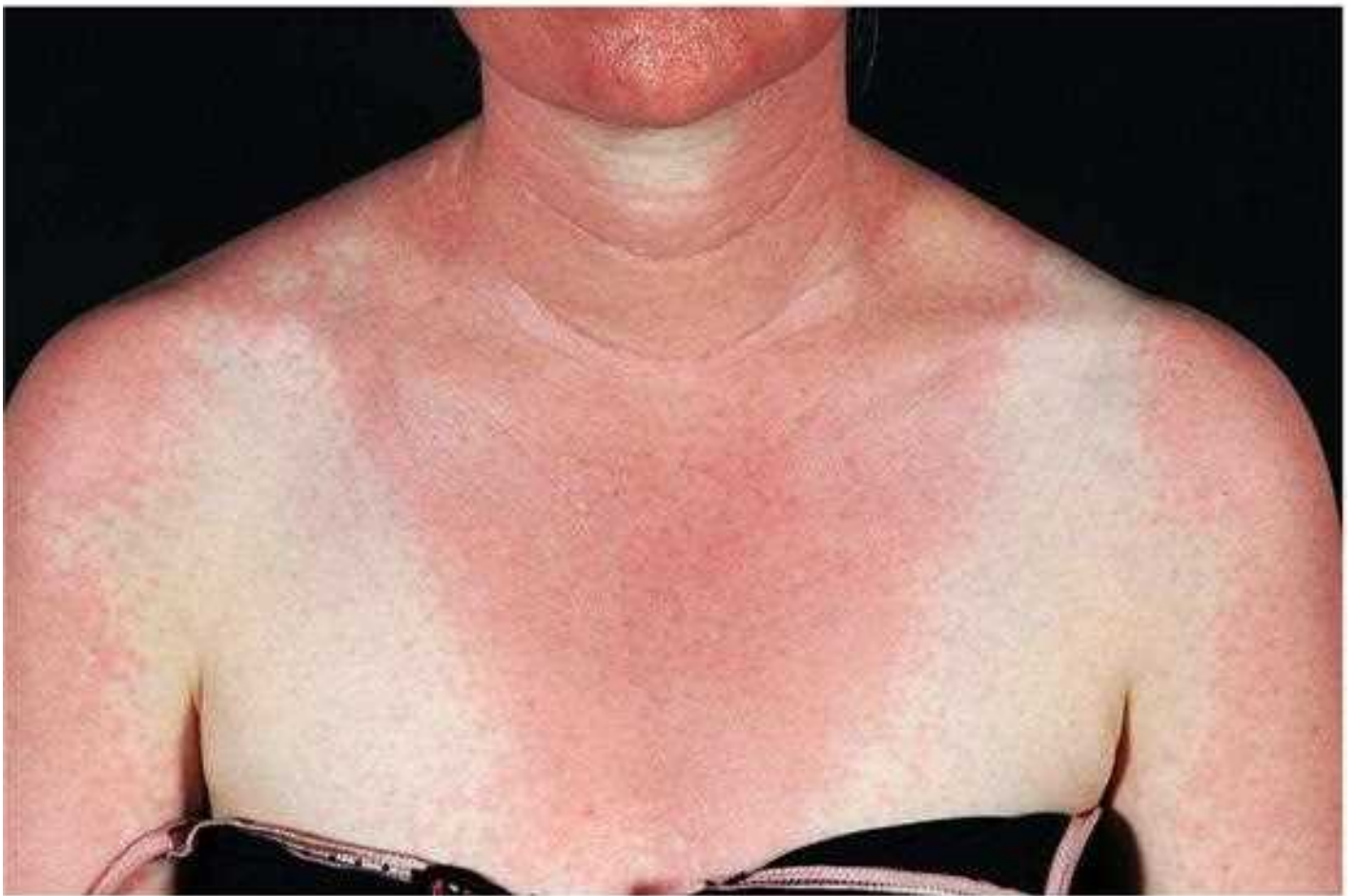Drugs which alter normal skin function

Photosensitivity

Drugs may cause excessive sensitivity to light in two ways: phototoxic reactions and photoallergic reactions. Phototoxic reactions ([Figure 7.1a, b](#)) are the more common, and resemble sunburn and may blister. The reaction is confined to light-exposed sites and may be characterised by a sharp demarcation between covered and uncovered skin. The onset will typically be fast (within 5–15 hours of taking the drug and exposure to light) and recovery is quick on withdrawal of the medication. Photoallergic reactions are usually eczematous, but may be lichenoid, urticarial, purpuric, or bullous. The onset may be delayed by weeks or months following introduction of the medication, and similarly, recovery may be slow on withdrawal. Patients taking medication known to cause light sensitivity (amiodarone, tetracycline antibiotics, and retinoids) should be advised to avoid excess sun exposure, and to wear a broad-spectrum sunscreen year-round. Drugs causing photosensitivity are detailed in [Table 7.1](#).



(a)



(b)

Figure 7.1 (a) Photosensitive eruption. (b) Phototoxic eruption.

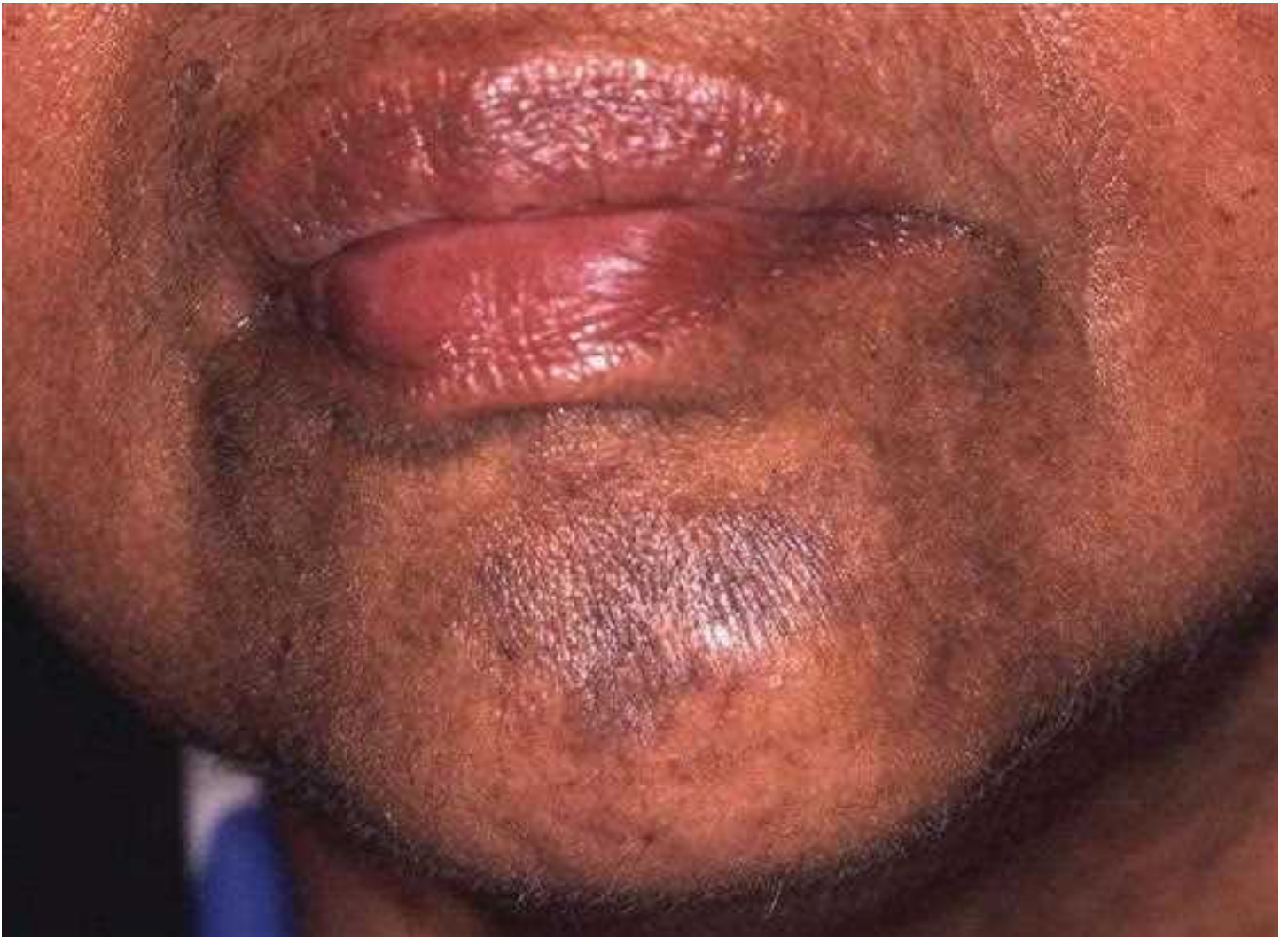

Figure 7.2 Diltiazem pigmentation on the face.

Table 7.1 Cutaneous reactions and the most commonly implicated drugs.

| Skin reaction | Drugs |
|--------------------------|--|
| Phototoxic reactions | Amiodarone, NSAIDs, tetracyclines, chlorpromazine |
| Photosensitive reactions | Amiodarone, tetracyclines, calcium channel blockers, diuretics, voriconazole, itraconazole, terbinafine, ritonavir, saquinavir |
| Photoallergic reactions | NSAIDs, antibiotics, thiazides, anticonvulsants, allopurinol, quinolones, nelfinavir |
| Pigmentation changes | Chlorpromazine, phenytoin, hydroxychloroquine, cyclophosphamide, bleomycin, amiodarone, clofazimine, minocycline, mepacrine |
| Urticaria/angio-oedema | NSAIDs, opioid analgesics, ACE inhibitors, antibiotics, anti-retrovirals (didanosine/nelfinavir/zidovudine), infliximab, proton pump inhibitors, IV contrast media |
| Drug-induced lupus | Terbinafine, hydralazine, procainamide, proton pump inhibitors, quinidine, isoniazid, diltiazem, and minocycline |
| Drug-induced vasculitis | Antibiotics, NSAIDs, phenytoin, ramipril, proton pump inhibitors, allopurinol, thiazides, adalimumab, indinavir |
| Lichenoid drug eruption | Gold, mepacrine, tetracyclines, diuretics, amlodipine, carbamazepine, propranolol, NSAIDs, ACE inhibitors, proton pump inhibitors, statins |
| Erythema nodosum | Oral contraceptives, antibiotics, gold, sulfonylurea |
| Fixed drug eruption | Antibiotics, NSAIDs, oral contraceptive, barbiturates |
| SJS/TEN | Antibiotics, anticonvulsants, NSAIDs, anti-retrovirals, allopurinol (didanosine/indinavir/saquinavir), barbiturates, ramipril, diltiazem |
| DRESS | Allopurinol, anticonvulsants, antibiotics, anti-retrovirals, imatinib (Gleevec), NSAIDs, ACE inhibitors, calcium channel blockers, terbinafine, tyrosine kinase inhibitors |
| AGEP | Antibiotics, anticonvulsants, anti-tubercular medications |

Antibiotics: most commonly sulfonamides, penicillins, ampicillin, tetracyclines, and vancomycin.

Anticonvulsants: most commonly phenytoin, carbamazepine, sodium valproate, and lamotrigine.

Calcium channel blockers: most commonly diltiazem, nifedipine, and amlodipine.

NSAIDs: most commonly aspirin and ibuprofen.

Pigmentation

Hyperpigmentation, hypopigmentation, and discolouration are all associated with certain drugs ([Table 7.2](#)). The pigmentary change may require light exposure to manifest. Common

examples would include the development of melasma in female patients taking the oral contraceptive pill, or the facial blue-black pigmentation which may be caused by amiodarone. Tetracycline antibiotics may also cause a slate-grey pigmentation. Mechanisms for drug-induced pigmentation are unclear, but may involve deposition of the drug or its metabolite in the dermis, or enhanced melanin production.

Table 7.2 Time from drug commencement to drug rash.

| Time to onset of rash after starting the drug | Cutaneous drug reaction |
|--|---|
| Hours/days | Urticaria/angio-oedema, contact urticaria, fixed drug eruption, vasculitis/urticarial vasculitis |
| Weeks | Toxic erythema, Stevens–Johnson syndrome, toxic epidermal necrolysis, erythema multiforme, acute generalised exanthematous pustulosis, contact dermatitis, erythroderma, photosensitive eruptions |
| Months | DRESS, Stevens–Johnson syndrome, pigmentation changes (Figure 7.2), contact dermatitis |

Hair and nails

Excessive hair: Hypertrichosis is the growth of hair at sites which are not normally hair-bearing; hirsutism is excessive growth of hair in the male pattern of hair growth, especially in women. Both hormonal and non-hormonal treatments may bring about this effect; the most commonly implicated would include ciclosporin and phenytoin.

Hair loss: Loss of hair may be dramatic or insidious in onset, and if the latter, may not be immediately noticed by the patient. The temporal relationship between the onset of the hair loss and the introduction of the medication depends on the part of the hair cycle which the drug is interfering with. Cytotoxic agents interrupt the anagen (‘growth’) phase of the hair cycle, and so loss is rapid and complete; delayed, insidious hair loss generally results from interference with the telogen (‘shedding’) phase of the hair cycle. Drugs such as acitretin, statins, and anti-thyroid drugs may have this effect. Androgenic drugs promote shrinkage of the hair follicles and shortening of anagen, and so can cause hair loss. An example would be exogenously administered testosterone used to treat hypogonadism in male patients.

Nails

Nails may become discoloured with use of mepacrine or hydroxyurea. Onycholysis, which is separation of the nail plate from the nail bed, may be caused by cytotoxic agents.

Drugs which exacerbate pre-existing dermatoses

Medications may exacerbate skin conditions which the patient already has. The following

summarises the most common associations:

Psoriasis – this is a common condition affecting approximately 2% of the population; however, some medications are known to worsen psoriasis. These are classically described as beta blockers, lithium, and antimalarial medications, though newer drugs such as ACE (angiotensin-converting enzyme) inhibitors can also worsen psoriasis. Non-prescribed drugs such as alcohol have a detrimental effect on psoriasis.

Eczema – statins and diuretics such as hydrochlorothiazide may worsen eczema.

Acne – some forms of the oral contraceptive pill, particularly progesterone-only pills, may worsen acne. Corticosteroids, ciclosporin, and anti-epileptics such as phenytoin may also have the same effect.

Urticaria – non-steroidal anti-inflammatory drugs (NSAIDs) and opiate analgesics may worsen urticaria in a susceptible individual, by lowering the threshold for mast cell degranulation. ACE inhibitors and angiotensin receptor blockers may exacerbate angio-oedema. This is non-allergic urticaria/angio-oedema; allergic urticaria/angio-oedema is described in the next section.

Common drug-induced rashes

Drug-induced exanthems

The most common cutaneous reaction to a drug is an exanthem, meaning a widespread rash. Such rashes may be morbilliform (resembling measles) or maculopapular (consisting of a mixture of raised and flat areas) ([Figure 7.3](#)). The patient may be symptomatic with burning, itch, or discomfort arising from the skin. Onset is typically within 7–10 days of starting the drug, representing a delayed-type hypersensitivity. However, subsequent reactions on inadvertent re-exposure to a culprit drug may provoke a reaction in the skin more quickly, because of the presence of memory T-cells in the lymph nodes. The proportion of the body surface area (BSA) involved may vary, and in cases where it exceeds 90%, the patient may be described as erythrodermic. Following withdrawal of the culprit drug, application of a potent topical corticosteroid and emollient will help alleviate discomfort and itch, and hasten resolution of the eruption. Any drug may cause a drug-induced exanthem but antibiotics of any class, anti-hypertensive agents, and cholesterol-lowering drugs are among the most common precipitants.

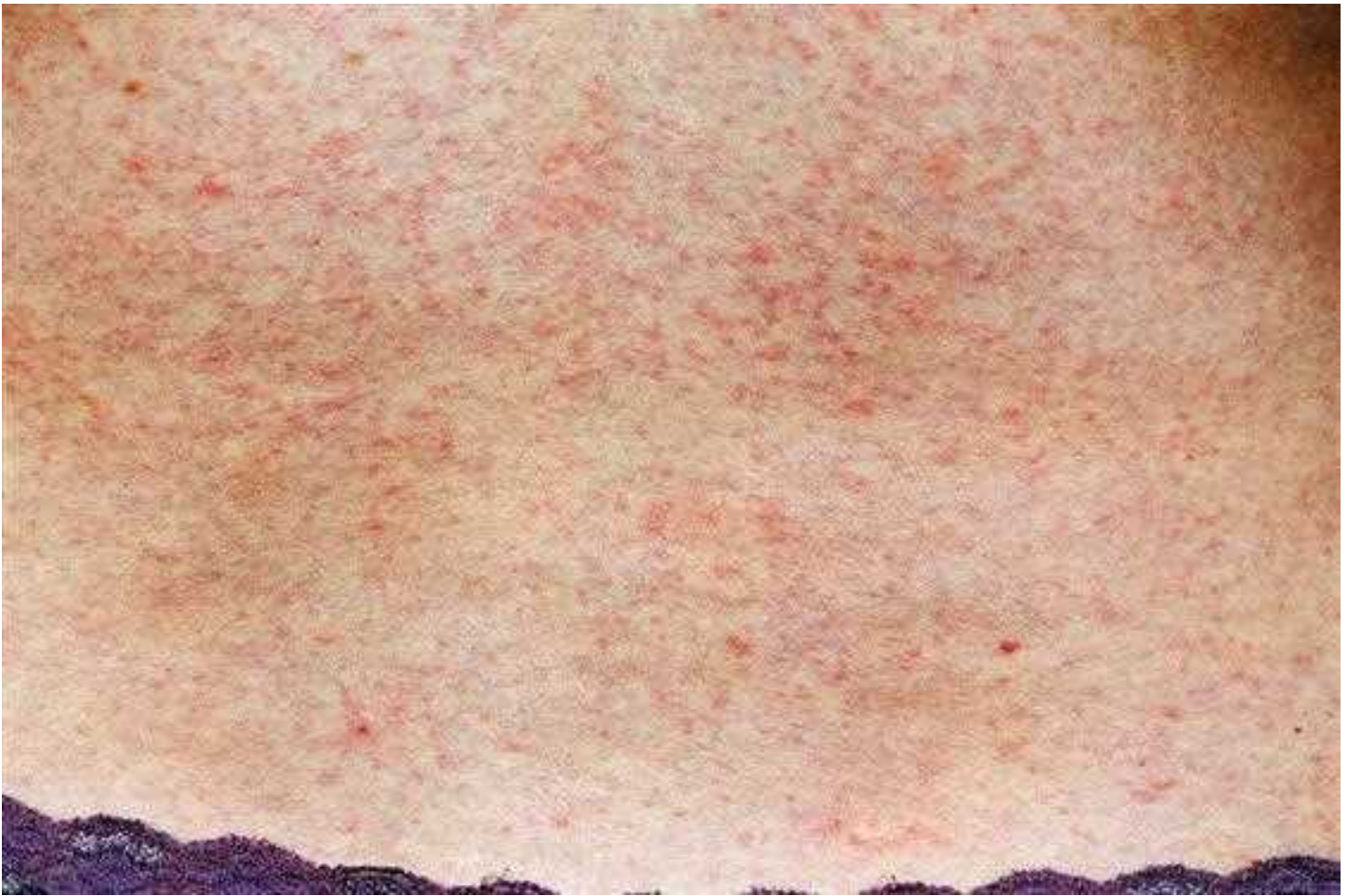

Figure 7.3 Maculopapular exanthem.

Urticaria/angio-oedema

The appearance of raised, red itchy wheals in the skin ([Figure 7.4](#)) may occur alone or in combination with angio-oedema, which is head and neck soft-tissue swelling. The latter may be serious, and when it involves the soft tissue of the airway, may cause respiratory embarrassment. It may be non-allergic (described above) or allergic; in the latter, a reaction occurs between a drug or its metabolite and a specific mast cell-bound IgE. A drug may cause anaphylaxis, occurring rapidly after drug ingestion (type I drug hypersensitivity) or may be delayed by a number of days following exposure to the drug (type IV hypersensitivity).

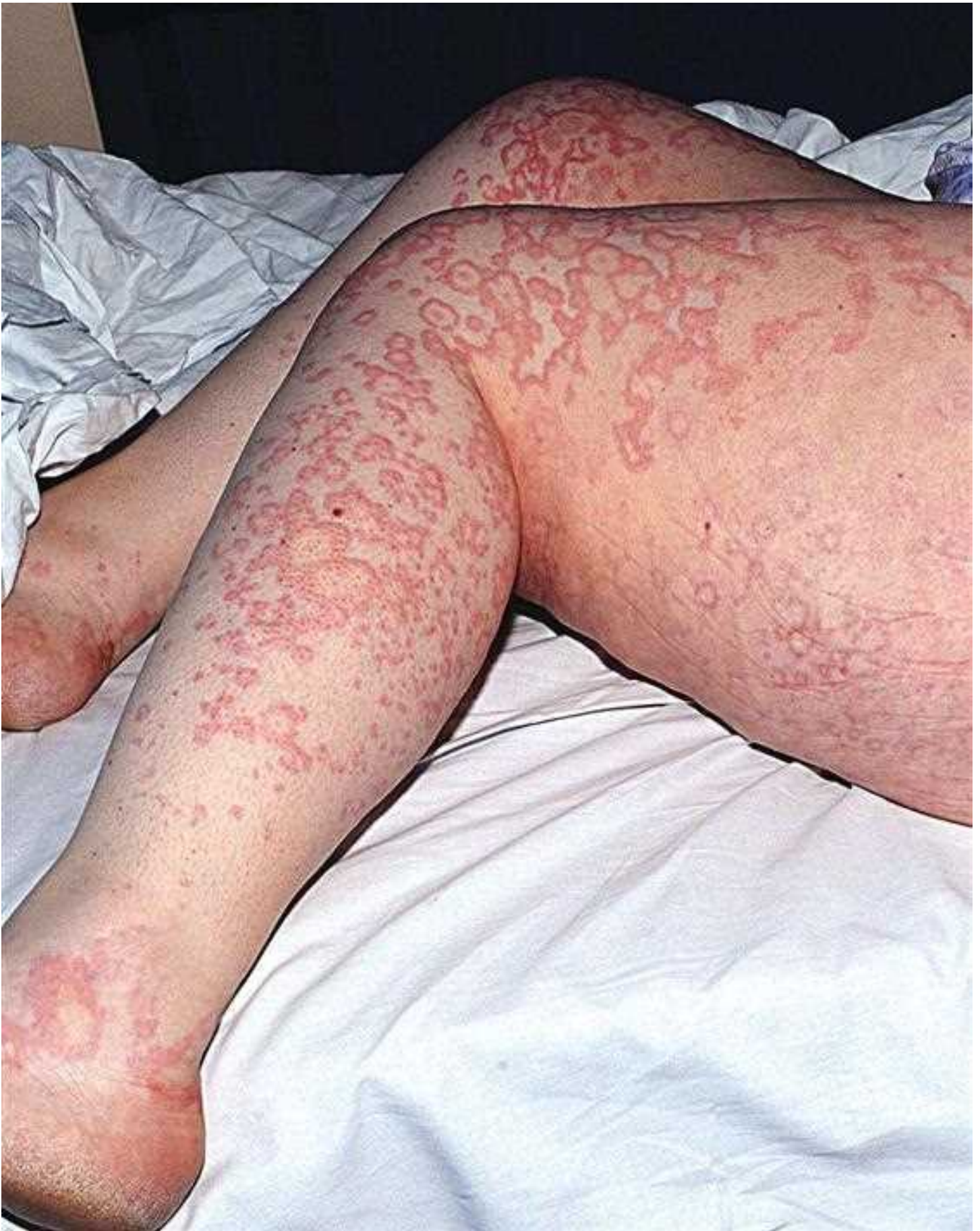
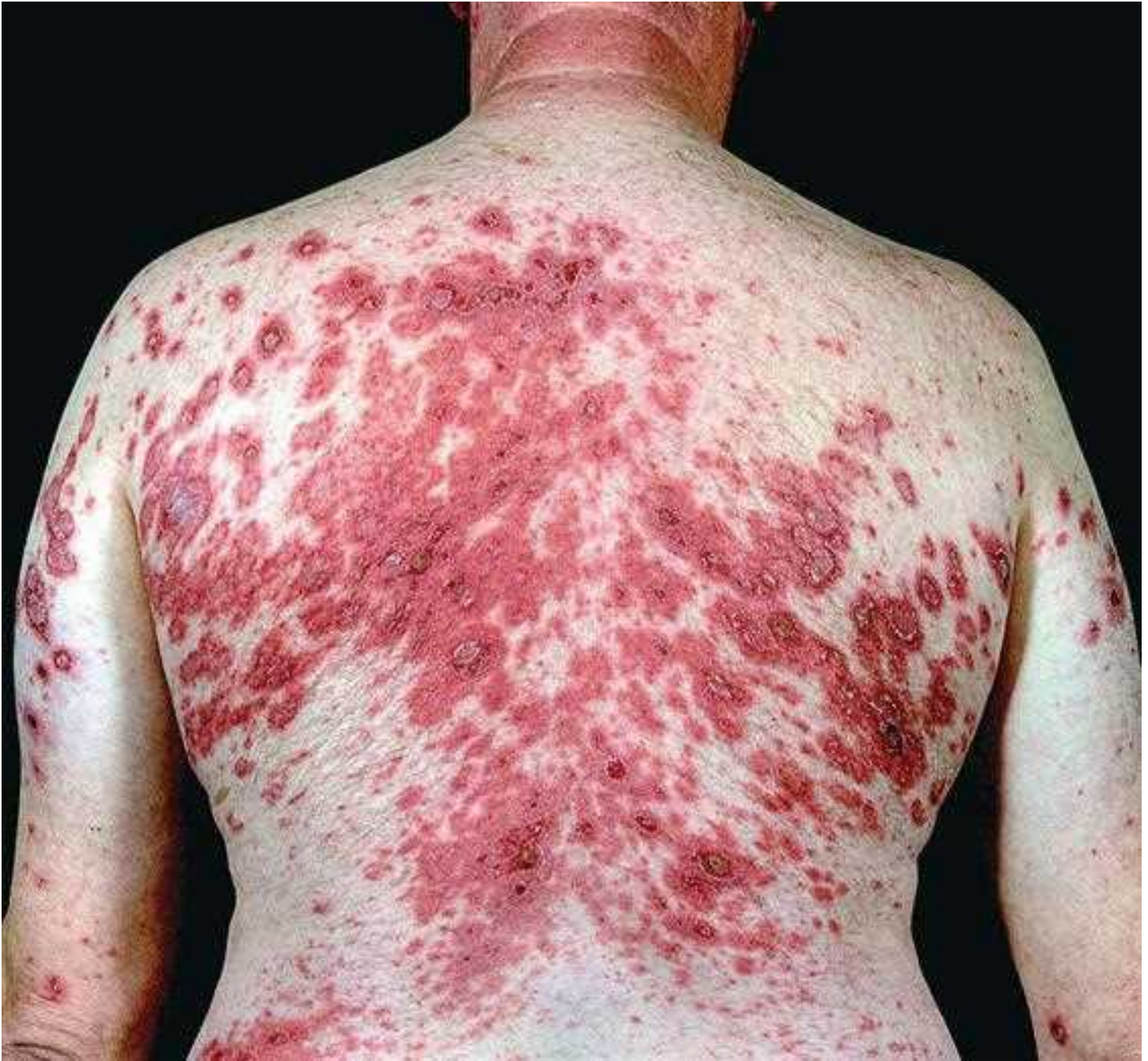
Figure 7.4 Urticaria secondary to penicillin.

Drug-induced lupus

Medication may produce an eruption indistinguishable from cutaneous lupus – in particular, the rash of subacute cutaneous lupus (SCLE) ([Figure 7.5](#)). The patient does not have any pre-existing autoimmune disease, and the condition remits on withdrawal of the culprit drug. The most common drugs to cause drug-induced lupus are listed in [Table 7.1](#), but a recent study named terbinafine as the most common culprit. Antihistone antibodies are present in >95% of cases, but dsDNA is usually negative and complement levels are normal.



[Figure 7.5](#) Drug-induced lupus.

Drug-induced vasculitis

Medication may cause a purpuric eruption that is indistinguishable from vasculitis ([Figure](#)

[7.6](#)). The distribution is usually predominantly in the lower limbs. As viral and bacterial infections may also cause vasculitis, it is often difficult to ascribe causality to a drug, as in cases where an antibiotic is suspected, the patient may also have had a recent infectious episode. In practice, in the absence of overt clinical signs of infection, causality is best determined by withdrawing the suspected culprit drug; if this brings about resolution of the vasculitis, then this adds weight to the diagnosis of a drug-induced phenomenon. Drugs associated with vasculitic eruptions include antibiotics, anticonvulsants, and NSAIDs.

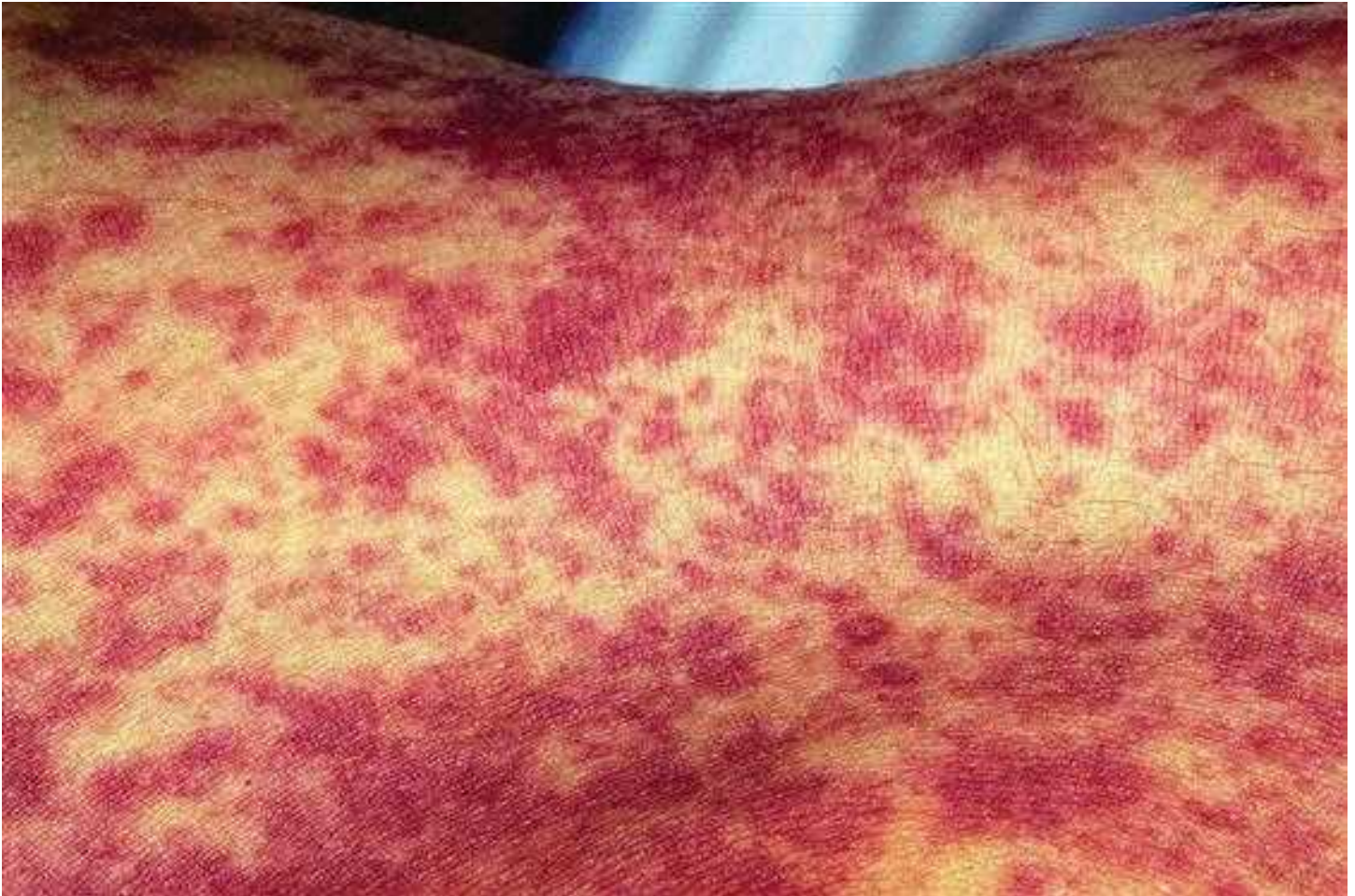
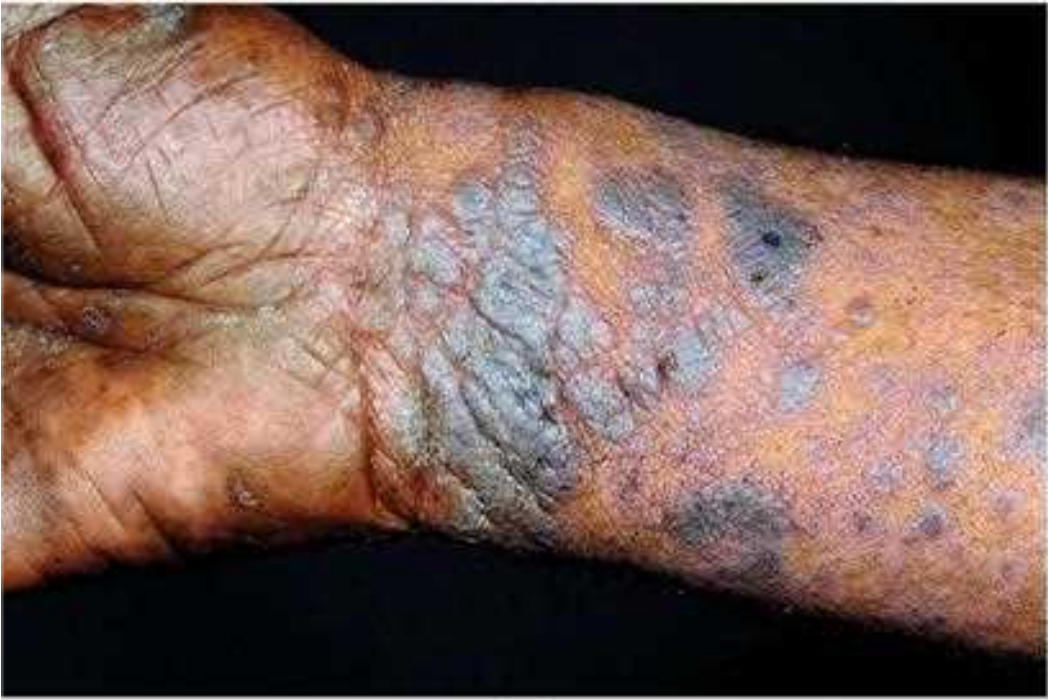
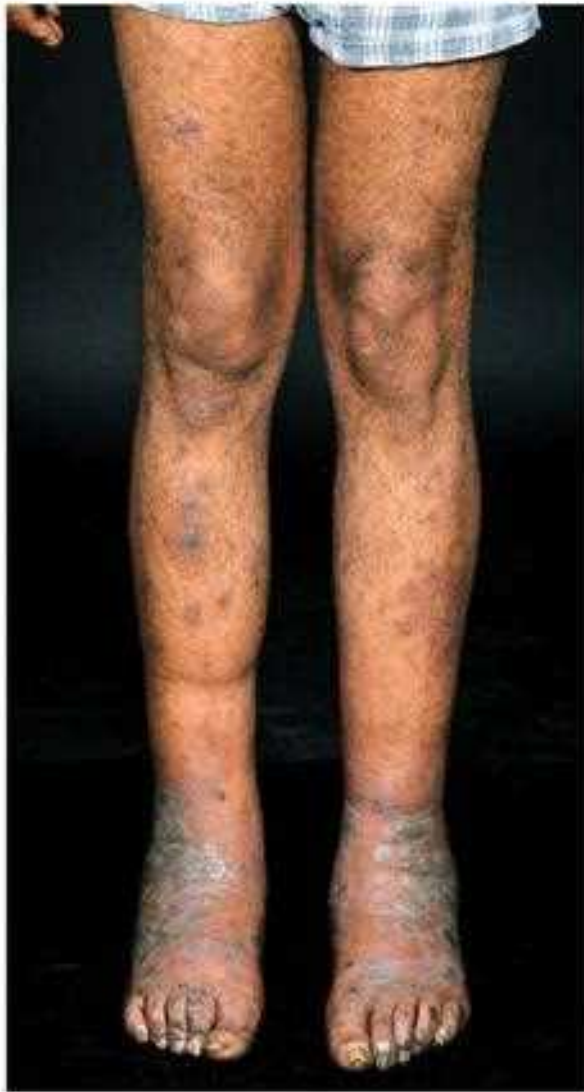Figure 7.6 Drug-induced vasculitis.

Drug eruptions

Lichenoid drug eruptions resemble idiopathic lichen planus, but may not be confined to the classic sites of predilection of the latter. They consist of purplish papules which may have a lace-like white change on their surface ([Figure 7.7a, b](#)). The sites of predilection are the forearms, the neck and inner thighs, but the eruptions can appear anywhere. Onset may be delayed by a number of months following introduction of the culprit medication, leading to difficulties in diagnosing the eruption as drug-induced. Resolution following drug withdrawal can be slow and take up to two months, and the post-inflammatory hyperpigmentation left behind may be dramatic. [Table 7.1](#) illustrates the drugs which most commonly cause lichenoid eruptions.



(a)



(b)

Figure 7.7 (a) Lichenoid drug reaction to nifedipine. (b) Lichenoid drug reaction to nifedipine; note swollen ankles, which is a side effect of calcium channel blockers.

Erythema nodosum

This is a tender, nodular eruption which classically appears on the anterior aspect of the legs. It is characterised histologically by septal panniculitis (inflammation in the subcutaneous fat). Although infective and inflammatory triggers are recognised (such as tuberculosis, *Yersinia* infections, rheumatoid arthritis, lupus, and inflammatory bowel disease), EN may also be a drug-induced phenomenon. Drugs which commonly cause this include the oral contraceptive pill, penicillin and sulfonamide antibiotics, and salicylates.

Fixed drug eruption

This is peculiar phenomenon whereby one or more inflammatory patches appear at the same cutaneous or mucosal site on each occasion that the patient ingests a culprit drug ([Figure 7.8](#)). The time frame for developing the lesion at the characteristic site can vary from 2 to 24 hours. Common sites include the torso, hands, feet, face, and genitalia. The patches resolve sometimes leaving post-inflammatory hyperpigmentation in the skin. Any drug can potentially cause a fixed drug eruption, but those more commonly associated are listed in [Table 7.1](#).

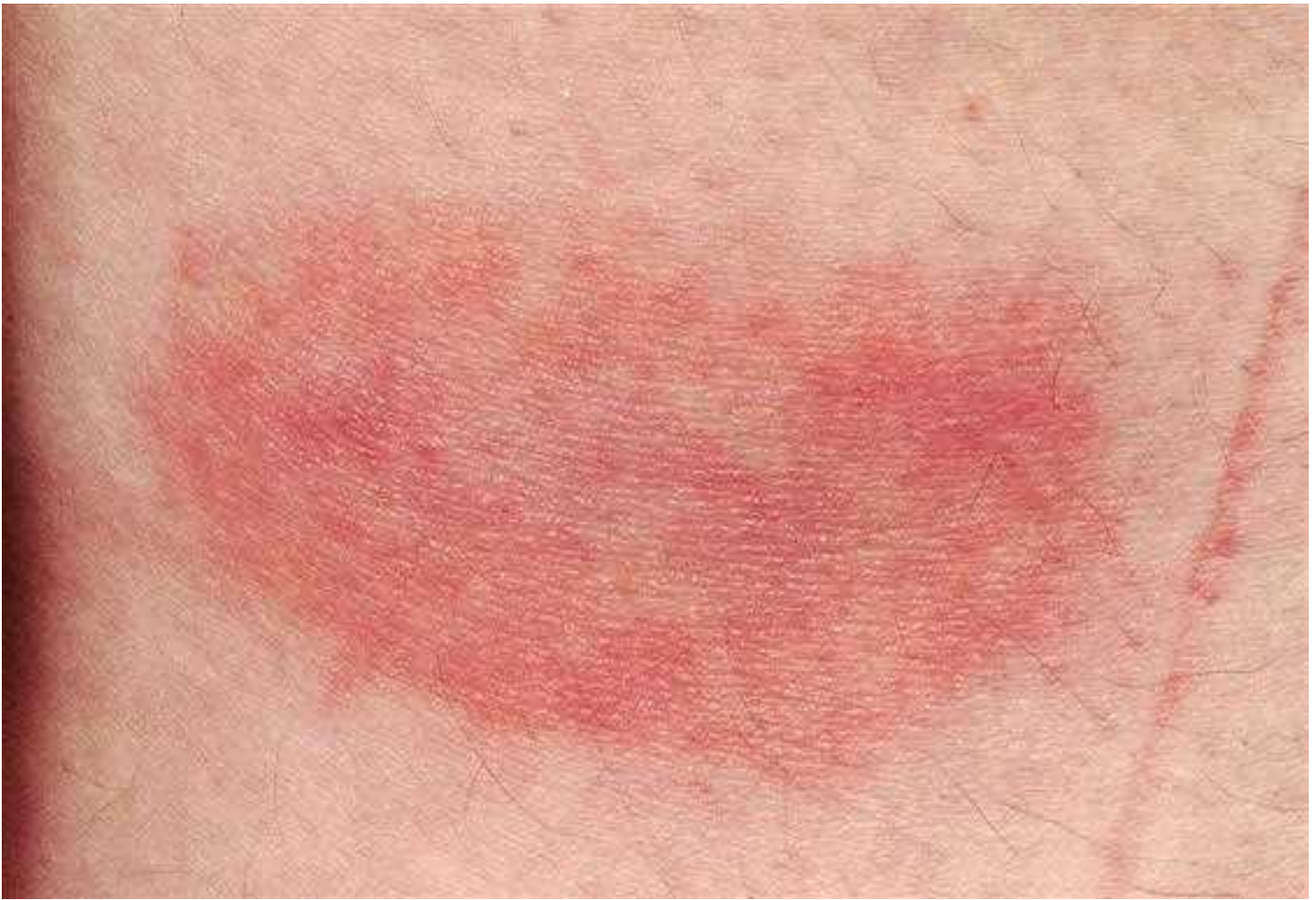

Figure 7.8 Fixed drug eruption.

Severe drug reactions in the skin

Stevens–Johnson Syndrome (SJS) and toxic epidermal necrolysis (TEN)

SJS and TEN are rare, life-threatening drug-induced hypersensitivity reactions in the skin and mucous membranes. This mucocutaneous disorder is characterised by widespread, painful areas of epidermal detachment, and erosions of the mucous membranes, including eyes, mouth, genitalia, and respiratory tract ([Figure 7.9a, b](#)). The appearance of the eruption may be preceded by a prodrome of fever, malaise, and coryzal symptoms, and skin *pain* is often the first cutaneous manifestation, prior to the appearance of the rash. The terms SJS and TEN represent points along a spectrum of severity, with SJS classically denoting <10% BSA detachment, TEN indicating >30% BSA involvement, and the term ‘SJS–TEN overlap’ being used to describe cases with between 10% and 30% loss. Mortality from TEN may be as high as 90% and is estimated using the SCORTEN tool [Table 7.3](#) SCORTEN parameters.

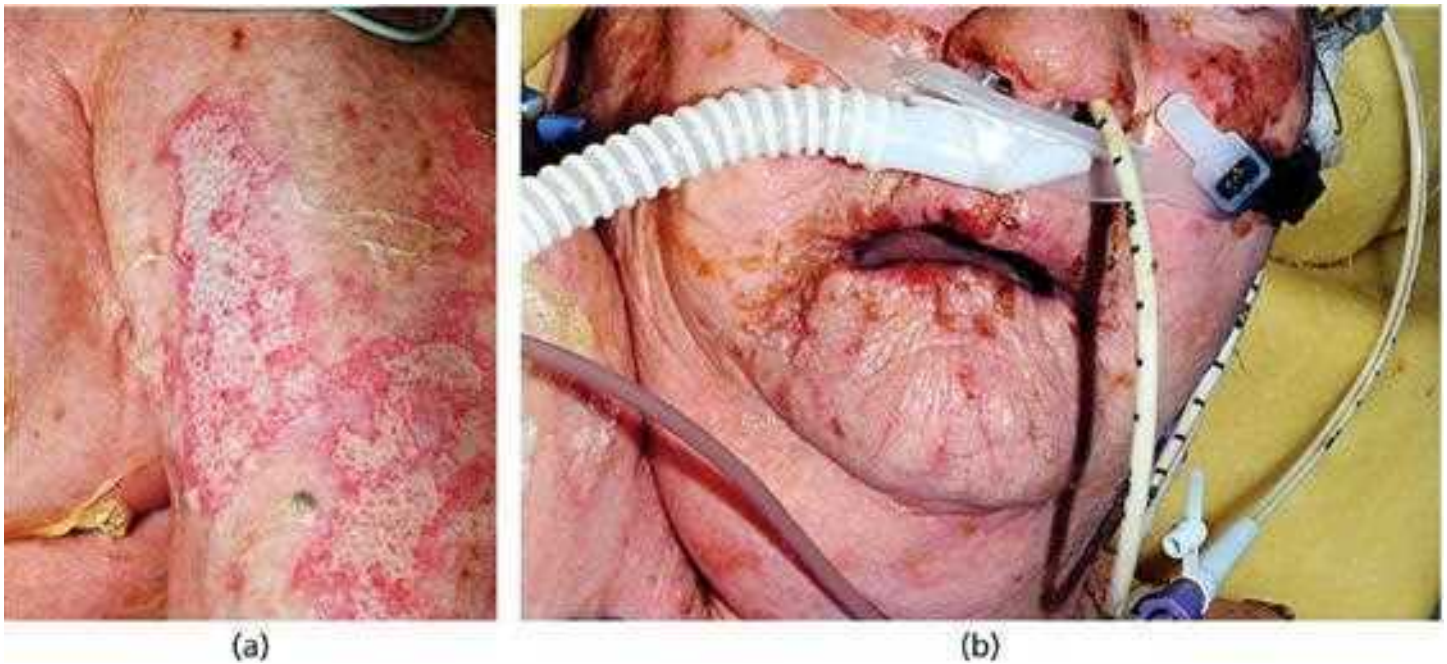


Figure 7.9 (a) Toxic epidermal necrolysis on the trunk. (b) Toxic epidermal necrolysis mucosal involvement.

Table 7.3 SCORTEN parameters.

| SCORTEN parameters (1 point for each) | |
|--|----------------------|
| Age (≥ 40 yr) | |
| Heart rate (≥ 120 bpm) | |
| Cancer/haematological malignancy | |
| Body surface area (BSA) involvement ($> 10\%$) | |
| Serum urea (> 10 mmol/l) | |
| Serum bicarbonate (< 20 mmol/l) | |
| Serum glucose (> 14 mmol/l) | |
| SCORTEN Score | Mortality (%) |
| 0–1 | 3 |
| 2 | 12 |
| 3 | 35 |
| 4 | 58 |
| ≥ 5 | 90 |

In the patient in whom SJS/TEN is suspected, the priority is to stop the offending drug. Common culprits include anticonvulsants, allopurinol, human immunodeficiency virus (HIV) medications, and antibiotics, particularly sulfonamide antibiotics. Treatment in the acute phase consists of supportive care. The patient will require high-dependency care in an intensive care environment, with organ support as dictated by clinical state. In addition to expertise from dermatologists and intensive care physicians, specialist input from

ophthalmology, oral medicine, urology, and gynaecology may be required for site-specific involvement. Skin loss and fragility demand specialist dermatology nursing care, with anti-shear handling, non-adherent dressings, and careful attention to antisepsis to prevent systemic infection. Expectant management of mucosal involvement will help prevent serious sequelae of the illness, described below.

The use of a number of active agents in the treatment of SJS/TEN has been described, including intravenous immunoglobulin, ciclosporin, corticosteroids, thalidomide, infliximab, and etanercept, but there is insufficient evidence to conclusively support the use of any of these.

If the patient survives the acute phase of illness, a number of sequelae may be experienced. Corneal involvement in the acute phase may lead to blindness, involvement of the genital tract may lead to stenoses and the patient may experience dry mouth as a consequence of oral cavity involvement.

Drug reaction with eosinophilia and systemic symptoms (DRESS)

DRESS is a drug-induced phenomenon comprising a constellation of clinical features: a characteristic rash (usually a maculopapular exanthema, associated with head and neck oedema; [Figure 7.10a, b](#)), fever, lymphadenopathy, eosinophilia and involvement of one or more solid organs (usually the liver). Mortality is estimated at 5%, this being largely attributable to the small number of cases who develop fulminant liver failure in the context of DRESS. Other solid organs may also be involved, including the pancreas, the kidneys, the lungs, the heart and thyroid gland. The latency period following drug exposure is generally more protracted than in other drug-induced syndromes, being 15–60 days. For this reason, the diagnosis is often overlooked, and symptoms of rash, fever and lymphadenopathy attributed incorrectly to infection. Management consists of withdrawal of the offending drug plus administration of corticosteroids. The latter may be given topically in the mildest cases, but generally either oral corticosteroids in the form of prednisolone or intravenously in the form of methylprednisolone will be required. Drugs with high notoriety for causing this condition are listed in [Table 7.1](#), with the anticonvulsants and allopurinol accounting for a large proportion of cases.

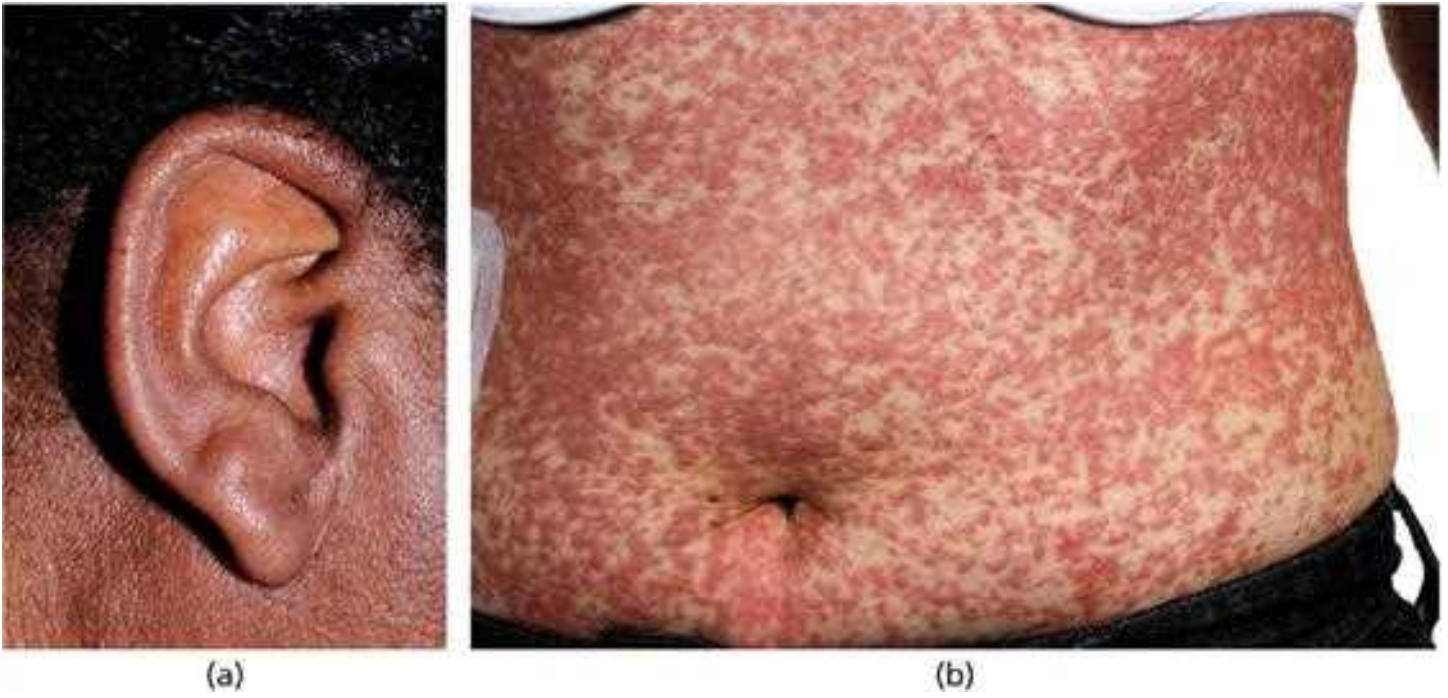
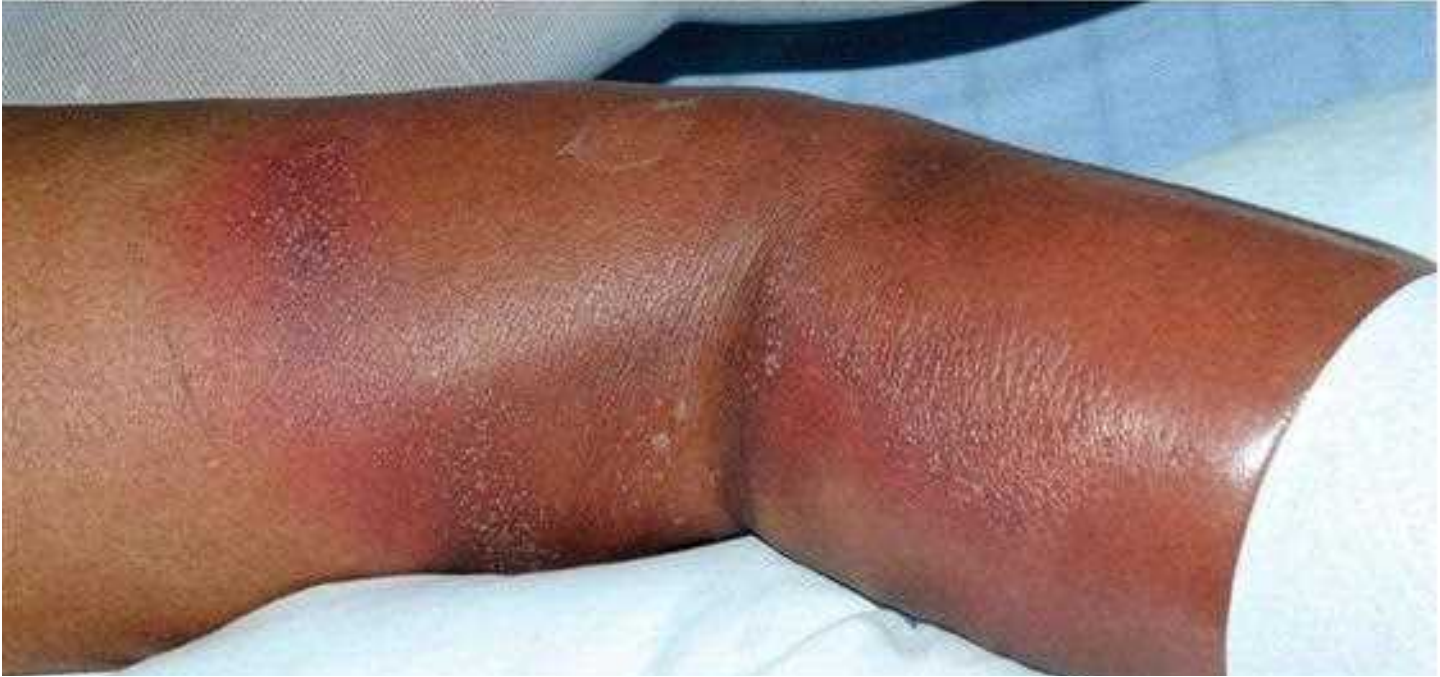

Figure 7.10 (a) DRESS swollen ears. (b) DRESS cutaneous eruption.

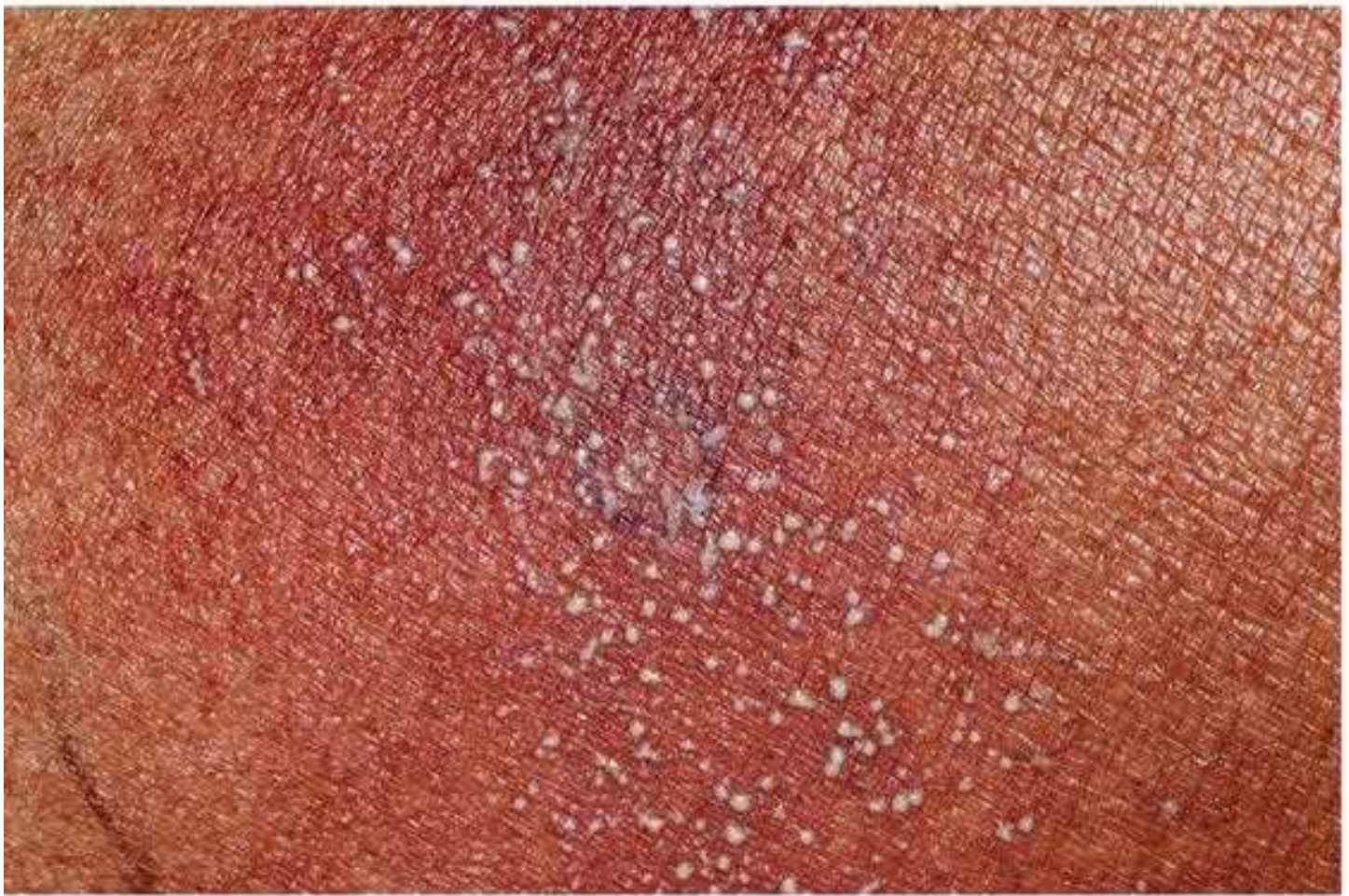Acute generalised exanthematous pustulosis (AGEP)

This is a rare pustular drug reaction recognisable by the appearance of sheets of non-follicular pustules which have a predilection for the major flexures (axillae, groin, and neck) appearing three to seven days after ingestion of a culprit medication ([Figure 7.11a, b](#)). The pustules resolve over three to seven days, in a phase characterised by post-pustular desquamation. The rash may be accompanied by fever and oedema, and in a small number of cases by systemic upset with involvement of the lungs or the liver. Recovery may be accelerated by the use of topical or oral corticosteroids. Antibiotics are the most common culprit drugs.





(a)



(b)

Figure 7.11 (a) Acute generalised exanthematous pustulosis multiple pustules on an erythematous base. (b) Acute generalised exanthematous pustulosis – inflammatory pustules which are non-follicular.

Further reading

Bastuji-Garin, S., Fouchard, N., Bertocci, M. et al. (2000). SCORTEN: a severity-of-illness score for toxic epidermal necrolysis. *Journal of Investigative Dermatology* **115**: 149–153.

Kardaun, S.H. (2012). *Severe Cutaneous Adverse Drug Reactions: Challenges in Diagnosis and Treatment*. Groningen: Uitgeverij Boxpress.

Revuz, J., Roujeau, J.-C., Kerdel, F. et al. (2009). *Life-Threatening Dermatoses and Emergencies in Dermatology*. Berlin: Springer.

CHAPTER 8

Immunobullous and Other Blistering Disorders

Rachael Morris-Jones

Guy's and St Thomas' NHS Foundation Trust, London, UK

OVERVIEW

- Blisters arise from destruction or separation of epidermal cells by trauma, viral infection, immune reactions, oedema as in eczema or inflammatory causes such as vasculitis.
- Immune reactions at the dermoepidermal junction and intraepidermally cause blisters.
- Susceptibility is inherited; trigger factors include genetic conditions, drugs, gluten, viral infections, hormones, and ultraviolet radiation.
- Differential diagnosis depends on specific features, in particular the duration, durability, and distribution of lesions.
- The most important immunobullous conditions are bullous pemphigoid, pemphigus, dermatitis herpetiformis (DH) and linear IgA.
- Investigations should identify underlying causes and the site and nature of any immune reaction in the skin.
- Management includes topical treatment, immunosuppressive drugs and a gluten-free diet.

Introduction

Blisters, whether large bullae or small vesicles, can arise in a variety of conditions. Blisters may result from *destruction* of epidermal cells (a burn or a herpes virus infection). *Loss of adhesion* between the cells may occur within the epidermis (pemphigus) or at the basement membrane (pemphigoid). In eczema there is *oedema* between the epidermal cells, resulting in spongiosis. Sometimes, there are associated *inflammatory* changes in the dermis (erythema multiforme/vasculitis) or a metabolic defect (as in porphyria). Genetic conditions (Epidermolysis bullosa) affecting adhesion structures can lead to skin fragility, blistering, and epidermal loss.

The integrity of normal skin depends on intricate connecting structures between cells ([Figure 8.1](#)). In autoimmune blistering conditions autoantibodies attack these adhesion structures. The level of the separation of epidermal cells within the epidermis is determined by the

specific structure that is the target antigen. Clinically, these splits are visualised as superficial blisters which may be fragile and flaccid (intraepidermal split) or deep mainly intact blisters (subepidermal split). Therefore, the clinical features can be used to predict the level of the underlying target antigen in the skin.

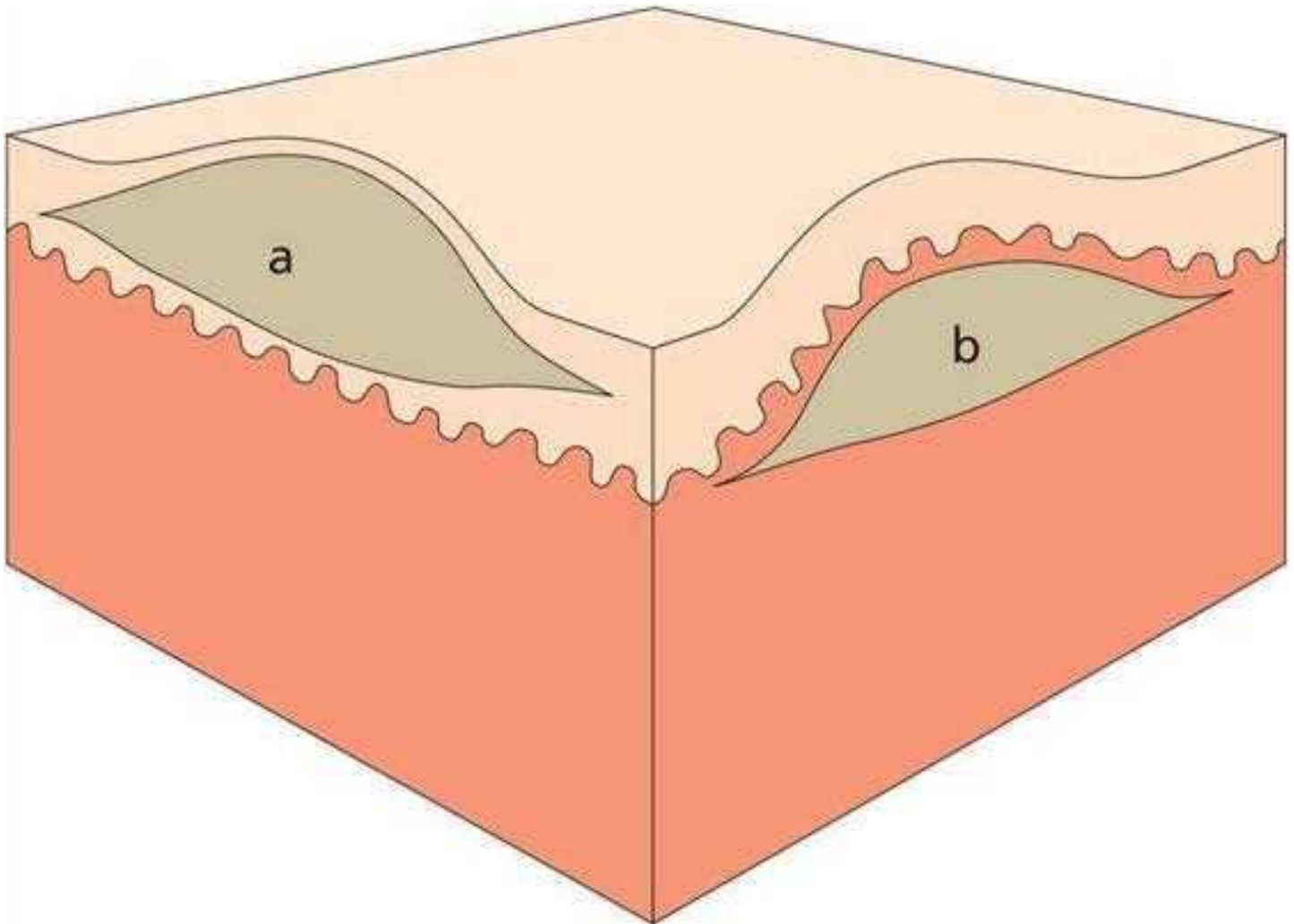


Figure 8.1 Section through the skin with (a) intraepidermal blister and (b) subepidermal blister.

Pathophysiology

Susceptibility to develop autoimmune disorders may be inherited, but the triggers for the production of these skin-damaging autoantibodies remains unknown. In some patients possible triggers have been identified including drugs (rifampicin, captopril, and D-penicillamine), certain foods (garlic, onions, and leeks), viral infections, hormones, ultraviolet (UV) radiation and X-rays.

Bullous pemphigoid results from IgG autoantibodies that target the basement membrane cells (hemidesmosome proteins BP180 and BP230). Studies have demonstrated a reduction in circulating regulatory T-cells (Treg) and reduced levels of interleukin-10 (IL-10) in patients with bullous pemphigoid, which partially correct following treatment. Complement activates

an inflammatory cascade, leading to disruption of skin cell adhesion and blister formation. The subepidermal split leads to tense bullae formation.

Pemphigus vulgaris results from autoantibodies directed against desmosomal cadherin desmoglein 3 (Dsg3) found between epidermal cells in mucous membranes and skin. This causes the epidermal cells to separate, resulting in intraepidermal blister formation. This relatively superficial split leads to flaccid blisters and erosions (where the blister roof has sloughed off). Pemphigus foliaceus (PF) is a rare autoimmune skin disease characterised by subcorneal blistering and IgG antibodies directed against desmoglein 1 (Dsg1) usually manifested at UV-irradiated skin sites.

Dermatitis herpetiformis (DH) is caused by IgA deposits in the papillary dermis which results from chronic exposure of the gut to dietary gluten triggering an auto-immunological response in genetically susceptible individuals. IgA antibodies develop against gluten-tissue transglutaminase (found in the gut) and these cross-react with epidermal-transglutaminase, leading to cutaneous blistering.

Differential diagnosis

Many cutaneous disorders present with blister formation. Presentations include large single bullae through to multiple small vesicles, and differentiating the underlying cause can be a clinical challenge ([Table 8.1](#)). The history of the blister formation can give important clues to the diagnosis, in particular the development, duration, durability, and distribution of the lesions – the ‘four Ds’.

Table 8.1 Differential diagnosis of immunobullous disorders – other causes of cutaneous blistering.

| Other causes of cutaneous blistering | Key clinical features | Diagnostic tests | Further reading |
|---|--|--|----------------------------|
| Epidermolysis bullosa | Neonatal period fragile skin, blisters, erosions usually at sites of pressure/trauma | Skin biopsy done at specialist centres to identify the level of the split and the defect in adhesion | Chapter 8 |
| Erythema multiforme | Target lesions with a central blister, acral sites | Skin biopsy for histology | Chapter 7 |
| Stevens–Johnson syndrome/toxic epidermal necrolysis | Mucous membrane involvement, Nikolsky-positive, eroded areas of skin | Skin biopsy for histology | Chapter 7 |
| Chickenpox | Scattered blisters in crops appear over days | Viral swab to detect varicella zoster virus (VZV); serology | Chapter 14 |
| Herpes simplex/varicella zoster virus | Localised blistering of mucous membranes or dermatomal | Vesicle fluid for viral analysis | Chapter 14 |
| <i>Staphylococcus impetigo</i> | Golden crusting associated with blisters | Bacterial swab for culture | Chapter 13 |
| Insect bite reactions | Linear or clusters of blisters, very itchy | Clinical diagnosis | Chapter 17 |
| Contact dermatitis | Exogenous pattern of blisters | Patch testing | Chapter 4 |
| Phytophotodermatitis | Blisters where plants/extracts touched the skin plus sunlight exposure | Clinical diagnosis | Chapter 6 |
| Porphyria | Fragile skin with scarring at sun-exposed sites | Urine, blood, faecal analysis for porphyrins | Chapter 6 |
| Fixed drug eruption | Blistering purplish lesion/s at a fixed site each time drug taken | Skin biopsy for histology | Chapter 7 |

Development

If erosions or blisters are present at birth then genodermatoses (Epidermolysis bullosa) must be considered in addition to cutaneous infections. Preceding systemic symptoms may suggest an infectious cause such as chickenpox or hand, foot and mouth disease. A tingling sensation

may herald herpes simplex, and pain, herpes zoster. If the lesions are pruritic, then consider DH or pompholyx eczema. Eczema may precede bullous pemphigoid.

Duration

Some types of blistering arise rapidly (allergic reactions, impetigo, erythema multiforme and pemphigus), while others have a more gradual onset and follow a chronic course (DH, pityriasis lichenoides, porphyria cutanea tarda, and bullous pemphigoid). The rare genetic disorder epidermolysis bullosa is present from, or soon after, birth and has a chronic course.

Durability

The blisters themselves may remain intact or rupture easily and this sign can help elude the underlying diagnosis. Superficial blisters in the epidermis have a fragile roof that sloughs off easily leaving eroded areas typically seen in pemphigus vulgaris, porphyria, Stevens–Johnson syndrome, toxic epidermal necrolysis, staphylococcal scalded skin, and herpes viruses. Subepidermal blisters have a stronger roof and usually remain intact and are classically seen in bullous pemphigoid, linear IgA, and erythema multiforme. Scratching can result in traumatic removal of blister roofs, which may confuse the clinical picture.

Distribution

The distribution of blistering rashes helps considerably in making a clinical diagnosis ([Boxes 8.1](#) and [8.2](#)). In general, immunobullous diseases present with widespread eruptions with frequent mucous membrane involvement. Herpes infections usually remain localised to lips, genitals, or dermatomes. Photosensitive blistering disorders involve sun-exposed skin.

Box 8.1 Widespread blistering eruptions

- Bullous pemphigoid.
- Pemphigus vulgaris.
- DH (or localised).
- Erythema multiforme.
- Drug rashes: Stevens–Johnson syndrome, toxic epidermal necrolysis.
- Chickenpox.

Box 8.2 Localised blistering eruptions

- Epidermolysis bullosa (hands/feet/buttocks)
- DH (knees, elbows, and buttocks)
- Pemphigus gestationis (abdomen)
- PF (upper trunk, face, and scalp)
- Porphyria (sun-exposed sites)
- Pompholyx eczema (hands and feet)
- Contact dermatitis
- Fixed drug eruption
- Insect bite reactions (often in clusters or linear patterns)
- *Infections*. Herpes simplex, herpes zoster, and staphylococcus (impetigo).

Clinical features of immunobullous disorders

Clinical features of the different immunobullous disorders ([Table 8.2](#)) are discussed in the following subsections.

Table 8.2 Clinical features of immunobullous disorders.

| Immunobullous disorder | Typical patient | Distribution of rash | Morphology of lesions | Mucous membrane involvement | Associated conditions |
|-------------------------------|------------------------|--|--|------------------------------------|--|
| Bullous pemphigoid | Elderly | Generalised | Intact blisters | Common | None |
| Mucous membrane pemphigoid | Middle-aged or older | Varied | Erosions, flaccid blisters, scarring | Severe and extensive | Autoimmune disease |
| Pemphigoid gestationis | Pregnant | Periumbilical | Intact blisters, urticated lesions | Rare | Thyroid disease |
| Pemphigus vulgaris | Middle-aged | Flexures, head | Flaccid blisters, erosions | Common | Autoimmune disease |
| Dermatitis herpetiformis | Young adults | Elbows, knees, buttocks | Vesicles, papules, excoriations | Rare | Small bowel enteropathy (gluten-sensitive), lymphoma |
| Linear IgA | Children and adults | Face and perineum (children) Trunk and limbs (adults) | Annular urticated plaques with peripheral vesicles | Common | Lymphoproliferative disorders |
| Paraneoplastic pemphigus | Older patients | Mucous membranes (mouth/eyes) skin sites | Severe erosive stomatitis, polymorphous skin lesions | Rare | Lymphoproliferative disorders, carcinoma, thymoma, sarcoma |

Bullous pemphigoid

This usually presents over the age of 65 years with tense blisters and erosions on a background of dermatitis or normal skin ([Figure 8.2](#)). The condition may present acutely or be insidious in onset, but usually enters a chronic intermittent phase before remitting after approximately five years. Some patients have a prolonged pre-bullous period in which persistent pruritic urticated plaques ([Figure 8.3](#)), or eczema, precedes the blisters. Characteristically, blisters have a predilection for flexural sites on the limbs and trunk. Mucous membrane involvement occurs in about 20% of cases ([Figure 8.4](#)). Blisters heal without scarring. Potential triggers include vaccinations, drugs (non-steroidal anti-

inflammatory drugs (NSAIDs)), furosemide, ACE (angiotensin-converting enzyme inhibitors and antibiotics), UV radiation, and X-rays. In children bullous pemphigoid usually follows vaccination, where the condition characteristically affects the face, palms, and soles.

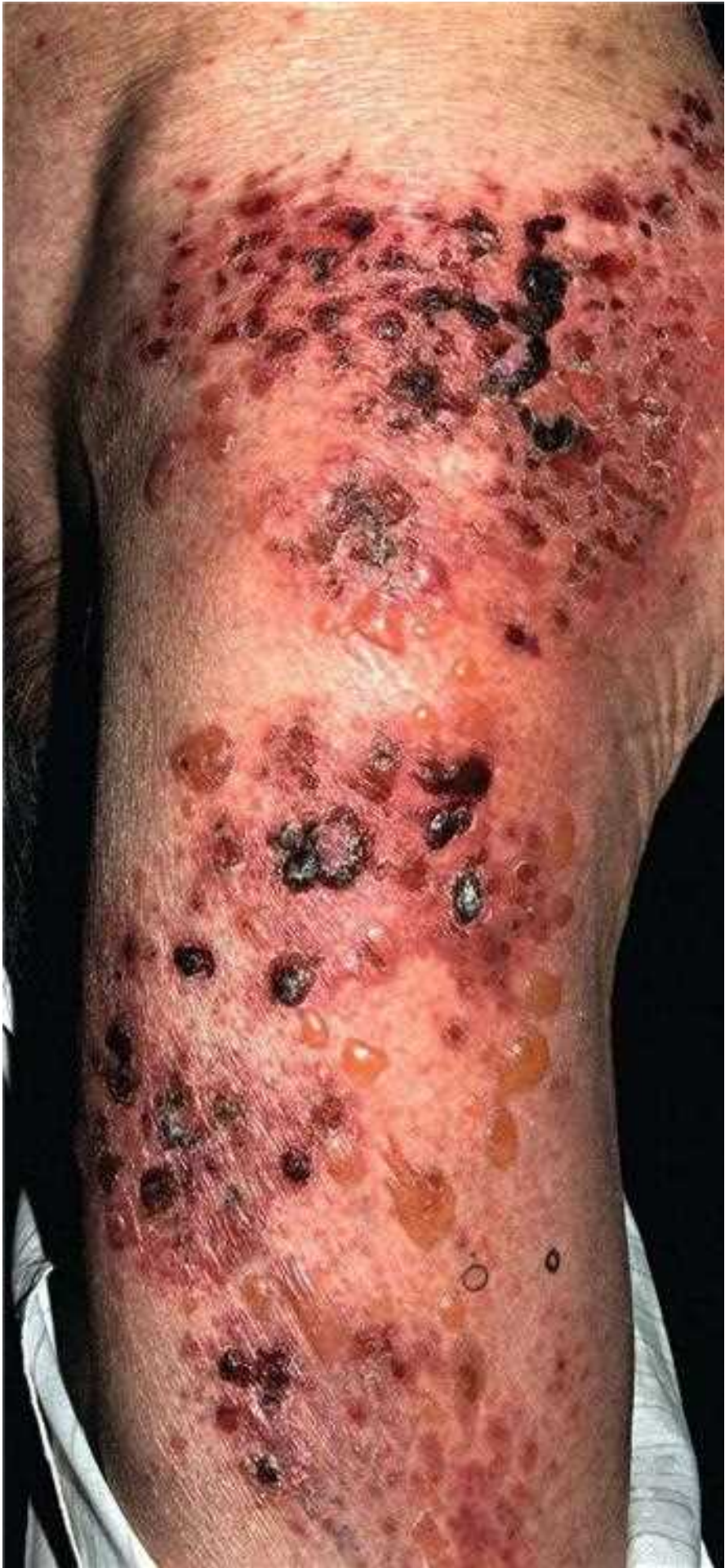

Figure 8.2 Bullous pemphigoid.

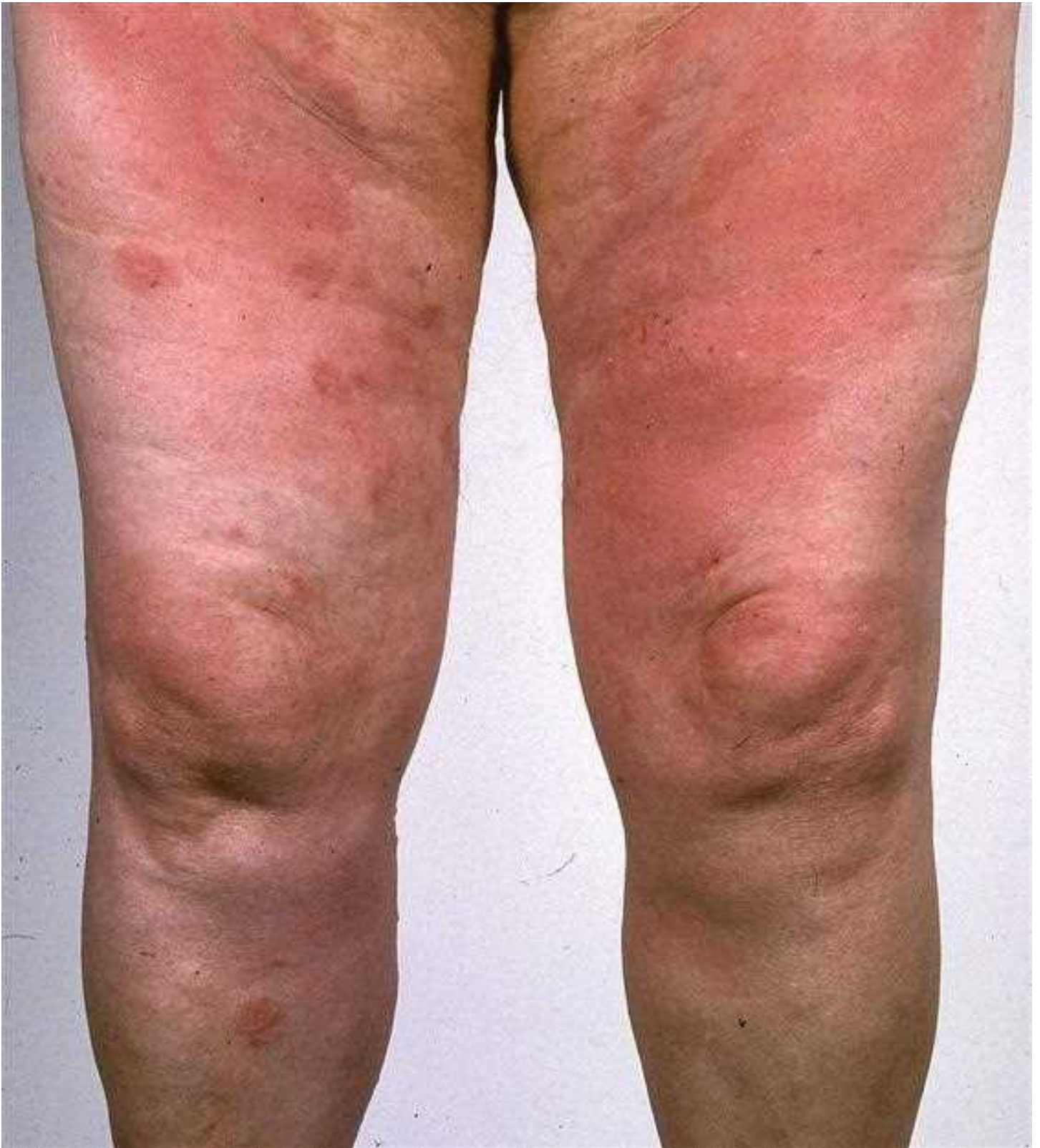

Figure 8.3 Urticated plaques in pre-bullous pemphigoid.

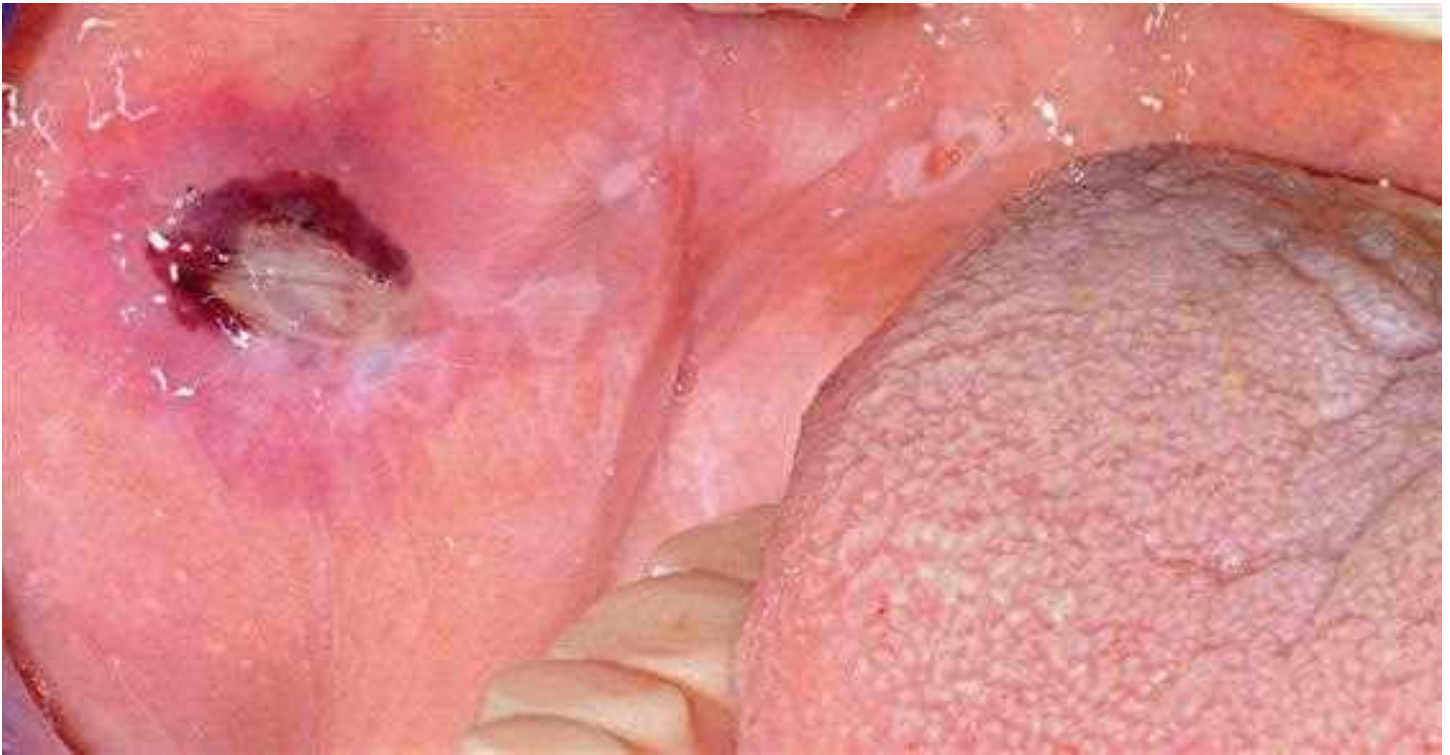

Figure 8.4 Bullous pemphigoid: showing mouth erosions.

Pemphigoid gestationis

This rare autoimmune disorder usually occurs in the second/third trimester of pregnancy. Mothers may have other associated autoimmune conditions. Acute-onset intensely pruritic papules, plaques, and blisters spread from the periumbilical area outwards ([Figure 8.5](#)). Mucous membrane involvement can occur. Babies may be born prematurely or small for dates and can have a transient blistering eruption that rapidly resolves. The maternal cutaneous eruption usually resolves within weeks after birth, but may flare immediately post-partum.

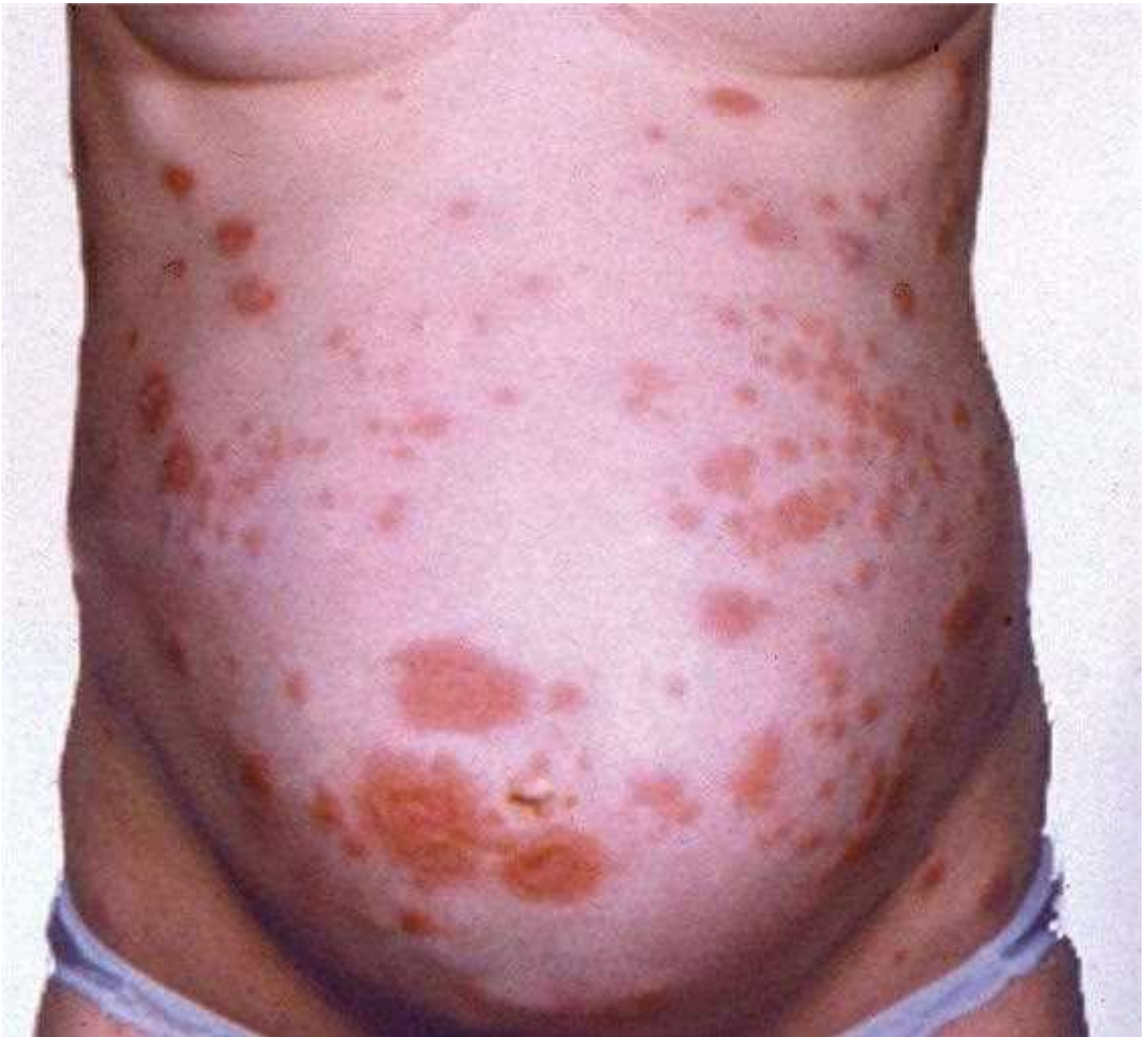

Figure 8.5 Pemphigoid gestationis on the abdomen.

Mucous membrane pemphigoid (cicatricial pemphigoid)

Patients usually present with painful sores in their mouth, nasal and genital mucosae, and may complain of a gritty feeling in their eyes. Cutaneous lesions occur in around 30% of patients; tense blisters may be haemorrhagic and heal with scarring ([Figure 8.6](#)). Scalp involvement can lead to scarring alopecia ([Figure 8.7](#)). Symptoms from mucous membrane sites can be very severe, with chronic painful erosions and ulceration that heals with scarring.

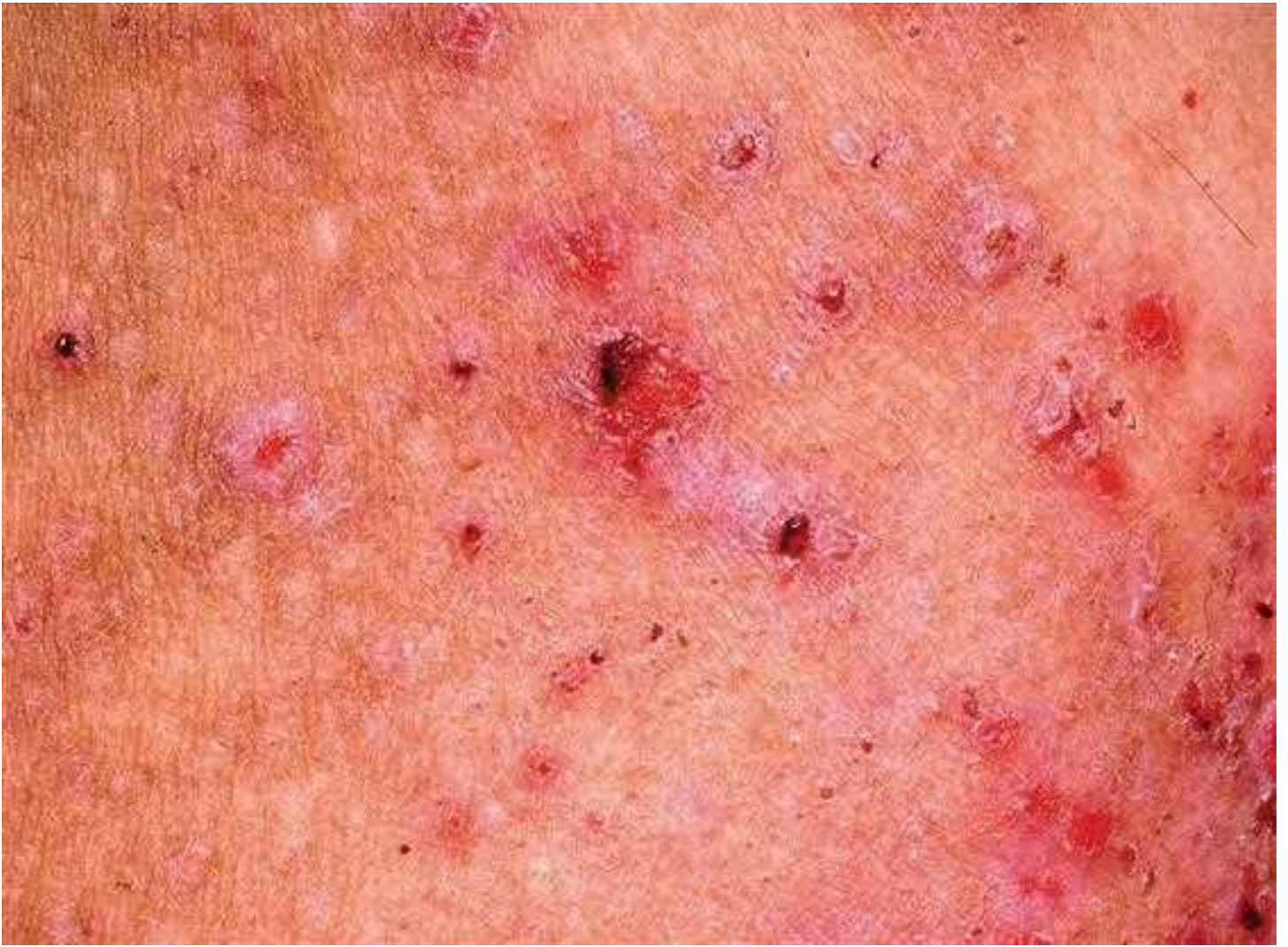

Figure 8.6 Mucous membrane pemphigoid: scarring skin eruption.

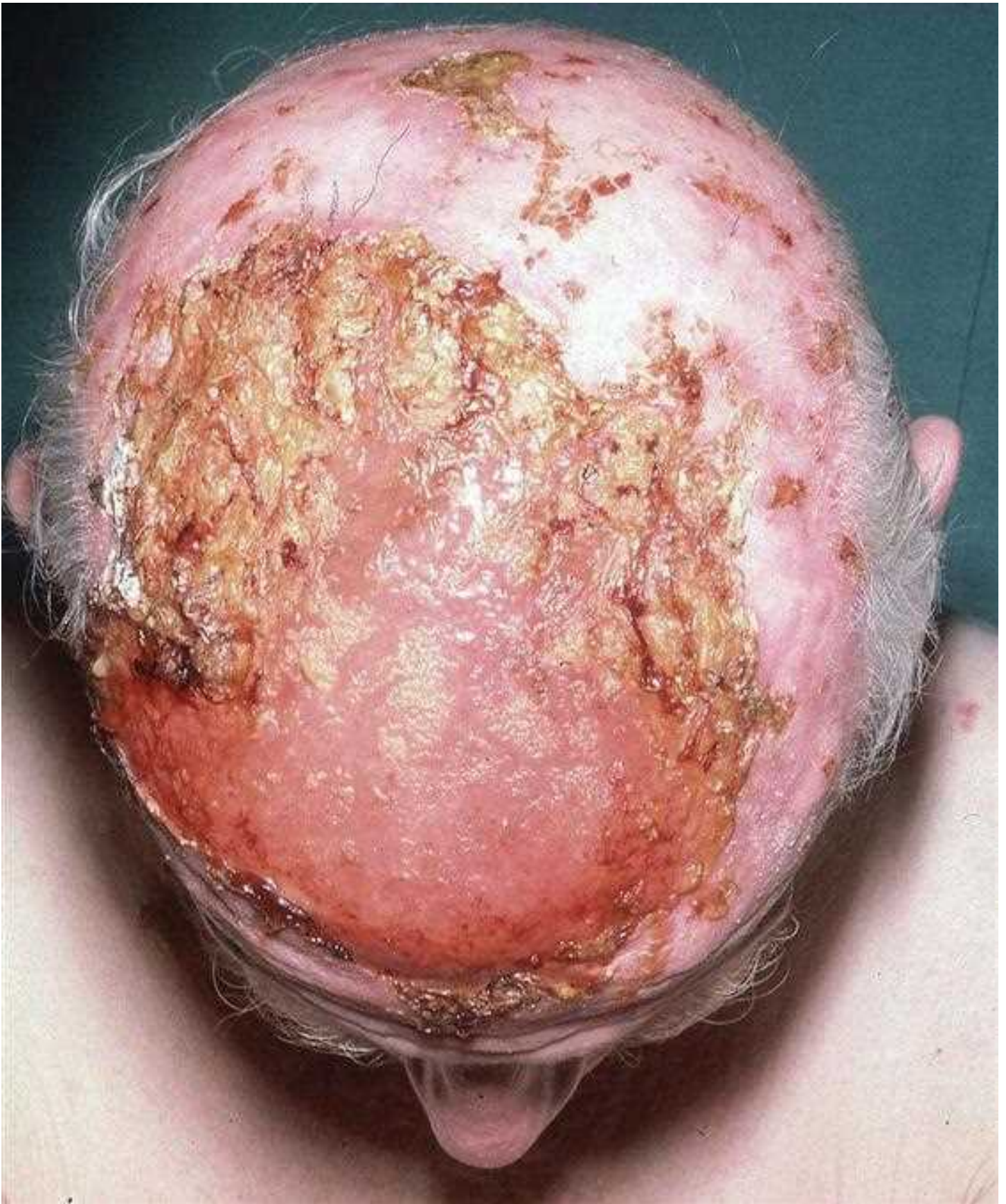

Figure 8.7 Mucous membrane pemphigoid on the scalp.

Ocular damage ([Figure 8.8](#)) can include symblepharon (tethering of conjunctival epithelium),

synechiae (adhesion of iris to cornea), and fibrosis of the lacrimal duct (dry eyes) resulting in opacification, fixed globe, and eventually blindness.

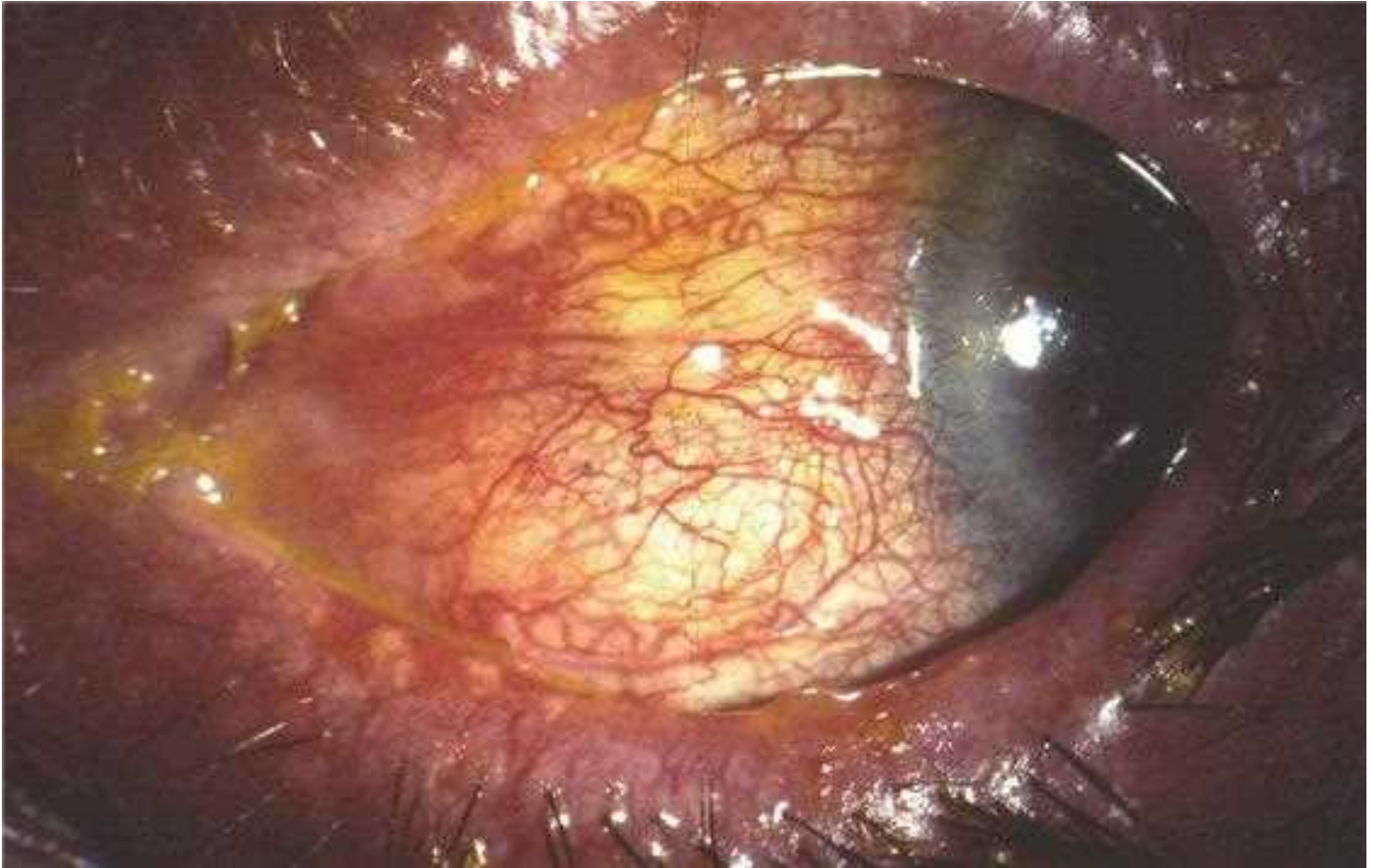


Figure 8.8 Mucous membrane pemphigoid: eyes.

Pemphigus vulgaris

Although it is a rare condition, it is more common on Ashkenazi Jews, individuals from India, Southeastern Europe, and the Middle East. Seventy percent of patients develop oral lesions in chronic progressive pemphigus vulgaris. Mucous membrane involvement may precede cutaneous signs by several months. Skin lesions do, however, occur in most patients and are characterised by painful flaccid blisters and erosions arising on normal skin ([Figure 8.9](#)). The bullae are easily broken, and even rubbing apparently normal skin causes the superficial epidermis to slough off (Nikolsky sign positive).

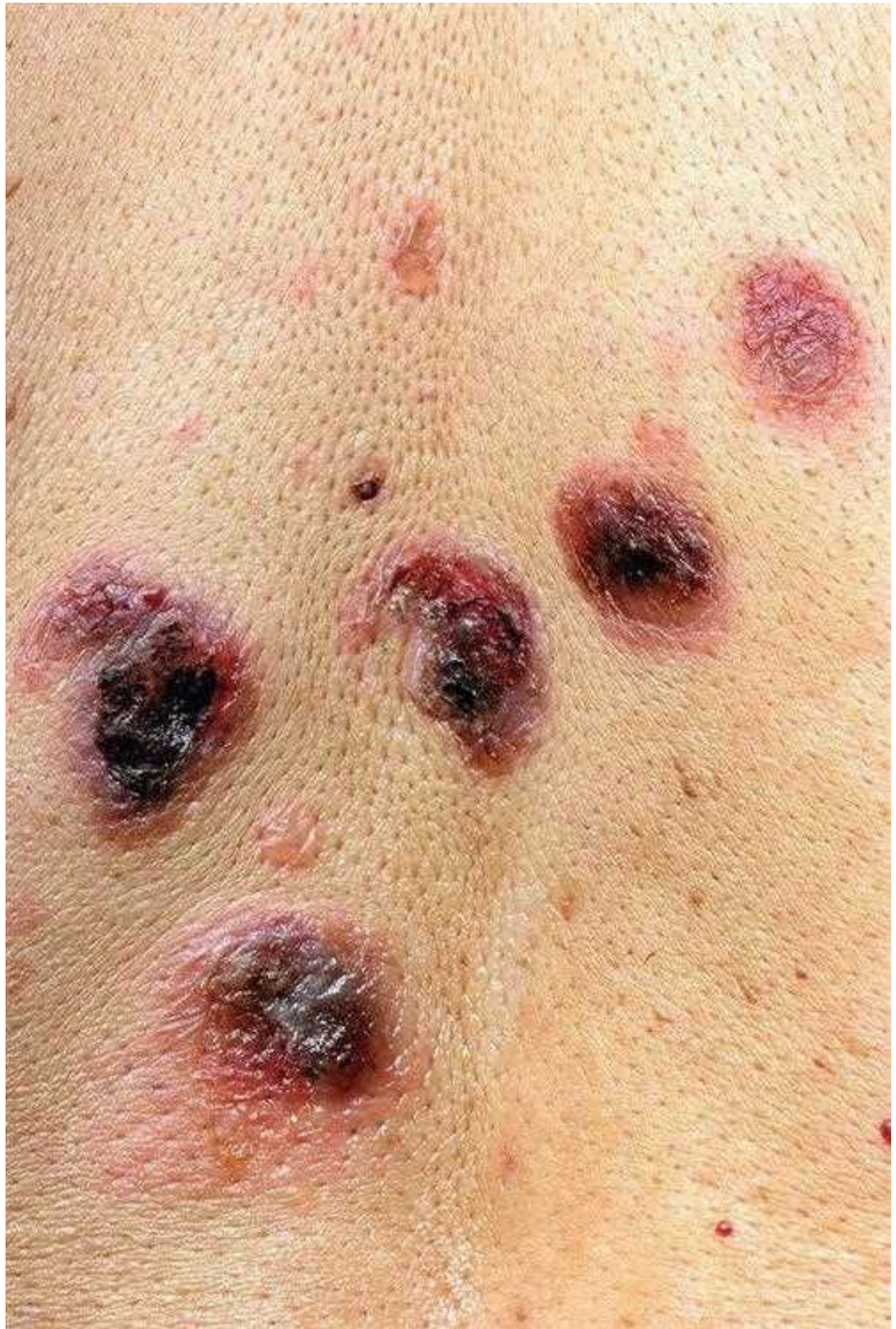

Figure 8.9 Pemphigus vulgaris on the trunk.

Slow-healing painful erosions occur in the mouth, particularly on the soft/hard palate and buccal mucosae, but the larynx may also be affected. The oral cavity lesions may be so severe that patients have difficulty eating, drinking, and brushing their teeth ([Figure 8.10](#)). Recognised drug triggers of pemphigus vulgaris include rifampicin, ACE inhibitors, and penicillamine. Paraneoplastic pemphigus is clinically similar to pemphigus vulgaris but with an associated underlying malignancy such as non-Hodgkin's lymphoma or chronic lymphocytic leukaemia.

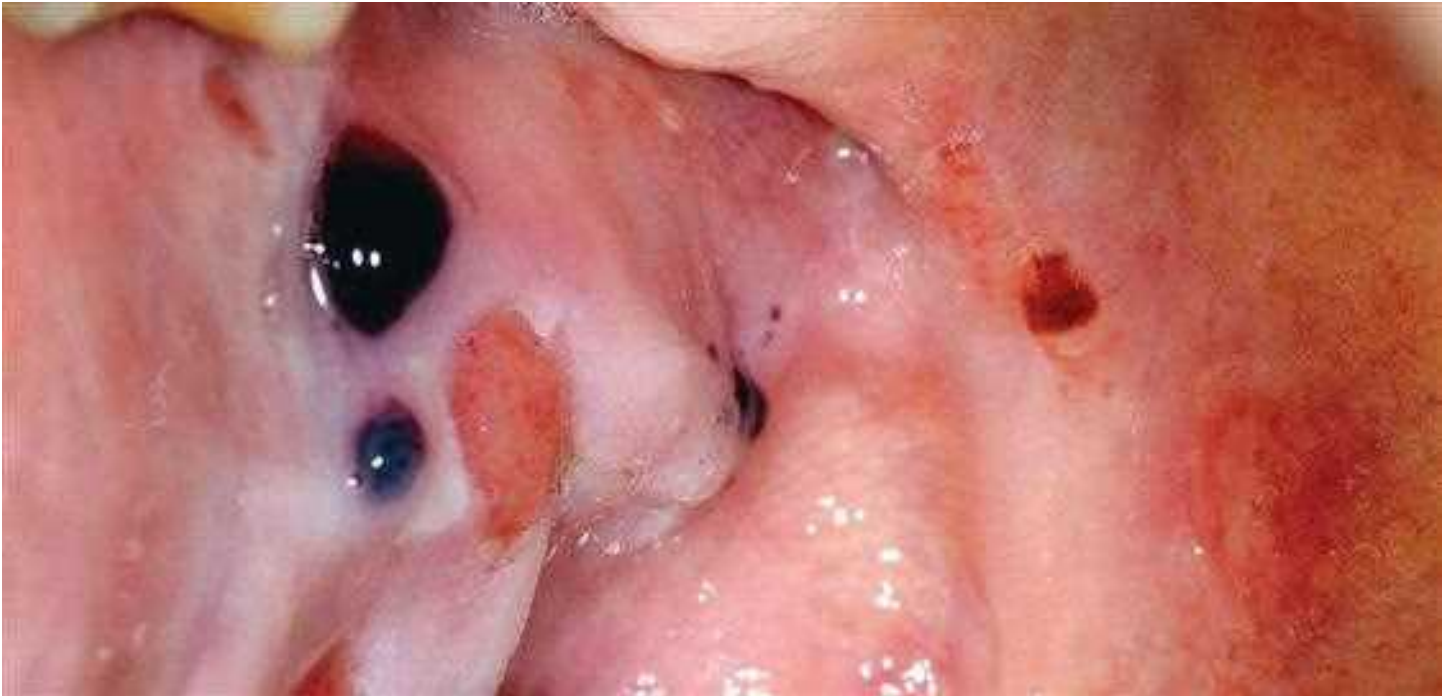

Figure 8.10 Pemphigus vulgaris in the mouth.

PF tends to affect patients in middle age and is characterised by flaccid small bullae on the trunk, face, and scalp that rapidly erode and crust. Drugs may induce PF; the most commonly reported are penicillamine, nifedipine, captopril, and NSAIDs.

Dermatitis herpetiformis (DH)

This is an intensely pruritic autoimmune blistering disorder that affects Northern Europeans who are young/middle-aged adults and is associated with an underlying gluten-sensitive enteropathy. Several human leukocyte antigen (HLA) types have been identified in patients with DH, most patients carry the HLA DQ2 or HLA DQ8 haplotype and 10% of patients report an affected relative. Cutaneous lesions are characteristically intermittent and mainly affect the buttocks, knees ([Figure 8.11](#)) and elbows. The intense pruritus leads to excoriation of the small vesicles which are consequently rarely seen intact by clinicians. Most patients do not report any bowel symptoms unless prompted; but may experience bloating and diarrhoea. Low ferritin and folate can result from malabsorption. Small bowel investigation reveals abnormalities (villous atrophy, raised lymphocyte count) in 90% of patients. There is an

increased frequency of small bowel lymphoma in patients with enteropathy.

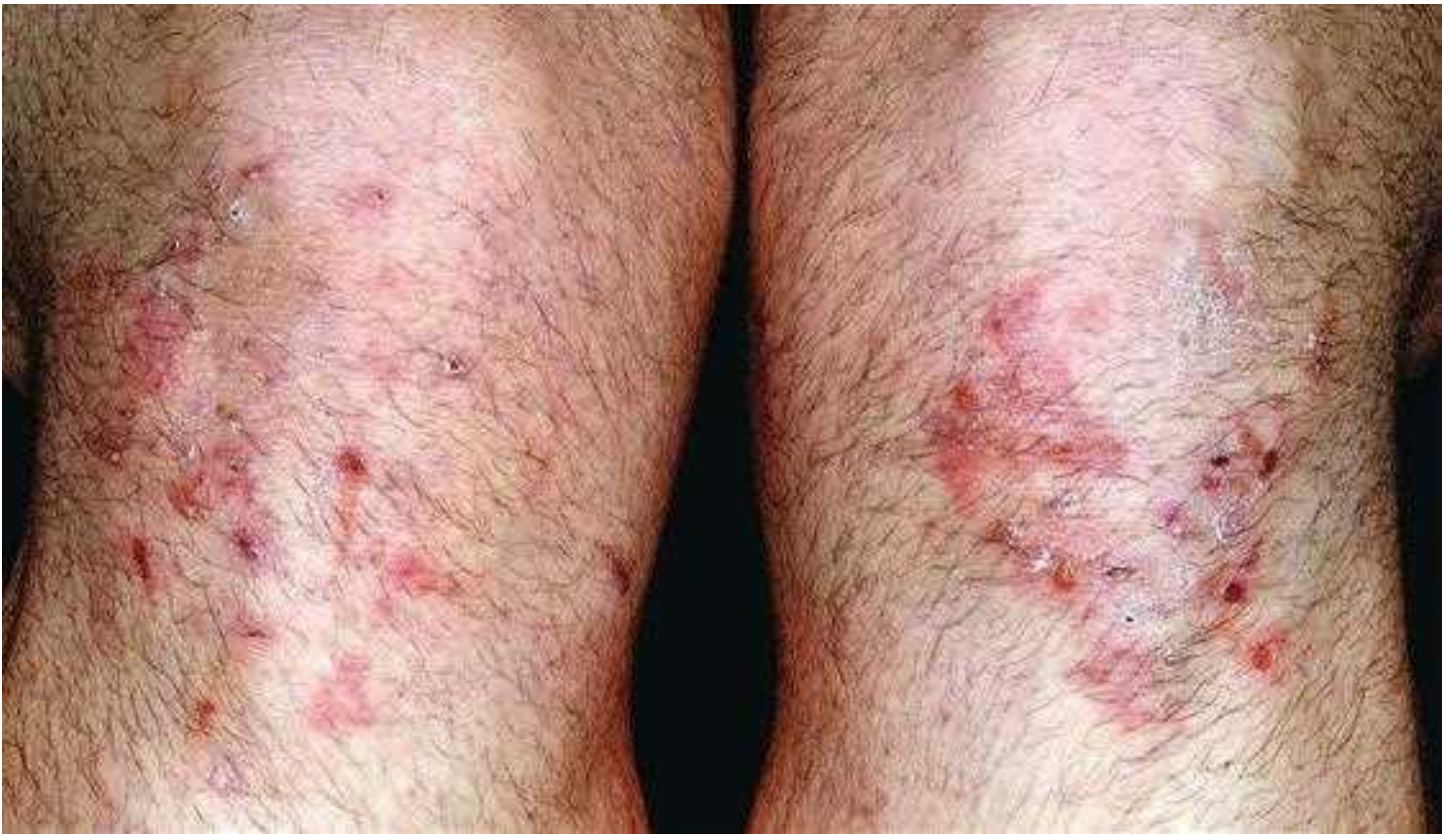

Figure 8.11 Dermatitis herpetiformis on the knees.

DH patients should be encouraged to follow a strict gluten-free diet, as this should control the cutaneous and gastrointestinal symptoms and is thought to reduce the risk of small bowel lymphoma. Patients should avoid wheat, rye, and barley. Dapsone and sulfapyridine can be used to control symptoms if dietary manipulation is unsuccessful. DH is a chronic condition and therefore lifelong management is needed.

Linear IgA

Children and adults can be affected by this autoimmune subepidermal blistering disorder. The clinical picture is heterogeneous, ranging from acute onset of blistering to insidious pruritus before chronic tense bullae. In children, the blisters tend to affect the lower abdomen and perineum, whereas in adults the limbs and trunk are most commonly affected ([Figure 8.12](#)). Blisters are usually intact and are classically seen around the periphery of annular lesions ('string of beads sign') or in clusters ('jewel sign'). Mucous membrane involvement is common. Reported drug triggers include vancomycin, ampicillin, and amiodarone. Management is similar to that for DH, with patients responding to dapsone and sulfapyridine.

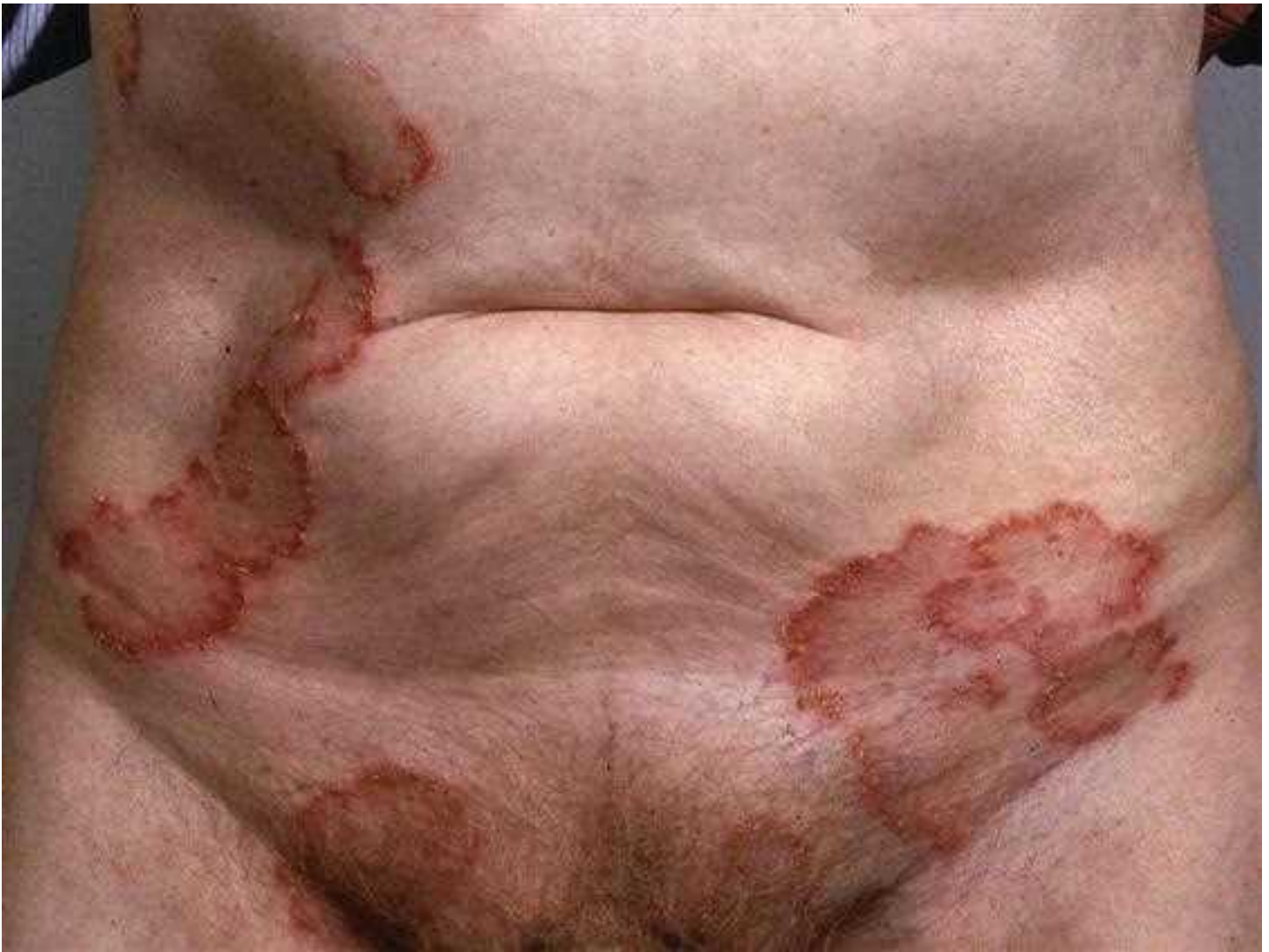

Figure 8.12 Linear IgA on the trunk.

Investigation of immunobullous disease

The gold standard for diagnosing immunobullous disease is direct immunofluorescent analysis of perilesional skin. Skin biopsies are taken across a blister/erosion; the lesional part is sent for histopathology and the adjacent skin sent for direct immunofluorescence ([Table 8.3](#)). The histological features can be diagnostic or supportive of the diagnosis. The level and pattern of immunoglobulin staining on direct immunofluorescence is usually diagnostic. Indirect tests involve taking the patients serum and applying this to a substrate such as monkey oesophagus or salt-split human skin substrate ([Figures 8.13–8.16](#)). Circulating intercellular antibodies may be detected in patients with pemphigus, leading to titre measurement which may help guide management.

Table 8.3 Skin biopsy findings in immunobullous disorders.

| Immunobullous disorder | Histology features | Immunofluorescence features |
|-------------------------------|--|--|
| Bullous pemphigoid | Subepidermal blister containing mainly eosinophils | Linear band of IgG at the basement membrane zone |
| Pemphigoid gestationis | Subepidermal blister containing mainly eosinophils | Linear band of C3 at the basement membrane zone |
| Mucous membrane pemphigoid | Subepidermal blister with variable cellular infiltrate | Linear band of IgG/C3 at the basement membrane zone |
| Pemphigus vulgaris | Suprabasal split (basal cells remain attached to basement membrane, looking like 'tombstones') | IgG deposited on surface of keratinocytes in a 'chicken-wire' pattern |
| Dermatitis herpetiformis | Small vesicles containing neutrophils and eosinophils in the upper dermis | Granular deposits of IgA in the upper dermis (dermal papillae) |
| Linear IgA | Subepidermal blisters with neutrophils or eosinophils | Linear deposition of IgA at the basement membrane zone |
| Paraneoplastic pemphigus | Suprabasal split leading to acantholysis with lichenoid interface dermatitis, features can be variable | IgG or C3 at the basement membrane (indirect IgG Rat bladder) ELISA serum antibodies to envoplakin and periplakin |

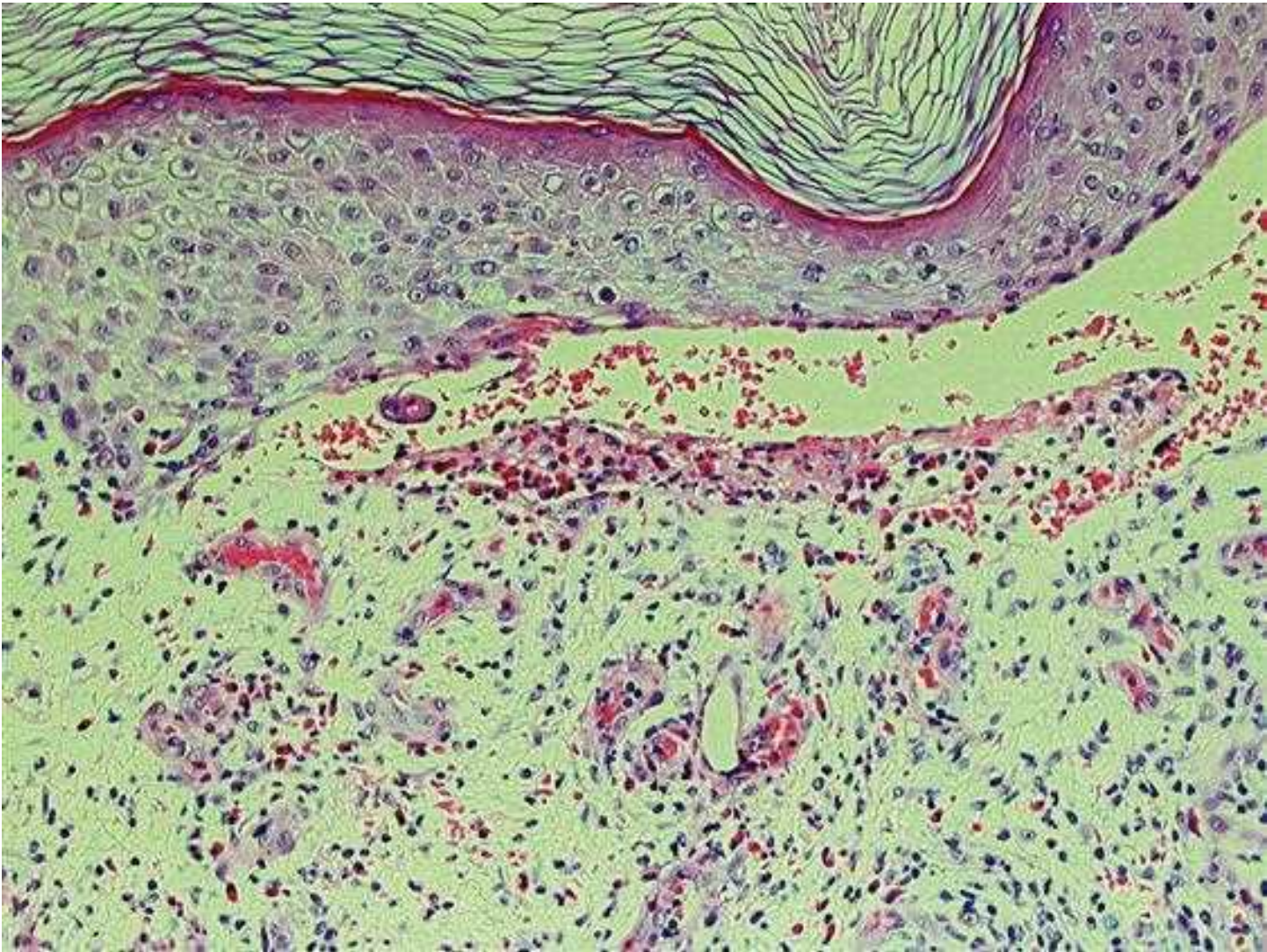


Figure 8.13 Histopathology of bullous pemphigoid.

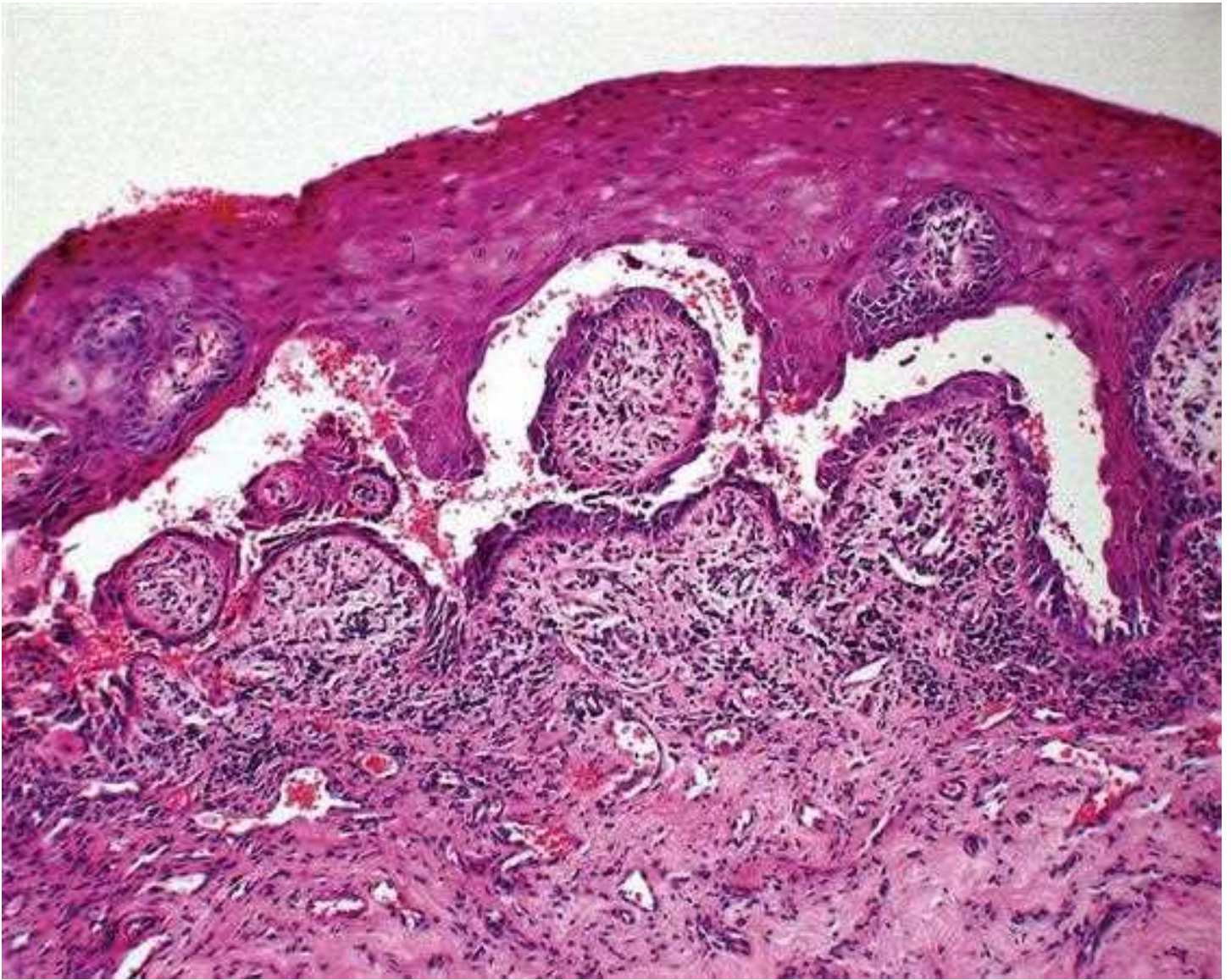

Figure 8.14 Histopathology of pemphigus vulgaris.

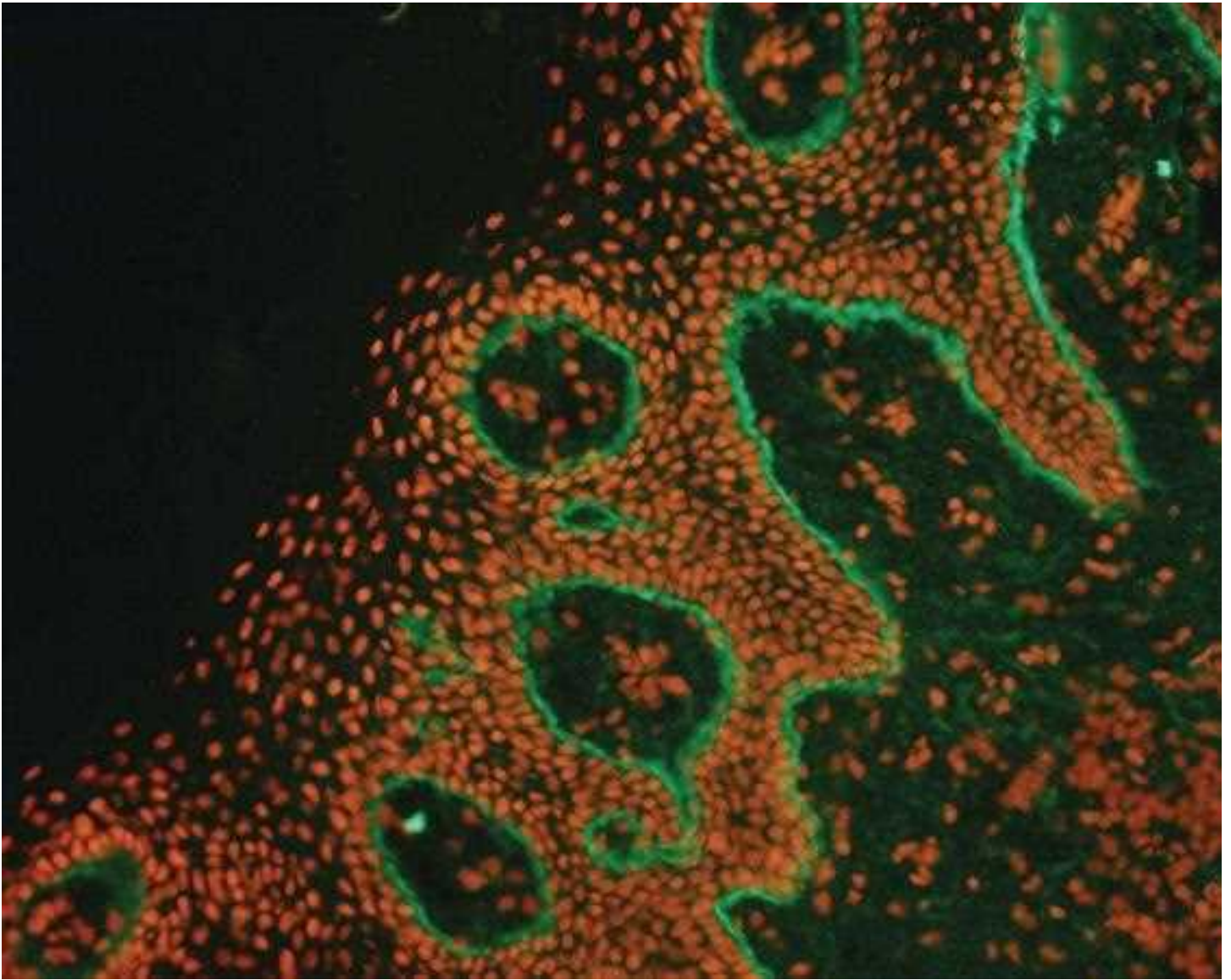


Figure 8.15 Immunofluorescence of bullous pemphigoid.

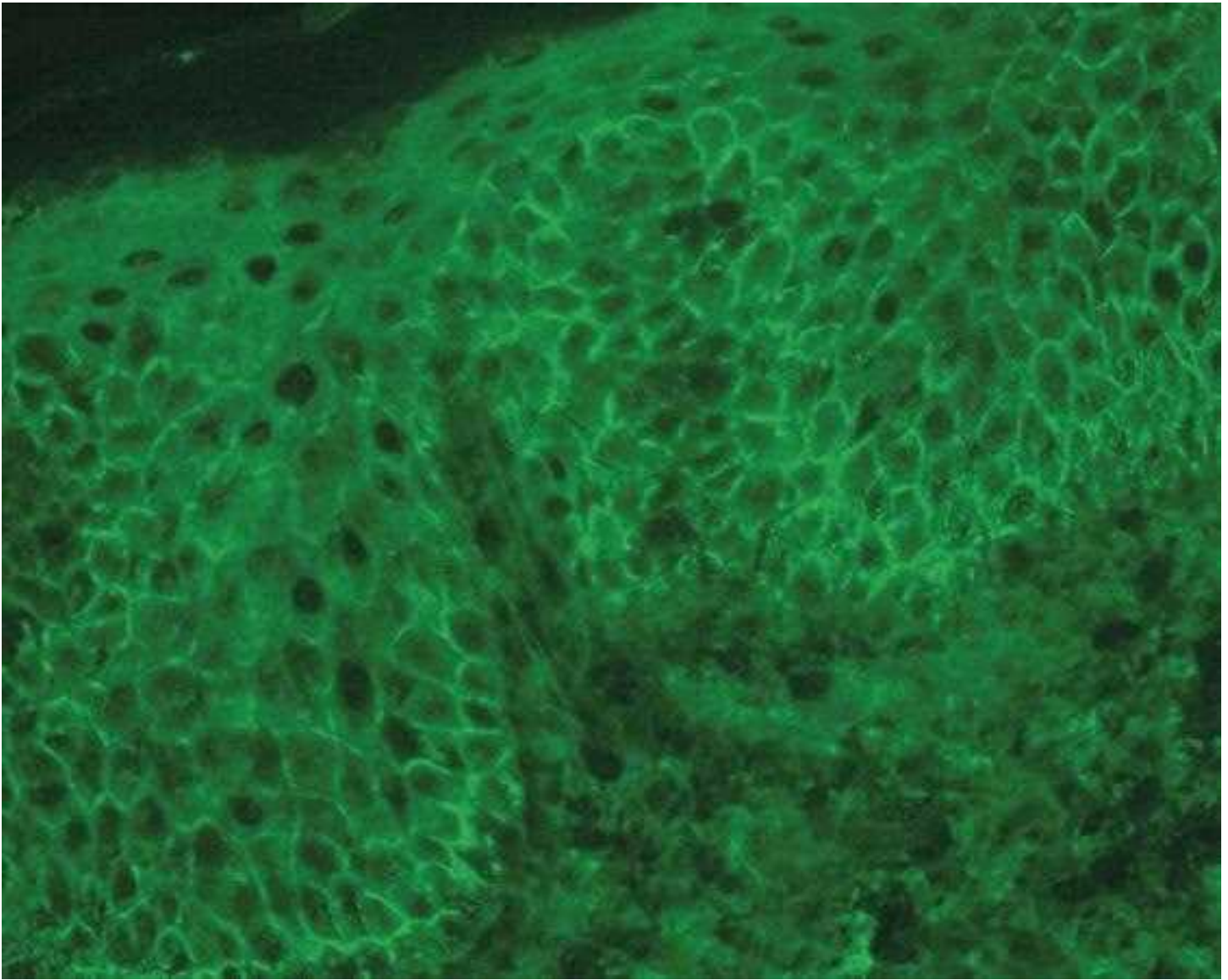


Figure 8.16 Immunofluorescence of pemphigus vulgaris.

Management of immunobullous disease

Tense intact blisters can be deflated using a sterile needle (the roof of the blister should be preserved as this provides a ‘natural wound covering’). Use of non-adherent dressings or a bodysuit can be used to cover painful cutaneous erosions. Liquid paraffin should be applied regularly to eroded areas to help retain fluid and prevent secondary infection.

In most cases of immunobullous disease immunosuppressive treatments are required. Bullous pemphigoid presenting in an elderly patient may respond to intensive potent topical steroids to affected skin. Reducing courses of systemic corticosteroids can be helpful in the short term to reduce the pruritus and development of new lesions, but most patients are maintained on doxycycline or azathioprine in the longer term. Other treatments used include methotrexate, cyclophosphamide, mycophenolate mofetil, and the anti CD-20 biological agent rituximab.

Severe forms of pemphigoid gestationis may require high doses of systemic corticosteroids

which can usually be rapidly reduced during the post-partum period. Care should be taken if mothers are breastfeeding as most drugs pass into breast milk.

Mucous membrane pemphigoid is chronic and resistant to many treatments, making management difficult. Oral disease may respond to topical steroids and tetracycline mouthwashes. Ophthalmic disease should be managed carefully as scarring can result in blindness. Topical steroid drops and mitomycin may be useful, but usually systemic immunosuppression such as mycophenolate mofetil is required.

The management of pemphigus vulgaris has been transformed by the use of rituximab which is a biological agent with anti-CD20 activity that depletes antibody-producing B-cells. A dose of 1 g of rituximab given at day 1 and 15 induces remission in 70% of patients by 70 days and 86% of patients at 6 months. About 40% of patients will subsequently relapse after two infusions of rituximab usually after many months and studies show that when they receive further infusions of rituximab at 500 mg, further disease remission can be achieved. In most cases, all other immunosuppressive medications can be stopped, leading to a reduction in long-term morbidity and mortality induced by medications.

A gluten-free diet is an effective way of controlling the cutaneous eruption of DH as well as relieving gastrointestinal symptoms and reducing the risk of developing small bowel lymphoma. Dapsone or sulfapyridine are both helpful in controlling the disease.

Paraneoplastic pemphigus (PNP) usually responds to treatment of the underlying tumour. However, it can continue for up to two years after resection of, for example, a thymoma. High-dose oral prednisolone (1 mg/kg/day) can help to diminish the cutaneous lesions; however, the oral involvement is often refractory to treatment. The use of rituximab has been disappointing in the management of PNP, though some patients with underlying non-Hodgkin's lymphoma do respond.

Further reading

Burge, S. and Wallis, D. (2011). *Oxford Handbook of Medical Dermatology*. Oxford: Oxford University Press.

Groves, R. (2016). Immunobullous Diseases. In: *Rook's Textbook of Dermatology*, 9e (ed. C.M. Griffiths, J. Barker, T. Bleiker, et al.). Chichester: Wiley.

Hertl, M. (2011). *Autoimmune Diseases of the Skin: Pathogenesis, Diagnosis, Management*. New York: Springer-Verlag/Wein.

CHAPTER 9

Connective Tissue Disease, Vasculitis, and Related Disorders

Rachael Morris-Jones

Guy's and St Thomas' NHS Foundation Trust, London, UK

OVERVIEW

- Many connective tissues disorders affect the skin.
- Fibrosis in connective tissue is a feature of systemic sclerosis, morphoea, CREST syndrome, and lichen sclerosus.
- Lupus erythematosus may be solely cutaneous or cause severe systemic disease.
- Dermatomyositis results in characteristic skin involvement and muscle weakness, it may be a marker of internal malignancy.
- Lichen planus is a common chronic inflammatory condition of the skin of unknown cause that can also affect mouth, eyes, and ears.
- Vasculitis results from changes in capillaries and arterioles and may involve internal organs in addition to the skin.
- Causes of cutaneous vasculitis include inflammatory, viral, and haematological conditions. A wide range of investigations may be indicated.

Introduction

The skin is a dynamic interface of trafficking immune cells that may remain localised and respond to nearby stimuli, or migrate through the skin in response to more distant triggers. The skin has been called 'the immunological battleground of the body' and immune cells involved in inflammatory reactions may be part of a local immune reaction or migrate to the skin as a result of antigenic stimuli at distant sites. Malfunction of the sophisticated human immune system may result in the body attacking its own tissues, that is, failure to distinguish 'self' from 'non-self'. These autoimmune responses may develop against a tissue in a specific organ such as the thyroid gland, or to tissues within and between organs resulting in connective tissue diseases.

Connective tissue disease

Connective tissue disease can be difficult to define but encompasses disorders that involve

tissues connecting and surrounding organs.

Connective tissues include the extracellular matrix and support proteins such as collagen and elastin. Acquired disorders of connective tissue are thought to have an autoimmune basis, many of which have distinctive clinical features and patterns in laboratory investigations. However, at times classification may not be easy. What triggers dysregulation of the immune system is usually unknown; however, some recognised factors include sunlight, infections, and medication. Patients may have an underlying hereditary susceptibility to develop autoimmune diseases, marked by specific HLA (human lymphocyte antigen) types in some cases.

In autoimmune disorders immune cells may be attracted to particular targets within the skin locally (pemphigus and pemphigoid – [Chapter 8](#)) or accumulate at sites of connective tissues in multiple organs (systemic lupus erythematosus (SLE) and dermatomyositis). Once at their destination these immune cells trigger a cascade of chemical messages leading to inflammation.

The possibility of an underlying connective tissue disorder should be considered if a patient complains of any combination of symptoms including cutaneous lesions (especially face and fingers), joint pains, muscle aches, malaise, weakness, photosensitivity, Raynaud's phenomenon, and alopecia. Linking the clinical symptoms and signs with the most appropriate investigations ([Box 9.1](#)) in order to arrive at a unifying diagnosis is a challenge to even the most experienced medical practitioner.

Box 9.1 Investigations might include the following

- Full blood count (FBC)
- Antinuclear antibodies (ANAs)
- Extractable nuclear antibodies (ENAs), (Ro, La)
- Myositis antibodies (Jo-1, SRP, Anti-Mi-2)
- Erythrocyte sedimentation rate (ESR)
- Renal and liver function
- ANCA (antineutrophil cytoplasmic antibodies)
- Hepatitis serology
- Streptococcal serology (ASOT)
- Rheumatoid factor
- Angiotensin-converting enzyme (ACE)
- Antiphospholipid antibodies
- Coagulation screen, lupus anticoagulant
- Anticardiolipin antibodies
- Factor V Leiden, antithrombin III, proteins S and C
- Urine dipstick and microscopy
- Blood pressure
- Chest X-ray

Vasculitis

Complex reactions occurring specifically in the capillaries and arterioles of the skin may lead to cutaneous erythema (redness). The erythema may be macular or papular and may be transient or last for weeks. Blood vessels can become leaky, leading to pouring out (extravasation) of red blood cells into the tissue with or without inflammation of the blood vessel walls. Inflammation of blood vessel walls is called vasculitis and may involve arteries and/or veins. Vasculitis can also lead to stenosis, occlusion, and ischaemia.

Symptoms can include pain in the skin, general malaise, fever, abdominal pain, and arthropathy. Clinically, patients have a non-blanching skin eruption that is most commonly seen on the lower limbs ([Figure 9.1](#)). Individual skin lesions may be macular or palpable

purpura, blistering, ulcerated, and necrotic ([Figure 9.2](#)). Vasculitis confined to the skin can be painful and unpleasant, but systemic vasculitis may be life-threatening.

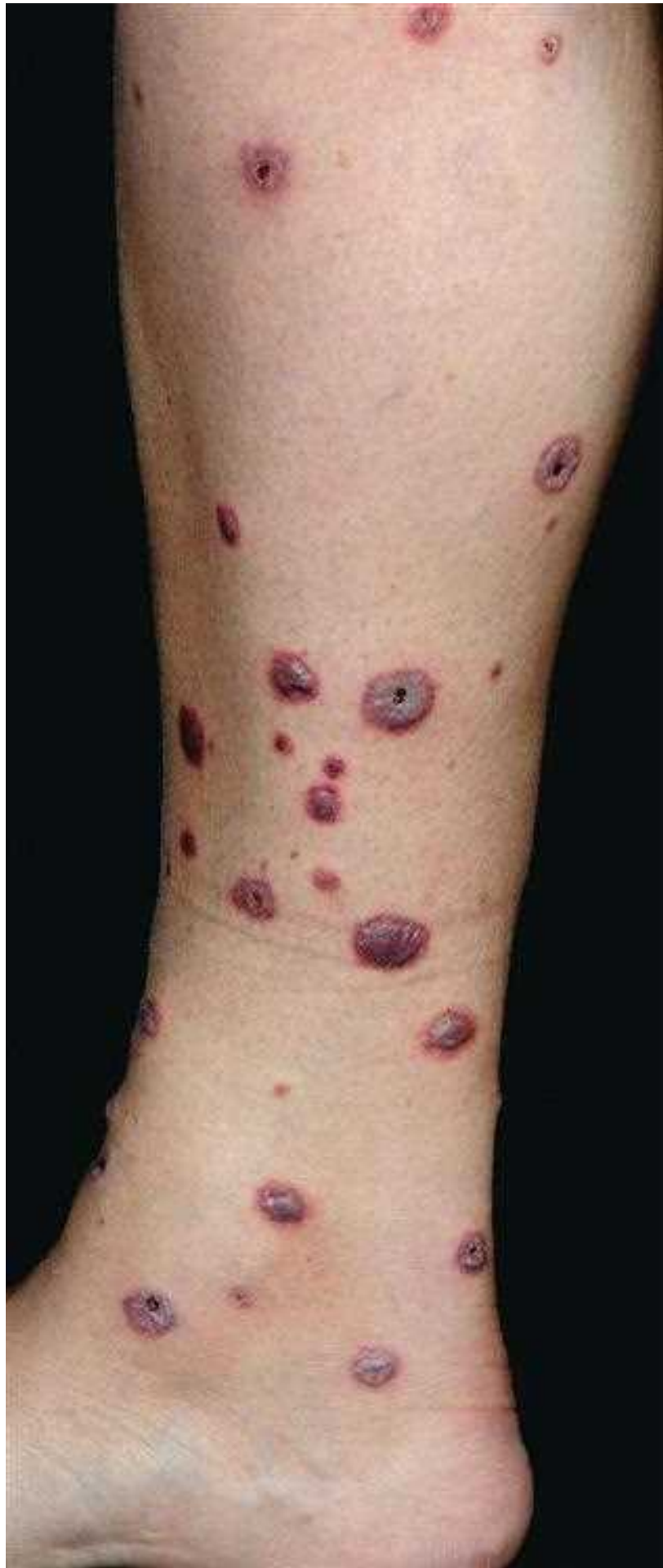

Figure 9.1 Vasculitis.

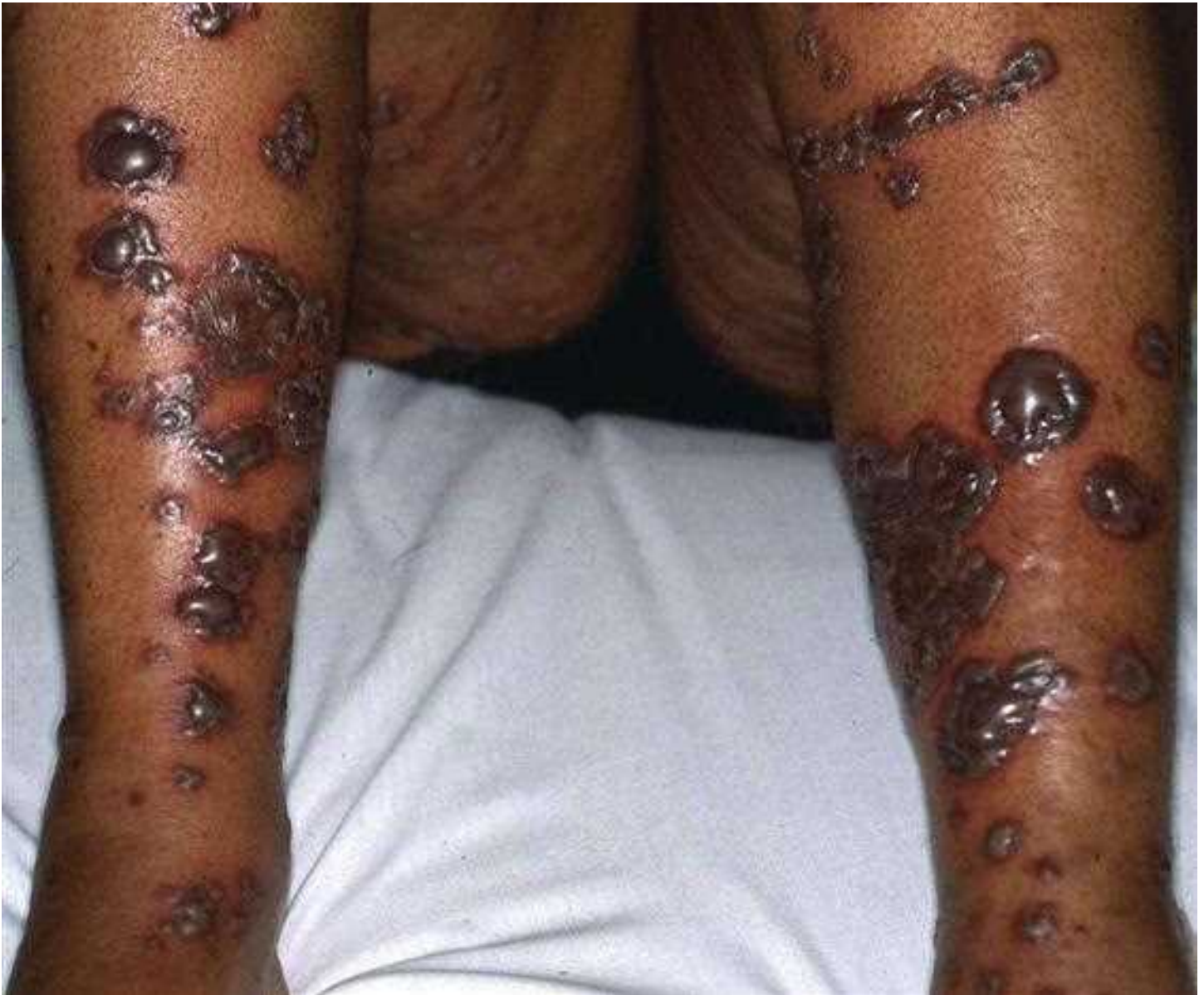

Figure 9.2 Bullous vasculitis with necrosis.

There are numerous possible underlying causes of vasculitis, including infections, medications, connective tissue disease, underlying malignancy, vascular/coagulopathy disorders, inflammatory bowel disease, and sarcoidosis ([Box 9.1](#). indicates appropriate investigations in patients with a vasculitis of unknown cause).

The pathophysiology of vasculitis is complex and poorly characterised but is thought to be antibody or immune complex mediated. Blood vessel endothelial lining cells become damaged as a result of immune complex deposition, antibody targeting, and consequent inflammatory cascades. Inflammation involves activation of complement and the release of inflammatory mediators resulting in vasodilatation and polymorph accumulation. The resultant leakage and occlusion of blood vessels leads to ischaemia.

Confirmation of cutaneous vasculitis from a skin biopsy for histology and

immunofluorescence (IMF) can be helpful but is not usually diagnostic of the underlying cause ([Box 9.2](#)). However, in Henoch–Schönlein purpura (IgA vasculitis) the IMF from the skin biopsy usually shows IgA deposition.

Box 9.2 Possible causes of cutaneous vasculitis

- Drug hypersensitivity
- Hepatitis
- Endocarditis
- Inflammatory bowel disease
- Connective tissue disease
- Coagulopathies
- Behçet's syndrome
- Kawasaki disease
- Sarcoidosis

Polyarteritis nodosa (PAN)

Polyarteritis nodosa (PAN) is a systemic vasculitis of small- to medium-sized arterioles that most commonly affects the skin and joints. Immune complexes mediate the disease, activating the complement cascade leading to inflammatory damage to vessels. The sites of blood vessel bifurcation are commonly affected and this leads to micro-aneurysm formation with resultant occlusion and haemorrhage. ANCA may be positive. Patients present with general malaise, fever, weight loss, weakness, arthralgia, neuropathies, and skin lesions. Of the patients, 60% develop renal involvement, which may lead to renal failure. Cutaneous manifestations may include a subtle lacy/mottled pattern (livedo reticularis), purpura, tender subcutaneous nodules, ulceration, and necrosis, particularly on the lower limbs ([Figure 9.3](#)). Investigations may include angiography and tissue biopsy (skin, sural nerve, or muscle). Management relies on oral steroids with the addition of cyclophosphamide in severe cases.

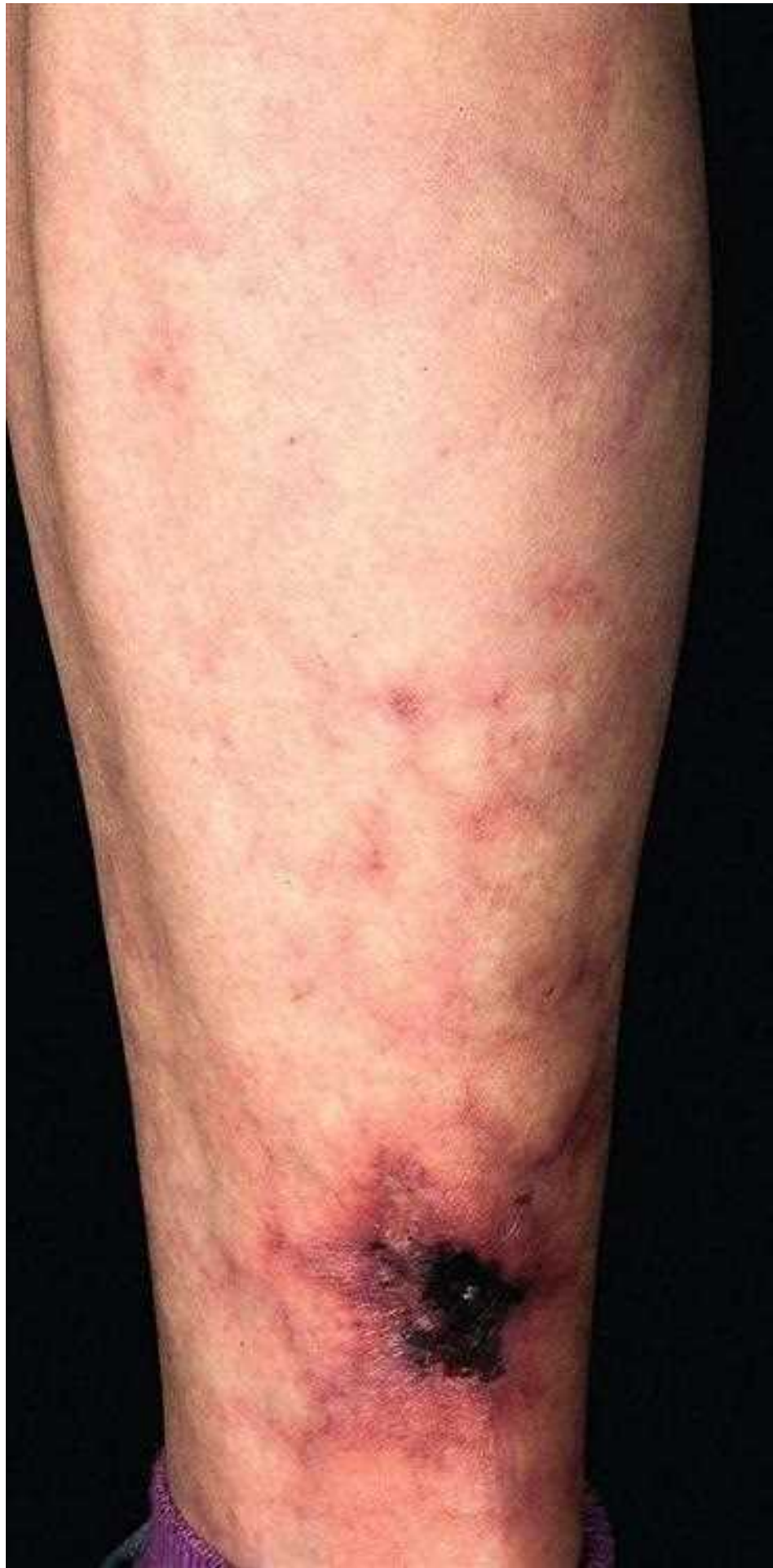

Figure 9.3 Livedo reticularis with skin necrosis in polyarteritis nodosa.

Henoch–schönlein purpura (IgA vasculitis)

This usually occurs in children (75% of cases) or young adults (M > F); the aetiology is unknown, but up to 50% of patients have preceding upper respiratory tract symptoms and a positive antistreptolysin O titre (ASOT). The skin, kidneys (IgA nephropathy), gastrointestinal (GI) tract, and joints are mainly affected. IgA, complement and immune complexes are deposited in small vessels (arterioles, capillaries, venules), leading to systemic vasculitis. HSP is characterised by a vasculitic rash on the buttocks and lower legs (which may be associated with oedema of scrotum/hands/ears), abdominal pain and vomiting, joint pains in the knees/ankles, and haematuria. Skin/renal biopsy may demonstrate deposition of IgA on IMF, which can support the diagnosis. Treatment is mainly supportive and most patients recover within weeks. Occasionally, the condition can persist and systemic corticosteroids have been used to treat skin, gastrointestinal, and arthritis symptoms but steroids have not been shown to prevent or treat renal disease.

Management of cutaneous vasculitis

Treat any underlying cause. For mild to moderate cutaneous involvement a potent topical steroid can be applied to the affected skin. If the lower legs are affected then support hosiery should be used and the legs elevated on sitting.

In more severe cases, systemic corticosteroids (30–60 mg) are usually required. Anticoagulation with heparin or warfarin may be needed. If the vasculitis persists then an alternative immunosuppressant may be needed in the long term such as azathioprine or methotrexate.

Chilblains (perniosis)

Occurs due to prolonged exposure to the cold in susceptible individuals when small arteries in the skin constrict leading to initially itchy and then painful erythema or purple discolouration that may lead to skin necrosis at the affected sites ([Figure 9.4](#)). Commonly affected areas include the hands and feet, thighs, nose, and ears. Risk factors include those with peripheral vascular disease, smoking, diabetes, malnutrition, and connective tissues diseases (lupus, systemic sclerosis (SSc) and Raynaud's phenomenon). Treat the acute phase with potent topical steroid and advise avoidance measures such as insulated gloves, woollen socks, smoking cessation, and possibly nifedipine.

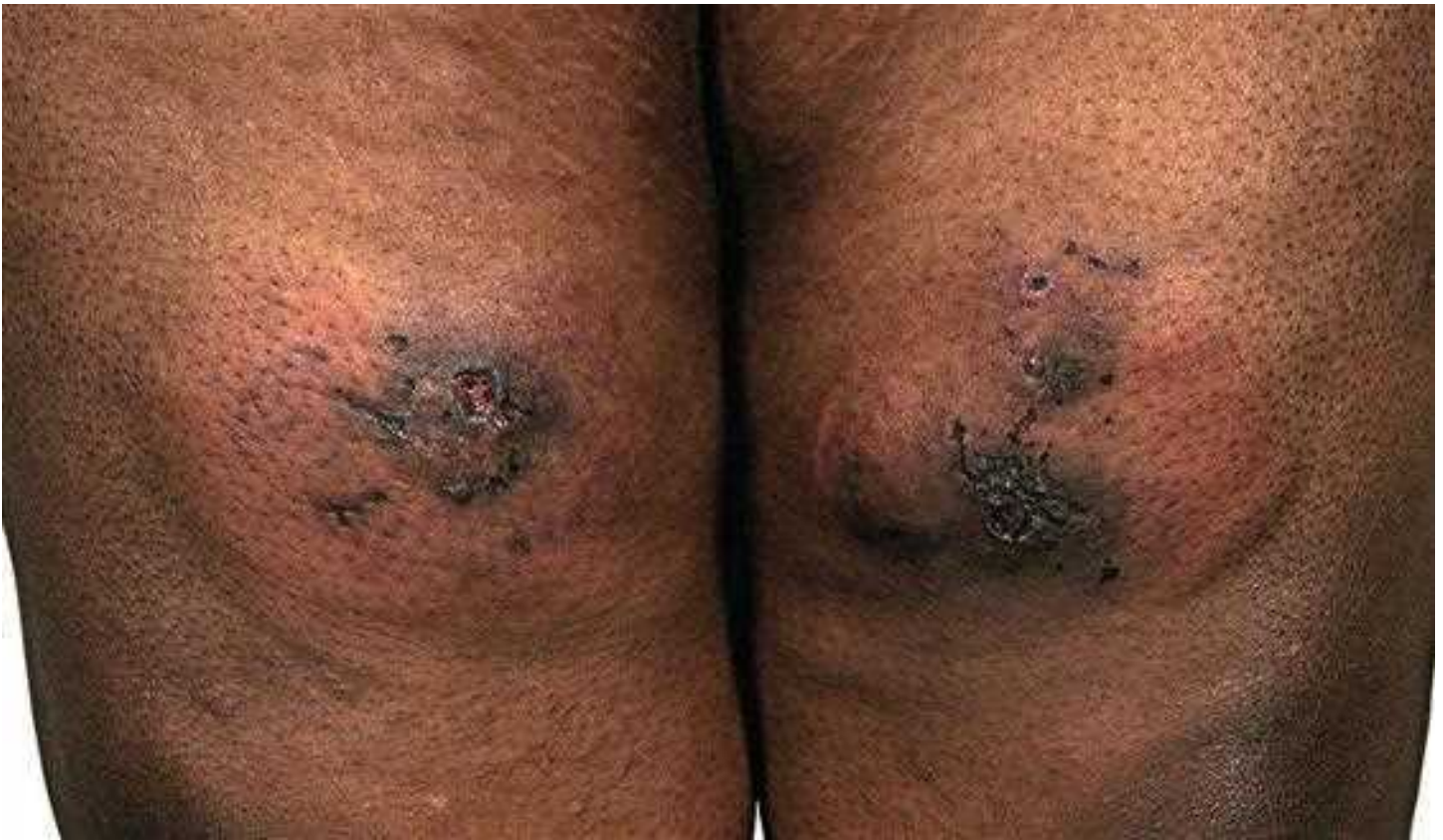

Figure 9.4 Perniosis on the knees from outdoor work in the winter.

Raynaud's phenomenon

Recurrent reversible vasospasm of peripheral arterioles secondary to cold exposure leads to transient ischaemia of the digits associated with an underlying autoimmune disease (Raynaud's disease is the same phenomenon without any underlying systemic disease). Raynaud's phenomenon is most commonly associated with systemic sclerosis, mixed connective tissue disease (MCTD), SLE, and cryoglobulinemia. In the cold, the affected digits characteristically turn white (vasospasm), then blue (cyanosis), and finally red (hyperemia); these colour changes may be associated with pain or numbness. The condition most frequently affects the fingers in a bilateral and symmetrical pattern but may also affect the toes, nose, and ears. Consider investigating patients with FBC, renal, and liver function, coagulation profile, thyroid function, serum glucose, creatinine kinase, hepatitis serology, and ANAs. Management involves keeping peripheries warm, nifedipine, and iloprost (prostacycline analogue).

Systemic sclerosis (SSc)

This is a condition in which there is extensive sclerosis (excessive collagen deposition and fibrosis) of the subcutaneous tissues in the fingers and toes as well as around the mouth (scleroderma), with similar changes affecting the internal organs, particularly the lung and kidneys. Blood vessels can be affected, leading to Raynaud's phenomenon (fingers), and

telangiectasia (mouth and fingers). The main types of SSc are limited (lSSc) and disseminated (dSSc), the former mainly affecting females. About 90% of patients with SSc will have at least one positive ANA. Antibodies against topoisomerase I DNA (Scl 70) are found in about 30% of patients (70% of those with dSSc and interstitial lung disease). About 38% of patients with SSc and skin involvement have a positive anticentromere antibody (most commonly in lSSc). Other positive ANAs include anti-SSA/Ro/RNA polymerase III. Additional investigations that may be helpful include CRP/ESR (raised), high resolution CT scan of the lungs (thickening of the alveolar walls), lung function tests (impaired ventilation-perfusion), and skin biopsy (fibrotic changes seen on histology). Clinically, there is considerable tethering of the skin on the fingers/toes, which becomes very tight with a waxy appearance and considerable limitation of movement. There are many other forms of scleroderma including undifferentiated connective tissue disease and the so-called 'CREST syndrome' ([Box 9.3](#)).

Box 9.3 CREST syndrome

C: Calcinosis cutis

R: Raynaud's phenomenon

E: Oesophageal dysmotility

S: Sclerodactyly

T: Telangiectasia

Morphoea is a benign form of localised systemic sclerosis in which there is localised sclerosis with very slight inflammation. There is atrophy of the overlying epidermis. In the early stages the skin may have a dusky appearance, but as the disease progresses the skin becomes discoloured and feels very firm ([Figure 9.5](#)). Localised morphoea in the frontoparietal area ('en coup de sabre') is associated with alopecia and a sunken groove of firm sclerotic skin.

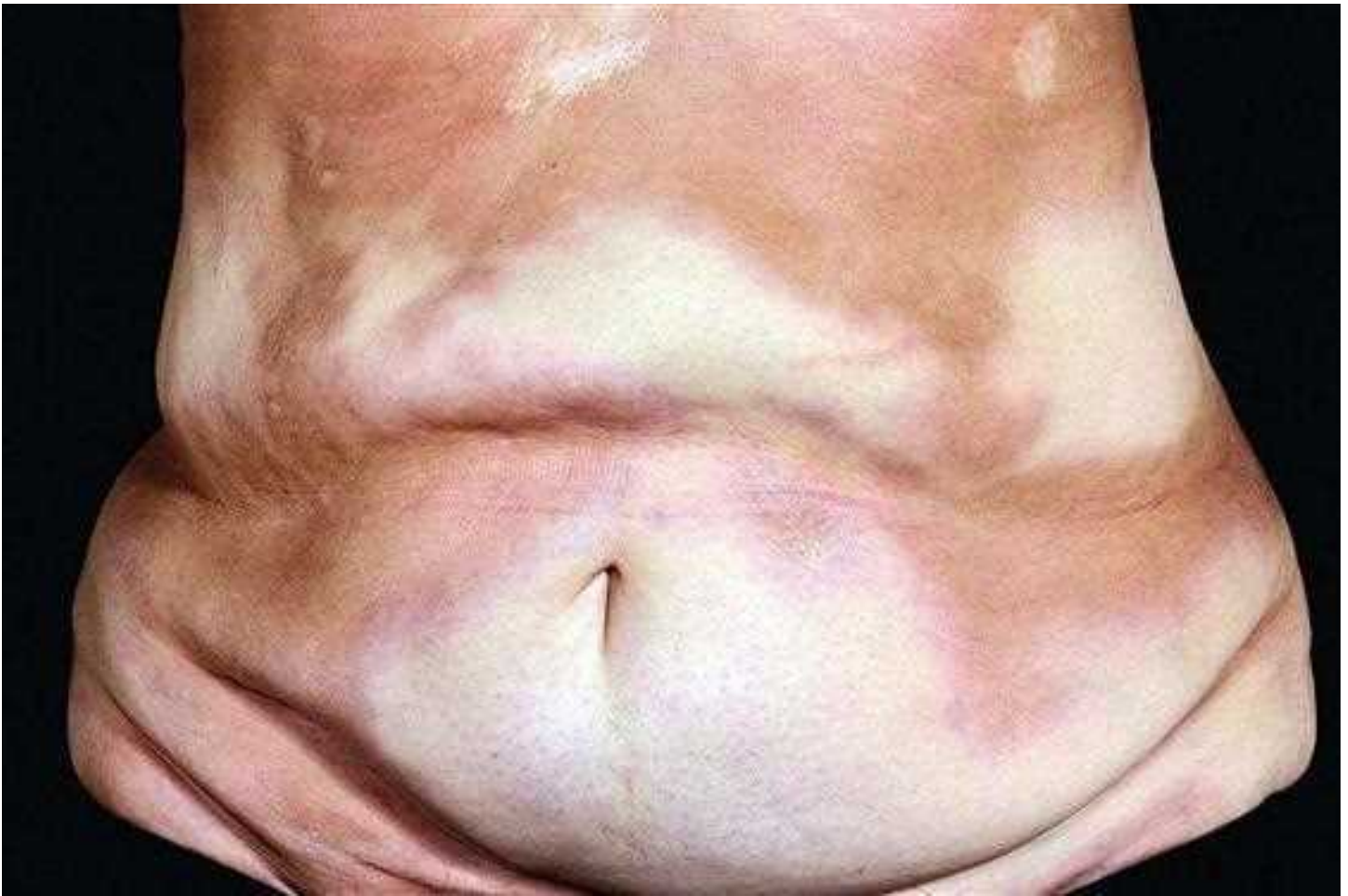

Figure 9.5 Morphea seen as hyperpigmented indurated plaques in the torso.

Patients who develop CREST usually first complain of Raynaud's phenomenon, followed by thickening of the skin of the digits due to scleroderma (progressive fibrosis) leading to sclerodactyly. Calcium deposits in the skin are seen as chalky-white material which can be painful ([Figure 9.6](#)). Patients then develop multiple telangiectasia, usually first seen on the face ([Figure 9.7](#)) but mucous membranes and the gastrointestinal tract may also be affected. Dysmotility of the oesophagus is usually a late development.

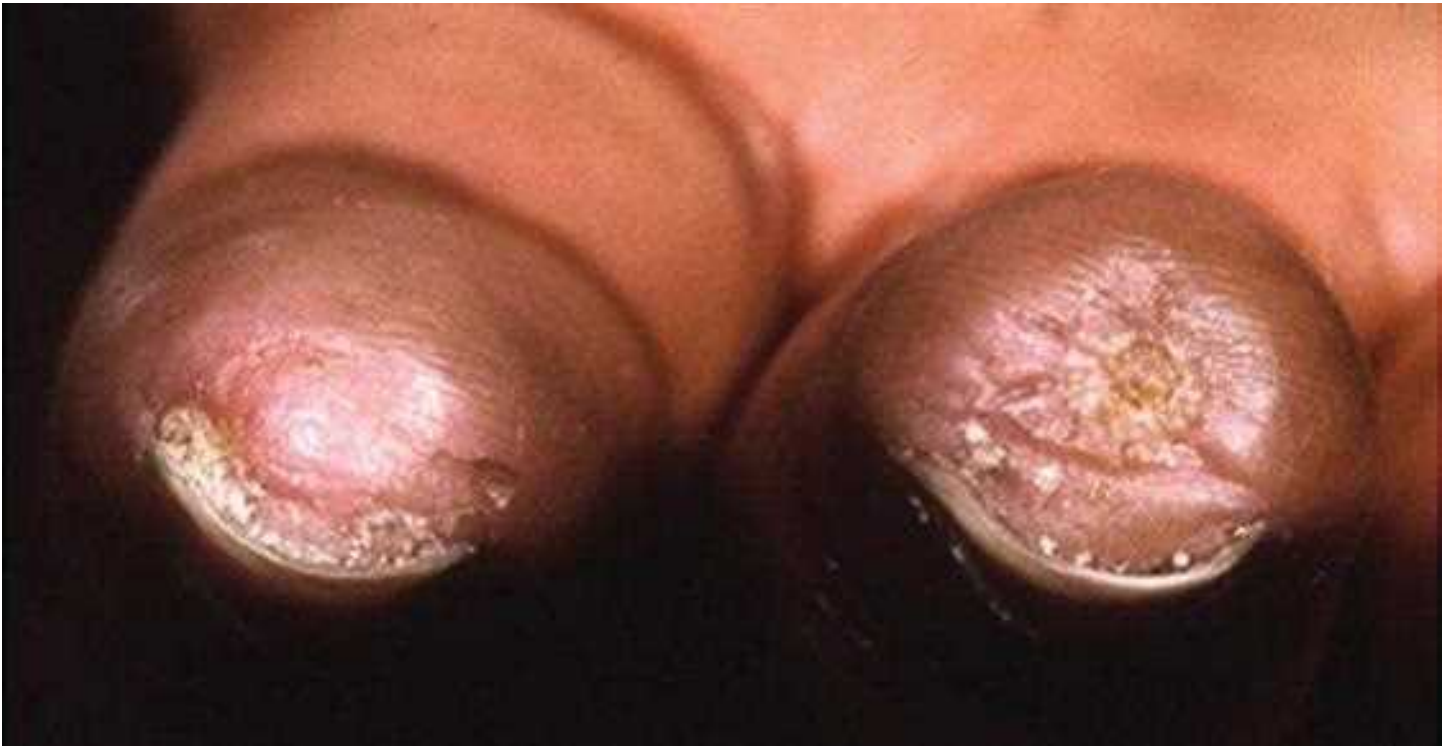

Figure 9.6 Calcinosis cutis.

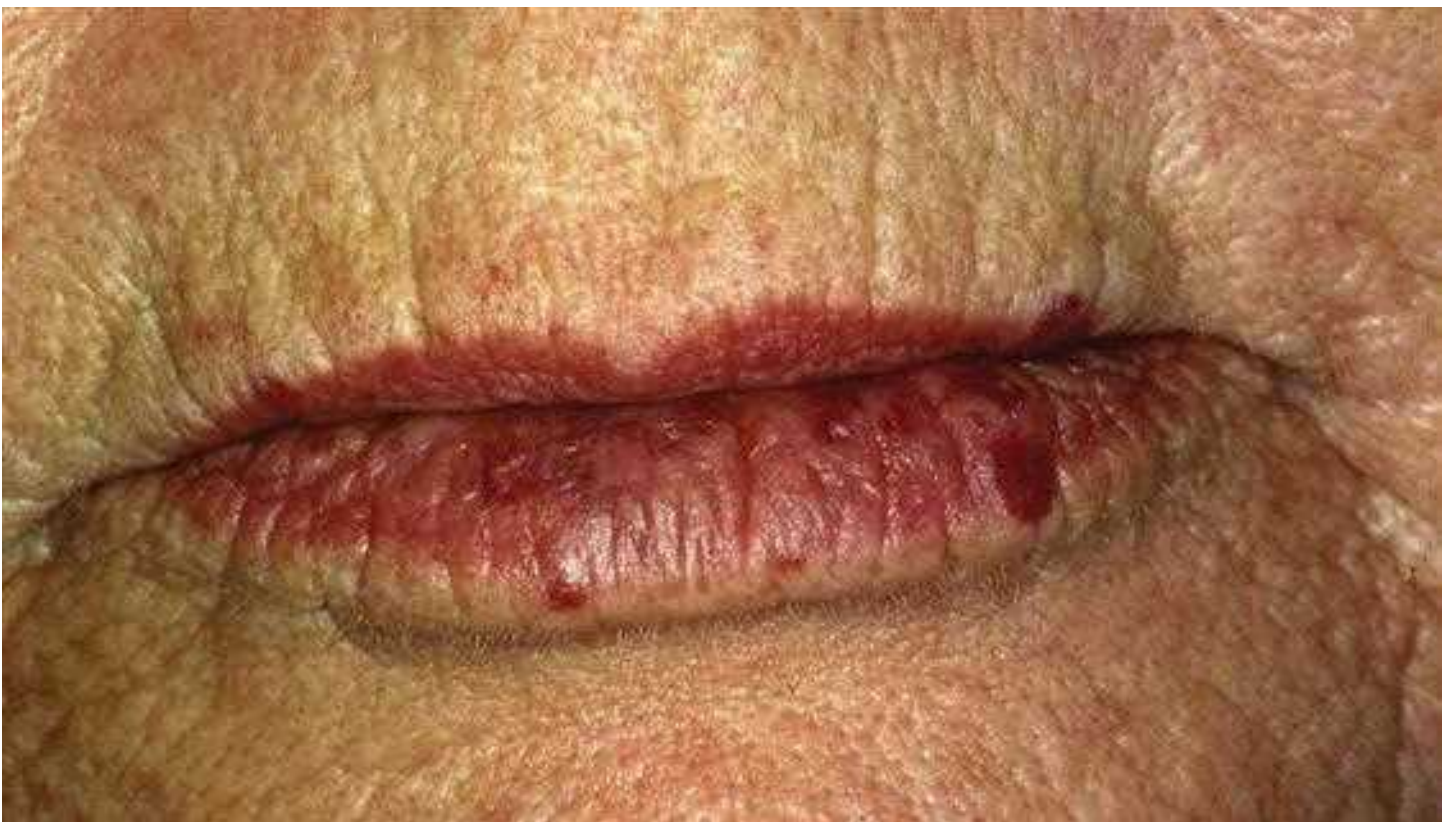

Figure 9.7 CREST syndrome.

Investigations should include an FBC, ANA, anticentromere antibody, and anti-Scl-70.

A multidisciplinary team approach to management is usually needed, including psychological support. Patients should keep themselves warm, especially their hands. Calcium channel

blockers and prostaglandins/protacycline may help prevent and treat Raynaud's phenomenon. Calcitriol may soften the sclerodactyly, and pulsed dye laser may treat facial telangiectasia.

Lichen planus (LP)

Clinically, patients have an itchy eruption consisting of shiny purple-coloured flat-topped papules that characteristically appear on the wrists ([Figure 9.8](#)) and ankles. White lines called Wickham's striae may appear on the surface of the lesions at any site. Lesions may appear in clusters or in linear scratches/surgical scars (Koebner's phenomenon). The underlying cause is unknown, but the condition is thought to have an immunological aetiology. The histological features are characterised by a band of lymphocytes attacking the basal keratinocytes which results in oedema, subepidermal clefts, and death of some keratinocytes. In patients with black skin, lichen planus (LP) may be very hypertrophic and heal with marked post-inflammatory hyperpigmentation. The mouth (especially, buccal mucosa; [Figure 9.9](#)) and genitals (erosions on labia minora) may also be involved and distinctive linear ridges may affect the nails. Scalp lesions are often scaly with marked follicular plugging that may result in scarring alopecia. Severe acute lichen planus can manifest as bullous lesions ([Figure 9.10](#)). Most cases resolve over one to two years. Hypertrophic LP may, however, persist for decades. Potent topical steroid applied to the itchy active lesions is usually effective. Occlusion of the steroid for treatment of hypertrophic lesions is usually more effective than steroid alone. Severe lichen planus can be treated with systemic corticosteroids, mycophenolate mofetil, methotrexate, or azathioprine.

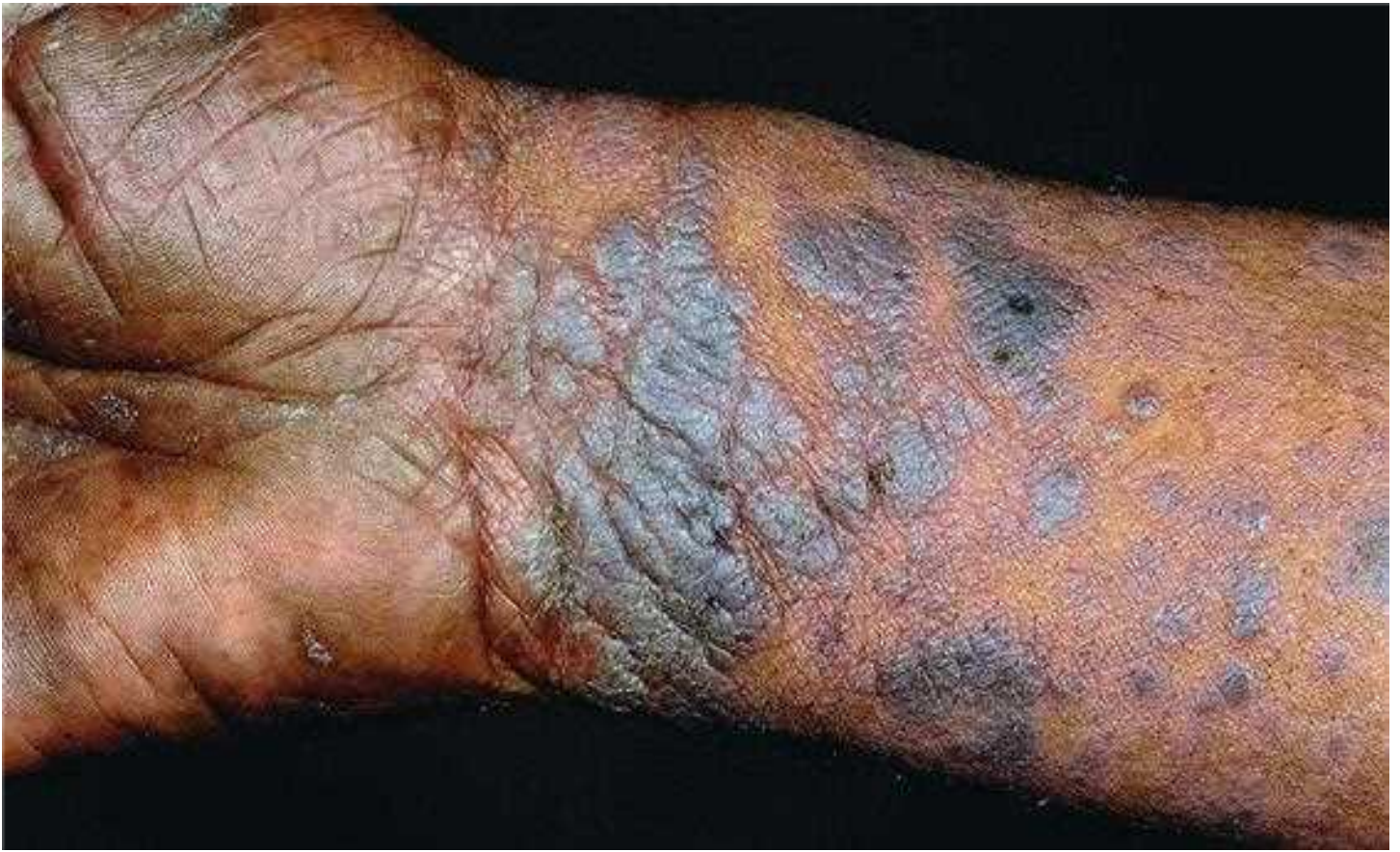

Figure 9.8 Lichen planus on the wrist.

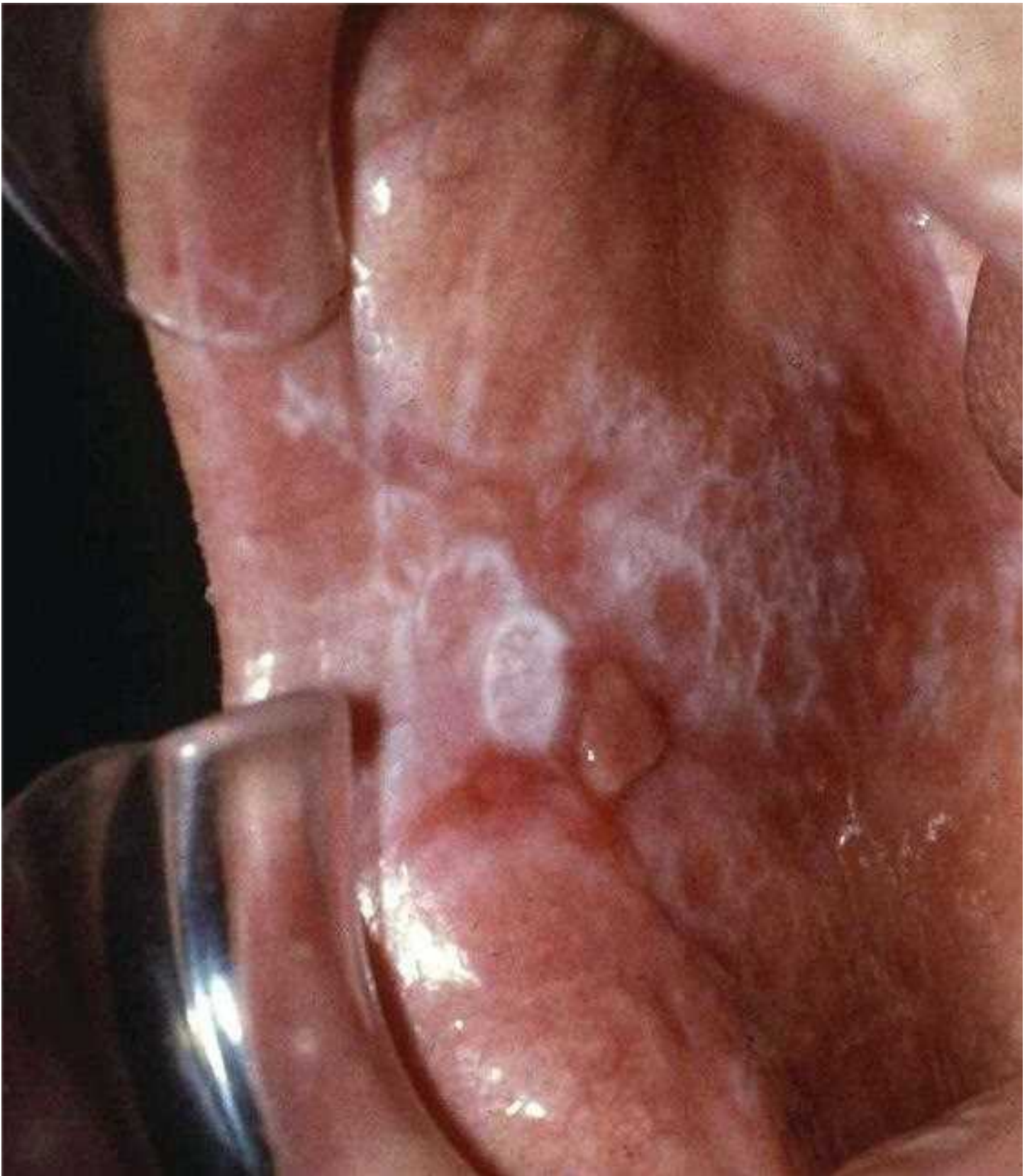

Figure 9.9 Lichen planus in the mouth.

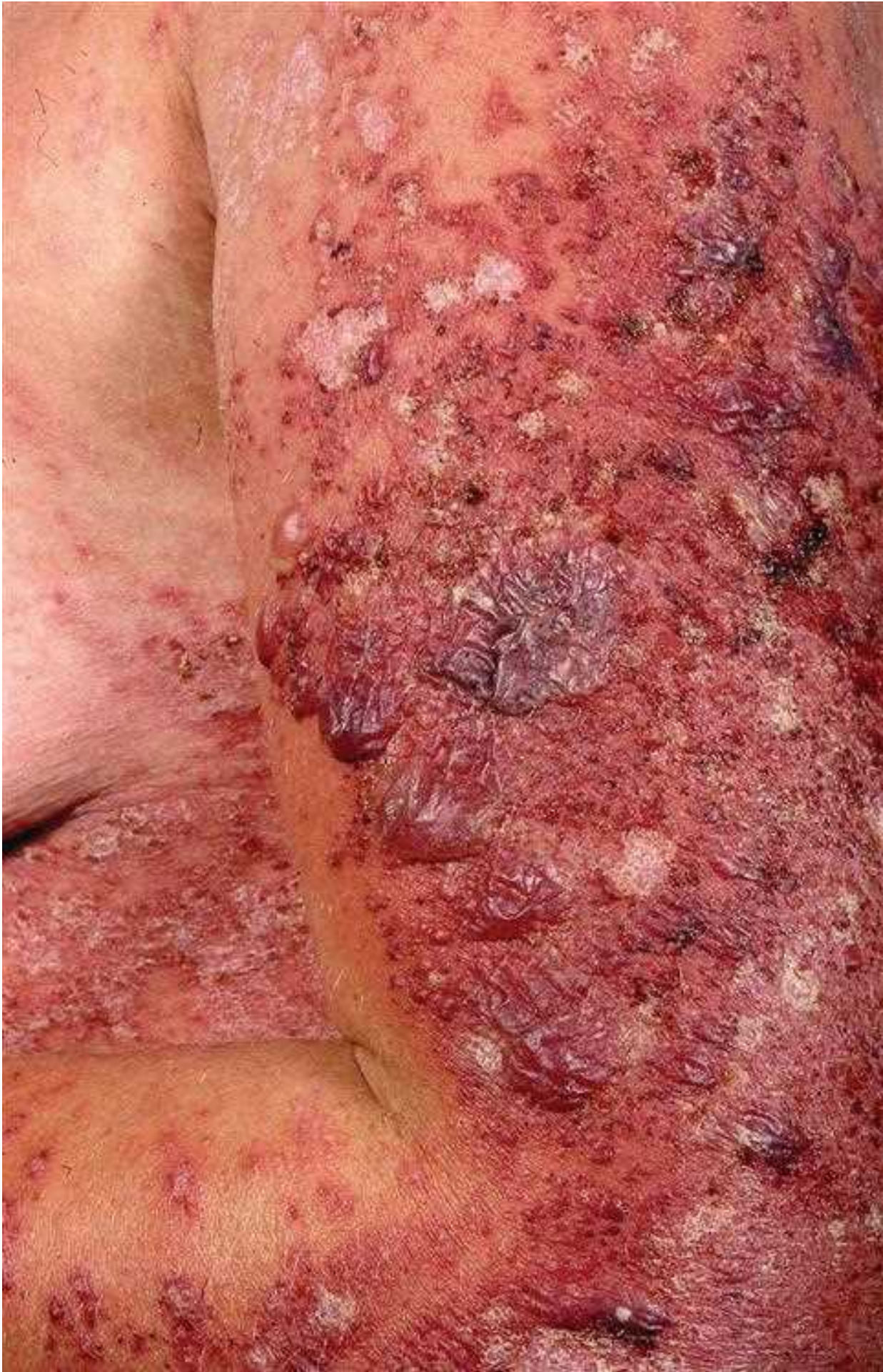

Figure 9.10 Bullous lichen planus.

Lichenoid drug eruptions are clinically similar to LP but lesions are usually more extensive and oral involvement is rare (see [Chapter 7](#)). Lesions only resolve very slowly after the drug is stopped, generally taking one to four months to settle and usually leaving hyperpigmentation on the skin.

Lupus erythematosus (LE)

There are four main clinical variants of lupus erythematosus (LE): systemic, subacute, discoid, and neonatal ([Box 9.4](#)).

Box 9.4 Clinical variants of lupus erythematosus

- Systemic
- Subacute cutaneous
- Discoid
- Neonatal

SLE is an autoimmune disorder characterised by the presence of antibodies against various components of the cell nucleus. SLE has been triggered by drugs including chlorpromazine, quinine, and isoniazid. SLE is a multisystem disease; 75% of patients have skin involvement, most commonly an erythematous ‘butterfly’ distribution rash on the face. Photosensitivity, hair loss, and areas of cutaneous vasculitis may occur. Some patients have antiphospholipid syndrome leading to vascular occlusion at the extremities ([Figure 9.11](#)). As the disease progresses the cutaneous manifestations can become extensive, particularly on the face ([Figure 9.12](#)). Systemic changes include fever, arthritis, and renal involvement, but there may be involvement of a wide range of organs.

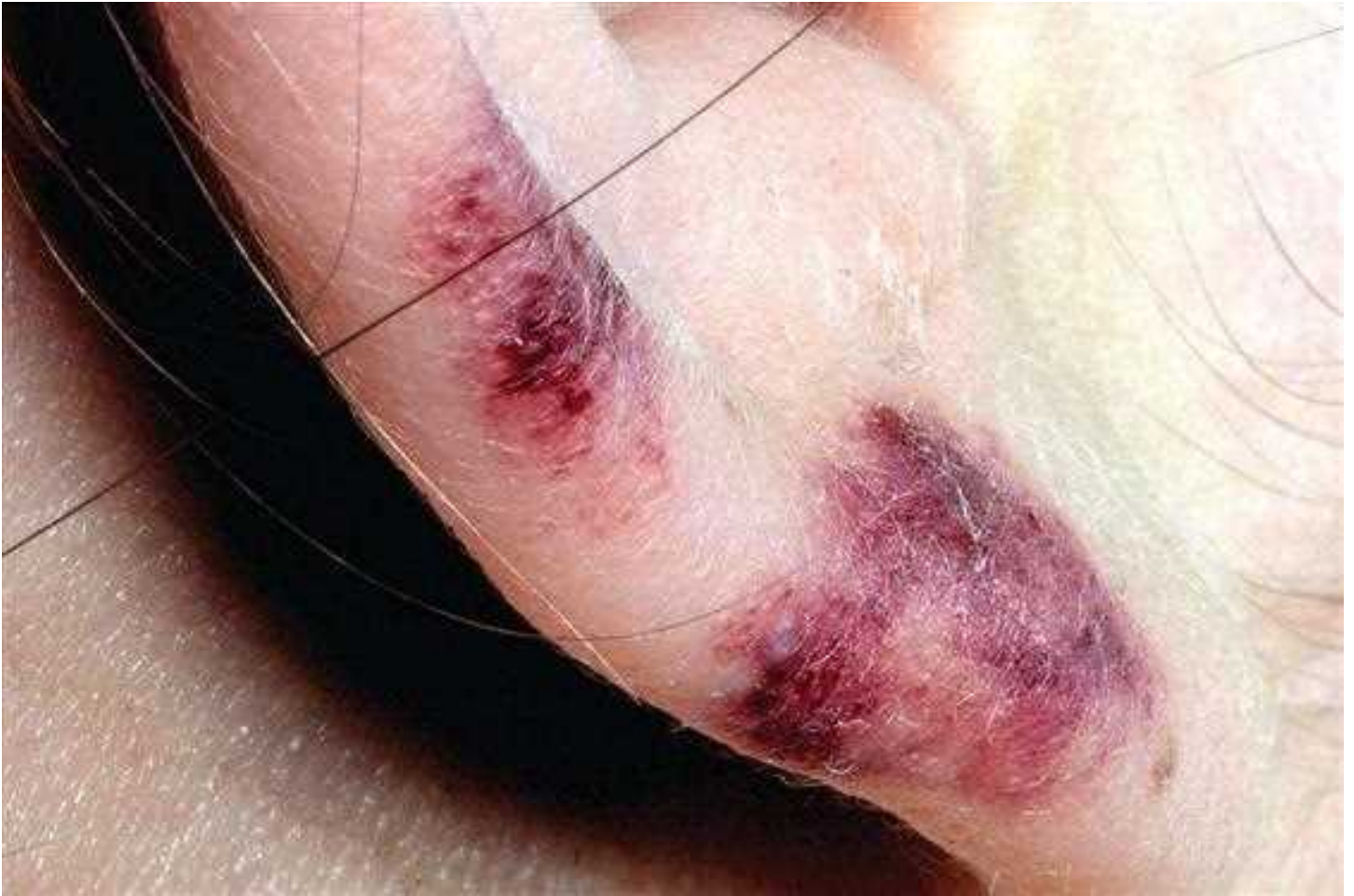

Figure 9.11 Antiphospholipid syndrome in systemic lupus erythematosus affecting the ears.

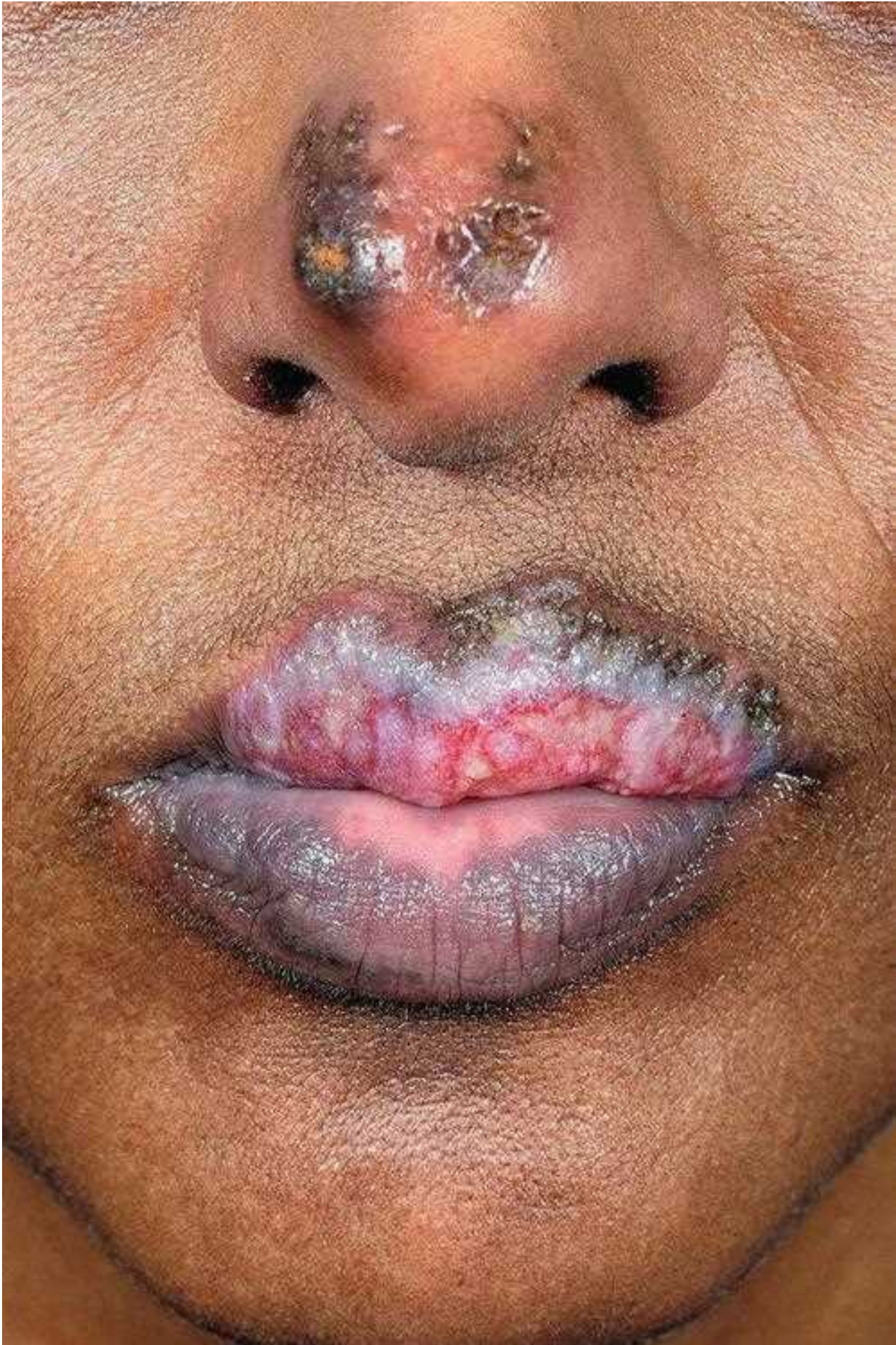


Figure 9.12 Systemic lupus erythematosus.

Diagnostic criteria for SLE include four of the following at any given time:

- malar rash
- serositis
- discoid plaques
- neurological disorders
- photosensitivity
- haematological changes
- arthritis
- immunological changes
- mouth ulcers
- ANAs
- renal changes.

Subacute lupus erythematosus (SCLE) is a variant that presents with an erythematous annular and serpiginous eruption on the skin and may be triggered by medications ([Figure 9.13](#)). Systemic involvement is less common/severe than in SLE. It is associated with a high incidence of neonatal lupus erythematosus in children born to mothers with the condition. The ENA test is positive in 60% and anticytoplasmic antibodies are present in 80% of patients.

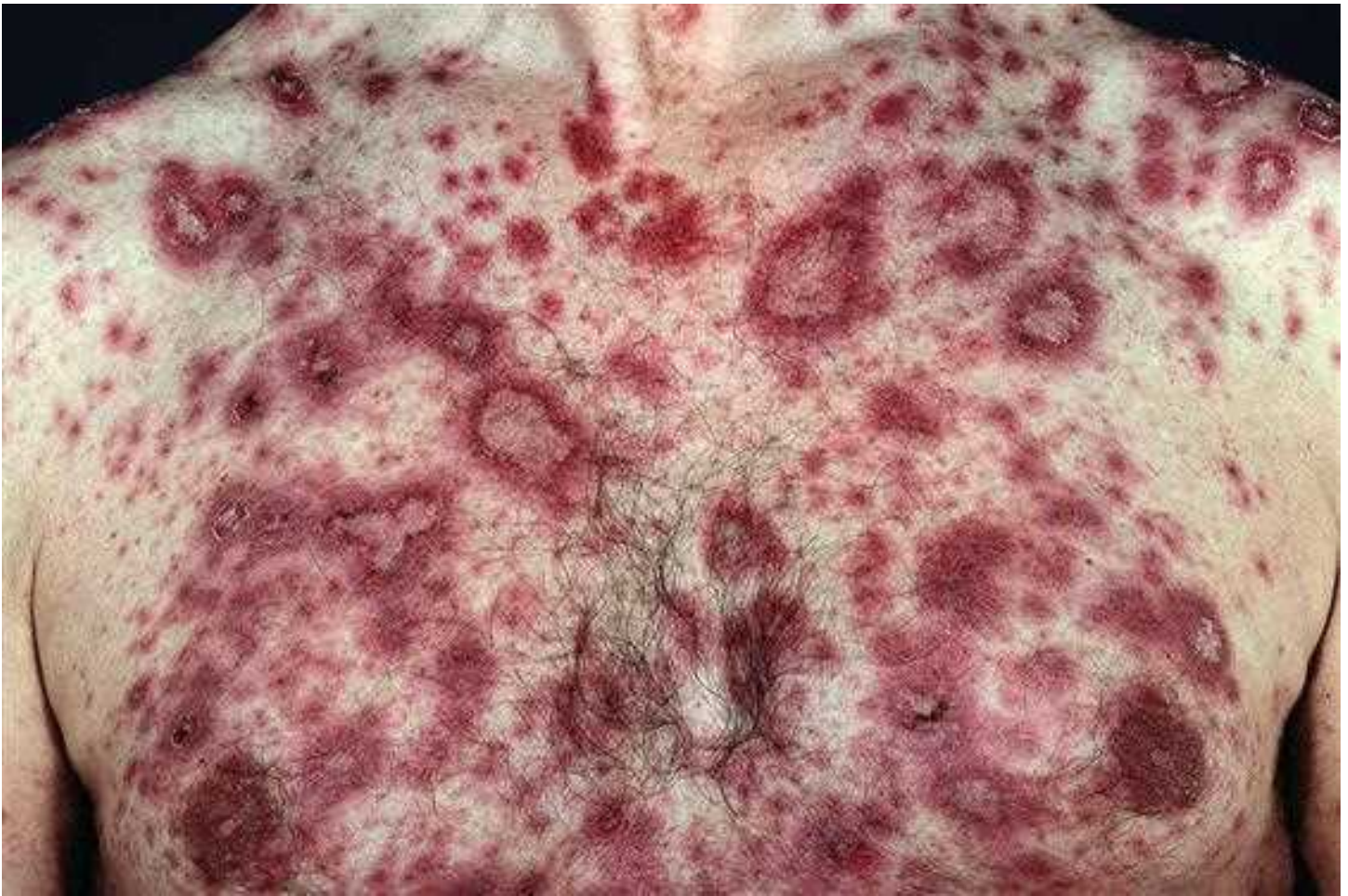
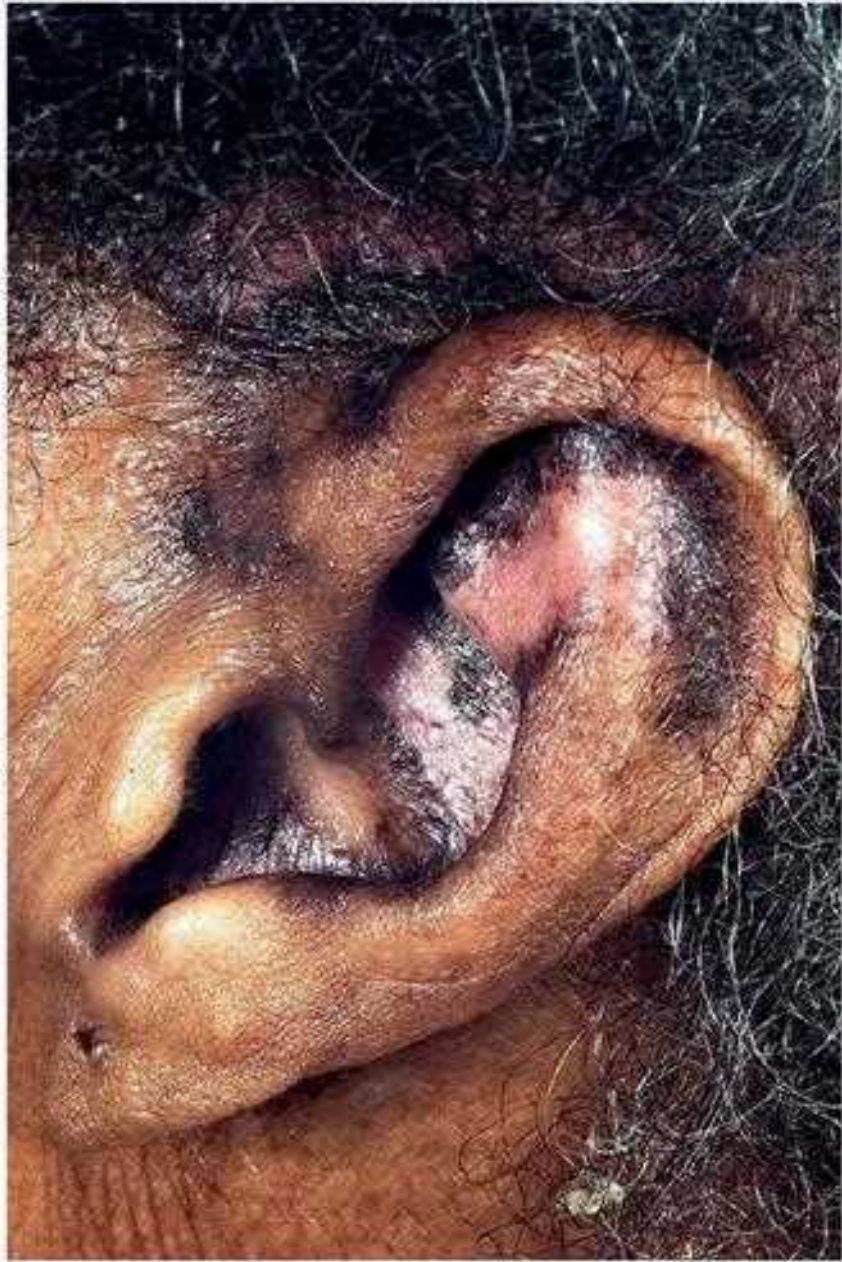
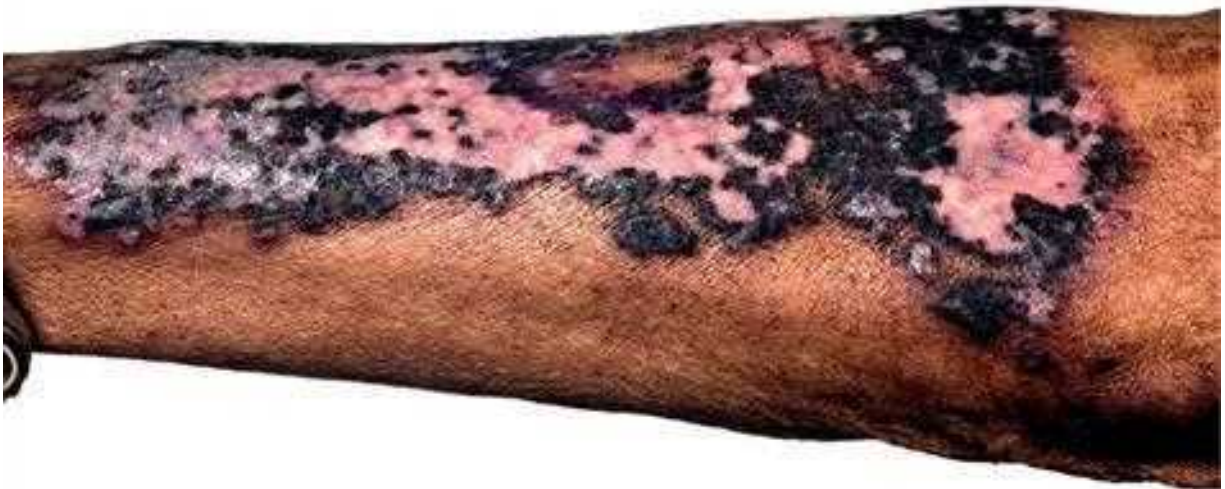Figure 9.13 Subacute lupus erythematosus triggered by terbinafine.

Discoid lupus erythematosus (DLE) is a photosensitive disorder in which well-defined erythematous lesions with atrophy, scaling, and scarring occur on the face, scalp (alopecia, follicular plugging) ([Figure 9.14a](#)), and occasionally arms ([Figure 9.14b](#)). This is a condition in which circulating ANAs are very rare and only 5% of patients go on to develop SLE. DLE should be treated with potent and super-potent topical steroids to limit scarring.



(a)



(b)

Figure 9.14 (a) Discoid lupus erythematosus classically affects the ears. (b) Discoid lupus erythematosus affecting sun-exposed skin.

Neonatal lupus erythematosus is caused by transplacental passage of maternal lupus antibodies (particularly Ro/La) to the neonate who may suffer skin lesions, which are characterised by annular scaly and inflammatory lesions on the face/scalp (**Figure 9.15**) and congenital heart block (which may require pacing). Skin lesions usually require topical steroid to reduce the likelihood of scarring/skin discolouration; the rash subsides as the level of autoantibody depletes.

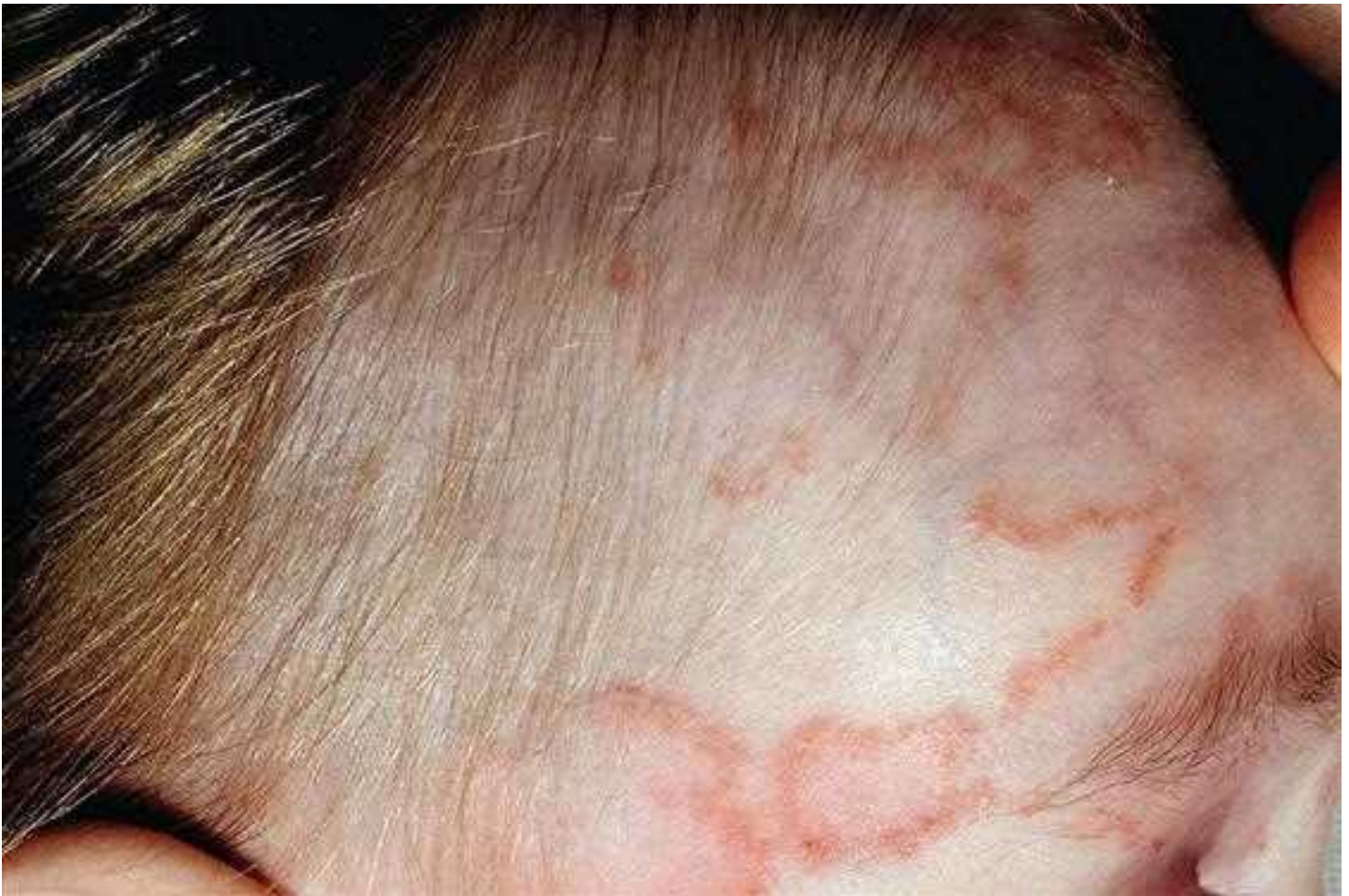

Figure 9.15 Neonatal lupus erythematosus.

Treatment of SLE with threatened or actual involvement of organs is important. Prednisolone is usually required and sometimes additional immunosuppressant drugs such as azathioprine and mycophenolate mofetil. Treatment of DLE is generally with topical steroids and sunscreen. Hydroxychloroquine 200 mg once/twice daily can be effective. Rarely hydroxychloroquine can cause ocular toxicity; however, patients should be asked to report any visual disturbance.

Dermatomyositis

Dermatomyositis is a rare disorder that affects the skin, muscle, and blood vessels. The cause is unknown but derangement of normal immune responses is observed. Evidence suggests that dermatomyositis may be mediated by damage to blood vessel walls triggered by a change in the humoral immune system, which leads to cytotoxic T-cell damage to skin and muscle. In the early stages, there is deposition of IgG, IgM, and C3 at the dermoepidermal junction as well as a lymphocytic infiltrate with CD4+ cells and macrophages. Circulating immune complexes have been isolated in up to 70% of patients, and autoantibodies may be demonstrated. Dermatomyositis in adults may precede the diagnosis of an underlying tumour (most commonly breast, lung, ovary, or gastrointestinal tract), and therefore patients should be investigated thoroughly.

Clinically, there is a rash in a mainly photosensitive distribution characterised by a purple hue (heliotrope) on the upper eyelids, cheeks, and forehead. The anterior 'V' ([Figure 9.16](#)) and posterior aspect (shawl sign) of the neck are usually involved. The dorsal surface of the fingers may be affected by the erythematous eruption and purplish (Gottron's) papules may predominate over the dorsal finger joints ([Figure 9.17](#)). Ragged cuticles and dilated nail-fold capillaries may also be seen ([Figure 9.18](#)). There is a variable association with muscle discomfort and weakness, which is mainly in the proximal limbs but bulbar and respiratory muscles may be affected.

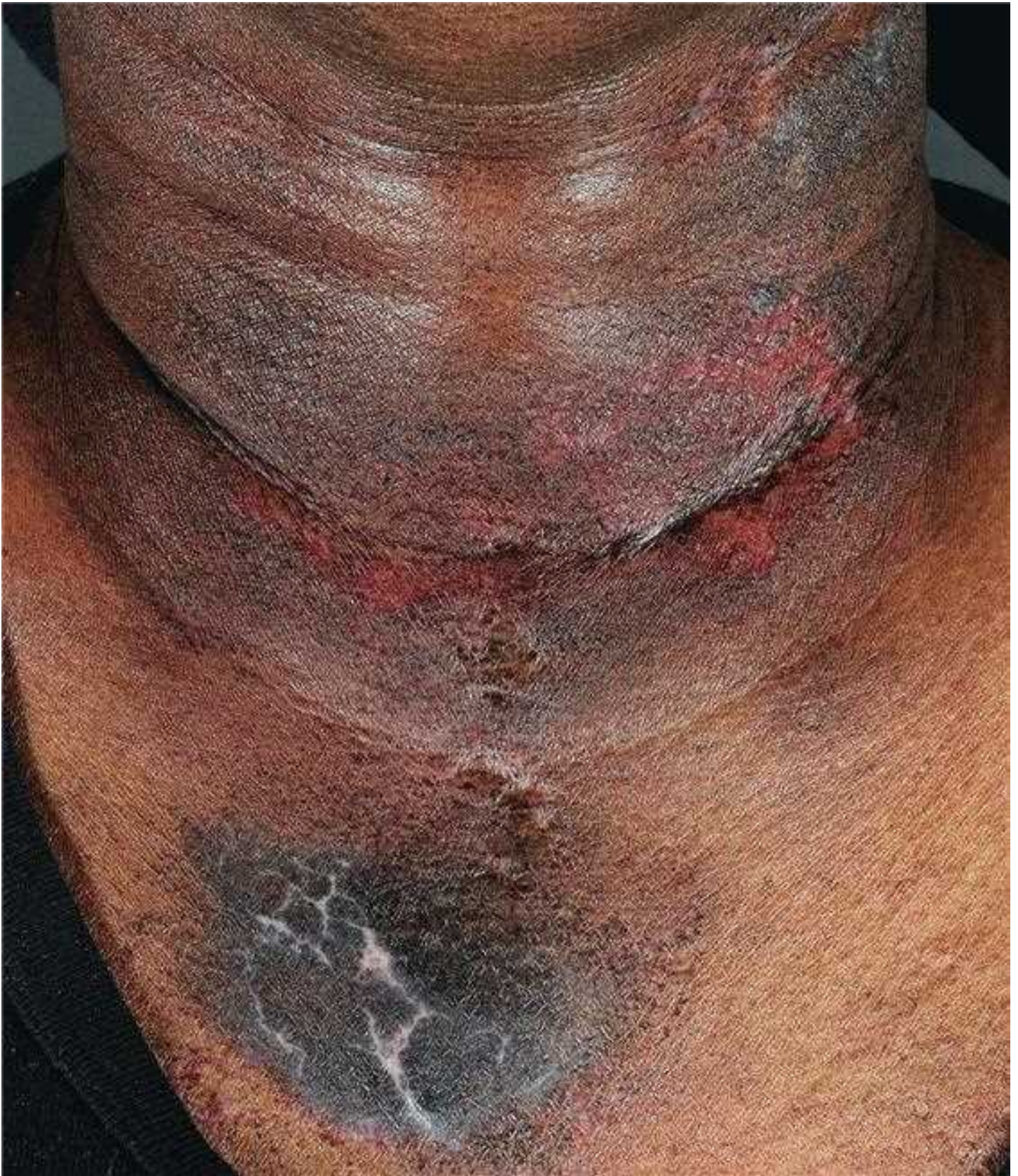

Figure 9.16 Dermatomyositis rash on the 'V' of the neck.

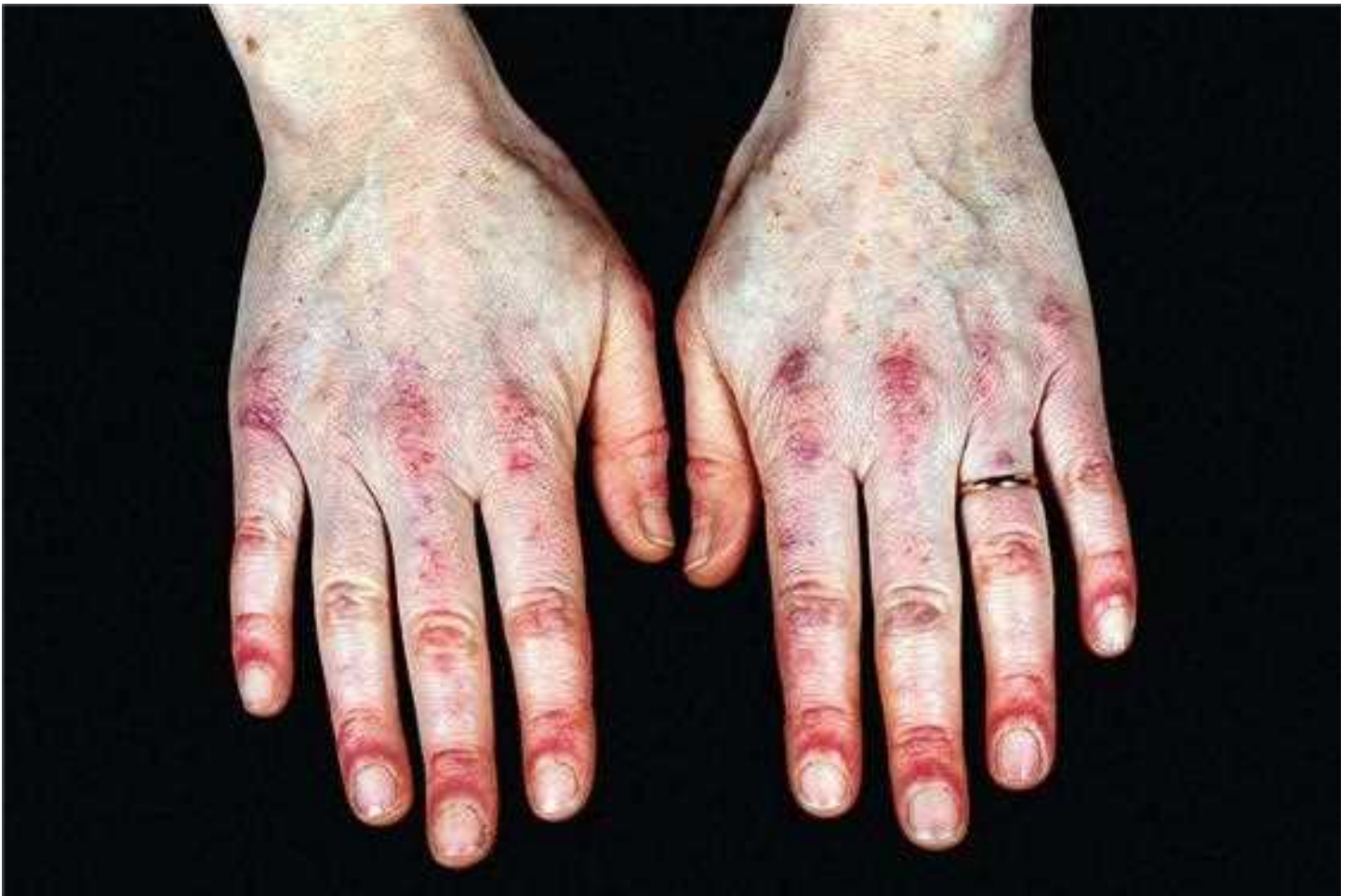

Figure 9.17 Dermatomyositis of the hands.

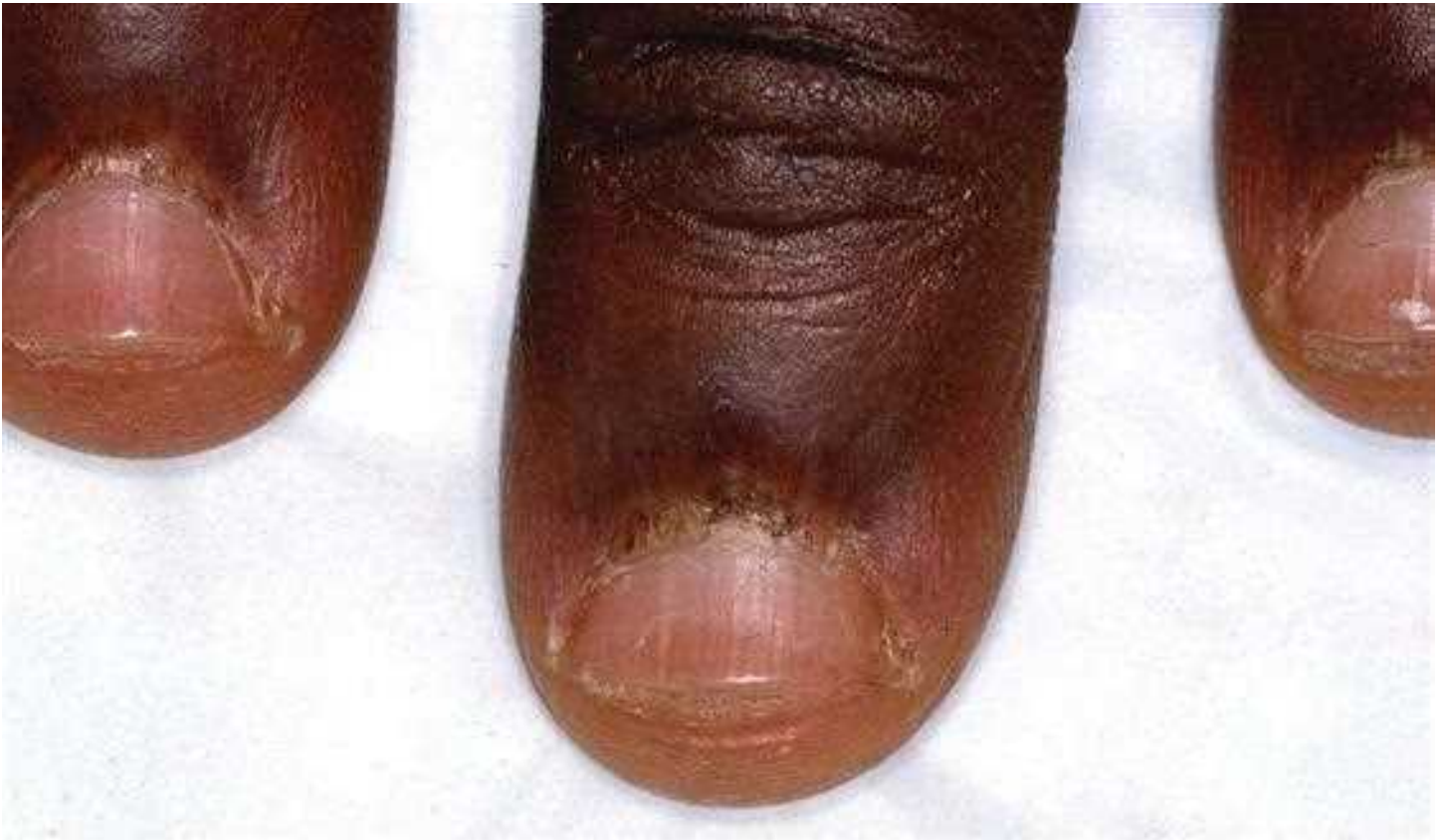

Figure 9.18 Dermatomyositis: ragged cuticles.

Investigations include myositis associated/specific antibodies including Anti-Ro, anti-Jo-1, Anti-PM/Scl, Anti-Ku, Anti-U1RNP, Anti-Mi-2, Anti-NXP-2, Anti-MDA5, Creatine phosphokinase (CK), and ESR may be elevated. Skin and muscle biopsy can be helpful in supporting the diagnosis. Electromyography and magnetic resonance imaging (MRI) can help demonstrate myositis.

Treatment with high-dose systemic corticosteroids (60–100 mg daily) or pulsed methyl prednisolone (1 g daily for three days) helps achieve rapid control of symptoms. Pulsed cyclophosphamide, azathioprine, methotrexate, and mycophenolate mofetil may also be used to control the disease. Treatment of any underlying malignancy will usually lead to resolution of these skin signs.

Mixed connective tissue disease (MCTD)

A group of patients with overlapping features of systemic lupus, scleroderma, and myositis with characteristic autoantibodies have been diagnosed with so-called MCTD. Although at first this group of mainly young women (age 15–25 years) seem difficult to characterise, clinically they usually have Raynaud's phenomenon, sclerodactyly/swollen hands, arthritis/arthritis, Sjögren's syndrome, myositis, malaise, oesophageal dysmotility, trigeminal neuralgia, and pulmonary hypertension. Patients usually have positive antibodies to U1-ribonucleoprotein (RNP) and small nuclear ribonucleoprotein (snRNP). Treatment aims to reduce pain and maintain function, with the aim of trying to keep patients as active as

possible. Traditional non-steroidal anti-inflammatory drugs (NSAIDs) are used to reduce pain and inflammation and the newer cyclooxygenase 2 (COX-2) inhibitor celecoxib is increasingly used to help reduced arthritis and myositis. Hydroxychloroquine can also be used and for more refractory disease low-dose oral corticosteroids and methotrexate.

Further reading

Mack, C.P. (2017). *Dermatomyositis: Diagnosis, Risk Factors & Treatment Options*. Nova Science Publishers.

Roccatello, D. and Lorenzo, E. (2016). *Connective Tissue Disease: A Comprehensive Guide*, vol. 1. New York: Springer.

CHAPTER 10

The Skin and Systemic Disease

Rachael Morris-Jones

Guy's and St Thomas' NHS Foundation Trust, London, UK

OVERVIEW

- Skin changes may be the first sign of an underlying systemic disease.
- Widespread reactive rashes result from underlying infections, medications, connective tissue diseases, and malignancy.
- Characteristic skin reactions such as erythema multiforme and erythema nodosum are often associated with underlying diseases.
- Reduced numbers of melanocytes can be genetic or associated with autoimmune disease or hormonal changes.
- Increased pigment in the skin can be associated with hormonal changes or underlying neoplasia.
- Generalised pruritus without a skin rash is a strong indicator of an underlying systemic disease – such as renal/hepatic dysfunction.
- Gastrointestinal disease may be associated with skin conditions such as dermatitis herpetiformis and pyoderma gangrenosum.

Introduction

The skin is the window on underlying systemic diseases as it may give visible diagnostic clues to underlying disease ([Box 10.1](#)). Cutaneous manifestations of systemic diseases are numerous and may be one of the first indicators of an underlying illness. Therefore, recognition of these reaction patterns and classic lesions in the skin associated with systemic disease can be a valuable aid to rapid and accurate diagnosis ([Box 10.2](#)). Systemic diseases may affect the skin in the same way that it affects other internal organs – such as connective tissue diseases ([Chapter 9](#)). However, underlying conditions may be associated with skin changes brought about by quite different processes, such as those seen in acanthosis nigricans (AN), dermatomyositis, and erythema multiforme (EM).

Box 10.1 Clues to a possible underlying systemic disease

- Rash associated with other symptoms such as joint pains, weight loss, fever, weakness, breathlessness, and altered bowel function.
- Rash not responding to topical treatments.
- Erythema of the skin due to inflammation around the blood vessels, which may be migratory or fixed.
- Vasculitis, characterised by non-blanching often palpable purplish fixed lesions which may be painful and blistering.
- Unusual changes in pigmentation or texture of the skin.
- Palpable dermal lesions secondary to granulomas, metastases, lymphoma, or deposits of amyloid, and so on.

Box 10.2 Characteristic rashes associated with underlying systemic disease

- *Erythema multiforme*. Herpes simplex virus, mycoplasma pneumonia, hepatitis B/C, borreliosis, pneumococcus (medications).
- *Pyoderma gangrenosum*. Haematological malignancy, inflammatory bowel disease, rheumatoid arthritis, monoclonal gammopathy.
- *Erythema nodosum (EN)*. Streptococcal infection, TB, sarcoid, pregnancy, inflammatory bowel disease, Hodgkin's lymphoma, Behçet's disease.
- *Vasculitis*. Hepatitis B/C, streptococcal infection, parvovirus B19, systemic lupus erythematosus (SLE), rheumatoid, inflammatory bowel disease, leukaemia, lymphoma.

Many widespread reactive cutaneous reactions are a result of medications taken and are manifested as toxic erythema ([Chapter 7](#)). The florid skin lesions associated with HIV vary from severe manifestations of common dermatoses to rare skin infections to exaggerated hypersensitivity reactions to drugs ([Chapter 15](#)). Drug rashes and manifestations of HIV are important topics and are addressed in detail in [Chapters 7](#) and [15](#) respectively.

Skin reactions associated with infections

Toxic erythema is the term used for a widespread symmetrical reactive rash consisting of maculopapular erythema ([Figure 10.1](#)) which looks ‘morbilliform’ (which means measles-like). The rash usually starts on the trunk and then spreads to the limbs and is blanching and may be mildly itchy. Toxic erythema is most commonly triggered by viruses including measles, rubella, Epstein–Barr virus (glandular fever patients given amoxicillin), parvovirus B19, West Nile virus, Zika, human herpes virus 6 (roseola infantum), flavivirus (dengue), coxsackievirus 4/5, and typhus (*Salmonella typhi*); bacterial infections such as scarlet fever (group A *Streptococcus*), Rickettsiosis (Rocky Mountain spotted fever), and parasitic infections (trypanosomiasis – sleeping sickness) can also result in this widespread reactive rash. No treatment is usually required for these toxic erythema rashes except an emollient and occasionally a mild topical steroid if symptomatic; what is required is management of the underlying disease.

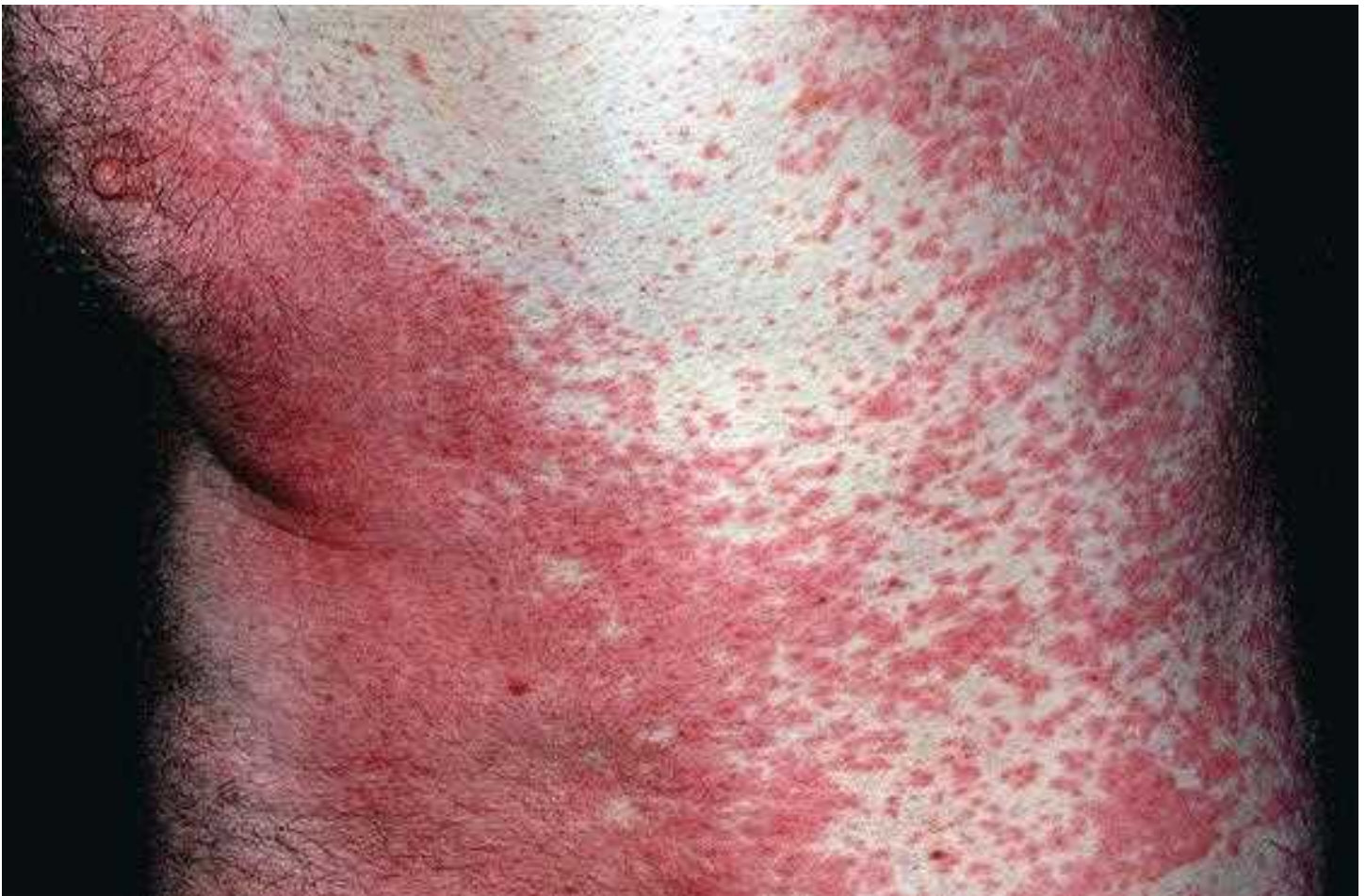

Figure 10.1 Toxic erythema reactive morbilliform rash.

EM consists of lesions that are erythematous macules that become raised and typically develop into characteristic ‘target lesions’ ([Figure 10.2](#)) in which there is a dusky red or purpuric/blistered centre with a pale indurated zone surrounded by an outer ring of erythema. The lesions are usually asymptomatic (occasionally painful) and may be few/multiple/diffuse and symmetrical, developing over a few days at acral sites (palms, soles, digits, elbows,

knees, and face). The rash is thought to result from an immunologically mediated hypersensitivity reaction. Systemic symptoms of the underlying infection usually precede the EM rash by 2–14 days. Involvement of mucous membranes (oral, conjunctival, genital) accompanies the classic cutaneous EM rash (<10% of body surface area) in the so-called EM Major. The most common infectious trigger is herpes simplex virus (HSV 1 or 2), which usually presents with a cold sore on the lip or sores/ulcers on the genitals or rarely herpetic whitlow. Other infectious triggers include *Mycoplasma pneumonia* (shortness of breath, cough, chest radiograph relatively normal), haemolytic *Streptococcus* (upper respiratory tract infection), adenovirus, coxsackievirus, Epstein–Barr virus, parvovirus B19, viral hepatitis, orf, borreliosis, and *Neisseria meningitides*. Adverse reactions to medications are also a common trigger for EM ([Chapter 7](#)). If possible, treat the underlying disease (e.g. aciclovir, penicillin) and apply topical steroid to skin lesions if painful or blistering; occasionally systemic steroids may be needed. EM can be recurrent with each reactivation of HSV, in which case patients may need secondary prophylaxis with aciclovir and possibly additional azathioprine.

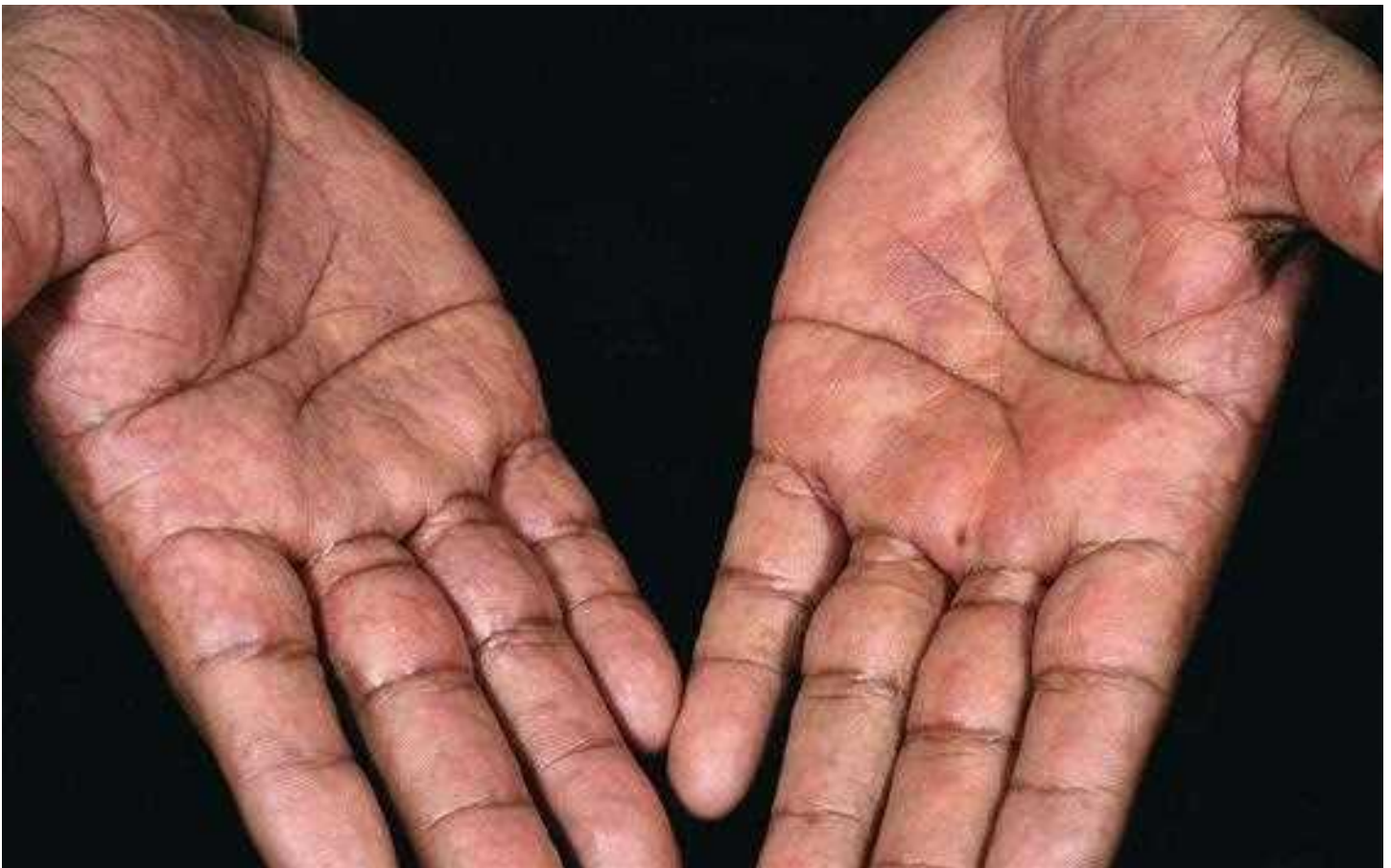

Figure 10.2 Erythema multiforme.

Gianotti–Crosti Syndrome (GCS) – papulovesicular acrodermatitis of childhood is a viral exanthema characterised by sheets of minute erythematous papules which may become vesicular in young children (age <12 years) that are distributed initially on the limbs (elbows/knees/feet/hands) and may affect the face (sparing the trunk). Individual erythematous papules may coalesce into clusters of larger patches of erythema and may feel ‘rough’ like

sandpaper and usually lasts for several weeks. Viral triggers include enteroviruses, echo virus, respiratory syncytial virus, rotavirus, rubella parvovirus B19, hepatitis B, and Epstein–Barr virus. GCS may also be triggered by vaccinations (polio, diphtheria, hepatitis B, measles, influenza, pertussis, swine-flu H₁N₁). GCS is more common in children with atopic dermatitis (AD). The exanthema settles over a few weeks with simple emollients.

Erythema nodosum (EN) consists of tender/painful subcutaneous erythematous nodules on the shins (arms can also be affected) secondary to a hypersensitivity reaction leading to inflammatory panniculitis (inflammation in the adipose tissue) ([Figure 10.3](#)). The lower leg lesions usually evolve over a few days following systemic symptoms such as fever and malaise and last for weeks or months depending on the trigger. Infectious causes of EN include *Streptococcus*, *Mycoplasma pneumoniae*, TB, histoplasmosis, coccidioidomycosis, and blastomycosis. Other non-infectious triggers include medications, inflammatory bowel disease, sarcoidosis, pregnancy, Behçet's, and Hodgkin's disease. In approximately 50% of cases there is no obvious cause determined. Management involves treating or removing the underlying cause, elevation and compression of the lower legs and non-steroidal anti-inflammatory drugs (NSAIDs).

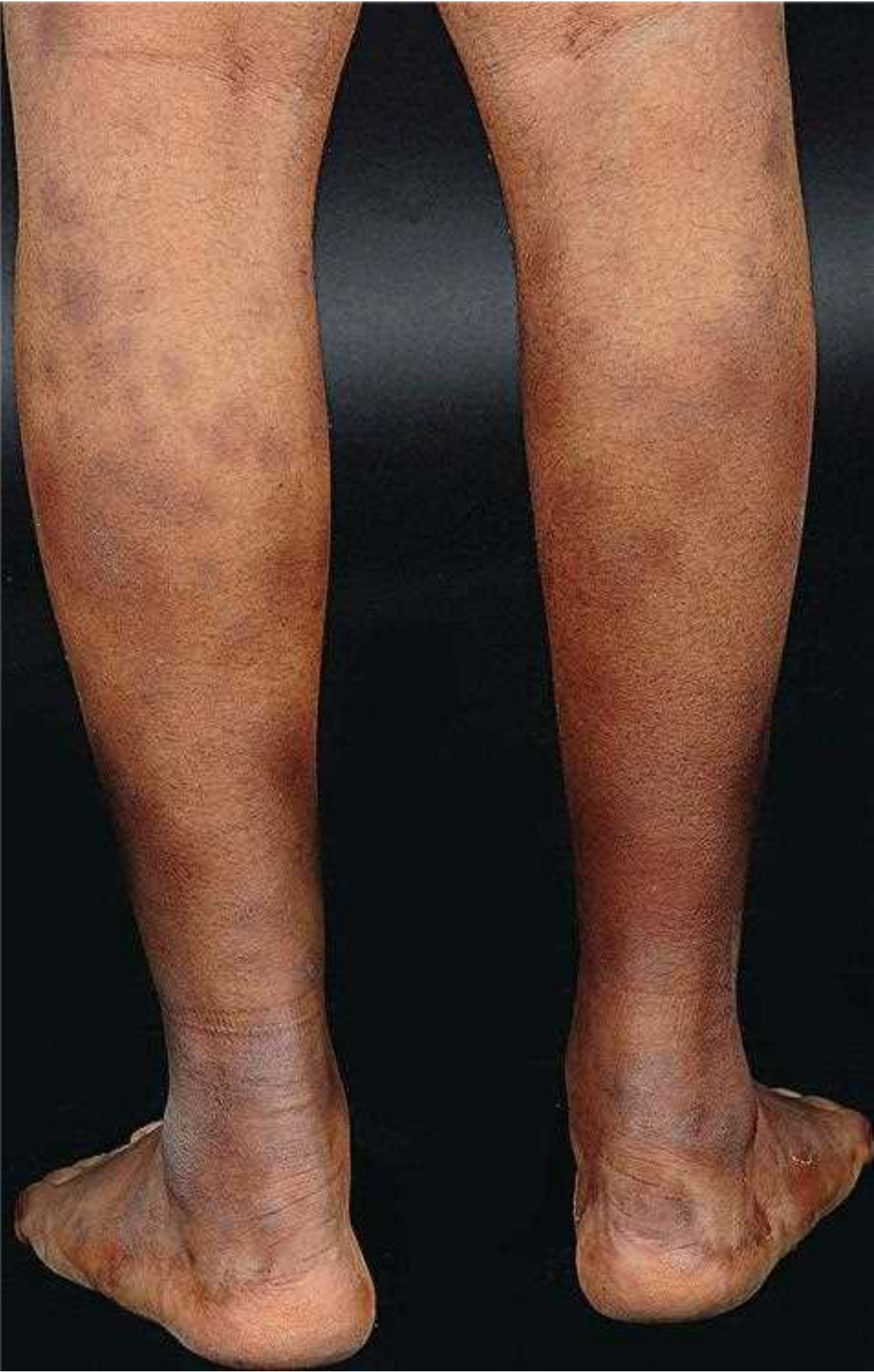

Figure 10.3 Erythema nodosum.

Erythema annulare centrifugum (EAC) consists of single/multiple erythematous expanding rings (annular/figurate/gyrate erythema) usually on the thighs or trunk which are asymptomatic. EAC lesions slowly enlarge to form incomplete/complete rings of palpable/macular erythema which may have a slight scale on the inner edge of the ring ([Figure 10.4](#)). A hypersensitivity reaction is the current thinking with triggers including Epstein–Barr virus, HIV, *Escherichia coli*, *Streptococcus*, *Trichophyton* fungal infections (tinea), *Candida albicans*, TB, and pubic lice. Other non-infectious causes include underlying leukaemia/lymphoma, solid tumours (breast, ovarian, lung carcinoma), medications, and other underlying systemic condition such as Graves' disease and sarcoid.

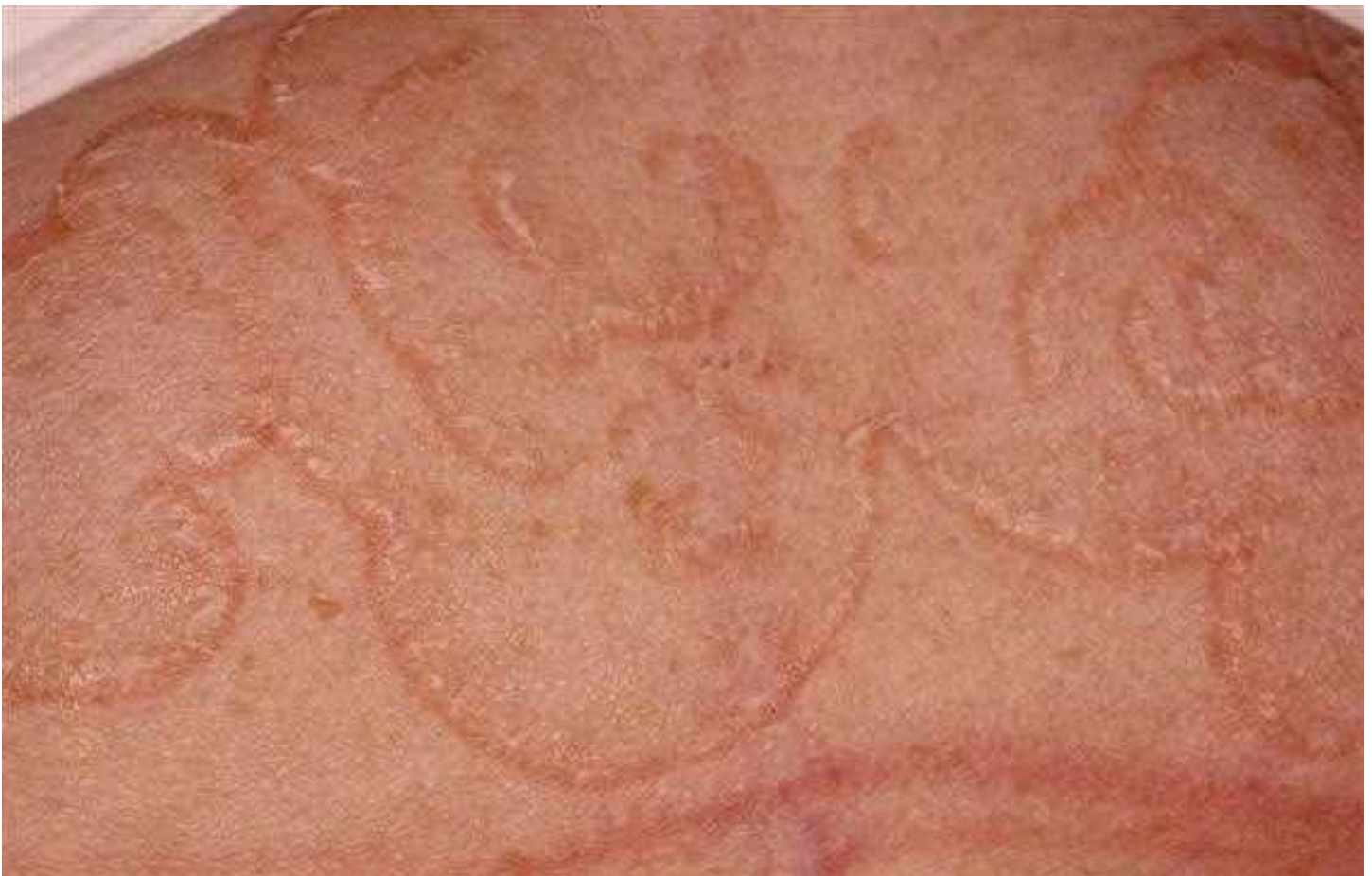

Figure 10.4 Annular erythema.

Erythema chronicum migrans is a migrating erythema that results from a cutaneous inflammatory response to infection caused by *Borrelia burgdorferi* (Lyme disease) ([Chapter 17](#)).

Sarcoidosis

The underlying aetiology of sarcoidosis remains unknown; however, there are increasing number of researchers who believe that an atypical mycobacterium may be the trigger.

Pulmonary and other systemic manifestations of sarcoidosis may occur without cutaneous disease. However, skin disease is a common presenting sign of underlying sarcoidosis in about 40% of patients. The most common skin changes are:

- EN, which is often a feature of early pulmonary disease
- asymptomatic papules, nodules, and plaques, which are associated with acute and subacute forms of the disease ([Figure 10.5](#))
- scar sarcoidosis, with papules
- lupus pernio with dusky red infiltrated lesions on the nose and fingers.

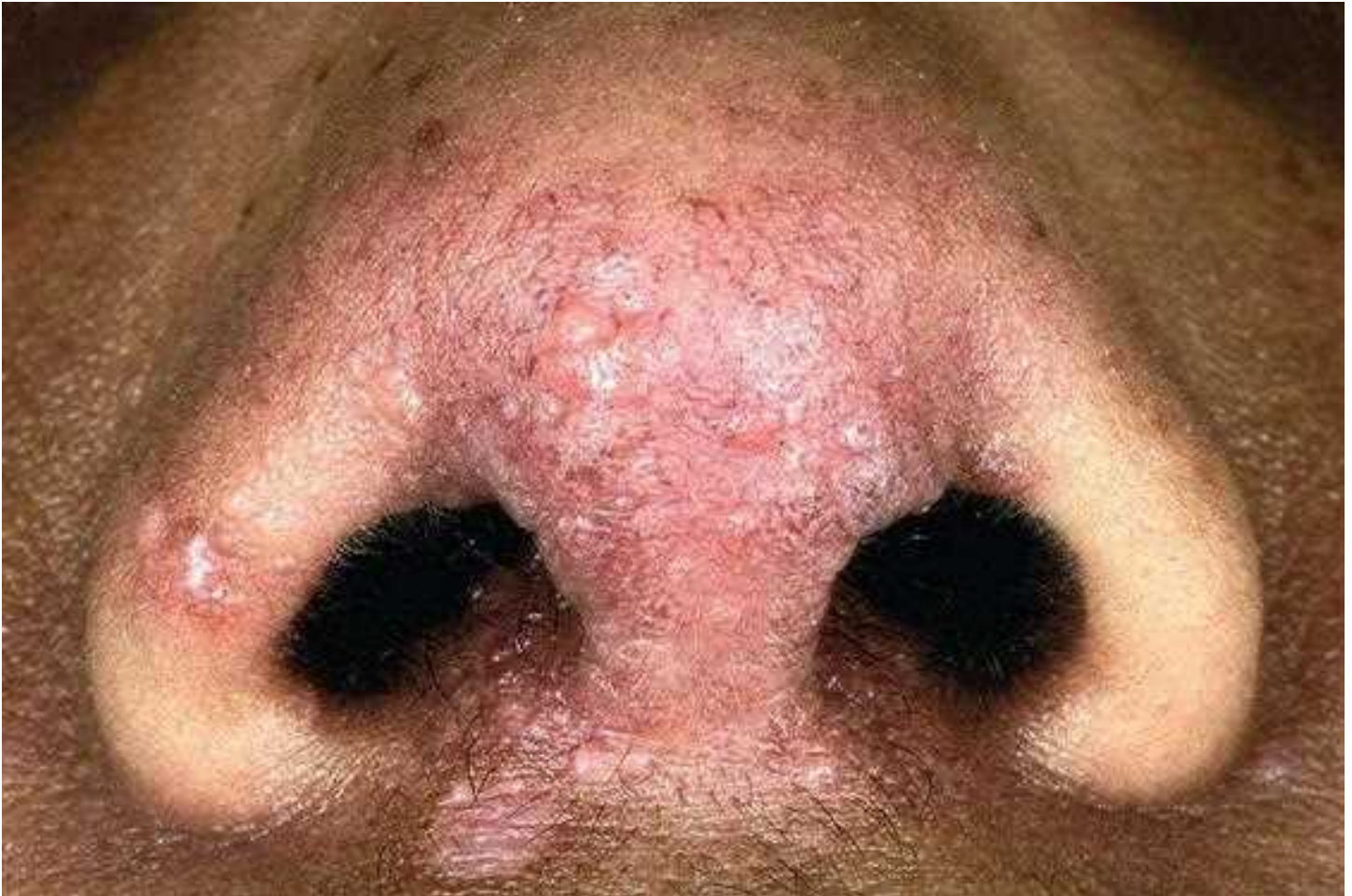

Figure 10.5 Sarcoid.

If sarcoidosis is suspected then check the serum angiotensin-converting enzyme (ACE) level, serum calcium, full blood count, liver and renal function, Erythrocyte sedimentation rate (ESR), thyroid function, prolactin, testosterone, growth hormone, FSH/LH, corticotrophin-releasing hormone, insulin-like growth factor and oestradiol. CXR looking for bilateral hilar lymphadenopathy should be requested.

Skin changes associated with hormonal imbalance

Hyperpigmentation is an increase in circulating hormones with melanocyte-stimulating

activity that occurs in hyperthyroidism, Addison's disease, and acromegaly. In pregnancy or in those taking oral contraceptives there may be a localised increase in melanocytic pigmentation of the forehead and cheeks known as *melasma* (or *chloasma*) ([Figure 10.6](#)). It may fade slowly if ultraviolet light is excluded from the affected skin using daily sun block.

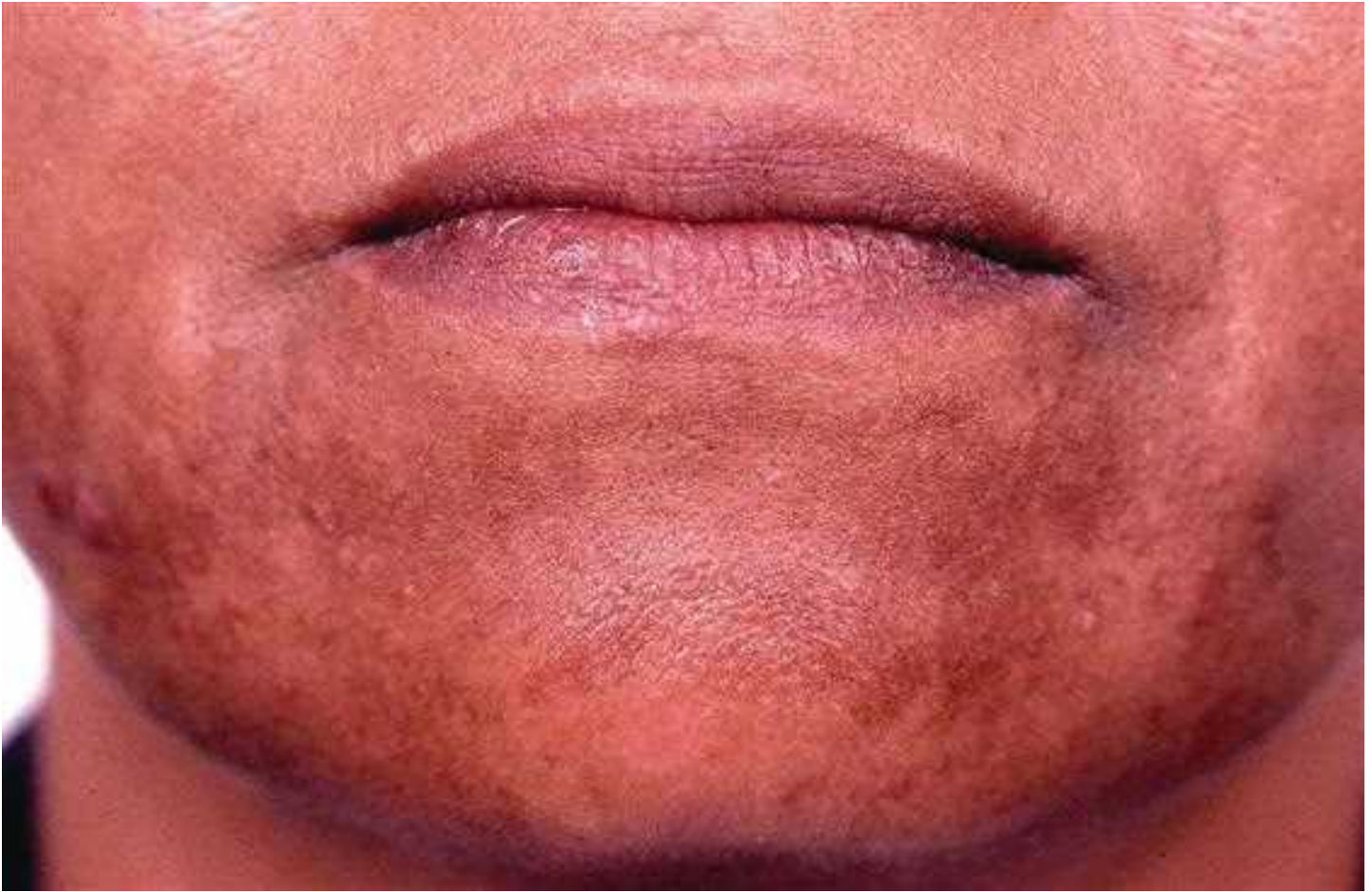
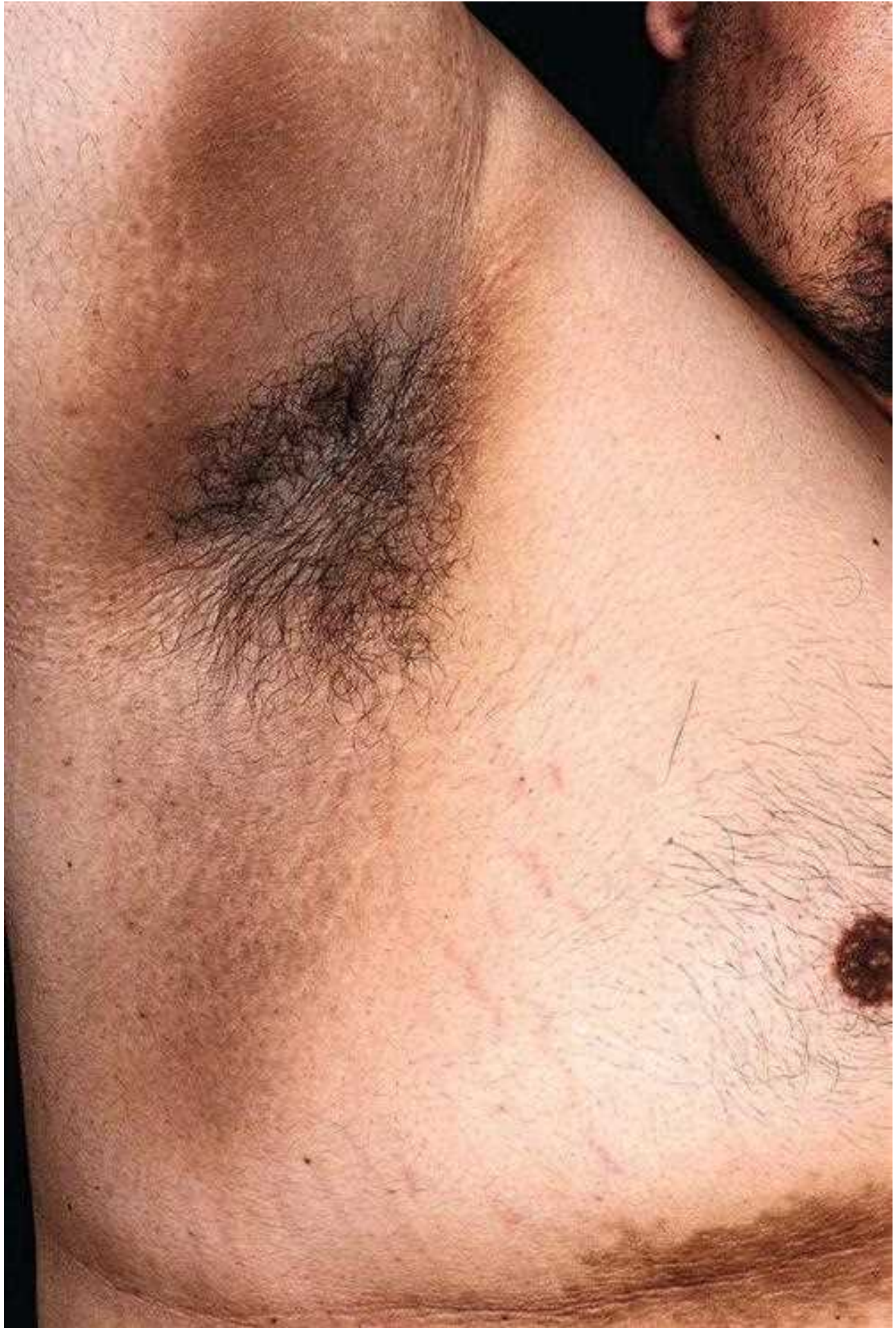
Figure 10.6 Melasma.

Hypopigmentation is a widespread partial loss of melanocyte functions with loss of skin colour seen in hypopituitarism and is caused by an absence of melanocyte-stimulating hormone.

Acanthosis nigricans (AN) is asymptomatic velvety thickening of the skin characteristically affecting the posterior and lateral aspects of the neck, axillae, and arm flexures ([Figure 10.7](#)); it appears as dark symmetrical plaques. The most common association is obesity, and with weight reduction the AN resolves. Syndromic AN is subtyped into Type A, which is associated with insulin resistance in young black women with hirsutism and polycystic ovarian syndrome, and Type B, which is associated with autoimmune conditions such as diabetes, thyroid disease, and lupus. Antibodies to insulin receptors may be detected in Type B. More extensive and rapidly evolving AN, particularly involving the lips/tongue/palms may herald underlying malignancy, particularly of the gastrointestinal (GI) tract. When the underlying cause is treated, the skin signs of AN usually regress.



[Figure 10.7](#) Acanthosis nigricans.

Diabetes leads to alteration of carbohydrate–lipid metabolism; small blood vessel lesions and neural involvement may be associated with skin lesions such as ‘diabetic dermopathy’ due to a microangiopathy, which consists of erythematous papules which slowly resolve to leave a scaling macule on the limbs. Atherosclerosis with impaired peripheral circulation is often associated with diabetes. Ulceration due to neuropathy (trophic ulcers) or impaired blood supply may occur, particularly on the feet. Diabetic patients have an increased susceptibility to cutaneous infections including staphylococcal, streptococcal, coliforms, *Pseudomonas*, and *C. albicans*.

Necrobiosis lipoidica – between 40% and 60% of patients with this condition may develop diabetes, but it is actually uncommon in the diabetic population (0.3%). However, checking of fasting glucose is recommended. Necrobiosis indicates necrosis of the underlying connective tissue with lymphocytic and granulomatous infiltrate. There is replacement of degenerating collagen fibres with lipid material. It usually occurs over the shin but may appear at any site ([Figure 10.8](#)).

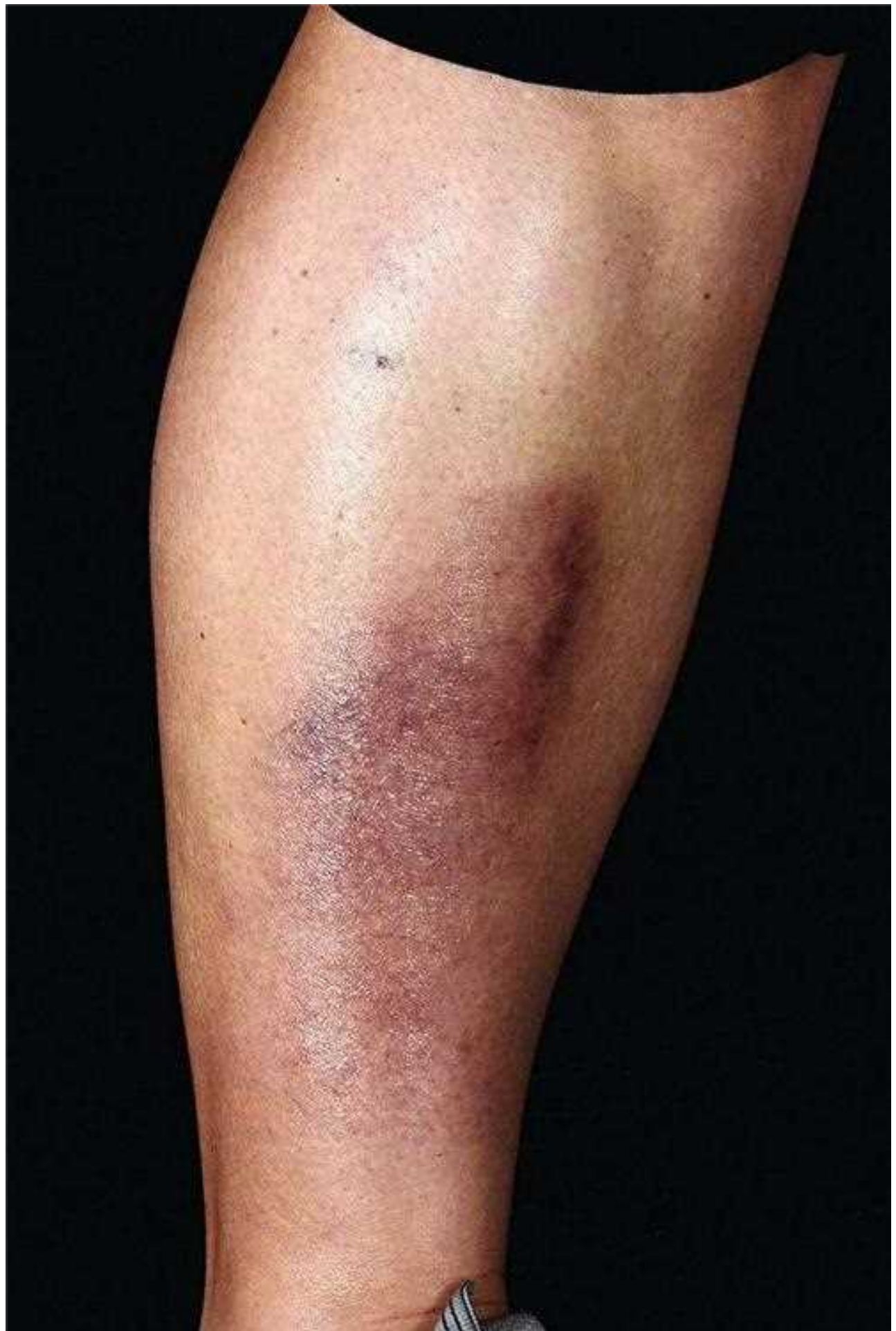
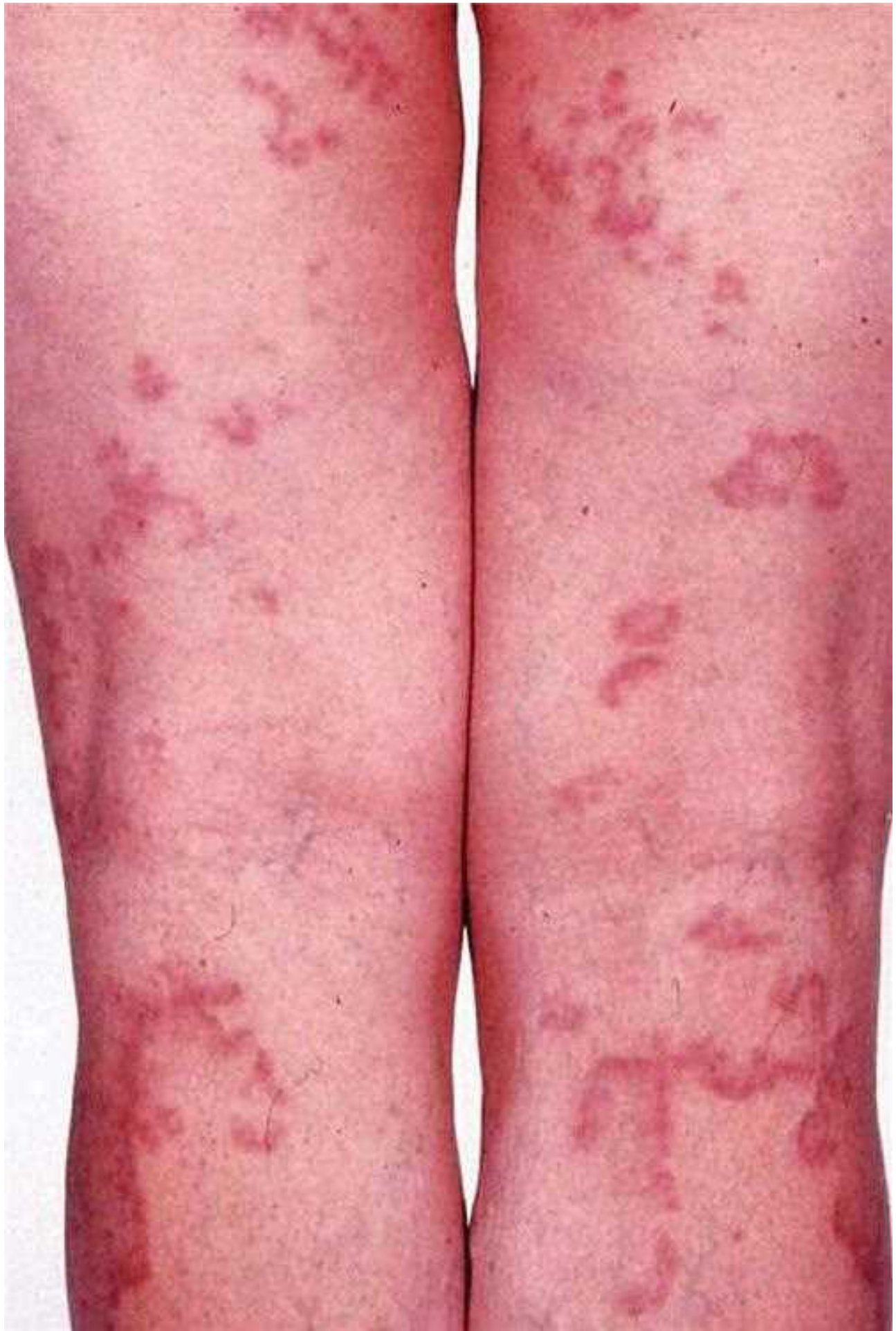
Figure 10.8 Necrobiosis lipoidica on the shin.

Granuloma annulare usually presents with localised papular lesions on the hands/feet and limbs ([Figure 10.9](#)) but may occur elsewhere also. The lesions may be partly or wholly annular and may be single or multiple. There is some degree of necrobiosis, with histiocytes forming 'palisades' as well as giant cells and lymphocytes. It is seen more commonly in women under the age of 30. There is an association with insulin-dependent diabetes. It may be pruritic or asymptomatic and is usually self-limiting but may recur.



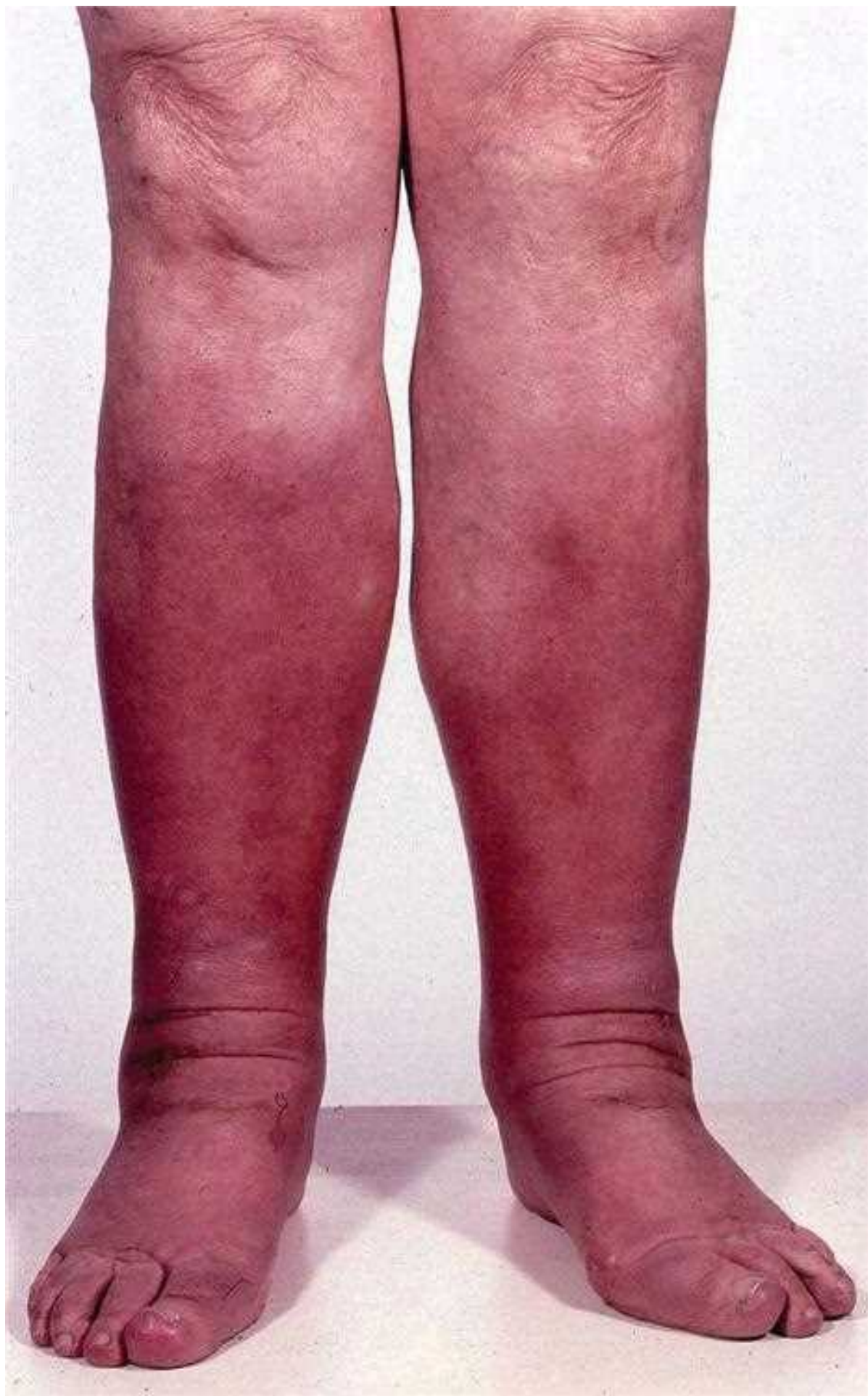[Figure 10.9](#) Granuloma annulare.

Thyroid disease

Thyroid disease is associated with changes in the skin, hair, and nails and may be among the earliest signs of underlying thyroid dysfunction ([Table 10.1](#)). Associated increases in thyroid-stimulating hormone concentration may lead to pretibial myxoedema ([Figure 10.10](#)). In autoimmune thyroid disease, vitiligo, and other autoimmune conditions may be present.

[Table 10.1](#) Clinical signs of thyroid disease.

| Hypothyroidism | Hyperthyroidism |
|--|--------------------------------------|
| Dry skin | Soft, thickened skin |
| Oedema of eyelids and hands | Pretibial myxoedema |
| Absence of sweating | Increased sweating (palms and soles) |
| Coarse, thin hair; loss of pubic, axillary, and eyebrow hair | Thinning of scalp hair |
| Pale 'ivory' skin | Diffuse pigmentation |
| Brittle poorly growing nails | Rapidly growing nails |
| Purpura, bruising, and telangiectasia | Palmar erythema |
| | Facial flushing |



[Figure 10.10](#) Pretibial myxoedema.

Skin changes associated with disorders of the gastrointestinal system and liver

Skin changes may occur as part of a systemic disease involving multiple organs such as vasculitis which may be associated with polyarteritis nodosa (medium vessel vasculitis) and connective tissue diseases (such as scleroderma) or as part of a metabolic disease such as porphyria, malabsorption/dietary deficiencies, and inflammatory conditions.

Malabsorption can lead to deficiency of iron, zinc, vitamins, and so on, which can result in dry skin, asteatosis, and pruritic skin, which can lead to superficial eczematous changes in a 'crazy paving' pattern. Increased pigmentation, brittle hair, and nails may also be associated with malabsorption states.

Vitamin C deficiency (scurvy) occurs in those with malabsorption problems, those on a poor diet, the elderly, and alcoholics and is manifested by fatigue, weakness, perifollicular hyperkeratotic papules which look similar to bruises usually on the legs, with corkscrew hairs. Bleeding and swollen gums may also be seen, and the majority of patients are also anaemic. Vitamin C supplementation of around 1 g is usually needed initially and then 0.5 g daily for a few weeks. Symptoms and signs will then recede as vitamin levels normalise.

Zinc deficiency (*acrodermatitis enteropathica*) is usually seen in neonates either as a genetic condition (defect in zinc transporter proteins) or as a result of breast milk deficient in zinc (i.e. mother may be zinc-deficient) or malabsorption (breast/bottle-fed/weaning). Skin changes usually appear within weeks of birth with erythematous inflamed scaly skin around the mouth, anus, and eyes as well as acral sites (hands, feet, elbows, and knees) ([Figure 10.11](#)). Patches may be confused with eczema, but this eruption is not itchy and is well demarcated at localised sites. If the condition is not recognised and treated promptly then the skin can become crusted, eroded, and secondarily infected. Babies may become irritable, feed poorly, develop diarrhoea, and fail to thrive. Serum zinc levels will be low. Zinc supplementation (1 mg/kg/day) should be continued until zinc levels normalise (or lifelong in inherited forms) – skin changes take several weeks to resolve.

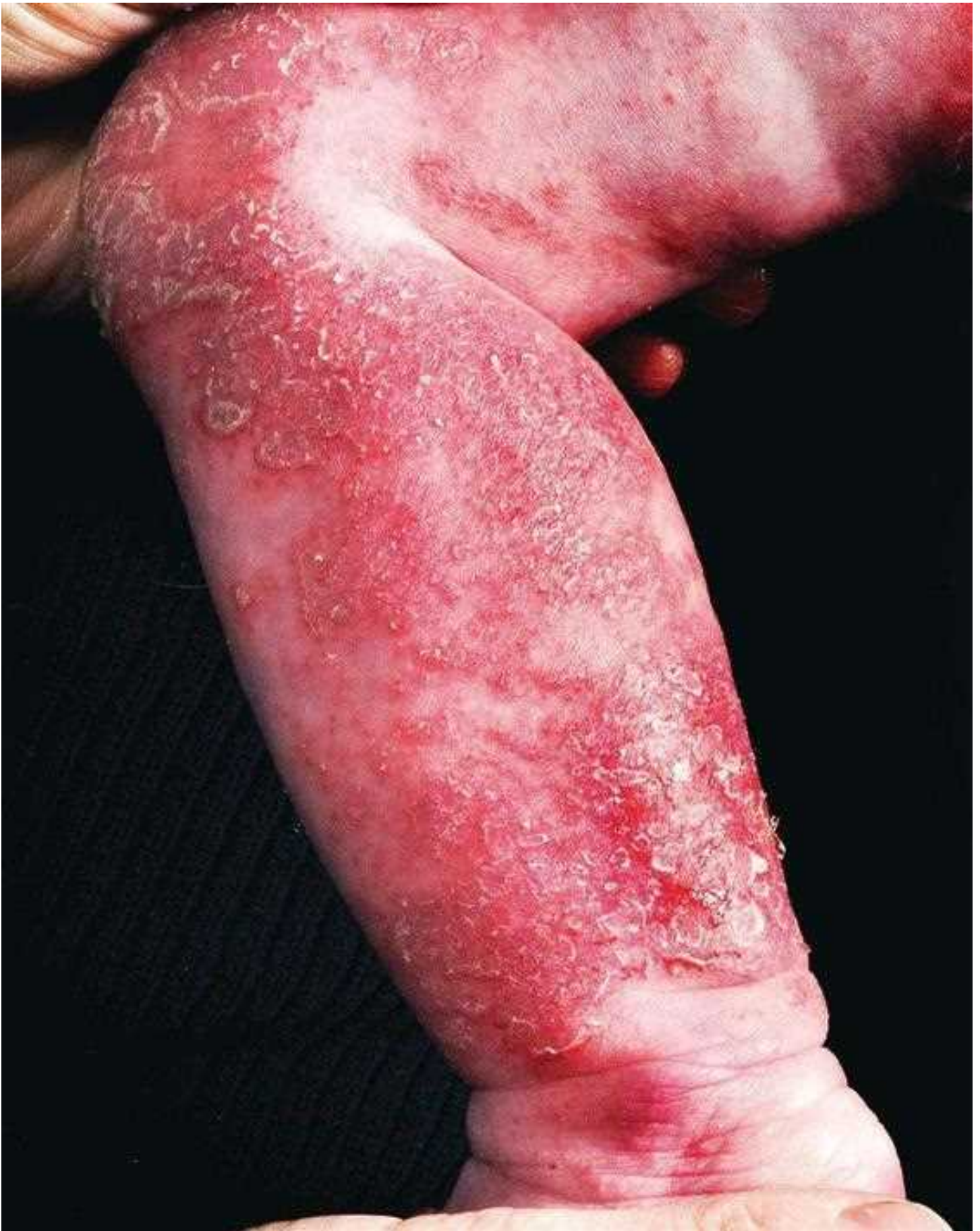

Figure 10.11 Zinc deficiency.

Shiitake mushroom flagellate dermatosis occurs in about 2% of the population as a result of ingestion of a polysaccharide toxin (lentinan) present in raw or undercooked shiitake mushrooms. Skin changes appear between one and five days after eating the mushrooms and are linear and characteristically flagellate in appearance with pruritic papules looking petechial ([Figure 10.12](#)). The rash starts to settle within a few days and then settle completely within three weeks.

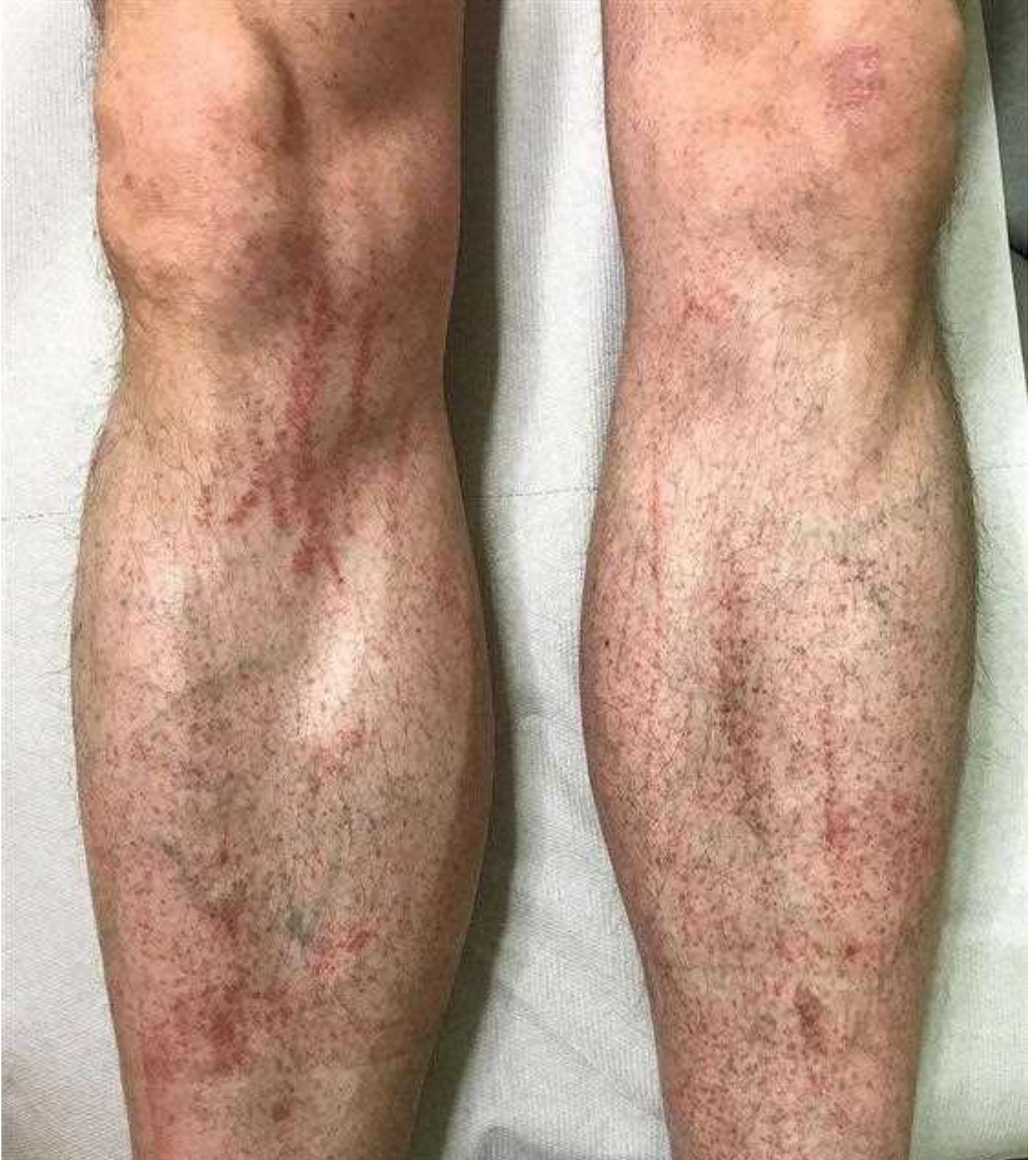



Figure 10.12 Shiitake mushroom flagellate dermatosis.

Inflammatory conditions of the bowel may lead to skin break down and pruritic rashes.

Pyoderma gangrenosum is a rapid onset painful area of necrotic skin ulceration with characteristic hypertrophic undermined purplish margins ([Figure 10.13](#)). There is a strong association with inflammatory bowel disease, rheumatoid arthritis, abnormal gamma globulins, and haematological malignancy ([Box 10.3](#)).

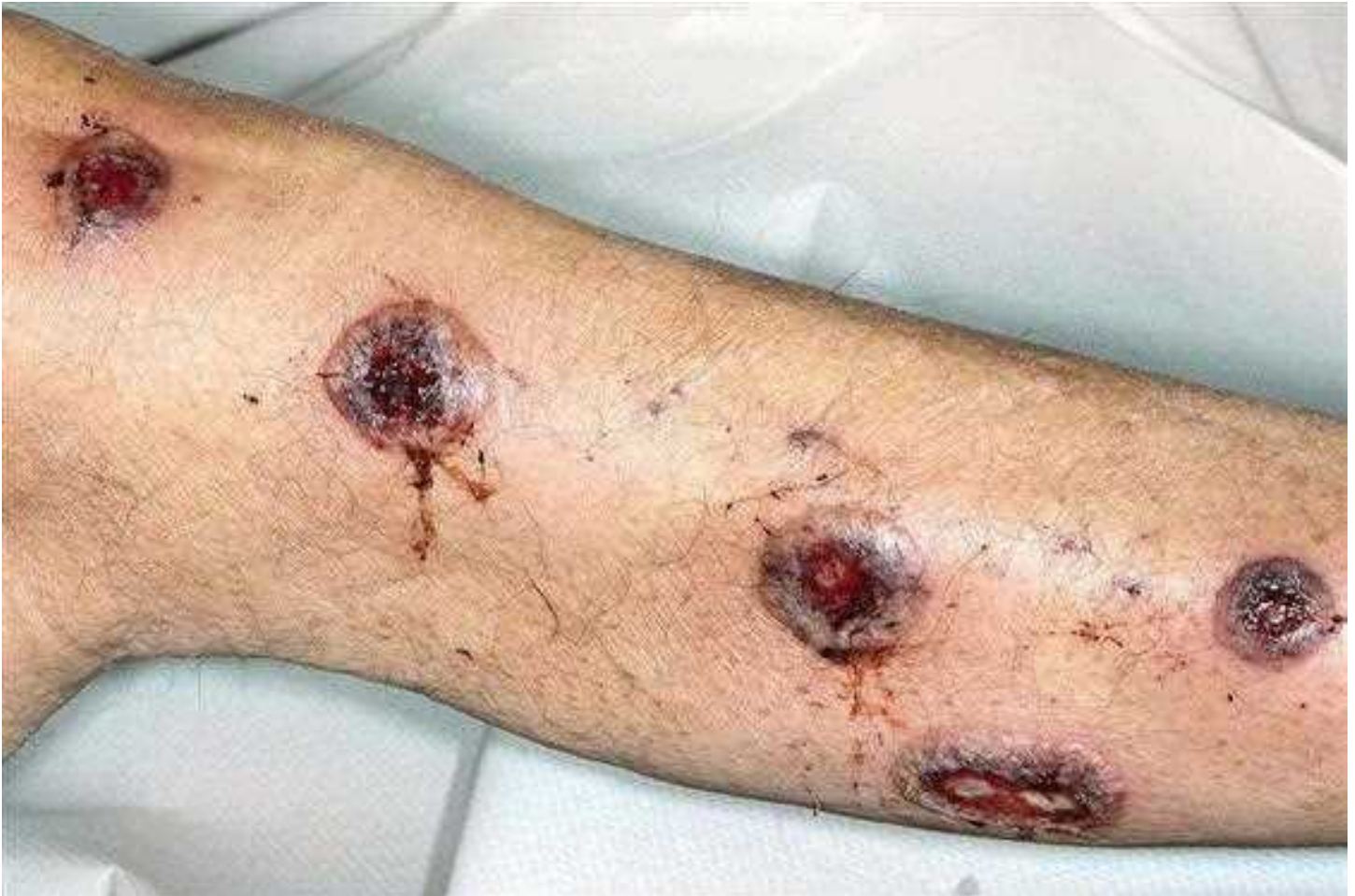

Figure 10.13 Pyoderma gangrenosum.

Box 10.3 Associations of pyoderma gangrenosum

- Ulcerative colitis
- Crohn's disease
- Rheumatoid arthritis
- Monoclonal gammopathy
- Leukaemia

Crohn's disease (regional ileitis) causes patchy inflammation of the bowel (anywhere from lips to anus) and may be associated with erosions/ulceration and sinus formation in the mucous membranes/skin/ileostomy/colostomy sites. Glossitis and granulomatous thickening of the lips and oral mucosa and vasculitis may also be associated.

Dermatitis herpetiformis is an intensely itchy, chronic skin disorder characterised by erythematous and blistering papules, particularly on the elbows, knees, and buttocks ([Figure 10.14](#)) and is usually associated with a gluten-sensitive enteropathy with some degree of villous atrophy. There is an associated risk of small bowel lymphoma.

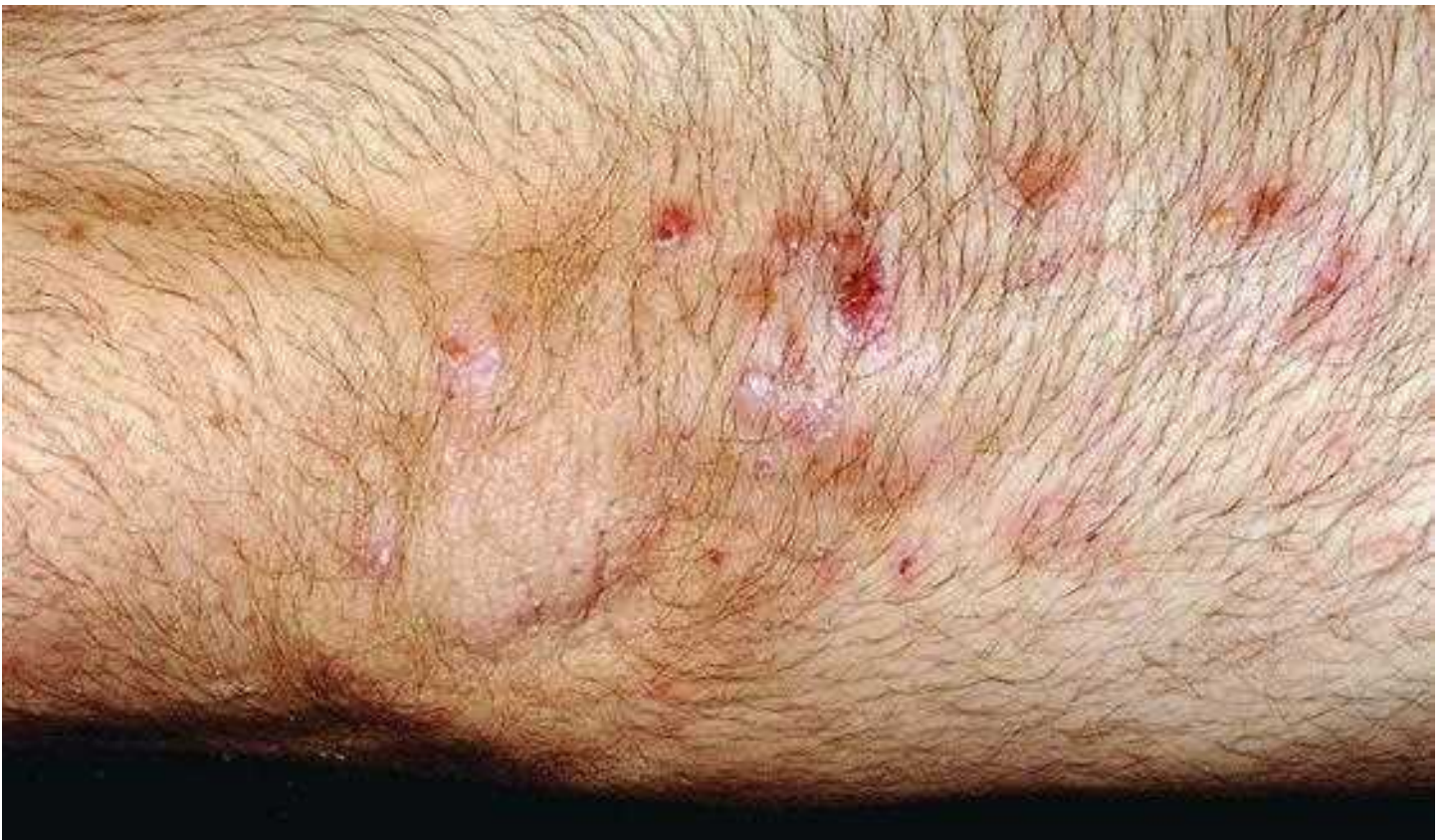

Figure 10.14 Dermatitis herpetiformis.

Congenital disorders of the bowel lead to various skin changes.

Peutz–Jeghers syndrome (hereditary intestinal polyposis syndrome) is an autosomal dominantly inherited condition characterised by the appearance in infancy of pigmented macules on the oral mucosal membranes, lips and face, hands/feet (differential diagnosis will include Addison's disease and McCune–Albright syndrome). Benign intestinal polyps, mainly in the ileum and jejunum, which rarely become malignant, are associated with the condition; however, carcinomas may develop in the liver, pancreas, breast, and so on.

Other conditions include congenital disorders with connective tissue and vascular abnormalities that affect the gut, such as Ehlers–Danlos syndrome and pseudoxanthoma elasticum (arterial GI bleeding), purpuric vasculitis (bleeding from GI lesions), and neurofibromatosis (intestinal neurofibromas).

Liver disease and the skin

Liver disease may affect the skin, hair, and nails to a variable degree ([Box 10.4](#)). Obstructive jaundice is often associated with itching which is thought to be due to the deposition of bile salts in the skin. Evidence of this is the fact that drugs that combine with bile salts such as cholestyramine improve pruritus in some patients. Jaundice is the physical manifestation of bile salts in the skin.

Box 10.4 Liver disease and the skin

Obstructive

Jaundice

Pruritus

Liver failure

Multiple spider naevi

Palmar erythema

White nails: hypoalbuminaemia

Porphyria cutanea tarda

Cirrhosis

Xanthomas (primary biliary cirrhosis)

Asteatosis

Liver failure is characterised by a number of skin signs, particularly vascular changes causing multiple spider naevi and palmar erythema due to diffuse telangiectasia. It is not unusual to

see spider naevi on the trunk in women but large numbers in men should raise suspicion of underlying hepatic disease.

Porphyria cutanea tarda (PCT) as a result of chronic liver disease produces bullae, scarring, and hyperpigmentation in sun-exposed areas of the skin ([Figure 10.15](#)). PCT usually occurs in men, with a genetic predisposition, who have liver damage as a result of an excessive intake of alcohol. There is an underlying deficiency of uroporphyrinogen decarboxylase in the haem synthesis pathway that leads to skin fragility and photosensitivity (face, dorsal hands), with blisters and erosions. A condition called *pseudoporphyria* mimics PCT clinically, but no porphyrins are found in urine/blood. Pseudoporphyria occurs in patients with chronic renal failure on haemodialysis, triggered by a number of medications (NSAIDs, diuretics, antibiotics, and oral contraceptives) and relating to underlying liver disease.

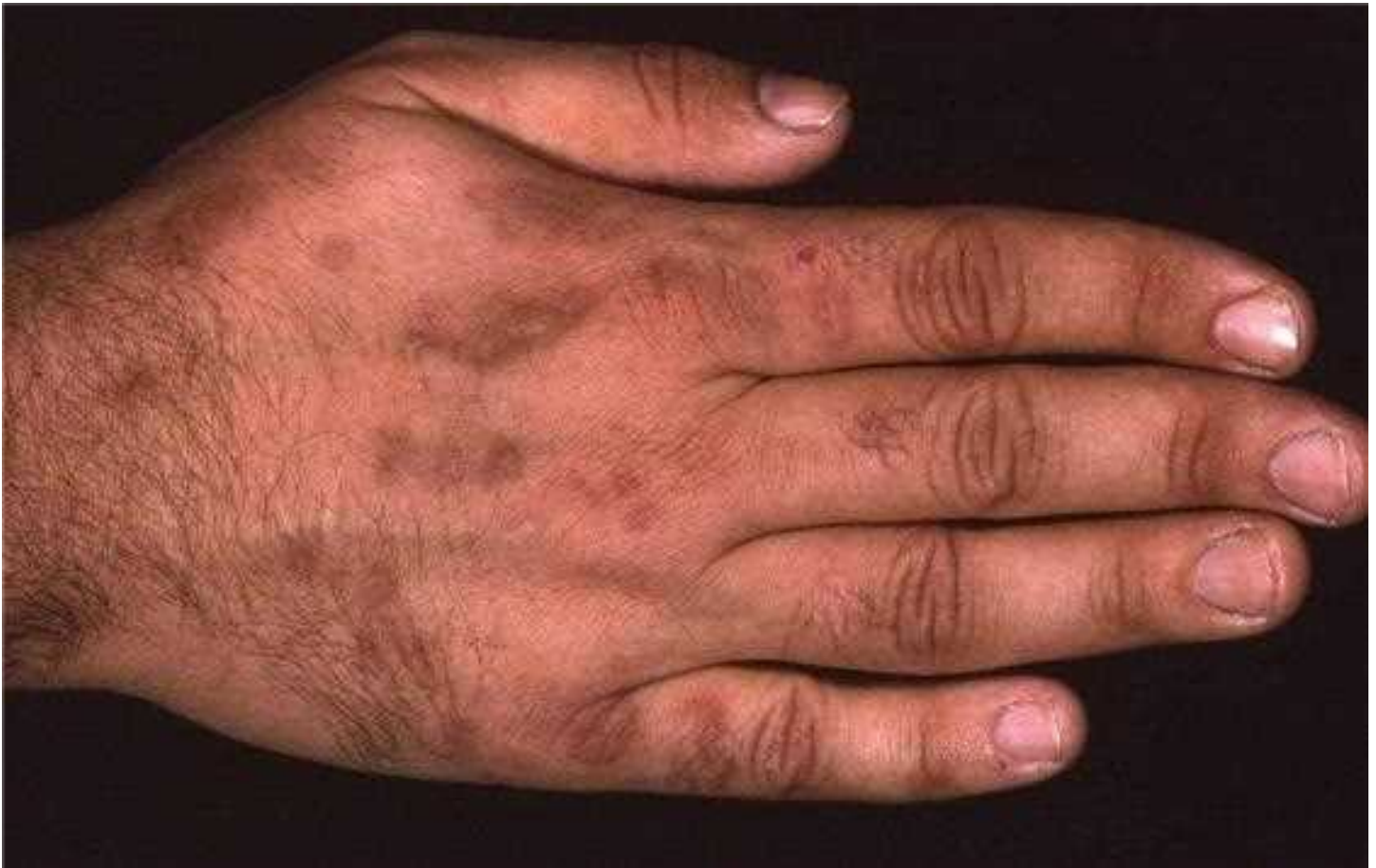

Figure 10.15 Porphyria cutanea tarda.

Porphyrias may also result from the accumulation of intermediate metabolites in the metabolic pathway of haem synthesis. There are several types. In hepatic porphyrias there is skin fragility leading to blisters from exposure to the sun or minor trauma. In erythropoietic and erythrohepatic photoporphyrias, there is intense photosensitivity including sensitivity to long-wavelength ultraviolet light that penetrates window glass.

Xanthomas are lipid-laden macrophages deposited in the skin and may be associated with liver disease such as primary biliary cirrhosis and Alagille syndrome ([Figure 10.16](#)) and associated with hyperlipidaemia (either primary or secondary to diabetes, the nephrotic

syndrome, or hypothyroidism). Diabetes may be associated with an eruptive type of xanthoma.

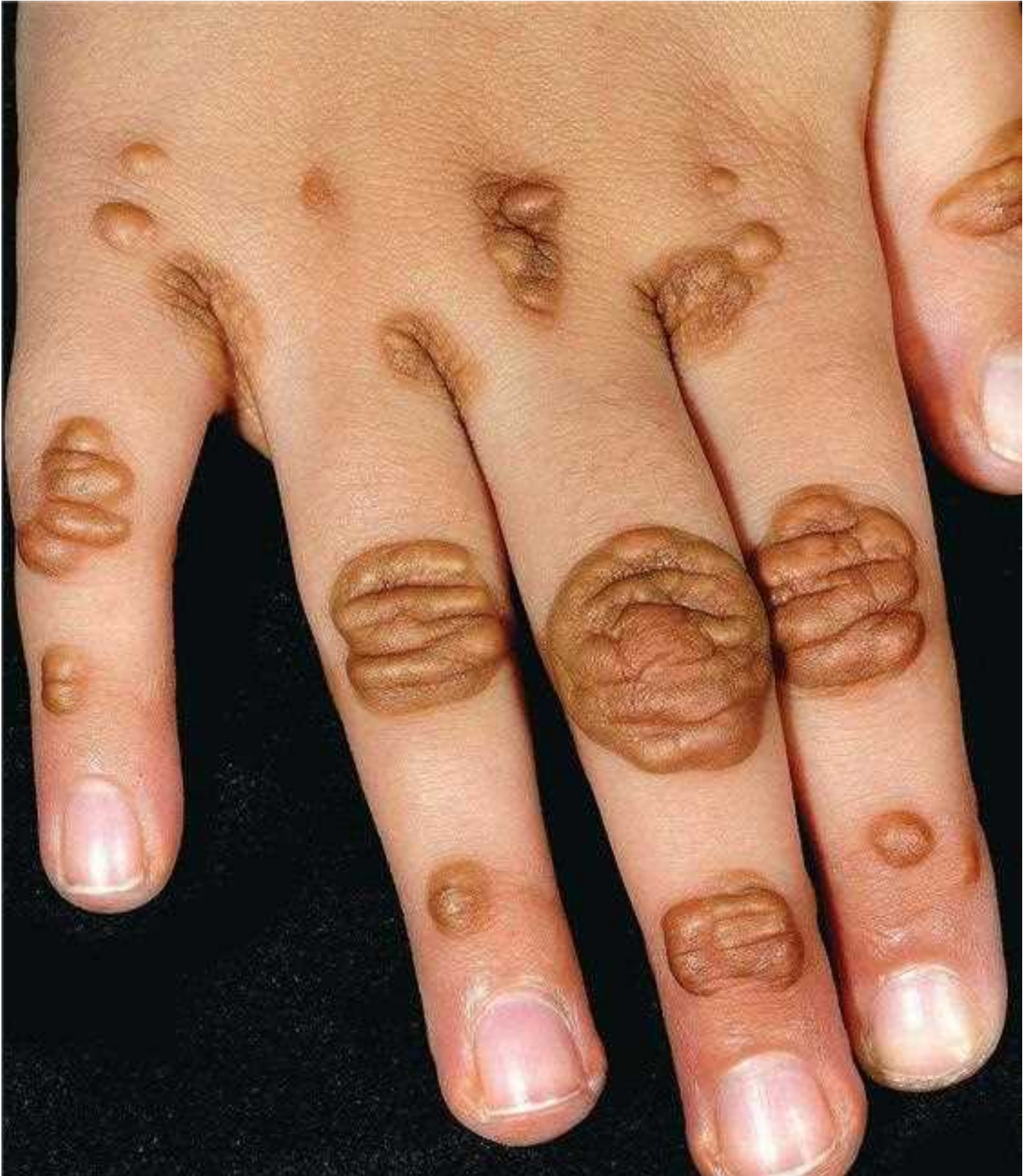


Figure 10.16 Xanthomas in Alagille syndrome.

Multiple spider naevi, with a central blood vessel and radiating branches, are most frequently

seen in women (especially during pregnancy) and children (see [Chapter 21](#)). If they occur in large numbers, however, they may indicate underlying liver or connective tissue disease. Palmar erythema and yellow nails may also be present in liver failure.

Pigmentation disorders

Hypopigmentation

Albinism is inherited through a recessive gene and may manifest as diminished or loss of pigment in the skin, hair, and eyes (see [Chapter 6](#)). Other genetic conditions with loss of skin pigment include piebaldism ([Figure 10.17](#)), phenylketonuria, and tuberous sclerosis.

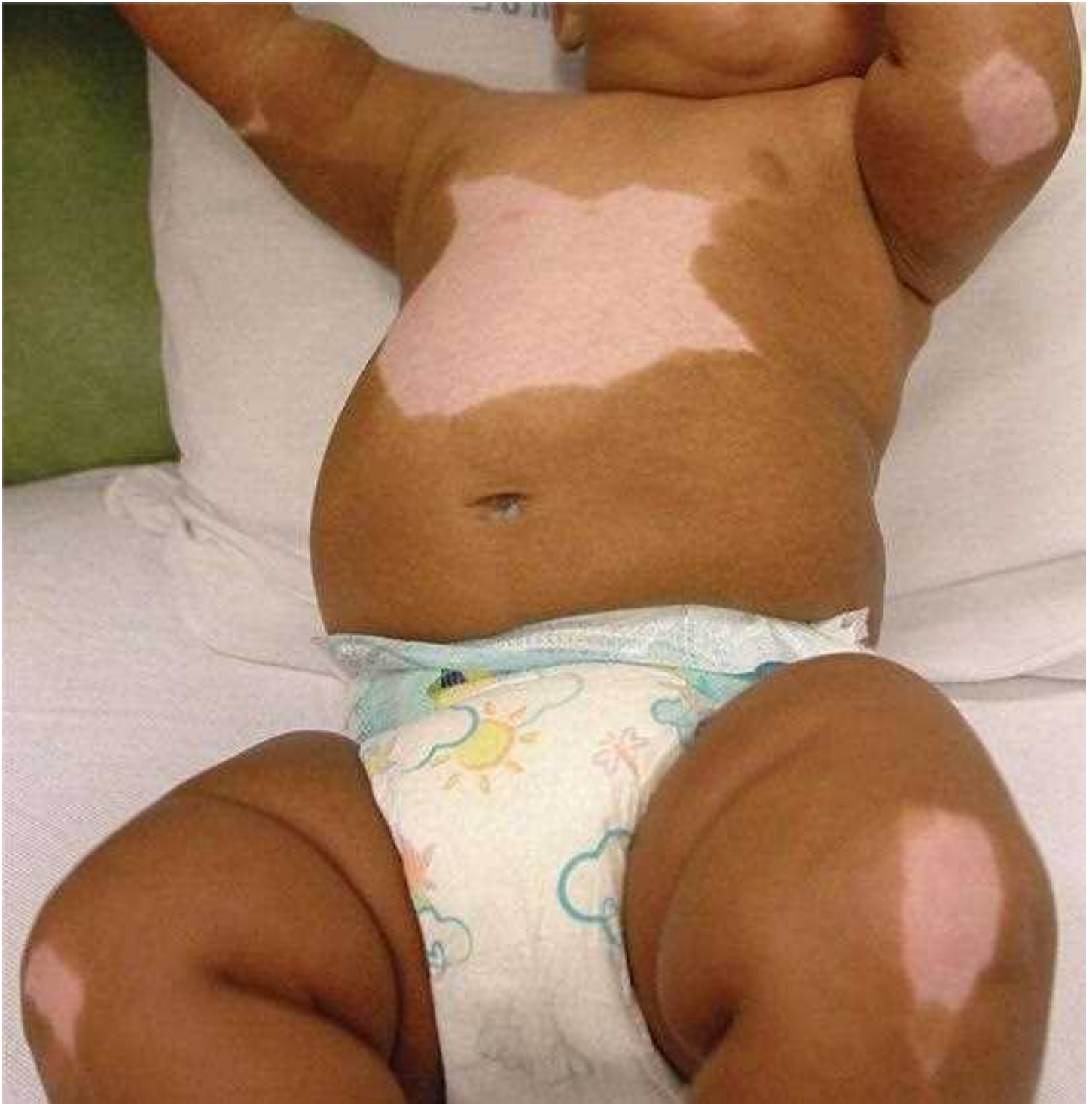

Figure 10.17 Piebaldism.

Localised depigmentation is most commonly seen in vitiligo; a family history of the condition is found in one-third of the patients. In the sharply demarcated, symmetrical macular lesions there is loss of melanocytes and melanin ([Figure 10.18](#)). There is an increased incidence of organ-specific antibodies and their associated diseases ([Box 10.5](#)).

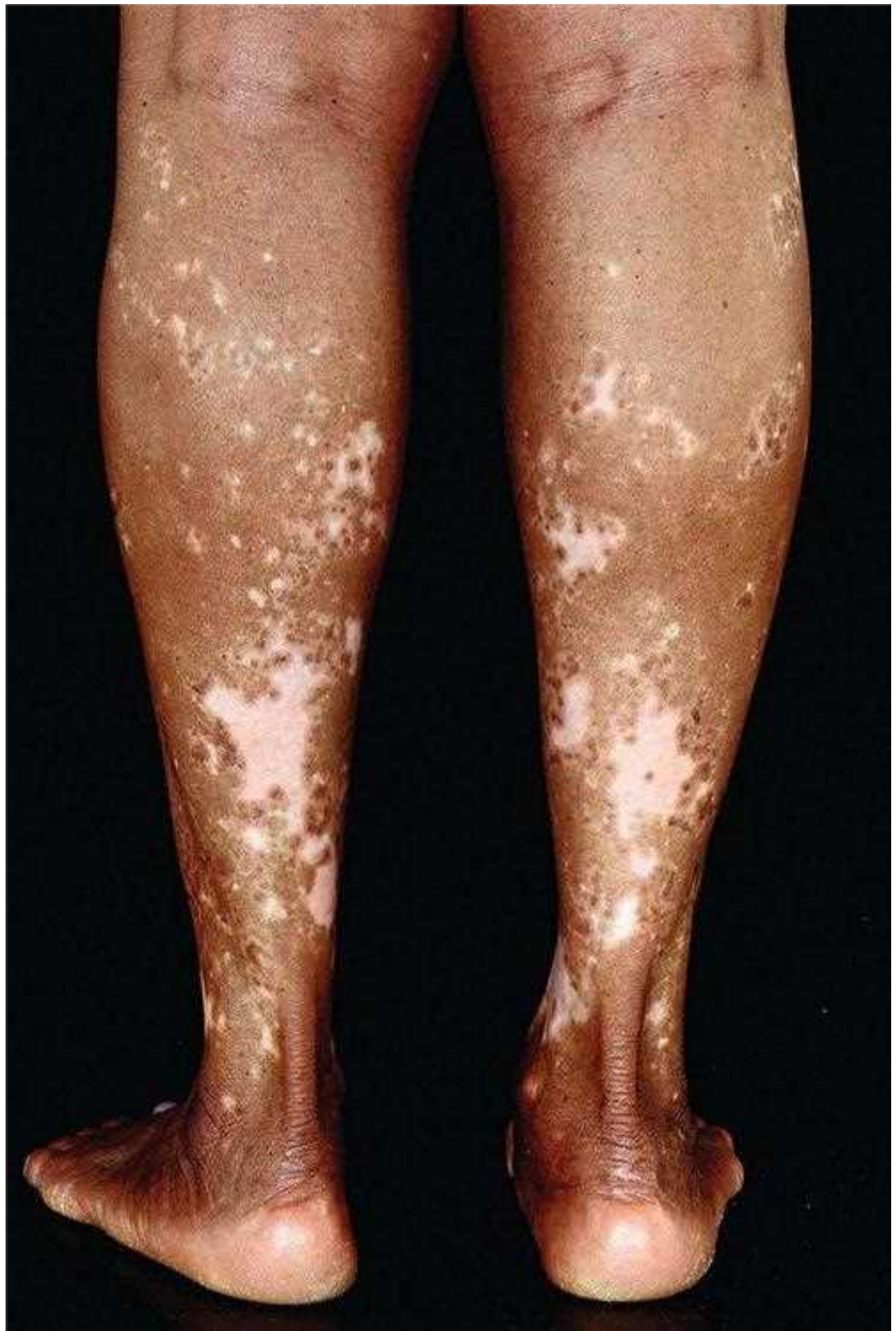

Figure 10.18 Vitiligo being treated with phototherapy (TL-01).

Box 10.5 Autoimmune associations with vitiligo

- Thyroid disease
- Myasthenia gravis
- Pernicious anaemia
- Alopecia areata
- Hypoparathyroidism
- Halo naevus
- Addison's disease
- Morphea and lichen sclerosus
- Diabetes

Other causes of hypopigmented macules include post-inflammatory conditions such as psoriasis, eczema, lichen planus, and lupus erythematosus; infections, for example, pityriasis versicolor and leprosy; chemicals, such as hydroquinones, hydroxychloroquine and arsenicals, reactions to pigmented naevi, seen in halo naevi (when the mole develops a pale ring around it) and genetic diseases, such as tuberous sclerosis ('ash leaf' macules).

Hyperpigmentation

There is wide variation in the pattern of normal pigmentation as a result of hereditary factors and exposure to the sun. Darkening of the skin may be due to an increase in the normal pigment melanin or to the deposition of bile salts from liver disease, iron salts (haemochromatosis) ([Figure 10.19](#)), drugs, or metallic salts from ingestion. In agyria, ingested silver salts are deposited in the skin. Medications such as chlorpromazine, other phenothiazines, and minocycline may cause an increased pigmentation in areas exposed to the sun. Phenytoin can cause local hyperpigmentation of the face and neck. AZT can cause cutaneous and nail hyperpigmentation.

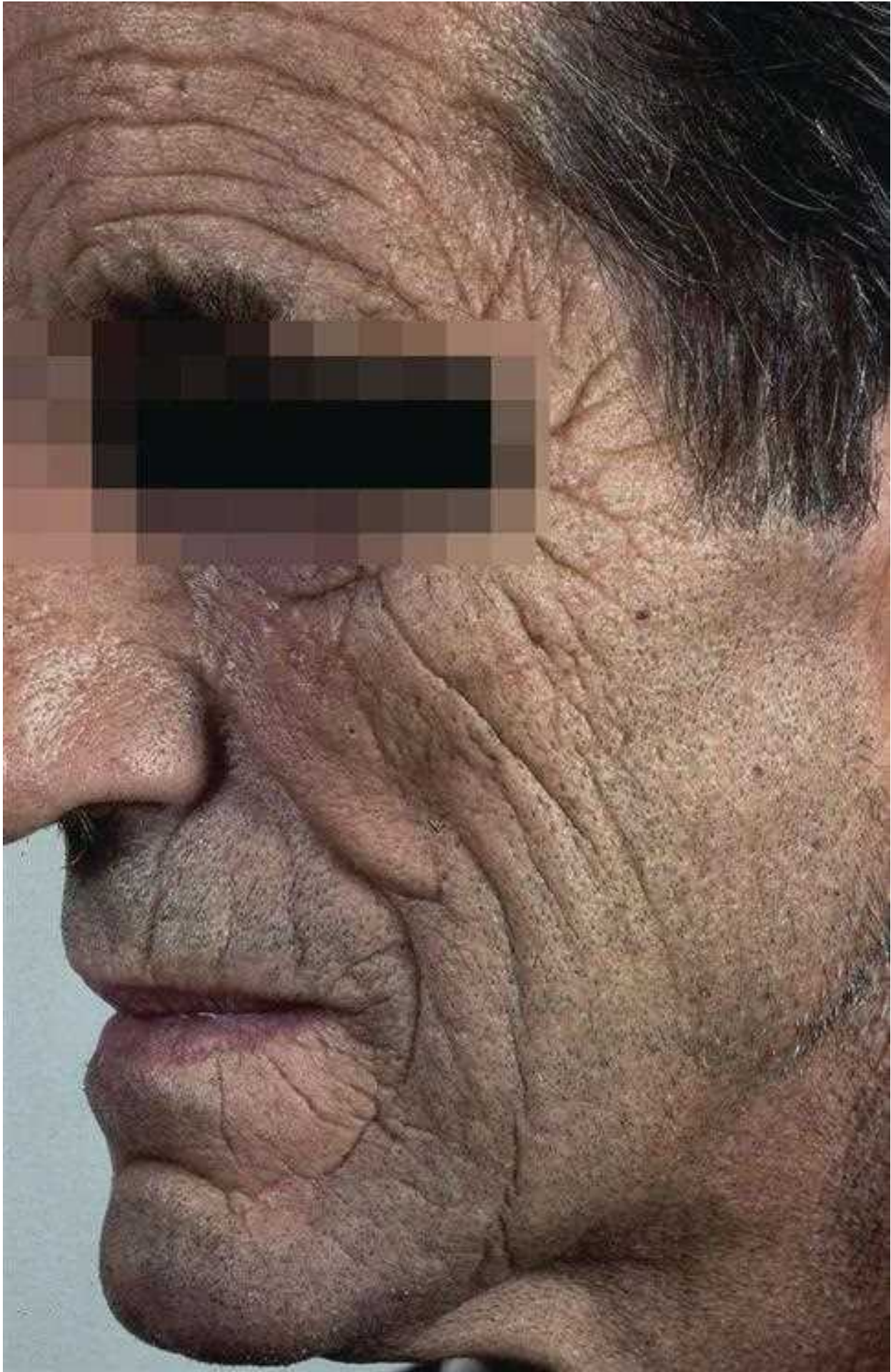


Figure 10.19 Haemochromatosis.

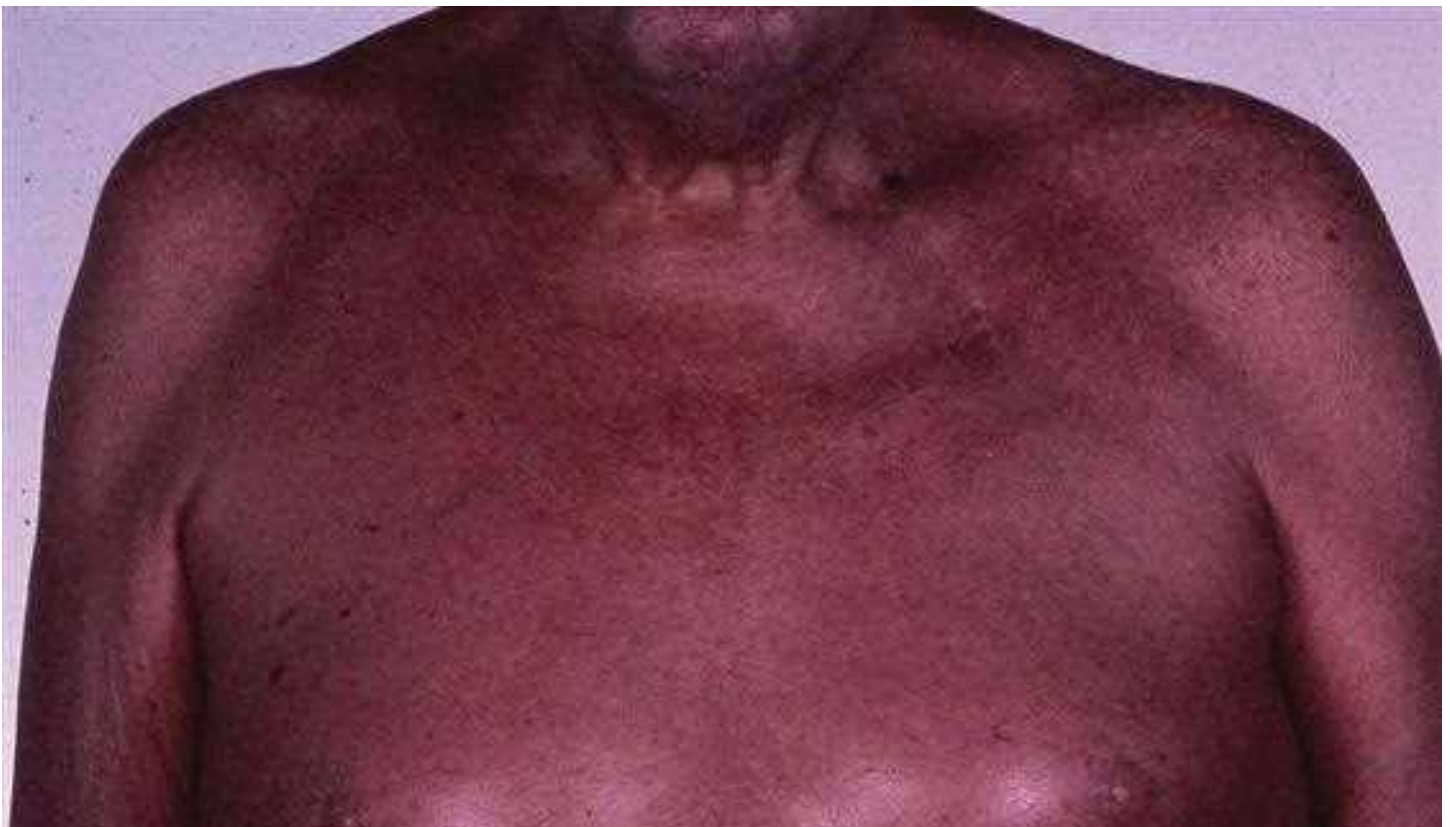AN is characterised by darkening and thickening of the skin of the axillae, neck, nipples, and umbilicus (see above). Increased skin pigmentation may also be observed in patients with acromegaly who have an underlying pituitary tumour.

Post-inflammatory pigmentation is common, often after acute eczema, fixed drug eruptions, and lichen planus. Areas of lichenification from rubbing the skin are usually darkened. In malabsorption syndromes, pellagra, and scurvy, there is commonly increased skin pigmentation.

Skin manifestations of underlying malignancy

Underlying systemic malignancies may lead to characteristic patterns in the skin such as those seen in dermatomyositis or may present as a nodule of secondary deposits (metastases) ([Boxes 10.6](#) and [10.7](#)). Lymphomas can arise in or invade the skin. Pruritus may be associated with Hodgkin's disease.

Mycosis fungoides is a T-cell lymphoma of cutaneous origin. Initially, well-demarcated erythematous plaques usually develop over the trunk area, which may be mildly pruritic. In some cases, there is a gradual progression to infiltrated lesions, nodules and ulceration and occasionally erythroderma in Sézary syndrome ([Figure 10.20](#)) where there are atypical circulating Sézary cells. In others, the tumour may occur de novo or be preceded by generalised erythema. Primary cutaneous B-cell lymphoma can also rarely occur ([Figure 10.21](#)).



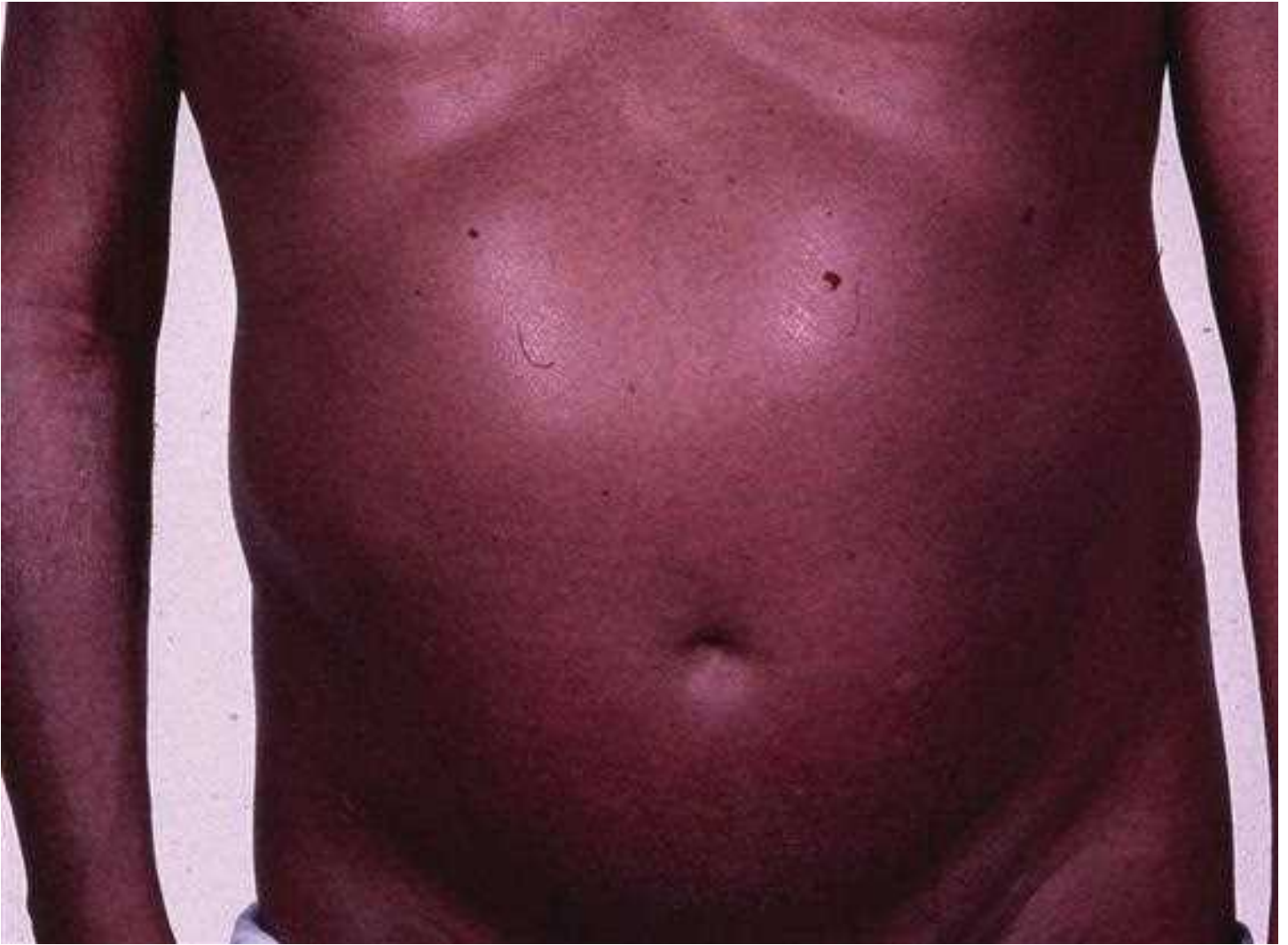

Figure 10.20 Sézary syndrome (erythroderma with abnormal circulating Sézary cells).

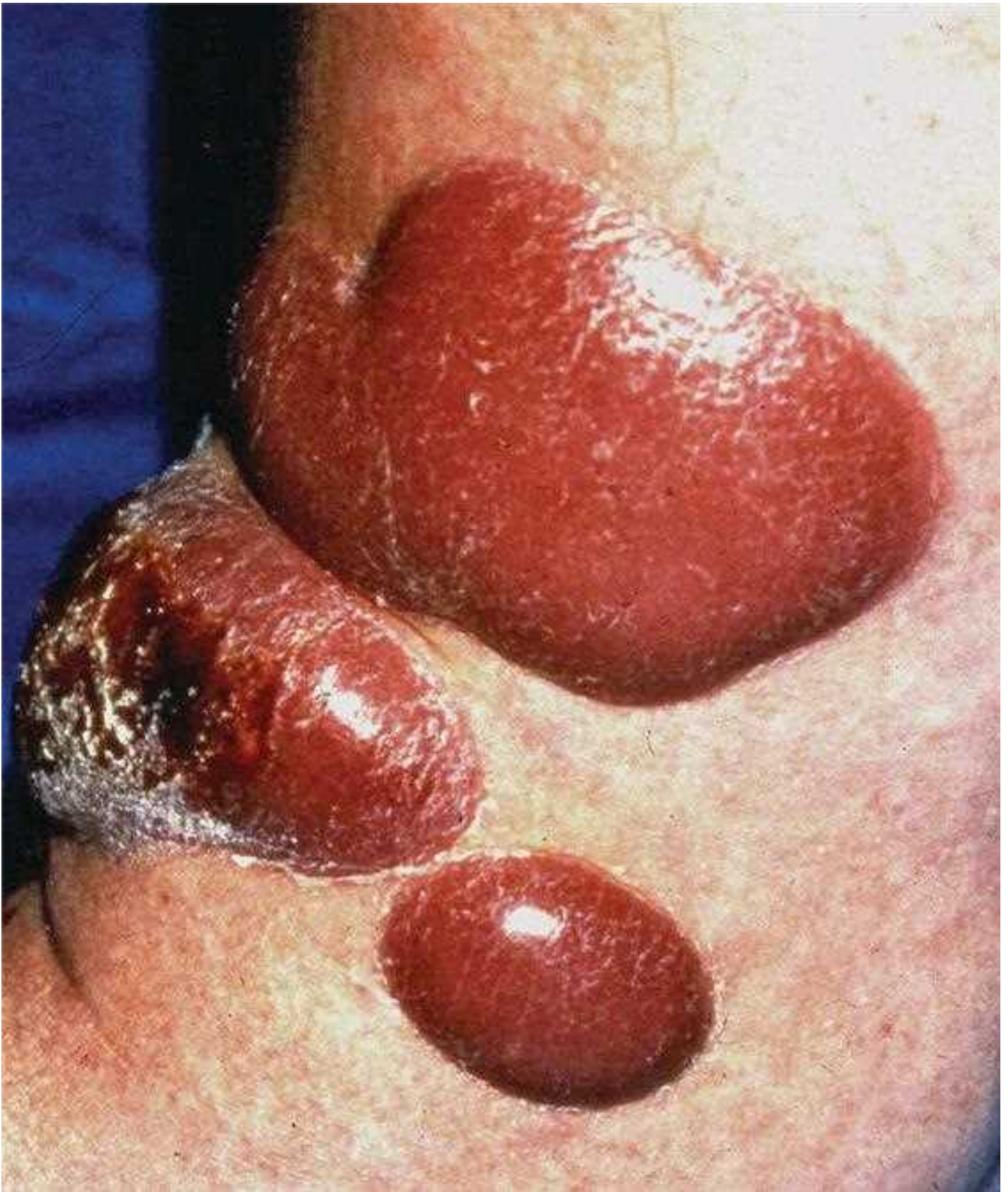

Figure 10.21 Cutaneous B-cell lymphoma.

Box 10.6 Skin markers of internal malignancy

- Acanthosis nigricans can be associated with gastric adenocarcinoma.
- Figurate erythemas can be associated with bronchial/oesophageal/breast carcinoma.
- Pruritus can be associated with lymphoma.
- Dermatomyositis can be associated with lung/breast/ovarian/testicular carcinomas.
- Acquired ichthyosis can be associated with Hodgkin's disease, sarcoma, lymphoma.

Box 10.7 Non-specific skin changes associated with malignant disease

- Secondary deposits
- Secondary hormonal effects
- Acne (adrenal tumours)
- Flushing (carcinoid)
- Pigmentation (pituitary tumours)
- Generalised pruritus (particularly lymphoma)
- Figurate erythema
- Superficial thrombophlebitis

Parapsoriasis is a term used for well-defined erythematous scaly patches and plaques that slightly resemble psoriasis often in a 'digitate pattern' on the lateral borders of the trunk in middle/old age. Some cases undoubtedly develop into mycosis fungoides and a biopsy specimen should be taken from any fixed plaques that do not clear with topical steroids.

Poikiloderma, in which there is telangiectasia, reticulate pigmentation ([Figure 10.22](#)), atrophy and loss of pigment, may precede mycosis fungoides, but it is also seen after radiotherapy and in association with connective tissue diseases.

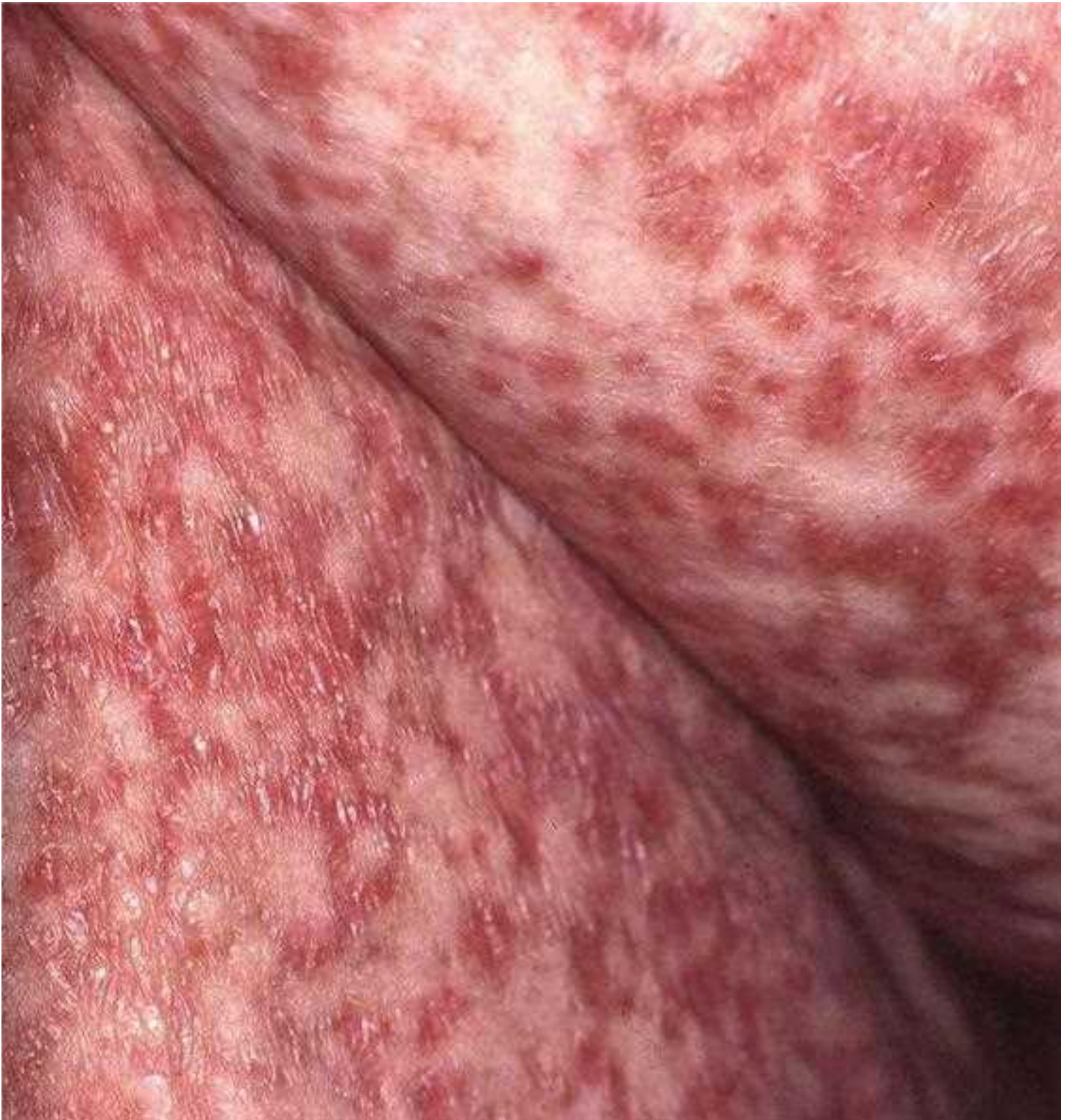

Figure 10.22 Poikiloderma.

Pregnancy and the skin

Pregnancy may be associated with pruritus, in which the skin appears normal in 15–20% of women (prurigo gestationis). It is generally more severe in the first trimester.

Polymorphous eruption of pregnancy (PEP) (previously named pruritic urticarial papules

and plaques of pregnancy, PUPPP) ([Figure 10.23](#)) is a pruritic erythematous rash that usually starts in the striae of the abdomen during the third trimester and can become widespread. The condition does not affect the baby. It usually resolves post partum and rarely recurs in subsequent pregnancies with the same partner. Topical (and occasionally systemic) steroids usually provide symptomatic relief.

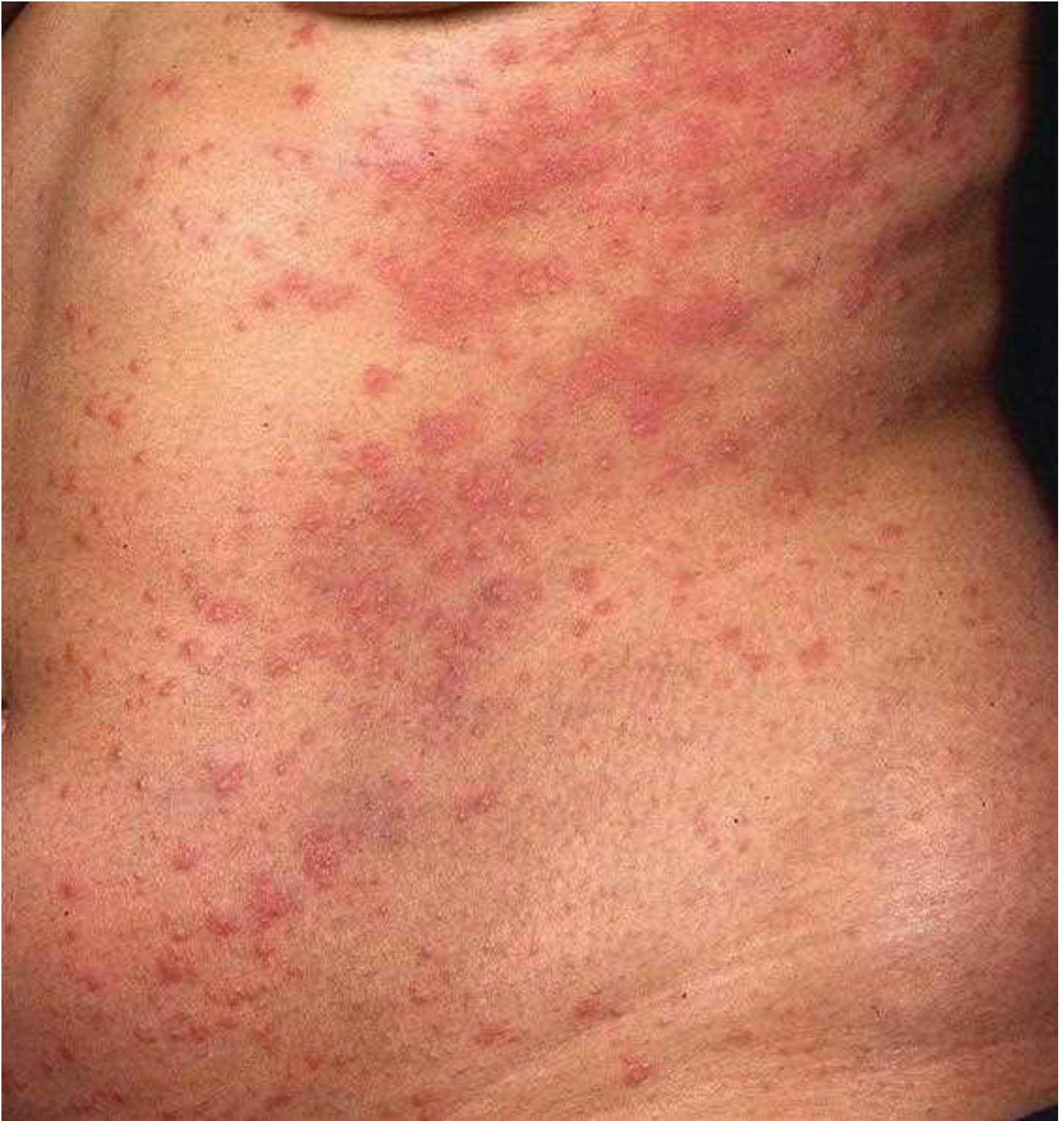

Figure 10.23 Polymorphous eruption of pregnancy (PEP).

Pemphigoid gestationis (PG) is a rare disorder that may initially resemble PEP but develops

pemphigoid-like vesicles, spreading over the abdomen and thighs ([Figure 10.24](#)). PG is an autoimmune disorder, in which cross-reactivity between placental tissues and the skin is thought to be important. It is strongly associated with HLA-DR3/4 and most patients develop anti-HLA antibodies. There is a greater prevalence of premature and small-for-dates babies and occasional mortality of the foetus.

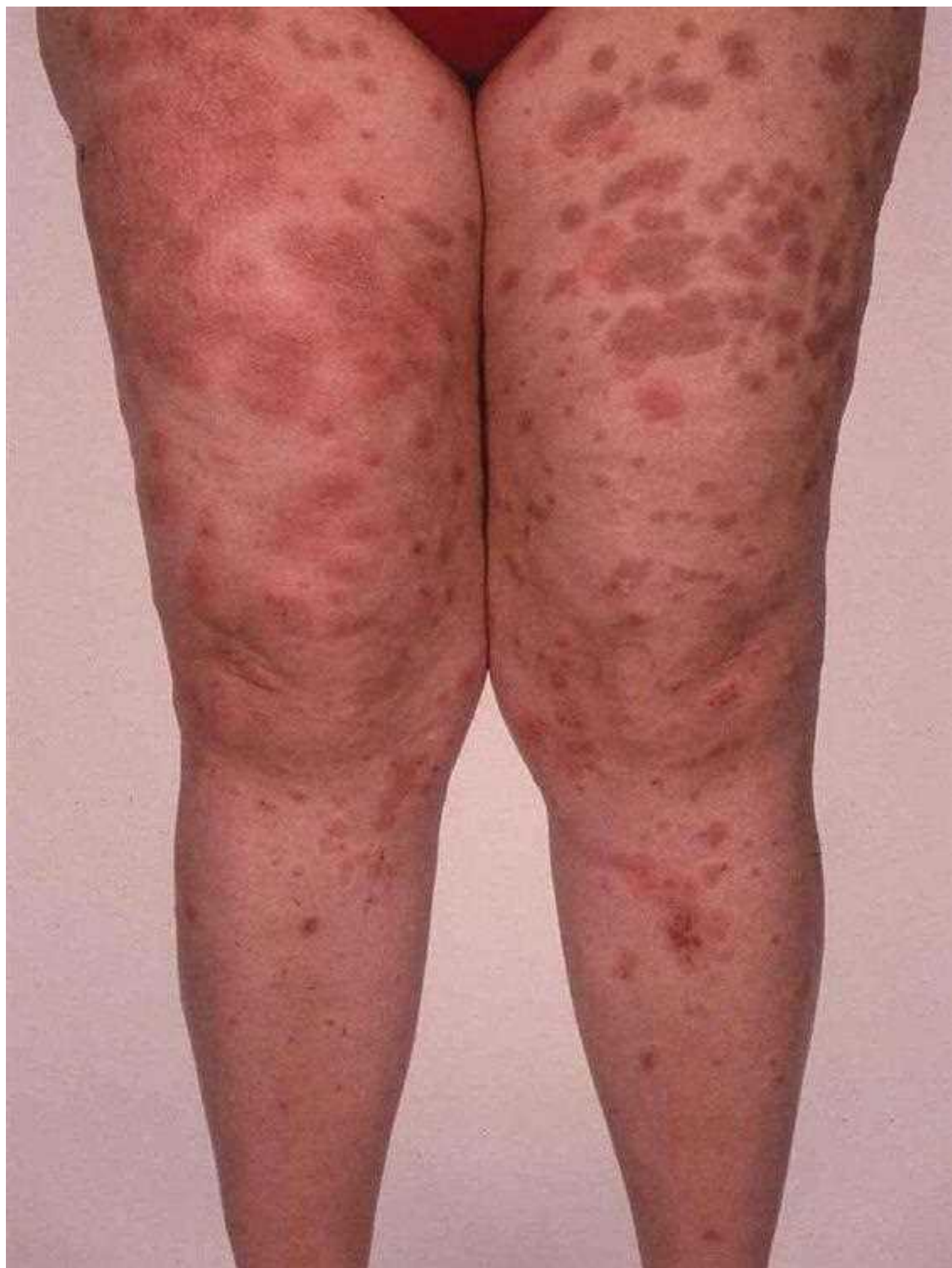

Figure 10.24 Pemphigoid gestationis.

Genetics and skin disease

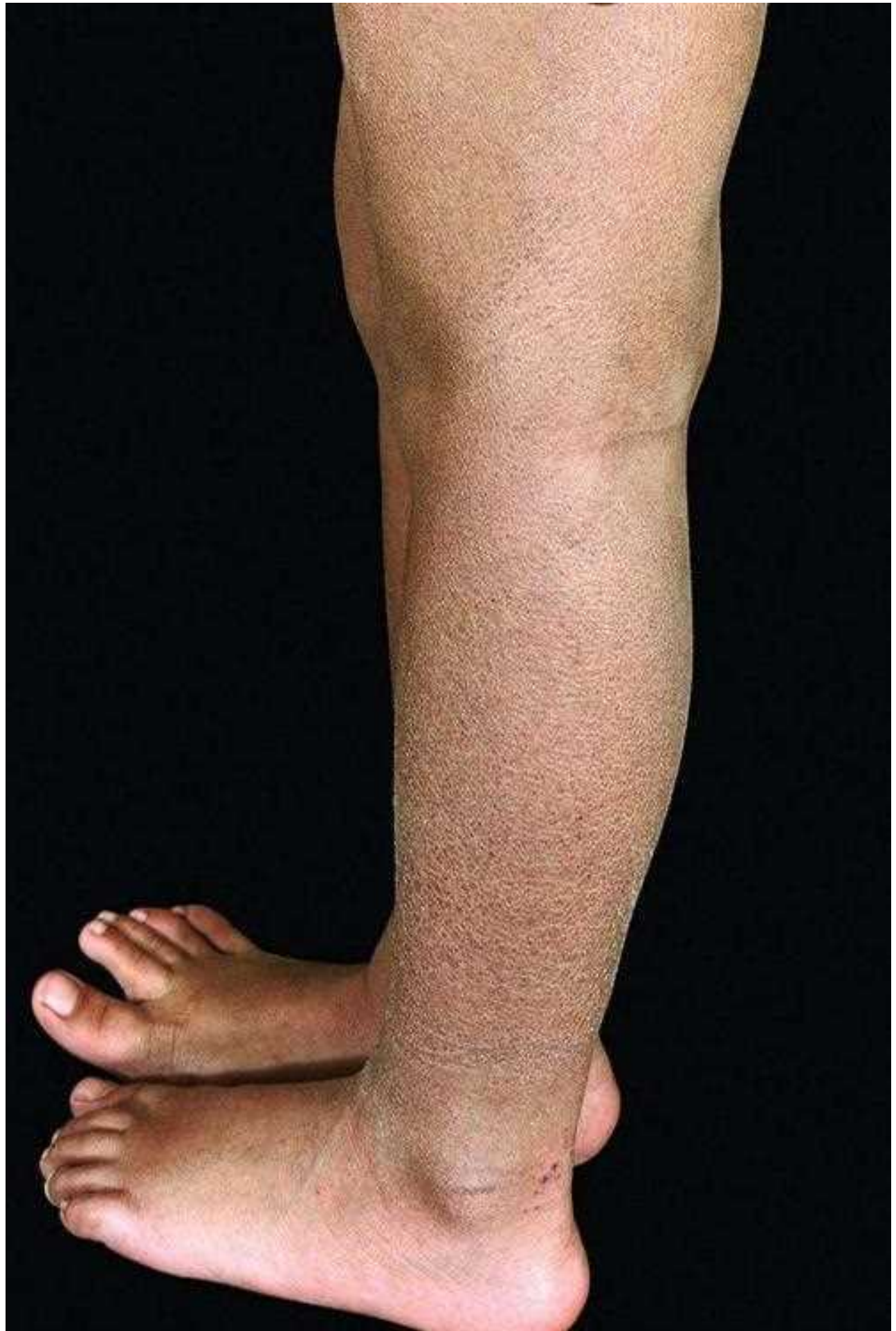An international project to sequence the human genome (3 billion base pairs) was completed in 2003. This human genome database will allow genetic researchers the opportunity to examine closely the specific genes that are of interest in relation to specific diseases. For example, those working in the field of genodermatoses can look at the structure, function, any detrimental mutations, interaction with other genes and other diseases mapped to that gene's location when undertaking research on a particular cutaneous disorder. Skin diseases that were originally classified according to clinical manifestations are now being more logically classified according to molecular defects at a genetic level ([Table 10.2](#)). Currently, around 500 single inheritance gene disorders with a significant cutaneous component have been identified at the molecular level. Although these disorders tend to be rare they can provide valuable information into the function of the particular protein or adhesion molecule, and so on, that is affected by the gene defect. In addition, this has led to a deeper understanding of inheritance patterns, more accurate diagnoses for neonates, where applicable prenatal diagnosis, and the hope for future treatments in the form of gene therapy.

Table 10.2 Abnormality underlying some inherited skin disorders.

| Skin disorder | Abnormality |
|-------------------------------------|---------------------------------------|
| Ehlers–Danlos syndrome | Collagen and the extracellular matrix |
| Dystrophic epidermolysis bullosa | Type VII collagen |
| Pseudoxanthoma elasticum | Elastic tissue |
| Xeroderma pigmentosum | DNA repair |
| Simple epidermolysis bullosa | Keratins 5 and 14 |
| Epidermolytic hyperkeratosis | Keratins 1 and 10 |
| Palmo-plantar keratoderma | Keratins 9 and 16 |
| Junctional epidermolysis bullosa | Laminins |
| X-linked recessive ichthyosis | Steroid sulfatase |
| Ichthyosis vulgaris | Filaggrin in stratum corneum |
| Darier's disease | Epidermal cell adhesion |
| Albinism (tyrosinase negative type) | Tyrosinase |

As a general rule, common cutaneous disorders that run in families (familial), such as psoriasis, atopic eczema, and acne, have more complex patterns of inheritance and are therefore more difficult to define genetically. These disorders are referred to as *multifactorial* as several genes are involved in the expression of the disease in addition to environmental modification (aeroallergens, food allergy, medication, infections).

Recent advances include the identification of two loss-of-function filaggrin gene defects that lead to dysregulation of keratohylin synthesis manifesting as *ichthyosis vulgaris (IV)* (which affects 1 in 250 individuals) ([Figure 10.25](#)), an inherited condition that affects skin barrier function. Filaggrin is an essential structure barrier function molecule in the stratum corneum. Abnormalities of filaggrin lead to increased levels of transepidermal water loss. Many patients with IV also suffer from AD, which leads to the discovery of similar filaggrin mutations in some patients with AD.



[Figure 10.25](#) Ichthyosis vulgaris.

Gene therapy is an exciting future prospect in the management of gene defect associated disease. The accessibility of the skin as a therapeutic target is being exploited in developing novel treatments for the delivery of 'corrected genes' into skin tissues and beyond. Inherited blistering disorders such as epidermolysis bullosa are at the forefront of experimental gene therapy such as a child with junctional EB being successfully treated with a whole-body graft of genetically modified stem cells. The technique involves taking some of the patient unaffected skin, culturing the epidermal cells (including some stem cells), and these are then infected with a retrovirus bearing healthy copies of the affected gene (in this case *LAMB3*). The 50–150 cm² sheets of genetically modified epidermal cells are grown in the lab and then applied to the individuals diseased skin areas. The success in this particular case meant the child could return to full-time education and playing football.

Single gene disorders

These tend to be rare disorders that are inherited in a Mendelian pattern: autosomal recessive, autosomal dominant, and X-linked recessive/dominant. Most of these disorders result from a single gene mutation that affects its protein product, which may in turn be increased, lost, or modified. Not all these genetic disorders are evident at birth: many may present in later life such as neurofibromatosis type 2. The 'two-hit' principle is thought to be responsible for later presentations of genetic disorders when patients possess one mutant gene, but its counterpart is normal until a second event occurs later in life. When the second gene mutates, the disease is expressed.

Single gene mutations may affect particular molecular structures in the skin such as the hemidesmosome (BP180), leading to one of the inherited types of junctional epidermolysis bullosa. However, the same BP180 protein may be targeted by acquired disorders such as bullous pemphigoid. Clinically, both conditions are characterised by skin fragility due to subepidermal splits.

Mosaicism refers to two or more cell populations that are genotypically different from each other but occur in the same individual. Cutaneous mosaicism may result from a mutation during development that is restricted to a few particular skin cells. This frequently results in linear abnormalities in the skin, usually present at birth. The mosaic defects often follow Blaschko's lines ([Figure 10.26](#)), a bizarre pattern of lines and whorls which are thought to represent the developmental growth patterns in the skin ([Figure 10.27](#)). The genetic abnormalities found in localised mosaic cells may be identical to those found in generalised genodermatoses. For example, the same abnormalities in the genes controlling the production of keratins 1 and 10 can be responsible both for a generalised epidermolytic hyperkeratosis and for localised warty linear naevi.

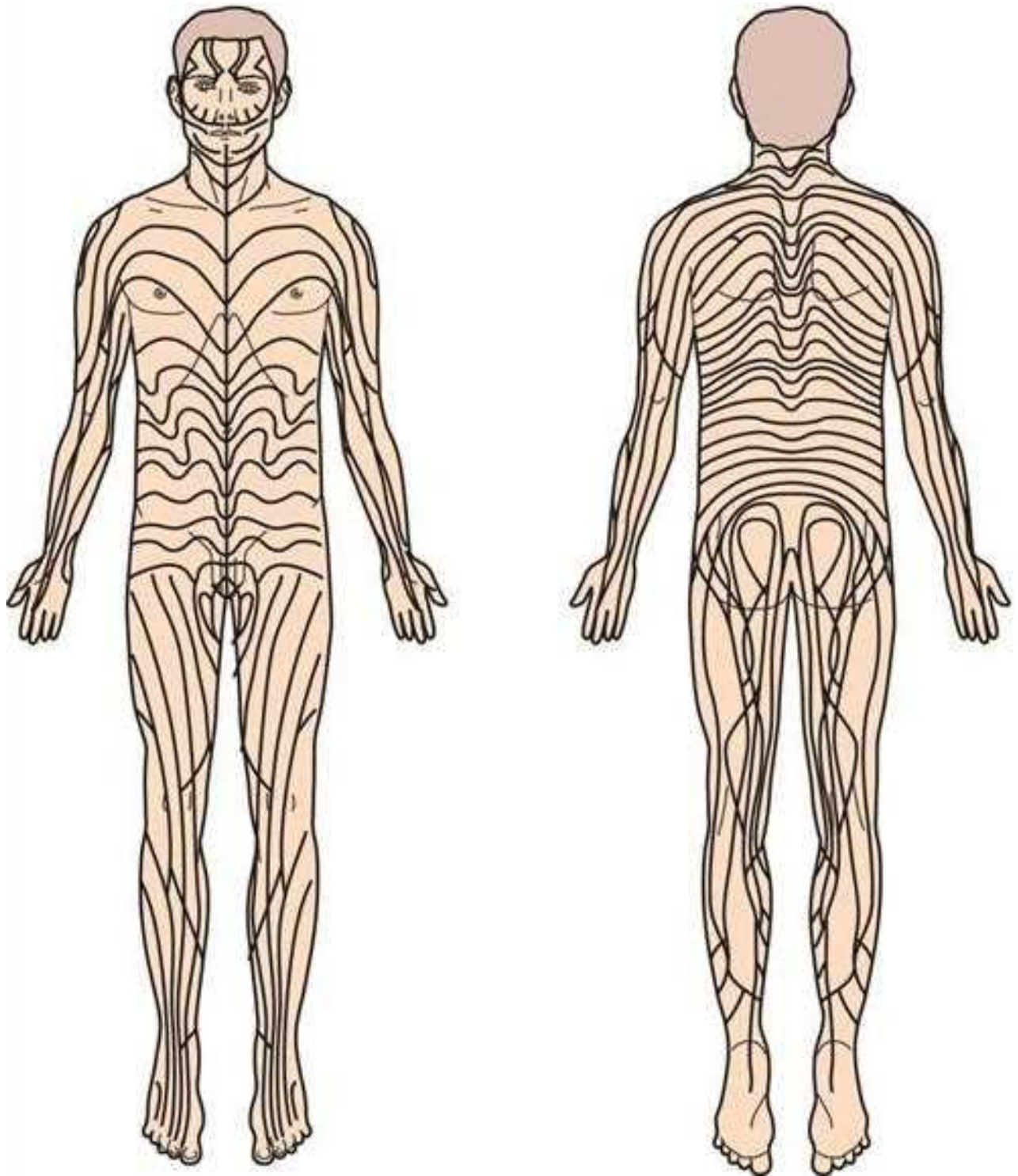


Figure 10.26 Blaschko's lines.

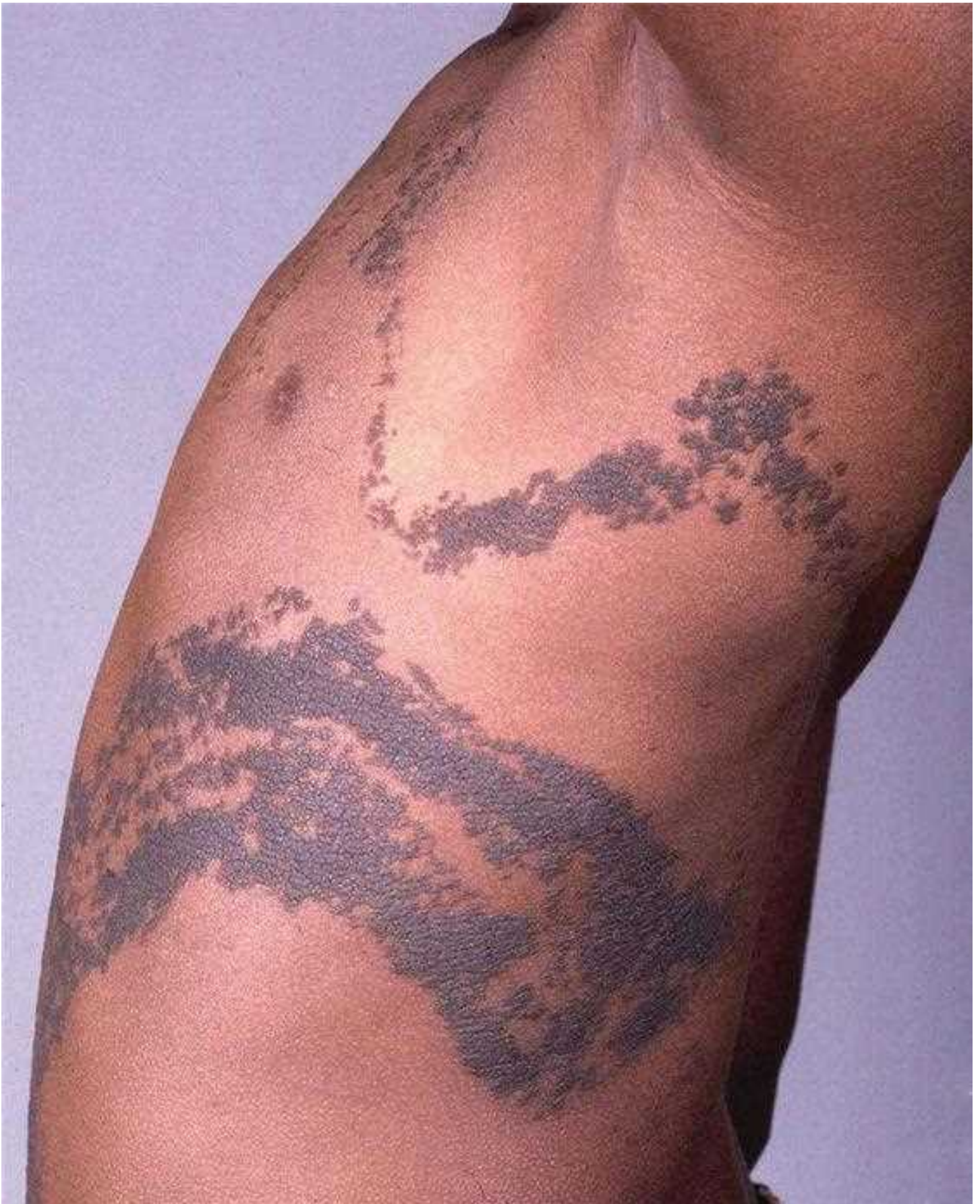

Figure 10.27 Epidermal naevus following Blaschko's lines.

Further reading

English, J.C., Huen, A.C., Patton, T.J., and Grandinetti, L.M. (2015). *Skin and Systemic Disease a Clinician's Guide*. CRC Press.

Sarzi-Puttini, P., Doria, A., Girolomoni, G., and Kuhn, A. (2006). *The Skin in Systemic Autoimmune Disease*. Amsterdam: Elsevier Science.

CHAPTER 11

Leg Ulcers

Rachael Morris-Jones

Guy's and St Thomas' NHS Foundation Trust, London, UK

OVERVIEW

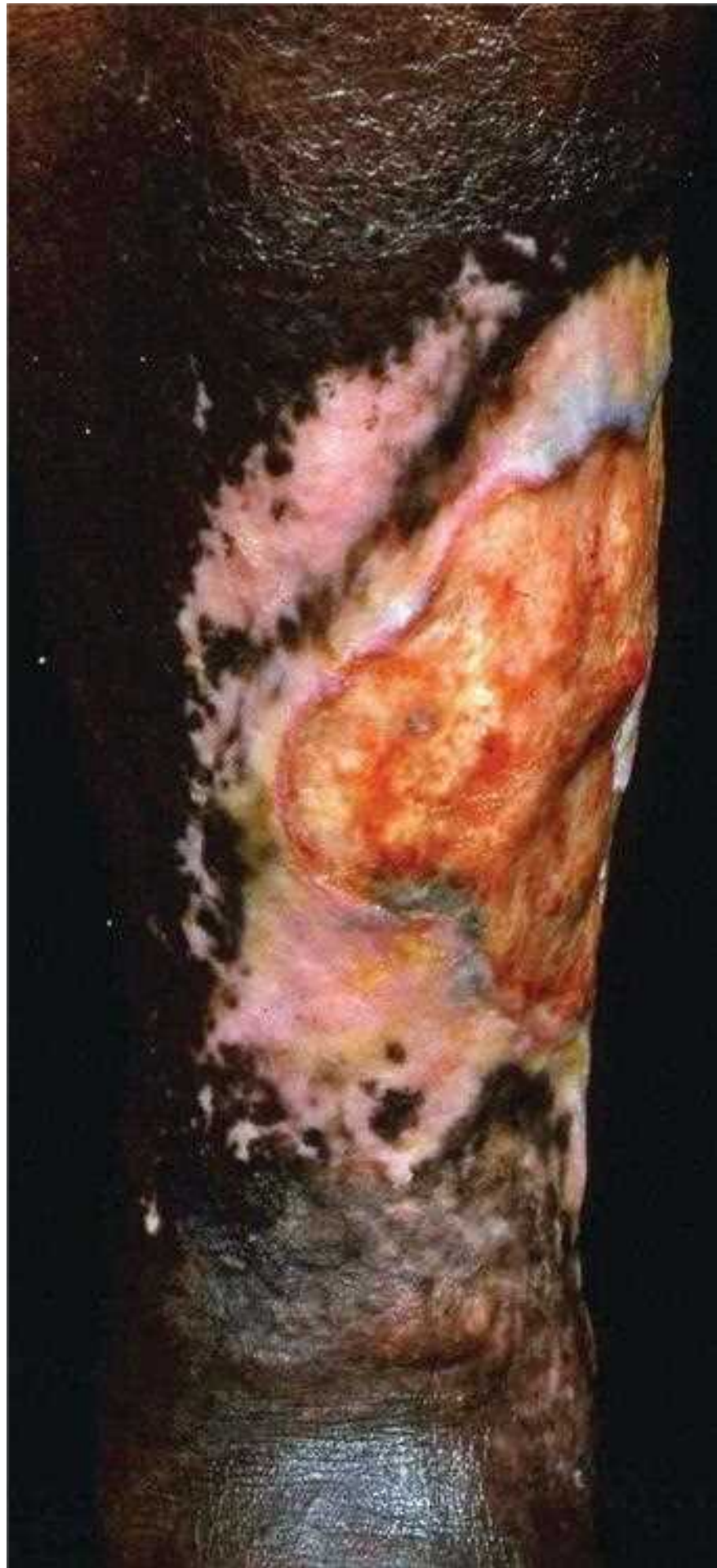- The underlying cause of most ulcers is inadequate blood perfusion of the skin.
- The majority of leg ulcers arise due to oedema and raised pressure in the intercellular space, preventing capillary perfusion and causing back pressure in the venules.
- Risk factors for venous ulceration include increasing age, immobility, obesity, lower leg trauma, oedema, varicose veins, and thrombosis.
- Risk factors for arterial ulcers include hypertension, atherosclerosis, peripheral vascular disease, polycythaemia, cryoglobulinaemia, vasculitis, and connective tissue disease.
- Clinical features of venous ulcers: most commonly over medial malleolus; pitting oedema, dilated tortuous veins; ulcers have a well-defined, sloping edge and central slough.
- Clinical features of arterial ulcers: most commonly over shins, dorsal foot; painful, pale hairless legs, poor peripheral pulses, ulcers sharply defined with 'punched-out' edge.
- Management: correction of underlying cause if possible, clean ulcers, application of non-adherent dressings and appropriate compression bandages.

Introduction

The prevalence of leg ulceration is estimated to be between 0.3% and 1.0% of the general population, rising to 2% of those over the age of 80 years; however, with rising rates of obesity the incidence is expected to rise. Leg ulcers cause significant morbidity for those affected and the cost to the National Health Service in the UK is estimated to be £600 million per annum. The estimated total cost of treating all wounds in the NHS per year is £4.5 billion. Many patients have recurrent ulceration requiring repeated courses of bandages and dressings; 80% of patients are treated in the community. If the underlying cause of ulceration cannot be relieved by an operation or medical intervention, then the key worker will often be the specialist nurse who has considerable experience in assessing and facilitating the healing of difficult chronic ulcers.

Assessment of any ulcer should include consideration of the following parameters: site, size, edge, base, surrounding skin, leg shape, duration, symptoms, underlying systemic/cutaneous diseases, peripheral pulses/sensation, medication, and current and past ulcer treatments. Investigations may include ankle: brachial pressure indices (ABPI), venous and/or arterial duplex scanning, microbiology swabs, ulcer biopsy (usually through the edge), and patch testing.

A basic understanding of the underlying principles of ulceration is essential in reaching a clinical diagnosis and appreciating the different approaches to management. Most (95%) of ulcers are 'venous' (stasis) in nature ([Figure 11.1](#)) and therefore these are considered first in some detail.



[Figure 11.1](#) Venous leg ulcer.

Venous ulcers

Pathology

The skin

Ulcers arise because the skin (epidermis and dermis) dies from inadequate provision of nutrients and oxygen. This occurs as a consequence of (i) oedema in the subcutaneous tissues with poor lymphatic and capillary drainage and (ii) the extravascular accumulation of fibrinous material that has leaked from the blood vessels. The result is a rigid cuff around the capillaries, which prevents diffusion of oxygen and nutrients through the vessel wall into the surrounding tissues with consequent fibrosis.

The blood vessels

Arterial perfusion of the leg is usually normal or increased, but stasis occurs in the venules. The lack of venous drainage is a consequence of incompetent valves between the superficial veins and the deeper large veins on which the calf muscle 'pump' acts. In the normal leg, there is a superficial low-pressure venous system and deep high-pressure veins ([Figures 11.2](#) and [11.3](#)). If the blood flow from superficial to deep veins is reversed, then the pressure in the superficial veins may increase to a level that prevents venous drainage ([Figure 11.4](#)). The resulting back pressure leads to varicose veins with stasis and oedema; consequently, there is diminished blood flow to the skin, causing ulceration. Chronic venous insufficiency and the resulting venous hypertension cause venous ulcers.

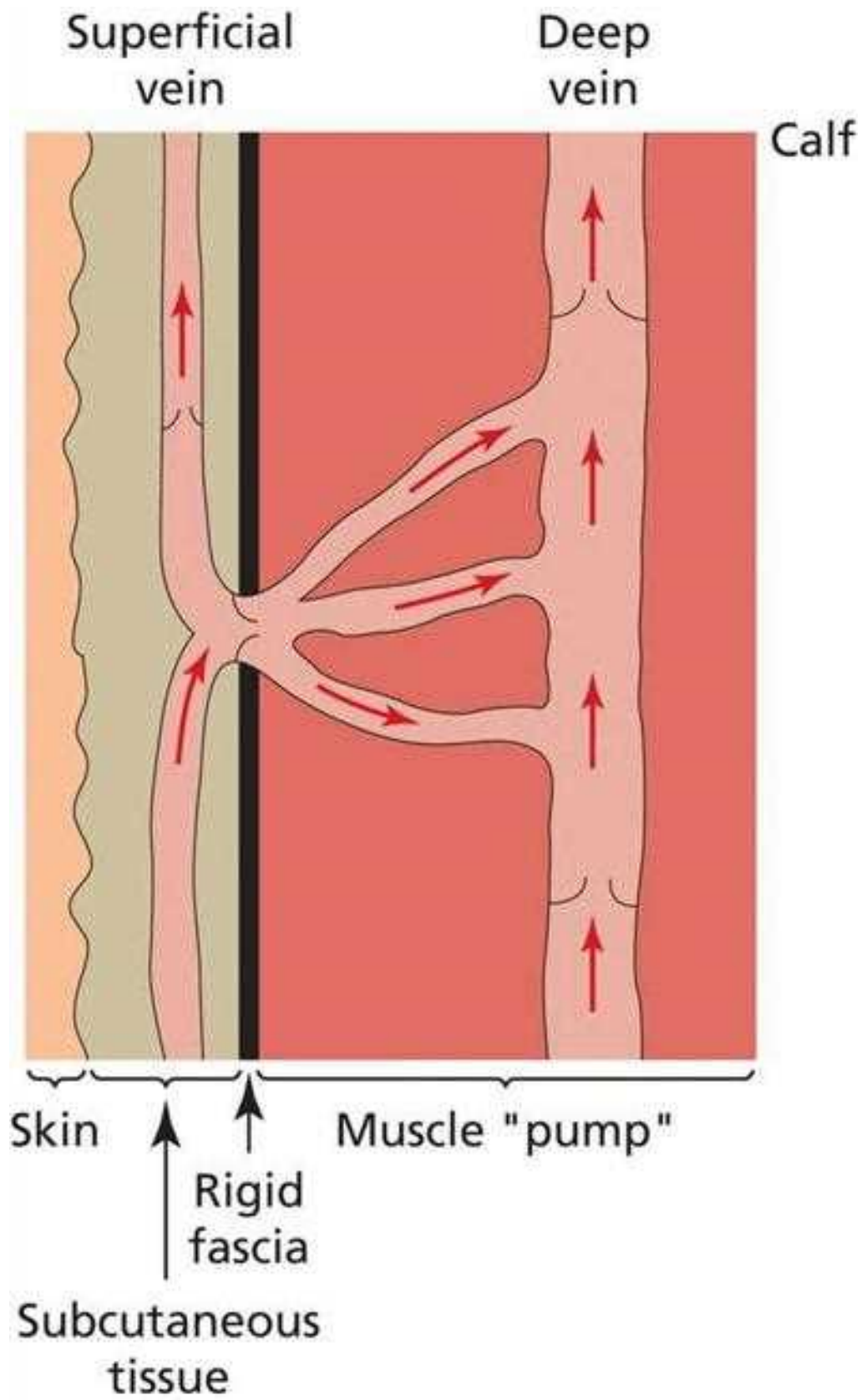


Figure 11.2 Healthy valves in legs.

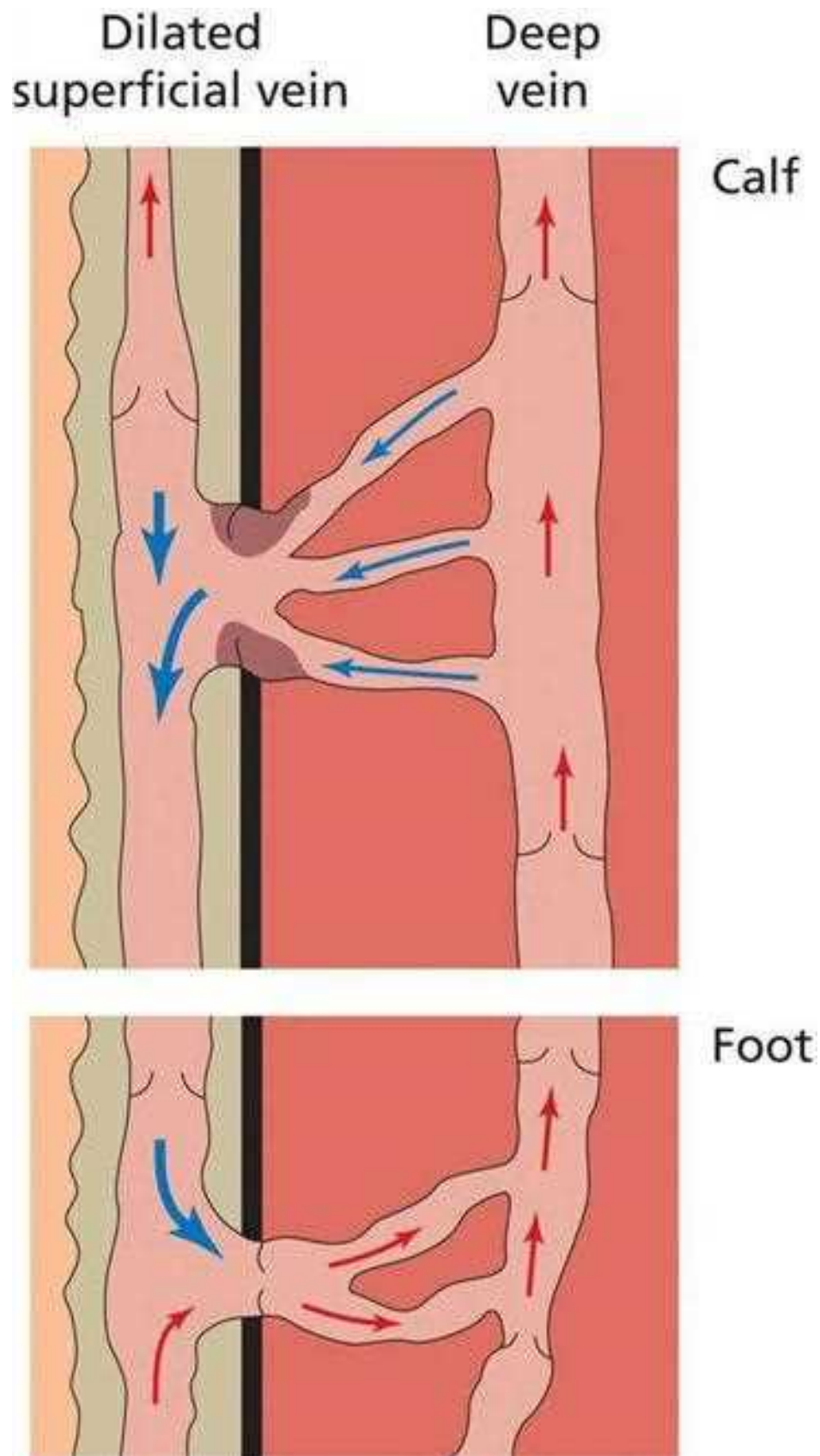
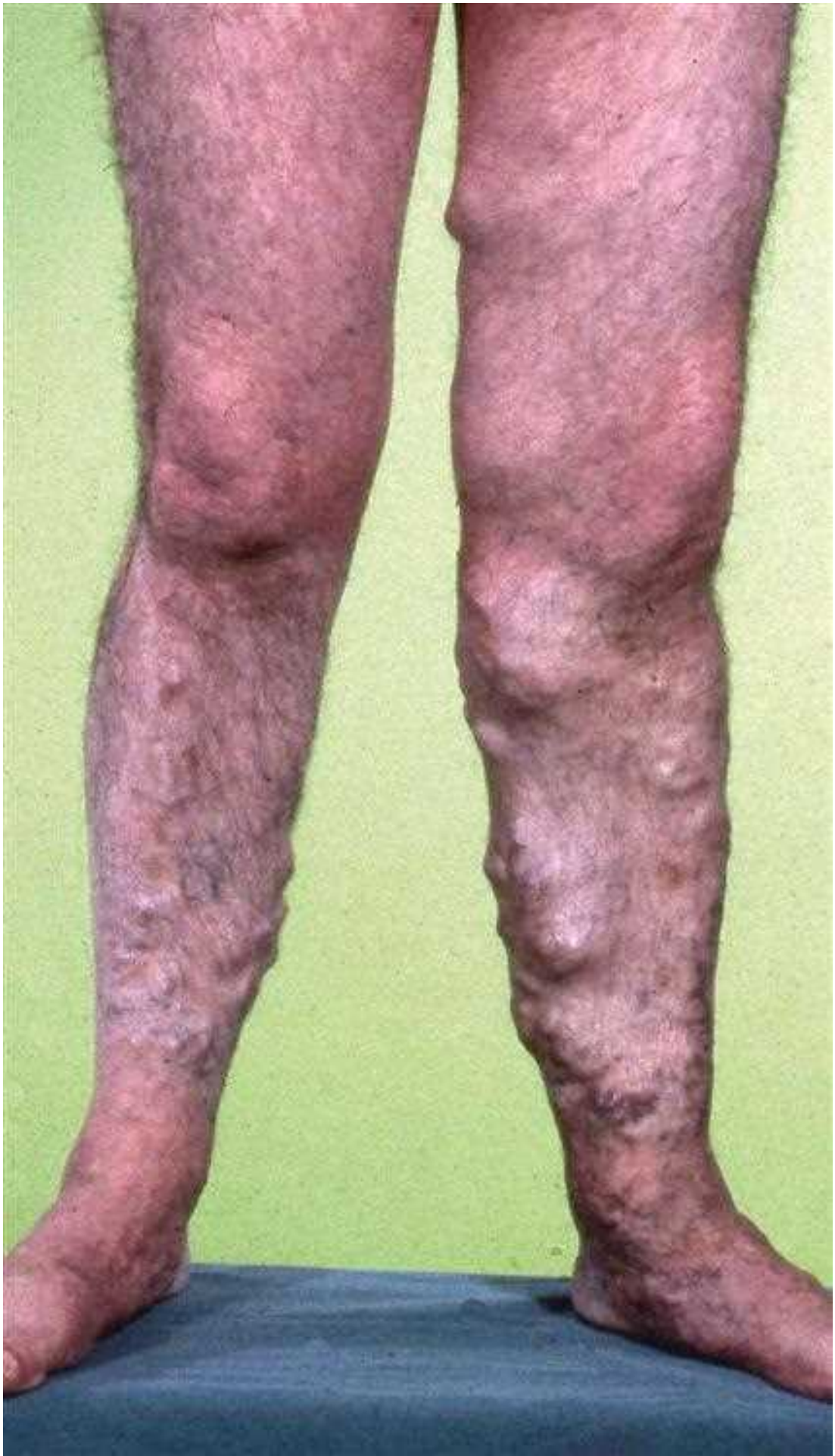

Figure 11.3 Incompetent valves in legs.



[Figure 11.4](#) Varicose veins.

Incompetent valves

Incompetent valves leading to gravitational ulcers may be preceded by:

1. Deep vein thrombosis (DVT) associated with pregnancy, injury, immobilisation, or infarction
2. Primary long saphenous vein insufficiency
3. Familial venous valve incompetence that presents at an earlier age (approximately 50% of patients)
4. Deep venous obstruction.

Risk factors for venous ulceration

Women are more at risk than men. Other risk factors are a family history of venous disease, increasing age, immobility, obesity, lower leg trauma, peripheral oedema, DVT, varicose veins, and a previous history of venous leg ulceration. Patients may develop severe venous eczema prior to ulceration ([Figure 11.5](#)), which, if treated early and effectively, can prevent ulceration.

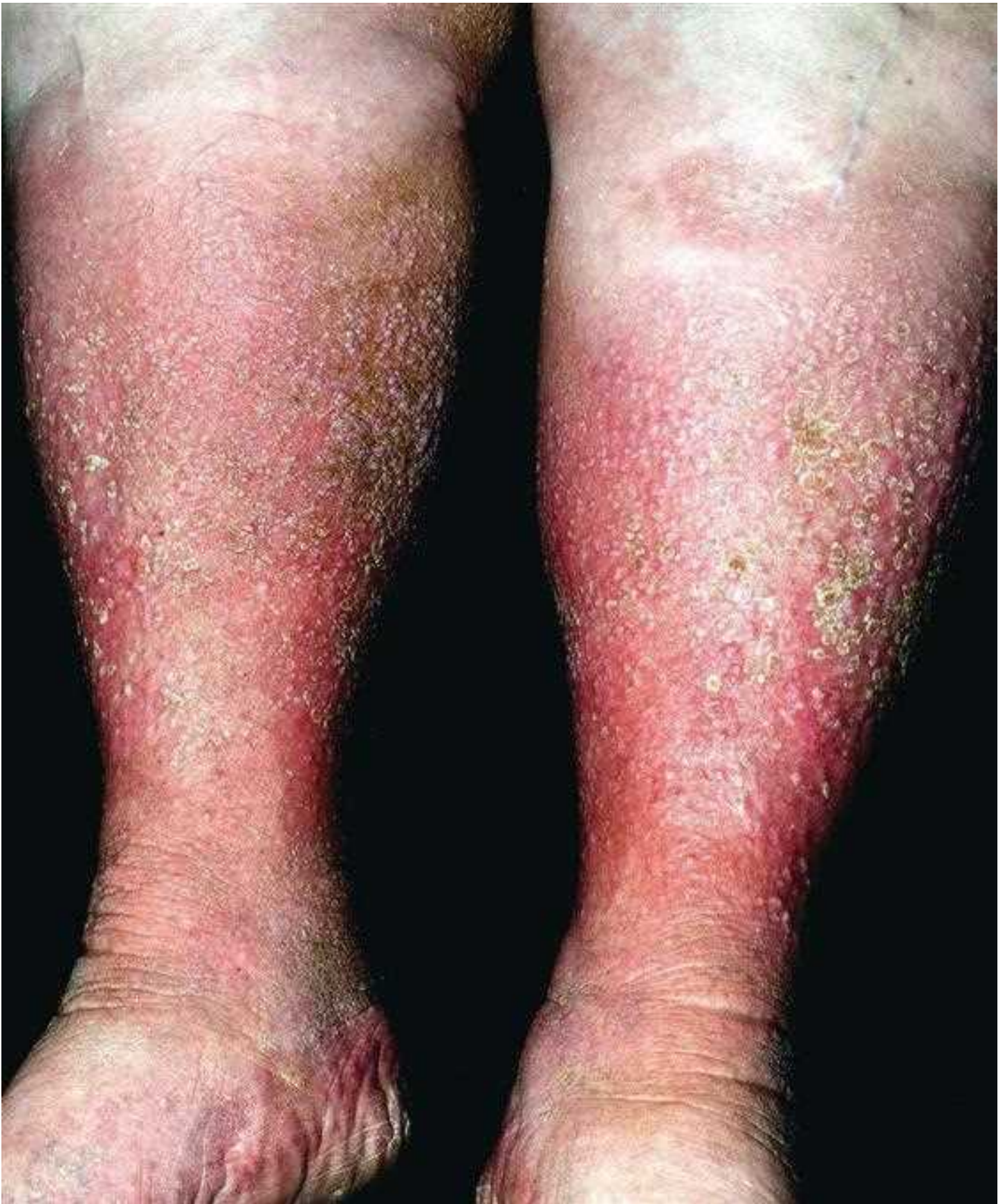
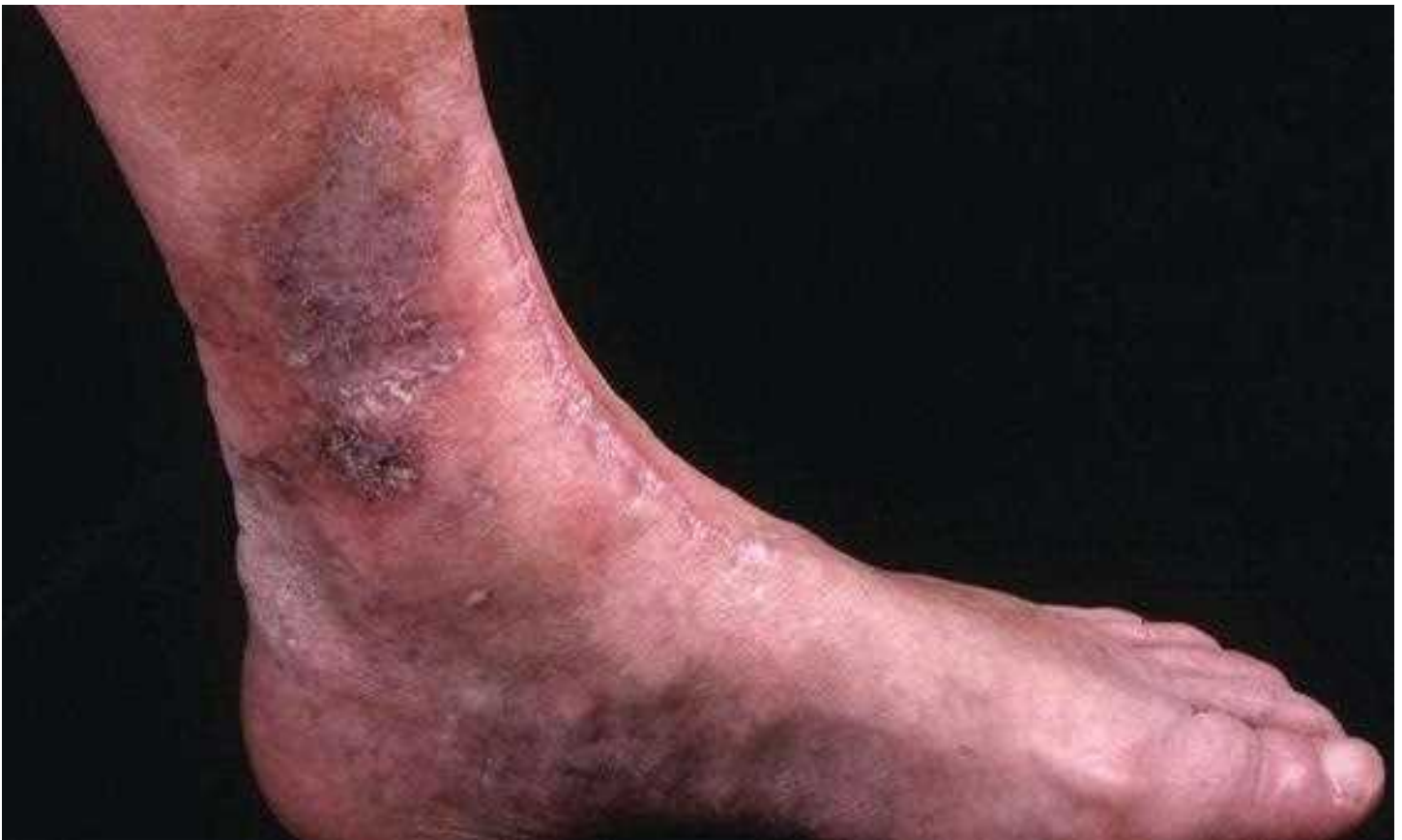
Figure 11.5 Varicose eczema.

Clinical features

Venous ulcers occur around the ankle (gaiter area), most commonly over the medial malleolus. Patients frequently have swollen lower legs with marked pitting oedema. Chronic pitting oedema and fibrinous exudate often lead to fibrosis of the subcutaneous tissues, which may be associated with localised loss of pigment and dilated capillary loops, an appearance known as '*atrophie blanche*' ([Figure 11.6](#)). This occurs around the ankle with oedema and dilated tortuous superficial veins proximally and can lead to 'inverted champagne bottle'-shaped legs. Lymphoedema results from obliteration of the superficial lymphatics, with associated fibrosis ([Figure 11.7](#)). There is often hypertrophy of the overlying epidermis known as *lipodermatosclerosis*, which is a scleroderma-like hardening of the legs in patients with venous insufficiency characterised by induration, hyperpigmentation, and depression of the skin ([Figure 11.8](#)).



[Figure 11.6](#) Atrophie blanche.

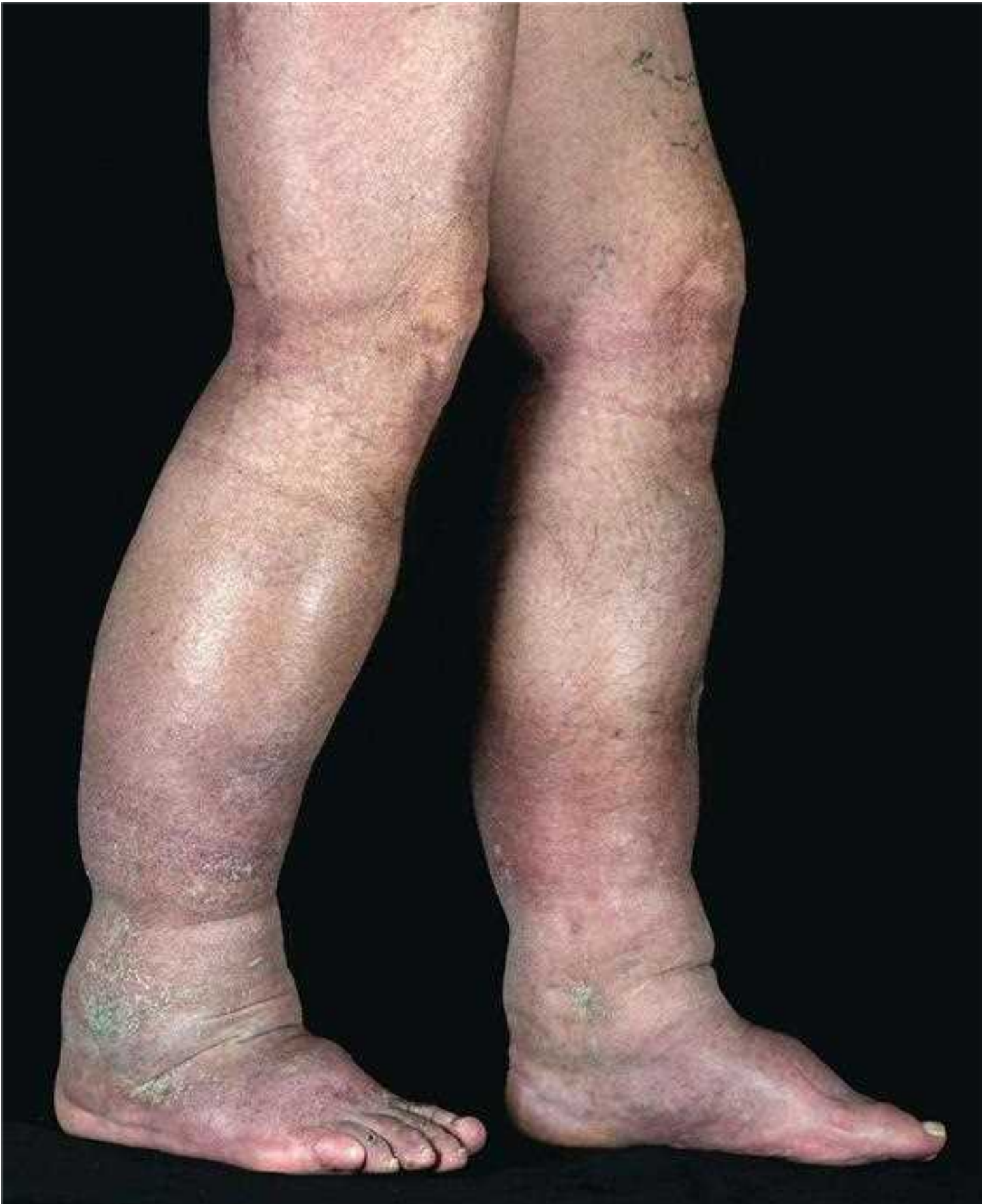

Figure 11.7 Lymphoedema.

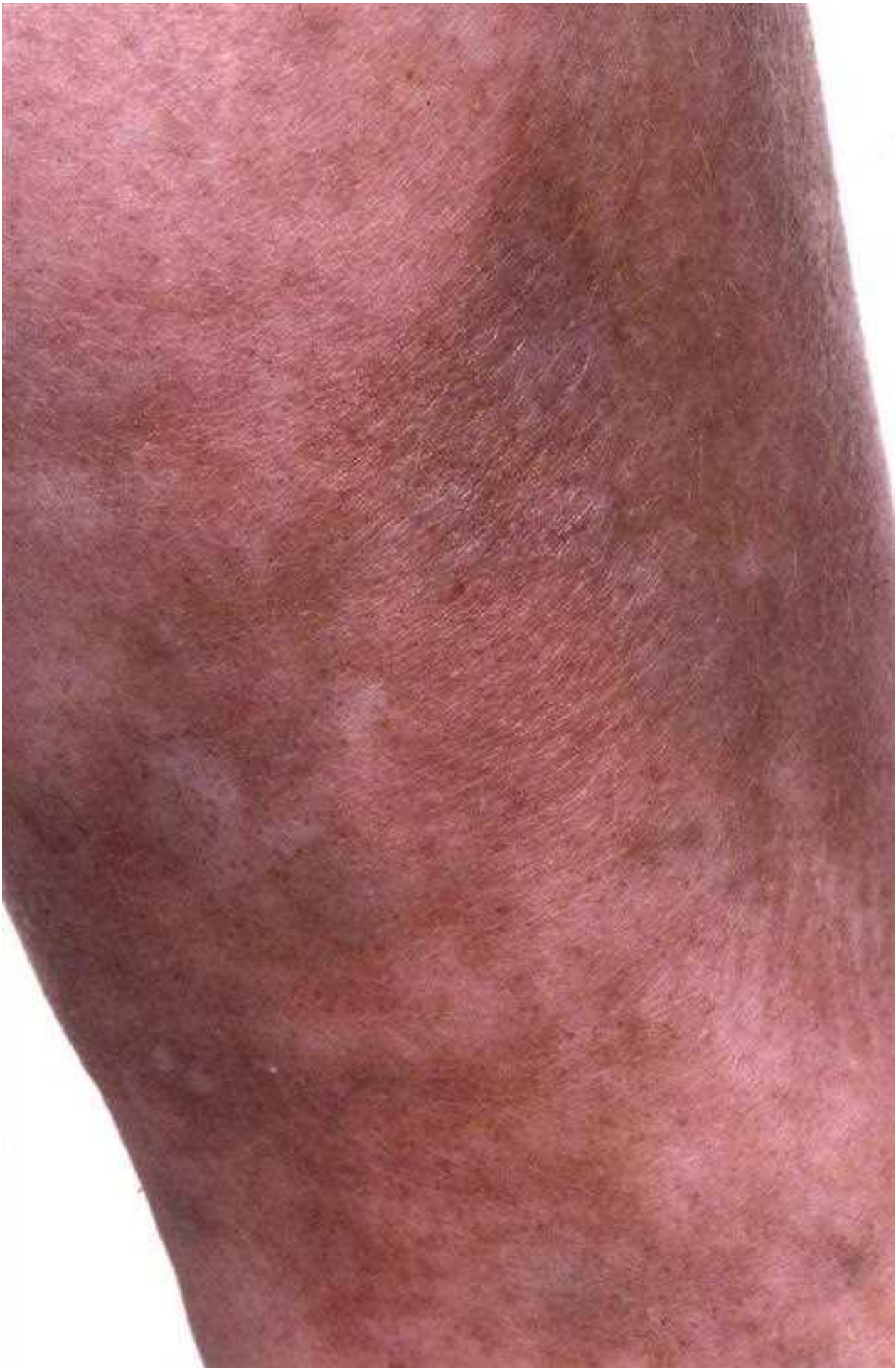

Figure 11.8 Lipodermatosclerosis.

Ulceration often occurs for the first time after a trivial injury. The ulcer margin is usually well defined with a shelving edge and central slough. The surrounding skin may be eczematous (erythematous, inflamed, and itchy): the so-called *varicose eczema*. Venous ulcers may be mildly painful, may exude serous fluid and may become odorous from secondary infection.

It is important to check the pulses in the leg and foot as compression bandaging of a leg with impaired blood flow can cause ischaemia and necrosis. Long-standing ulcers can rarely undergo malignant change (Marjolin's ulcer) when the edge becomes heaped up and atypical because of transformation to squamous cell carcinoma.

Local/topical treatments

When new epidermis can grow across an ulcer it will, and the aim is to produce an environment in which this can take place. To this end several measures can be taken ([Box 11.1](#)).

- Try to eliminate oedema by means of: (i) diuretics; (ii) keeping the legs elevated when sitting; (iii) avoiding standing as far as possible; (iv) walking helps through activation of the 'calf muscle pump'; (v) applying compression bandages with greater pressure at the ankle than the thigh (see [Chapter 25](#)) ([Figure 11.9](#)).
- Exudate and slough should be removed. Washes can be used to clean the ulcer, such as 0.9% saline solution, sodium hypochlorite solution or 5% hydrogen peroxide ([Figure 11.10](#)). Modern dressings such as alginate, hydrocolloid, and Hydrofiber[®] can efficiently absorb the exudate. There is some evidence that antiseptic solutions and chlorinated solutions delay collagen production and cause inflammation. Enzyme preparations may help by 'digesting' the slough. To prevent the formation of over-granulation tissue, use silver nitrate 0.25% compresses, a silver nitrate 'stick' for more exuberant tissue and curettage, if necessary.
- The dressings applied to the ulcer can consist of (i) simple nonstick, paraffin gauze dressings (an allergy may develop to those with an antibiotic); (ii) wet compresses with saline or silver nitrate solutions for exudative lesions; (iii) silver sulfadiazine (Flamazine) or hydrogen peroxide creams (Hioxyl and Crystacide); (iv) absorbent dressings, consisting of hydrocolloid patches or powder, which are helpful for smaller ulcers (see [Chapter 25](#)); and (v) try to ensure that patients sleep in a bed at night rather than a chair.
- Paste bandages, impregnated with zinc oxide and antiseptics or ichthammol, help to keep dressings in place and provide protection. They may, however, traumatise the skin, and allergic reactions to their constituents are not uncommon.
- Treatment of infection is less often necessary than is commonly supposed. All ulcers are colonised by bacteria to some extent, usually coincidental staphylococci. A purulent

exudate is an indication for a broad-spectrum antibiotic and a swab for bacteriology. Erythema, oedema, and tenderness around the ulcers suggest a β -haemolytic streptococcal infection, which may require longer courses of antibiotic treatment. Soaking the leg in a bucket containing potassium permanganate can be a very effective antiseptic and can help reduce exudate and slough. A swab for culture and sensitivity helps keep track of organisms colonising the area.

- Surrounding eczematous changes should be treated with moderate-strength topical steroids avoiding the ulcer itself. Ichthammol 1% in 15% zinc oxide and white soft paraffin or Ichthopaste bandages can be used as a protective layer, and topical antibiotics can be used if necessary. It is important to remember that any of the commonly used topical preparations can cause an allergic reaction: neomycin, lanolin, formaldehyde, tars, and clioquinol (the 'C' of many proprietary steroids).
- Skin grafting can be very effective. There must be a healthy viable base for the graft, with an adequate blood supply; natural re-epithelialisation from the edges of the ulcer is a good indication that a graft will be supported. Pinch grafts or partial-thickness grafts can be used. However, autologous keratinocyte suspensions harvested from the patient's healthy skin may ultimately become the preferred surgical approach.
- Maintaining general health, with adequate nutrition and weight reduction, is important.
- Corrective surgery may be possible for some associated venous abnormalities.

Box 11.1 Treatment of venous leg ulcers

- Elevation of the leg and compression is the key to healing leg ulcers.
- Never apply steroid preparations to the ulcer itself or it will not heal.
- Beware of contact allergy developing to topical agents (antibiotics, steroids, dressings, and bandages).
- Antibiotics should only be given if there is clinical/microbiological evidence of infection (cellulitis).
- A vascular 'flare' around the ankle and heel with varicose veins, sclerosis, or oedema indicates a high risk of imminent ulceration.
- Make sure arterial pulses are present. A Doppler apparatus can be used to measure ABPIs.

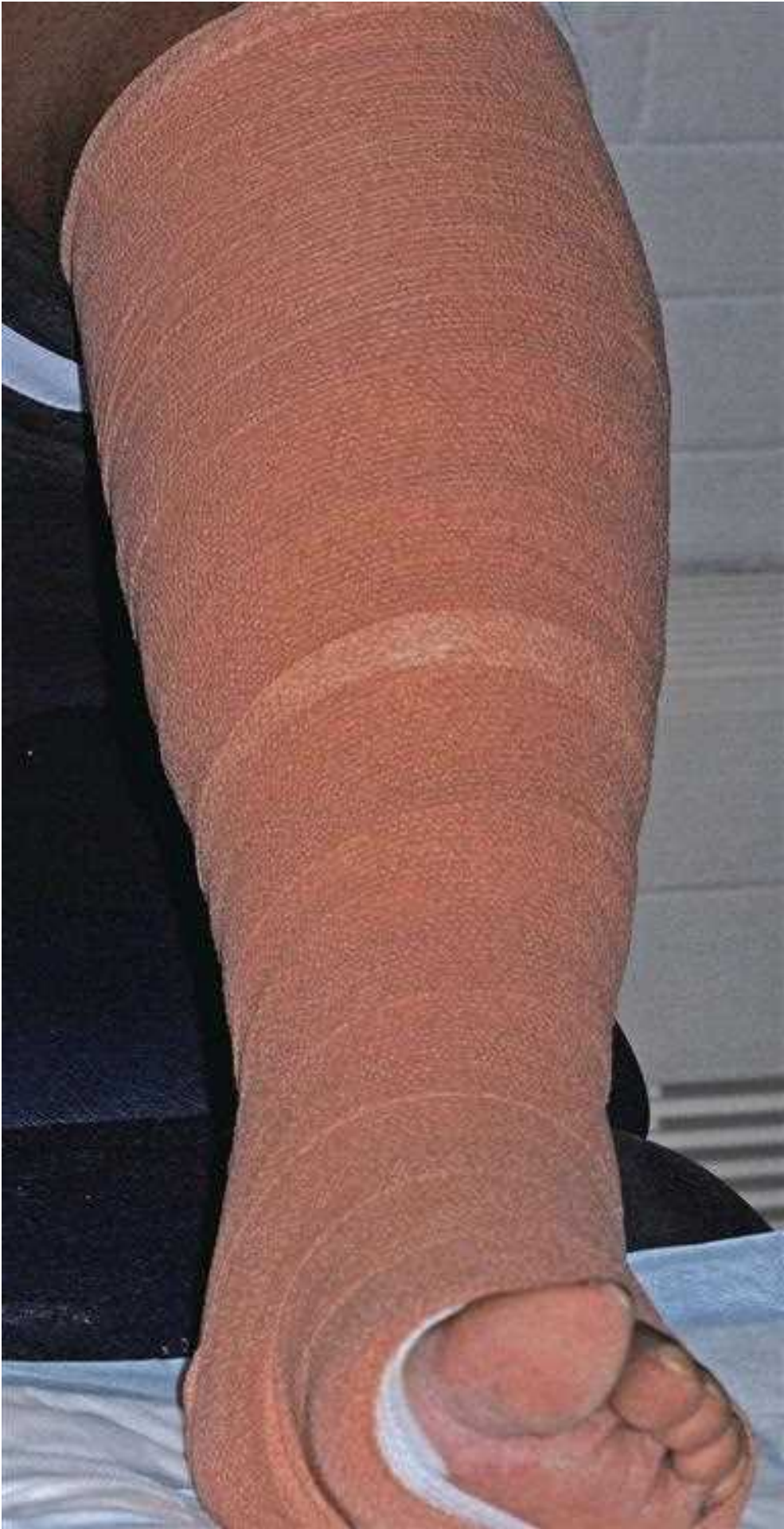

Figure 11.9 Compression bandaging.



Figure 11.10 Cleaning leg ulcers.

Additional manoeuvres in the management of venous ulcers:

1. Modern 'active' dressings have been shown to heal over 80% of wounds that have previously failed to respond to conventional approaches. These active dressings may contain growth-promoting factors such as platelet or fibroblast-derived growth factors (see [Chapter 25](#)).
2. Some units are using low-intensity ultrasonic stimulation to help heal wounds through local activation of angiogenesis, leukocyte adhesion, and production of growth factors.

3. Studies using intermittent pneumatic compression have shown good efficacy in treating chronic venous ulcers and may be a viable alternative to conventional compression bandaging.

Arterial ulcers

Ulcers on the leg also occur as a result of (i) atherosclerosis with poor peripheral circulation, particularly in older patients; (ii) vasculitis affecting the larger subcutaneous arteries; and (iii) arterial obstruction in macroglobulinaemia, cryoglobulinaemia, polycythaemia, and 'collagen' disease, particularly rheumatoid arthritis.

Arterial ulcers are sharply defined ([Figure 11.11](#)) and accompanied by pain, which may be very severe, especially at night. The pretibial area of the lower leg, dorsal foot, and toes are most commonly affected. Simple or magnetic resonance angiography may be needed to map the arterial tree and look for obstructions and narrowing. Compression bandaging will make arterial ulcers worse and may lead to ischaemia of the leg.

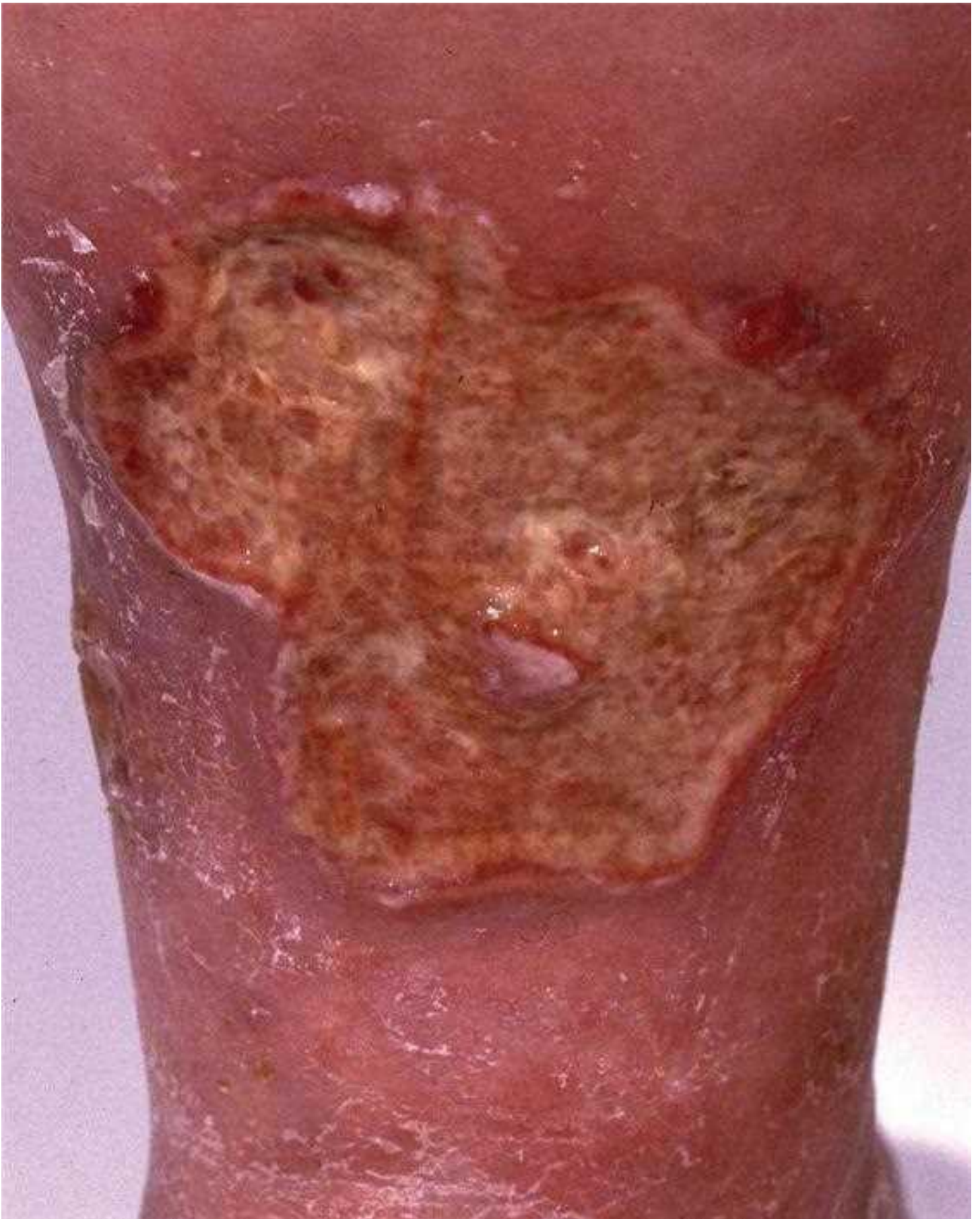
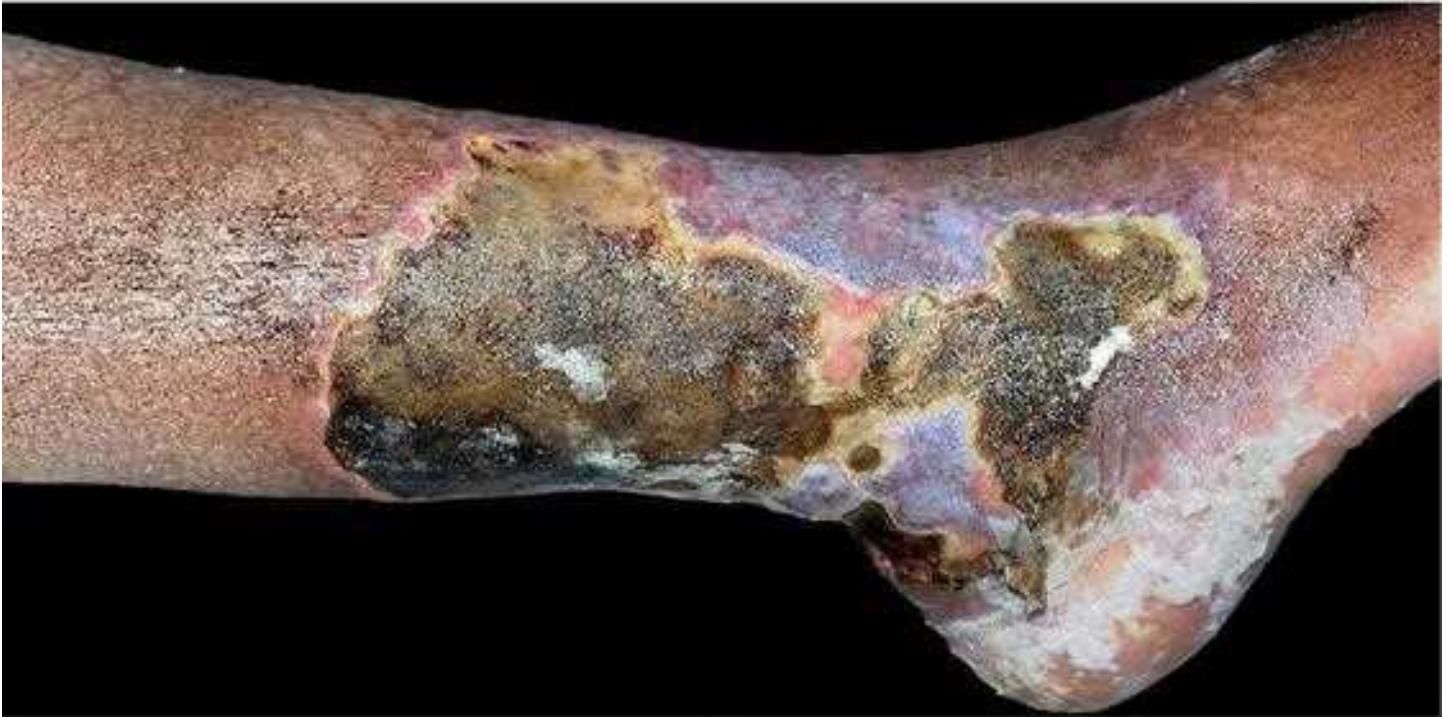
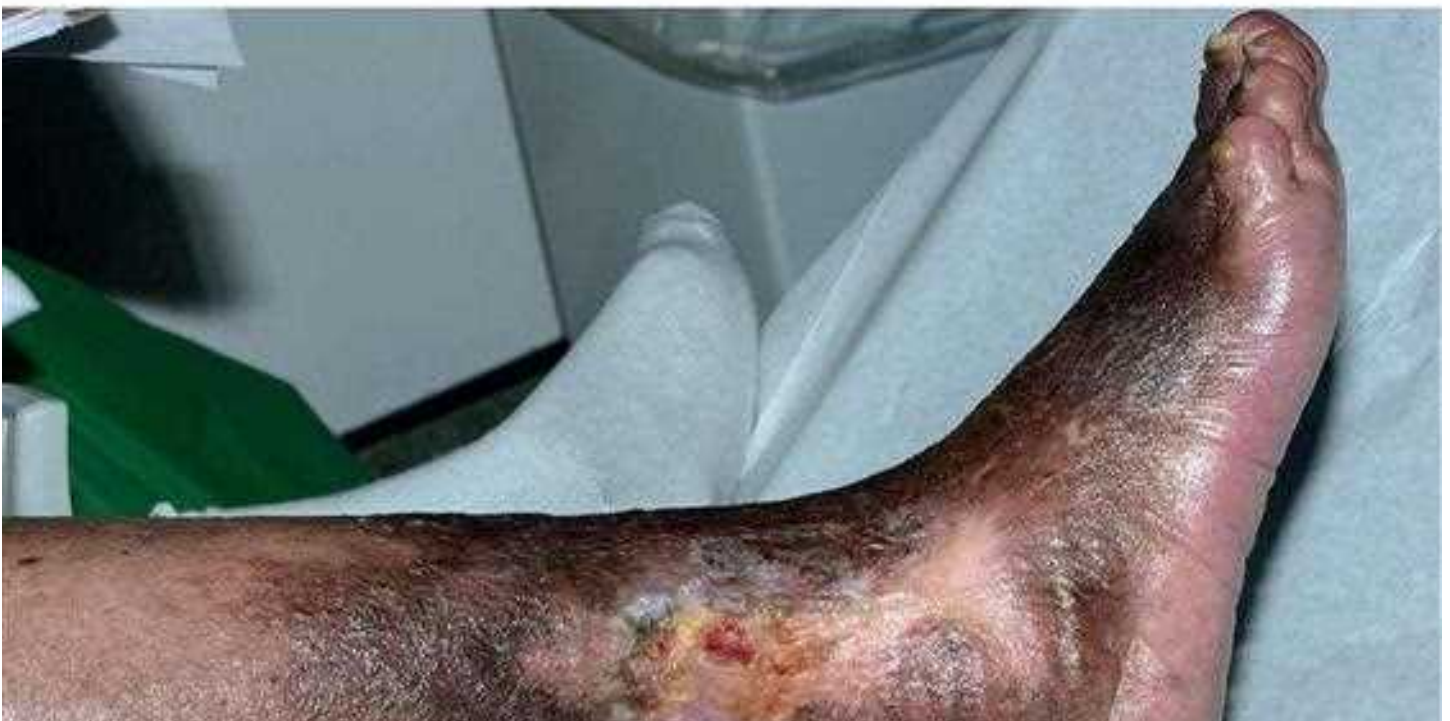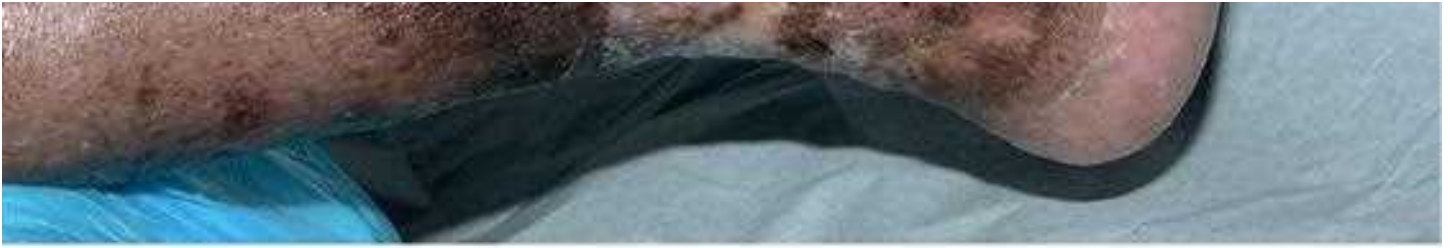Figure 11.11 Arterial ulcer.

In patients with hypertension (usually long-standing and poorly controlled), a very painful ulcer can develop often posteriorly on the lower leg (*Martorell ulcer*). This hypertension-associated ulcer is more common in women and usually affects those aged 50–60 years. The legs may be hairless and pale with poor peripheral pulses; however, patients don't suffer from rest pain or intermittent claudication. The ulcer margin may be inflamed, the ulcer asymmetrical in shape and may be very deep ([Figure 11.12a](#)). Adequate control of the patient's hypertension with specific beta 1-blockers and ACE inhibitors is essential to facilitate ulcer healing and pain reduction ([Figure 11.12b](#)).



(a)





(b)

Figure 11.12 (a) Martorell ulcer caused by uncontrolled hypertension. (b) Healing of Martorell ulcer with control of patient's hypertension.

Diabetic/neuropathic ulcers

Up to 15% of patients with diabetes will develop a foot/leg ulcer at some stage during their lifetime; a significant proportion will recur following initial healing and leading to a higher risk ultimately of amputation. Diabetics suffer from peripheral vascular disease and peripheral neuropathy. The loss or reduction in peripheral sensation leads to damage to the skin and subcutaneous tissue. Much of the trauma is minor and unnoticed, particularly over pressure points, but nonetheless resulting in ulceration. Poorly fitting shoes and extremes of heat or cold can also result in significant damage. Diabetic ulcers are usually well defined and 'punched-out', occasionally with deep sinus tracts that can be explored with a sterile probe ([Figure 11.13](#)). Assessment of the patient's arterial system can be crudely assessed by feeling the dorsalis pedis pulse (on the dorsal aspect of the foot just lateral to extensor hallucis longus tendon). More sophisticated measurements of the haemodynamic state of the lower leg can be made using plethysmography, which determines pulse volume recordings. ABPI measurements can be inaccurate in diabetic patients who are more likely to have calcified blood vessels which may result in falsely raised readings. Management of diabetic ulcers usually requires taking the pressure off the ulcerated area sometimes by making specialised footwear or limiting weight-bearing for a period of time. Cleaning wound and non-adherent dressings need to be used just as for the management of venous ulcers in the text outlined above.

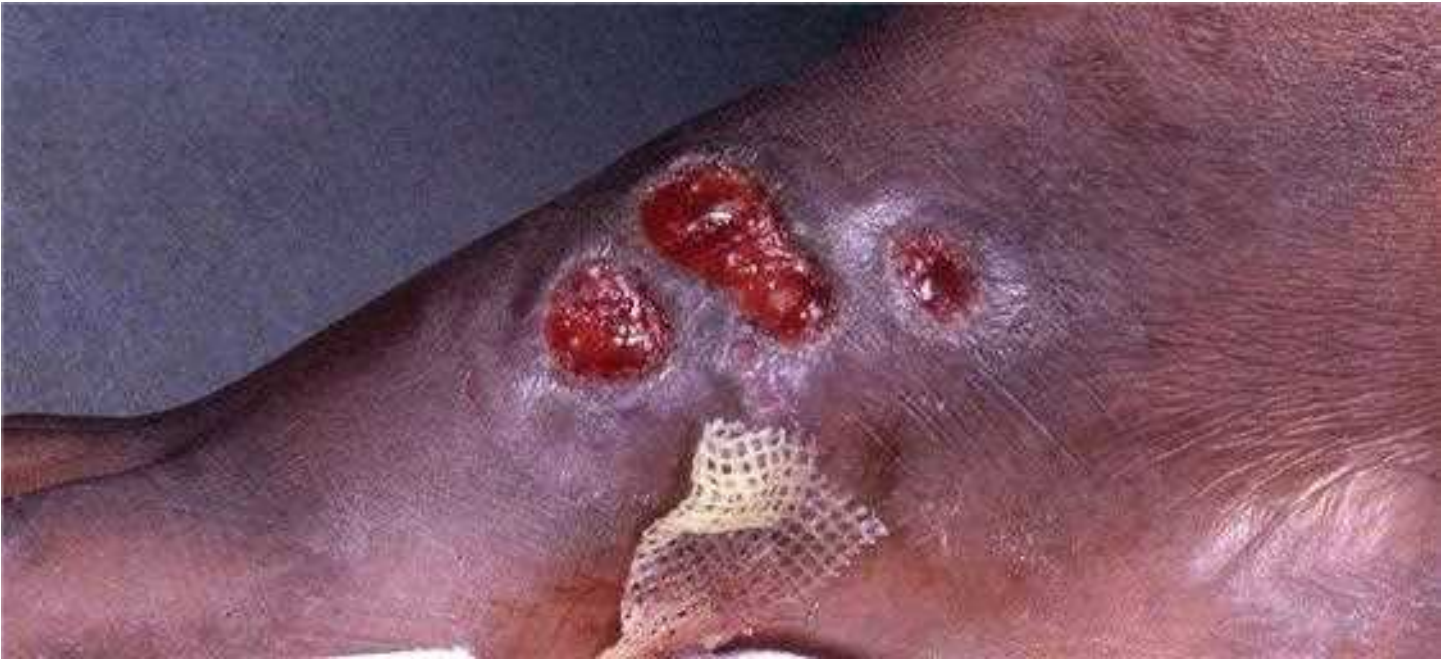

Figure 11.13 Ulcers in diabetic foot.

Inflammatory conditions

Ulcers of the lower legs may occur in polyarteritis nodosa and vasculitis ([Figure 11.14](#)). Pyoderma gangrenosum ([Figure 11.15](#)), a rapidly developing necrotic ulcer with surrounding induration, may occur in association with ulcerative colitis or rheumatoid vasculitis ([Figures 11.13](#) and [11.14](#)). In severe cases of pyoderma gangrenosum, systemic corticosteroids are usually required often with additional ciclosporin and even infusions of infliximab may be needed in recalcitrant cases. An underlying cause for the pyoderma gangrenosum should be sought. Sarcoidosis can lead to cutaneous ulceration usually of the lower legs, skin biopsy through the edge of the ulcer usually shows the characteristic non-necrotising granulomas on histological analysis. Treating the sarcoidosis with prednisolone and/or low-dose methotrexate usually leads to ulcer healing.

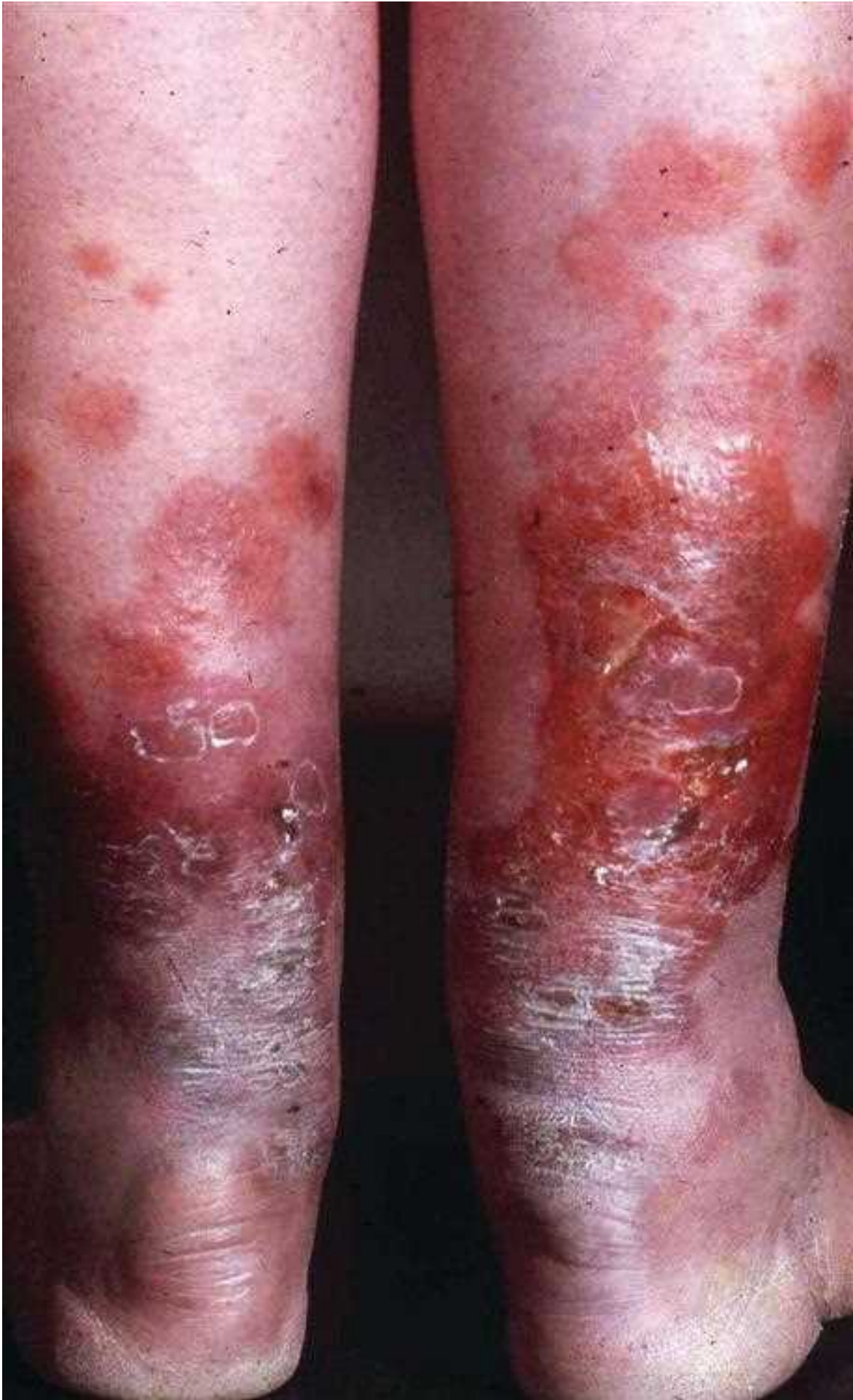

Figure 11.14 Vasculitis and perniosis pre-ulceration.

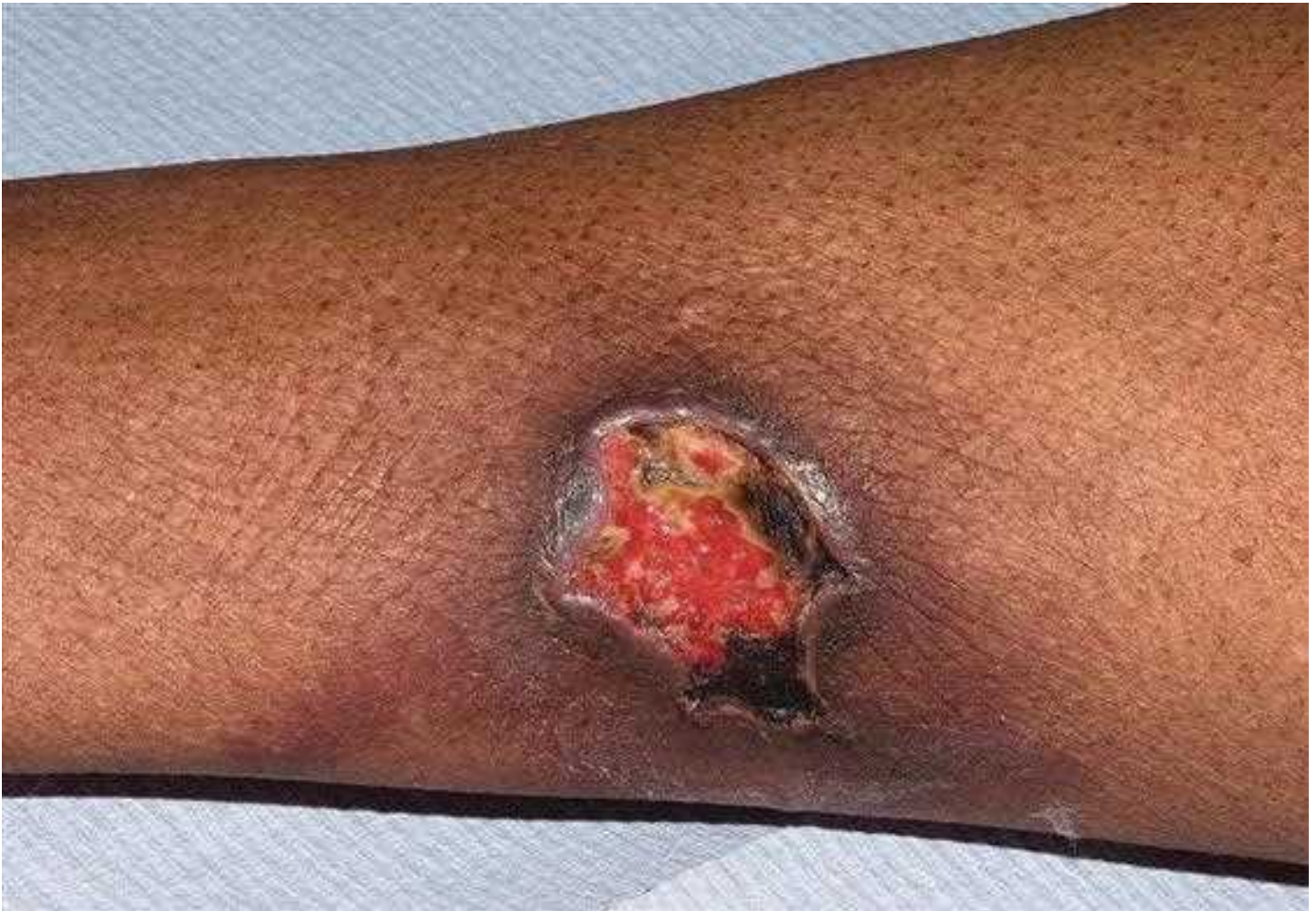

Figure 11.15 Pyoderma gangrenosum.

Infectious ulcers

Infections that cause ulcers include staphylococcal or streptococcal infections, tuberculosis (which is rare in the UK but may be seen in recent immigrants and may be associated with tuberculous osteomyelitis) and anthrax. Leishmaniasis may present with an ulcer at the cutaneous site of a sandfly bite (see [Chapter 18](#)).

Buruli ulcer caused by mycobacteria ulcerans has traditionally been seen in the Tropics in Africa but there has recently been a 400% increase in cases in coastal Australia (also called Daintree ulcer). The infection is usually acquired by contact with contaminated standing water, all ages are affected. Usual sites of infection with buruli ulcer are the extremities, small initial lesions rapidly ulcerate with extensive skin/soft tissue destruction ([Figure 11.16](#)). Treatment requires combinations of antibiotics such as rifampicin (10 mg/kg/day up to 600 mg) and clarithromycin (500 mg BD) plus limited surgical debridement at a later stage if necessary. A paradoxical worsening of the clinical signs can be seen at the commencement of antimicrobials, if this occurs some advocate the use of additional oral prednisolone (reducing

course over eight weeks).

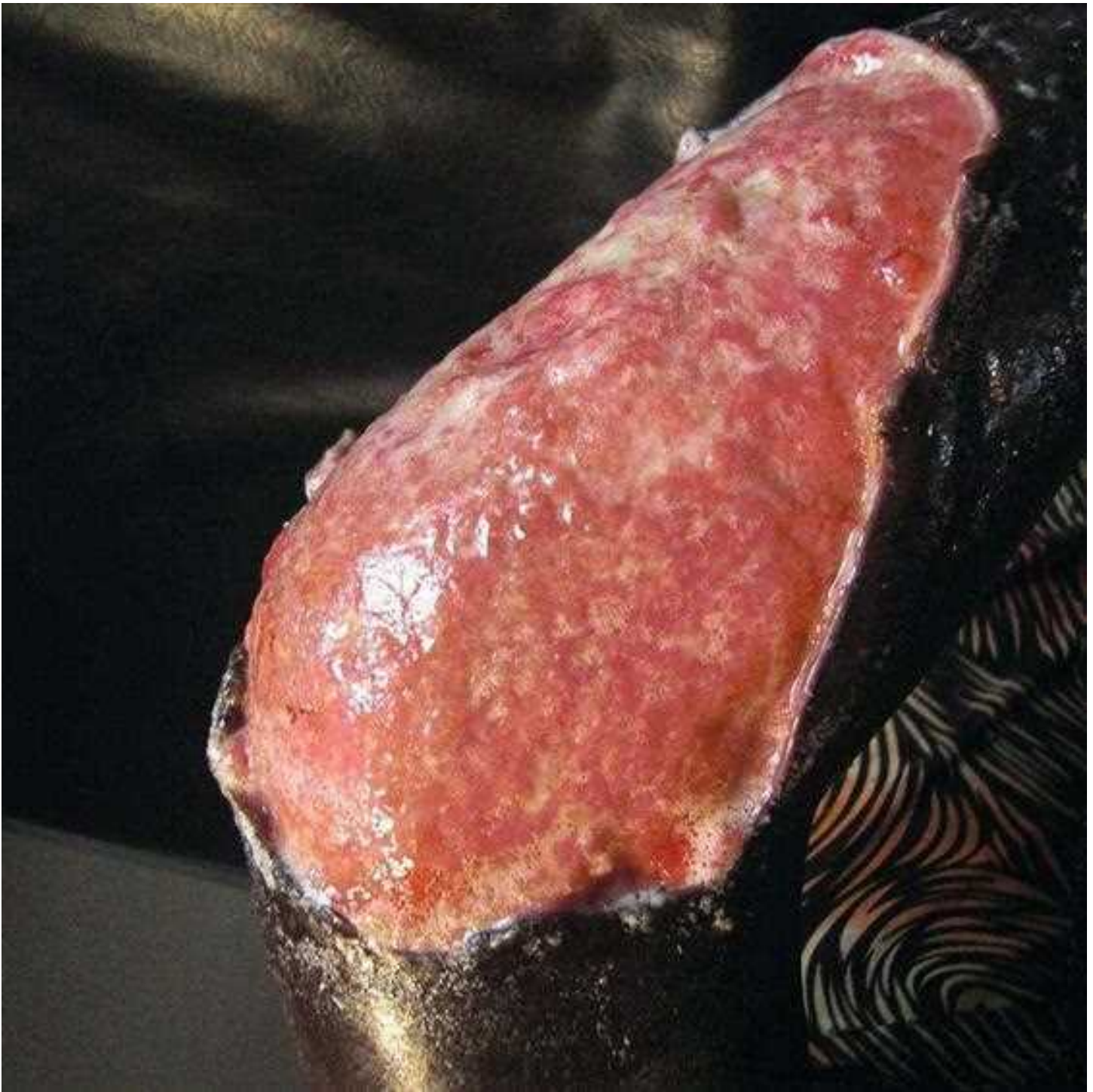

Figure 11.16 Buruli ulcer on the arm.

Malignant diseases

Squamous cell carcinoma may present as an ulcer or, rarely, develop in a pre-existing usually long-standing ulcer (Marjolin's ulcer) ([Figure 11.17](#)). Basal cell carcinoma and melanoma may develop into ulcers, as may Kaposi's sarcoma.

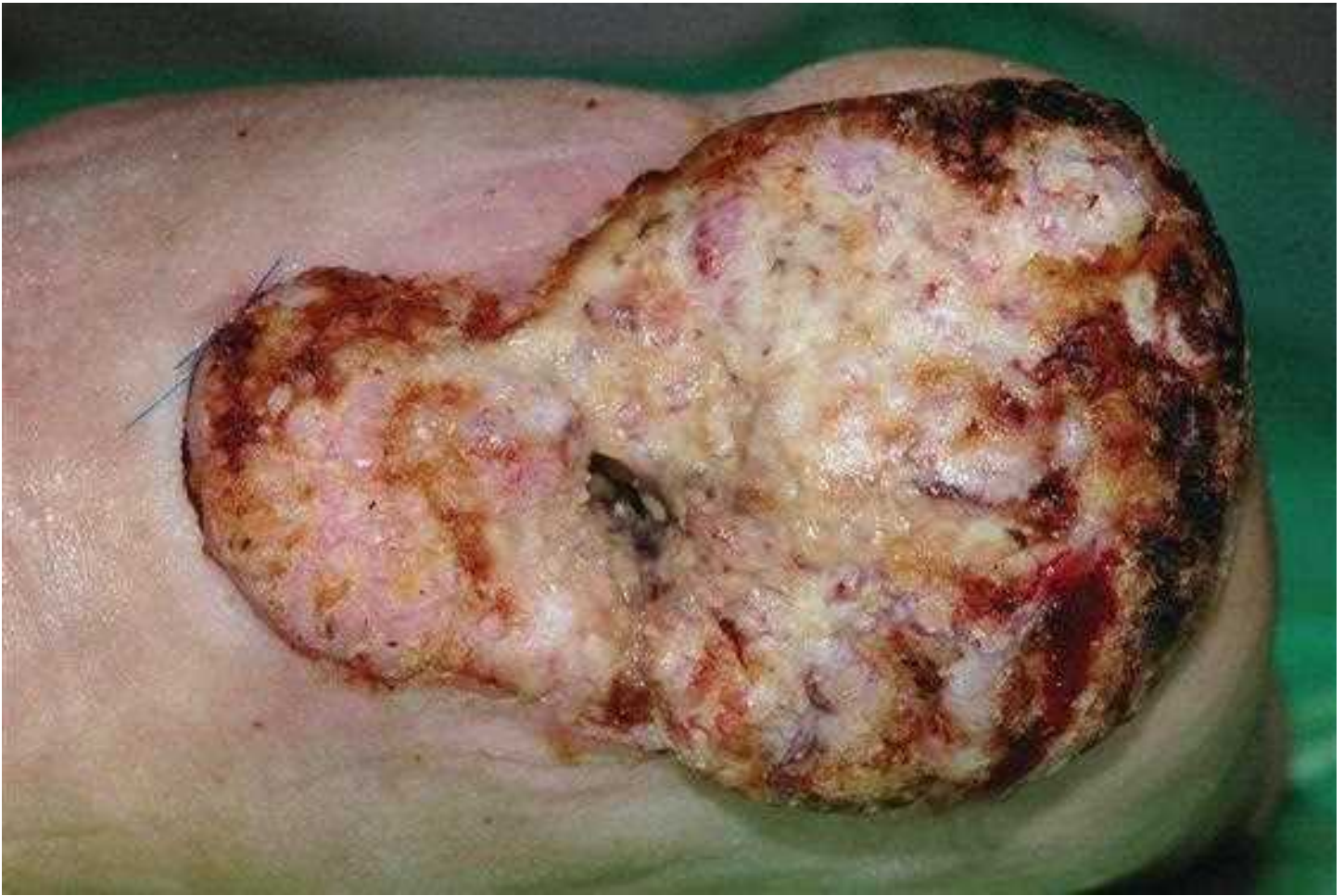

Figure 11.17 Squamous cell carcinoma in a chronic diabetic ulcer.

Trauma

Patients with diabetic or other types of neuropathy are at risk of developing trophic ulcers. Rarely, ulcers may be self-inflicted: 'dermatitis artefacta', where patients damage their own skin, leading to erosions and ulceration ([Figure 11.18](#)).

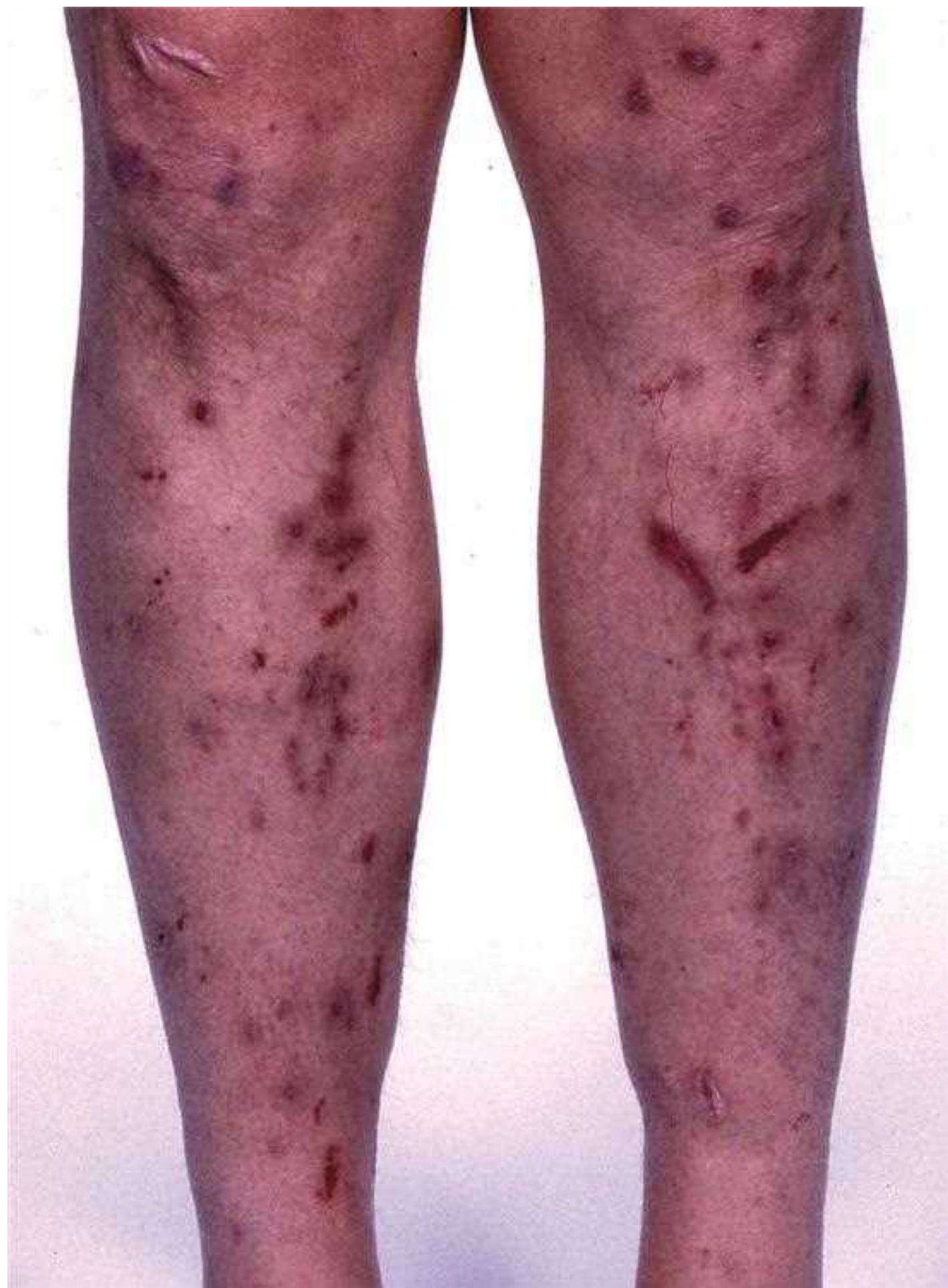

Figure 11.18 Dermatitis artefacta.

Further reading

Ousey, K. and McIntosh, C. (2007). *Lower Extremity Wounds: A Problem Based Approach*. Chichester: Wiley-Blackwell.

Wright, K. and Neil, A. (2017). *The Doctor's Guide to: Venous Leg Ulcers: Prevention and Treatment*. Mediscript Communications, Inc.

Ryan, K. (2013). *Nursing and Health Survival Guide: Wound Care*. Harlow: Pearson.

CHAPTER 12

Acne, Rosacea, and Hidradenitis Suppurativa

Rachael Morris-Jones

Guy's and St Thomas' NHS Foundation Trust, London, UK

OVERVIEW

- 80% of people living in developed countries suffer from acne at some stage in their lives.
- Acne lesions can be pustular and painful, leading to scarring and psychological/emotional upset.
- Androgenic hormones increase sebum secretion and the numbers of *Propionibacterium acnes*.
- Increased levels of oestrogen, testosterone, cortisol, and growth hormone can trigger acne.
- Medications implicated in promoting acne include steroids, oral contraceptives, phenytoin, isoniazid, ciclosporin, and lithium.
- Rosacea is characterised by facial flushing, persistent erythema, telangiectasia, inflammatory papules, pustules, and oedema.
- Conjunctivitis, blepharitis, and eyelid oedema may be associated with rosacea.
- Chronic oedema in rosacea can lead to gross thickening and hypertrophy of the nose called rhinophyma.
- Hidradenitis suppurativa manifests as recurrent boils in the axillae and groin that heal with scarring.
- Management of hidradenitis suppurativa can be challenging and usually requires medication and occasionally surgical excision of affected skin.

Introduction

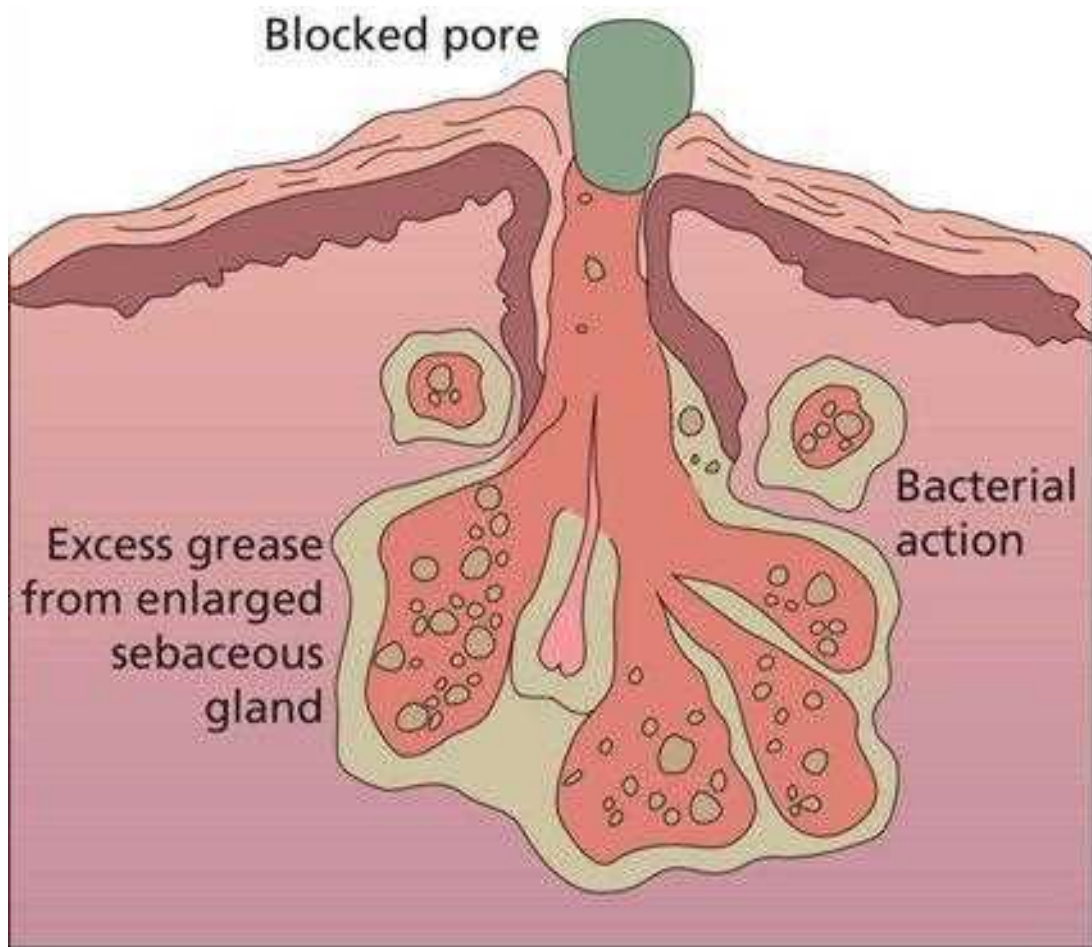
Most adolescents in developed countries suffer from acne leading many to conclude that acne is a 'normal'. However, the significant morbidity associated with it means it frequently has a negative impact on people's lives. Acne, from the Greek word 'acme' meaning 'prime of life', suggests a disorder mainly during adolescence; however, this is somewhat misleading as acne can affect young infants through to individuals in their 40s and 50s. Indeed, over the past two decades the number of individuals who suffer from acne in later life has been

increasing. Estimates show that 5% of the population over the age of 45 years still suffers from acne. Acne can have a significant psychological impact on patients regardless of its severity. Nonetheless, severe acne may, in addition, also be very painful, may cause irreversible scarring and may be associated with systemic symptoms including fever, joint pains, and malaise.

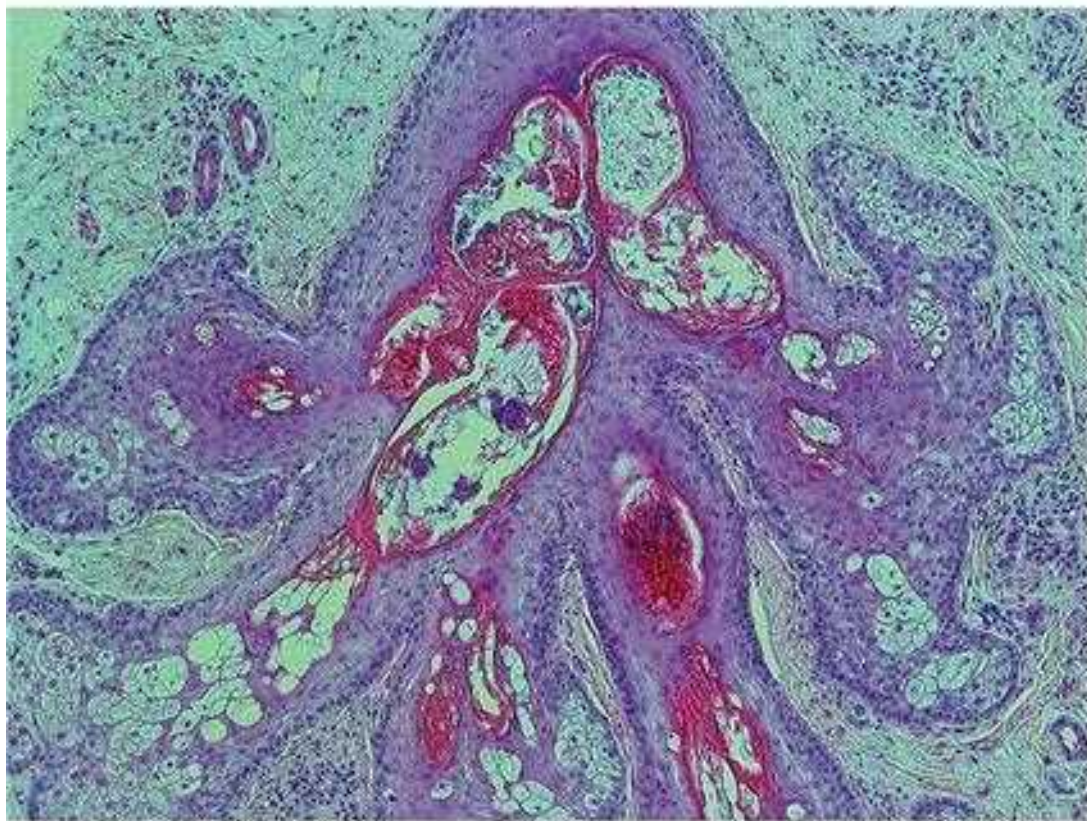
What is acne?

Acne lesions develop from the sebaceous glands associated with hair follicles: face, back, chest, and ano-genital area ([Figure 12.1](#)). (Sebaceous glands are also found on the eyelids and mucosa, prepuce, and cervix; however, they are not associated with hair follicles.) The sebaceous gland contains holocrine cells that secrete triglycerides, fatty acids, wax esters and sterols as 'sebum'. The main changes in acne include:

- thickening of the keratin lining and subsequent obstruction of the sebaceous duct resulting in closed comedones ('whiteheads') ([Figure 12.2](#)) or open comedones ('blackheads' whose colour is due to melanin, not dirt) ([Figure 12.3](#)). Acne cannot be diagnosed without the presence of comedones (there are no comedones seen in rosacea)
- an increase in sebum secretion
- an increase in *P. acnes* bacteria within the duct
- inflammation around the sebaceous gland.



(a)



(b)

Figure 12.1 (a) Sebaceous gland: pathology in acne. (b) Histology of acne.

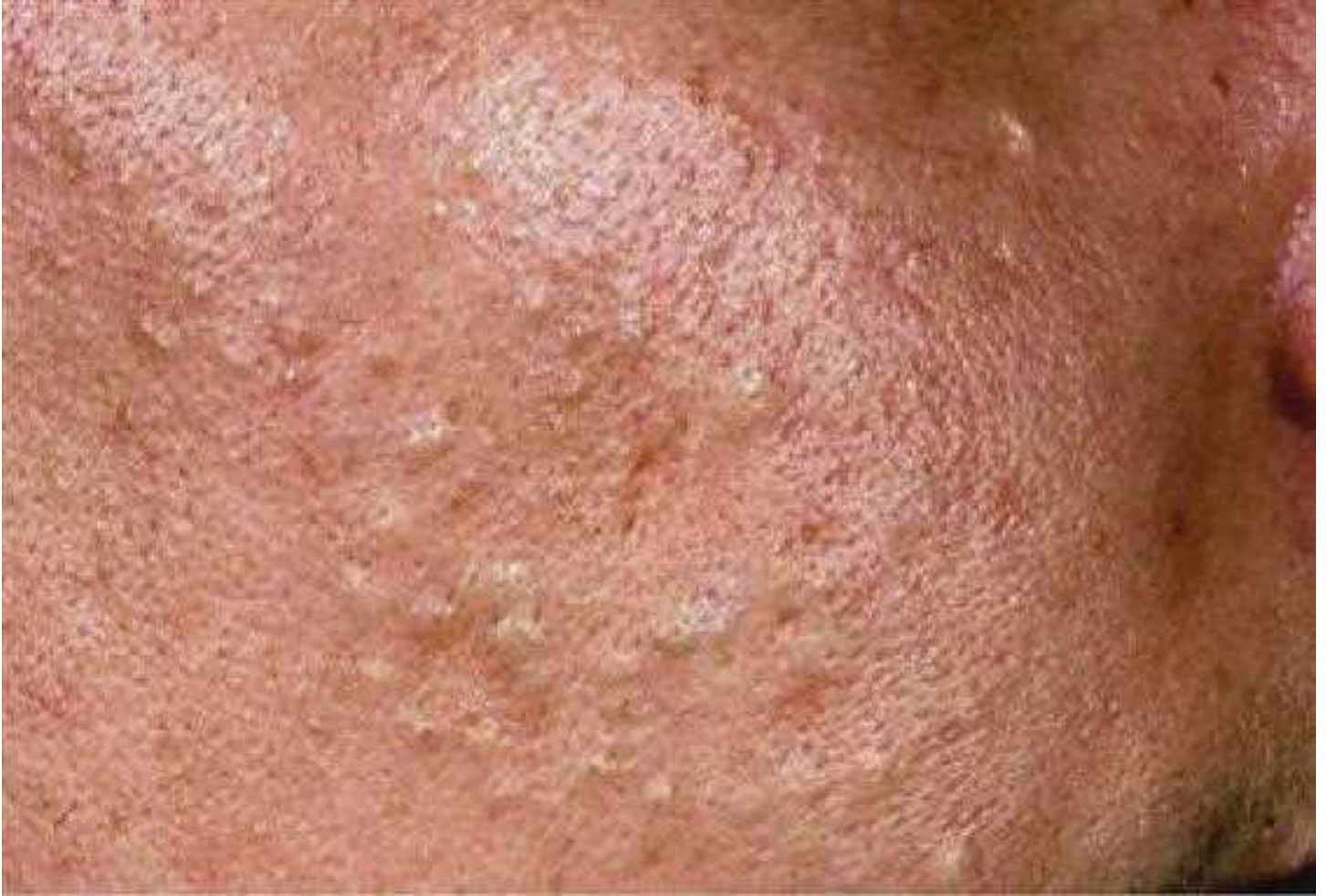
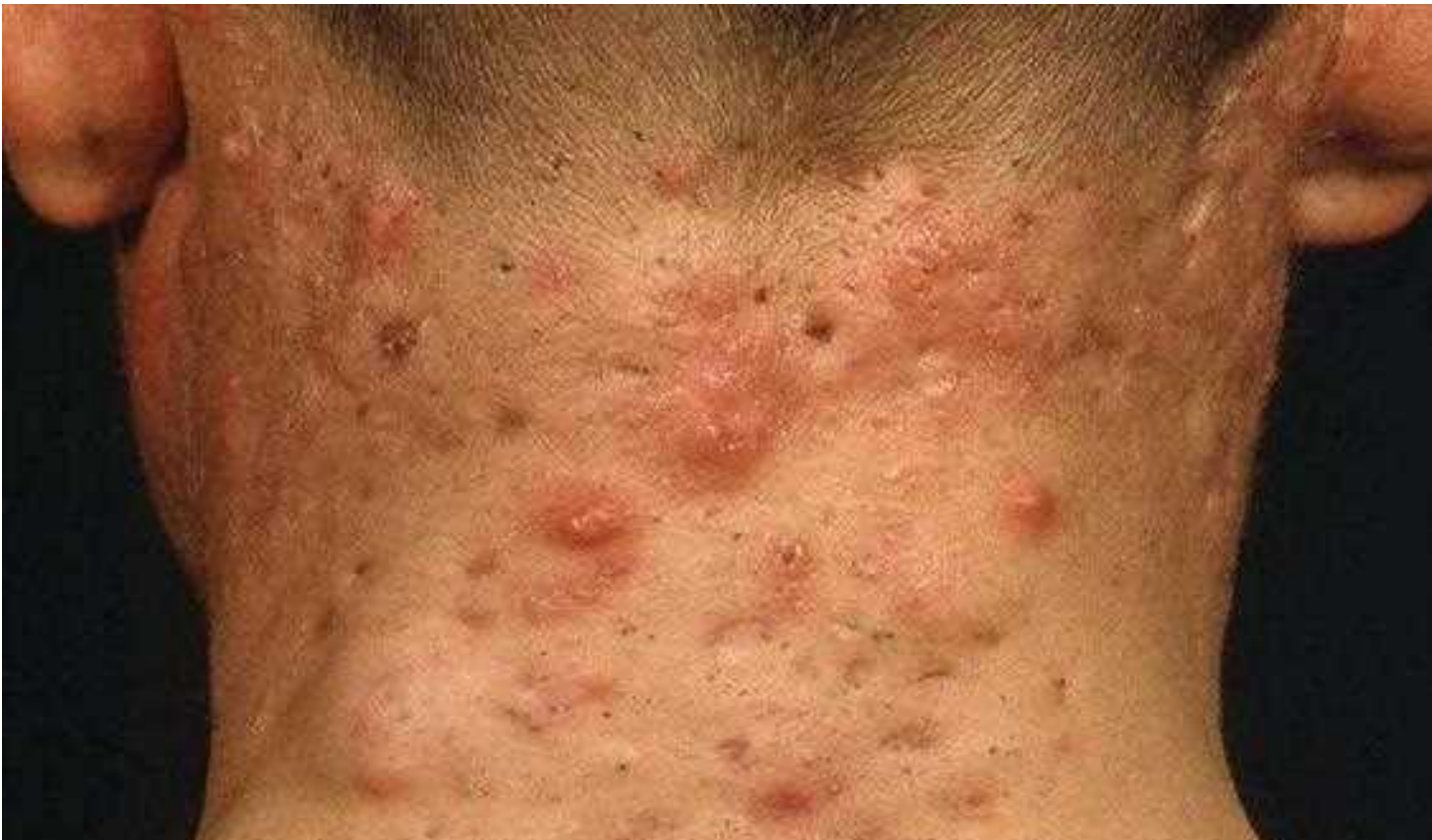
Figure 12.2 Acne with closed comedones.



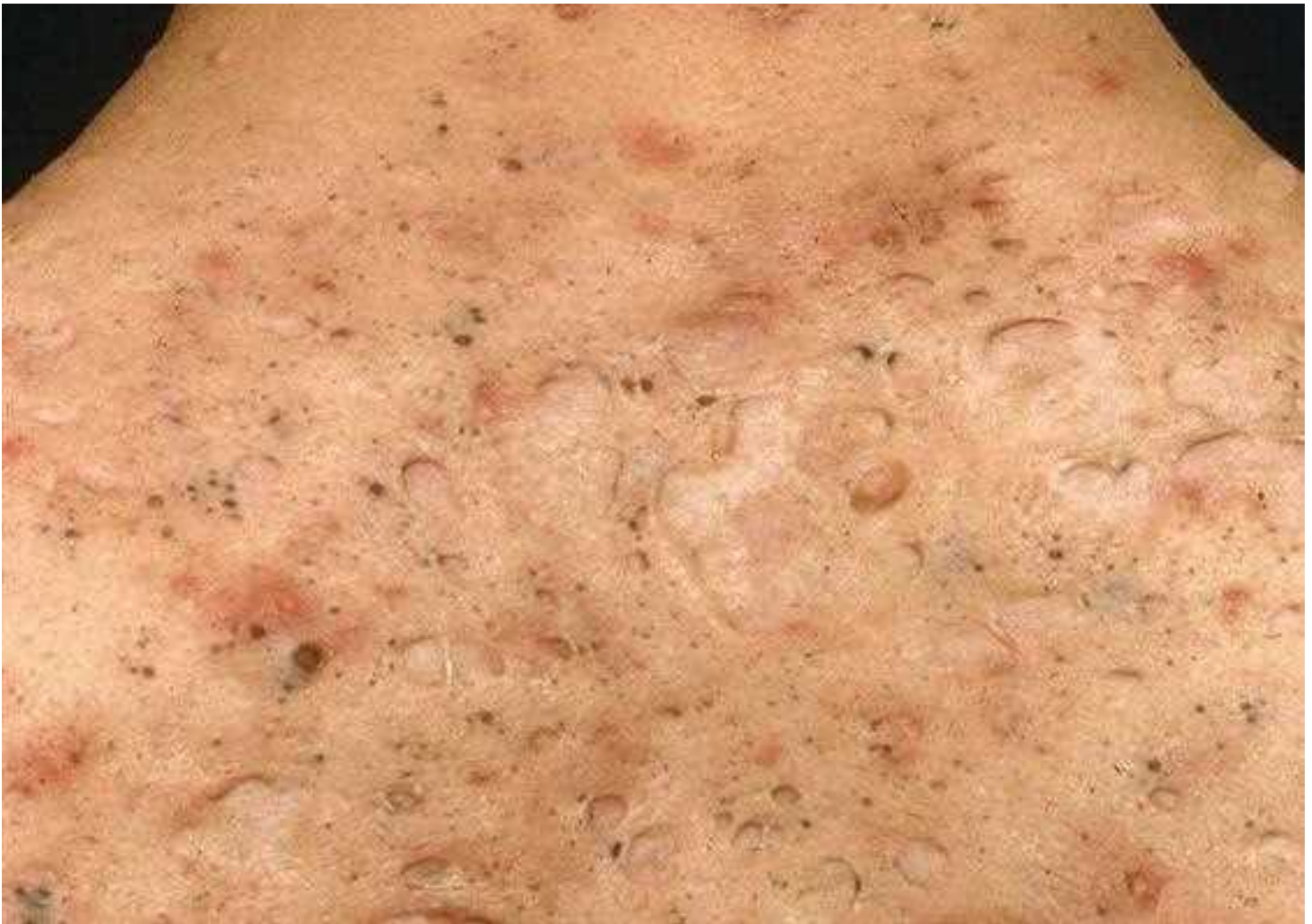

Figure 12.3 Acne with open comedones, cysts, and scars.

Underlying causes

There are various underlying causes of these changes ([Box 12.1](#)).

Hormones

Androgenic hormones increase the size of sebaceous glands and the amount of sebum in both male and female adolescents. Although androgen levels may be normal there is thought to be an increased sensitivity of the glands to androgen hormones. In some women with acne, there is a lowered sex hormone-binding globulin concentration with a consequent increase in free testosterone levels. These imbalances in hormone profile may be seen in females with polycystic ovarian syndrome (PCOS) who present with persistent/treatment resistant acne with irregular menses and possibly hirsutism (they have cysts in their ovaries seen in ultrasound scan). PCOS can lead to fertility issues and an increased risk in later life of metabolic syndrome and possibly endometrial carcinoma. Oral contraceptives containing more than 50 µg ethinyloestradiol can exacerbate acne. Progesterone-only contraceptive pills ('mini pill') increase sebum production and therefore exacerbate acne in those women who are predisposed. Fifteen per cent of women having the Mirena® coil (contains levonorgestrel,

a synthetic form of progestin) inserted will experience worsening/new onset of acne.

Infantile acne occurs in the first few months of life. It can rarely be caused by congenital adrenal hyperplasia or virilising tumours; but is most commonly due to transplacental stimulation of the adrenal gland by maternal hormones causing increased adrenal androgens.

Box 12.1 Factors causing acne

Intrinsic factors

Hormones

- PCOS
- Virilising tumours
- Congenital adrenal hyperplasia
- Increased cortisol (Cushing's syndrome)
- Increased growth hormone (acromegaly)

Medications

- Topical and systemic steroids
- Oral contraceptive pill (higher androgen content, progesterone-only pill)
- Phenytoin
- Barbiturates
- Isoniazid
- Ciclosporin
- Lithium.

Extrinsic factors

- Oils/pomades
- Coal and tar
- Chlorinated phenols
- DDT and weed killers.

Fluid retention

Premenstrual exacerbation of acne is thought to be due to fluid retention, leading to increased hydration and swelling of the sebaceous duct. Sweating also makes acne worse, possibly by

the same mechanism.

Stress

It has long been observed by patients that stress leads to a worsening of their acne. Now there is evidence to back up the clinical observation. Stress induces inflammation in the pilosebaceous unit, leading to acne or acne exacerbation. There is evidence that within sebocytes is a complete corticotrophin-releasing hormone system that leads to increased lipid and steroid synthesis and an interaction with testosterone and growth hormone.

Diet

Many patients believe their acne is exacerbated by eating certain foods. Most commonly implicated foods include dairy products, chocolate, nuts, coffee, and fizzy drinks. Some epidemiological studies have suggested that a Westernised diet with high levels of refined sugars and starch may explain striking differences in the prevalence of acne among different populations that are not thought to be explained by genetic factors or weight differences. Several small studies have shown when Westerners are given a low glycaemic index diet, both their BMI and their acne lesion count reduce. Other small studies have shown a weak potential link between acne and cow's milk and possibly even cocoa. The best advice to patients would be to eat a normal diet. However, if there are certain foods that they feel exacerbate their acne, then they should avoid eating those foods.

Seasons

Acne often improves with natural sunlight. Phototherapy with artificial light sources using visible blue light alone or in combination with red light has been shown in several clinical trials to be an effective treatment for acne in a proportion of patients. Heat and sweat can make acne worse.

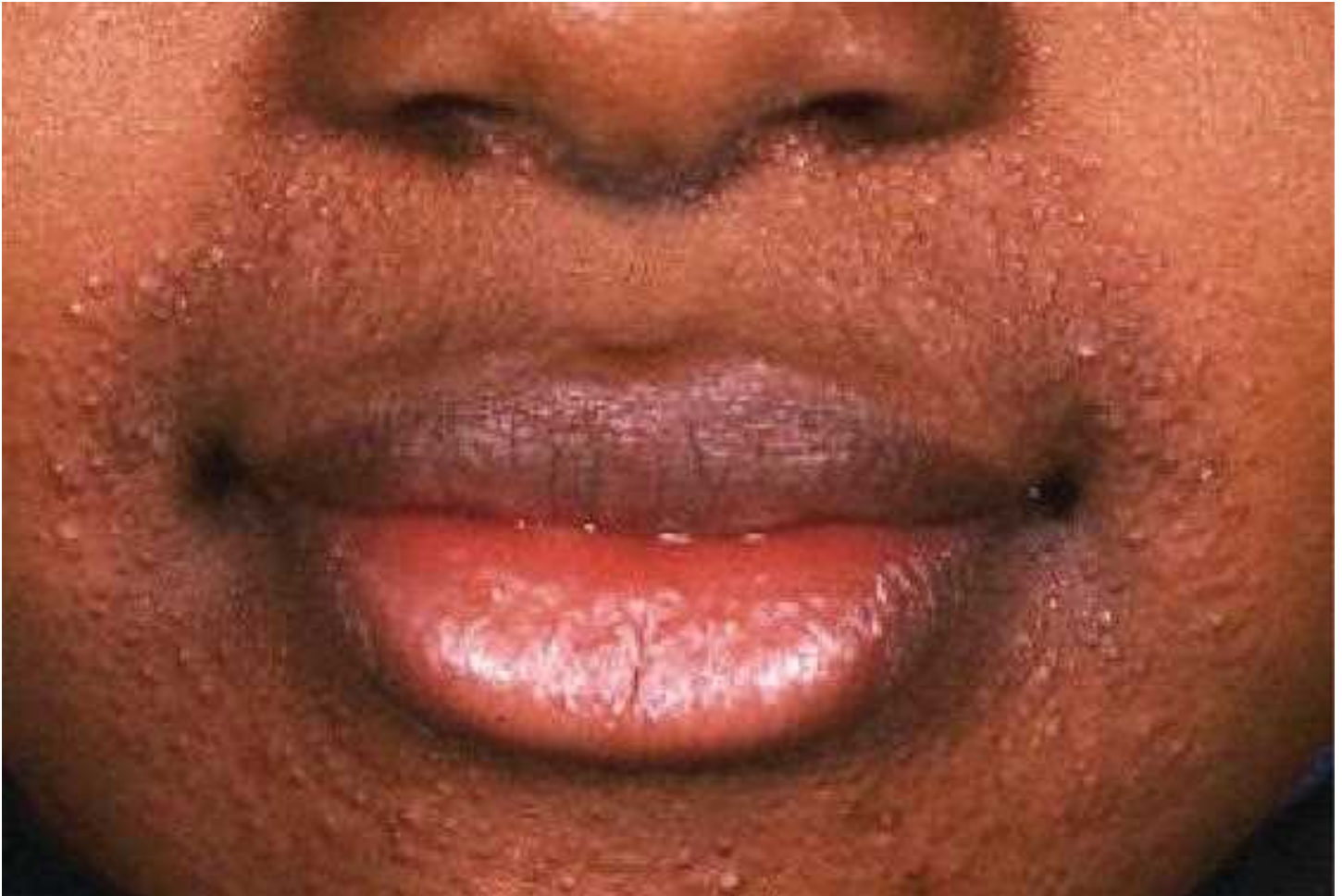
External factors

Oils, whether vegetable oils in the case of cooks in hot kitchens or mineral oils in engineering, can cause 'oil folliculitis', leading to acne-like lesions through contact with the skin. Other acnegenic substances include coal tar, dicophane (DDT), cutting oils, and halogenated hydrocarbons. Cosmetic acne is seen in adult women who have used cosmetics containing comedogenic oils over many years. Individuals who use rich oils in the scalp can suffer from 'pomade acne', which occurs close to the hairline.

Iatrogenic factors

Corticosteroids, both topical and systemic, can cause increased keratinisation of the pilosebaceous duct resulting in acne. Androgens, gonadotrophins, and corticotrophin can induce acne in adolescence. OCPs of the combined type/progesterone-only pill (mini pill) and antiepileptic drugs may also cause acne. However, an OCP with a high oestrogen

combined with low androgen can actually be used to treat acne in women. Some patients develop perioral dermatitis ([Figure 12.4](#)) after application of topical steroids to the face, which is characterised by papules and pustules around the mouth and eyes that may mimic acne but there are no comedones. The topical steroid should be stopped and the patient treated with oral tetracycline or erythromycin for six weeks.



[Figure 12.4](#) Perioral dermatitis.

Types of acne

Acne vulgaris

Acne vulgaris, the common type of acne, occurs during puberty and affects the comedogenic areas of the face, back, and chest. There may be a familial tendency to acne. Acne vulgaris is more common in boys, 30–40% of whom develop acne between the ages of 18 and 19 ([Figure 12.5](#)). In girls, the peak incidence is between 16 and 18 years. Adult acne is a variant affecting 3% of men and 5% of women over the age of 40. Acne keloidalis is a type of scarring acne seen particularly on the neck in men ([Figure 12.6](#); [Box 12.2](#)).

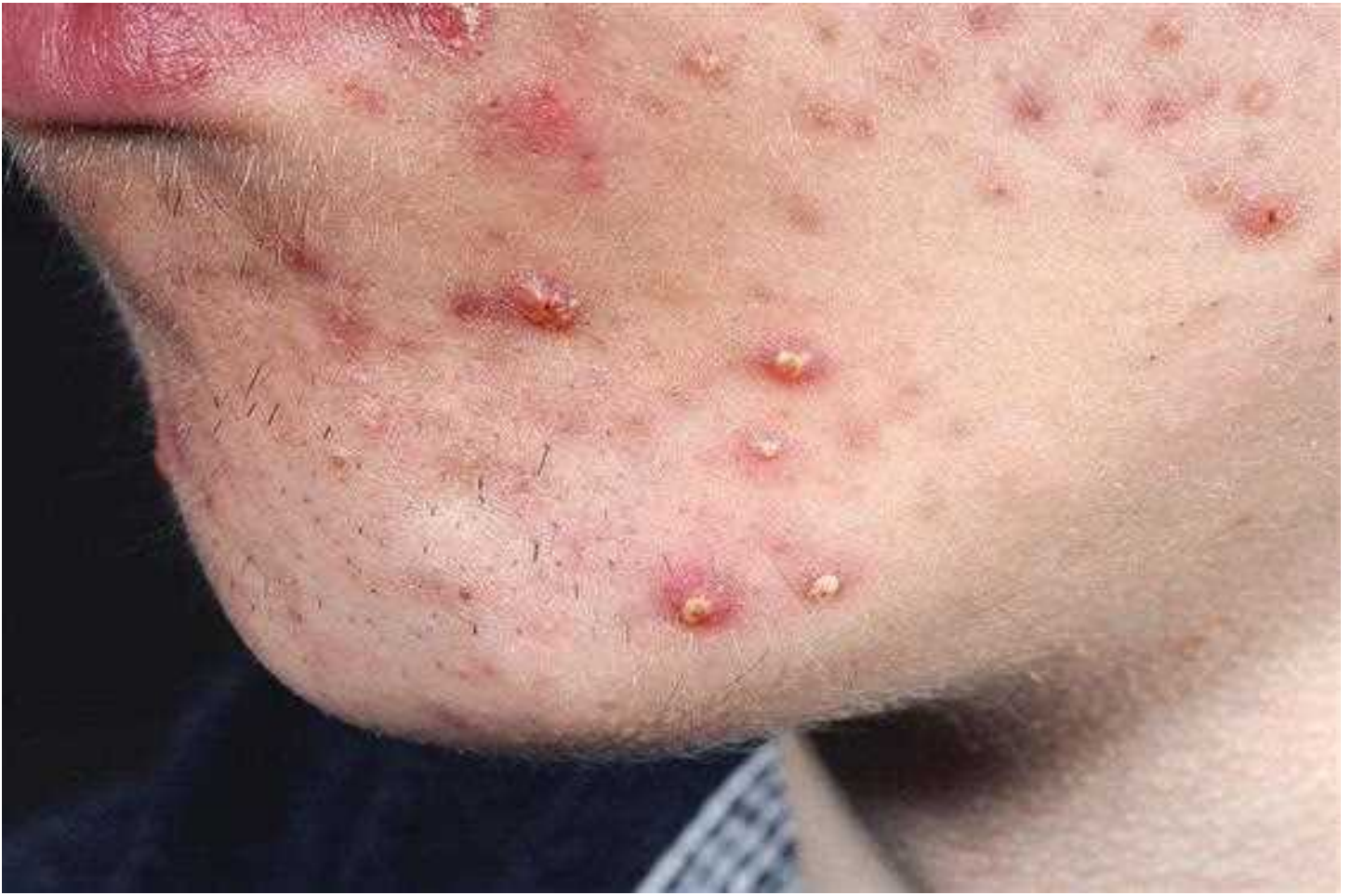

Figure 12.5 Acne vulgaris with inflammatory papules and pustules.

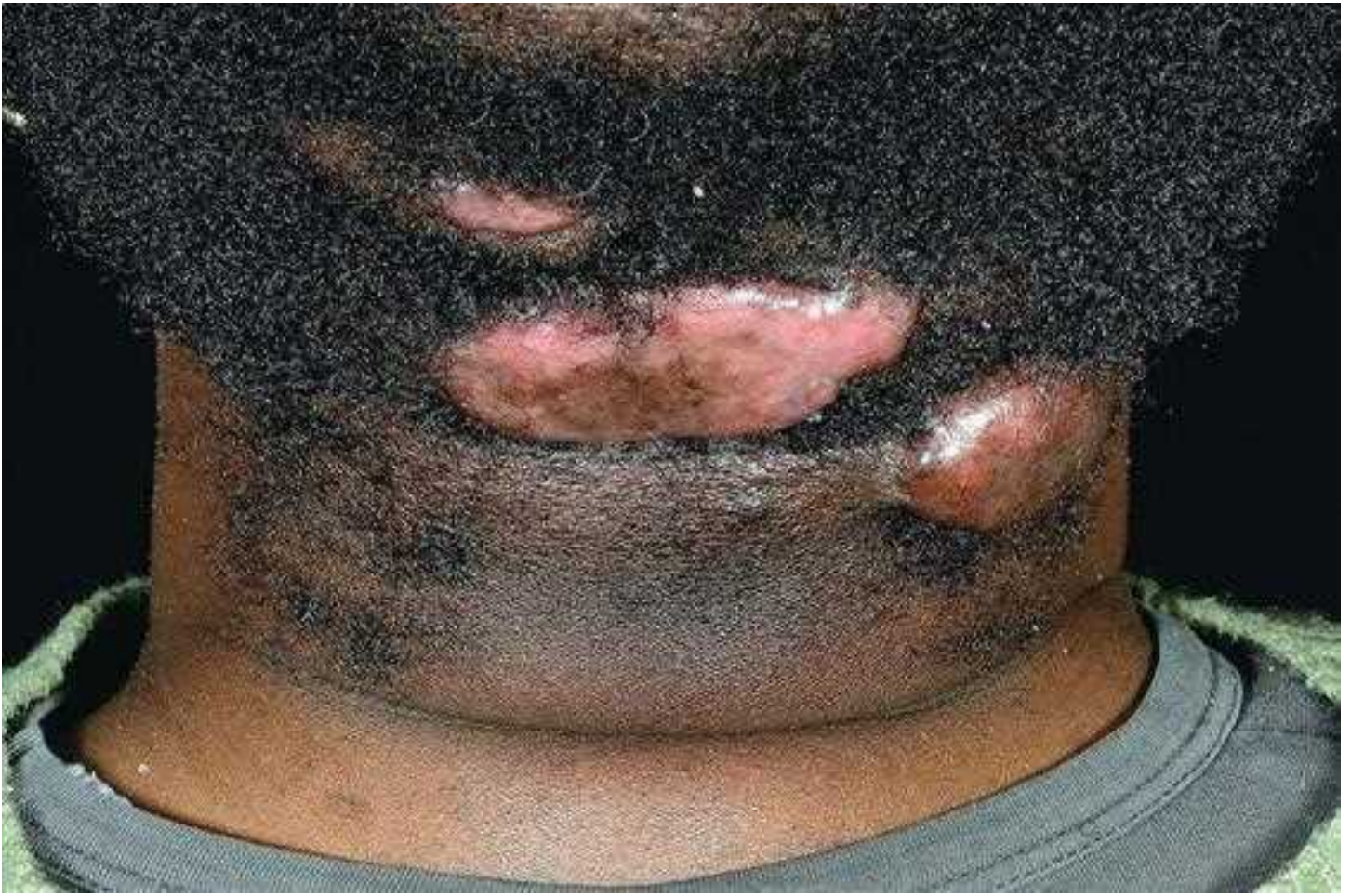

Figure 12.6 Acne keloidalis nuchae hypertrophic scarring affecting posterior neck/scalp.

Box 12.2 Ladder of treatment for rosacea

Avoid exacerbators

- Avoid harsh soaps, strong sunlight, oil-based make-up, and hot showers.
- Avoid alcohol and spicy food.

Topical treatment

- Water-based emollient.
- Metronidazole gel or cream
- Ivermectin 1% cream
- Azelaic acid
- Tacrolimus/pimecrolimus cream.

Systemic treatment

- Tetracycline antibiotics: minocycline 100 mg MR once daily (OD), lymecycline 408 mg OD.
- Low-dose isotretinoin.

Patients with acne often complain of excessive greasiness of the skin, with ‘spots’, ‘blackheads’, or ‘pimples’. These may be associated with inflammatory papules and pustules developing into larger cysts and nodules. Resolving lesions leave post-inflammatory pigment changes and scarring. Scars ([Figure 12.7](#)) may be atrophic and pitted, deep, (‘ice-pick’) ([Figure 12.8](#)), rolling, and boxcar or they may be more hypertrophic or even keloid ([Figure 12.9](#)). Scars may also be hyper/hypopigmented and erythematous.

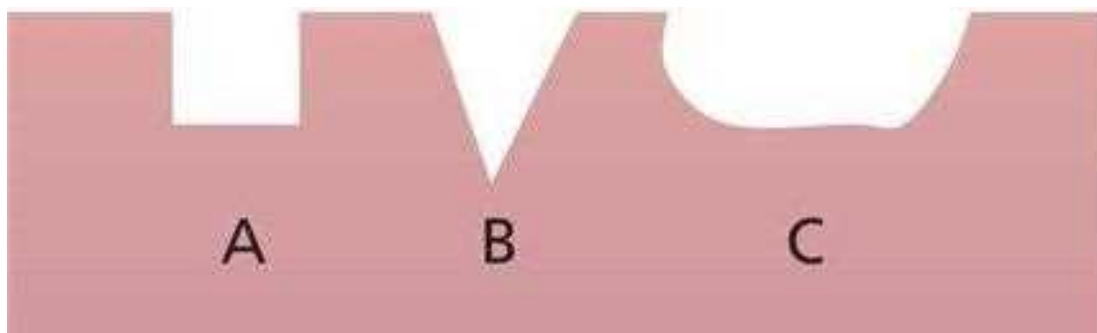


Figure 12.7 Types of atrophic acne scars (A, boxcar; B, ice-pick; C, rolling).

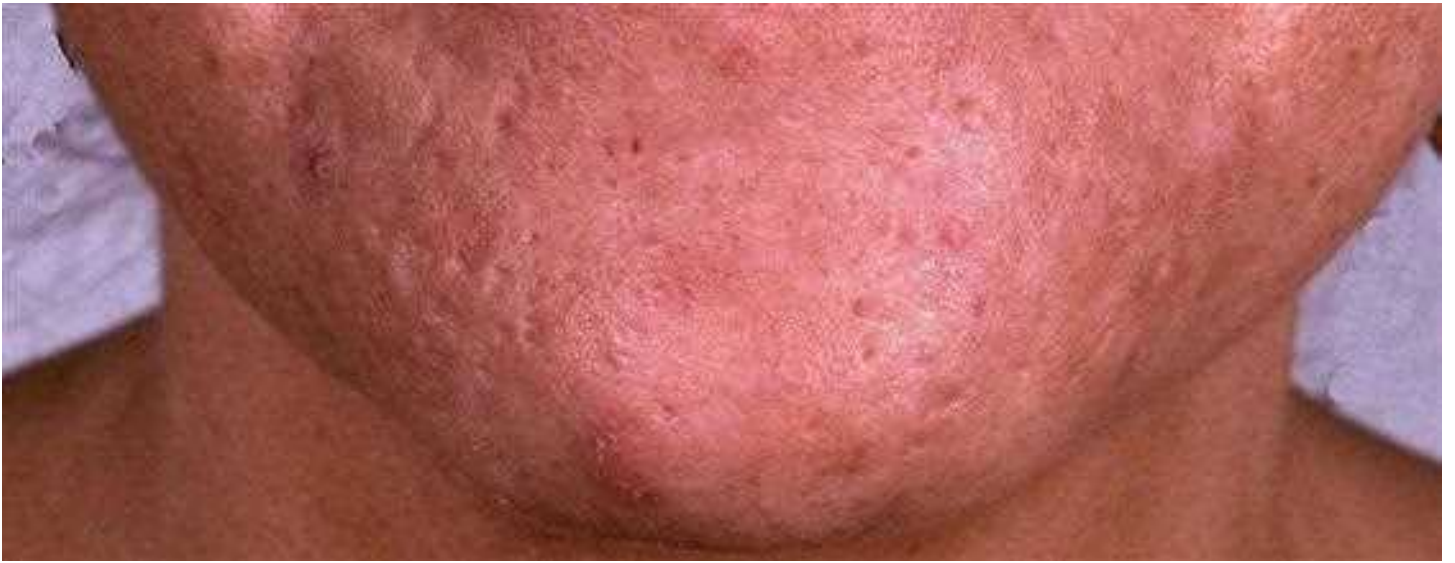
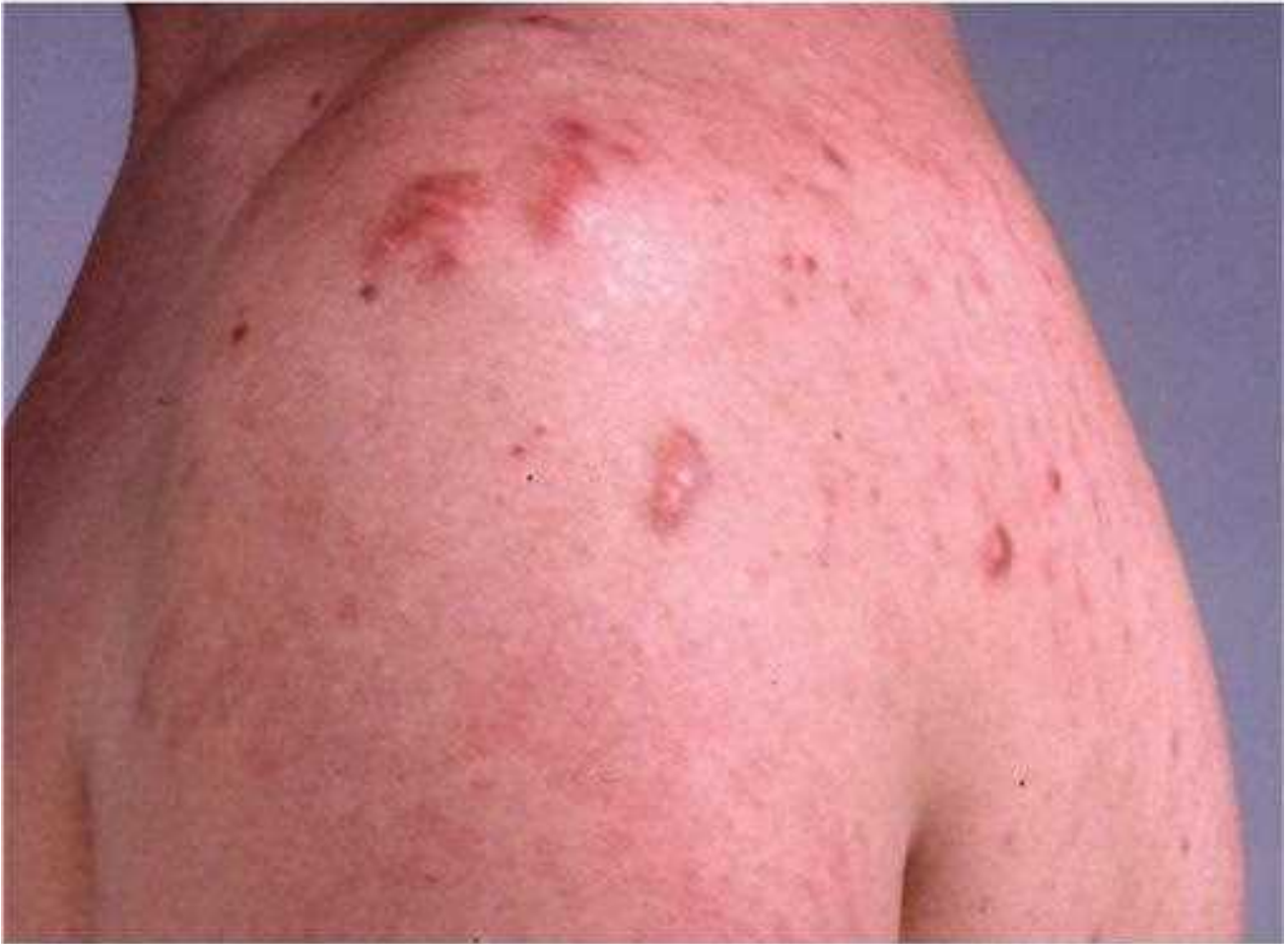
Figure 12.8 'Ice-pick' scars.



(a)



(b)

Figure 12.9 (a) and (b) Keloid scars secondary to acne.

Treatment of acne scarring does depend on the severity and scar type. Generally, more superficial procedures are used to improve the appearance of shallow acne scars (chemical peel, dermabrasion, and fillers) whereas deeper scars may require more aggressive therapy (dermaroller, punch excision, spot fractional resurfacing, fraxel, and intense pulsed light).

Acne excoriée

In this variant of acne, the patient picks at the skin producing disfiguring erosions ([Figure 12.10](#)). The acne itself is usually mild but tends to be persistent as it is often very difficult to help the patient break this habit.

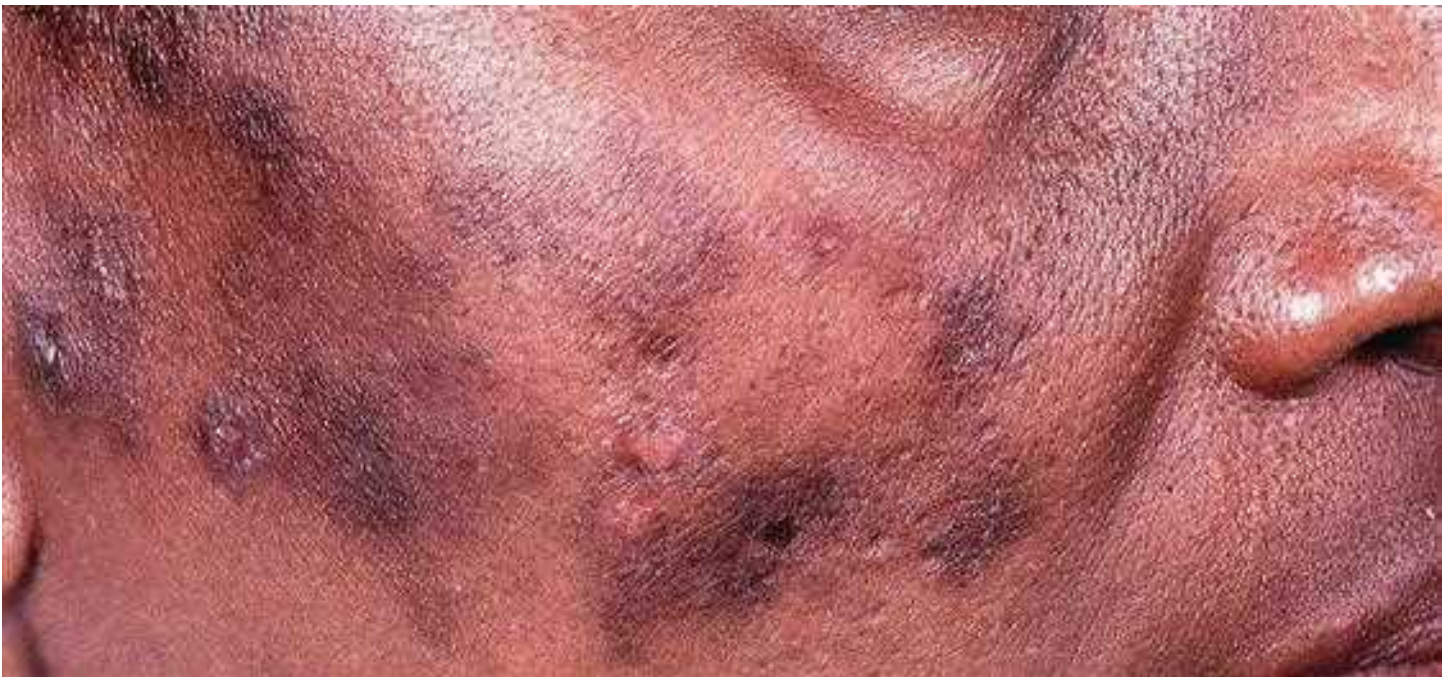

Figure 12.10 Acne excoriée.

Infantile acne

Localised acne lesions occur on the face in the first few months of life. Infantile acne may require topical or systemic therapy as although it will resolve spontaneously it may last up to five years and can cause scarring. There is an association with severe adolescent acne.

Acne conglobata/fulminans

This is a severe form of acne, more common in boys and in tropical climates. There is extensive, nodulocystic acne, and abscess formation affecting particularly the trunk, face, and limbs ([Figure 12.11](#)). Acne fulminans is similarly severe but is associated with systemic symptoms of malaise, fever, and joint pains ([Figure 12.12](#)). It appears to be associated with a hypersensitivity to *P. acnes*. Another variant is pyoderma faciale, which produces erythematous and necrotic lesions and occurs mainly in adult women.

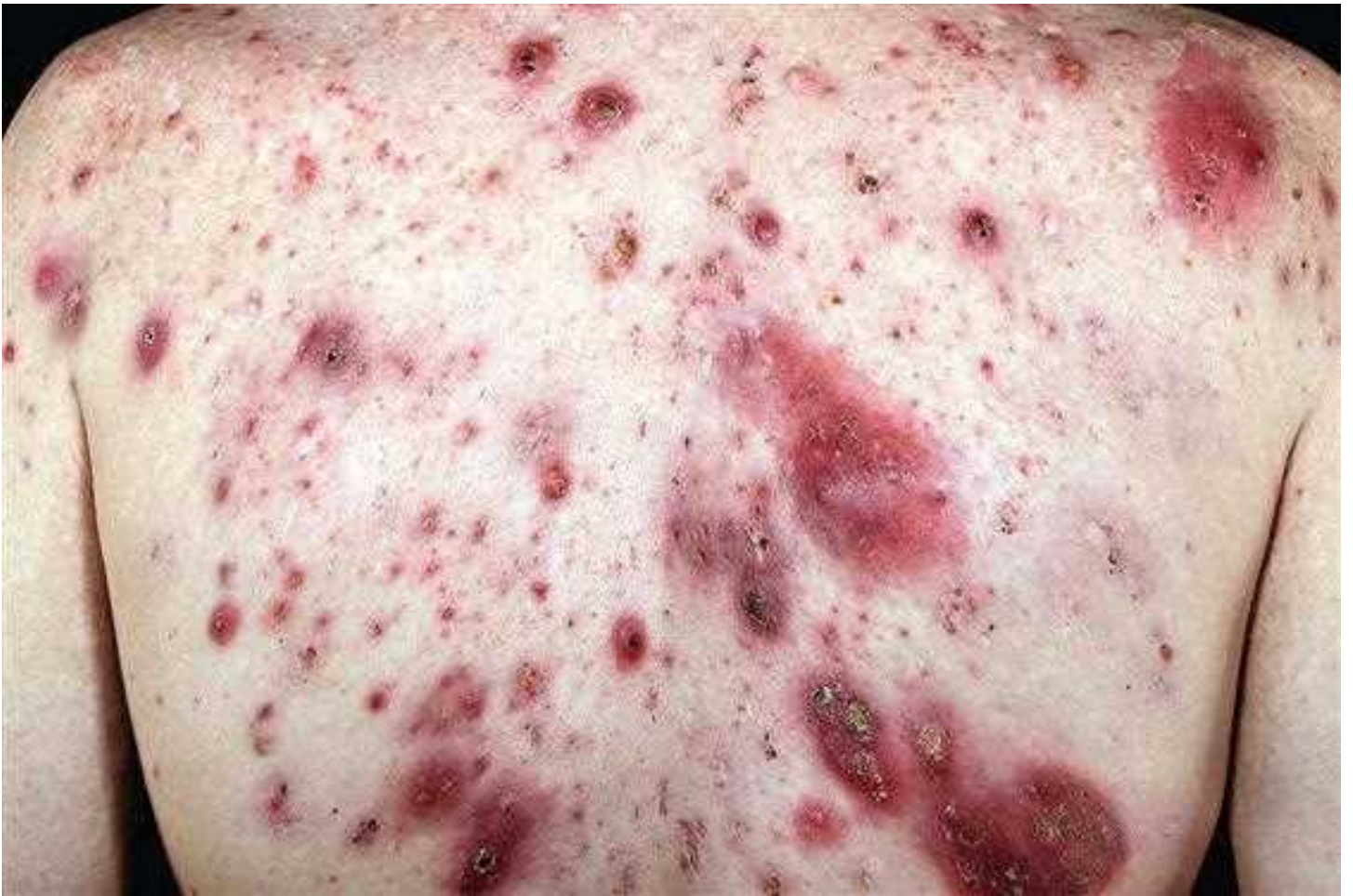

Figure 12.11 Acne conglobate on the back.

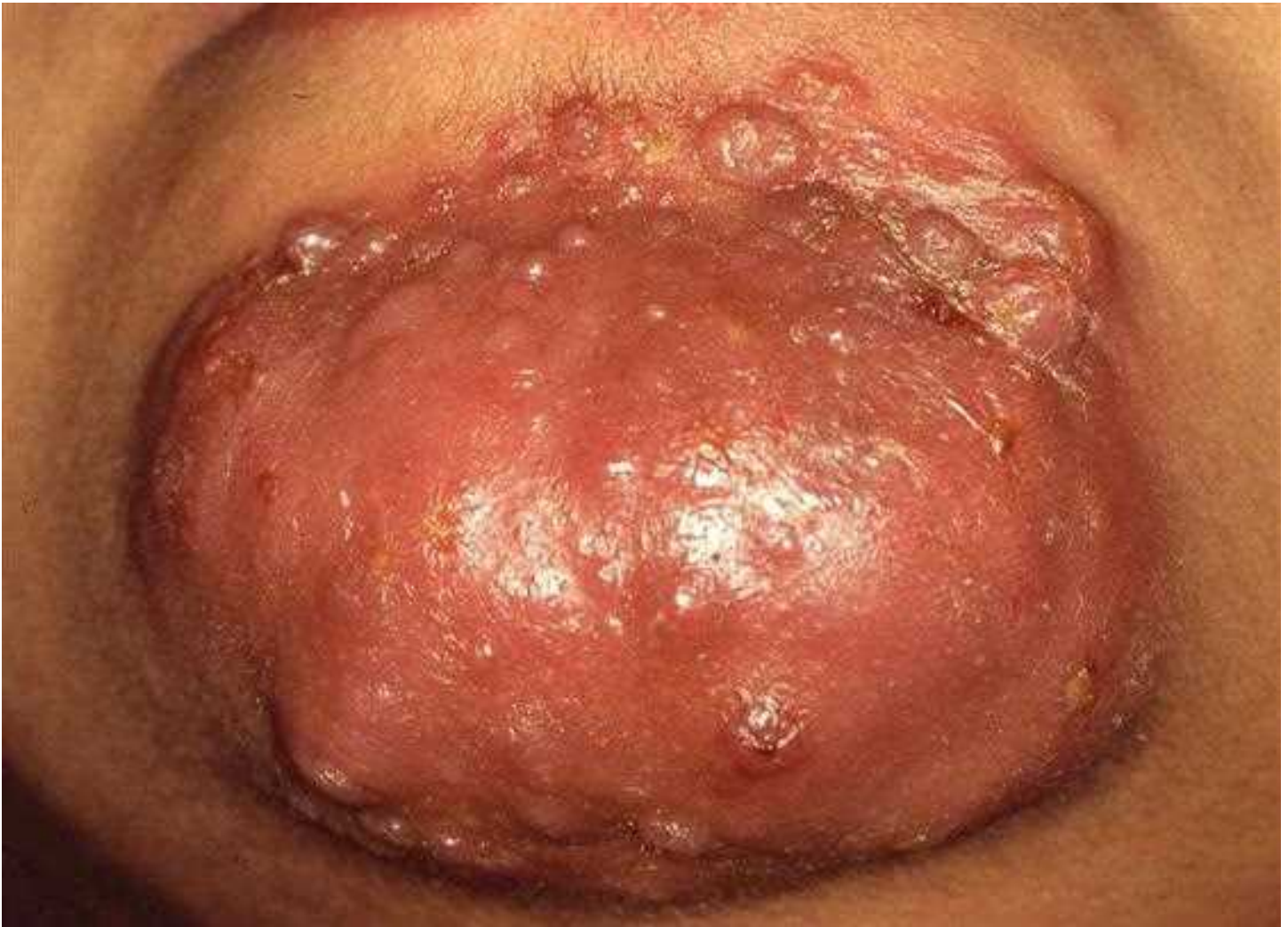

Figure 12.12 Acne fulminans on the chin.

Treatment of acne

Although acne can be very painful and may result in pigment change and scarring, it is the psychological impact of the condition that is often the most debilitating for those affected. In the past some medical practitioners have underestimated the effect acne has on patients' lives and consequently patients were often dismissed with no treatment on the assumption they would 'grow out of it'. Although most acne will settle with time, early intervention for those seeking medical advice results in a significant improvement in their quality of life scores as determined by DLQI (dermatology life quality index, which is a validated questionnaire to assess the impact of skin disease on quality of life). DLQI scores for acne are similar to those for psoriasis. Early intervention can also help reduce the likelihood of permanent scars and post-inflammatory pigment changes ([Table 12.1](#)).

Table 12.1 Treatment of acne.

| Treatment | Comedones | Inflammatory papules/pustules | Mixed picture | Nodulocystic |
|-------------|--|--|--|---|
| First line | Topical retinoid Azelaic acid Salicylic acid | Benzoyl peroxide | Topical retinoid ± topical antibiotic ± benzoyl peroxide Combination of all three | Oral antibiotic + topical retinoid |
| Second line | Physical comedone extraction | Oral antibiotic Oral contraceptive pill (high oestrogen, low androgen, e.g. Yasmin [®]) | Azelaic acid + benzoyl peroxide ± topical antibiotic | Oral isotretinoin A short course of systemic steroids may be given initially with the isotretinoin |
| Third line | | Anti-androgens e.g. co-cypindiol (Dianette [®]) Different oral antibiotic | Hormone therapy Spironolactone Oral antibiotic Oral isotretinoin | Triamcinolone injections to unresponsive lesions |

When choosing a topical formulation to prescribe for a patient with acne it is worth bearing in mind the patient's skin type: for dry/sensitive skin, prescribe creams; for oily skin, use solutions or gels; and for combination skin and hair-bearing sites, lotions are well tolerated.

When treating patients with acne it is important to advise them that they may not see any improvement in their acne for several months and that treatment may need to continue for months or years.

Cleansers

Mild acne may respond well to simple measures such as cleansing the skin with proprietary keratolytics; these dissolve the keratin plug of the comedones. Cleansers need to be used with care as they can cause considerable dryness and scaling of the skin.

Topical treatments

Benzoyl peroxide has been available for the treatment of acne for many years; it has bacteriostatic effects against *P. acnes* and is mildly comedolytic. It is available with or without prescription at concentrations ranging from 1% to 10% in numerous formulations including lotions, creams, gels, and washes. Mild irritant dermatitis may result, particularly if the patient is using additional anti-acne treatments. Bleaching of clothing and bedding may occur.

Salicylic acid promotes desquamation of follicular epithelium and therefore inhibits the

formation of comedones. It is available over the counter at concentrations between 0.5% and 2% in cream and lotion formulations to be used twice daily.

Azelaic acid appears to be effective through its antikeratinising and antibacterial effects. Twenty percent azelaic acid cream is available on prescription and can be used twice daily for up to six months. Mild skin irritation can result in approximately 5% of patients. Azelaic acid can cause depigmentation of the skin and therefore should be used with care.

Topical retinoids are vitamin A derivatives that are anti-inflammatory and comedolytic. Treatments currently available include tretinoin, adapalene, and tazarotene. Topical retinoids are available in cream and gel formulations and are usually applied once daily at night (as they can cause photosensitivity). The main side effect is skin irritation that results in erythema and desquamation; if this occurs patients may be able to tolerate alternate night applications. Tolerance to the irritation usually appears with continued use. Occasionally, an initial acne flare may occur with the use of topical retinoids; this is not, however, an indication to stop treatment as it usually heralds accelerated resolution of the acne.

Topical antibiotics are effective through their bactericidal activity against *P. acnes* and consequent anti-inflammatory effects. The most commonly prescribed antibiotics include erythromycin and clindamycin either alone or in combination with other agents such as zinc or benzoyl peroxide. Preparations are usually applied twice daily. Antibiotic resistance has been reported more commonly with antibiotics used alone than in combination. Also bear in mind that patients shouldn't be prescribed topical and oral antibiotics to treat their acne simultaneously.

Phototherapy with ultraviolet, visible light or even some laser combinations may be effective as alternative therapies in those unresponsive to or unable to tolerate conventional treatments. Photodynamic therapy has been shown to be superior to blue-red light treatment for mild to moderate acne. However, new hand-held blue-light devices (2 J/cm²/day and 29 J/cm²/day) are available for use at home, with reported reduction in acne lesions about 70% at eight weeks after daily treatment to the whole face.

Systemic treatments

Hormone therapies

These include certain types of OCPs that increase sex hormone-binding globulin and consequently reduce free testosterone levels. These are generally OCPs that have higher oestrogen and lower androgen potential (such as Yasmin®). *Antiandrogen* treatment alone can be teratogenic and therefore is given to women in the form of a contraceptive that contains cyproterone acetate with ethinyloestradiol (Dianette®). Long-term safety data are available up to five years. Dianette may also help diminish mild hirsutism.

Spirolactone (androgen receptor blocker) may be used in recalcitrant or recurrent acne usually in women over the age of 25 years with 'hormonal acne' (worse around their menstrual cycle and affecting the lower jawline), often given in conjunction with oral

contraception. Hormone therapies need to be given for at least 3–6 months before benefits are seen. Spironolactone 50–150 (200) mg daily is frequently effective, the dose is usually started at 50 mg daily and built up slowly, once the acne is controlled then low-dose maintenance (25–50 mg daily) can be continued as necessary. There is a small risk of hyperkalaemia and patients should be advised not to consume excessive amounts of bananas/coconut water.

Oral antibiotics

Tetracyclines continue to be the mainstay of treatment in those over the age of 12 years (below this age, they may cause dental hypoplasia and staining of teeth). Once-daily preparations (lymecycline 408 mg, minocycline 100 mg (MR), and doxycycline 100 mg) are more convenient to use than twice-daily preparations (tetracycline and oxytetracycline) and are equally well tolerated. Tetracyclines should be avoided in pregnancy/breastfeeding and children <12 years. Erythromycin and trimethoprim are good alternatives. Treatment benefits may not be seen for the first six to eight weeks of therapy. An adequate treatment course should last approximately 6–12 months, depending on severity and response.

Oral retinoids

Isotretinoin has revolutionised the treatment of severe acne, but it is usually reserved for moderately severe/resistant disease unresponsive to other oral therapies. This is because of its side effect profile including teratogenesis (90% risk of birth defects) and its ability to potentially cause a rise in liver enzymes and lipids. Blood testing may be required before and during therapy as indicated clinically. Female patients of child-bearing age (who are sexually active) will need to use a robust form of contraception while taking isotretinoin and for one month following its cessation. Pregnancy testing is usually undertaken before release of prescriptions for females.

All patients will experience some drying of the lips ([Figure 12.13](#)) and skin ([Figure 12.14](#)), and it is this side effect that may limit the dose of isotretinoin tolerated, at least initially. Mood change and depression have been suggested as a possible side effect of isotretinoin. However, a recent meta-analysis showed that there was no difference in low mood/depression between patients with moderately severe acne and patients with moderately severe acne taking oral isotretinoin. The conclusion at this time therefore is that moderately severe acne leads to low mood/depression. Nonetheless, most patients are advised that if they notice any adverse effects on their mood then they should stop the medication immediately.

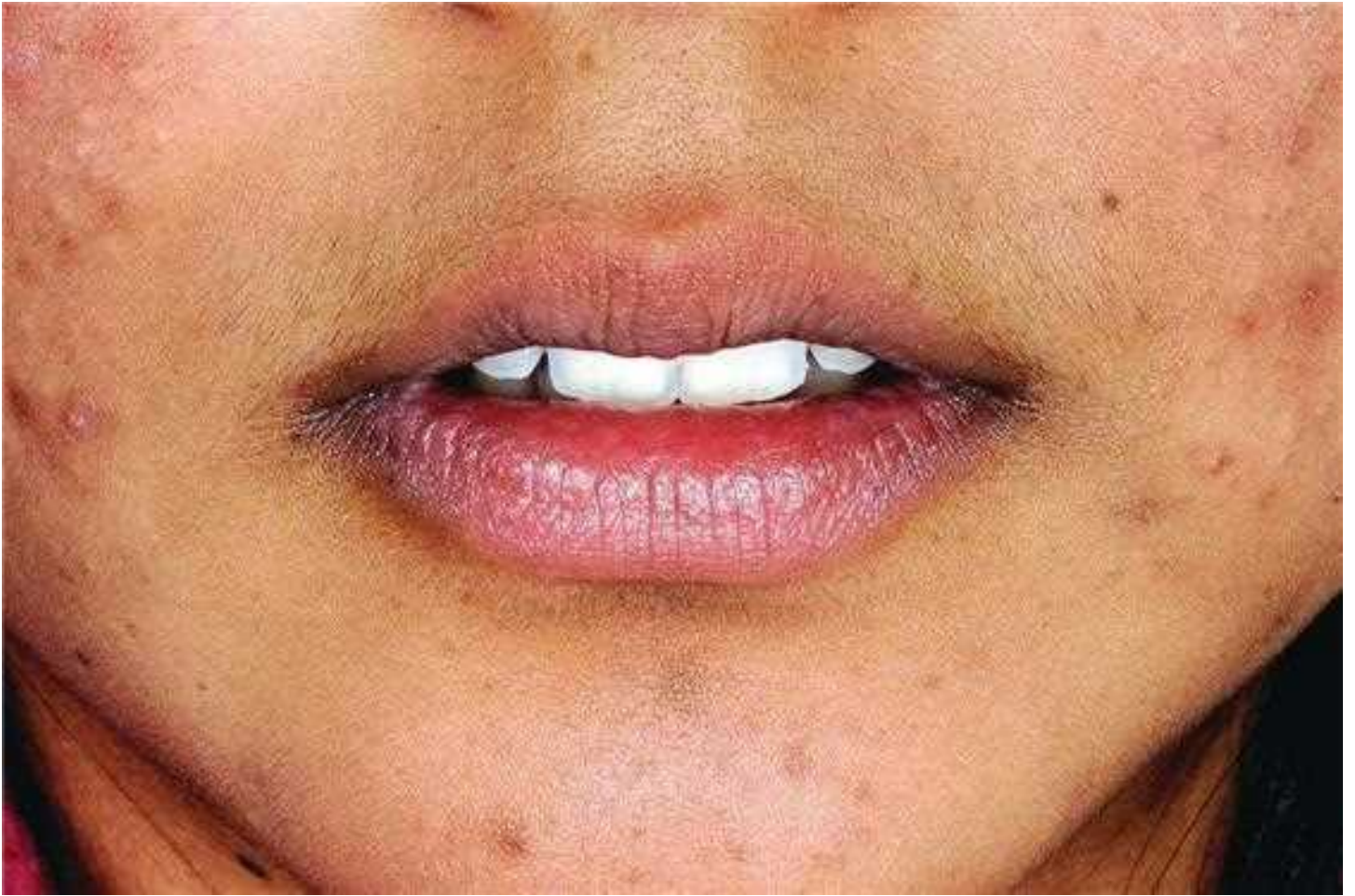


Figure 12.13 Dry lips as a result of oral isotretinoin.

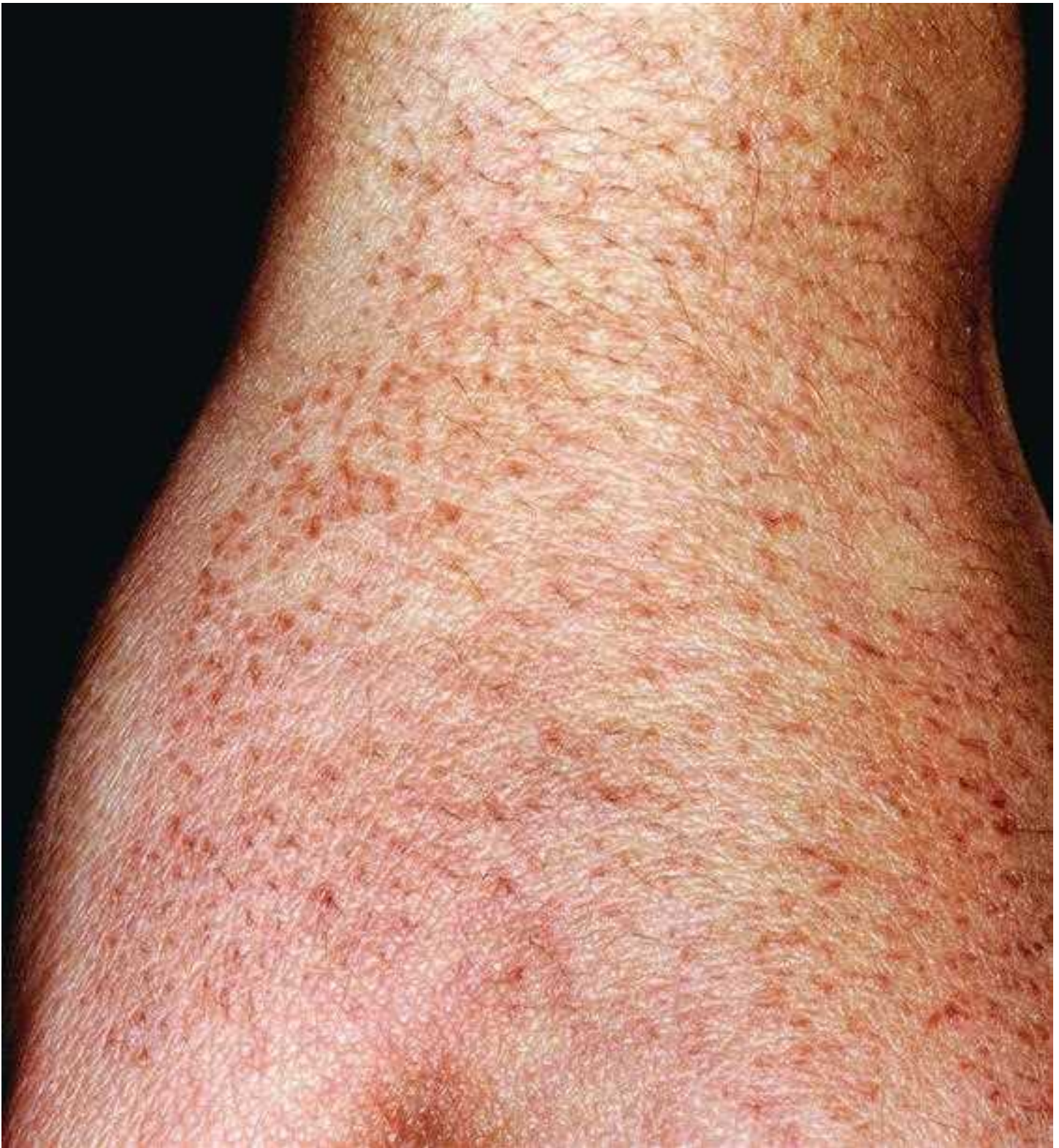

Figure 12.14 Classic xerotic rash on the dorsal hand secondary to taking oral Isotretinoin.

A modern approach to isotretinoin dosing is for patients to start on a low dose for the first one to two months (20–40 mg daily) and then increase to 1 mg/kg/day to minimise initial xerosis. The cumulative target dosage for isotretinoin is 120–150 mg/kg based on studies showing that acne is likely to be ‘cured’ if a full treatment course is taken. Occasionally, patients require a second or even third course of isotretinoin treatment, and some patients

(particularly males with very severe acne/seborrhoea) may require long-term treatment with very low doses such as 20 mg/week.

Residual lesions, keloid scars, cysts, and persistent nodules can be treated by injection with triamcinolone, topical retinoids, chemical dermabrasion, carbon dioxide laser resurfacing and collagen injections. For severe atrophic boxcar and 'ice-pick' scarring punch biopsies can be used to remove scars from the face and pinch grafts applied to the areas (harvested from behind the ear). When healing is complete dermabrasion can then be used for resurfacing with good cosmetic results. For milder scarring chemical peels or dermaroller treatments may be considered.

Rosacea

Rosacea is characterised by facial flushing, persistent erythema, telangiectasia, inflammatory papules, pustules, and oedema ([Figure 12.15](#)); in some patients the changes may be localised to one cheek or the nose ([Figure 12.16](#)). In chronic rosacea the nasal skin can become coarse in texture, eventually resulting in gross thickening and hypertrophy – known as rhinophyma ([Figure 12.17](#)) (from the Greek, 'rhis' nose, 'phyma' growth). Conjunctivitis, blepharitis ([Figure 12.18](#)), and eyelid oedema may be associated. Facial flushing and erythema are frequently exacerbated by heat, exercise, hot food/drinks, spicy food, emotion, alcohol, and sunlight. Eventually, facial erythema can become permanent due to multiple dilated blood vessels – telangiectasia.

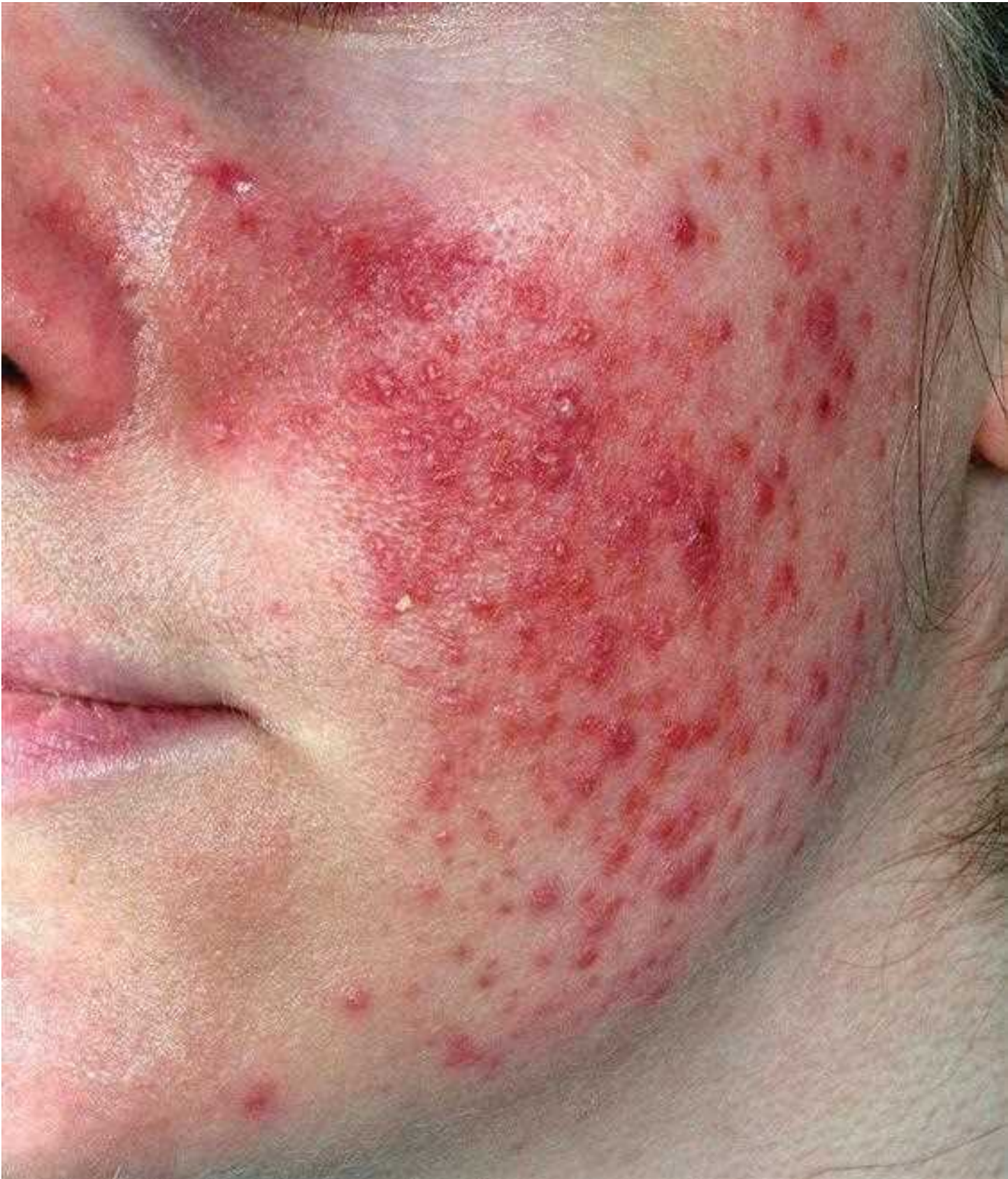

Figure 12.15 Rosacea.

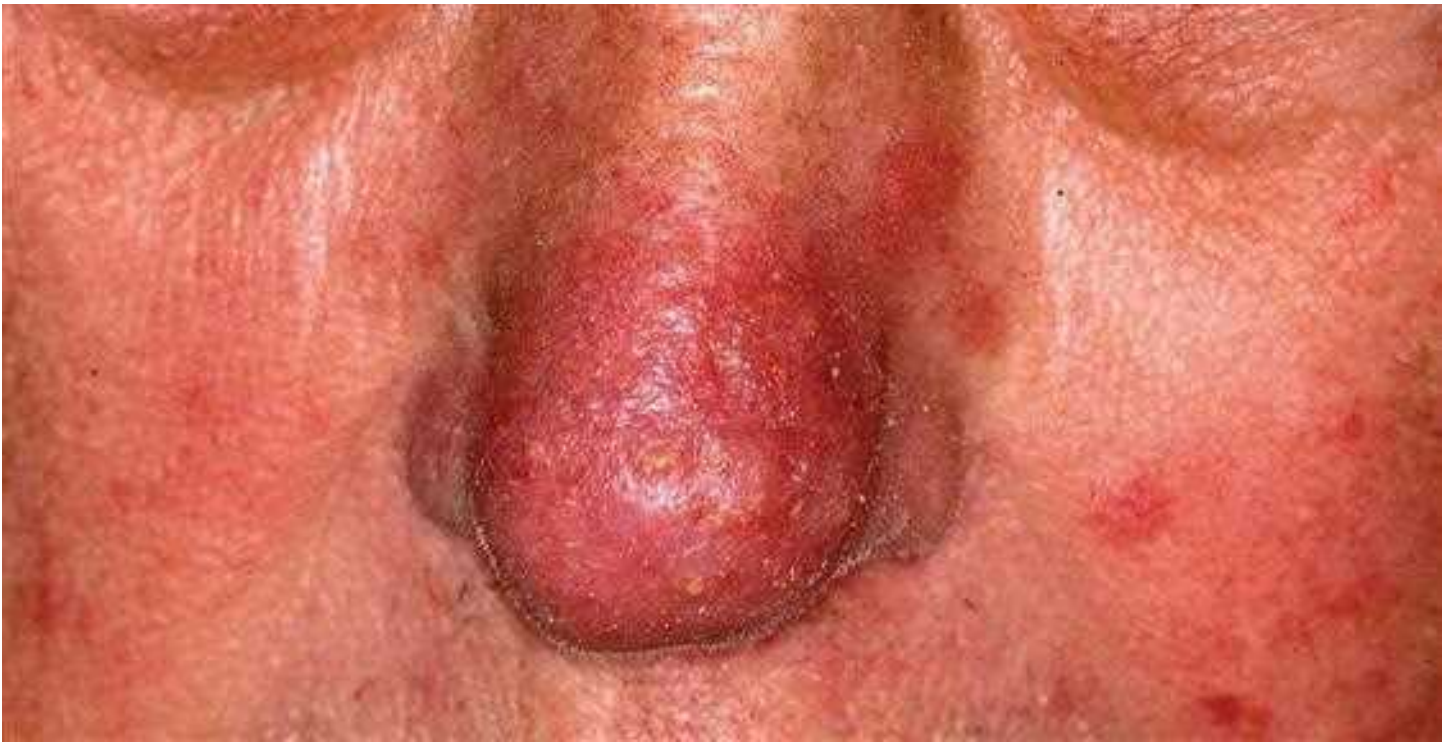

Figure 12.16 Rosacea localised to the nose.

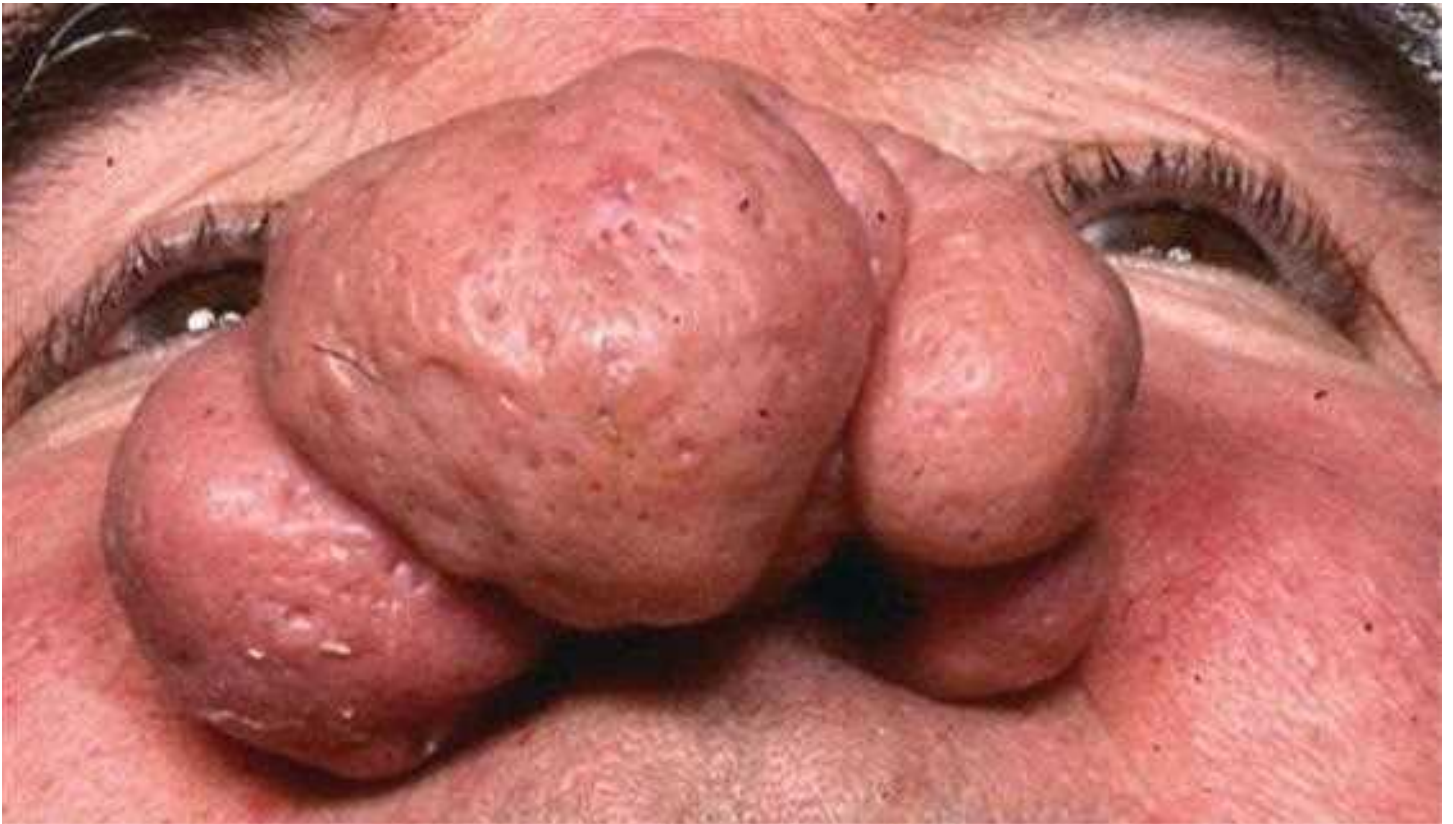

Figure 12.17 Rhinophyma.

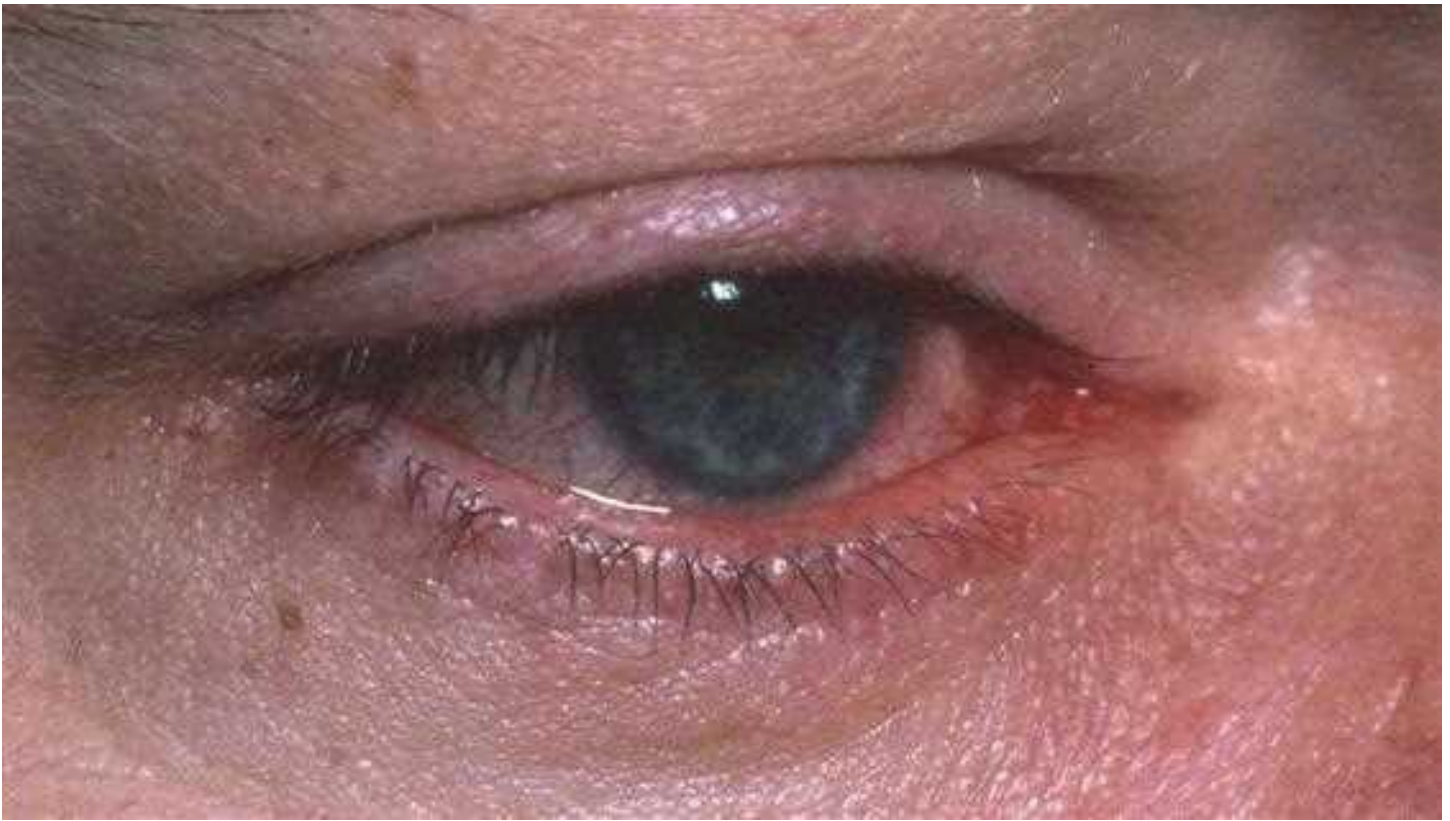

Figure 12.18 Blepharitis.

Differential diagnosis of rosacea

- Acne, in which there are comedones, a wider distribution and improvement with sunlight. (Acne may, however, co-exist with rosacea – hence the older term ‘acne rosacea’.)
- Seborrhoeic eczema, in which there are no pustules and eczematous changes are present, scalp flaking usually present. However, an overlap syndrome of seborrhoeic dermatitis/rosacea is recognised.
- Dermatomyositis, where there may be periorbital and upper eyelid swelling and erythema.
- Lupus erythematosus, which shows light sensitivity, erythema, and scarring, but no pustules.
- Perioral dermatitis, which occurs mainly in women with pustules and erythema around the mouth and chin ([Figure 12.4](#)). This may be precipitated by the use of potent topical steroids; some patients experience a premenstrual exacerbation. Treatment is to stop the topical steroids and prescribe oral tetracyclines.

Management

Trigger factors should be identified and ideally avoided. All patients should be encouraged to

avoid using skin irritants such as soaps or astringent cleansers. There is evidence that regular use of a broad-spectrum sunscreen can be helpful.

Topical metronidazole has been the mainstay of treating mild disease for many years; however, benefits may not be apparent for several months. Gel and cream formulations of metronidazole 0.75–1% should be used twice daily to the affected skin. Topical 1% ivermectin cream (Soolantra®) has been shown on recent trials to be slightly superior to metronidazole. It is thought to reduce the numbers of demodex mites in the skin. Azelaic acid 15% in a gel formulation is now also available for the treatment of rosacea. Topical preparations seem to be more effective at treating the papules and pustules than the erythema and flushing. However, α -adrenoreceptor agonists have recently been evaluated for treatment of diffuse facial erythema because of their ability to reversibly constrict peripheral vasculature with some promising results. Oxymetazoline/xylometazoline (0.05% solutions once daily), both α 1-agonists, and brimonidine tartrate (0.5% gel once daily), α 2-agonist, have been shown to reduce diffuse facial erythema for up to 12 hours; however, larger studies are ongoing and there is the theoretical risk of tachyphylaxis and rebound once the applications are stopped.

Oral antibiotics including tetracycline, doxycycline, erythromycin, and minocycline have all been used to effectively treat rosacea. Patients should be advised that there may be no visible clinical improvement for several weeks, and treatment courses may need to continue for many months.

The use of low-dose oral isotretinoin for between three and nine months has been shown to be effective in those with refractory disease.

Laser ablation of dilated telangiectatic vessels with a pulsed dye laser can be undertaken once the inflammatory component has been treated. An average of three treatments six to eight weeks apart is usually required to achieve significant improvement. Intense pulsed light (IPL) can also be effective at reducing erythema, telangiectasia, and papules. One study delivered IPL every three weeks for an average of seven treatments, which led to 70% of patients reporting reduced flushing and improved skin texture. Carbon dioxide laser or shave removal with a scalpel blade of excess skin from the nose can significantly improve the appearance of rhinophyma.

Hidradenitis suppurativa (HS) is a chronic relapsing disease leading to occlusion of mainly follicular structures in the intertriginous skin of the axillae, groin, inner thighs, buttocks, perineal, and sub-mammary folds. This occlusion leads to follicular rupture and then an inflammatory response, which translates clinically into chronically inflamed and painful nodules/boils/abscesses and draining sinuses that eventually heal with scarring and then relapse at the same/adjacent sites ([Figure 12.19](#)). HS can be painful, distressing, and embarrassing and patients may suffer from depression as a result.

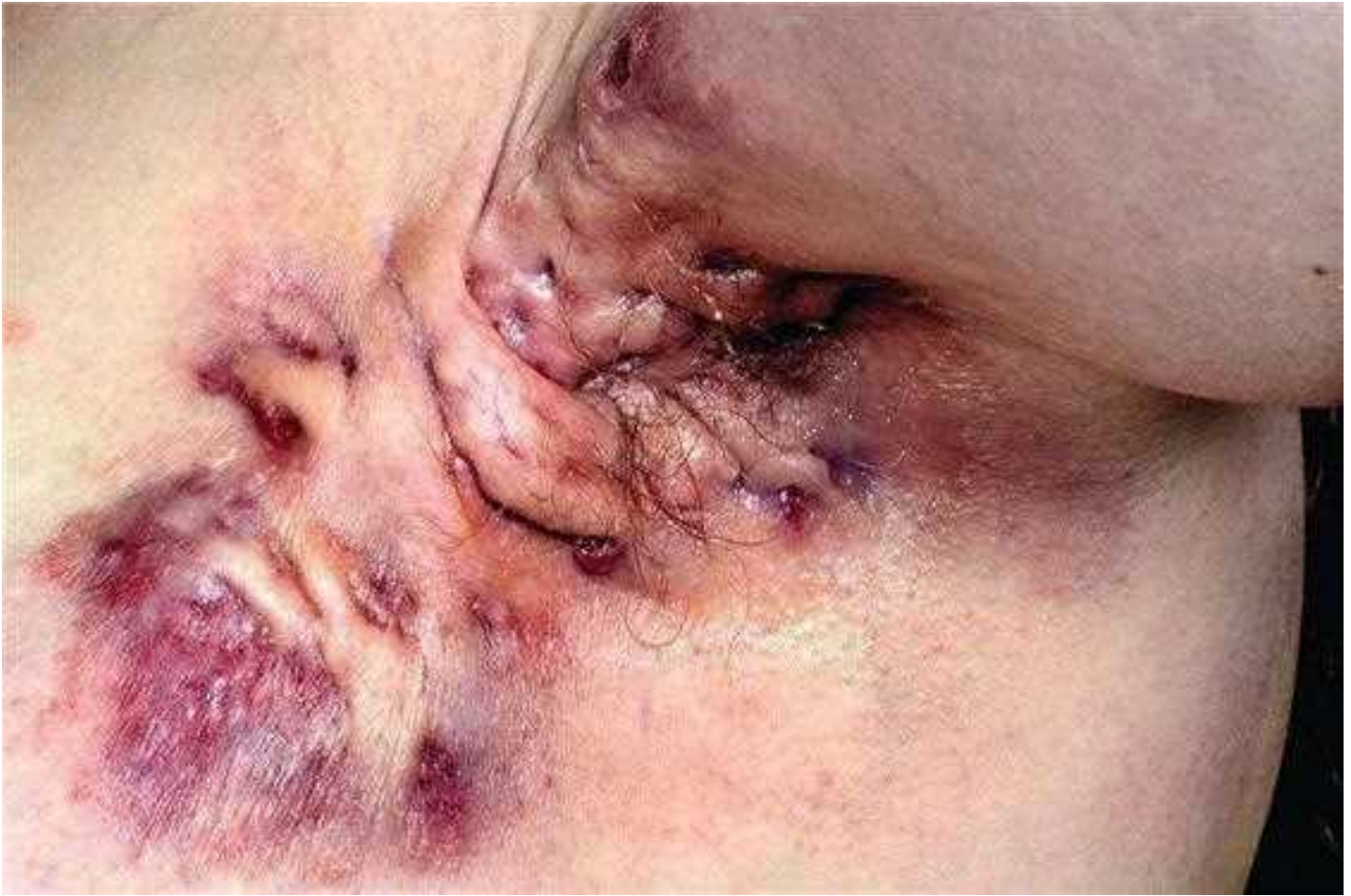

Figure 12.19 Hidradenitis suppurativa (Hurley stage III) affecting the axilla.

The prevalence is around 3% of the population in the developed world, with a female preponderance, more common in smokers, and presentation usually around age 20–30 years. There may be a family history of HS, especially in patients presenting at a younger age. Patients with HS are more likely to be overweight or obese compared to the general population and there seems to be a link with the severity of the HS and higher BMI. The role of bacteria in HS is uncertain but most physicians agree that secondary infection or colonisation of individual lesions leads to exacerbation of the HS and there is some evidence that the skin microbiome may be altered in diseased skin. HS is thought to be associated with acne, follicular occlusion triad, metabolic syndrome, cardiovascular disease, diabetes, and inflammatory bowel disease.

Clinical stages can be useful to determine the best management strategy for each patient. Hurley describes three stages:

- Stage I: single or multiple abscesses without sinus tracts or scarring
- Stage II: recurrent abscesses with sinus tracts and scarring at single and widely separated lesions
- Stage III: diffuse involvement with connecting sinus tracts and abscesses across an entire area.

Management of HS should include patient education, psychological support, and assessment of QoL. Patients should be encouraged to stop smoking and try to manage their weight and try to achieve their ideal BMI. Measures such as avoiding friction to the skin of the affected area are also thought to be helpful, as is daily washing with 4% chlorhexidine (if tolerated). Topical 1% clindamycin solution used twice daily has been shown to be effective in mild (Hurley stage 1) disease. 10 mg/ml triamcinolone injections can be used to settle painful inflammatory nodules, punch de-roofing of new lesions can relieve pressure and allow active drainage. Chemical peels containing keratolytics have been shown in limited trials to help settle mild/moderate lesions more rapidly. However, there may be mild peeling of the surrounding skin. Dapsone 50–200 mg daily can be used to treat Hurley class I/II.

Oral tetracycline antibiotics are frequently used for Hurley class II/III, doxycycline 100 mg/200 mg daily can be taken, or tetracycline, lymecycline, or minocycline. For more severe disease combination rifampicin and clindamycin (300 mg twice daily) can be prescribed for 12 weeks. Other combinations include rifampicin, moxifloxacin plus metronidazole. Oral retinoids can be used (acitretin, isotretinoin) but these medications are teratogenic, which may limit the numbers of patients who are suitable to take them. Oral antiandrogens have also been shown to be of some benefit to women suffering from HS, including cyproterone acetate, spironolactone, and finasteride. Metformin may also be helpful.

Biological agents including infliximab, adalimumab, and ustekinumab have been used with some success in patients with Hurley stage III.

Surgical treatment with punch de-roofing can be used for individual stubborn lesions or sinus tracts has been shown to be beneficial however for more extensive disease wide local excision (possibly with grafting) may be the only option to give the patient long-lasting symptomatic relief.

Further reading

Danby, F.W. (2015). *Acne: Causes and Practical Management*. Chichester: Wiley-Blackwell.

Zouboulis, C.C., Katsambas, A.D., and Kligman, A.M. (2014). *Pathogenesis and Treatment of Acne and Rosacea*. New York: Springer.

CHAPTER 13

Bacterial Infections

Rachael Morris-Jones

Guy's and St Thomas' NHS Foundation Trust, London, UK

OVERVIEW

- Damage to the epidermis/dermis results in reduced barrier function, which enables bacteria to invade the skin.
- Cutaneous bacterial infections produce signs of acute inflammation: erythema, swelling/oedema, heat/warmth and pain/discomfort.
- Localised superficial skin infections can be managed with antiseptic washes and topical antibiotics.
- Systemic antibiotics are needed for widespread, deep, and persistent bacterial skin infections.
- Clinical signs of bacterial infections include folliculitis, boils/abscesses, blistering, crusting, erosions, ulcers, and cellulitis.
- Mycobacterial skin infections most commonly arise from implantation/trauma and are usually localised in immunocompetent patients.
- Atypical mycobacteria can result in localised suppurative lesions, persistent granulomas, and sporotrichoid spread via lymphatics.




Introduction




Intact skin forms a highly effective barrier against invading pathogenic bacteria. Many micro-organisms come into contact with the skin and some live there as part of the normal skin flora, but they rarely cause disease. Normal skin flora consists of coagulase-negative *Staphylococcus*, *Corynebacterium*, diphtheroids and α -haemolytic *Streptococci* in the epidermis, and *Propionibacterium* in the pilosebaceous unit. Normal flora competes with invading pathogenic micro-organisms, thereby acting as a 'biological shield'. However, if the host immune system weakens or there is a change in the micro-environment (such as an underlying skin disease), this may allow such bacteria to become pathogenic.


Bacterial skin infections may be acquired from the external environment (from plants, soil, fomites, animals, or other humans) by implantation, direct contact, aerosols, or water-borne transmission. Bacteria most frequently invade a traumatic break in the skin, follicular openings, and mucous membranes where host barriers are more vulnerable.

Bacterial skin infections vary from the very minor to life-threatening and overwhelming. It is often tempting to assume a single organism is responsible for any particular cutaneous infection, but often the contrary is true. Synergistic microbial invasion is frequently present in cutaneous wounds. See [Table 13.1](#) for a summary of the common patterns of bacterial infection in the skin.

Table 13.1 Common patterns of bacterial infection in the skin.

| Infection | Clinical photograph | Clinical presentation | Organisms | Management |
|------------------|---|--|--|---|
| Infected eczema |  | Background inflammatory atopic dermatitis with excoriations and marked crusting and exudate | <i>Staphylococcus aureus</i> <i>Streptococcus pyogenes</i> | Antiseptic wash Topical antibiotic/steroid combination cream. Treat eczema thoroughly to restore the barrier function. Oral flucloxacillin/erythromycin may be needed |
| Impetigo |  | Mainly children, especially face and limbs. Highly contagious. Yellow crusted lesions surrounded by normal skin | <i>S. aureus</i> <i>S. pyogenes</i> | Antiseptic wash Topical antibiotic Oral flucloxacillin or erythromycin |
| Bullous impetigo |  | Children and adults. Face, limbs and flexures affected. Erythema with bullae which rupture leaving superficial erosions and crusts | <i>S. aureus</i> with exfoliative toxins A/B (may become generalised – staphylococcal scalded skin syndrome) | Oral flucloxacillin or erythromycin |
| | | | | |

| | | | | |
|-------------------------------|---|---|--|--|
| <p>Boils (abscesses)</p> |  | <p>Tender, inflamed indurated nodules with central pus, may be single or multiple. If recurrent and recalcitrant, consider toxin-producing bacteria</p> | <p><i>S. aureus</i> Consider Panton Valentine Leukocidin Toxin-producing <i>S. aureus</i></p> | <p>Antiseptic wash Oral flucloxacillin or erythromycin If PVL-positive, give nasal bactroban and consider giving clindamycin plus rifampicin for four to six weeks</p> |
| <p>Bacterial folliculitis</p> |  | <p>Hair-bearing sites, particularly legs, beard area, and scalp. May result from shaving damage to skin. In recurrent infections look for <i>S. aureus</i> nasal carriage</p> | <p><i>S. aureus</i> <i>Pseudomonas aeruginosa</i> (differential diagnosis <i>Malassezia</i> spp)</p> | <p>Topical antibiotics Acetic acid cream EarCalm[®] for <i>P. aeruginosa</i> Oral flucloxacillin or erythromycin Avoid shaving if possible</p> |
| <p>Ecthyma</p> |  | <p>Children, the elderly/debilitated. Mainly on the legs. Initially small bullae with necrotic dry adherent crust and underlying ulceration</p> | <p><i>S. pyogenes</i> <i>S. aureus</i></p> | <p>Antiseptic wash Oral penicillin V or erythromycin</p> |

| | | | | |
|------------|---|---|---|---|
| | | Heal slowly with scarring | | |
| Erysipelas |  | Face or lower leg. Portal of entry is broken skin (trauma and tinea pedis). Well-demarcated bright erythema | <i>S. pyogenes</i> (group A <i>Strep.</i> but also B, C, G) <i>S. aureus</i> (less common) | Intravenous benzyl penicillin or erythromycin |

Clinical presentation

Patients with a bacterial skin infection may recall an episode of trauma to the skin such as a graze, laceration, insect bite or implantation of foreign material, or they may have a history of ongoing skin disease. A more detailed history may reveal contact with potentially contaminated water via bathing, animal contact, travel abroad or other family members/close contacts similarly affected. However, many patients will not have any obvious source from the history alone.

Acute bacterial infections in the skin generally produce some or all of the classical characteristics of acute inflammation: erythema, swelling/oedema, heat/warmth, and pain/discomfort. Patients may develop systemic symptoms such as fever and malaise. Many cutaneous infections start as an isolated lesion that then spreads to involve the surrounding previously uninvolved skin. Multiple lesions may be present in a follicular distribution.

Bacterial investigations

Taking bacterial swabs for microscopy and culture can be very useful in managing patients with probable cutaneous infections. Microbiological testing can identify the bacterial species, antibiotic resistance/sensitivity patterns and bacterial toxin production. This information allows medical practitioners to make informed decisions regarding patient management. Lesional skin and carrier sites can be swabbed. Nasal swabs may identify *Staphylococcus aureus* carriers who can suffer from recurrent infections because of bacterial shedding from the nose. When taking swabs they should be moistened in the transport media before contact with the skin and each surface of the swab should be rotated on the infected skin surface. Methicillin-resistant *Staphylococcus aureus* (MRSA) may be community- or hospital-acquired. Panton Valentine Leukocidin (PVL) is a toxin produced by some strains of *S. aureus* which cause the bacteria to be highly virulent and highly transmissible. Patients with PVL-positive *S. aureus* often present with multiple/recurrent boils not settling with short

courses of flucloxacillin ([Figure 13.1](#)). Often other family members are similarly affected. Request PVL testing when sending swabs to microbiology. In severe skin infections or when you suspect mycobacterial infections, take a skin biopsy for culture and polymerase chain reaction (PCR).

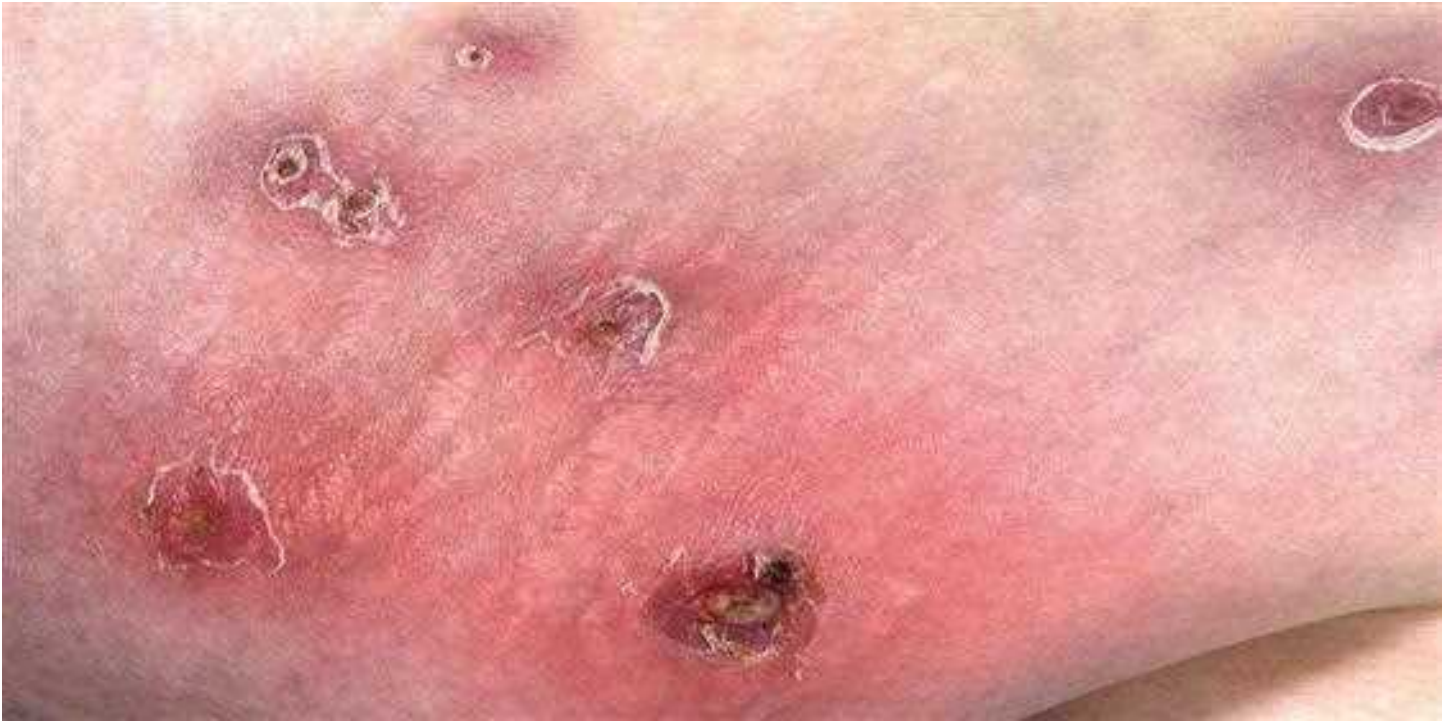

Figure 13.1 Multiple abscesses due to PVL *Staphylococcus aureus* infection.

General approach to management

The treatment approach depends on the extent and the severity of the cutaneous infection.

Antiseptic skin washes or creams containing chlorhexidine hydrochloride can be helpful in removing superficial bacteria, and many of the novel formulations are suitable for use in patients with sensitive skin such as atopic eczema. Potassium permanganate soaks or diluted bleach can be very effective at treating any cutaneous infections, particularly on the lower legs, which may be submersed in a solution. Alternatives include Betadine[®], iodine, and eosin solution. The skin should be washed daily whenever possible to remove adherent infected crusts.

Topical antibiotics applied twice daily can be used alone to treat mild localised infections. Fusidic acid, mupirocin, neomycin, polymyxins, retapamulin, silver sulfadiazine, and metronidazole are all available in topical formulations. Prolonged exposure to topical antibiotics leads to the selection of resistant organisms and rarely contact dermatitis (neomycin most commonly). Topical antibiotic/steroid combinations are useful in treating infection and inflammation simultaneously.

Systemic antibiotics are needed for more extensive cutaneous bacterial infections.

Staphylococcal cover is provided by flucloxacillin, erythromycin, clarithromycin, azithromycin, co-fluampicil (contains flucloxacillin and ampicillin), co-amoxiclav, clindamycin, fusidic acid, ciprofloxacin, cefuroxime, dicloxacillin, cloxacillin, linezolid, pristinamycin, and roxithromycin. For MRSA, use vancomycin, nafcillin, daptomycin, or tigecycline.

Streptococcal cover is provided by penicillin V, amoxicillin, flucloxacillin, erythromycin, clarithromycin, azithromycin, coamoxiclav, cefuroxime, ceftazidime, clindamycin, pristinamycin, roxithromycin, vancomycin, and levofloxacin.

Superficial infections

Impetigo is usually caused by *S. aureus* or *Streptococcus pyogenes* and is highly contagious between close contacts and develops rapidly into clusters of pustules and vesicles which break down into the classic golden crusts ([Figure 13.2](#)). Bullous lesions are more likely to occur with *Staphylococcal* infections which produce epidermolytic toxins A/B ([Figure 13.3](#)). *Streptococcus* is more likely to be the causative organism if there is associated regional lymphadenopathy, but many patients will have a mixed infection. Several family members may be affected simultaneously, particularly in conditions of poor hygiene in hot humid climates. There may be an association with minor trauma such as insect bites. Secondary impetigo may co-exist with any pre-existing skin lesion. Topical treatment includes antiseptic washes, fusidic acid, mupirocin, and polymyxins. Oral antibiotics most frequently used include flucloxacillin and erythromycin.

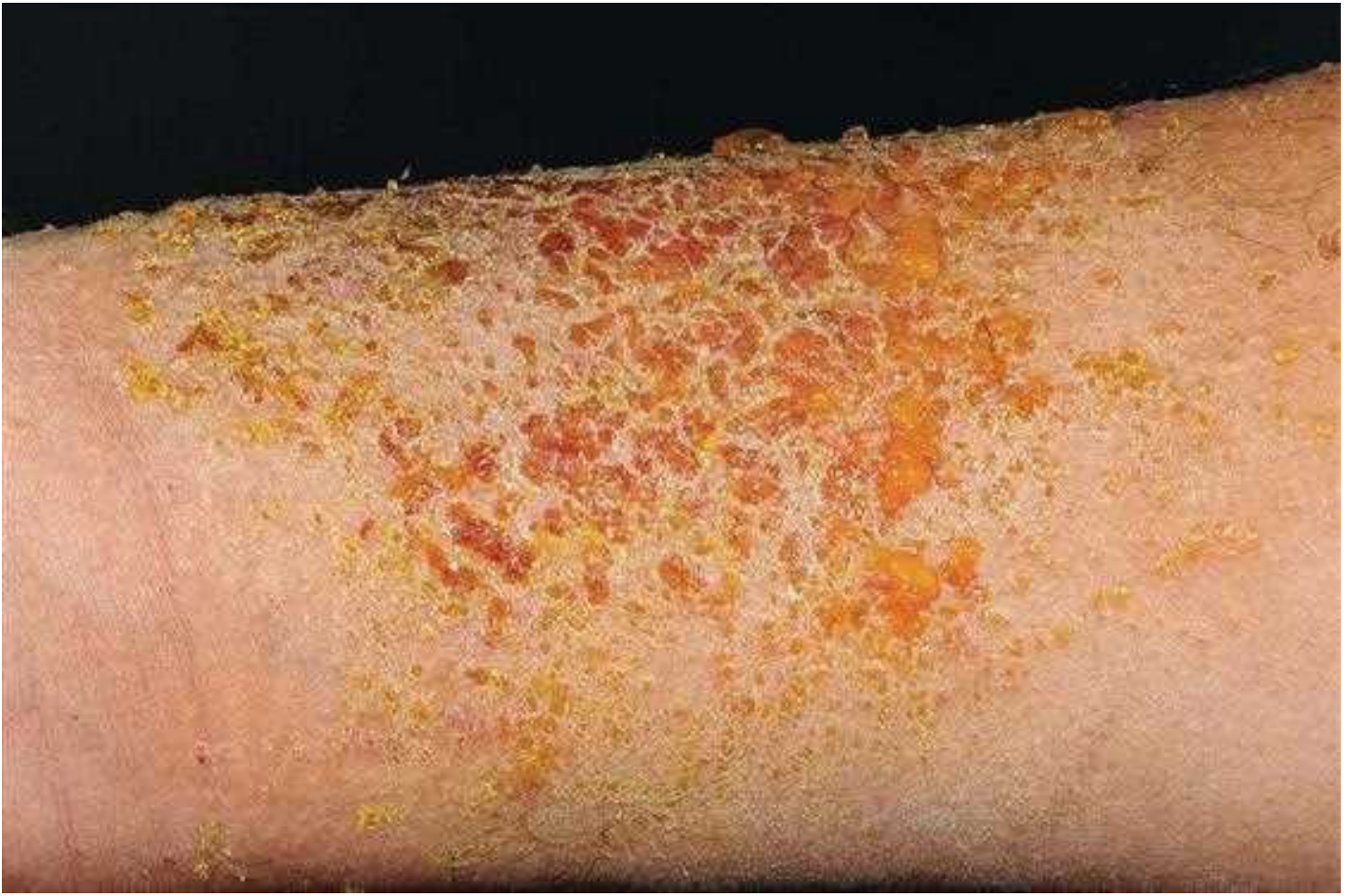

Figure 13.2 Impetigo with golden crusting.

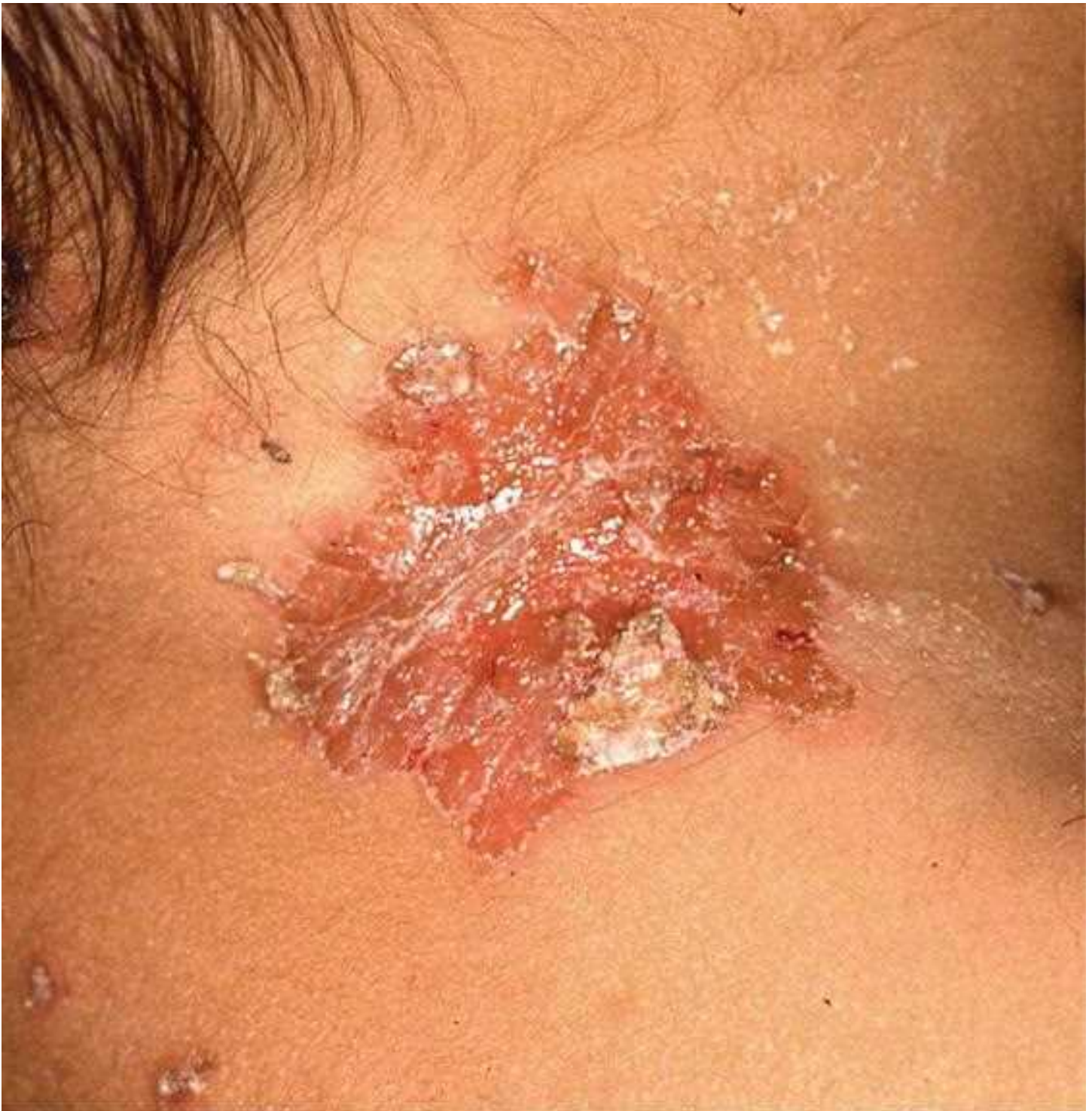

Figure 13.3 Impetigo with bullae and erosions.

Bacterial folliculitis is defined as infection in the hair follicles which may be superficial and/or deep and is usually caused by *S. aureus*. The majority of those affected by folliculitis never seek medical advice as these infections are frequently mild and self-limiting. Clinically, there is a pustule and erythema around the follicular orifice which may be associated with mild irritation ([Figure 13.4](#)). Folliculitis may result from minor trauma such as hair removal by shaving or waxing.

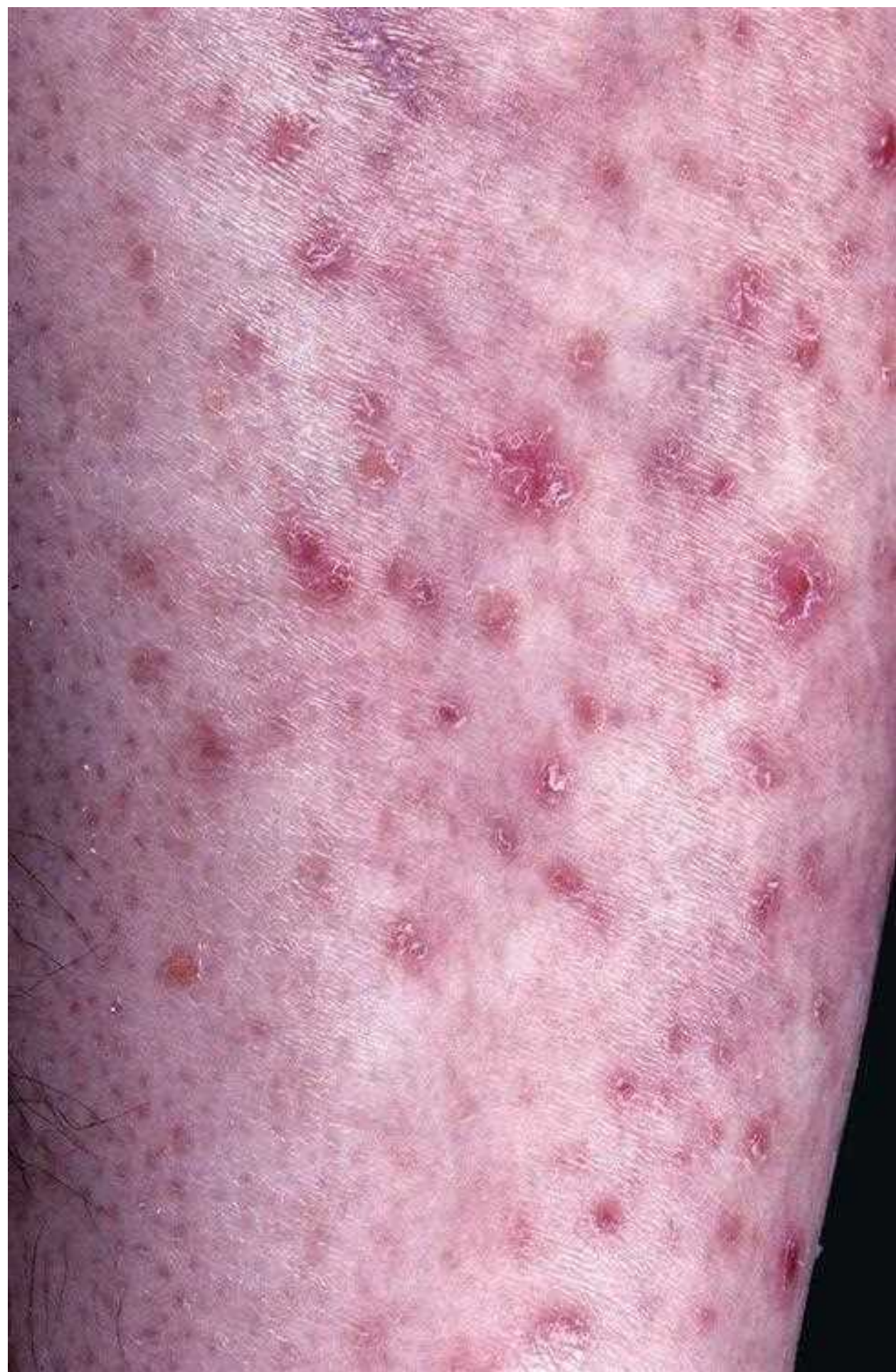

Figure 13.4 Bacterial folliculitis.

Deeper follicular infections are characterised by abscess formation (which is termed *sycosis barbae* in the beard area), boils, and furunculosis. When several furuncles coalesce they form a carbuncle. Hot-tub folliculitis caused by *Pseudomonas aeruginosa* appears within two days of exposure to contaminated water or water accessories (such as loofahs and wetsuits).

Pseudofolliculitis has a similar clinical appearance but this is caused by occlusion of the follicular openings by heavy emollients rather than bacterial infection. In pseudofolliculitis the lesions are all at the same stage of development and are clinically very monomorphic, and the pustules are sterile ([Figure 13.5](#)). *Pseudofolliculitis barbae* ('razor bumps') in the beard area has a similar clinical appearance but is in fact a perifolliculitis. KRT75 gene defect has recently been identified to be associated with a predisposition to pseudofolliculitis barbae, this gene is on the long arm of chromosome 12 and is associated with the synthesis of type II keratin. Clinically the condition is most common in young black men affecting their face/neck. Coarse curly hair punctures the skin adjacent to the hair follicle (from which it has arisen), resulting in a foreign body reaction with inflammation which can become chronic and lead to scarring.

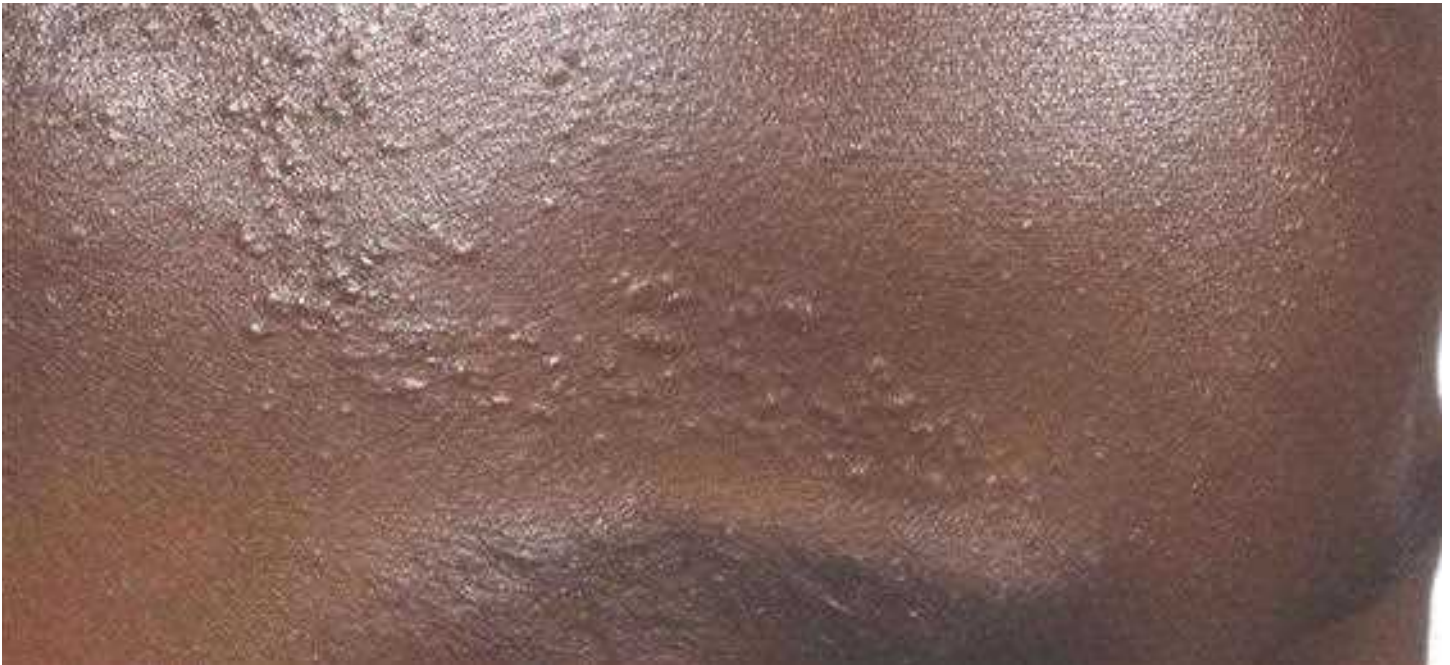

Figure 13.5 Pseudofolliculitis: forehead.

In the occipital area of the scalp *acne keloidalis nuchae* results from folliculitis and perifolliculitis with resultant alopecia and keloid scarring from chronic inflammation. A similar appearance is seen in the beard area ([Figure 13.6](#)). The exact mechanism of causation is unknown, but most theories suggest that trauma from hair removal practices and chronic inflammation in a predisposed individual (usually black men) leads eventually to hypertrophic/keloid scarring.

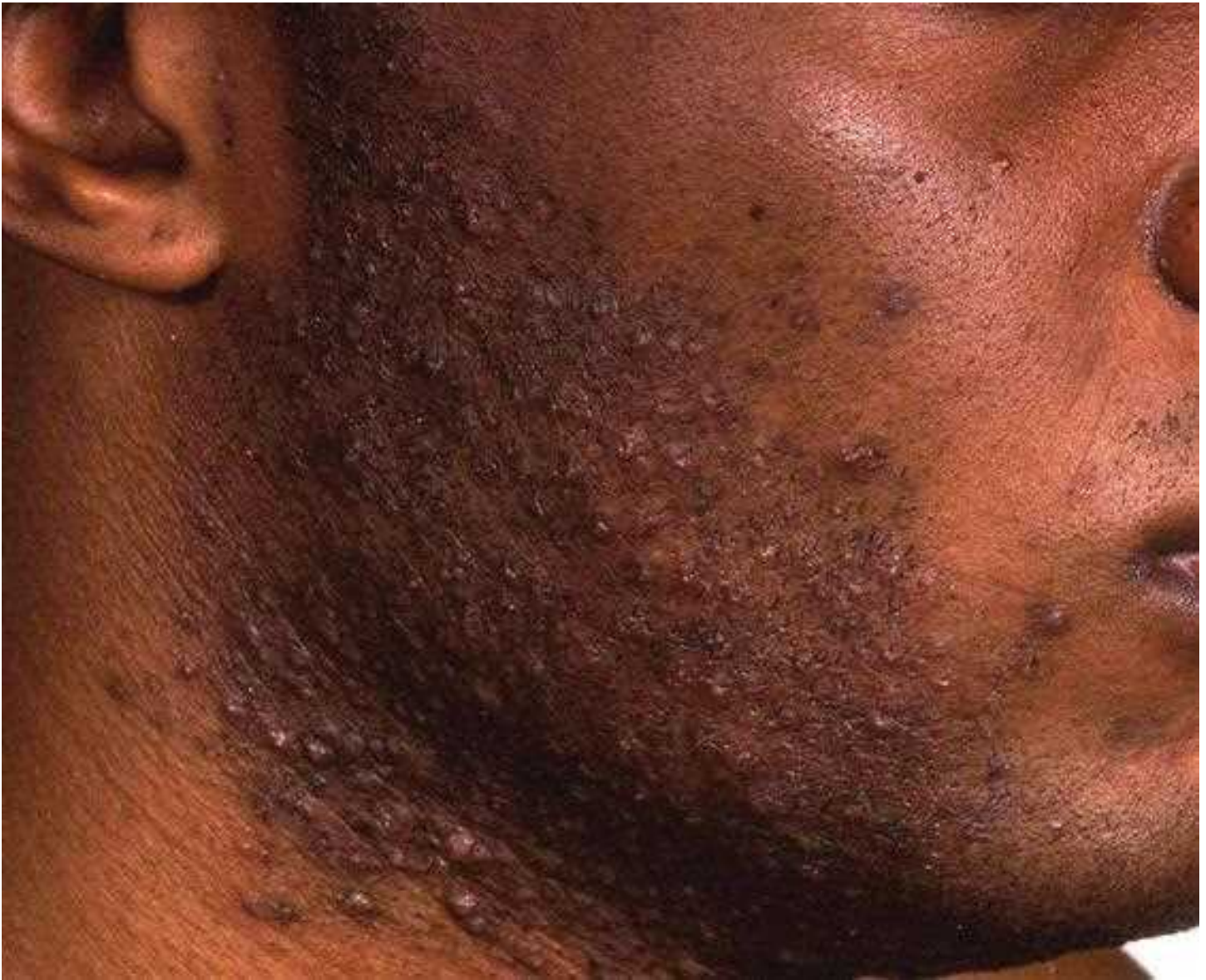

Figure 13.6 Acne keloidalis.

Erythrasma usually affects the flexural skin sites, particularly the axilla and groin. There is superficial scaling and mild inflammation, often with a reddish-brown discolouration ([Figure 13.7](#)). It is frequently mistaken for a fungal infection so isolation of the causative bacterium *Corynebacterium minutissimum* from skin scraping can be useful. Under Wood's ultraviolet light the affected skin (bacteria) fluoresces pink. First-line treatment is usually oral erythromycin (250 mg QDS for 7–14 days), but if topical treatment is preferred, then clotrimazole, miconazole, fusidic acid, or neomycin can be effective.

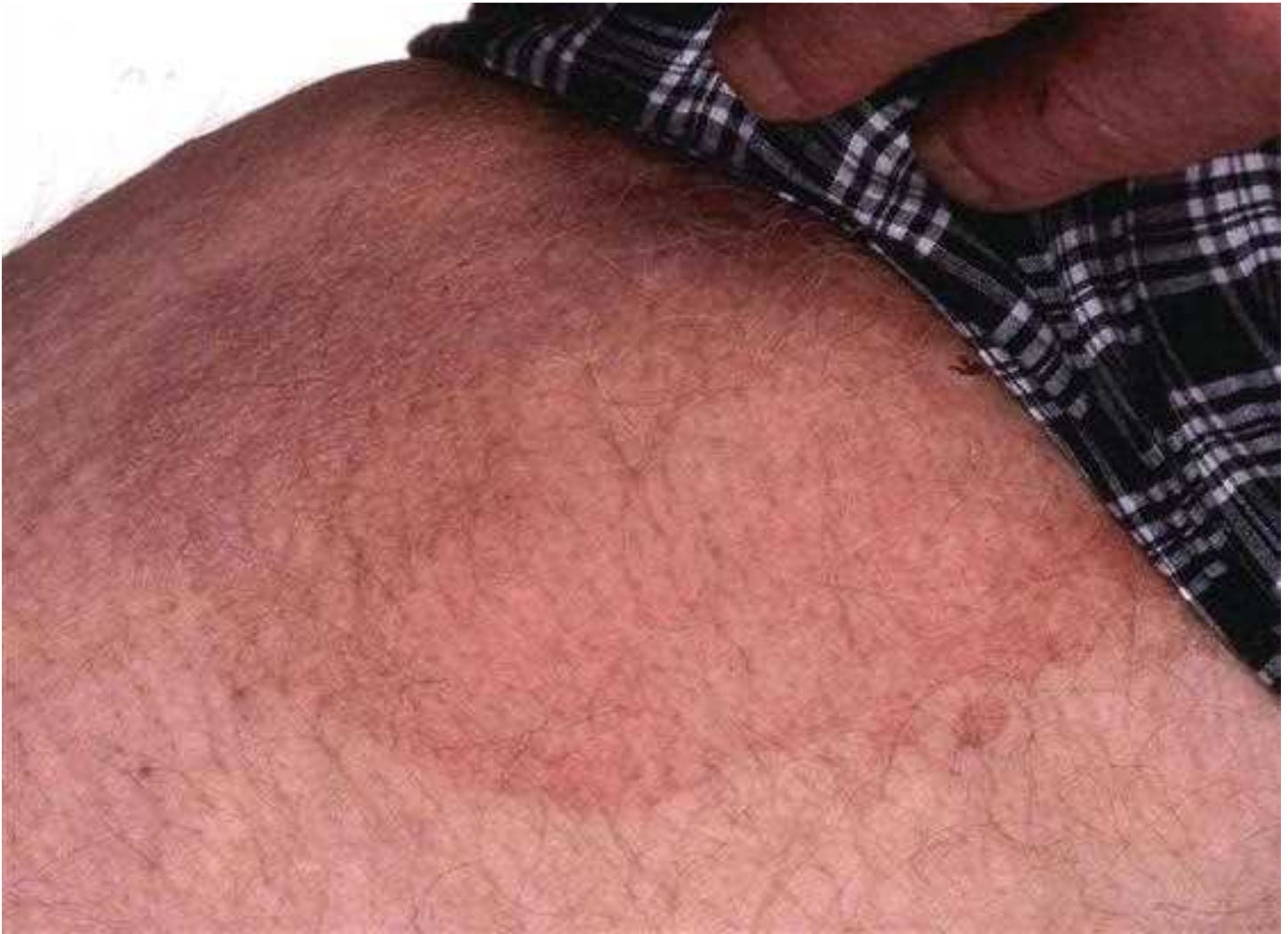

Figure 13.7 Erythrasma.

Deeper infections

Erysipelas is caused by a *Streptococcus* infection. Over approximately 48 hours the inflammation spreads across the skin with a characteristic red, shiny, raised, spreading plaque with a well-demarcated edge ([Figure 13.8](#)). Occasionally, blistering may occur at the active edge; patients may have fever and malaise. The face (*S. pyogenes* from throat colonisation) and lower legs are most frequently affected. Differential diagnosis of erysipelas on the face includes contact dermatitis, photodermatitis, rosacea, systemic lupus erythematosus, and fifth disease or 'slapped cheek'.

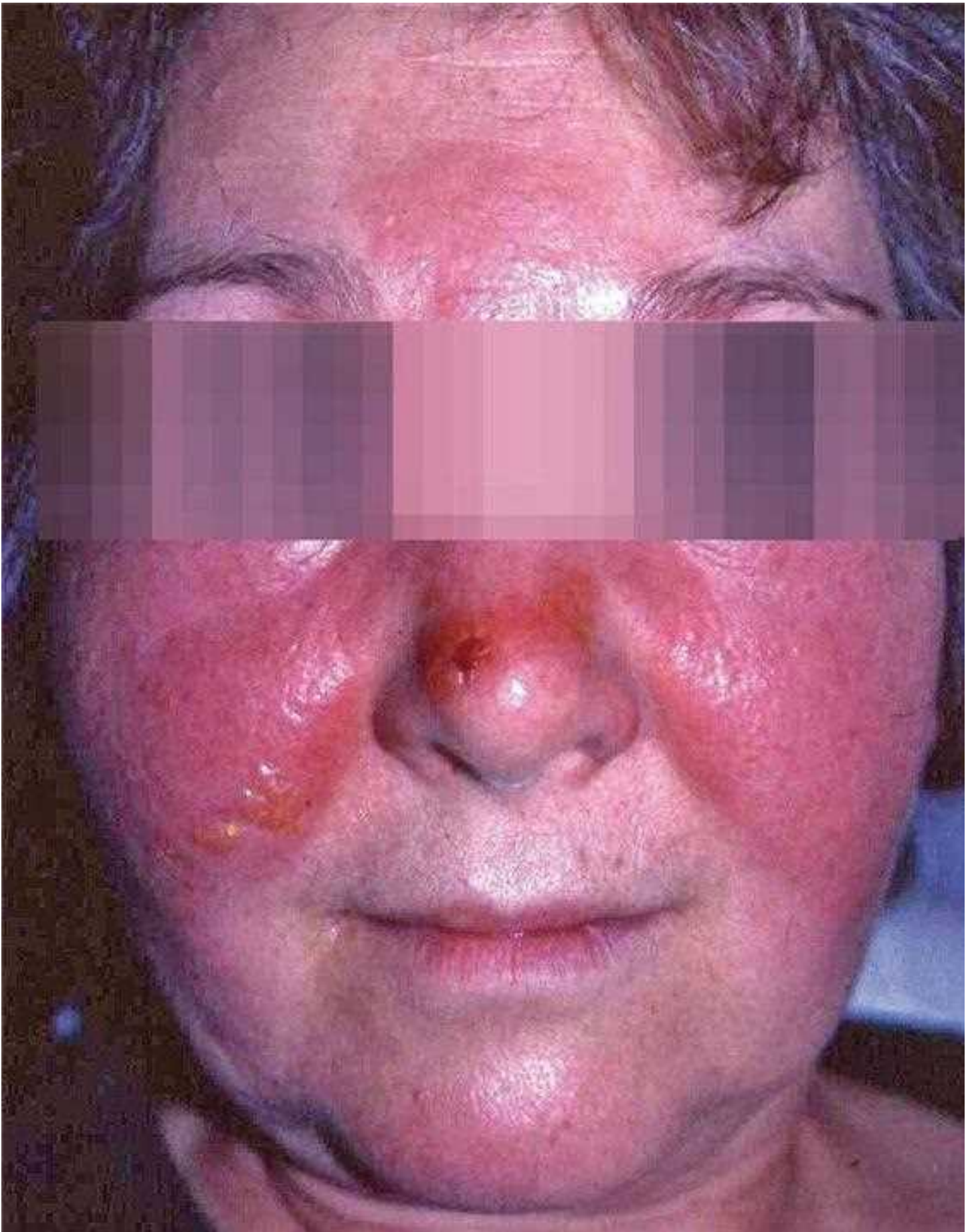

Figure 13.8 Erysipelas.

The *Streptococcus* organisms invade the dermis and penetrate the lymphatics, which clinically is well demarcated; this contrasts with the clinical appearance of cellulitis (infection in the deeper layers), which is poorly demarcated. There may be a minor skin laceration or tinea pedis (look between the toes) as the portal of entry. If the infection is severe, treat with intravenous benzylpenicillin or orally with amoxicillin, roxithromycin, or pristinamycin for one to two weeks. Recurrent attacks are reported in 20% of patients with predisposing conditions; these individuals may require long-term secondary prophylaxis (penicillin V 500 mg daily, or macrolide in penicillin-sensitive patients).

Erysipelas is the local manifestation of a group A streptococcal infection; however, the same organism through the production of toxins or superantigens can cause other skin lesions such as (i) the rash of scarlet fever; (ii) erythema nodosum; (iii) guttate psoriasis; and (iv) an acute generalised vasculitis.

Cellulitis develops more slowly than erysipelas and has a poorly defined margin and marked regional lymphadenopathy. Patients may have fever and general malaise. In cellulitis, *S. pyogenes* (also groups C/G β -haemolytic *Streptococcus*, or rarely *S. aureus*) organisms invade deeper tissues than those found in erysipelas. The lower leg is the most common site affected ([Figure 13.9](#)). Patients may have underlying dermatoses such as a diabetic foot ulcer, tinea pedis, or stasis dermatitis which act as a portal of entry for the streptococcal bacteria. In severe infections intravenous benzylpenicillin may be needed for up to a week as the infection settles slowly.

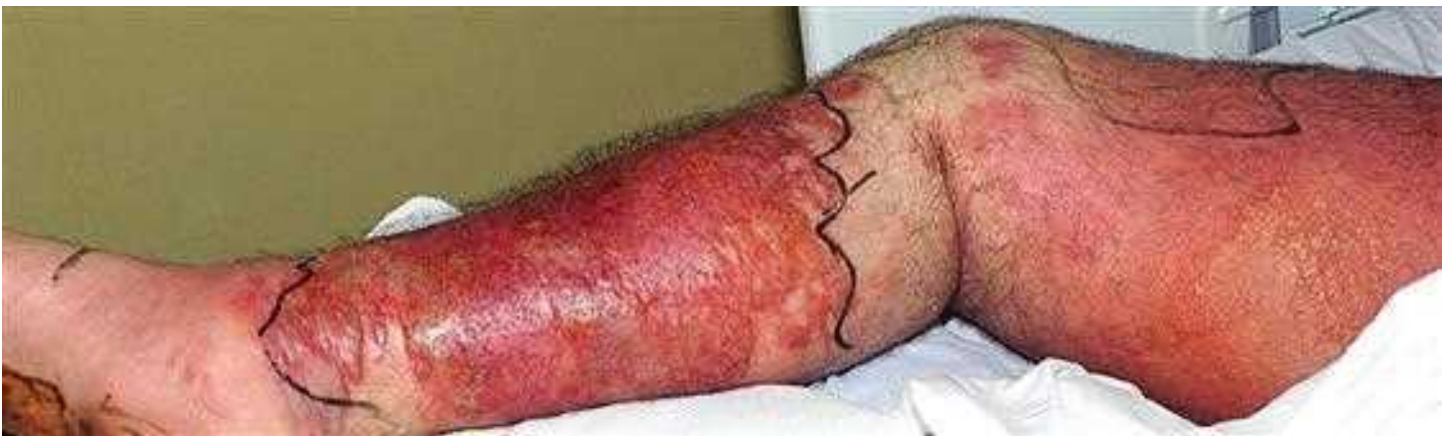

Figure 13.9 Extending cellulitis.

Necrotising fasciitis is characterised by dusky purplish erythema associated with extensive life-threatening necrosis of the deeper tissue because of rapidly progressive mixed (anaerobic and aerobic bacteria) infection of the deep fascia leading to gas formation in the subcutaneous tissues. Patients often have a history of recent trauma or surgery. There is usually severe pain initially at the site followed by anaesthesia. Patients appear very unwell – often disproportionately to the clinical picture. Dusky erythema associated with necrosis at the skin surface is usually the tip of the iceberg, with much more extensive life-threatening necrosis of the deeper tissues. Urgent surgical debridement and broad-spectrum antibiotics are indicated.

Staphylococcus scalded skin syndrome (SSSS) is caused by strains of *S. aureus* that produce exfoliative toxins A/B resulting in intraepidermal splitting (the target is desmoglein 1 which is responsible for keratinocyte adhesion). A localised form of the disease is called *bullous impetigo*. The clinical presentation in children below five years of age is usually with conjunctivitis, otitis media, or a nasopharyngeal infection, with fever, malaise, and red tender skin. Generalised cutaneous erythema is followed by widespread superficial blistering (Nikolsky sign positive) and exfoliation which may be most striking in the flexures ([Figure 13.10](#)). Although most children are not unwell, there is a 4% mortality rate for generalised SSSS. Give systemic antibiotics to treat *Staphylococcus*. If patients fail to respond, then consider treating for MRSA which has a higher mortality rate.

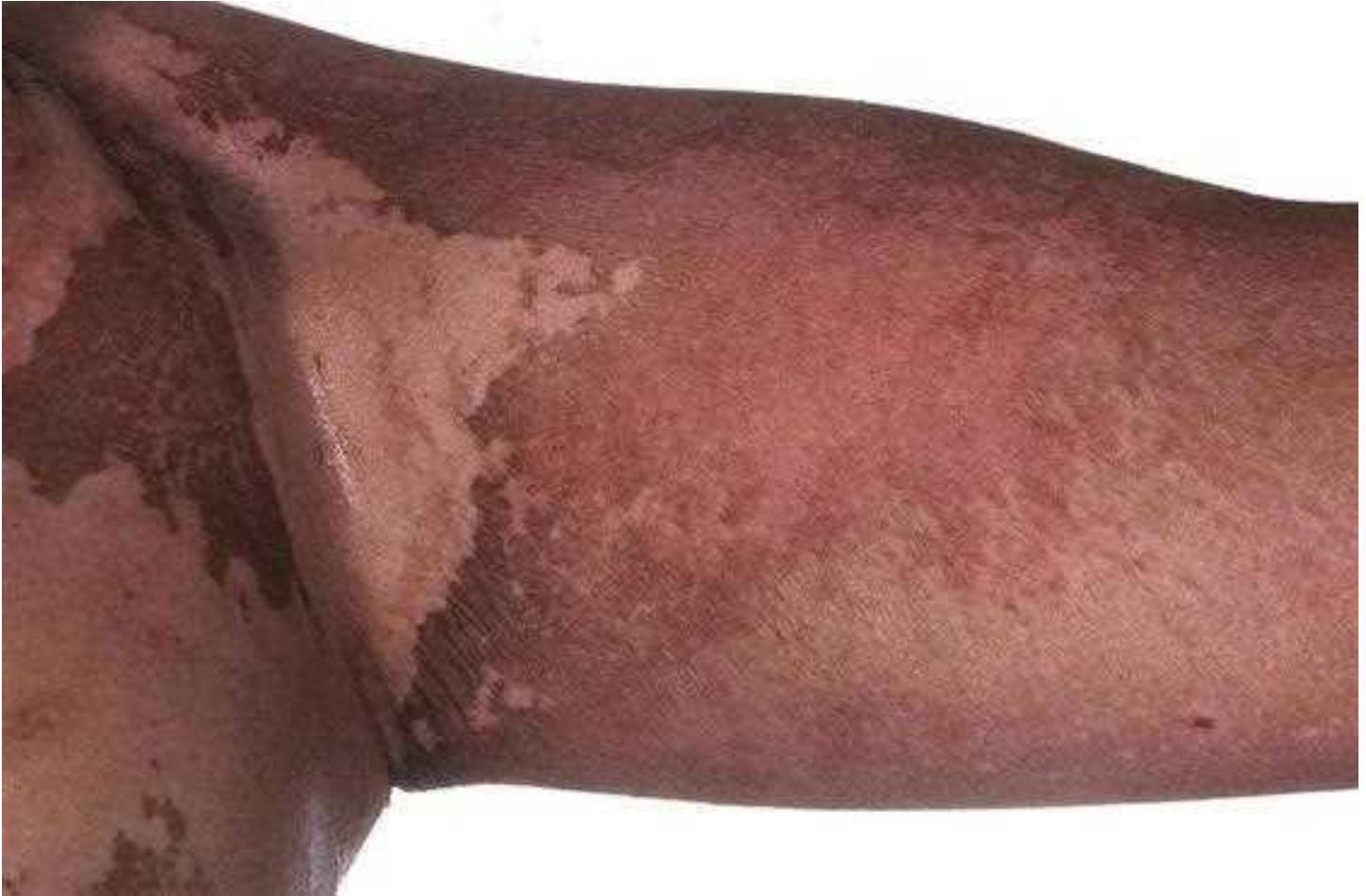

Figure 13.10 *Staphylococcus* scalded skin syndrome.

Ecthyma is often referred to as a deeper form of impetigo as the group β -haemolytic Streptococci (*S. pyogenes*) invade the dermis leading to superficial ulcers. Lesions start as small pustules that have adherent crust and underlying ulceration, and most commonly occur on the lower legs of children and elderly people who live in humid climates. Lesions usually heal slowly with scarring ([Figure 13.11](#)).

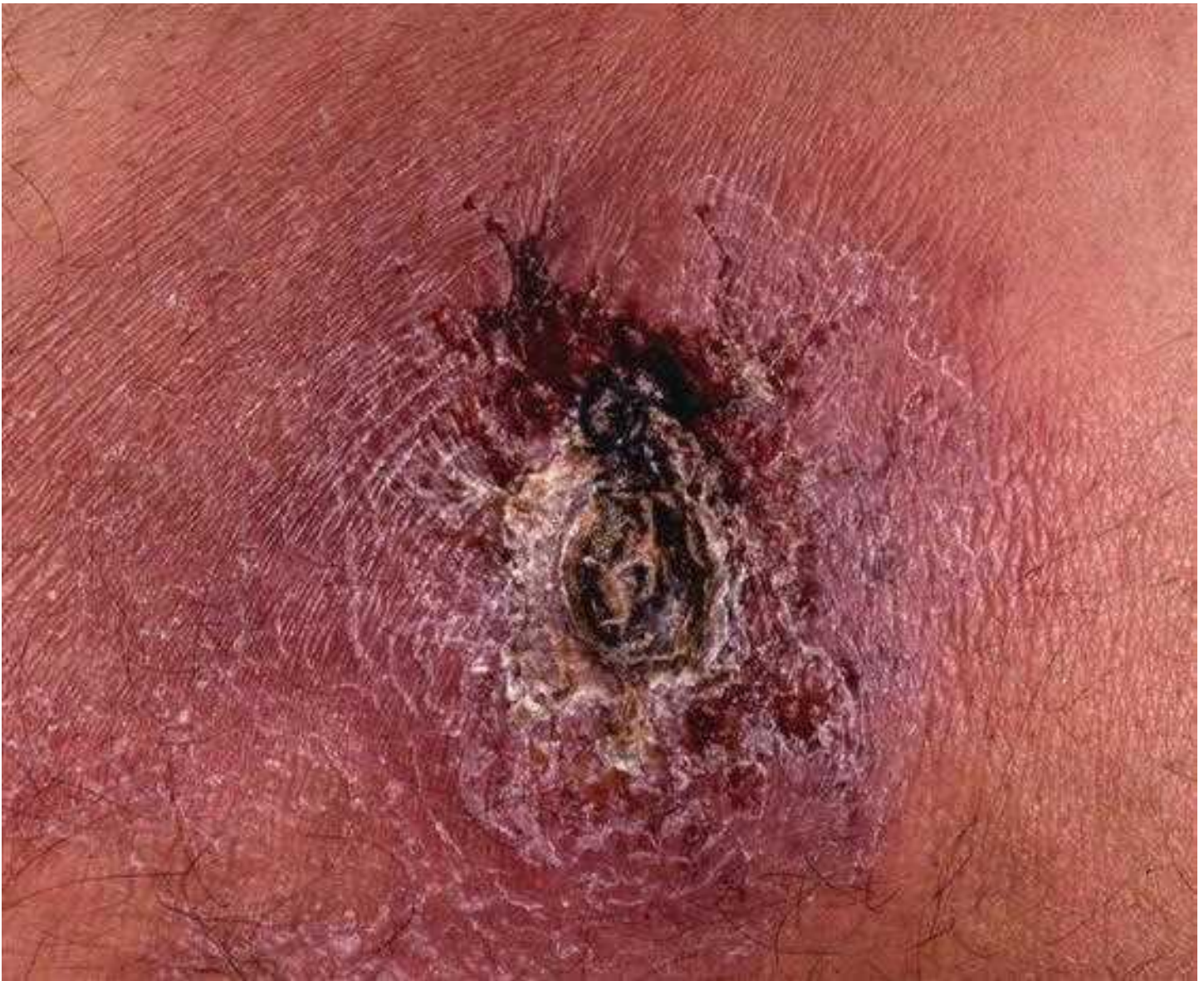

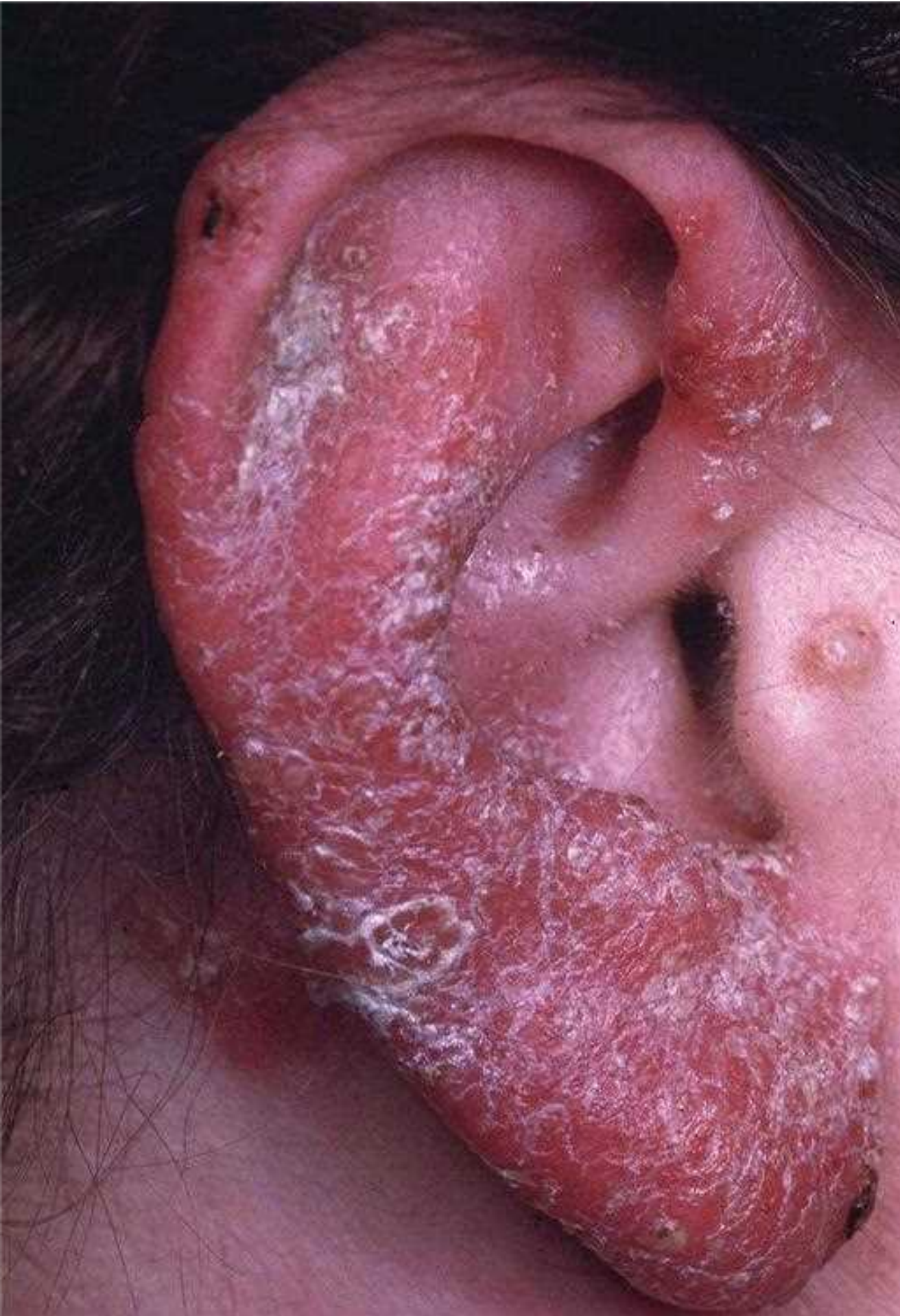Figure 13.11 Ecthyma.

Mycobacterial disease

Clinical manifestations of mycobacterial infections are largely determined by the ability of the host to mount an immune response. Disease spectrums therefore range from dissemination to mild localised lesions; for example, *Mycobacterium tuberculosis* may present with miliary TB or lupus vulgaris, and *Mycobacterium leprae* may present with lepromatous (multibacillary) or more tuberculoid (paucibacillary) phenotypes (see [Chapter 18](#)).

Cutaneous *M. tuberculosis* (TB) is rare even in endemic areas. TB in the skin usually occurs as a secondary manifestation of disease with its primary focus in the respiratory tract. The most common manifestation is lupus vulgaris, which usually presents on the head and neck. Lesions appear as slowly growing well-demarcated red-brown papules that coalesce to form indolent plaques of a gelatinous nature: the so-called ‘apple-jelly nodules’ ([Figure 13.12](#)). A

number of mechanisms are thought to cause clinical lupus vulgaris, including spread of TB to the skin from lymphatics or blood, and direct extension of TB from underlying tissues (scrofuloderma) from primary cutaneous inoculation or spread from a BCG vaccination site.



[Figure 13.12](#) Lupus vulgaris.

Allergic-type hypersensitivity reactions called *tuberculids* can occur in the skin of patients with underlying TB. Tuberculids are thought to represent hypersensitivity reactions to antigenic fragments of dead bacilli deposited in the skin via haematogenous spread. Recent studies have demonstrated TB DNA in the affected skin in 25–75% of cases. Tuberculids include erythema induratum (Bazin's disease), where patients present with tender nodules and plaques that ulcerate and heal with scarring on the lower legs, papulonecrotic tuberculid (which some authors believe to be a more superficial form of Bazin's disease) ([Figure 13.13](#)), and lichen scrofulosorum (very small lichenoid papules over the trunk and limbs in young patients).

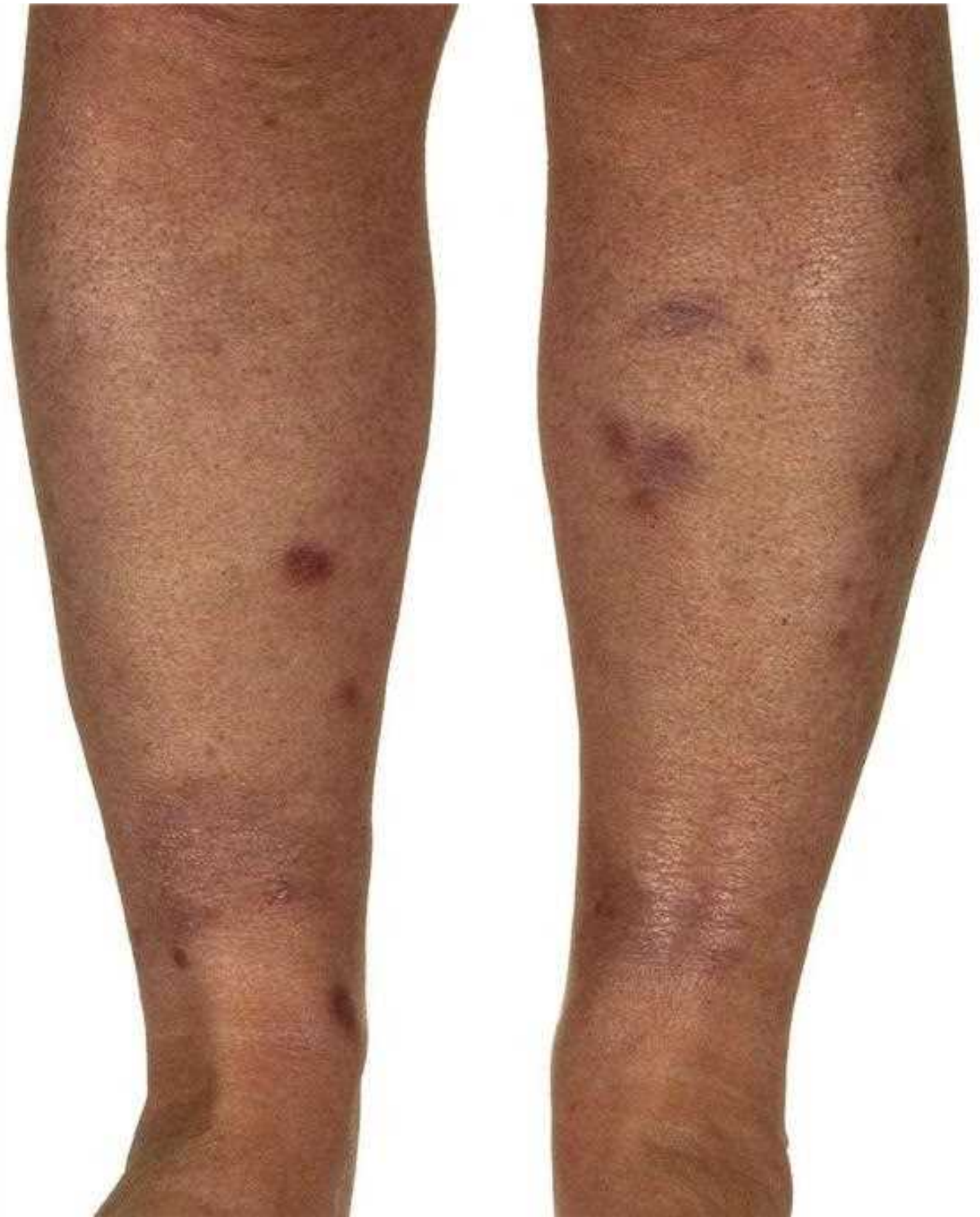

Figure 13.13 Erythema induratum (Bazin's disease).

Atypical mycobacteria (ATM) are usually found in the environment in vegetation and water.

Rapidly growing *Mycobacterium chelonae* complex/*M. abscessus*/*M. fortuitum* may be associated with boil-like skin lesions from traumatic implantation. *Mycobacterium avium* complex (MAC) is associated with lymphadenitis in children and disseminated disease (including papular skin lesions) in human immunodeficiency virus (HIV) patients. Immunocompromised patients are most frequently affected in addition to those with underlying systemic diseases such as diabetes, chronic renal failure, connective tissue disease, and malignancy. Patients require treatment with clarithromycin, rifampicin plus ciprofloxacin/moxifloxacin, or doxycycline for four to six months or six to eight weeks past 'clinical cure' in immunocompromised patients.

Mycobacterium marinum or 'fish tank' or 'swimming pool granuloma' usually occurs because of contact with infected tropical fish or contaminated water. The hand or fingers are most frequently affected; initially, a single warty nodular and occasionally pustular lesion appears with subsequent sporotrichoid spread along local lymphatics, forming a chain of nodules ([Figure 13.14](#)). Patients should be treated with oral clarithromycin for several months.

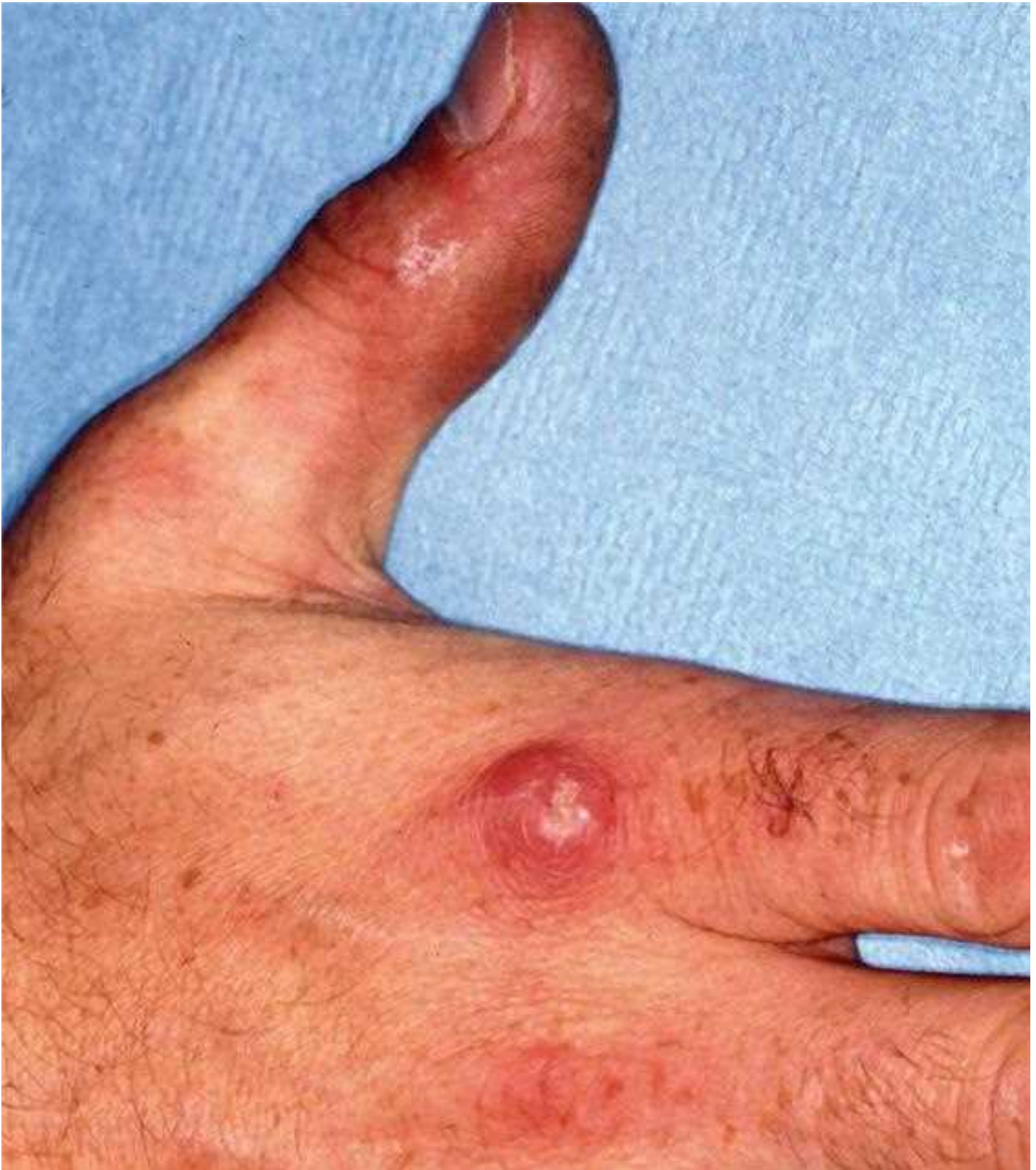

Figure 13.14 Sporotrichoid spread of *Mycobacterium marinum*.

Mycobacterium ulcerans causes extensive non-painful ulceration (buruli ulcer) usually on the limbs in children/young adults living in tropical humid areas associated with minor skin trauma and contact with the mycobacterium in standing water.

Other infections

Bacillary angiomatosis caused by *Bartonella henselae* and *Bartonella quintana* infections presents in HIV patients with multiple small haemangioma-like papules. Clinical manifestations are most commonly seen in the skin and mucous membranes but underlying visceral disease (especially liver) may occur simultaneously. Patients usually present with multiple small cherry-like haemangiomas on the skin which appear over weeks to months ([Figure 13.15](#)). Serology rather than culture is usually used to confirm the diagnosis (indirect fluorescent assay or ELISA IgG > 1 : 64 indicates likely current infection). Erythromycin 500 mg qds for up to 12 weeks is recommended, or 4–6 weeks of azithromycin 500 mg daily.

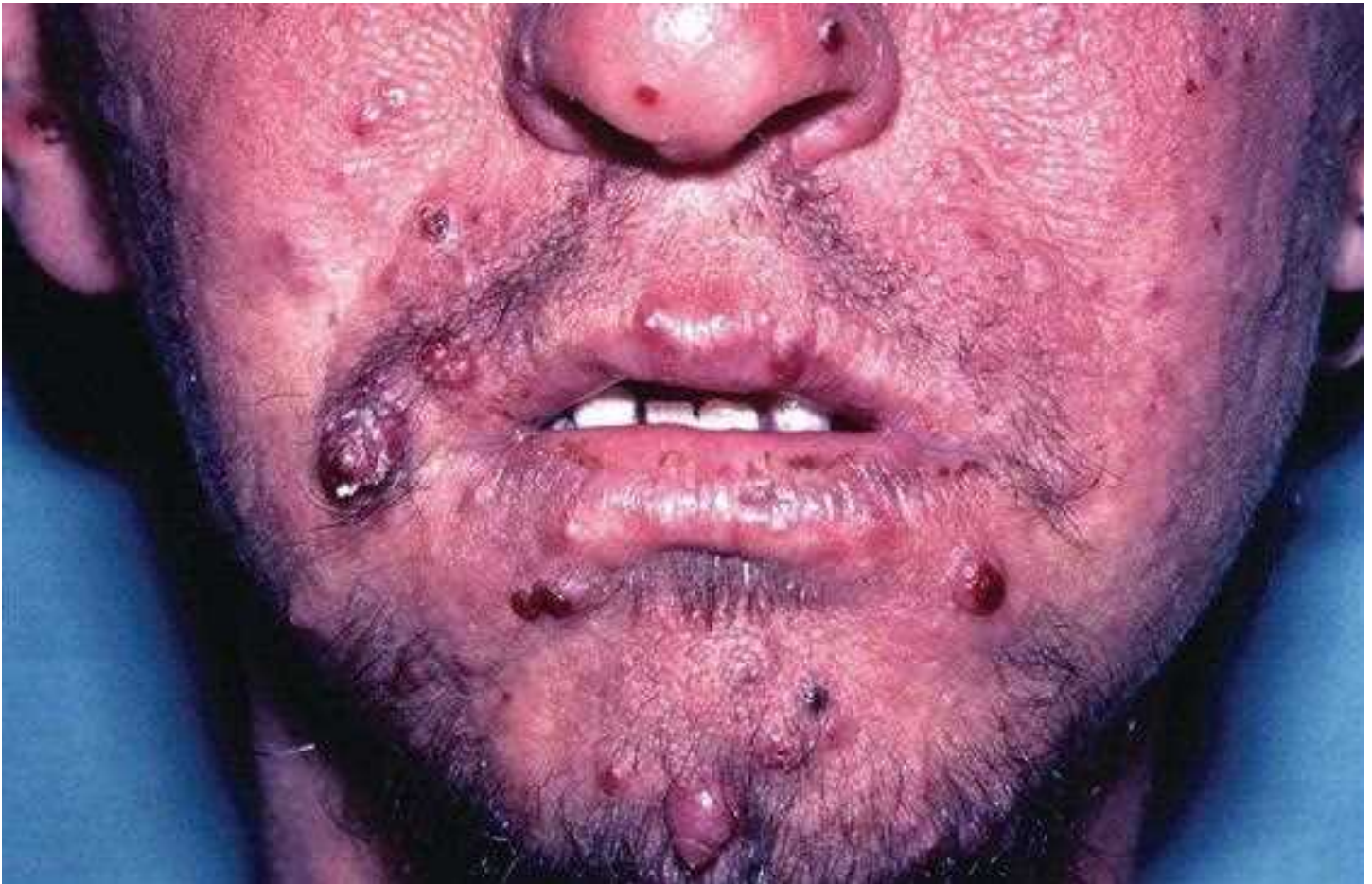
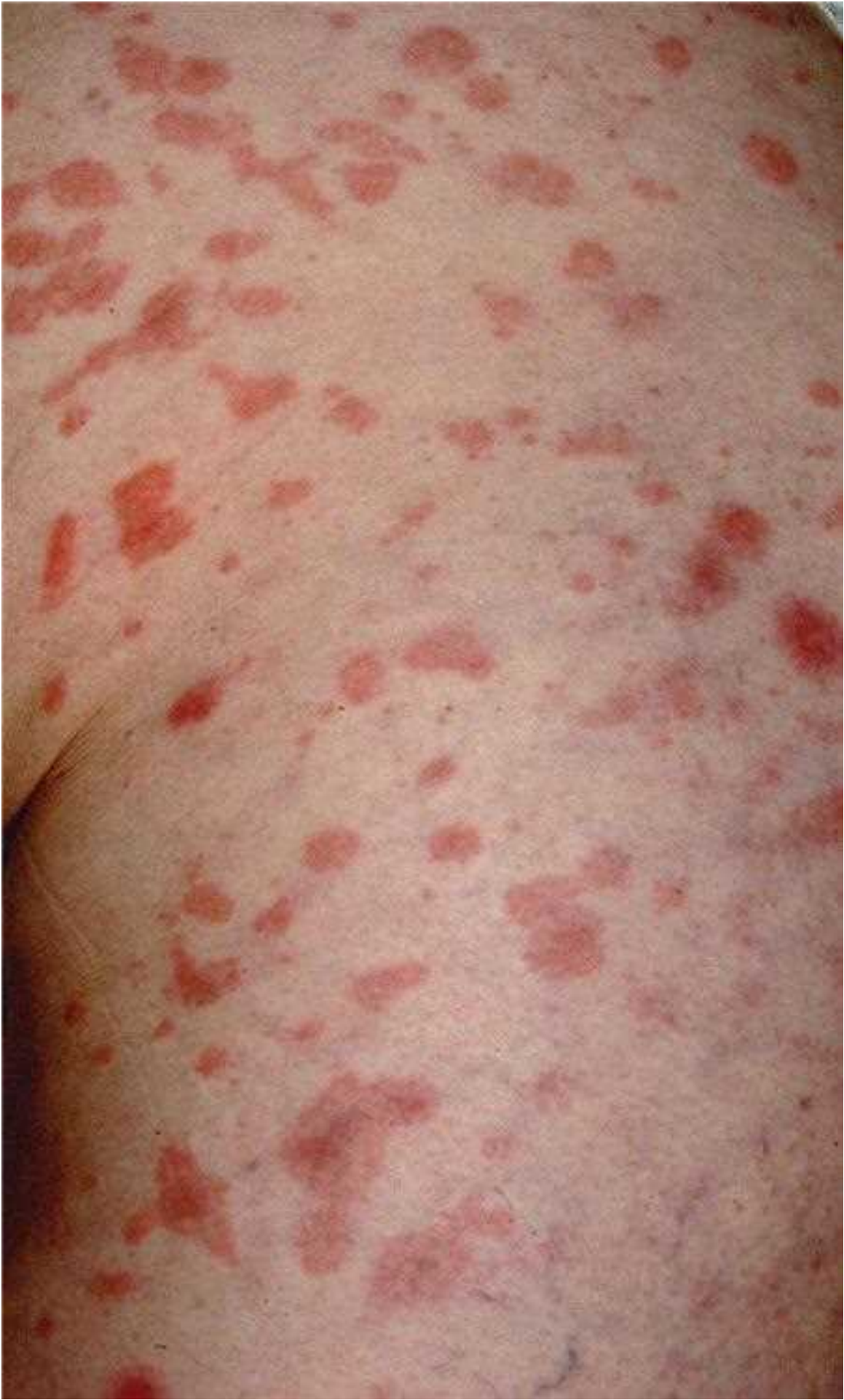
Figure 13.15 Bacillary angiomatosis.

Cat-scratch disease is caused by the bacterium *B. henselae*. Crusted nodules appear within 3–12 days at the site of a scratch (usually by a kitten) associated with the development of regional painful lymphadenopathy one or two months later. The disease usually undergoes spontaneous remission within two to four months. A five-day course of azithromycin can speed up recovery.

Rickettsial organisms are a diverse group of slow-growing small gram-negative bacteria that are mainly transmitted by ticks and mites. Rocky mountain spotted fever (RMSF) is one of the most common rickettsial infections (*Rickettsia rickettsii*) in the USA and has a 4% mortality rate. The most common vector of RMSF is the dog tick. Within a week of the bite

patients present with high fever, headache, myalgia, and a petechial rash which characteristically appears on the palms and soles but may spread to the trunk ([Figure 13.16](#)). There may be a necrotic lesion (tache noire) at the site of the tick bite. Treat adults with doxycycline 100 mg twice daily for approximately one week and children with azithromycin for five days.



[Figure 13.16](#) Rocky mountain spotted fever.

Syphilis is caused by the spirochete bacterium *Treponema pallidum* which is transmitted through sexual intercourse, transplacental spread, and via unscreened blood transfusions. The incidence of syphilis is steadily increasing due to co-infection with HIV (see [Chapter 15](#) for more details). Primary syphilis manifests as a painless genital ulcer at the site of inoculation. Cutaneous manifestations of secondary syphilis are characterised by a widespread eruption of red-brown scaly patches and macules that affects the trunk and limbs (particularly palms and soles) ([Figure 13.17](#)). In patients with HIV the rash may be florid with marked crusting. Serology is needed to know whether patients have previous or current infection, which will subsequently guide management and contact tracing.

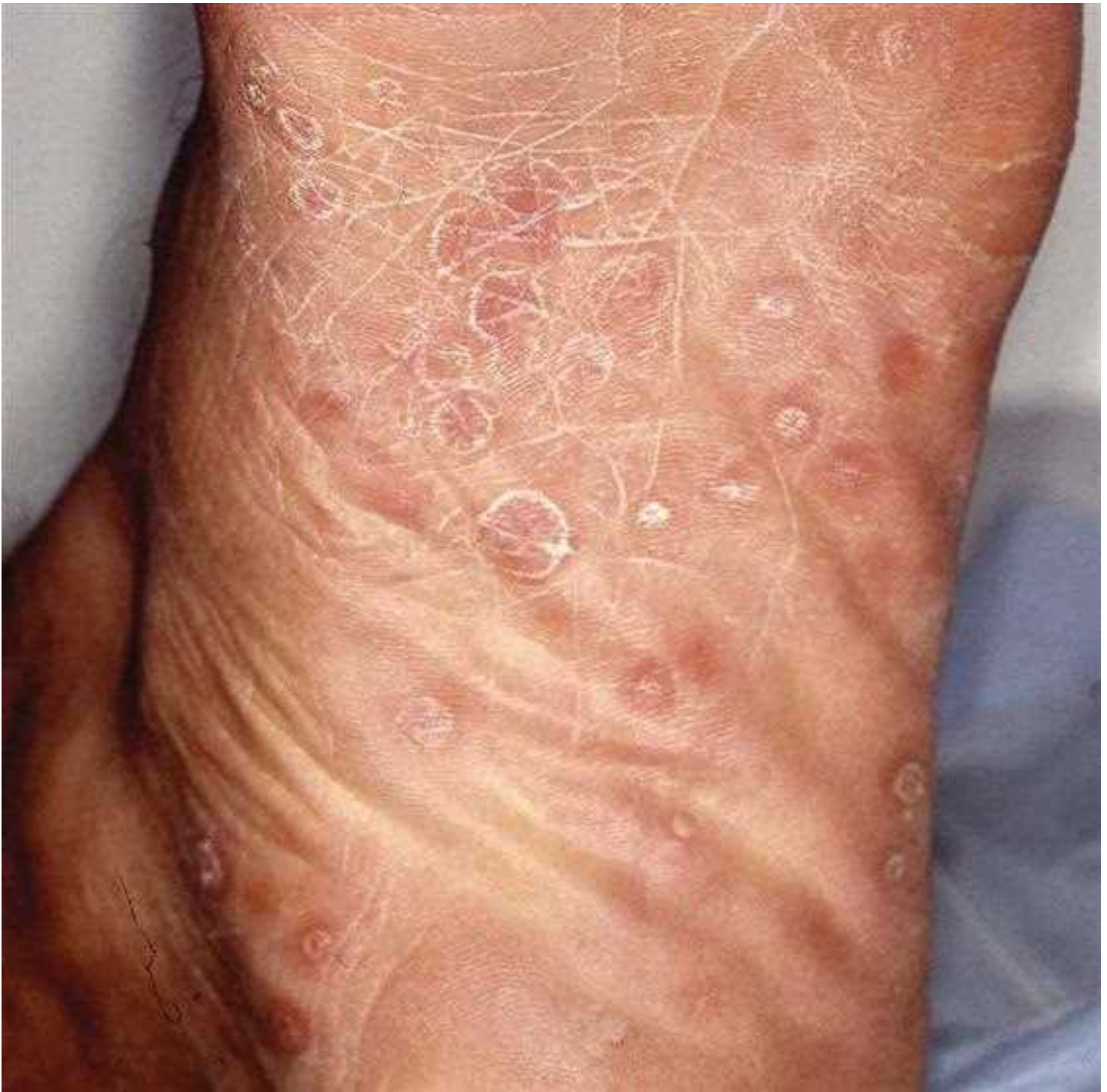

Figure 13.17 Secondary syphilis.

Further reading

Hall, B.J. and Hall, J.C. (2009). *Skin Infections: Diagnosis and Treatment*. Cambridge: Cambridge University Press.

Weber, C.G. (2013). *Wound Care and Skin Infections 2013* (The clinical medicine series). www.clinicalmedconsult.com. Primary Care Software.

CHAPTER 14

Viral Infections

Rachael Morris-Jones

Guy's and St Thomas' NHS Foundation Trust, London, UK

OVERVIEW

- Viruses are obligate parasites able to make important changes in cellular function and immune responses of the host.
- As well as modifying genetic material of the host cell, the viral genome itself undergoes changes – shift and drift.
- RNA viruses are unstable, undergoing multiple mutations and causing systemic disease (measles).
- DNA viruses are more stable and cause local infections (human papilloma virus warts, molluscum).
- Herpes simplex infections are acquired by local contact and reactivate at the inoculation site, usually mucosae (lips and genitals).
- Herpes zoster (shingles) is due to reactivation of previously acquired varicella zoster virus (chickenpox).
- Specific antiviral medications are few and therefore the current primary strategy for reducing viral infections is vaccination.

Introduction

The term *virus* comes from Latin, meaning poison or toxin. Most modern medical practitioners think of viruses as micro-organisms rather than toxins, but some experts argue that viruses are not living organisms as they do not fulfil all the necessary criteria. Viruses do not have cell structures and they require host cells to replicate and synthesise new products. This spontaneous self-assembly within the host cells has been likened to the autonomous growth of crystals. Viral self-assembly has also been used to strengthen the hypothesis that the 'origins of life' started from self-assembling organic molecules. Nonetheless, viruses do possess genes, cause disease, trigger immune responses, and evolve through natural selection; so, from a practitioner's point of view, living or otherwise, they have an enormous impact on human health.

The inability of viruses to grow or replicate outside the host cell means that they have become masters at persistence within the host. Viruses persist within the host cell because

they are often able to replicate without killing the host cells, their gene expression can be restricted, they can mimic host molecules, down-regulate host immunity, and directly infect the host's immune cells. Viruses continuously change, either gradually (called 'drift') where they accumulate minor mutations, or suddenly (called 'shift') following major changes during recombination of the viral genome.

RNA viruses such as measles and human immunodeficiency virus (HIV) are unstable, undergoing immense drift and shift, with up to 2% of their genome altered each year through multiple mutations. These viruses tend to cause systemic disease in humans, leading to generalised cutaneous eruptions such as a 'viral exanthem'. In contrast, DNA viruses such as human papillomavirus (HPV), molluscum contagiosum, herpes simplex virus (HSV), and varicella zoster virus (VZV) are more stable. They are frequently inoculated directly into the skin and replicate in epidermal cells.

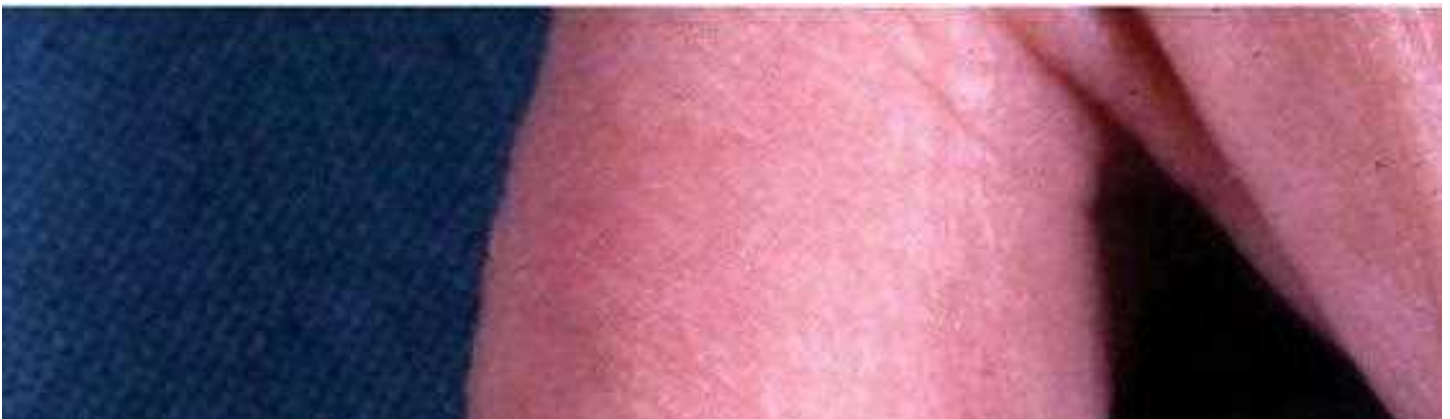Viruses can be transmitted by direct contact from skin to skin, through aerosols, transplacental spread, blood products, contaminated needles, and via the faecal–oral route. Once inside the host, viruses can spread directly from cell to cell, via the blood, or central nervous system by axonal transport. Many viruses demonstrate tropism (in other words a predilection for a certain host cell) via virus attachment to protein-specific cell surface receptors. HPV, for example, has tropism for keratinocytes.

The behaviour of different viruses therefore determines the type of disease they cause with resultant localised or widespread reactive skin disorders. Common viral infections of the skin are usually easily identified by pattern recognition through the characteristic skin or mucous membrane site affected and/or typical lesions.

Herpes viruses

Herpes simplex

HSV is spread by direct contact – 'shedding' from one host to another. Two viral subtypes exist: type I is associated mainly with facial lesions although the fingers ([Figure 14.1](#)) and genitals may be affected. Type II is associated almost entirely with genital infections. HSV remains within the host for life, remaining latent in the sensory nerve ganglia, leading to recurrent reactivation.



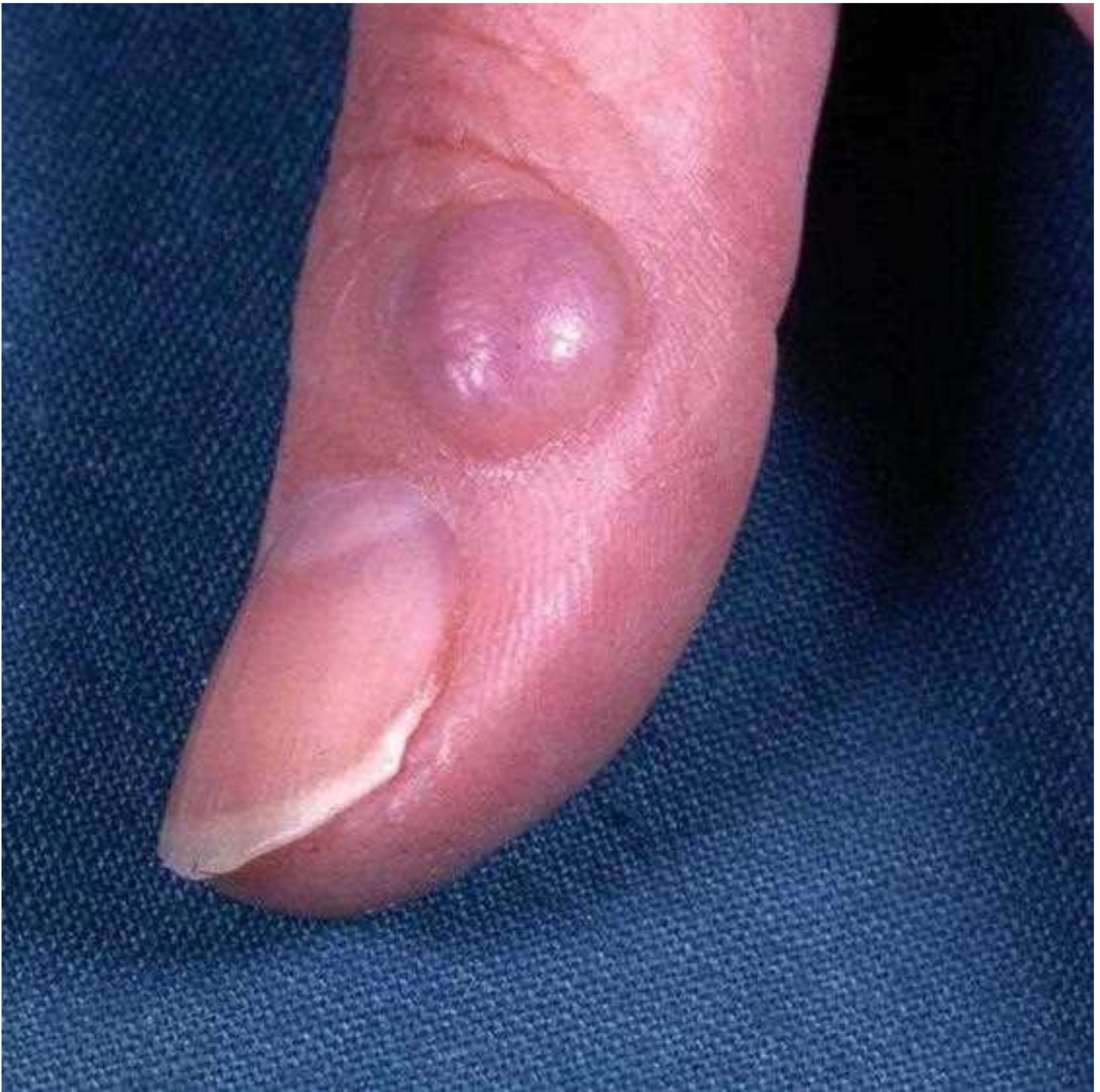

Figure 14.1 Inoculation herpes.

Primary herpes simplex (type I) infection usually occurs in or around the mouth/nose, with variable involvement of the face ([Figure 14.2](#)). Lesions consist of small vesicles ([Figure 14.3](#)) which crust over and are associated with regional lymphadenopathy. HSV type II infects the external genitalia; the initial vesicle or vesicles rapidly break down into painful ulcers ([Box 14.1](#)).

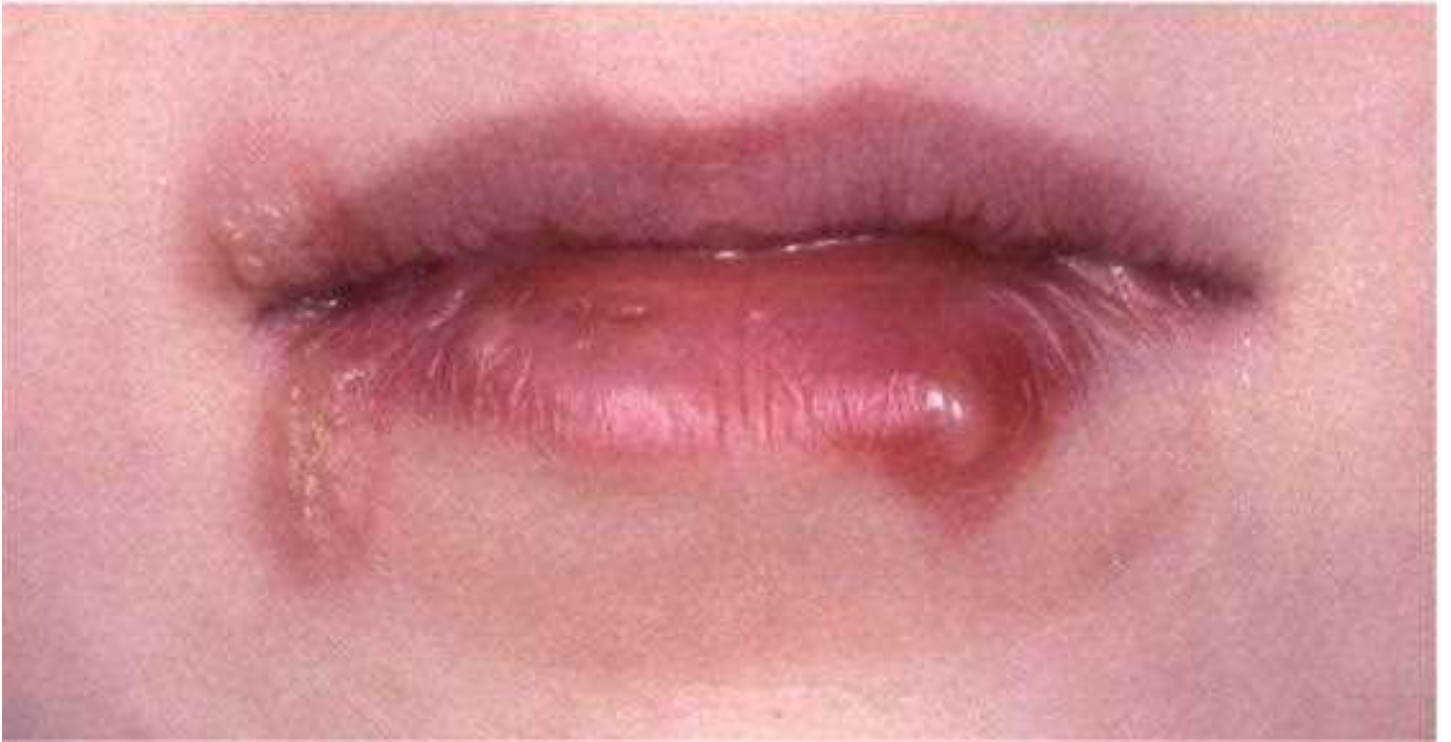
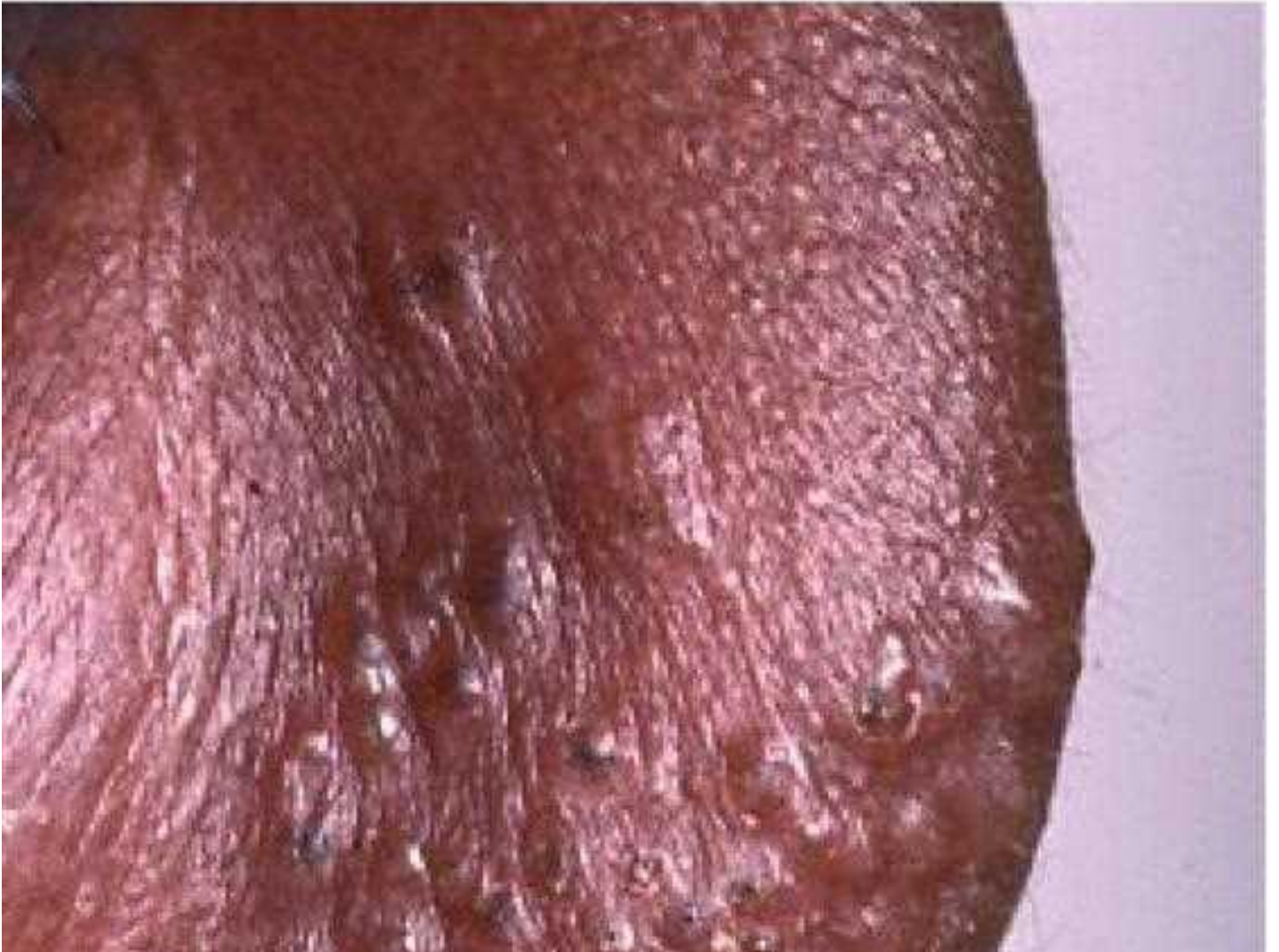
Figure 14.2 Herpes 'cold sore'.



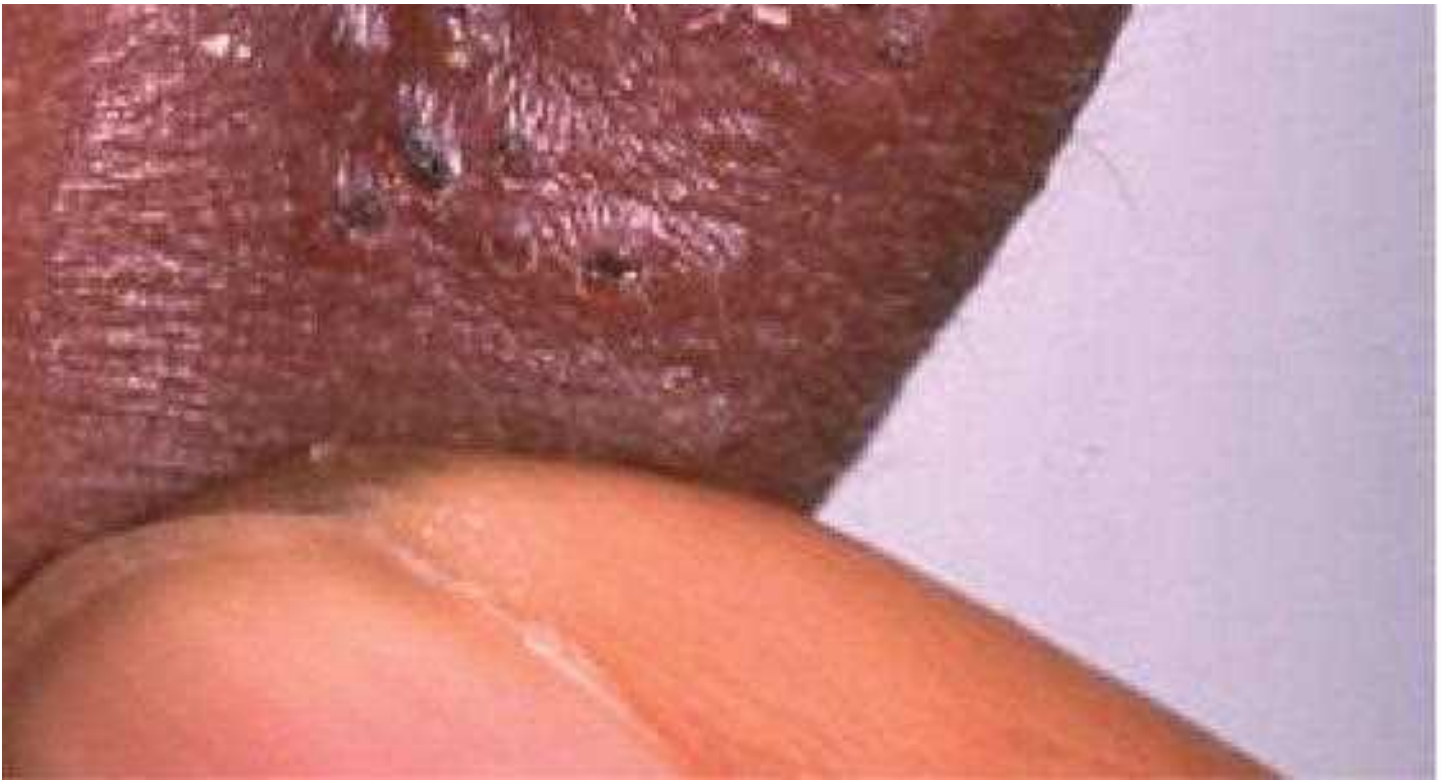

Figure 14.3 Herpes simplex vesicles on posterior pinna.

Box 14.1 Herpes simplex – points to note

- Genital vesicles may not be visualised as they rapidly ulcerate.
- Prodrome symptoms consist of itching, tingling, and tenderness.
- Rapid viral detection from scraping the vesicle/ulcer base using electron microscopy, immunofluorescence, or polymerase chain reaction (PCR).
- Genital herpes in pregnancy carries a risk of ophthalmic infection of the infant. Caesarean section may be indicated.
- ‘Eczema herpeticum’ occurs in patients with atopic eczema where the HSV disseminates across abnormal skin ([Figure 14.4](#)).

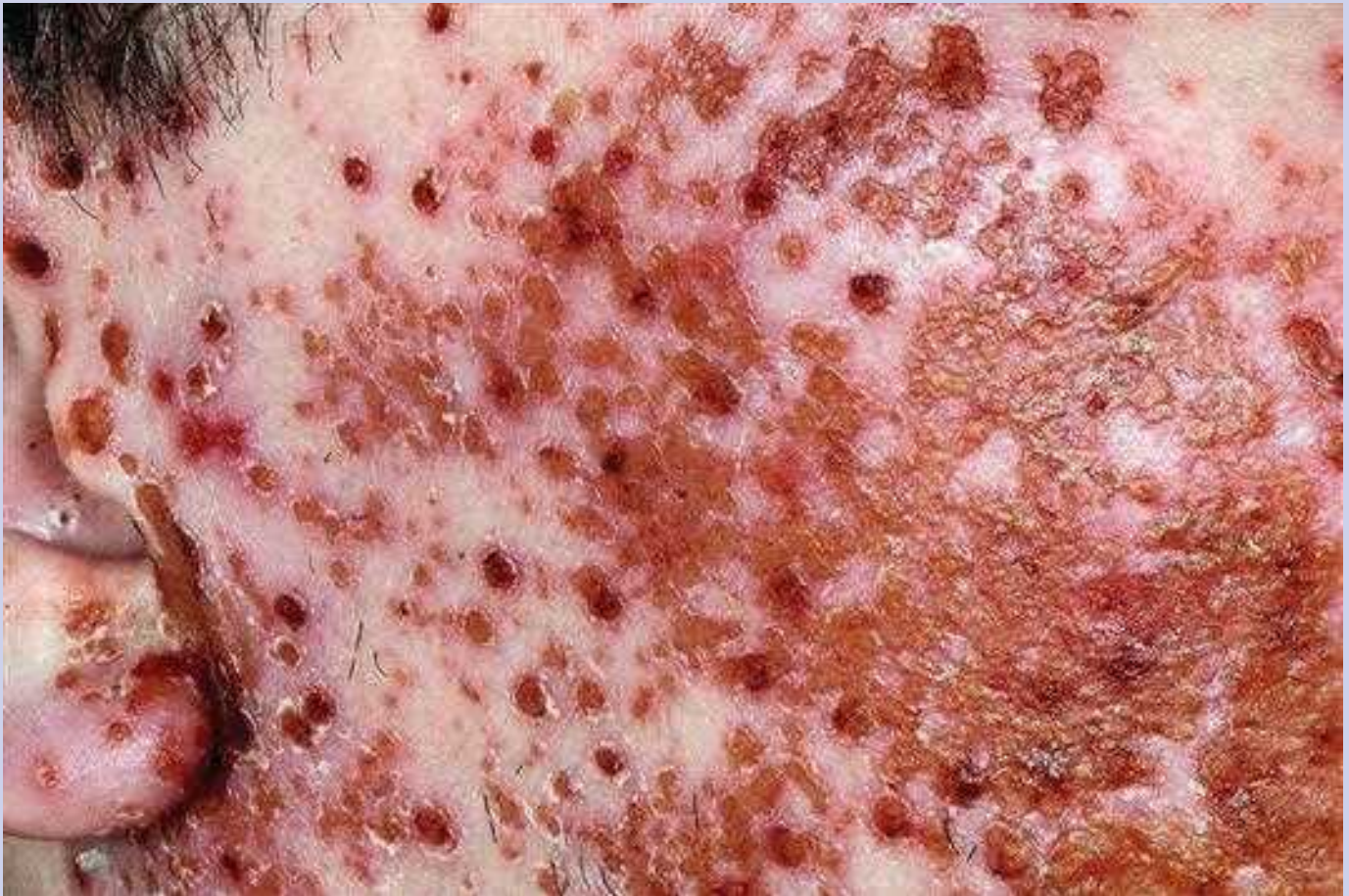

Figure 14.4 Eczema herpeticum.

Episodes of reactivation of HSV may be triggered by the cold (‘cold sore’), bright sunlight, trauma, immunosuppression, or intercurrent illnesses. There is frequently a prodrome of tingling or itching before the appearance of the vesicles, which occur in the distribution of a sensory nerve. Topical aciclovir/penciclovir/idoxuridine cream can be used to treat mild labial herpes. Severe infections should be treated with oral aciclovir 200 mg five times daily

or 400 mg three times a day for five days.

Secondary prophylaxis (suppressive therapy) for frequent reactivation can be given as 400 mg once or twice daily. Higher doses are needed in immunocompromised patients.

Valaciclovir (HSV 500 mg twice daily for five days, VZV 1 g three times daily for seven days) and famciclovir (genital HSV 250 mg three times daily for seven days, VZV 750 mg daily for seven days) are alternatives that are taken less frequently. Brisk inflammatory responses to genital HSV can be seen in patients with HIV whose immune system is reconstituting once they start their HAART (highly active antiretroviral therapy) – the so-called *immune reconstitution inflammatory syndrome* (IRIS). Clinically, this is seen as deteriorating signs and symptoms of HSV disease and may look like a hyperkeratotic nodule (pseudoepithelial hyperplasia) and may warrant aggressive treatment of the HSV with oral high-dose valaciclovir (with additional imiquimod 5% cream) and occasionally a reduction in the HAART medication.

Varicella zoster virus

VZV is a herpes virus that causes chickenpox (the primary illness), which is characterised by a prodromal illness for about two days followed by crops of papular-vesicular lesions ([Figure 14.5](#)) that eventually crust over and heal. Primary chickenpox in adults can lead to a severe pneumonitis. Subsequently shingles (reactivation) may occur as the virus remains latent in the sensory nerve ganglia ([Box 14.2](#)). The thoracic nerves are most commonly affected. In shingles, pain, fever, and malaise may precede the rash, which is characterised usually by its dermatomal distribution ([Figure 14.6](#)); however, adjacent dermatomes may be affected ([Figure 14.7](#)). Erythematous papules usually precede vesicles which develop over several days, crusting as they resolve, often with secondary bacterial colonisation. Occasionally, peripheral motor neuropathy can result, and a proportion of patients develop severe chronic post-herpetic neuralgia. Skin lesions of shingles and nasopharyngeal secretions can transmit chickenpox to susceptible individuals.

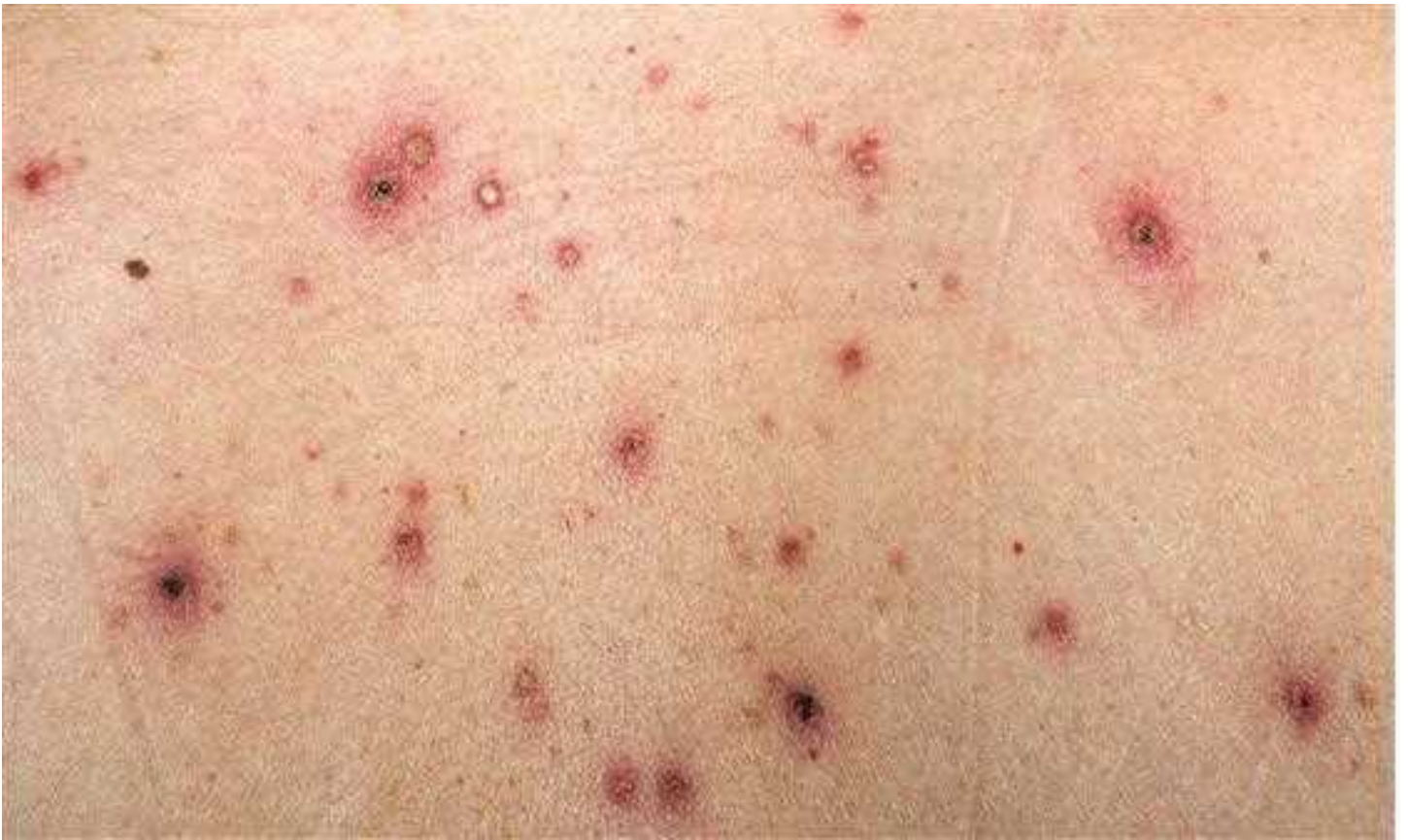

Figure 14.5 Varicella zoster virus chickenpox infection in an adult.

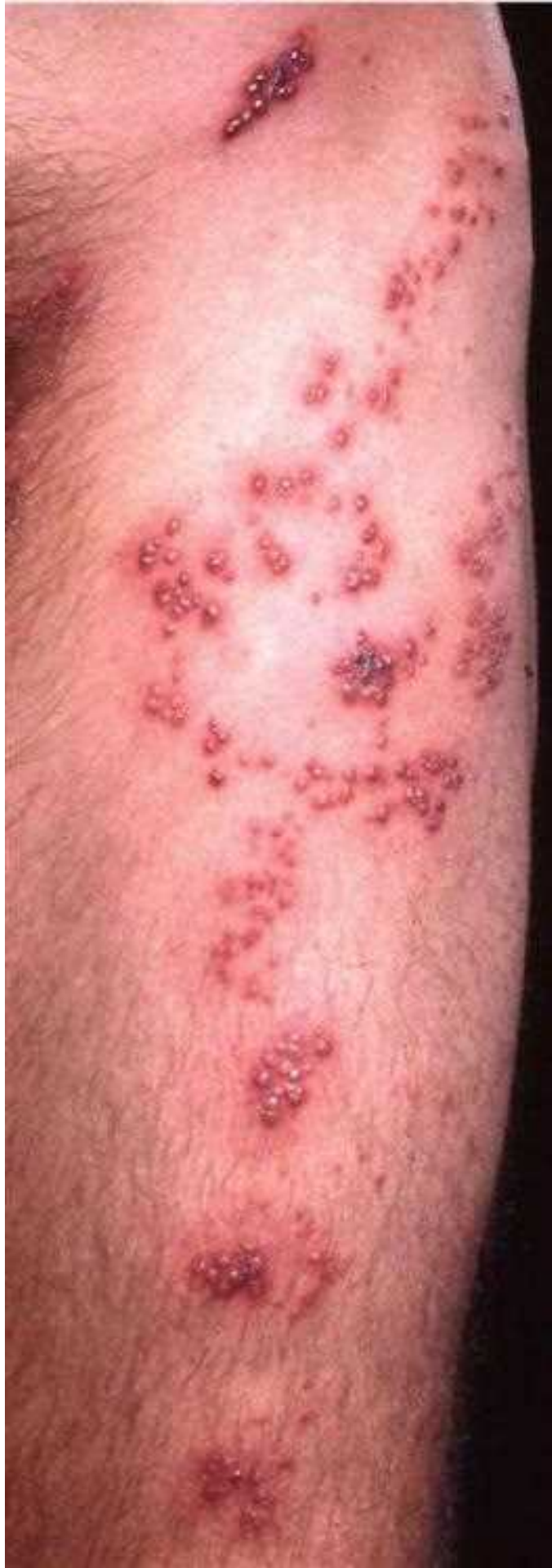

Figure 14.6 Herpes zoster in a dermatome (shingles).

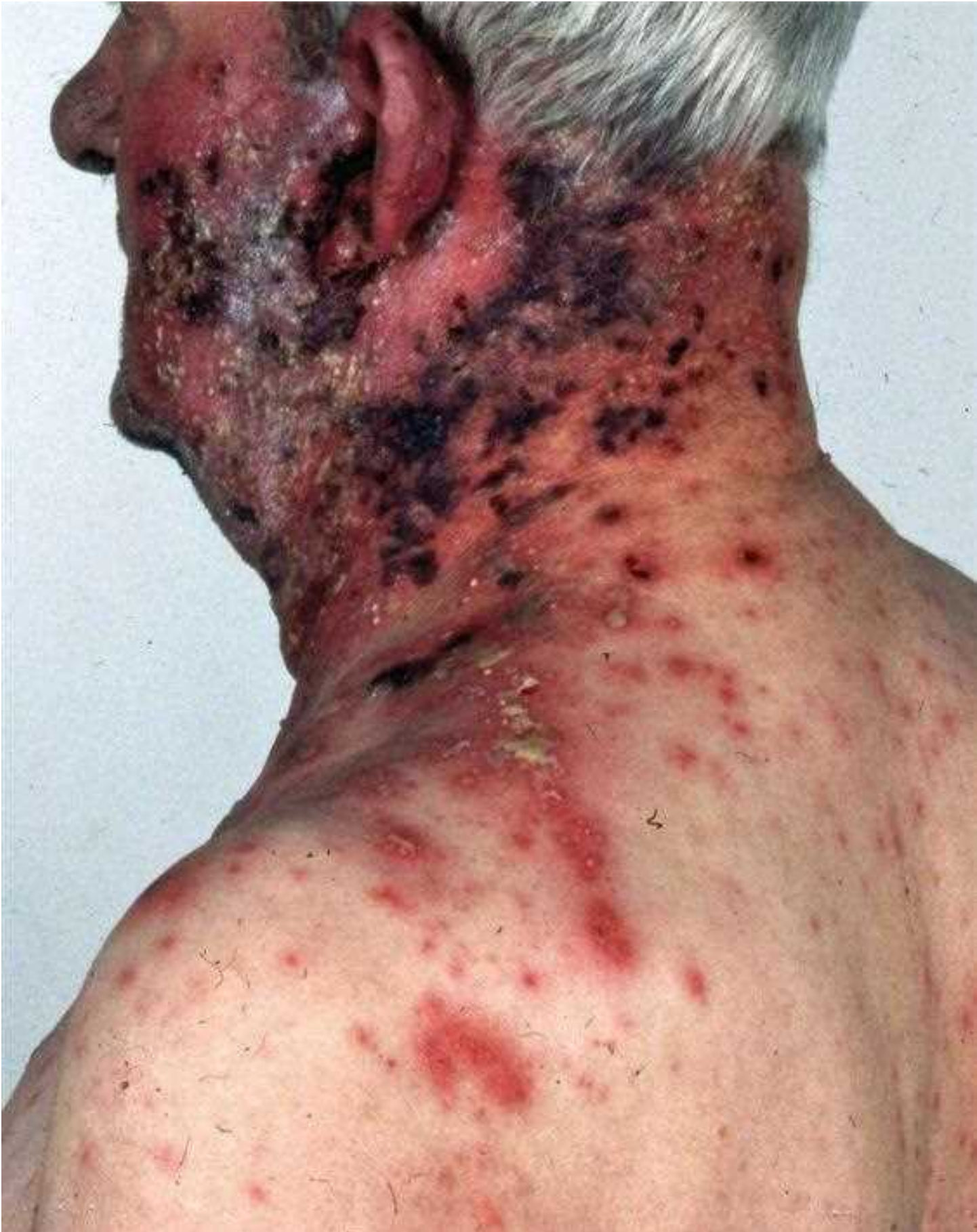

Figure 14.7 Multidermatomal varicella zoster virus (shingles).

Box 14.2 Shingles – points to note

- Trigeminal shingles may affect:
 - the ophthalmic nerve (causing severe conjunctivitis)
 - the maxillary nerve (causing vesicles on the uvula or tonsils)
 - the mandibular nerve (causing vesicles on the floor of the mouth and on the tongue) ([Figure 14.8](#)).

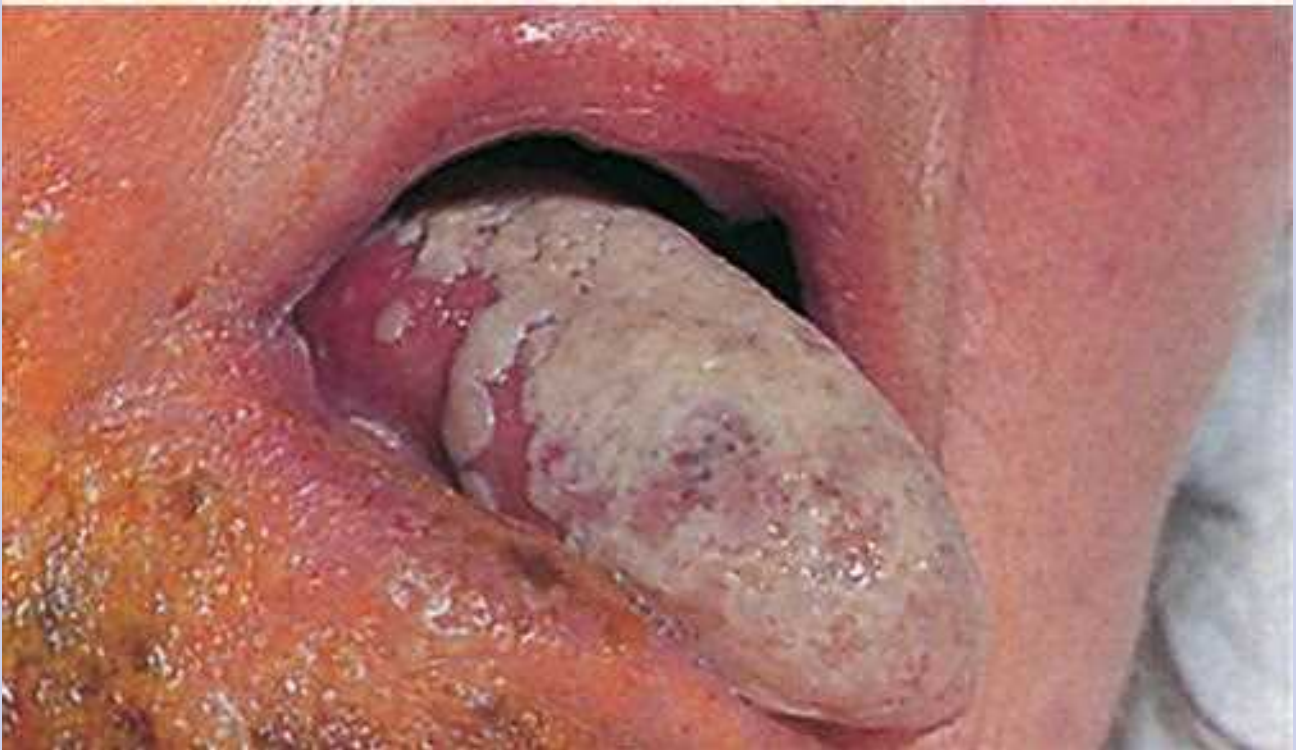

Figure 14.8 Mandibular nerve zoster.

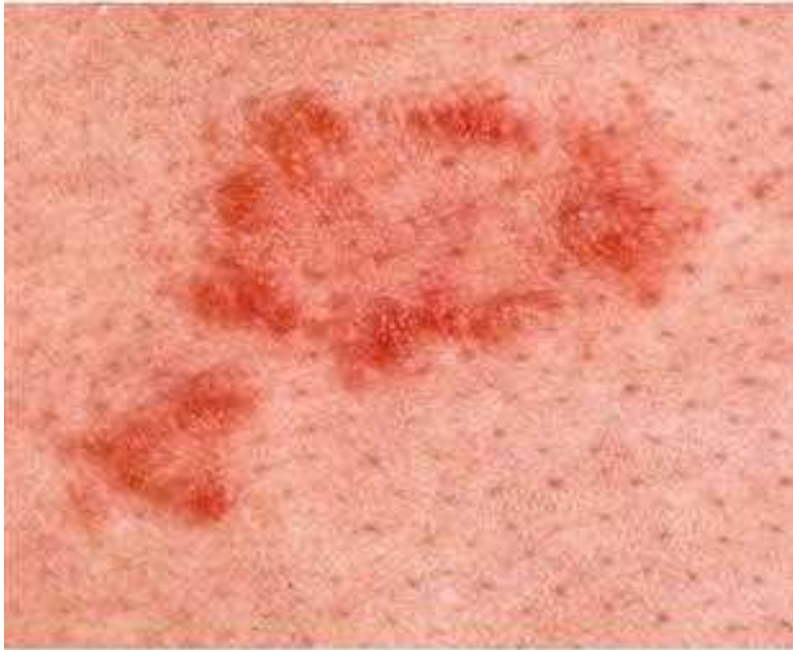- Shingles affecting the facial nerve presents with lesions in the external auditory canal (Ramsay Hunt syndrome).
- Disseminated shingles may present with widespread cutaneous and visceral lesions.
- In the context of HIV, shingles lesions may be multidermatomal, extensive, and haemorrhagic.

Patients ideally should receive high-dose aciclovir (800 mg five times daily for seven days) within 72 hours of the onset of the eruption. If the eye is affected or there is nerve compression, then intravenous aciclovir (5 mg/kg every eight hours for five days) should be considered and patients may require systemic steroids (prednisolone 40–60 mg daily) to prevent nerve paralysis in severe cases. Greasy emollient should be applied to the affected

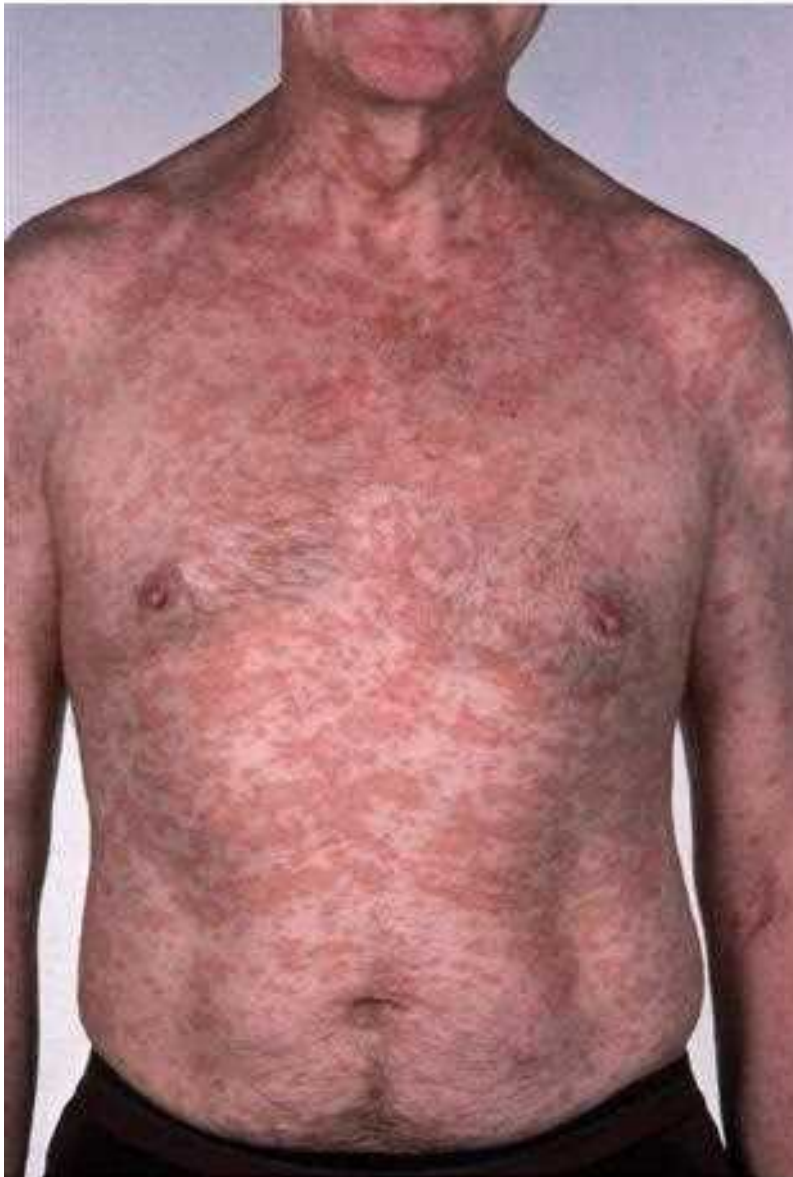skin regularly to prevent cracking and reduce pain as lesions heal. Topical antibiotic ointments can be used to treat secondary bacterial infections (mupirocin, fusidic acid, and polymyxin). Post-herpetic neuralgia may respond to gabapentin or carbamazepine. Preliminary studies using a topical 8% capsaicin patch applied for one hour reduced pain by >30% in 40% of shingles patients for up to eight weeks. For one month following herpes zoster (shingles) there is an increased risk of cerebrovascular accident (stroke), particularly following herpes zoster ophthalmicus (HZO). Ischaemic stroke was more common than haemorrhagic stroke after herpes zoster infection, and this appears to be more common in those under the age of 40 years and those who had not received antiviral treatment for their zoster infection.

Varicella zoster virus vaccination is given in some countries to prevent primary chickenpox infections, a single dose of vaccine is 80% successful in preventing disease and two doses 95% effective. Any breakthrough disease is likely to be milder following primary vaccination. Shingles (reactivation of VZV) is thought to occur as the specific cell-mediated immunity against the virus wanes with time. Vaccination to try to prevent shingles is currently given to individuals in their seventh decade in the UK using non-live recombinant zoster vaccine (two doses); this has been shown to give a boost to zoster immunity. Studies showed a 90% reduction in shingles and 98% reduction in post-herpetic neuralgia at 3.7 years in patients vaccinated over the age of 70 years. Shingrix® a recombinant (non-live) shingles vaccine is also available and will be the preferred vaccination for the immunosuppressed.

Pityriasis rosea (PR) has been thought recently to be triggered by an upper respiratory tract infection with human herpes virus type 6 or 7. The evidence for this is not conclusive but for the ease of categorisation PR is described here. PR classically presents with an initial single annular erythematous patch with a collarette of scale – the ‘herald patch’ ([Figure 14.9a](#)), so called because it heralds the onset of the rest of the rash within five to eight days, which consists of multiple smaller scaly patches on the trunk ([Figure 14.9b](#)) and upper arms and thighs (old-fashioned bathing suit distribution). On the back, the lesions may follow the angle of the ribs in a ‘Christmas tree pattern’. Patients may have experienced corysial symptoms before the onset of the rash as part of the viral illness. Patients mainly present in spring and autumn and there may be clustering of cases. The rash settles spontaneously over about four to six weeks, but a mild topical steroid and emollient can be given if the rash is pruritic or inflammatory. Some practitioners advocate the use of high-dose acyclovir to shorten the course of the rash.



(a)



(b)

[Figure 14.9](#) (a) Herald patch of pityriasis rosea. (b) Rash of pityriasis rosea.

Poxviruses

The poxviruses are large DNA viruses, with a predilection for the epidermis. Variola (smallpox), once a disease with high mortality, has been eliminated (last reported case of smallpox occurred in Somalia in 1977) by vaccination with modified vaccinia (cowpox) virus. Vaccination of the general population is no longer required due to the eradication of the virus, but some military and front-line medical personnel are being vaccinated due to the theoretical threat of biological attack with smallpox.

Molluscum contagiosum

The commonest poxvirus skin infection is usually acquired in childhood. It is highly contagious and is spread by direct contact often within families or schools. The incubation period is variable, between 14 days and 6 months. In adults florid molluscum may be an indication of underlying immunodeficiency such as HIV. Flesh-coloured, umbilicated papules are characteristic ([Figures 14.10](#) and [14.11](#)). Large solitary lesions (giant molluscum) and infected lesions may look atypical. Resolving lesions may be surrounded by a small patch of inflammation; this is usually a sign that the lesions may soon resolve because of activation of the immune system.

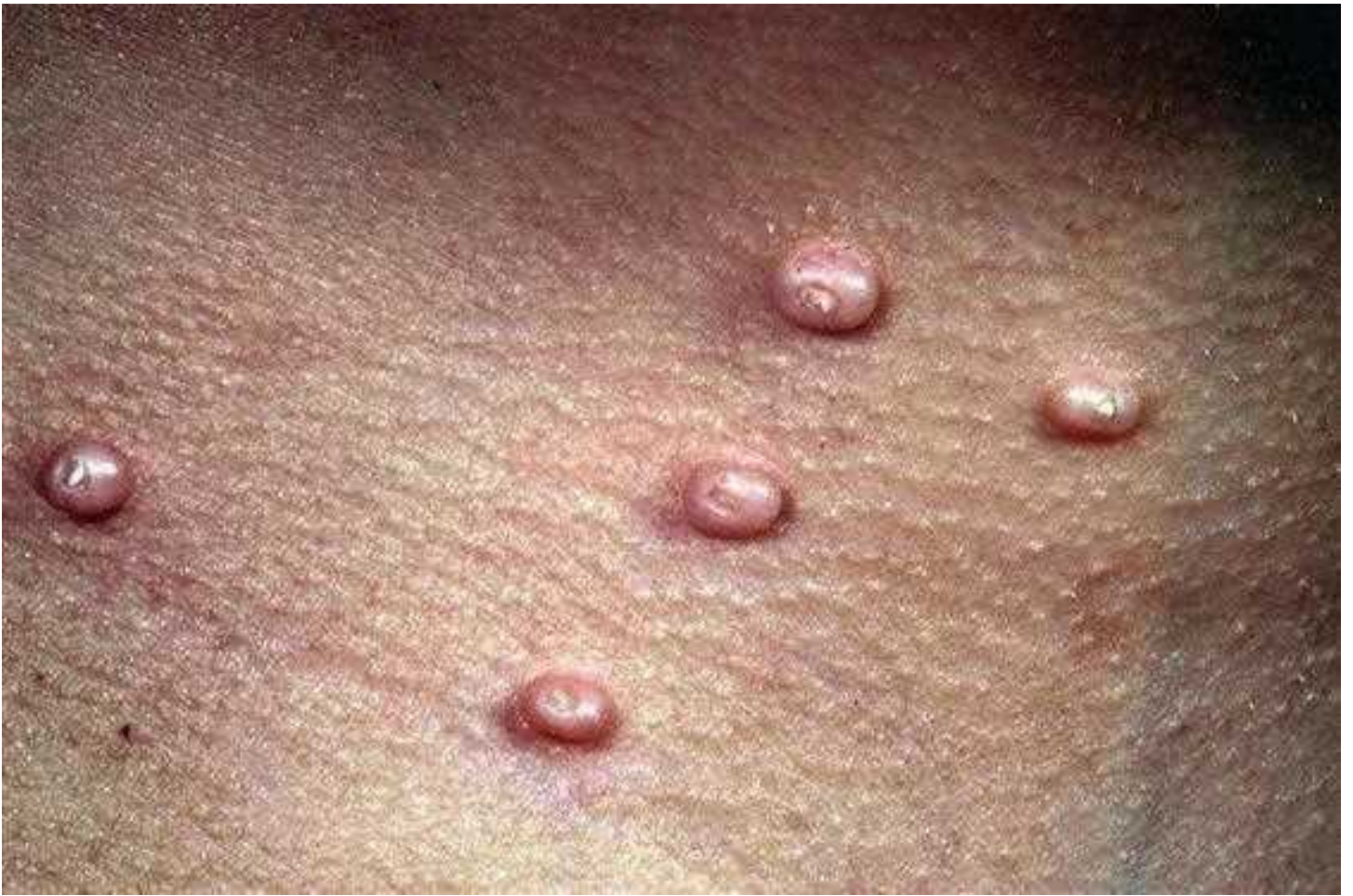

Figure 14.10 Molluscum contagiosum.

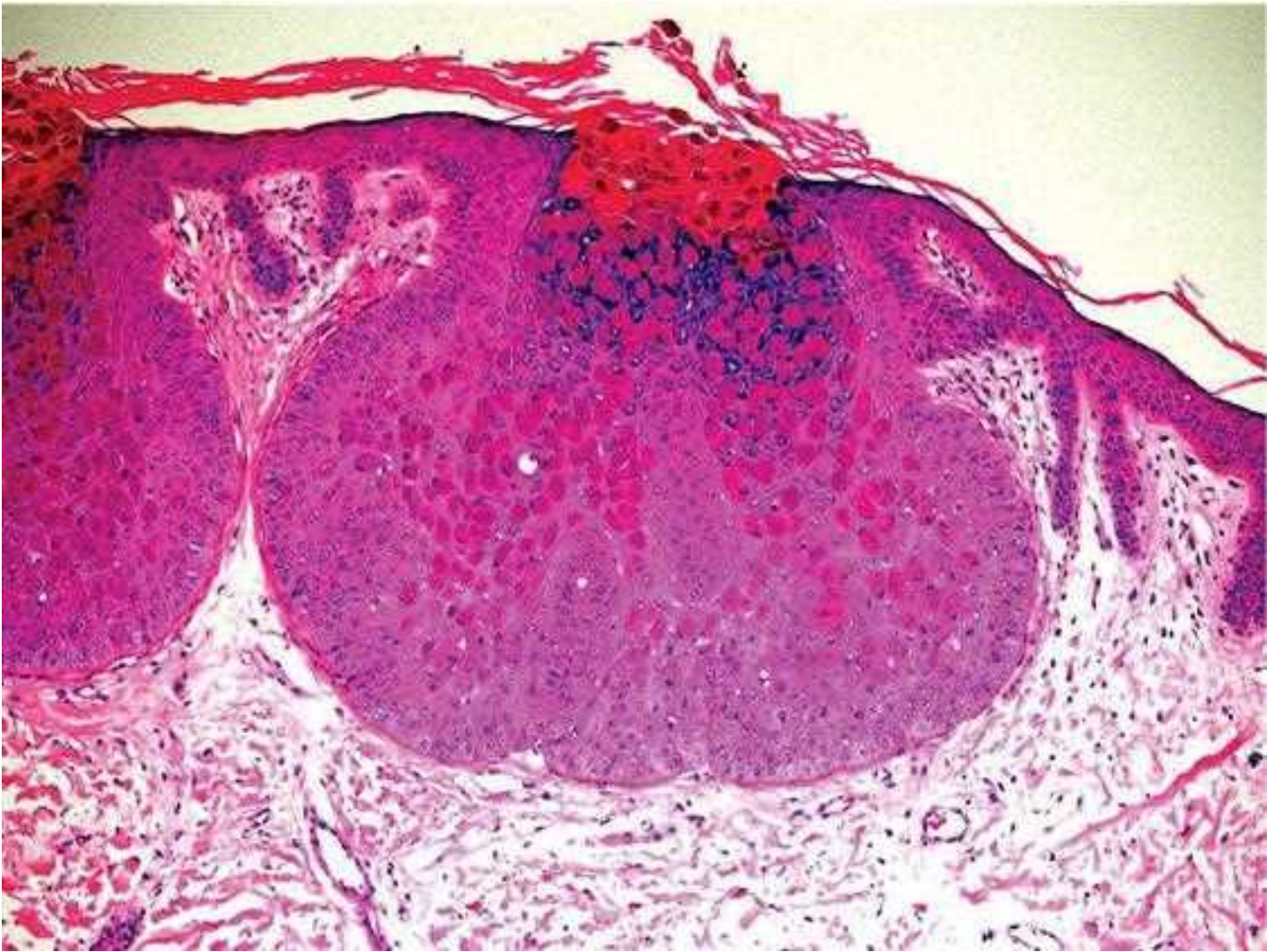

Figure 14.11 Histology showing molluscum bodies.

Parents may be keen for their children with molluscum to be treated. However, most lesions will resolve spontaneously, leaving no marks on the skin. Therefore, painful and potentially scarring treatments should be avoided if possible. Topical hydrogen peroxide 10–15% and cryotherapy can be used to cause local inflammation and speed up resolution in non-cosmetically vulnerable sites. 5% imiquimod cream is not beneficial in the treatment of molluscum.

Orf is usually recognised in rural areas. It is seen mainly in early spring as a result of contact with infected lambs. A single papule or group of lesions develops on the fingers or hands with purple papules developing into bullae ([Figure 14.12](#)). These rupture to leave annular lesions 1–3 cm in diameter with a necrotic centre and surrounding inflammation. The incubation period is a few days and the lesions last two to three weeks with spontaneous healing. Associated erythema multiforme and widespread rashes are occasionally seen. Lifelong immunity does not result from infections.

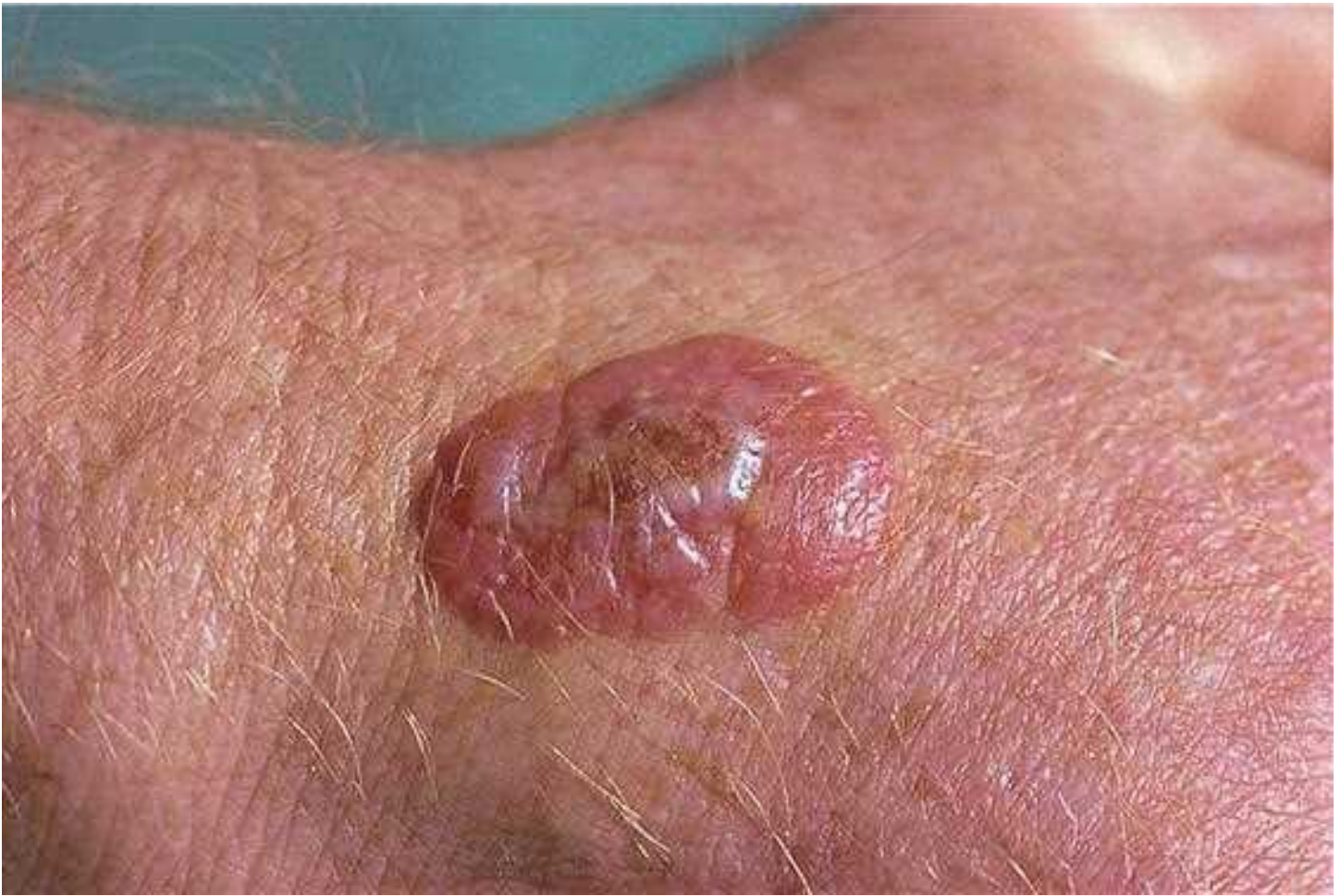

Figure 14.12 Orf.

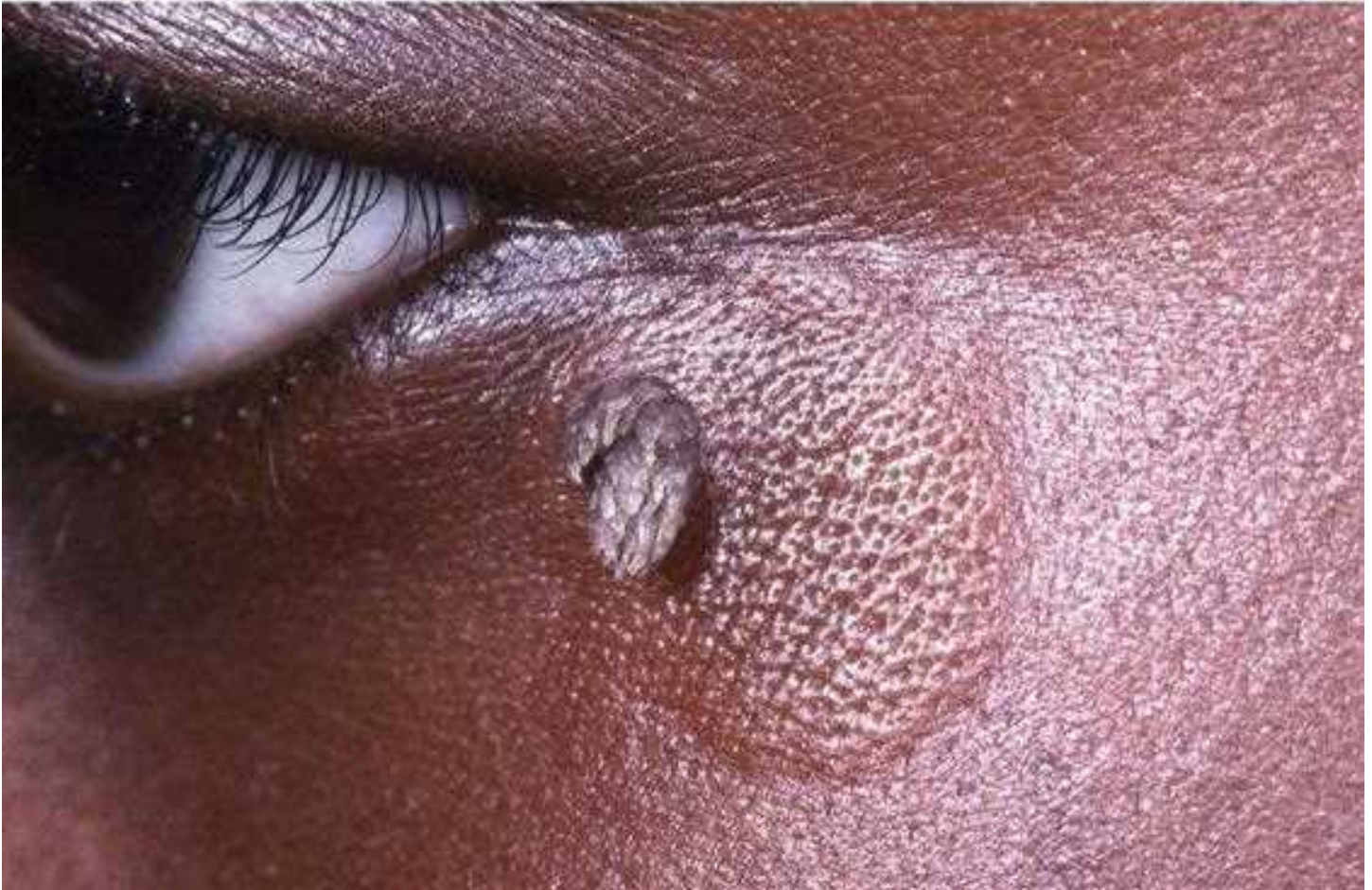Wart viruses

More than 100 different subtypes of HPV have currently been identified. HPV subtypes 6 and 11 are responsible for the majority of genital warts and subtypes 16/18 with the development of cervical/anal/vulval/vaginal/oral carcinomas. This discovery led to the production of two vaccines against HPV (Cervarix against 16, 18 and Gardasil against 6, 11, 16, 18), which are administered in three doses, mainly to teenage girls/boys. It is thought, however, that HPV infection alone does not cause malignant transformation and identified cofactors include smoking, UV light, folate deficiency, and immunosuppression. Vaccinated women should still have regular cervical smears.

Warts are classified as ano-genital/mucosal, non-genital cutaneous, and epidermodysplasia verruciformis (EV). The latter is a rare condition associated with a defect of specific immunity to wart virus. Genital HPV infections are also described as symptomatic (latent, i.e. viral DNA detected), subclinical (detected with acetic acid under magnification), or clinical (warts easily seen).

HPV only infects humans and is spread by direct contact, usually through a small break in the skin/mucous membrane. Viral warts can have a varied clinical appearance from filiform ([Figure 14.13](#)) to hyperkeratotic periungual ([Figure 14.14](#)). HPV can remain viable in the

environment at low temperatures for prolonged periods and therefore be contracted from contact with inanimate objects (changing room floors). The basal keratinocytes become infected, causing epidermal hyperplasia seen clinically as an exophytic warty lesion. Plantar warts (verruca) form painful plaques (mosaic) containing black 'dots' ([Figure 14.15](#)) that represent thrombosed capillaries.



[Figure 14.13](#) Filiform HPV wart.

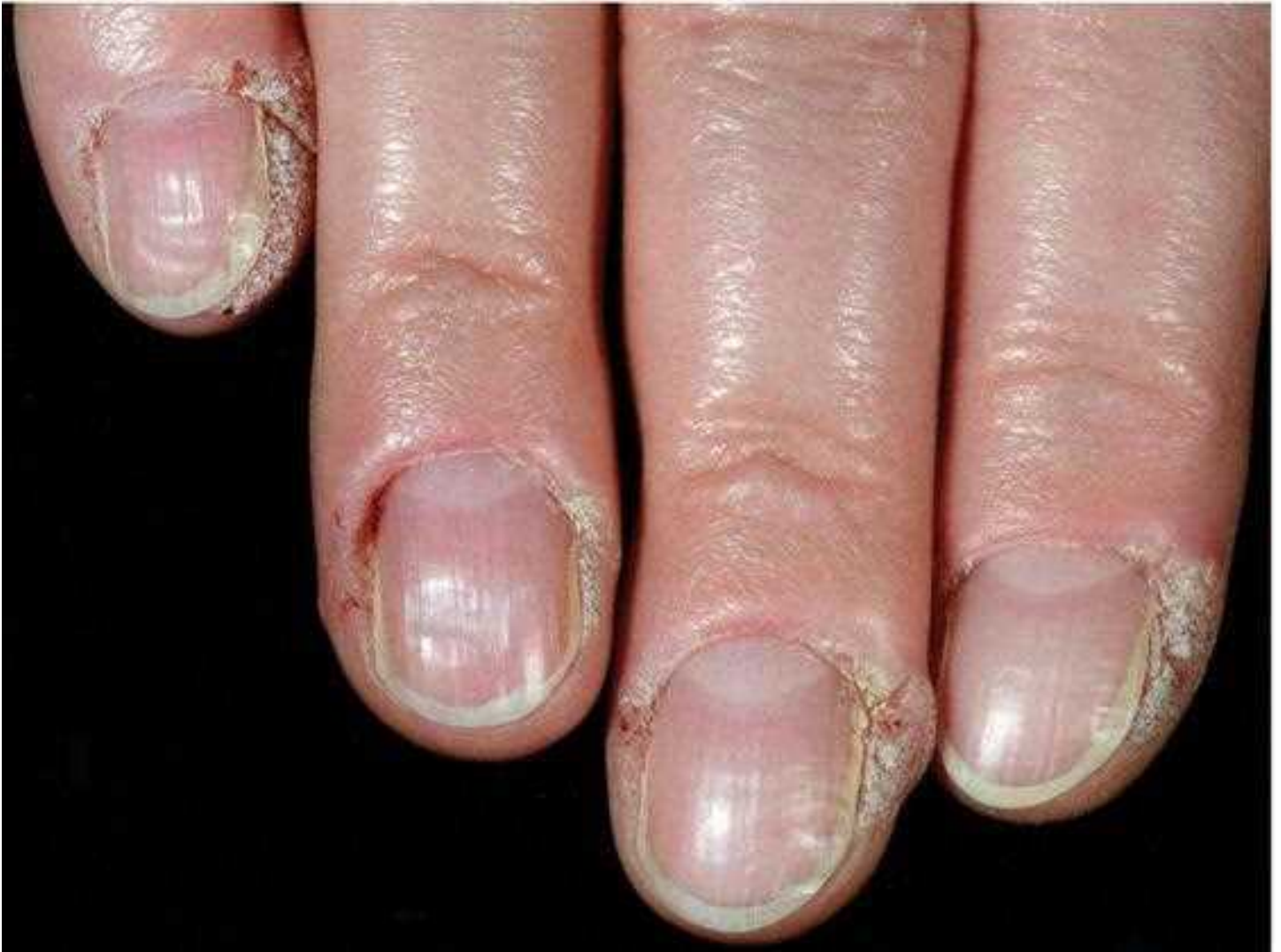

Figure 14.14 Periungual hyperkeratotic HPV warts.

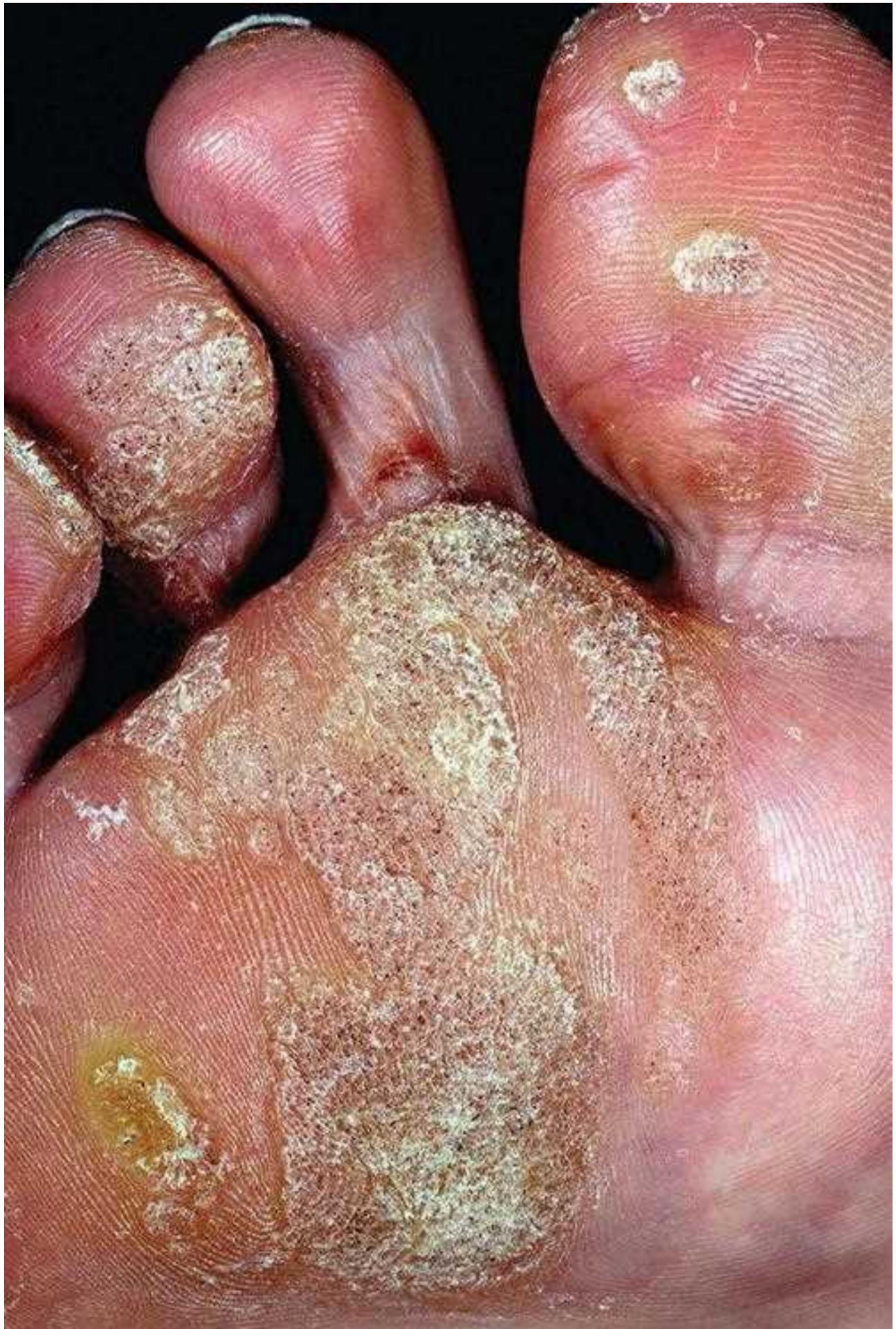

Figure 14.15 Plantar warts (verrucae).

Cutaneous HPV lesions can undergo malignant transformation, particularly in individuals who are immunosuppressed by HIV or medication. If skin lesions suddenly increase in size or are painful, then transformation to squamous cell carcinoma should be suspected. Acitretin is given to some transplant recipients to try to reduce the rate of cutaneous malignant transformation.

Treatment

Warts commonly occur in childhood and usually resolve spontaneously. There are, however numerous treatment options available (indicating that not all warts respond to a particular treatment). Warts are generally slow to clear but studies show 70% will resolve following four months of salicylic acid applied once daily. Salicylic, lactic acids, and glutaraldehyde in various formulations can be purchased over the counter and online.

Gels/ointments/paints/lotions should be applied daily after paring down the wart surface with a file or pumice stone to remove dead skin cells. Occlusion with a plaster can help drive the treatment into the wart surface.

Duct tape (used by builders) has been shown in some studies to be beneficial; however, other studies showed no benefit over placebo.

Glutaraldehyde 10% solution has been shown to have some antiviral properties and is useful in clinical practice at drying out vascular warts which are then easier to pare down.

For large/painful/recalcitrant warts other measures may be considered.

Liquid nitrogen is effective but has to be stored in special containers and replaced frequently. It can be applied with cotton wool or discharged from a special spray with a focused nozzle. Freezing is continued until a rim of frozen tissue forms around the wart, this is then repeated three times with thawing in-between cycles. Cryotherapy is accompanied by a burning sensation or pain and is not usually tolerated in young children. Subsequent pigment changes, blistering, and even scarring may occur. Carbon dioxide is more readily available and can be transported in cylinders that produce solid carbon dioxide 'snow'. The temperature (about -64°C) is not as low as that of liquid nitrogen (-196°C).

Diathermy loop cautery under local anaesthetic is effective for perianal warts. Curettage and cautery for very large warts under local anaesthetic is often used to debulk the lesions prior to other measures.

Podophyllin derived from Mayapple is available in various formulations including ointment (Posalfilin[®]) for plantar warts (daily) and solution/cream (weekly) for genital warts (Warticon[®] and Condyline[®]). Podophyllin 15% paint should only be applied to warts by a trained practitioner as it can cause chemical burns. It should not be used on large numbers of warts simultaneously because of toxicity and must never be used in pregnancy.

Immune response modifier imiquimod 5% cream is licensed for the treatment of genital warts. It stimulates cytokine production at the site of application, which is carried out three times per week. Treatment should continue until the warts resolve or up to a maximum of 16 weeks. Local irritation and inflammation can be severe, especially on mucosal surfaces. Imiquimod 5% can also be used to treat cutaneous warts but daily application is usually required under occlusion to aid penetration and efficacy.

Immunotherapy with the contact sensitiser diphencyprone (DPC) can also be effective. Following sensitisation to DPC increasing concentrations are painted onto the warts to cause a local inflammatory response. At six months, 60% complete cure rates are reported in patients with previously highly recalcitrant warts.

Other treatments include carbon dioxide laser vapourisation, 5-fluorouracil, intralesional bleomycin and interferon alpha, oral cimetidine, and oral isotretinoin.

Viral diseases with rashes

Many childhood viral illnesses have become less common because of increased availability of effective vaccines ([Box 14.3](#)). However, these vaccines are not universally available or accepted by parents, leading to regional outbreaks among susceptible populations. Approximately 880 000 deaths from measles occur worldwide each year. Recently, there has been a marked resurgence of measles in parts of the UK following a decline in take-up of MMR (measles/mumps/rubella) vaccinations. Measles is probably the best-known example of a viral exanthema – a widespread reactive cutaneous eruption that usually results from RNA viruses.

Box 14.3 Viral diseases with rashes

- Measles
- Rubella
- Infectious mononucleosis
- Erythema infectiosum
- Roseola infantum
- Gianotti–Crosti syndrome
- Hand, foot, and mouth disease
- Primary HIV infection.

Measles usually affects children under the age of five years and is highly contagious. The incubation period is 7–14 days. Prodromal symptoms include fever, malaise, upper

respiratory symptoms, conjunctivitis, and photophobia. Children are miserable and look unwell. Initially, Koplik's spots (white spots with surrounding erythema) ([Figure 14.16](#)) appear on the oral mucosa and then within two days a macular rash appears, initially behind the ears and on the face and trunk, and then on the limbs ([Figure 14.17](#)). Papules form and coalesce and may be haemorrhagic or vesicular, which fade to leave brown patches. Rarely encephalitis, otitis media, and bronchopneumonia may complicate the infection. Reliable rapid diagnostic testing can be undertaken using oral fluid samples to detect measles virus RNA using real-time RT-PCR. Urine and serology tests are also available. There is no specific treatment for measles except supportive care; however, some studies have shown that vitamin A supplementation during the acute illness can reduce morbidity/mortality. Parents should be encouraged to get their children vaccinated with two doses of live-attenuated MMR.

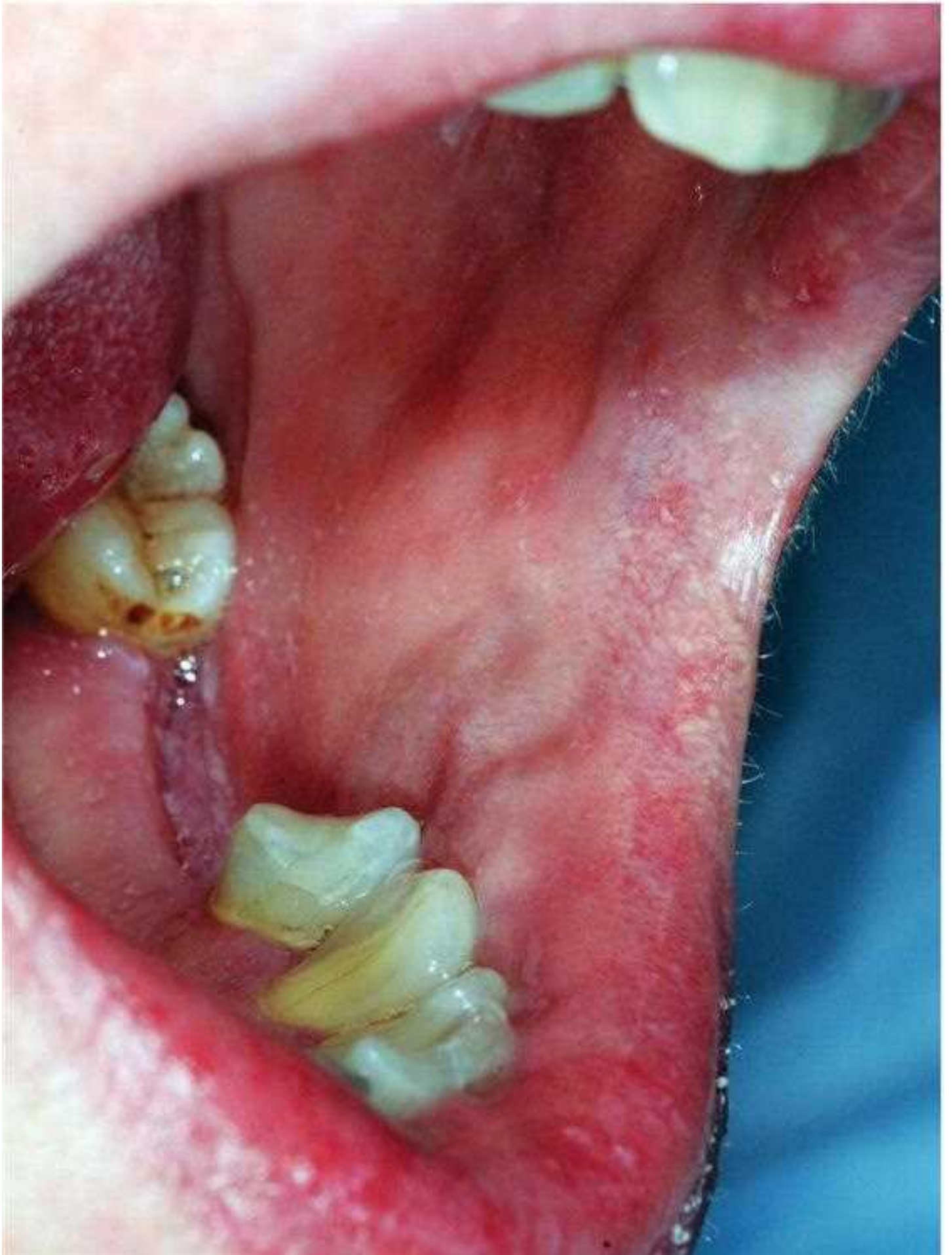

Figure 14.16 Koplick's spots in measles.

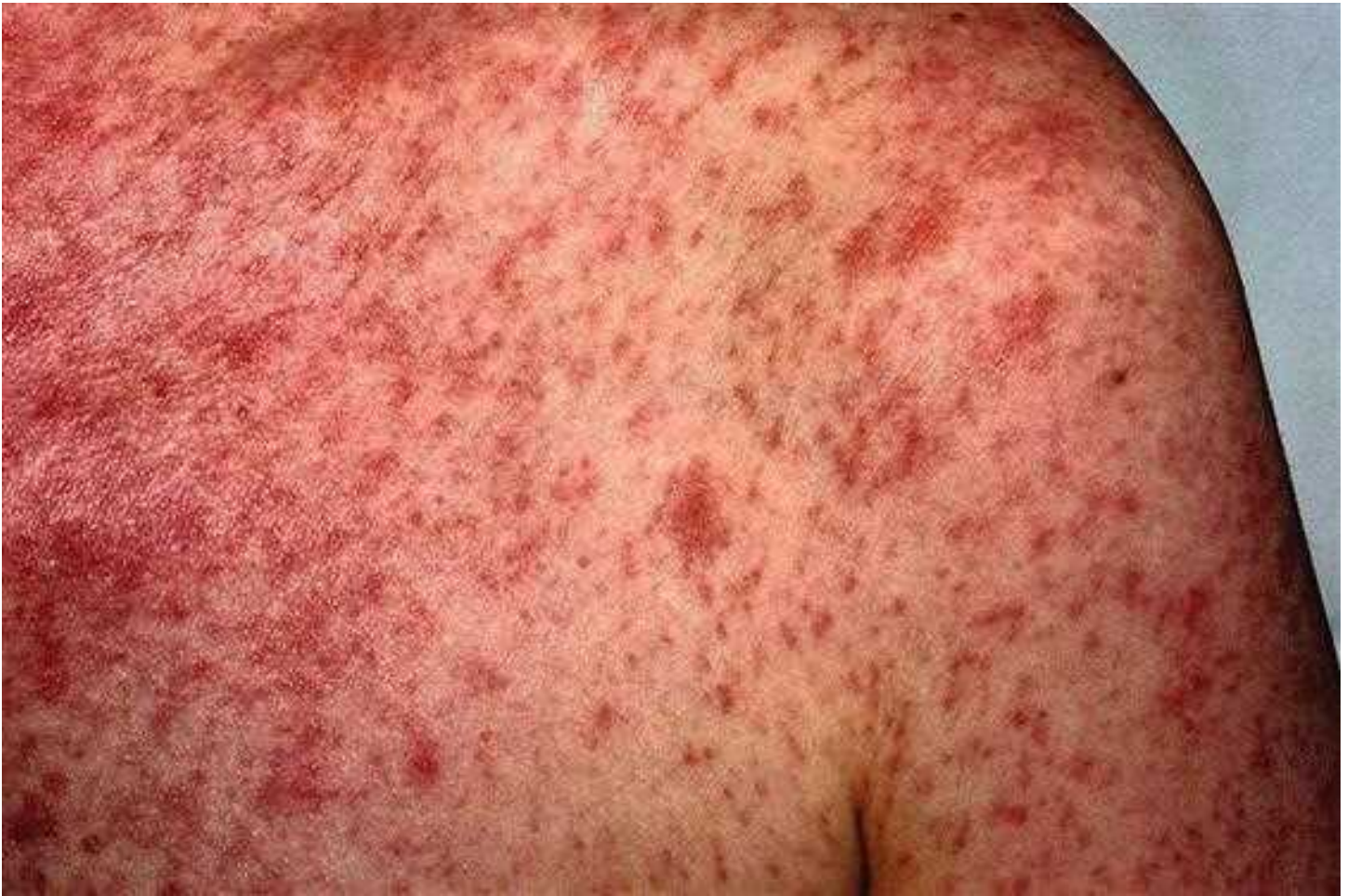

Figure 14.17 Measles rash.

Rubella affects children and young adults who may display prodromal fever, malaise, and upper respiratory tract symptoms. The incubation period is 14–21 days. First signs of the disease include erythema of the soft palate and lymphadenopathy. Later, pink macules appear on the face, spreading to trunk and limbs over one to two days ([Figure 14.18](#)). The rash clears over one to two days (occasionally no rash develops). Infection during pregnancy can cause congenital defects. The risk is highest in the first trimester. The acute diagnosis is usually clinical with confirmation from convalescent serum antibody titres. Prevention through immunisation of school-aged girls is highly effective.

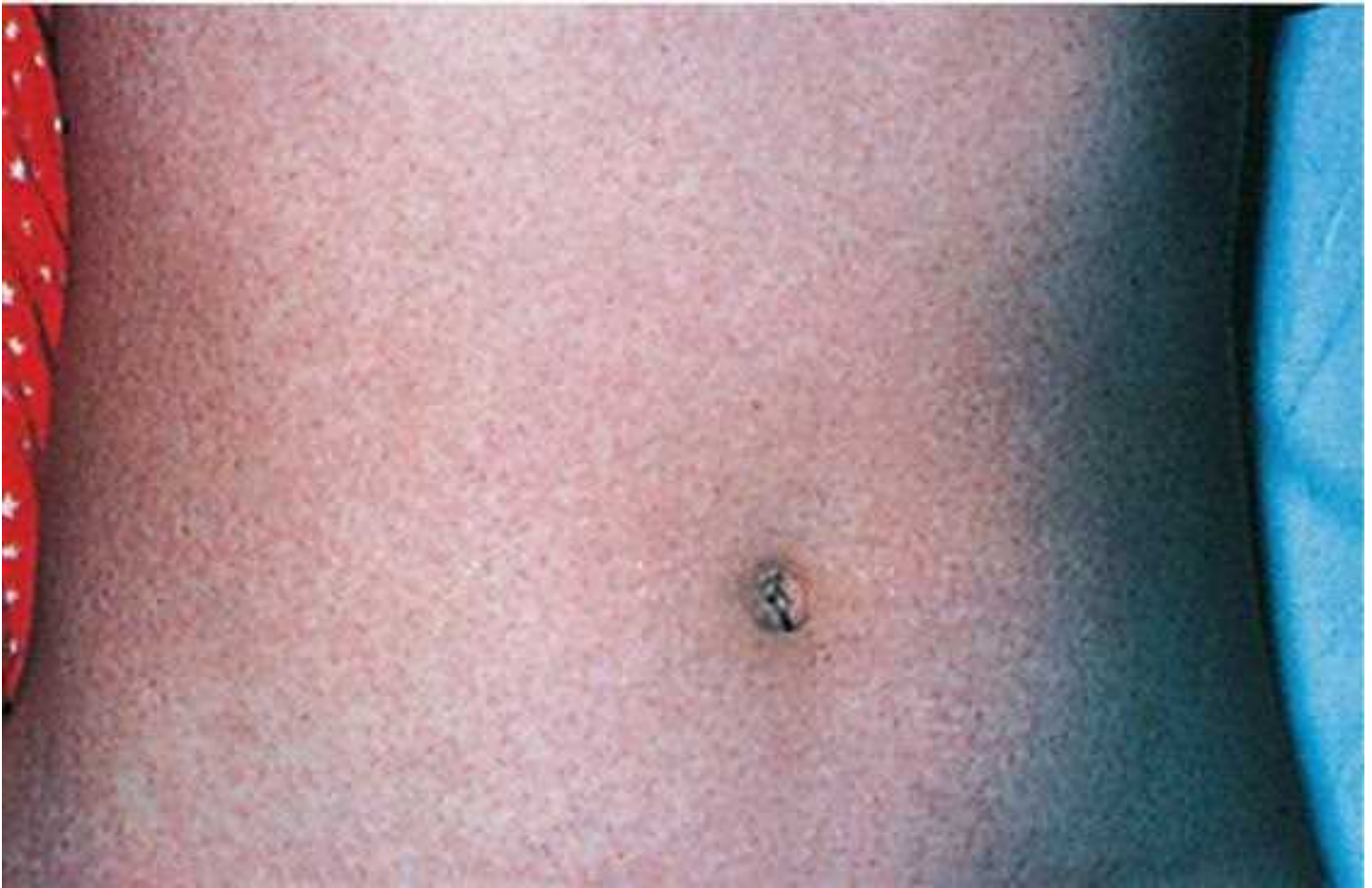

Figure 14.18 Rubella.

Erythema infectiosum (*fifth disease*) is caused by parvovirus B19, which mainly affects children aged 2–10 years. The incubation period is 5–20 days. The disease manifests as a prodrome of mild fever before the onset of a hot erythematous eruption on the cheeks – hence the ‘slapped cheek syndrome’. Over two to four days a maculopapular eruption develops on the limbs and trunk ([Figure 14.19](#)), which can extend to the hands, feet and mucous membranes, and then fades over one to two weeks. The diagnosis can be confirmed by serology for parvovirus B19-specific IgM antibody. Complications include thrombocytopenia, arthropathy, and foetal abnormalities if acquired in utero.

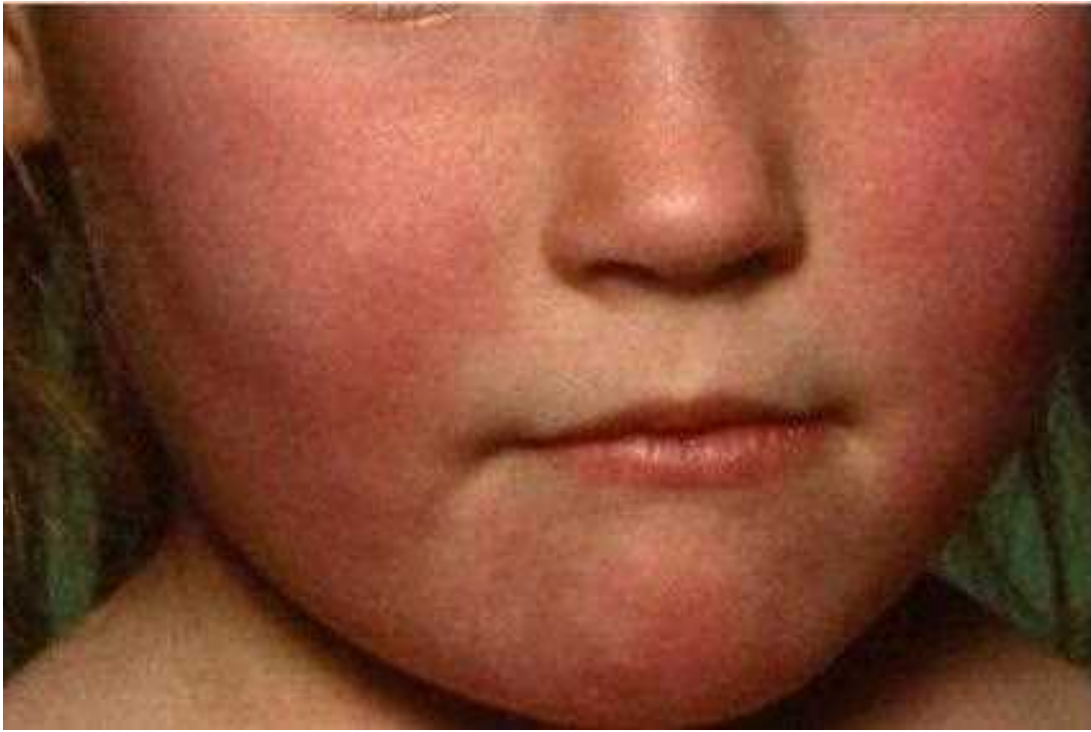

Figure 14.19 Erythema infectiosum.

Roseola infantum (sixth disease) is caused by human herpesvirus type 6 (HHV6). This mainly affects infants below two years of age. The incubation period is 10–15 days. The onset of a rose-pink maculopapular rash appearing on the neck and trunk usually follows a few days of fever. The rash can spread to the limbs before clearing over one to two days. The diagnosis is made on clinical ground; however, HHV6 virus can be isolated from the blood or serology to detect antibody responses if necessary. Young infants may develop febrile convulsions. Care is supportive.

Gianotti–Crosti syndrome is the term given to a papular viral exanthem caused by infections due to Epstein–Barr virus (EBV) and hepatitis B. Children under the age of 14 years are most commonly affected. The incubation period is unknown; however, children generally present with malaise, lymphadenopathy, and an acral eruption. Initially the rash consists of erythematous papules on the face, neck, limbs, buttocks, palms, and soles ([Figure 14.20](#)). The rash is usually itchy and may become purpuric before it slowly settles over two to six weeks. Viral-specific serology can be requested. Rarely lymphadenopathy and hepatomegaly can persist for many months. The symptoms from the exanthem can be relieved with a topical steroid.

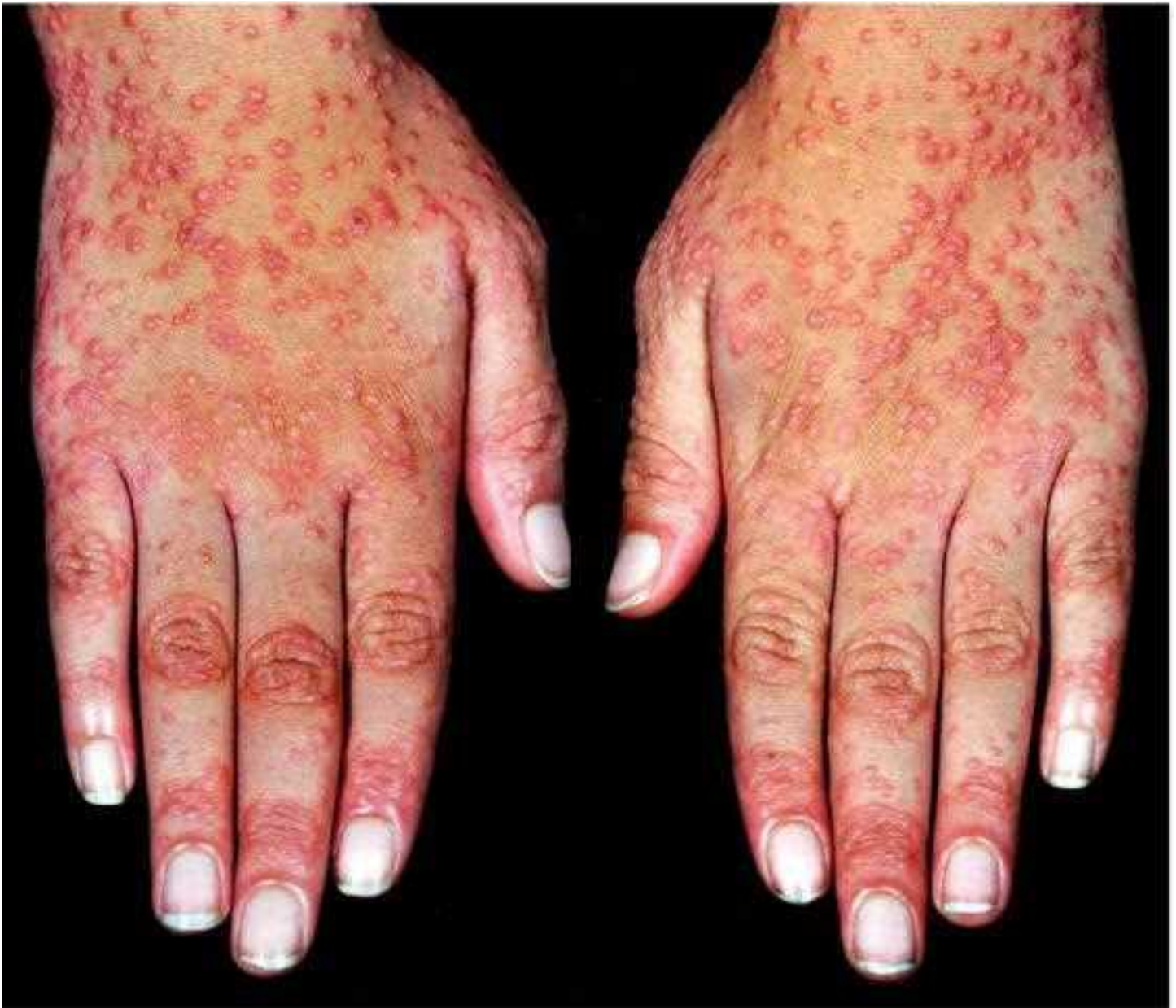

Figure 14.20 Gianotti–Crosti syndrome.

Hand, foot, and mouth disease (HFMD), as the name suggests, is an infection causing lesions on the hands/feet and in the mouth. It is most commonly associated with Coxsackievirus A16 and Enterovirus 71 (the later can be associated with severe illness, flaccid paralysis) and affects mainly children. The virus is highly contagious with a short incubation period of three to six days. Young children in particular present with fever, headache, and malaise alongside the rash. The characteristic rash consists of intense erythema surrounding yellow-grey vesicles 1–1.5 mm in diameter on palms/soles and lips ([Figure 14.21](#)). A global upsurge of Coxsackie A6 has led to atypical presentations of HFMD in children and adults with a more severe and generalised eruption ([Figure 14.22a,b](#)). Onychomadesis (nail shedding) is seen in 20% of these Coxsackie A6 cases two months after the infection ([Figure 14.23](#)). Treatment is supportive care. The rash and symptoms usually settle rapidly over four to six days (two to three weeks for A6). The virus can be rapidly isolated from lesions using viral swabs or be identified in the stools. Serology for viral-specific antibody can also be requested. Rarely,

erythema multiforme can also occur.

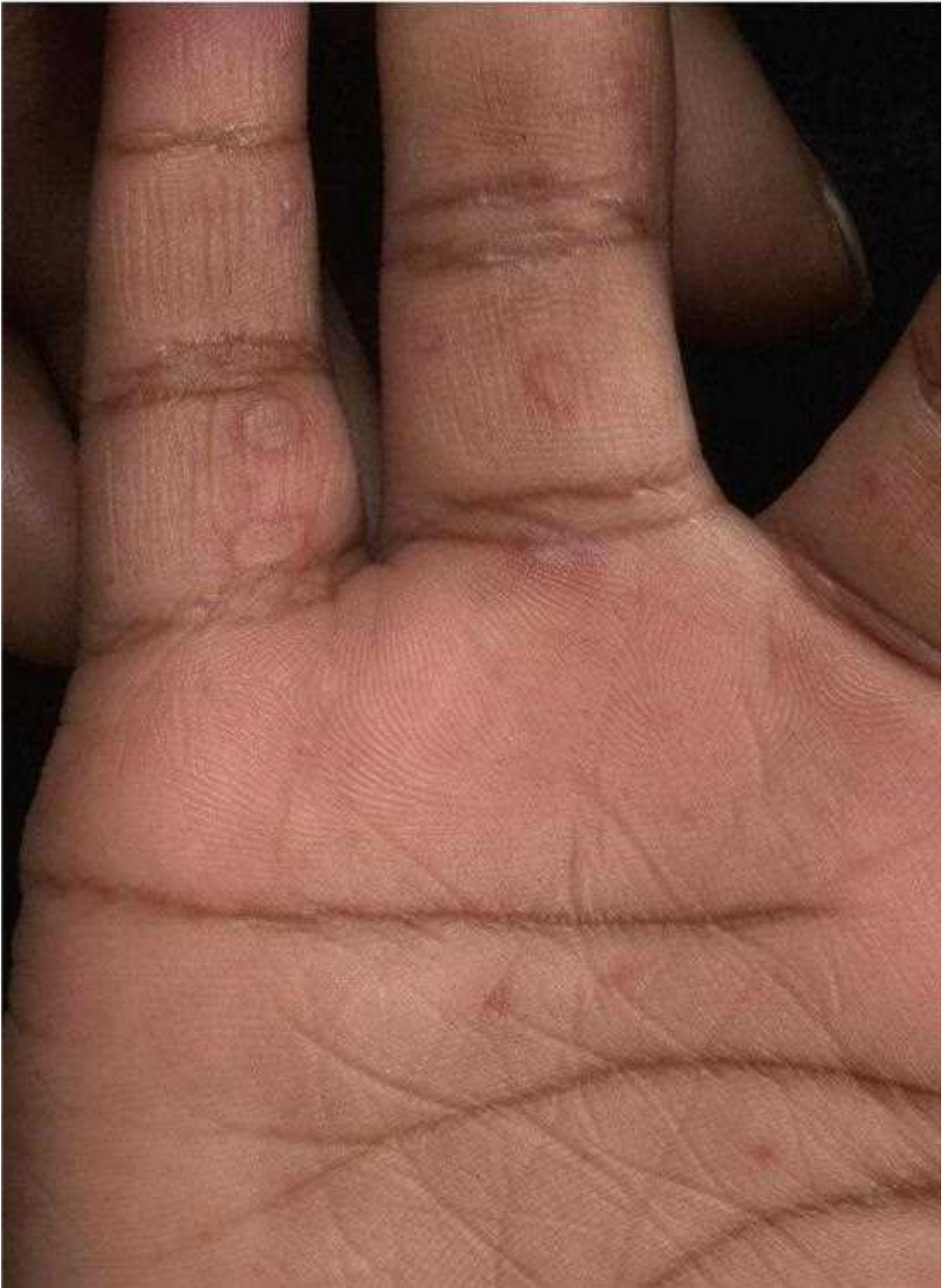

Figure 14.21 Classic oval blisters in HFMD Coxsackie A16.

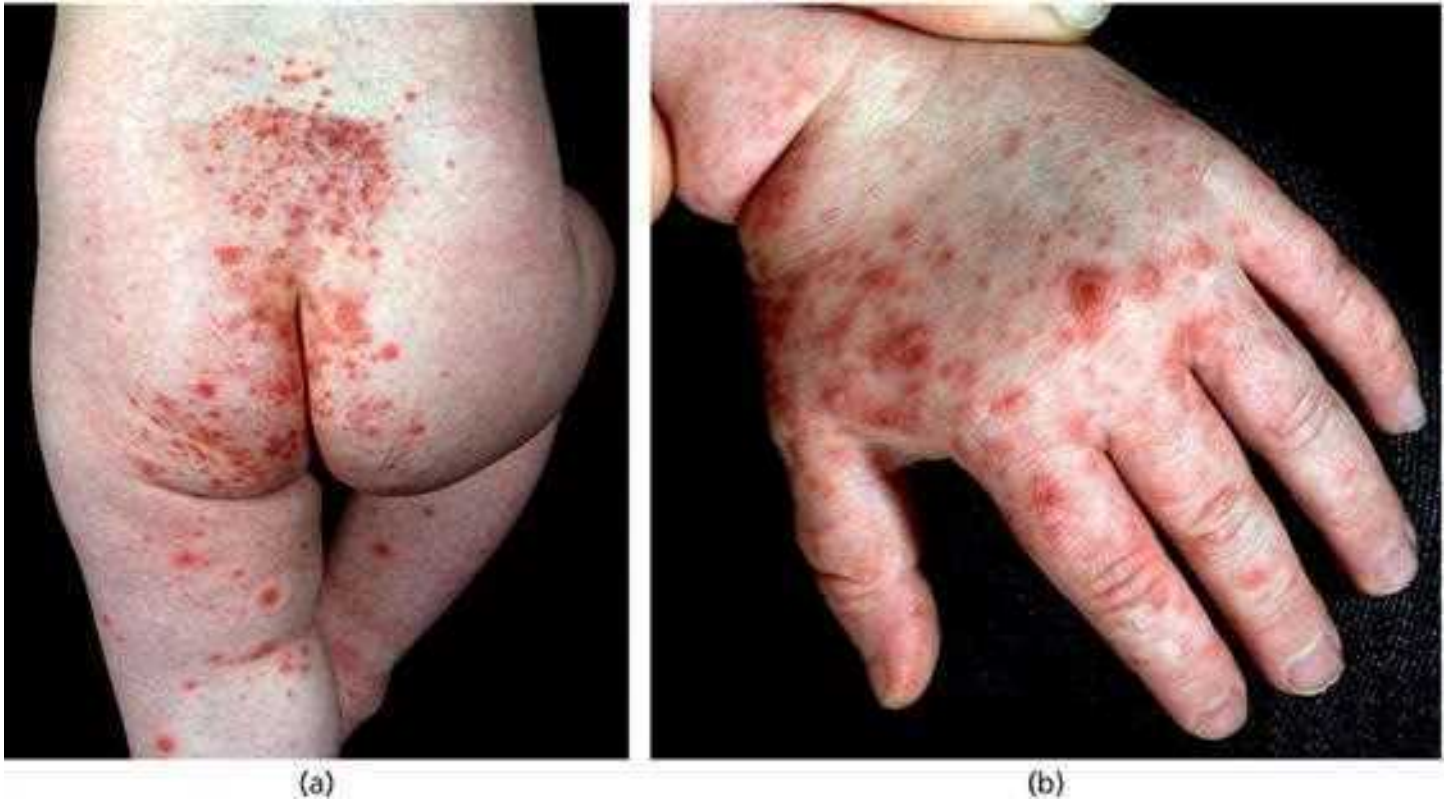

Figure 14.22 (a and b) More severe form of HFMD Coxsackie A6.

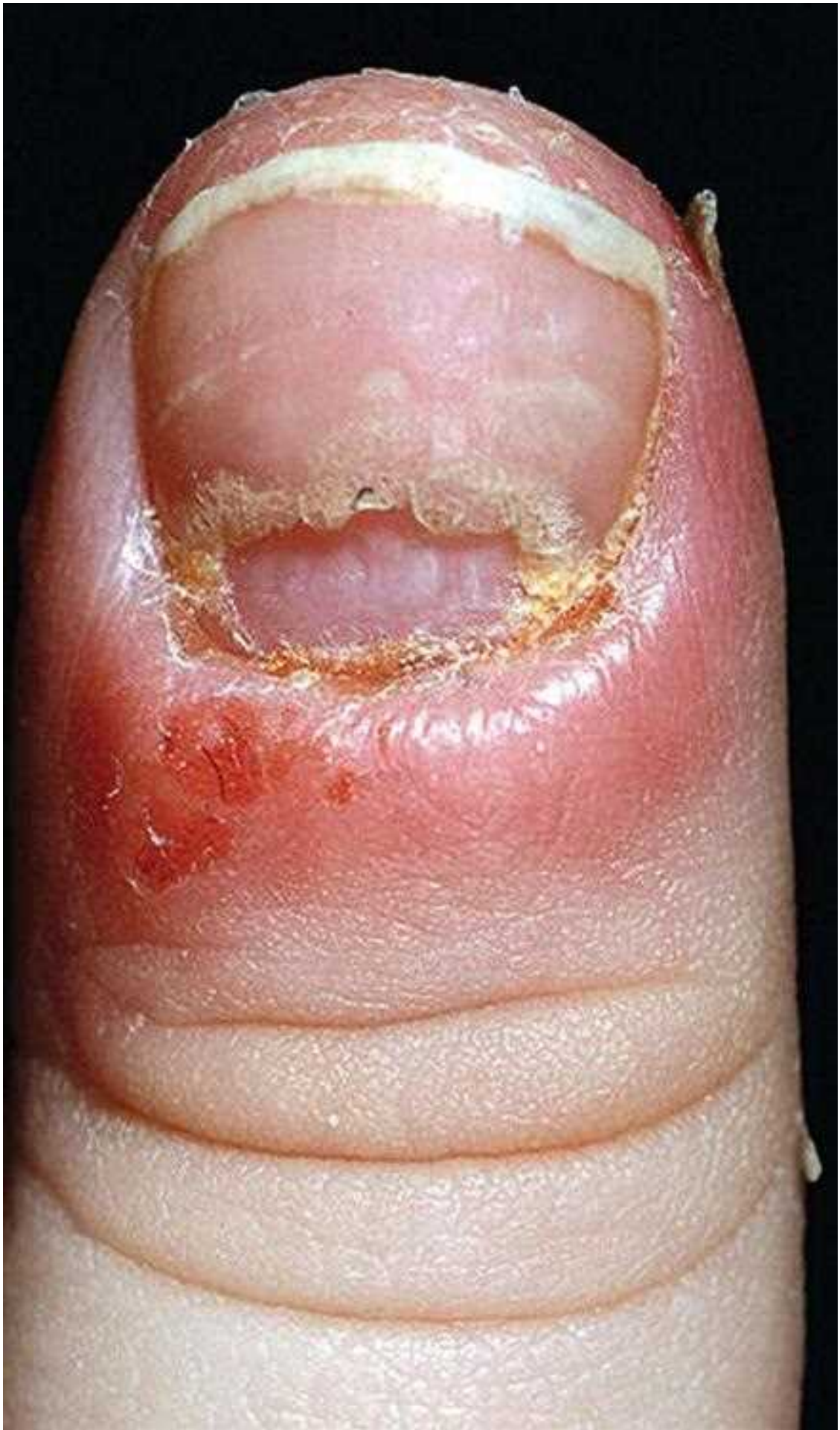

Figure 14.23 Onychomadesis (nail shedding) one to two months after HFMD Coxsackie A6.

Further reading

Biluk, E.J. (2011). *Microbiology Case Studies: Bacterial, Parasitic, Viral and Fungal Diseases of the Skin and Wounds*. Barnes & Noble ebook.

Straus, E.G. and Strauss, J.H. (2007). *Viruses and Human Disease*, 2e. California: Academic Press.

CHAPTER 15

HIV and the Skin

Rachael Morris-Jones

Guy's and St Thomas' NHS Foundation Trust, London, UK

OVERVIEW

- HIV infection leads to a progressive fall in the CD4 count with resultant immunosuppression and, if untreated, eventually AIDS.
- A widespread maculopapular rash occurs in 50% of patients during primary HIV infection.
- Cutaneous eruptions in the context of HIV are common, atypical, and frequently severe.
- Common skin complaints associated with HIV include nodular prurigo, seborrhoeic dermatitis, and pruritic papular eruption.
- Adverse drug eruptions are common in HIV patients, from mild toxic erythema to severe life-threatening toxic epidermal necrolysis.
- Skin conditions often improve as the immune system is restored with antiretroviral therapy.
- As the immune system reconstitutes there may be a brisk inflammatory response to high levels of antigen building up in chronic infections.

Introduction

The human immunodeficiency virus (HIV) is the cause of the acquired immune deficiency syndrome (AIDS). Worldwide, 36.7 million children and adults are currently living with HIV according to current WHO (World Health Organization) statistics (2016). 54% of adults and 43% of children living with HIV are currently taking antiretroviral therapy (ART). Globally it is estimated that 70% of HIV-positive individuals know their status. As yet, there is no effective vaccine against HIV. Methods for reduced transmission of HIV include condoms, voluntary male circumcision, prevention of mother-to-child transmission, sterile injection equipment, screening blood products, and pre-exposure prophylaxis for sero-discordant couples are starting to reduce the number of new people becoming infected. Trials of pre-exposure prophylaxis with tenofovir disoproxil fumarate (TDF) 300 mg alone or with emtricitabine 200 mg have been shown to reduce the risk of acquiring HIV by 60–90% depending on adherence. It is estimated that between 2000 and 2016 there has been a 40% reduction in new HIV infections.

HIV is an RNA retrovirus that replicates itself by reverse transcriptase to produce a DNA copy; this then becomes incorporated into the host DNA where further replication occurs. HIV persists in the body within the host's immune cells – the CD4 lymphocytes and monocytes – thereby directly weakening the host's immune system. Initially, the virus remains latent for an average of 10 years before causing profound immunosuppression. The extent to which an individual's immune system is affected by HIV is measured through the CD4 cell count and the HIV viral load. AIDS is defined as a CD4 count of less than 200 cells/ μ l, or HIV associated with any one of 26 (mainly opportunistic infections) conditions.

Patients with low CD4 counts who are profoundly immunosuppressed tend to have more frequent and more severe skin disorders. Common cutaneous diseases such as psoriasis, eczema, seborrhoeic dermatitis (SD), and acne tend to be more severe, have atypical features and are often resistant to conventional treatments. The spectrum of cutaneous manifestations in HIV has changed over the past decade because of the use of ART. Once a patient's immune system has reconstituted on ART and their viral load remains undetectable they are thought to no longer be able to transmit the virus.

When ART is initiated occasionally the so-called immune reconstitution inflammatory syndrome (IRIS) can occur, where there is a brisk inflammatory response related to the presence of previously 'unrecognised antigen' e.g. from tuberculosis, cryptococcus, varicella zoster virus, etc. This paradoxical worsening, for example in pre-existing herpes simplex viral (HSV) in the genital region, on starting ART can give atypical clinical appearances such as nodular hyperkeratotic lesions. Treatment with valaciclovir and imiquimod is usually effective without the need to stop or reduce the ART. For other opportunistic infections these should be treated before the initiation of ART to try to prevent IRIS developing.

In general, HIV/AIDS should be considered in any patient with a florid or atypical inflammatory skin disease that is resistant to treatment or who has severe and extensive infection of the skin. Because of the atypical nature of cutaneous manifestations in HIV medical practitioners should have a low threshold for performing a skin biopsy for histology and culture ([Box 15.1](#)). Many modern health care systems are introducing HIV screening for all patients newly registering at primary care facilities in the community or any patient who attends their local hospital. Diagnosing and treating those with HIV early on in the disease will result in less morbidity, less premature mortality, and reduced onwards transmission and ultimately be cost-effective.

Box 15.1 HIV and the skin

- Skin disorders affect 80% of HIV patients.
- Fifty percent develop a rash during the primary HIV infection, so-called 'seroconversion'.
- Severity of skin disorders usually increases with decreasing CD4 counts.
- Cutaneous presentations are frequently atypical.
- Consider taking a skin biopsy for histology and culture in any HIV patient with a rash.
- Management of skin diseases can be difficult; ART is usually beneficial.
- Patients have a high risk of developing adverse drug reactions.

Stages of HIV

Primary HIV infection

Eighty percent of individuals have acute signs and symptoms associated with their primary HIV infection – the so-called 'seroconversion illness'. The incubation period is two to six weeks. Symptoms include fever, malaise, headache, nausea, vomiting, and diarrhoea. Clinical signs include cervical lymphadenopathy, pharyngitis, weight loss, and rash. The skin eruption associated with primary HIV infection is present in 50% of patients and consists of a maculopapular rash mainly on the face, neck, and trunk lasting two to three weeks ([Figure 15.1](#)). Some patients develop a papulovesicular eruption or erosions in the mouth rather than a classic viral exanthem. During seroconversion abnormalities in the full blood count (FBC) may be seen (leukopenia, lymphopenia, thrombocytopenia, low haemoglobin) and diagnostically HIV RNA may be detected in the plasma.

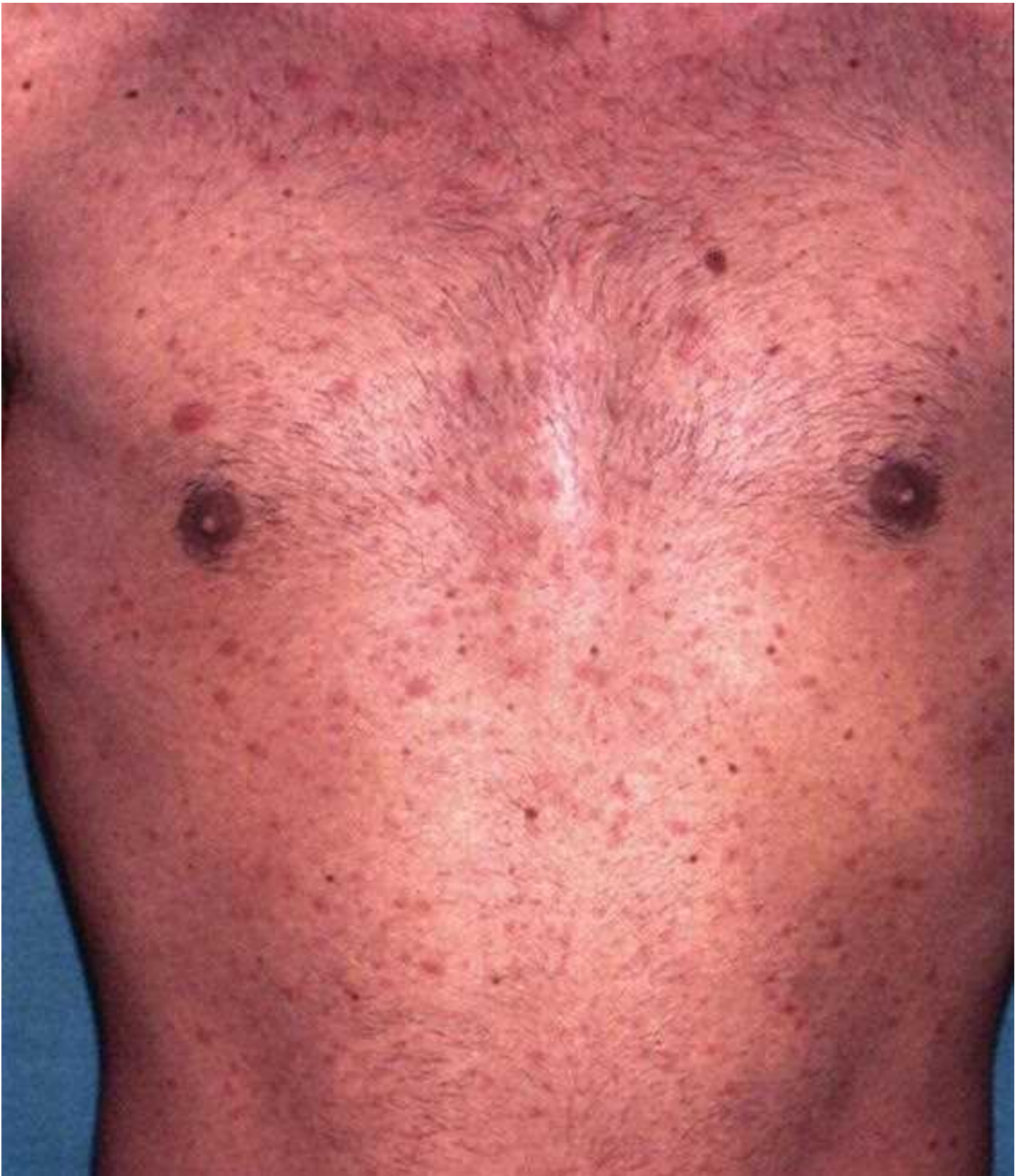

Figure 15.1 Primary HIV infection: seroconversion rash.

Early stages

Within one to two months of the primary infection, 50% of patients will have detectable

antibodies to HIV. The proportion of CD4 lymphocytes variably decreases and this is associated with an increased frequency and severity of skin disorders. Patients may experience worsening of premorbid skin complaints such as psoriasis or present de novo with sudden florid skin disease such as SD. Adverse drug reactions are more frequent and often severe.

Late-stage HIV infection

As the patient's immune system becomes increasingly suppressed and the CD4 count falls below 200 cells/ μ l, he or she is classified as having AIDS. Patients with AIDS may present with severe widespread dermatoses including SD, crusted scabies, multidermatomal varicella zoster virus, Kaposi's sarcoma (KS), widespread fungal/yeast infections, bacillary angiomatosis (BA), and eosinophilic folliculitis (EF). These conditions are described in more detail below.

Skin disorders in HIV

Seborrhoeic dermatitis

Fifty percent of HIV patients develop SD compared to 1–3% of the general population. SD may be one of the first indicators of HIV infection. It is interesting to note that as the immune system becomes increasingly suppressed by HIV, there is a higher incidence of allergic-type reactions. SD is thought to be an allergic contact dermatitis to the lipophilic yeast *Malassezia globosa*, which is a normal skin commensal. SD classically affects the scalp, eyebrows, nasal creases, moustache, and anterior chest. Adherent greasy scales cover underlying inflammatory eczema which may be very itchy ([Figure 15.2](#)). Management is aimed at reducing the numbers of yeast on the skin and suppressing the eczema. Ketoconazole shampoo can be used to wash the body and scalp once/twice weekly to reduce yeast carriage. Twice-daily topical steroids (\pm miconazole) can be used to control the dermatitis. In refractory cases systemic imidazoles such as itraconazole 200 mg daily for one to two weeks can be effective. However, if the patient's immune system reconstitutes with ART, SD usually abates ([Box 15.2](#)).

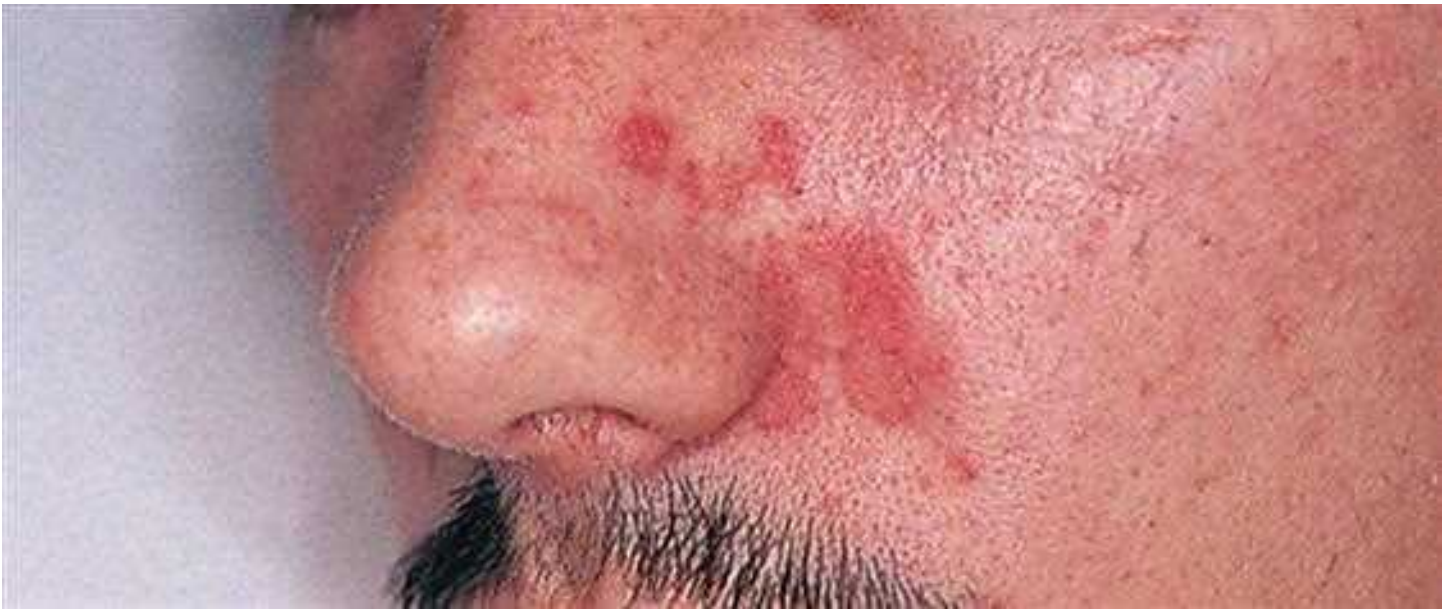

Figure 15.2 Seborrheic dermatitis.

Box 15.2 Skin disorders in HIV/AIDS

- Seborrheic eczema (severe)
- Psoriasis (severe)
- Fungal infections (extensive, recurrent)
- Bacterial infections
- Viral infections
- Papular pruritic eruption
- Eosinophilic folliculitis
- Kaposi's sarcoma (epidemic)
- Nodular prurigo
- Frequent adverse drug reactions (often severe)
- Oral hairy leukoplakia (OHL).

Psoriasis

It is estimated that 5% of HIV patients develop psoriasis and of those 50% suffer from psoriatic arthropathy. The pathophysiology of psoriasis is complex; however, there is a general consensus that it is a T-cell mediated autoimmune disease. The paradox in HIV is that immune dysregulation of T-cells goes hand in hand with severe, extensive, and

refractory psoriasis, indicating that there are likely to be other cells involved in the development of psoriasis such as Th17. A dermatology specialist is usually needed to manage patients with HIV and severe psoriasis. Conventional immunosuppressive treatments such as ciclosporin and methotrexate can be used with care. Drug interactions need to be considered with ciclosporin. PUVA (psoralen plus ultraviolet A) can be very useful at controlling extensive thick plaques, particularly in patients with pigmented skin.

Eosinophilic folliculitis (EF)

EF is an intensely pruritic condition of unknown aetiology that tends to occur when the CD4 count falls below 250 cells/ μ l. Speculation that the causative agent is *Demodex*, a commensal skin mite that lives in the perifollicular region has not been proven in studies. An autoimmune process with responses against the sebocytes/sebum has also been suggested. Clinically, patients present with multiple discrete, erythematous, perifollicular papules and pustules affecting the face, neck, and trunk ([Figure 15.3](#)) that can look like acne (but no comedones are seen). Differential diagnoses include *Staphylococcus* or *Pityrosporum* folliculitis and acne. Microbiological swabs are negative in EF. Peripheral eosinophilia and raised IgE may be noted. ART therapy can help if the CD4 count rises above 250 cells/ μ l. Ultraviolet B (UVB) phototherapy can be very effective. Topical corticosteroids may reduce pruritus. Systemic indomethacin, minocycline, and itraconazole have also been used. Low-dose oral isotretinoin can be beneficial.

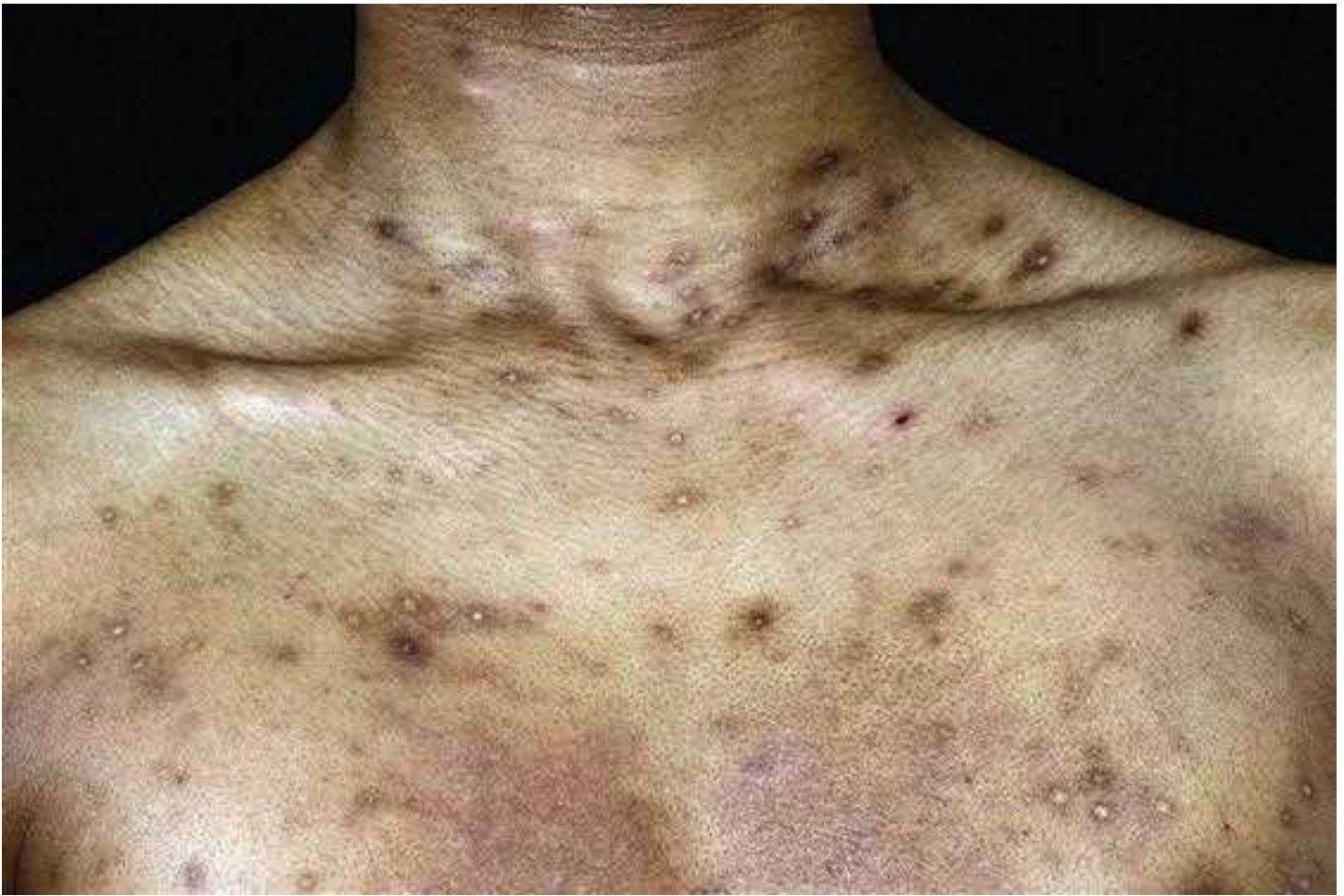
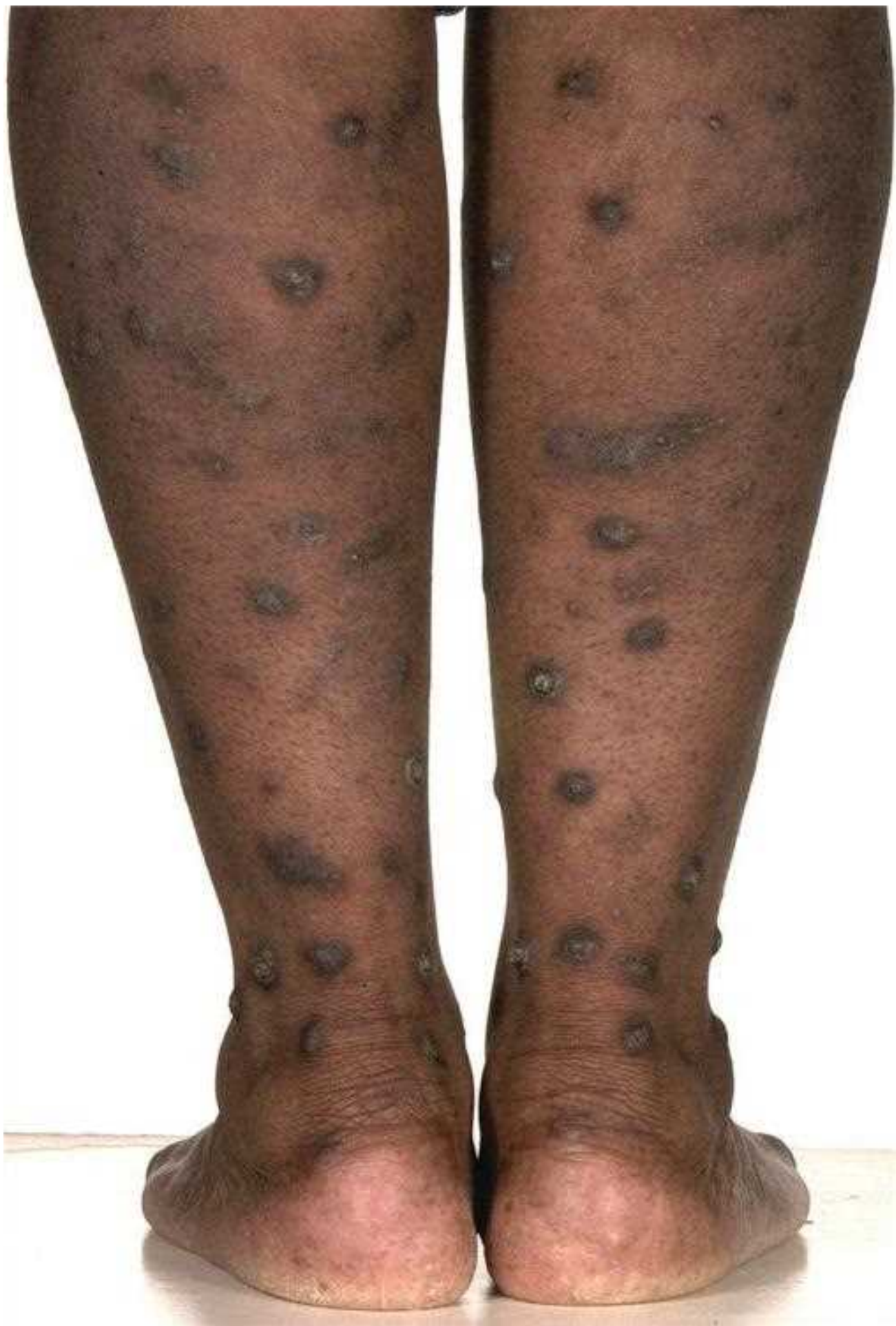
Figure 15.3 Eosinophilic folliculitis.

Nodular prurigo

Non-specific pruritus is common in HIV patients, with 30% developing itchy nodular lesions on the skin, called *nodular prurigo*. The cause is unknown. Classically, small red papules develop on the trunk and limbs, which itch intensely, and through scratching chronic nodules form ([Figure 15.4](#)). Nodular prurigo can be very aggravating and persistent. Relief from pruritus may be gained by regular applications of emollients. Potent topical steroids applied daily under occlusion of wraps or body suits may flatten lesions and relieve itching. UVB phototherapy and amitriptyline can also be used.



[Figure 15.4](#) Nodular prurigo.

Infections

Fungal infections

Superficial dermatophyte and yeast infections are frequently more extensive in HIV patients with a higher incidence of dissemination systemically. Deep fungal infections that are not normally seen in healthy individuals occur in AIDS patients as opportunistic infections. *Cryptococcus neoformans* and *Histoplasma capsulatum* may cause inflammatory papular and necrotic lesions, particularly in the later stages of the disease.

Candidiasis is common and often associated with secondary bacterial infections. The oral mucosa can be extensively infected with *Candida albicans* that spreads to the pharynx and oesophagus. Clinically, there are extensive white plaques on a background of erythema. Candidiasis of the skin has a predilection for the flexures where classically there is confluent erythema with peripheral satellite lesions ([Figure 15.5](#)). Patients may complain of cutaneous discomfort and itching and oral ulceration and dysphagia ([Figure 15.6](#)). Women with HIV can develop severe vulvovaginitis caused by chronic candidiasis.

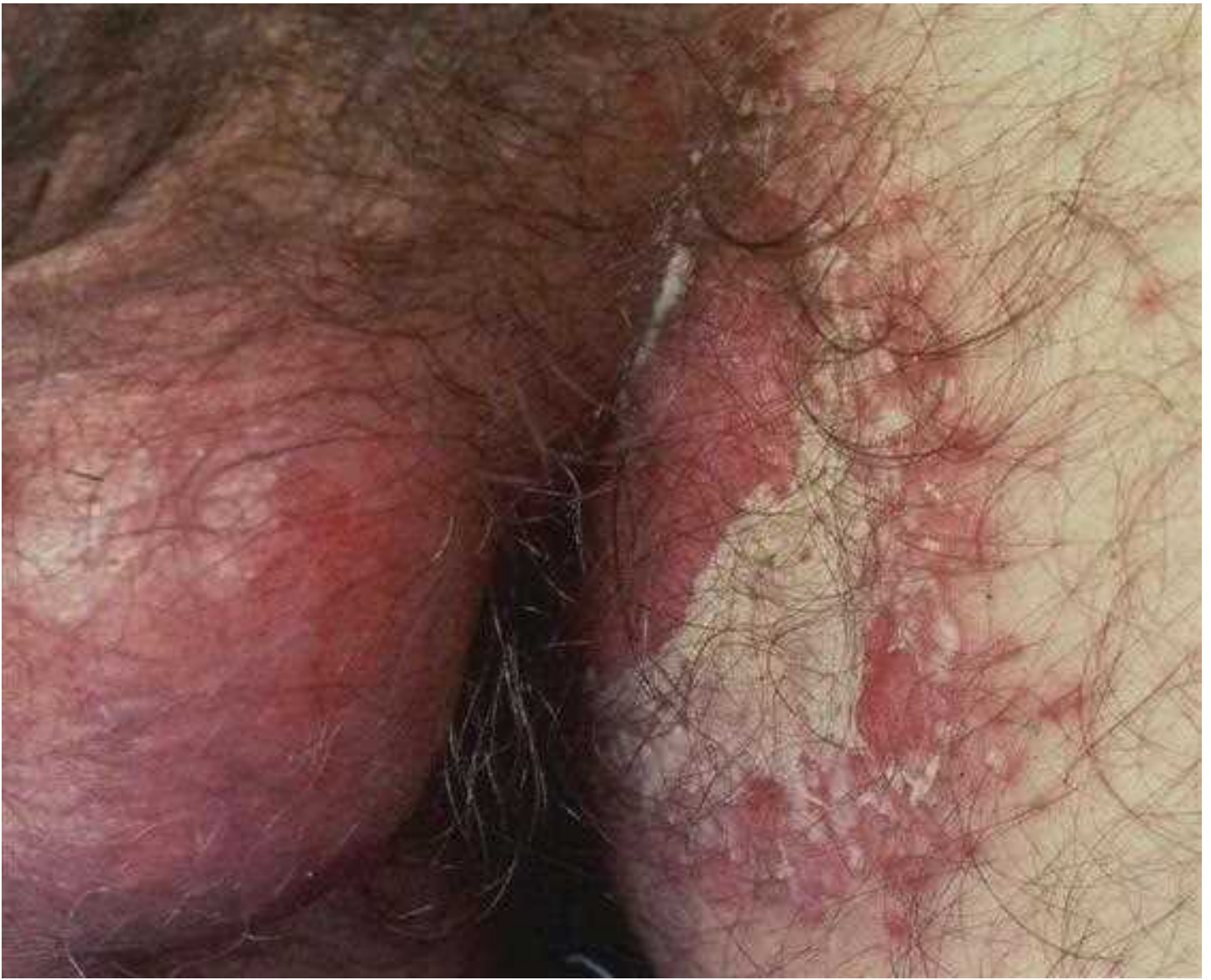

Figure 15.5 Flexural *Candida* infection.

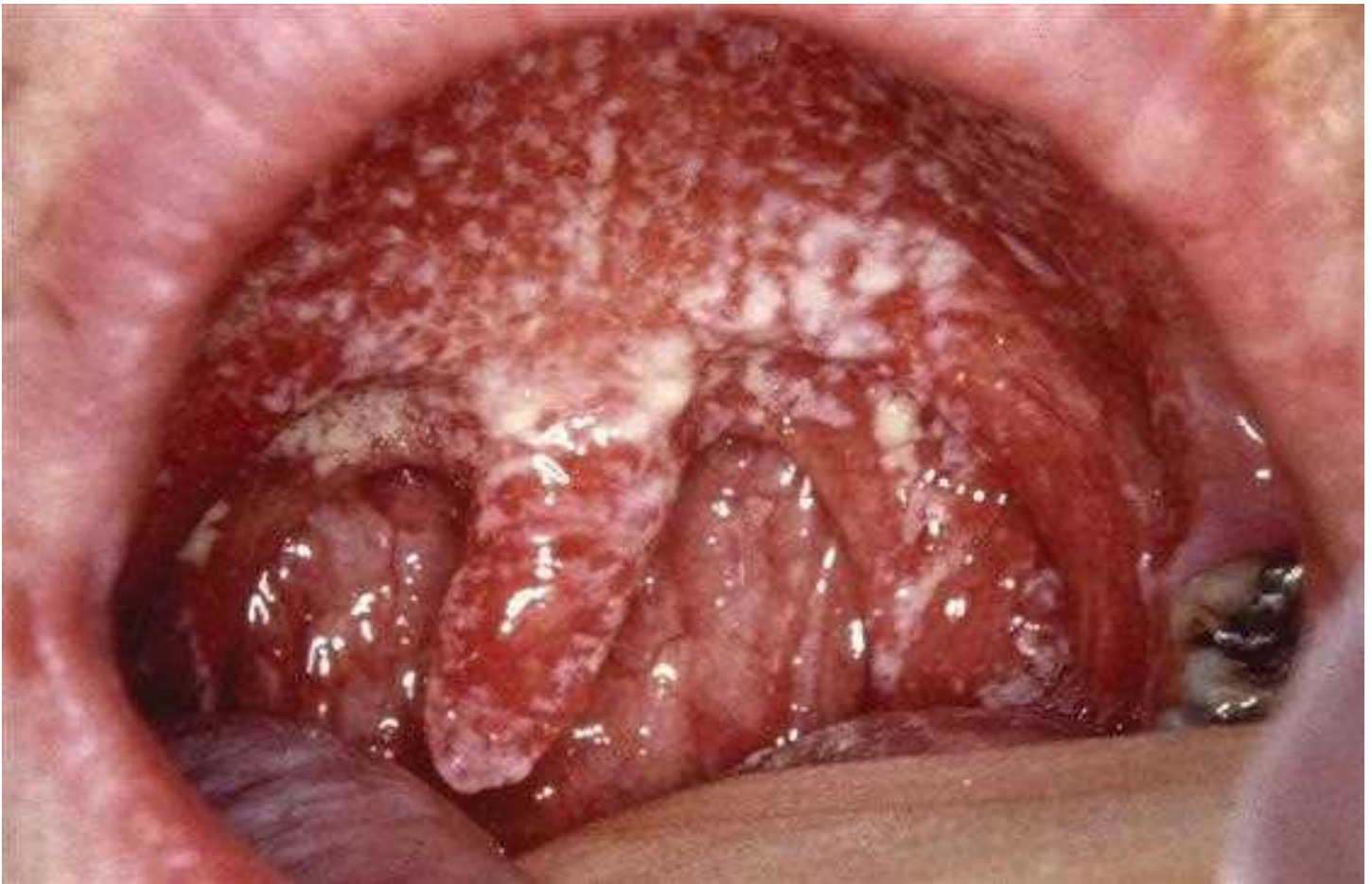

Figure 15.6 Pseudomembranous *Candida*.

Bacterial infections

Impetigo caused by *Staphylococcus aureus* may be severe with large bullous lesions associated with strains producing exfoliative toxins A/B. Erythrasma (*Corynebacterium*) may be persistent and recurrent in the flexural areas and are often mistaken for a superficial fungal infection.

Bartonella henselae and *Bartonella quintana* infections can cause bacillary angiomatosis (BA) in AIDS patients, who present with multiple small haemangioma-like papules on the skin and mucous membranes. Skin lesions develop slowly over several weeks ([Figure 15.7](#)), and visceral organs may also be affected – most commonly, the liver. Differential diagnosis usually includes Kaposi's sarcoma. Blood cultures are usually diagnostic, but the laboratory must be alerted to the possibility of *Bartonella* as blood cultures must be incubated for three weeks under specific conditions. Skin biopsy for histology is usually diagnostic. *Bartonella* are highly sensitive to macrolide antibiotics which are bacteriostatic and therefore an anti-angiogenic effect through down-regulation of endothelial cells has been postulated as the mechanism of action in BA. The treatment of choice is erythromycin 500 mg qds for up to 12 weeks. Azithromycin 500 mg on the first day and then 250 mg daily for five days is also highly effective.

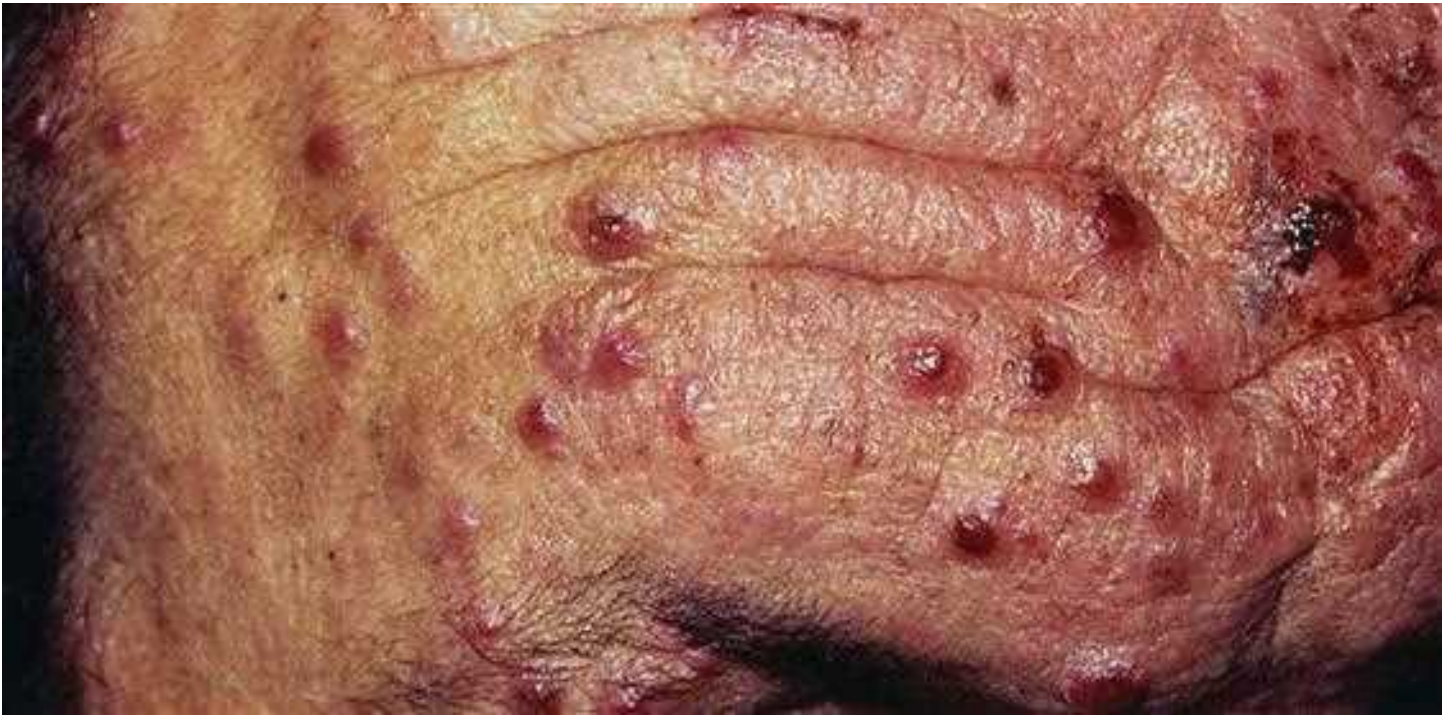

Figure 15.7 Bacillary angiomatosis.

Syphilis

Approximately 12 million new cases of syphilis infection are reported each year according to the WHO, with a notable resurgence in many parts of the world where the incidence was previously low. Between 20% and 70% of patients in the United States and Europe are co-infected with HIV and syphilis simultaneously. Syphilis is caused by the spiral bacterium (spirochaete) *Treponema pallidum*. Syphilis is the great mimicker of other diseases and in the context of HIV infection presentations may be atypical.

Classically, a painless genital ulcer develops three to four weeks after transmission via sexual intercourse. Secondary syphilis presents with a rash, fever, arthralgia, and lymphadenopathy four to eight weeks after the initial infection. The rash is usually asymptomatic and characteristically affects the trunk, palms, and soles. Early lesions are usually annular erythematous brown macules ([Figure 15.8](#)). Serological testing for syphilis should be performed to confirm the diagnosis. Primary/secondary syphilis should be treated with a single dose of intramuscular benzathine penicillin 2.4 megaunits, or intramuscular procaine penicillin 600 000 units daily for 10 days. Latent syphilis requires prolonged treatment.

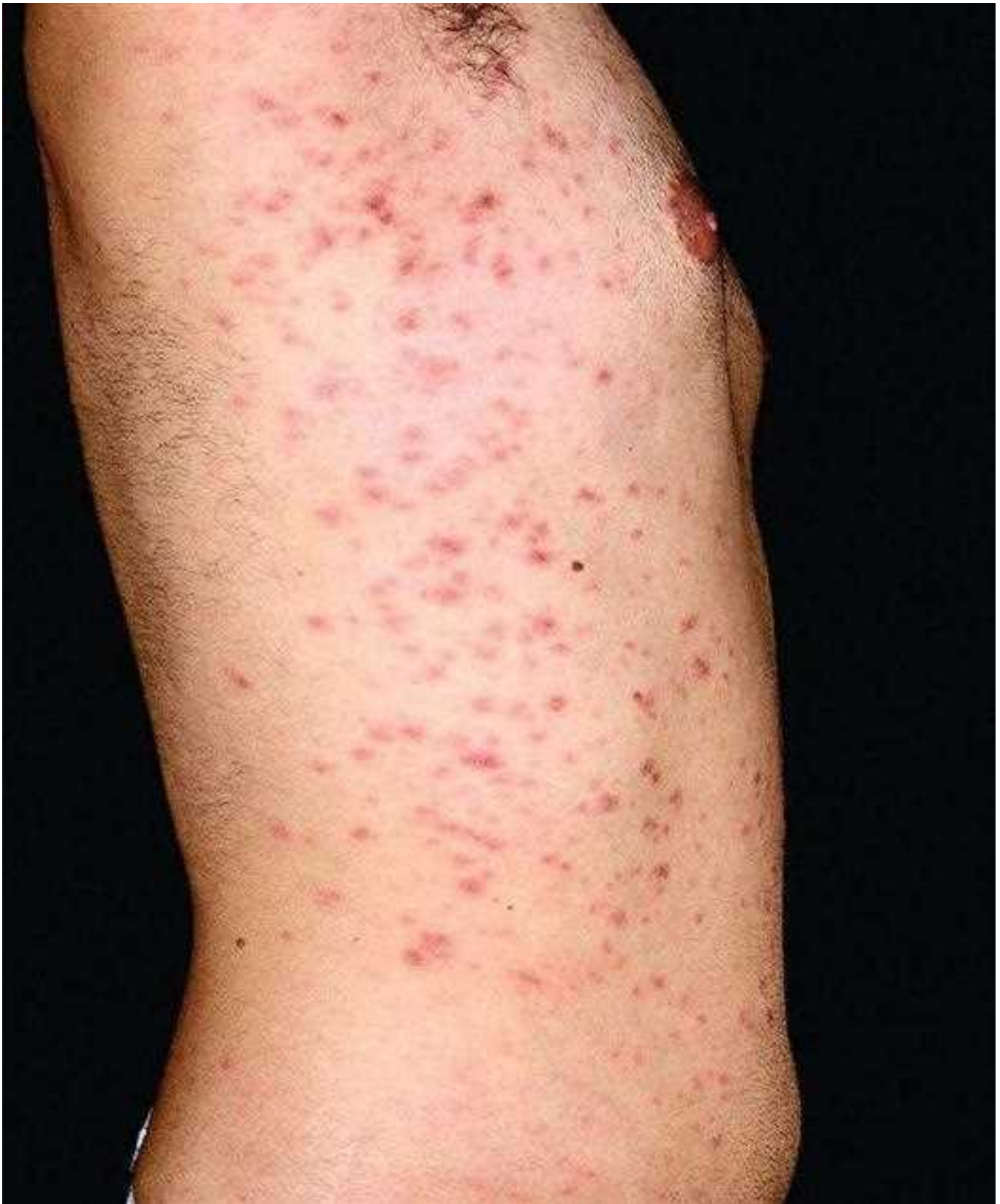

Figure 15.8 Secondary syphilis.

Mycobacteria may produce widespread cutaneous and systemic lesions. Varieties of mycobacteria that do not normally infect the skin may cause persistent necrotic papules or ulcers.

Viral infections

Herpesviruses

Herpesvirus types 1, 2, and 3 including herpes simplex (oral/genital) and herpes zoster infections may be unusually extensive, with large individual lesions in patients with HIV. Herpes zoster (shingles) classically spreads to involve adjacent dermatomes. Occasionally, persistent ulcerated lesions are seen with resultant squamous cell carcinoma, which can arise in any chronic ulcer. HSV infections may be particularly severe and recurrent such that patients require secondary long-term prophylaxis. In the context of highly active antiretroviral therapy (HAART), an IRIS can occur in association with genital HSV with florid debilitating inflammatory reactions, leading to extensive and persistent painful ulceration ([Figure 15.9a](#)) and occasionally proliferative change that can mimic squamous cell carcinoma ([Figure 15.9b](#)).

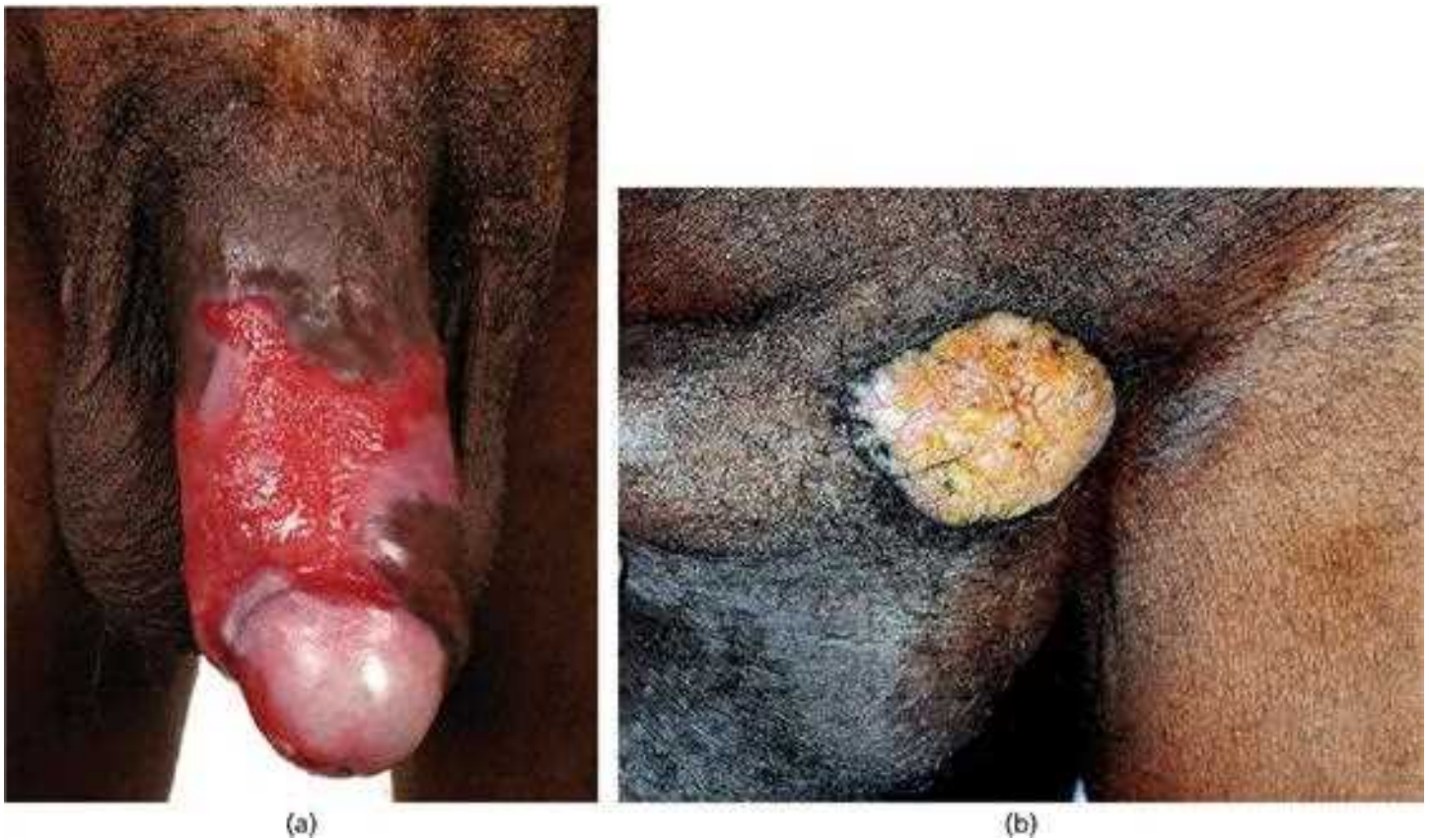


Figure 15.9 (a) HSV (immune reconstitution inflammatory syndrome, IRIS). (b) IRIS causing verrucous HSV.

Epstein–Barr virus (EBV) is human herpesvirus type 4. Ninety percent of adults have evidence of past infection with EBV which remains latent in the body in B-cells. In 30–50% of AIDS patients, EBV enters a replicative phase, leading to oral hairy leukoplakia (OHL). OHL is characterised by overgrowth of epithelial plaques on the sides of the tongue ([Figure 15.10](#)) with a verrucous grey/white surface. Biopsies from OHL show a lack of host Langerhans cells, which may account for the lack of immune response to the virus. Looking for OHL in the mouth can be a very quick and simple way of assessing potential

immunosuppression in a previously undiagnosed individual in the clinic or field setting. OHL has also been reported in the context of haematological malignancy and after organ transplantation.

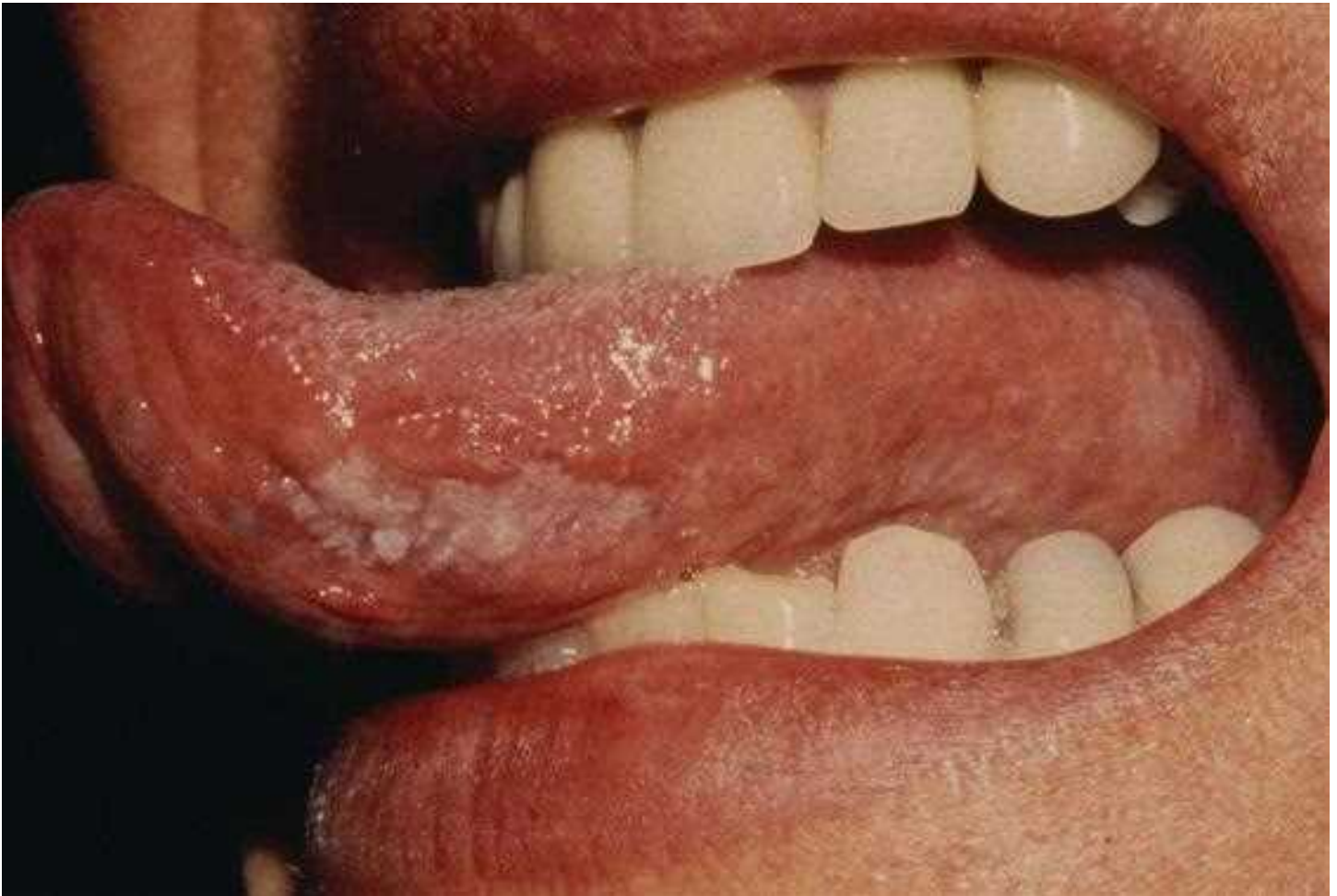


Figure 15.10 Oral hairy leukoplakia.

Kaposi's sarcoma (KS) is an angioproliferative disorder caused by infection with human herpesvirus type 8. There is an endemic form of the disease (usually affecting the skin of the lower leg) seen mainly in elderly men living in sub-Saharan Africa who are HIV negative and more recently seen in MSM (men who have sex with men) who are also HIV negative. In HIV patients (epidemic form) lesions usually affect the face, oral cavity ([Figure 15.11](#)), and perineum. Early lesions may be erythematous-violaceous patches or papules which progress to firm nodules ([Figure 15.12](#)) or plaques with a purplish brown discolouration. Lesions may eventually ulcerate. KS koebnerises (occurs at sites of skin trauma) and secondary lymphoedema may occur, particularly in affected limbs. Histology from skin/mucosal lesions can be diagnostic. Patients traditionally had CD4 counts below 200 in order to present with KS; however, there are increasingly numbers of cases where patients present with CD4 counts between 300 and 400. Cutaneous therapy is directed at haemostasis, restoring function, improving the cosmetic appearance and debulking advanced disease. A variety of measures can be considered such as excision, radiotherapy, pulsed dye laser, and intralesional chemotherapy (vinblastine, vincristine, and bleomycin).

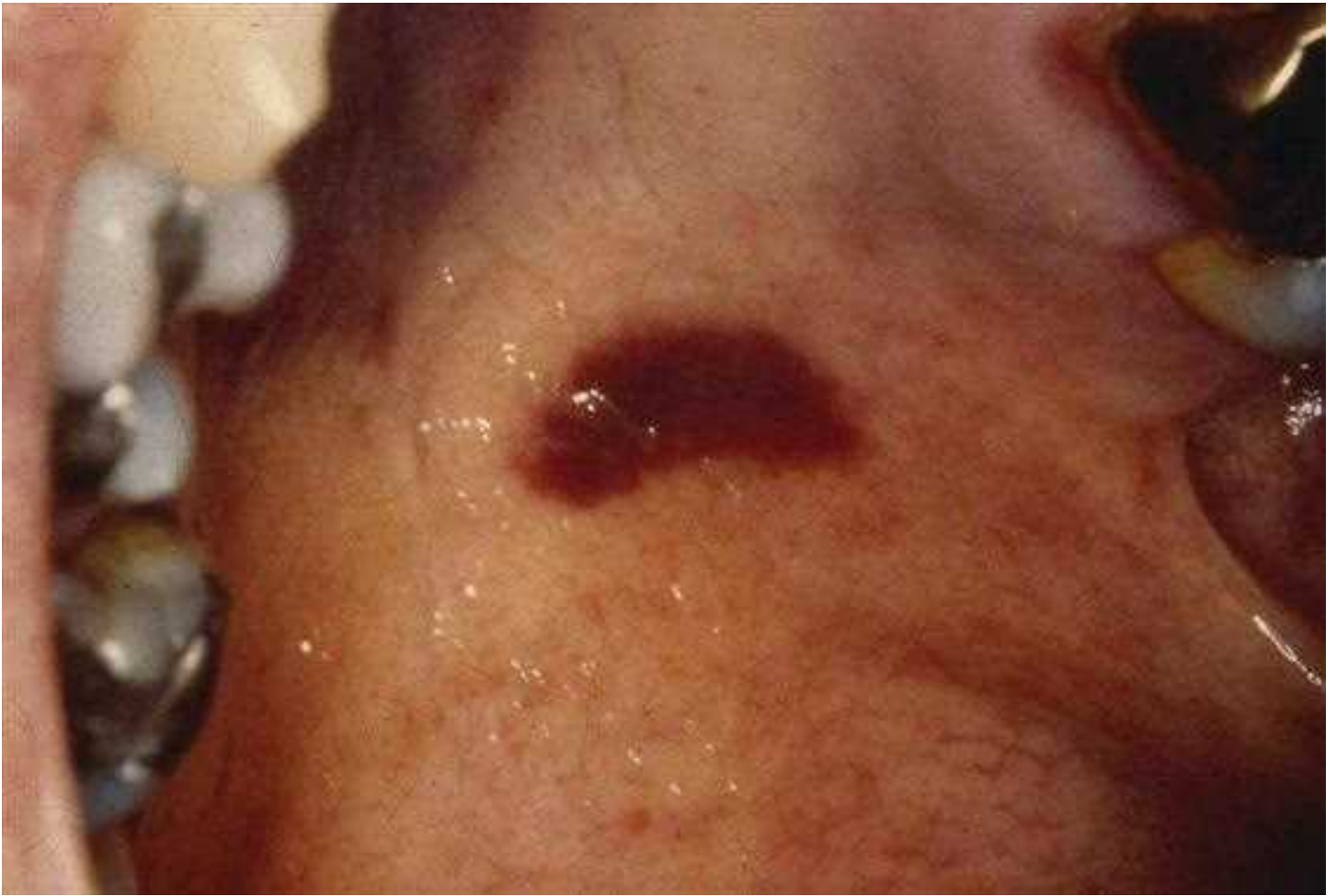

Figure 15.11 Kaposi's sarcoma on the hard palate.

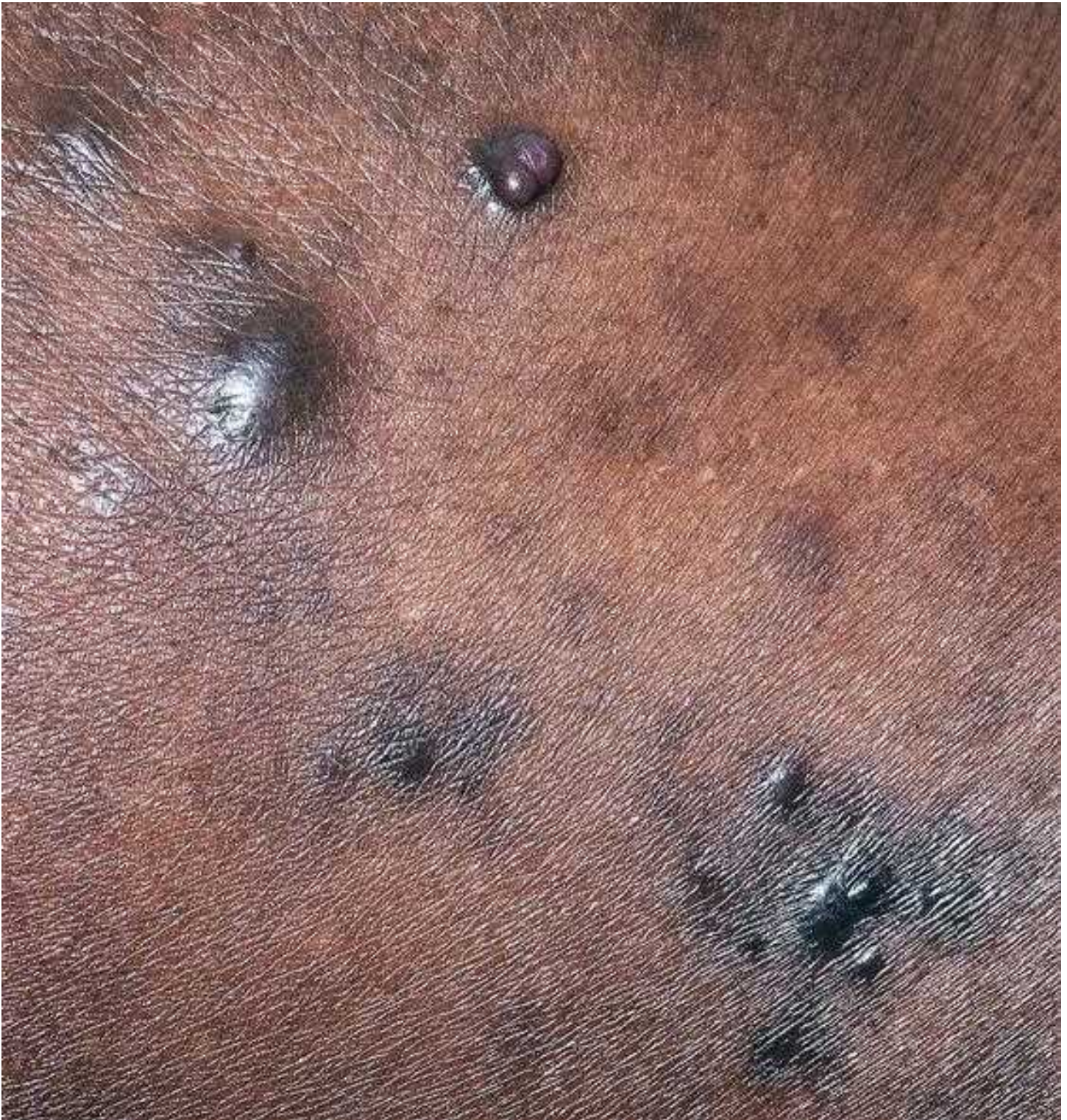

Figure 15.12 Kaposi's sarcoma nodules.

Other viruses

Molluscum contagiosum infections are frequent in HIV patients. Individual lesions may be larger than usual (giant molluscum) and they may be extensive. Mollusca are readily identified as firm papules with an umbilicated centre ([Figure 15.13](#)). The differential diagnosis of large mollusca-like lesions in the context of HIV includes fungal infections due to *Cryptococcus* and histoplasmosis. If the diagnosis is in question, then a skin biopsy for

histology analysis can be very helpful.

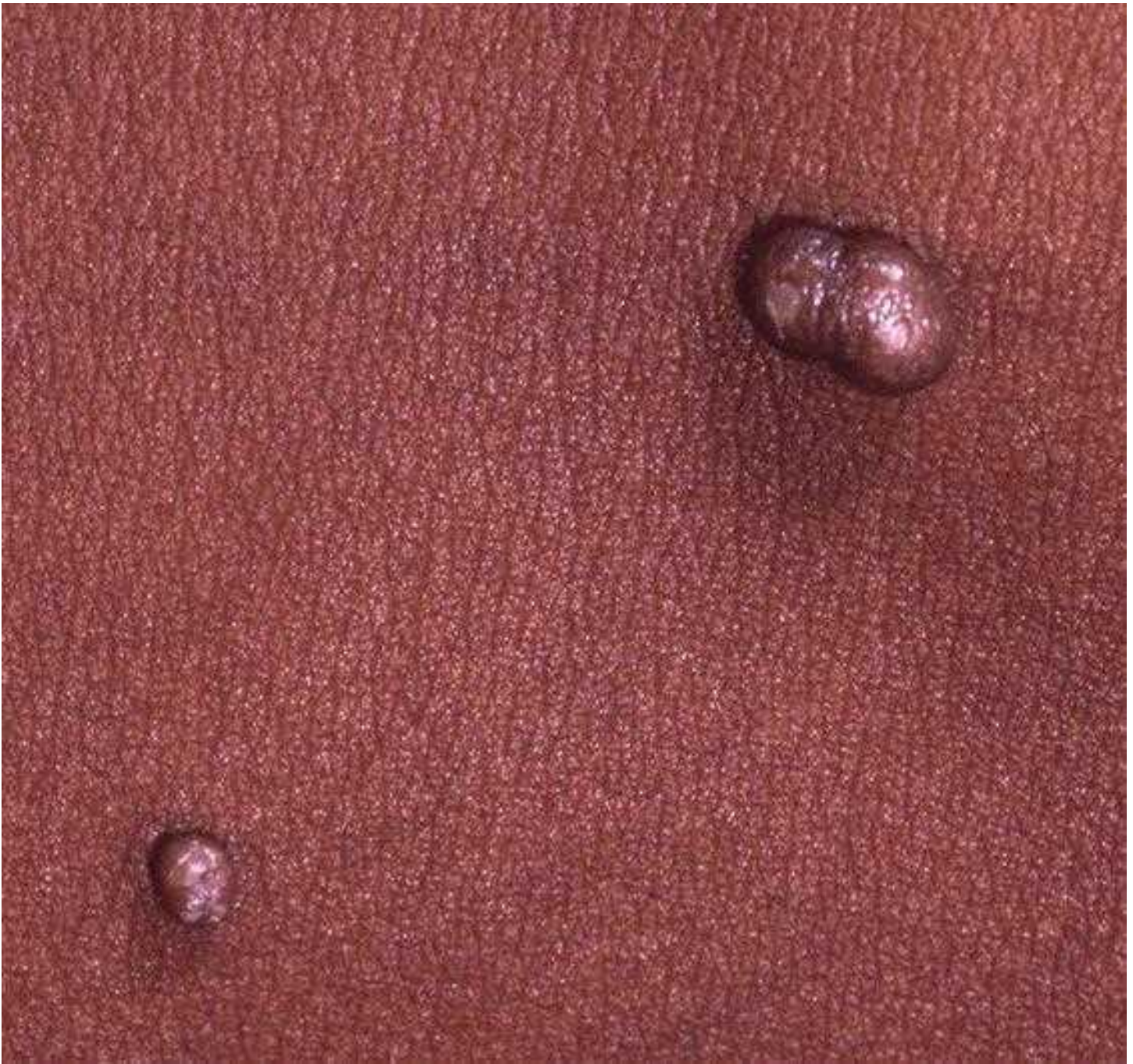

Figure 15.13 Molluscum contagiosum.

Human papillomavirus (HPV) warts may be numerous and large in HIV patients ([Figure 15.14](#)). Perianal and genital warts can be particularly troublesome and may be associated with intra-epithelial neoplasia of the cervix and sometimes invasive perianal squamous cell carcinoma. With immune reconstitution HPV warts tend to resolve, but in the meantime, they may respond to wart therapies including salicylic acid, cryotherapy, imiquimod, and diphencyprone therapy.

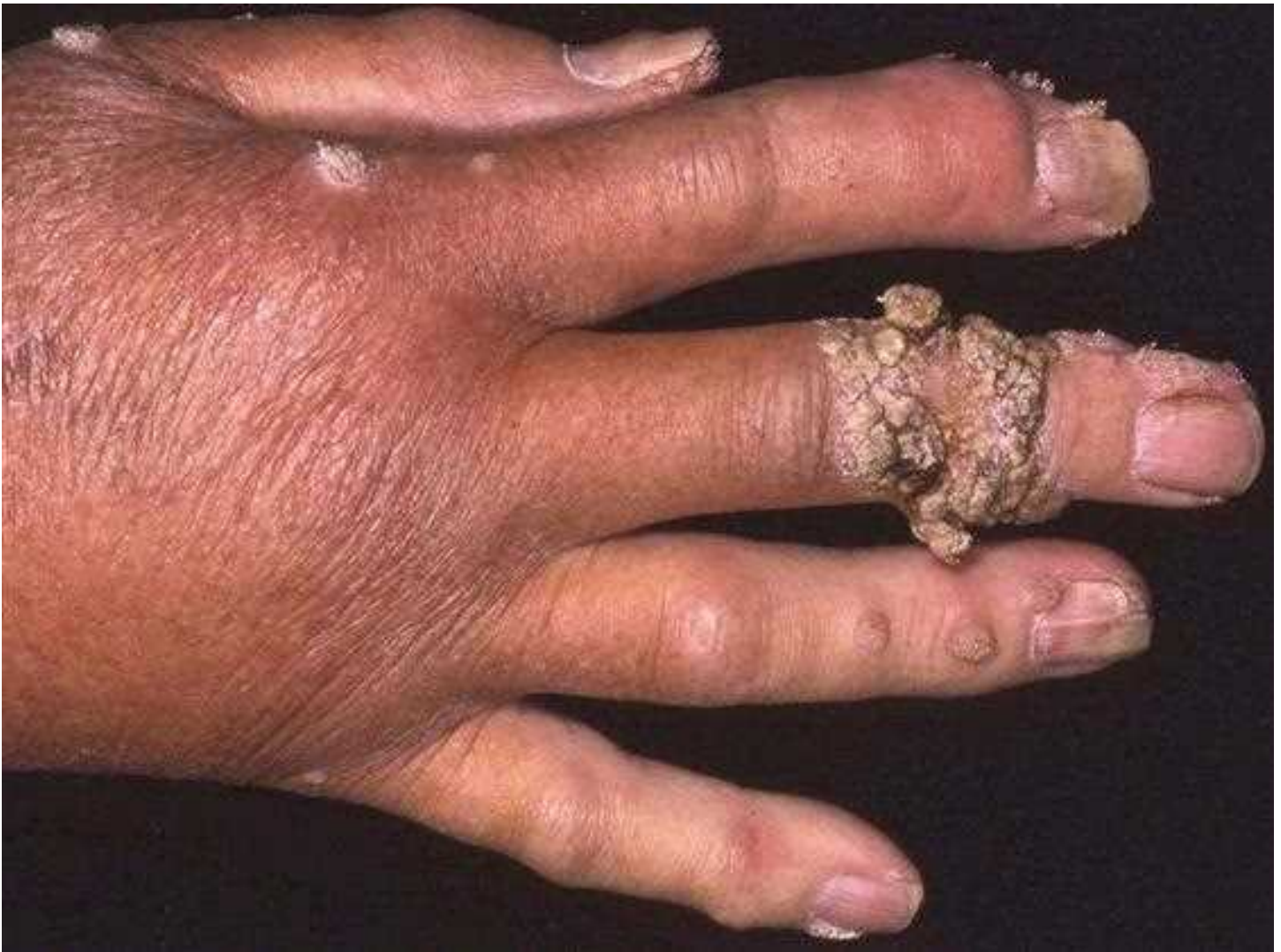

Figure 15.14 Human papillomavirus warts: extensive.

Infestations

Scabies in HIV patients may present with classic burrows on the fingers and genitals or as widespread crusted scabies which is highly contagious ([Figure 15.15](#)). Patients present with hyperkeratotic papules and plaques with relatively little inflammation (helping to distinguish it from psoriasis). Itching may be mild or intractable. Microscopic examination of the crusts is a simple rapid diagnostic test. Topical treatment with 5% permethrin (two applications seven days apart) may be effective, but ivermectin 200 µg/kg as a single dose (or repeated after seven days) may be needed in refractory/crusted and recurrent infestations.

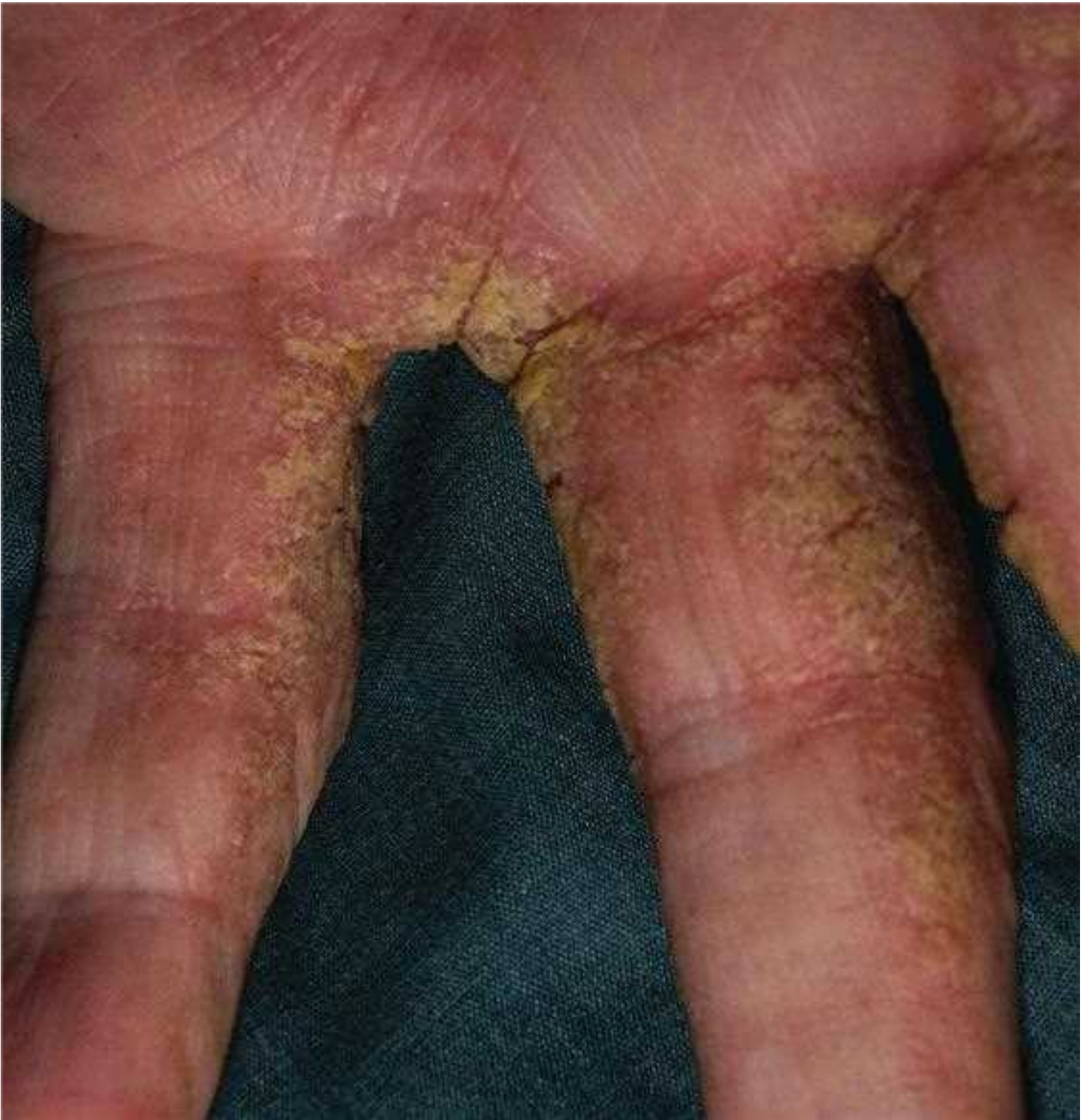

Figure 15.15 Crusted scabies on the hand.

Drug rashes

HIV patients frequently take multiple medications, many of which have a reputation for causing drug rashes (sulfonamides and antibiotics). Nonetheless, the frequency of drug rashes in HIV patients is extremely high (10 times higher than in the general population), especially at CD4 counts below 200 cells/ μl . This is partially explained by the fact that HIV itself affects the metabolism of many drugs. The majority of drug rashes occur within 7–20

days after starting the offending drug and take the form of toxic erythema (maculopapular eruption), which is usually mild and resolves when the medication is stopped.

However, severe life-threatening drug reactions such as toxic epidermal necrolysis (TEN) are 1000 times more common in HIV-positive individuals. In HIV patients, TEN has been reported in association with nevirapine, abacavir, and co-trimoxazole. Clinically, patients present with rapid, widespread (>30% of skin surface area), painful, full-thickness skin necrosis, which is associated with a 25–30% risk of mortality ([Figure 15.16](#)).

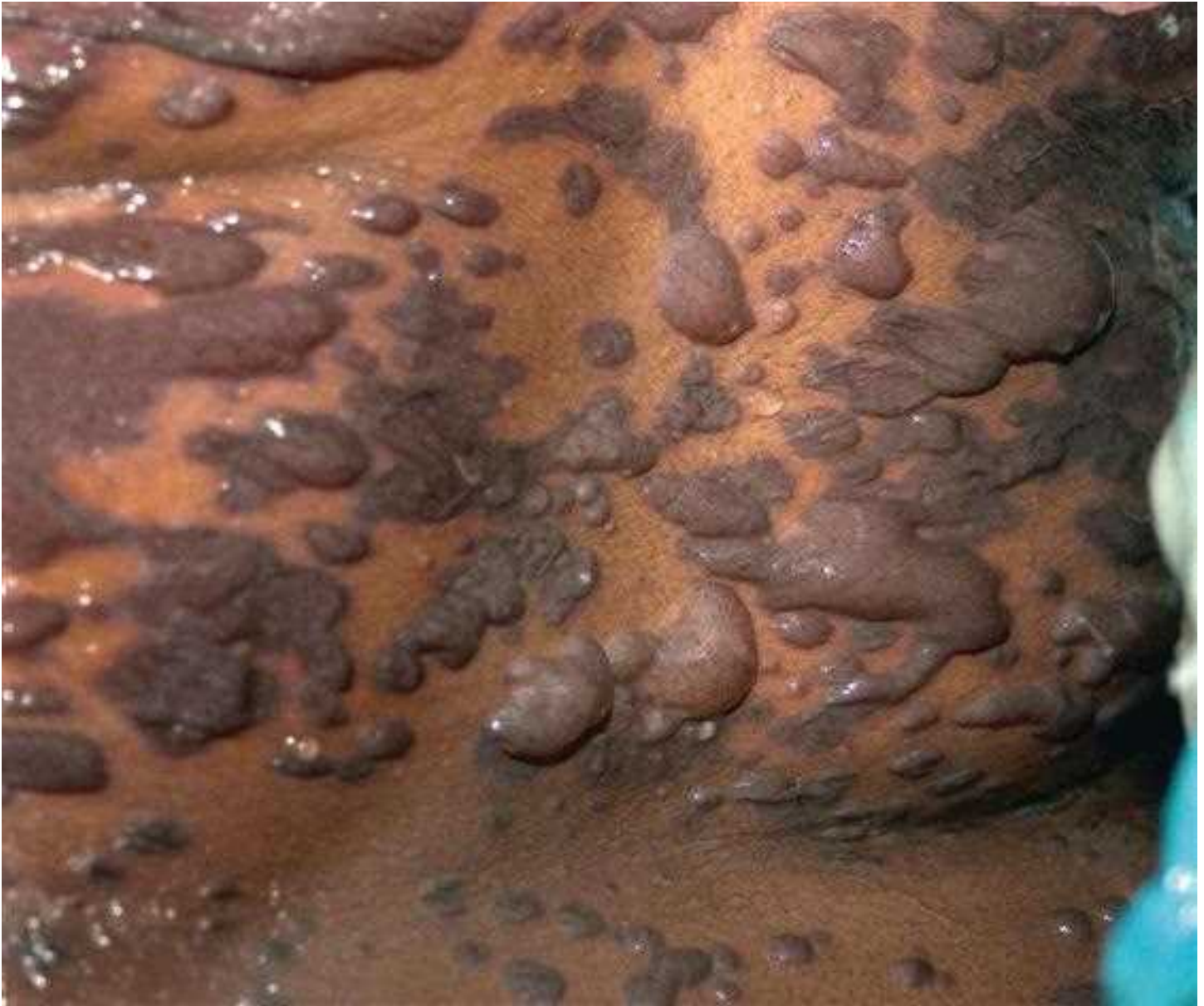

Figure 15.16 Toxic epidermal necrolysis.

Other drug rashes in HIV patients include pigmentation of nails/tongue/skin (zidovudine and clofazimine), hyperpigmentation of the palms and soles (emtricitabine) mucosal ulceration (zalcitabine, foscarnet and saquinavir), rash and pruritus (abacavir and raltegravir), alopecia and in growing nails (indinavir), diffuse erythema (abacavir), phototoxic rashes (St John's wort), injection site reactions (enfuvirtide) Stevens–Johnson syndrome (co-trimoxazole and

dapsone), and TEN.

Further reading

Adler, M.W., Edwards, S.G., Miller, R.F. et al. (2012). *ABC of HIV and AIDS*, 6e. Oxford: Wiley-Blackwell.

www.ashm.org.au.

CHAPTER 16

Fungal Infections

Rachael Morris-Jones

Guy's and St Thomas' NHS Foundation Trust, London, UK

OVERVIEW

- Fungi can cause infections of the skin, hair, nails, and orogenital tract.
- Fungal infections are more common in hot climates and in immunosuppressed individuals.
- A diagnosis of fungal infection is usually made clinically; however, it may be confirmed by culture of skin scrapings/scalp brushings.
- Tinea capitis usually needs to be treated with systemic antifungals.
- Onychomycosis (fungal infection of the nails) affects mainly adults and may be chronic.
- *Candida* (yeast) causes lesions in the mucous membranes and flexures, where it should be differentiated from psoriasis, seborrhoeic dermatitis, and contact dermatitis.
- Deep fungal infections may occur in diabetics, neutropenic, debilitated patients, and the immunosuppressed.

Introduction

One million species of fungi are currently recognised, of which 300 are pathogenic to humans and of these over three-quarters primarily infect the skin and subcutaneous tissues. Superficial fungal pathogens are the fourth commonest cause of any human disease worldwide. Historically, superficial fungal infections have caused minimal disease in temperate climates, with the most severe outbreaks occurring in the tropics and subtropics. The use of potent immunosuppressant and antimicrobial drugs has increased the incidence of fungal infective episodes in temperate climates. Currently, there is emerging resistance to antifungal medications and to date no human fungal vaccine exists.

Some fungi live on the skin as part of the normal skin flora while others come into contact with the skin through the environment and animals. Superficial fungal infections attack the epidermis, mucosa, nails and hair, and are divided into two groups: moulds (e.g. dermatophytes) and yeasts (e.g. *Candida*).

Yeast that comprise part of the normal skin flora can become pathogenic because of a change

in the host's immune system. This allows the yeast to disseminate throughout the body, causing serious life-threatening disease. Conversely, mycoses that originate as systemic infections can become deposited in the skin via haematogenous spread.

Investigations

Diagnosis of fungal infections can be made by taking skin scrapings, nail clippings, scalp brushings and skin biopsies for mycological analyses ([Box 16.1](#)). A moistened bacterial swab taken from the affected skin and inoculated into standard fungal media can be a useful additional test. Expert mycologists who perform fungal microscopy may be able to make an immediate diagnosis through recognition of characteristic fungal features. Macroscopic patterns of fungal growth from cultures may also lead to species diagnoses; however, fungi are usually slow to grow. Modern fungal diagnostics are moving towards the use of rapid polymerase chain reaction (PCR) tests and ELISA, which can rapidly process numerous specimens simultaneously. Some mycology reference laboratories may also be able to provide a sensitivity profile to antifungal drugs from any fungal strain isolated.

[Box 16.1](#) Principles of diagnosis

- Consider a fungal infection in any patient with itchy, dry, scaly lesions (usual distribution is asymmetrical).
- Skin samples are taken by scraping the edge of the lesion with a blunt blade held at right angles to the skin and collected onto a piece of dark paper.
- Nail clippings should be taken from the nail including subungual debris.
- Scalp brushings should be taken from the scalp (a travel toothbrush can be used).
- Laboratories will report initially on direct microscopy but culture results take two to four weeks.
- Lesions to which steroids have been applied are often quite clinically atypical because the normal inflammatory response is suppressed – *tinea incognito*.
- Wood's light (ultraviolet light) can reveal *Microsporum* infections of hair, as they produce a green-blue fluorescence.

General features of fungi in the skin

Superficial dermatophyte infections are named according to the body site affected: tinea capitis (scalp), tinea corporis (body), tinea cruris (groin) and tinea pedis (feet). Fungal infections invariably cause itching; the skin may be dry and scaly or in flexural areas wet

maceration can result.

Zoophilic (animal) fungi generally produce a more intense inflammatory response with deeper indurated lesions ([Figure 16.1](#)) than fungal infections due to anthropophilic (human) species. Some lesions have a prominent scaling margin with apparent clearing in the centre, leading to annular or ring-shaped lesions – hence the term ‘ringworm’.

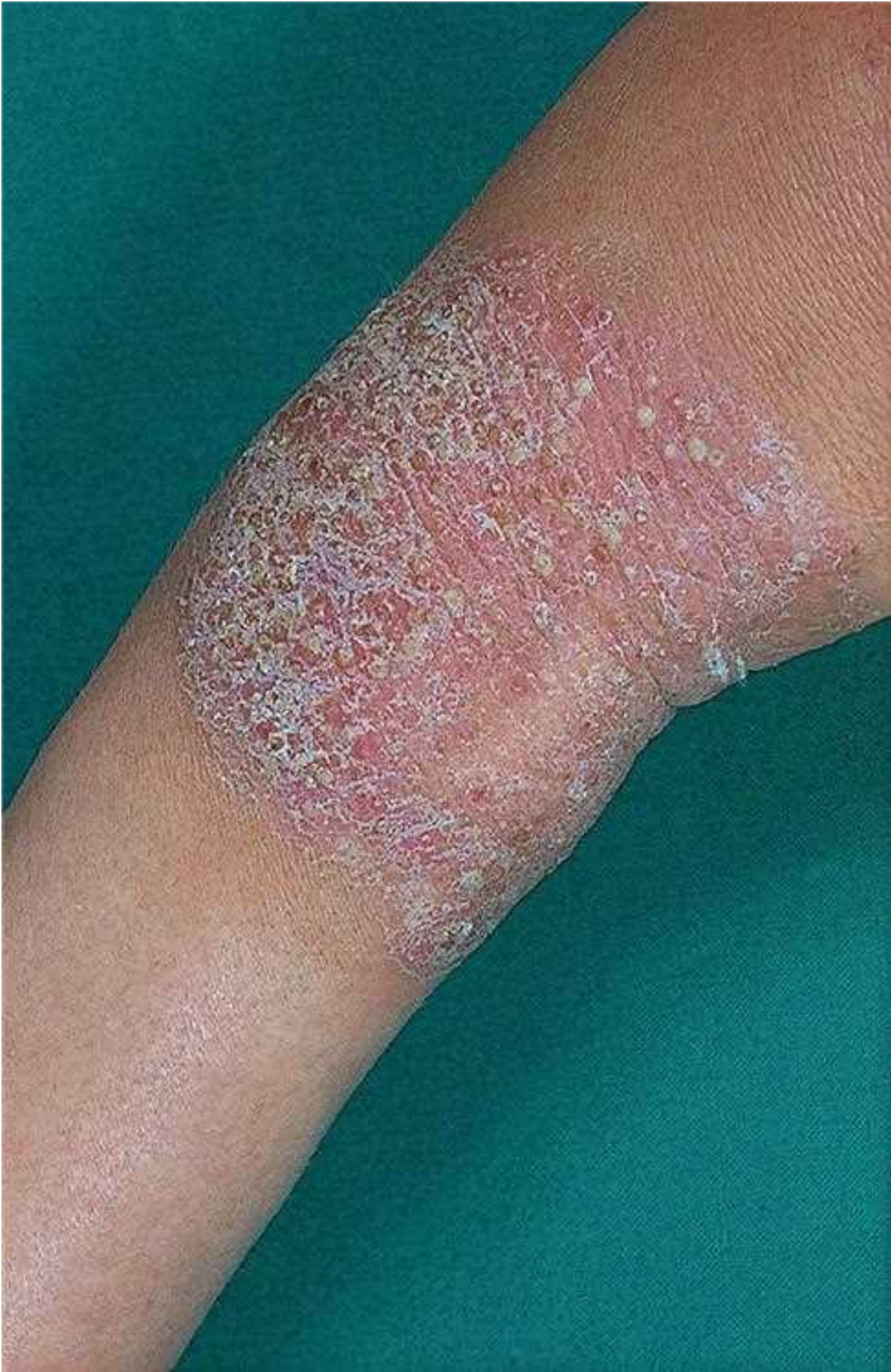

Figure 16.1 Animal ringworm.

Children below the age of puberty are susceptible to scalp ringworm, termed tinea capitis. In many inner city areas the most common fungus isolated is caused by a human species *Trichophyton tonsurans*, but fungi from animals (cattle, dogs, and cats) may also occur. Infection from dogs and cats with a zoophilic fungus (*Microsporum canis*) to which humans have little immunity can occur at any age (Figure 16.2). Adults typically are more commonly affected by tinea pedis. Tinea cruris in the groin is seen mainly in men, and fungal nail infections (onychomycosis) are particularly common in the elderly and debilitated.

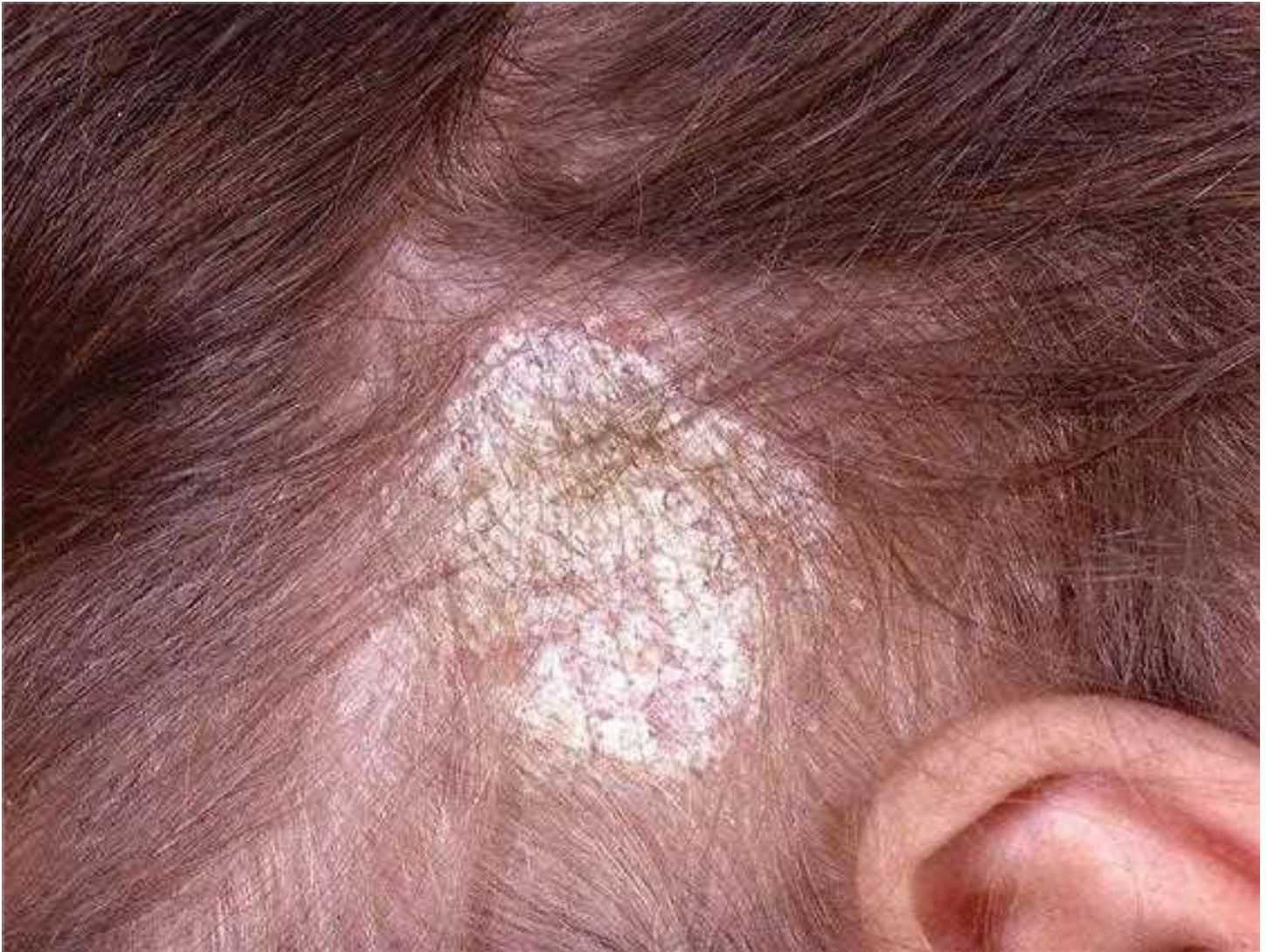

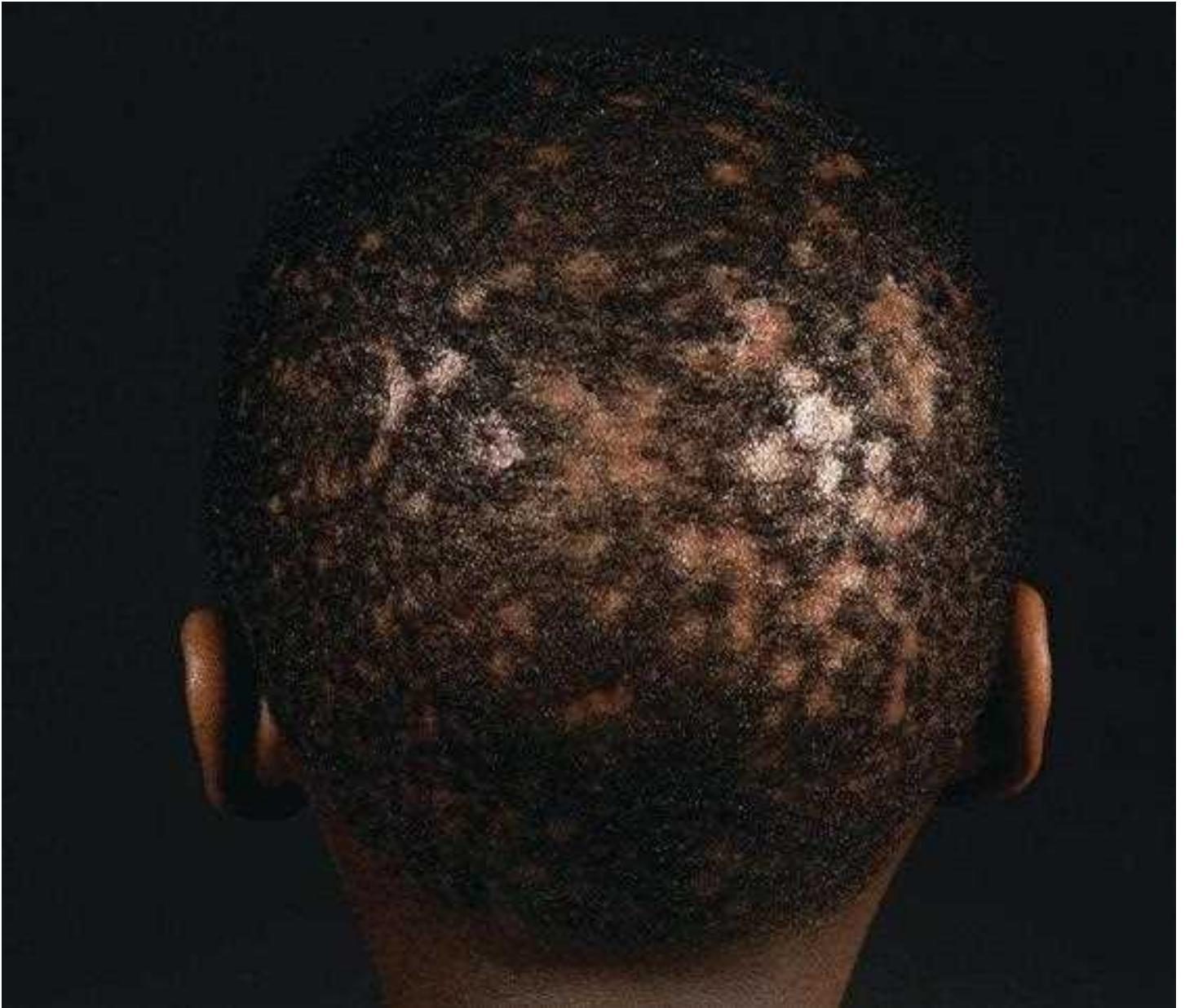Figure 16.2 Tinea capitis: *Microsporum*.

Scalp and face

Tinea capitis (scalp ringworm) mainly affects pre-adolescent children. The main fungal pathogens isolated include *Trichophyton*, *Microsporum*, and *Epidermophyton*. The most commonly isolated fungus in urban settings is *T. tonsurans*; it penetrates the hair shaft (endothrix fungus) and is characterised by single or multiple patches of alopecia, often minimal scaling and occasionally inflammation. *T. tonsurans* must be treated with systemic

antifungal therapy to clear the endothrix infection.

Clinically, features are highly variable: diffuse scaling, grey patches, black dots (broken-off hairs), multiple pustules, patchy alopecia ([Figure 16.3](#)), extensive alopecia with inflammation ([Figure 16.4](#)), kerion formation, and occipital lymphadenopathy. A *kerion* is an inflamed, boggy, pustular lesion on the scalp ([Figure 16.5](#)) that occurs when there is a brisk inflammatory response. This settles with systemic antifungal treatment and does not require surgical drainage. The clinical differential diagnosis of tinea capitis includes scalp eczema/psoriasis, folliculitis, alopecia areata, and seborrhoeic dermatitis (SD).



[Figure 16.3](#) Patchy alopecia in tinea capitis caused by *Trichophyton tonsurans*.

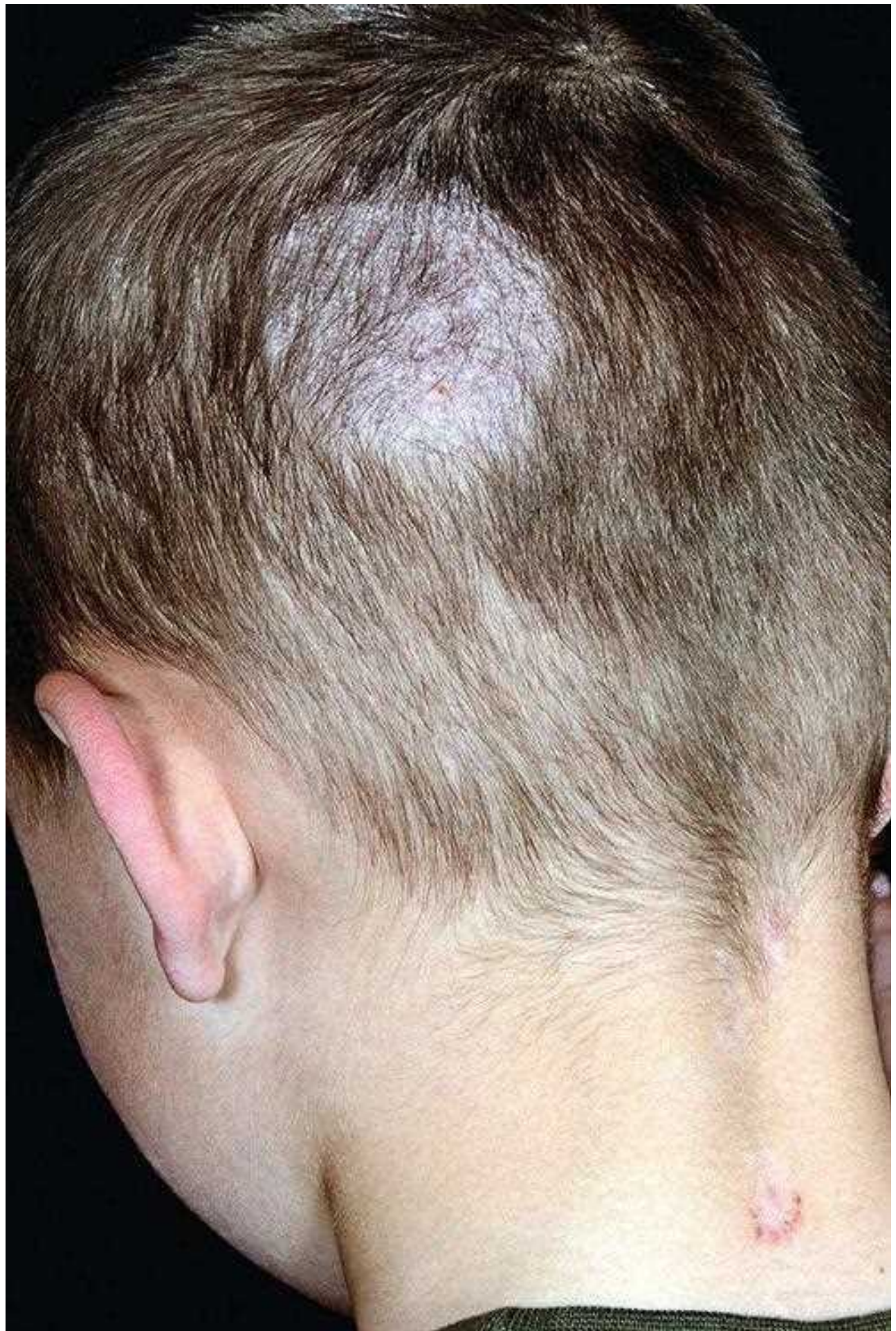

Figure 16.4 Scaling with alopecia in the scalp and scaly rash on the neck caused by *T. tonsurans* infection.

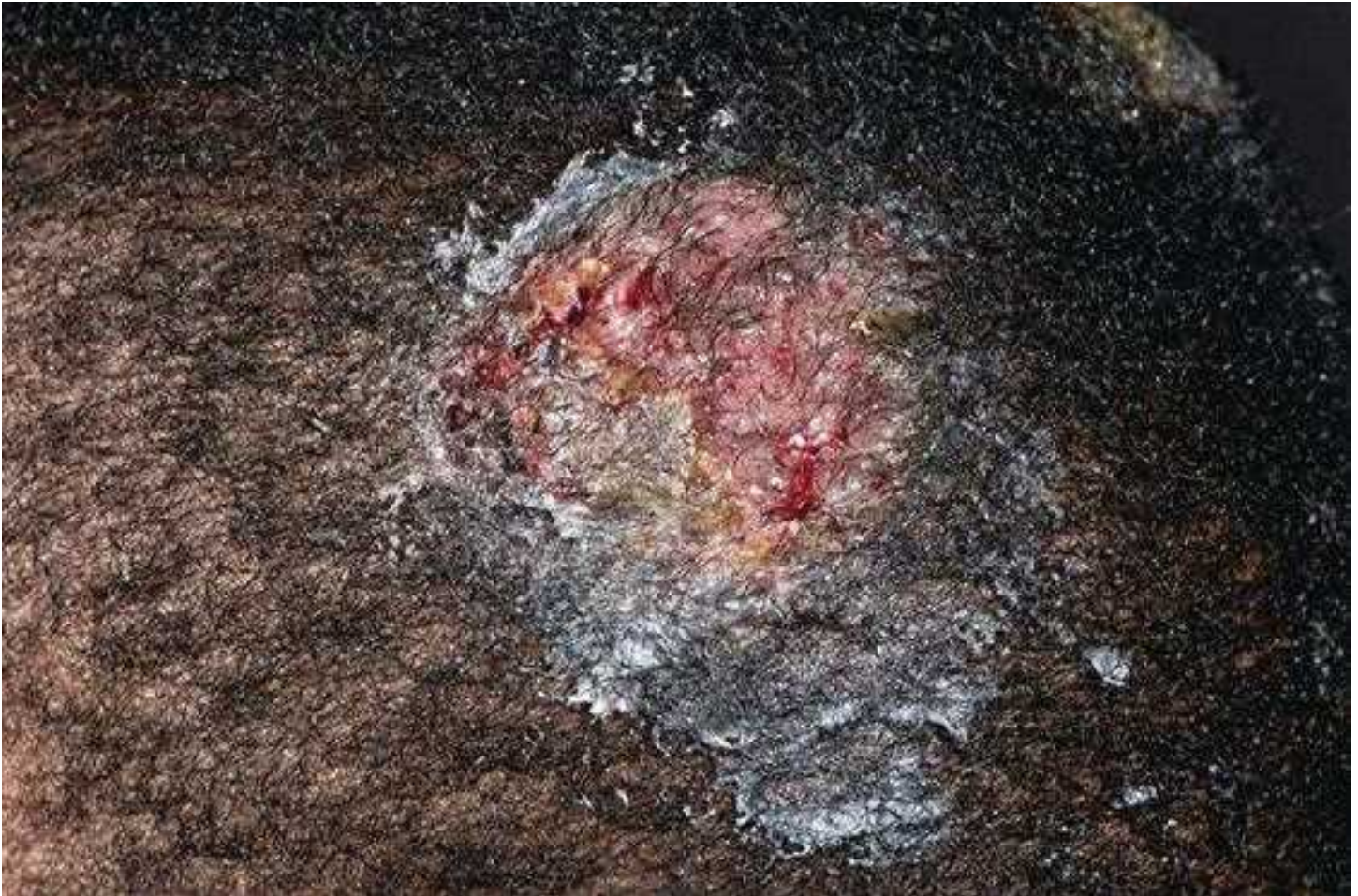

Figure 16.5 Kerion in *T. tonsurans* tinea capitis.

Scalp brushings should be taken to isolate the fungal pathogens from index cases and close family contacts. Parents may have tinea corporis on the shoulder/neck area where their child's infected head has come to rest.

Topical antifungals are unable to penetrate the hair shaft sufficiently to eradicate endo-thrix infections and therefore systemic antifungal agents are required for rapid clinical and mycological cure. Oral griseofulvin (10 mg/kg if over one month of age; occasionally 20 mg/kg is required) is the current FDA-approved treatment. It is effective for the treatment of *Microsporum* infections when given for 8–10 weeks but may cause gastrointestinal side effects. However, many dermatologists are using oral terbinafine as first-line therapy as it has a comparable safety profile and greater efficacy against *T. tonsurans* and is half the cost. Terbinafine is given daily for one month (dosage according to weight: <20 kg, 62.5 mg; 20–40 kg, 125 mg; >40 kg, 250 mg daily). Ideally, repeat scalp brushings should be taken after treatment to ensure mycological as well as clinical cure. Occasionally, a papular/pustular widespread cutaneous eruption appears after the commencement of systemic antifungal treatment – this is a so-called ‘id reaction’ (Figure 16.6), which is an immunological response and not an adverse drug reaction.

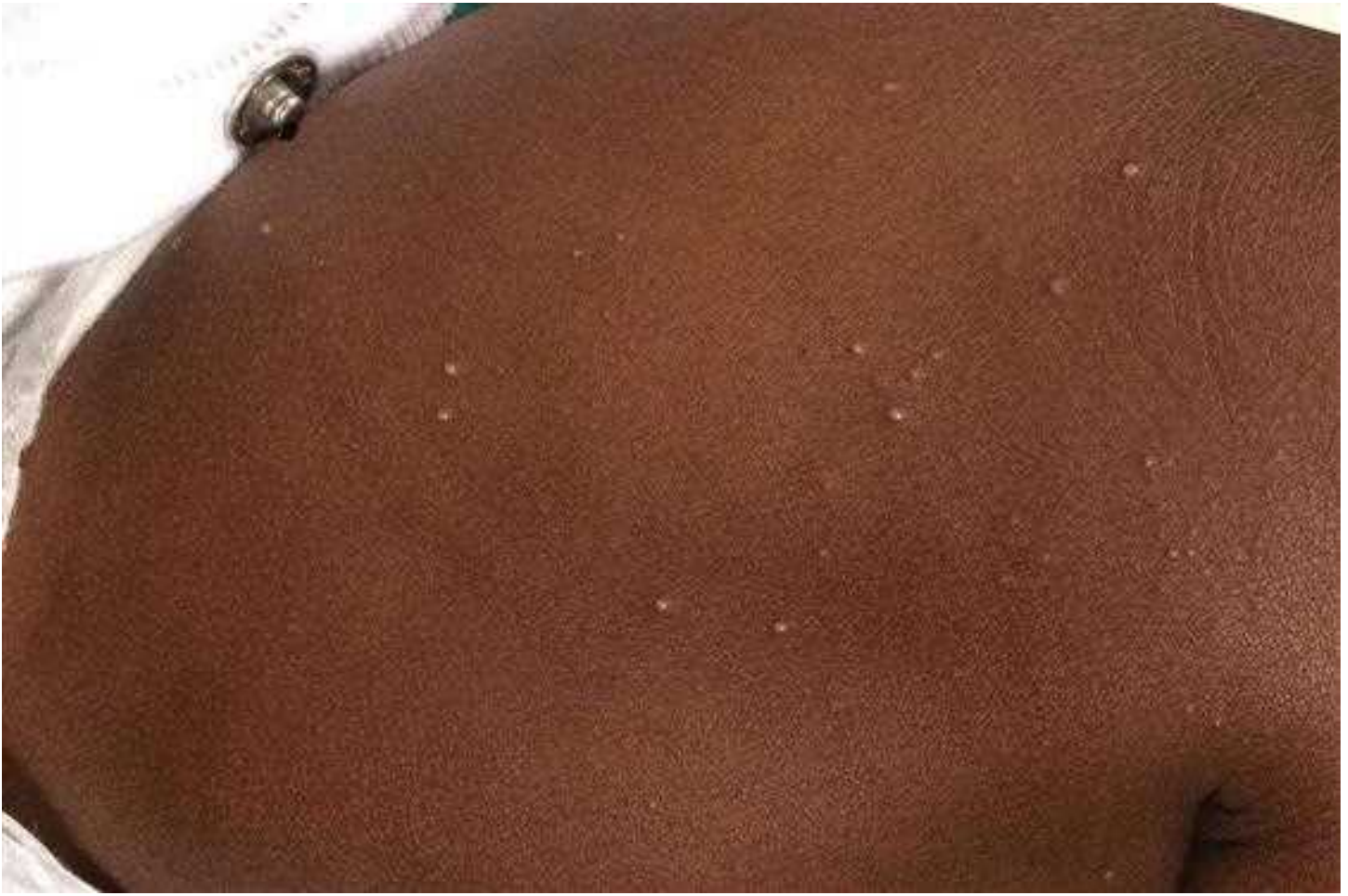

Figure 16.6 'Id reaction' after commencing oral treatment for tinea capitis.

Tinea incognito is the term used for the indistinct appearance of a superficial fungal infection on the skin caused by use of topical/systemic steroids. Therefore, because the typical clinical features of the fungal infection (raised scaly margin with inflammation) are lost, the diagnosis becomes more difficult ([Figure 16.7](#)). The groin, hands, and face are sites where this is most likely to occur. Management is to stop the steroids and treat with topical antifungal agents.

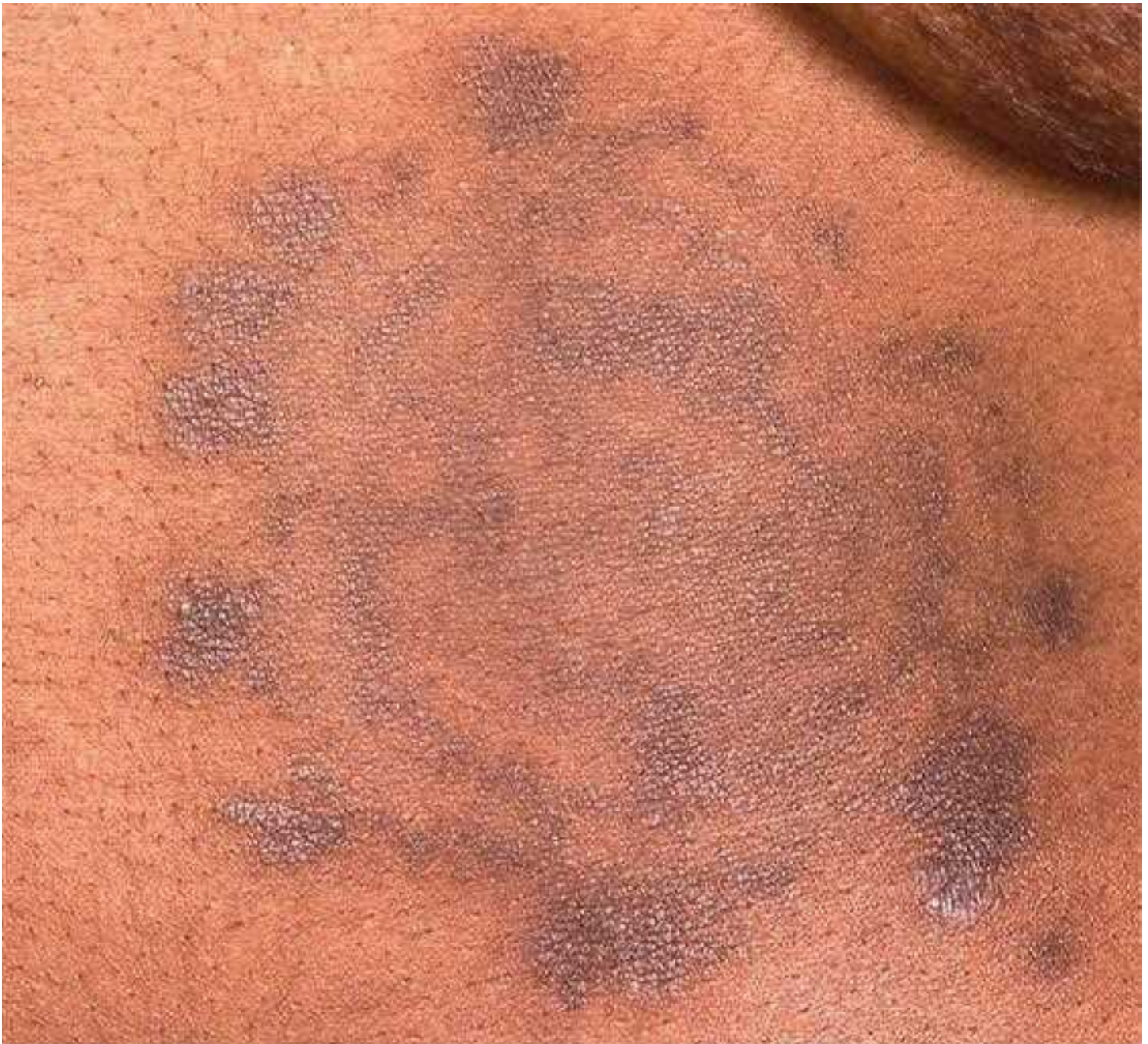

Figure 16.7 Tinea incognito.

Seborrhoeic dermatitis (SD) is thought to be an allergic contact dermatitis due to the yeast *Malassezia globosa*, which is part of the normal skin flora; therefore, the condition is usually chronic. SD most frequently affects the hair-bearing skin (scalp, eyebrows, moustache, and anterior chest) and nasal creases ([Figure 16.8](#)). There is marked scaling with associated eczema and adherent greasy scales. SD may be very itchy. The differential diagnosis of SD includes atopic eczema/psoriasis. It should be explained to patients that the problem will always tend to recur following treatment, which is aimed at reducing the numbers of yeast on the skin and controlling the eczema. Ketoconazole shampoo can be used to wash the body and scalp once-twice weekly to reduce yeast numbers. Twice-daily topical steroids (\pm miconazole) can be used to treat the eczema. In refractory cases, systemic imidazoles such as itraconazole can be effective.

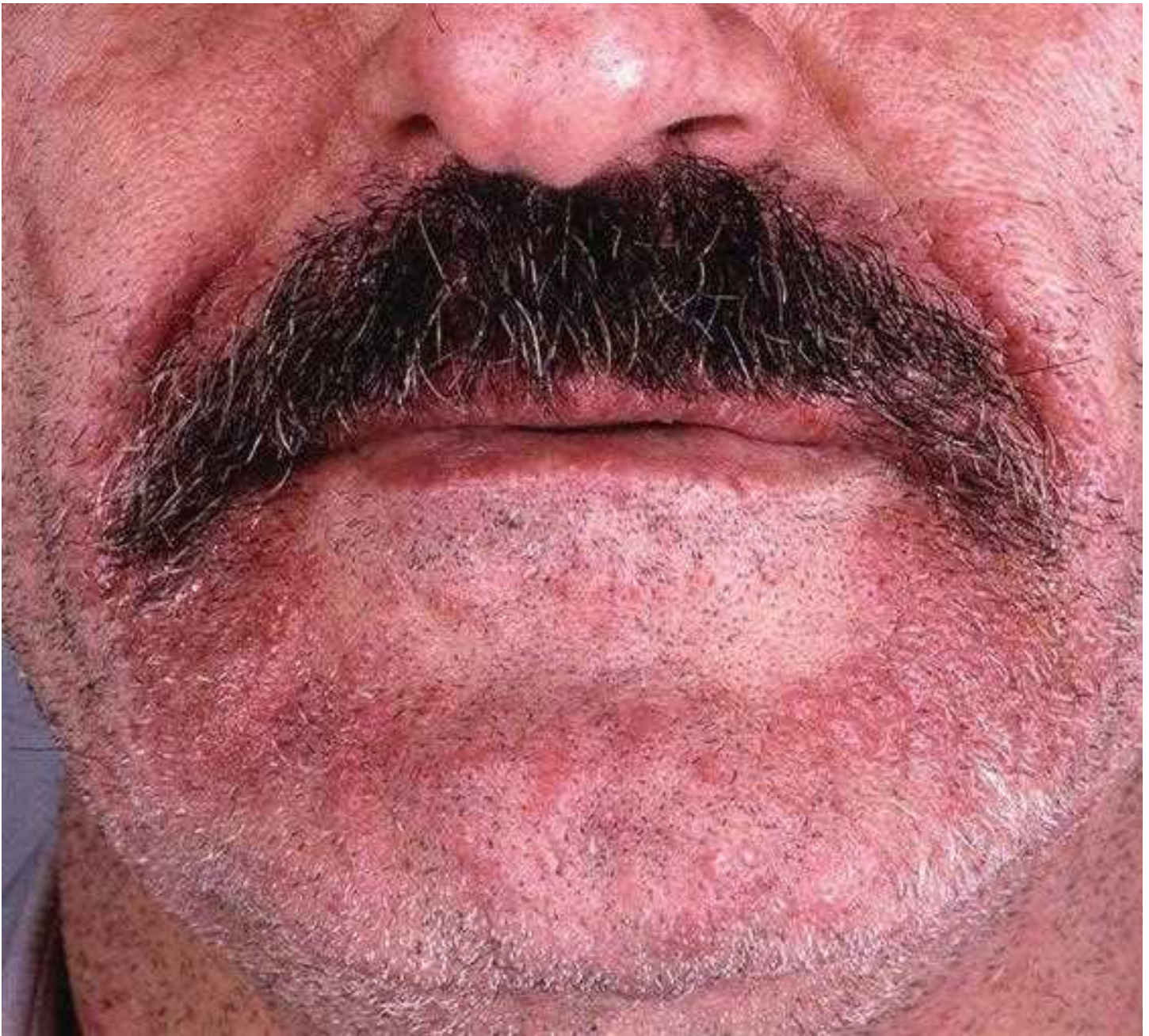


Figure 16.8 Seborrhoeic dermatitis.

Feet (and occasionally the dominant hand)

Tinea pedis or athlete's foot is a common disease mainly affecting adults. It is easily acquired in public swimming pools or showers, and industrial workers appear to be particularly predisposed to this infection. *Tinea pedis* is very itchy and can affect any part of the foot ([Figure 16.9](#)) but frequently occurs between the toes (especially the fourth toe web) where the skin becomes macerated ([Figure 16.10](#)). Across the plantar and dorsal aspects of the feet there is usually a dry, scaling rash, occasionally with vesicles at the active margins. The hands may be similarly affected. The condition needs to be differentiated from psoriasis and eczema (particularly pompholyx) and therefore scrapings for mycology can be helpful. Terbinafine 1% cream twice daily for two to four weeks is usually effective but recurrent

infections may occur.

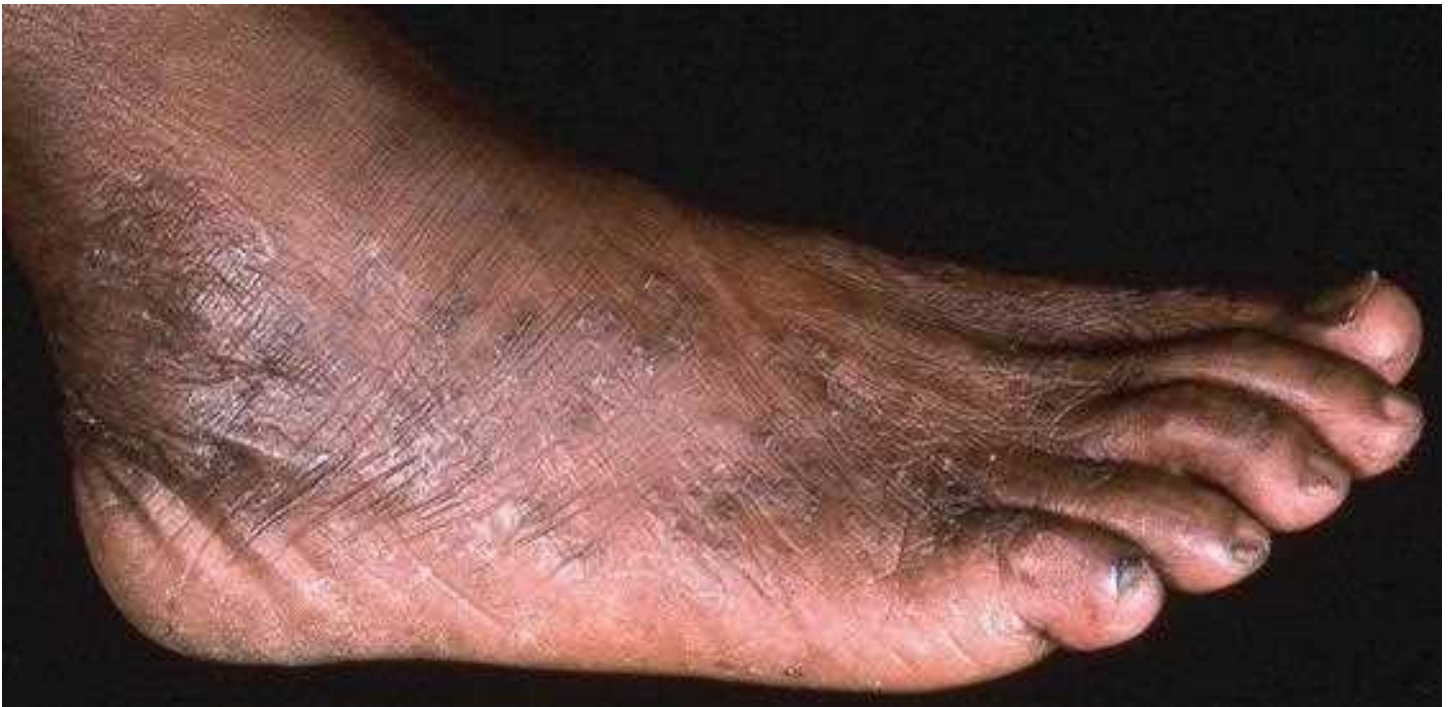

Figure 16.9 Tinea pedis.

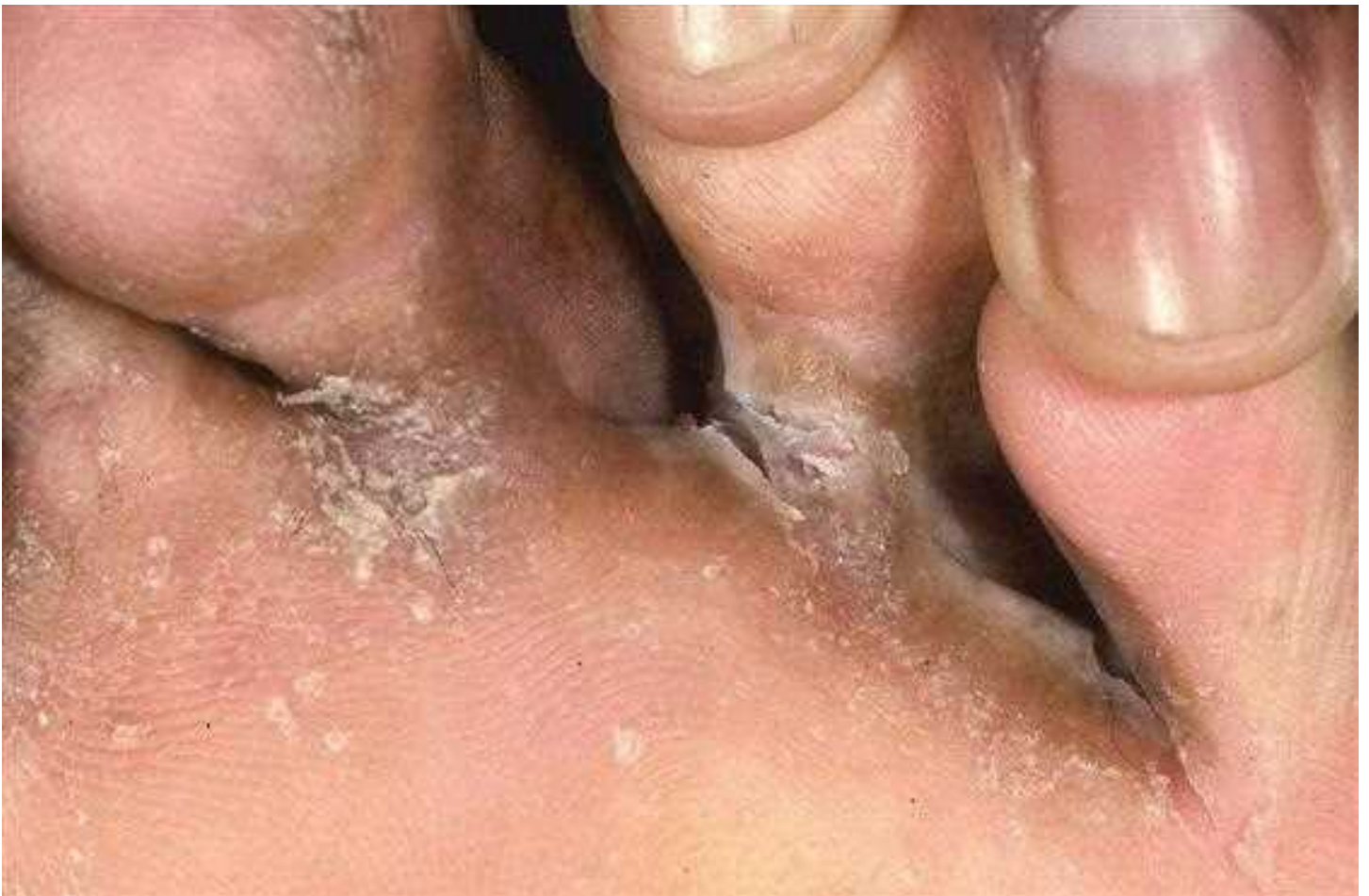

Figure 16.10 Toeweb tinea pedis.

Trunk

Tinea corporis also causes pruritus. Lesions tend to be erythematous with a well-defined scaly edge ([Figure 16.11](#)). In the groin, tinea cruris ([Figure 16.12](#)) is usually symmetrical dry scaling and may spread to the upper inner thighs. Conversely, intense erythema and satellite lesions suggest a *Candida* yeast infection. The differential diagnosis includes erythrasma due to *Corynebacterium minutissimum* (which may require a systemic erythromycin/tetracycline), psoriasis, mycosis fungoides, and eczema. Terbinafine 1% cream is the most effective topical treatment for tinea corporis/cruris; other agents include miconazole, clotrimazole, ketoconazole, and econazole for two to four weeks. If systemic therapy is required, itraconazole (100 mg daily) or terbinafine (250 mg daily) for two weeks is usually effective.

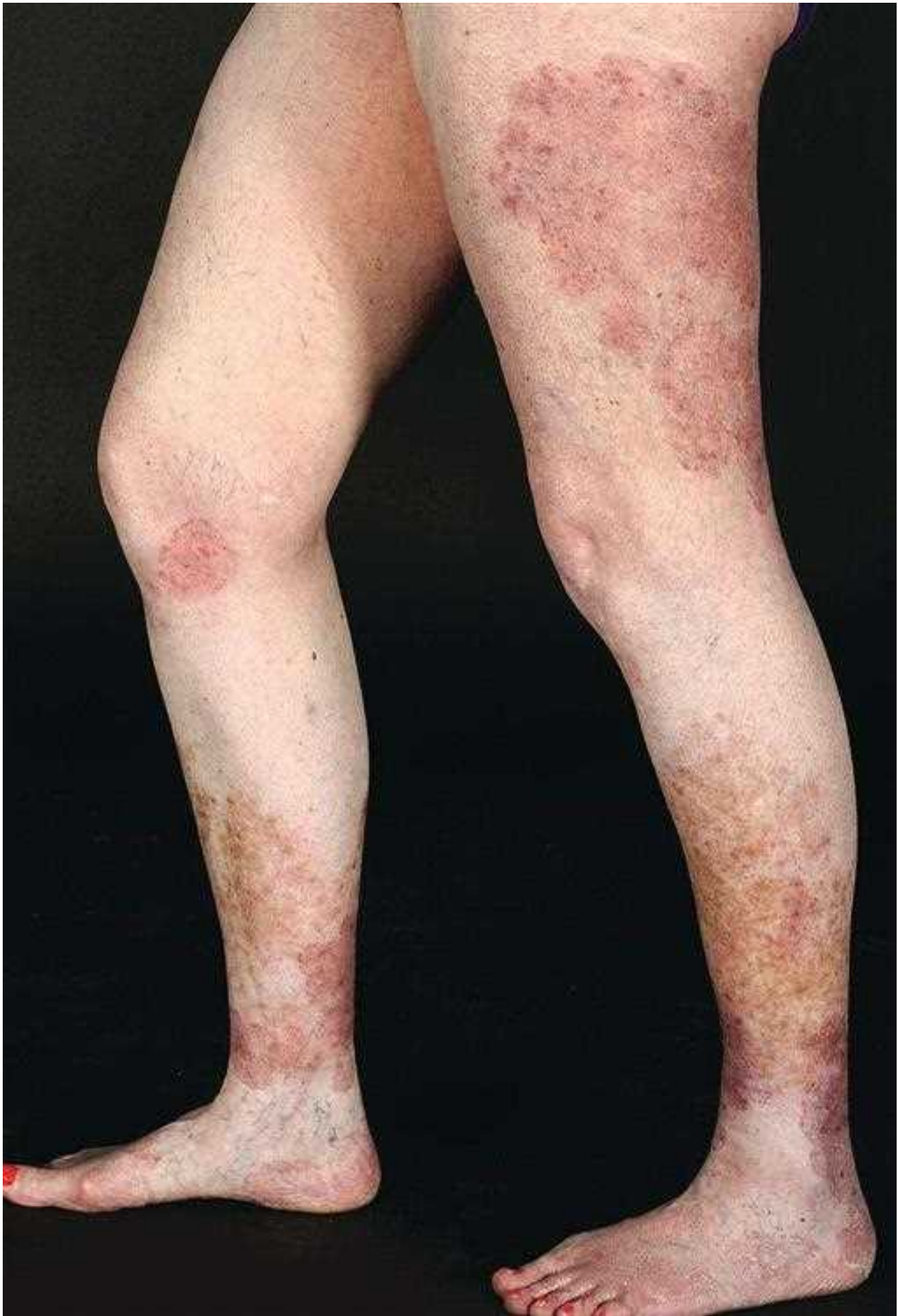

Figure 16.11 Tinea corporis.

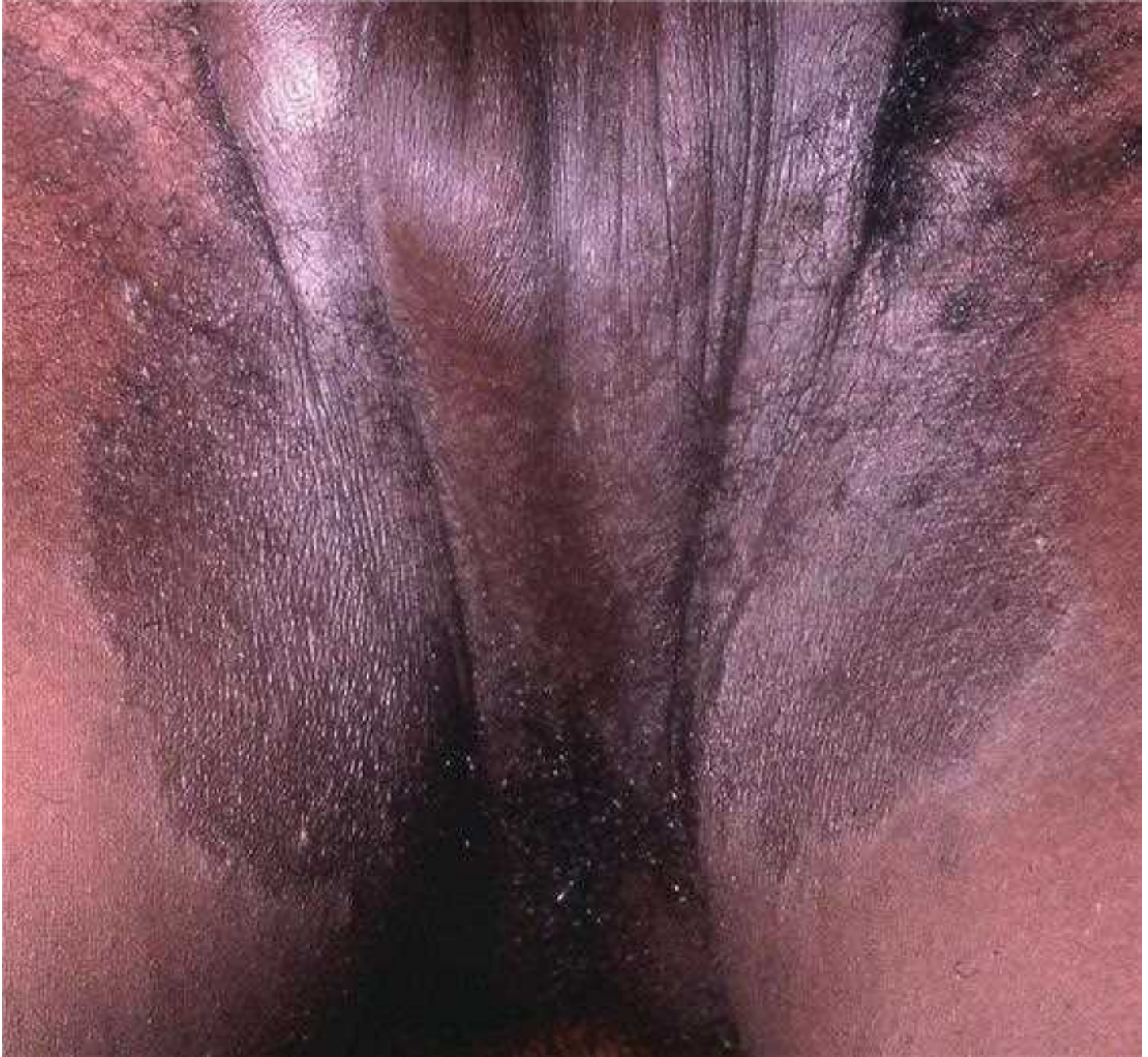

Figure 16.12 Tinea cruris.

If antifungals are not available, then simple measures such as antiseptic paints – Neutral Red or Castellani's paint – can be used. Whitfield's ointment (benzoic acid ointment) is easily prepared and is reasonably effective for superficial fungal infections.

Pityriasis versicolor affects the upper back, neck, chest, and arms. It usually becomes apparent when the skin is exposed to the sun as these areas fail to tan. Well-defined macular lesions of variable colour (hence the name 'versicolor') from darker brown ([Figure 16.13](#)) to pale tan-coloured fine scale ([Figure 16.14](#)) appear. The differential diagnosis includes seborrhoeic dermatitis, pityriasis rosea, guttate psoriasis, and vitiligo. In skin scrapings, the

causative organism *Malassezia furfur* can be readily identified. Topical selenium sulfide (Selsun[®]) and topical ketoconazole 2% cream applied once daily for two weeks reportedly cures between 70% and 80% of patients, but one-third relapse. Systemic treatment with ketoconazole (200 mg once daily for two weeks), fluconazole (300 mg once weekly for two weeks) or itraconazole (200 mg once daily for seven days) gives comparable results. The pale areas left behind after treatment will only repigment once the patient is re-exposed to sunlight.

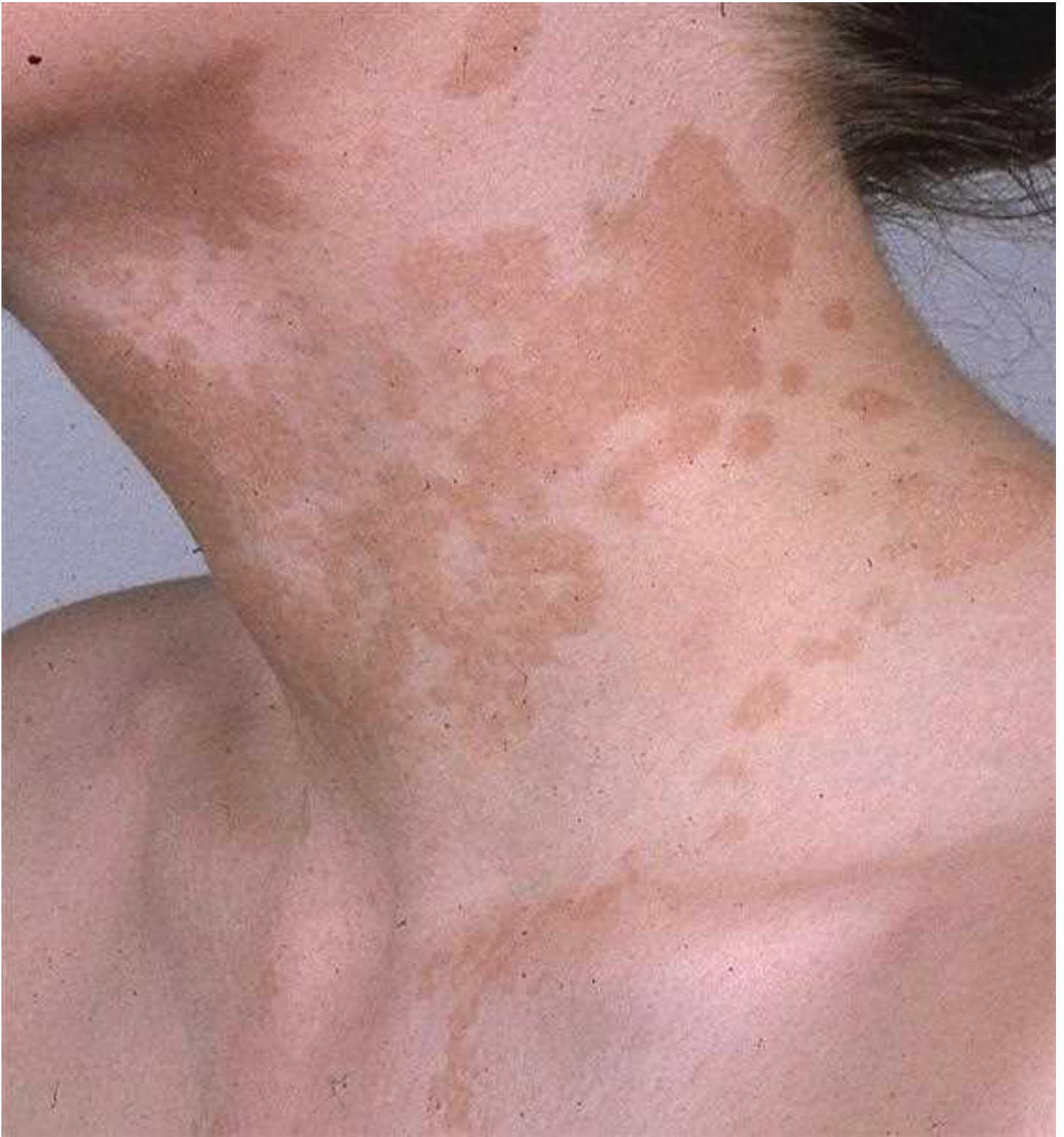

Figure 16.13 Pityriasis versicolor with hyperpigmented scaling.

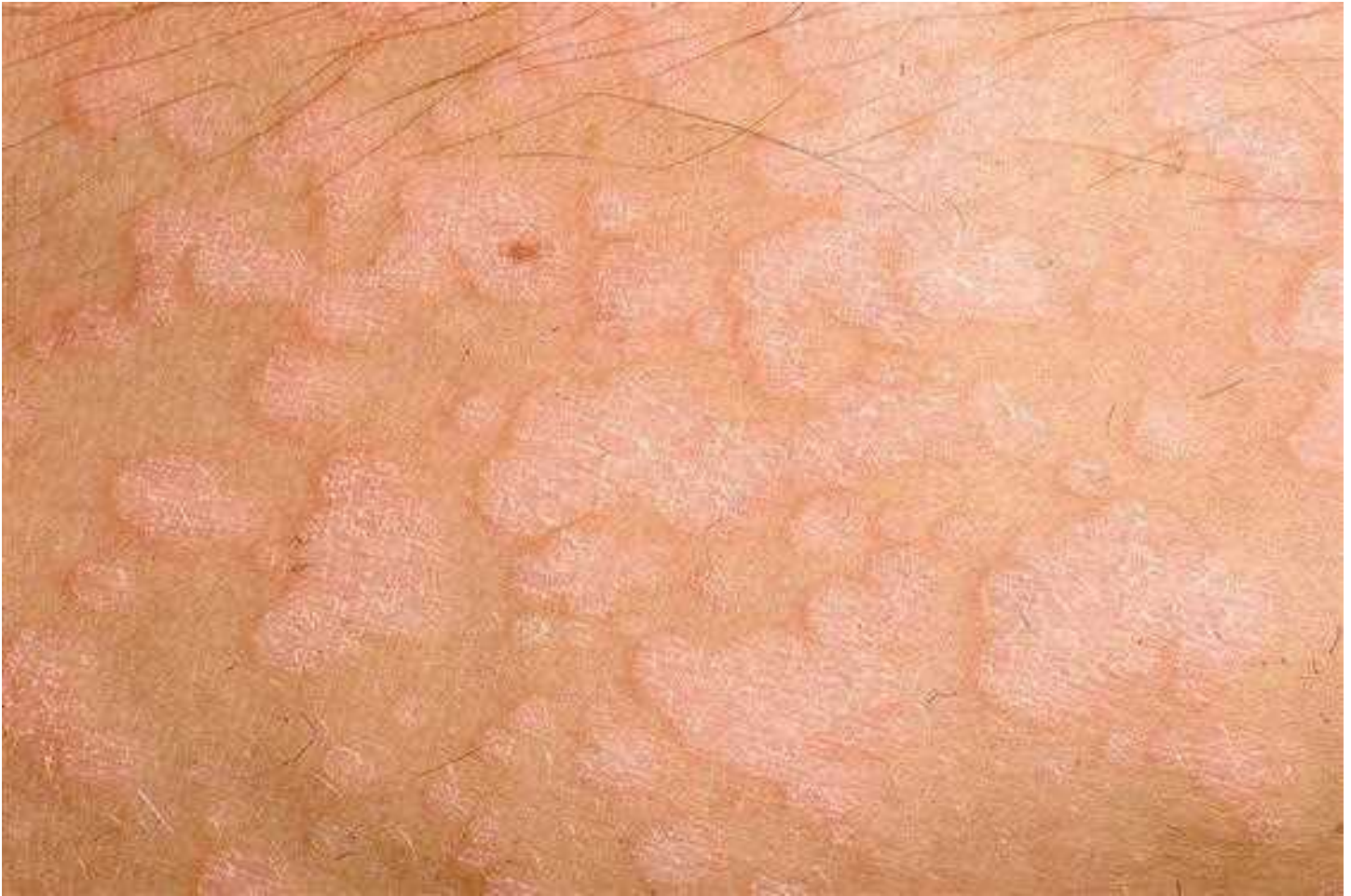

Figure 16.14 Pityriasis versicolor with hypopigmented scaling.

Nails

Onychomycosis affects mainly adult toenails and is usually caused by dermatophytes. Nail plates become thickened, brittle, and white to yellow/brown ([Figure 16.15](#)). The distal nail plate is usually affected initially with spread proximally to involve the nail fold. In psoriasis of the nail, the changes occur proximally and tend to be symmetrical and are associated with pitting and other evidence of psoriasis elsewhere. Lichen planus may also cause nail dystrophy, but this is usually manifested by vertical ridging and nicks in the nails (see [Chapter 20](#)). Onychomycosis may be caused by yeast infection such as *Candida albicans* ([Figure 16.16](#)).

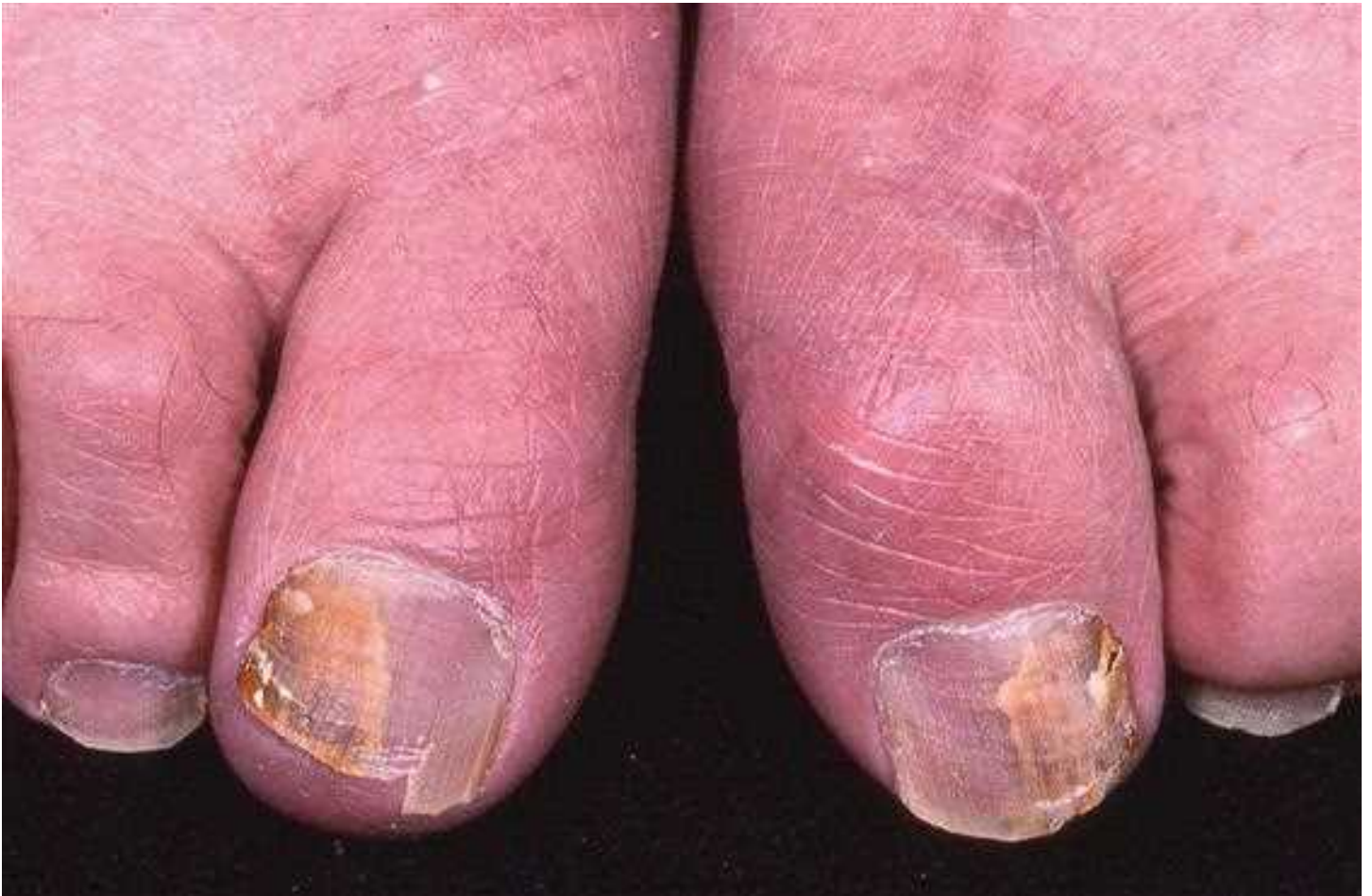

Figure 16.15 Onychomycosis caused by *Trichophyton rubrum*.

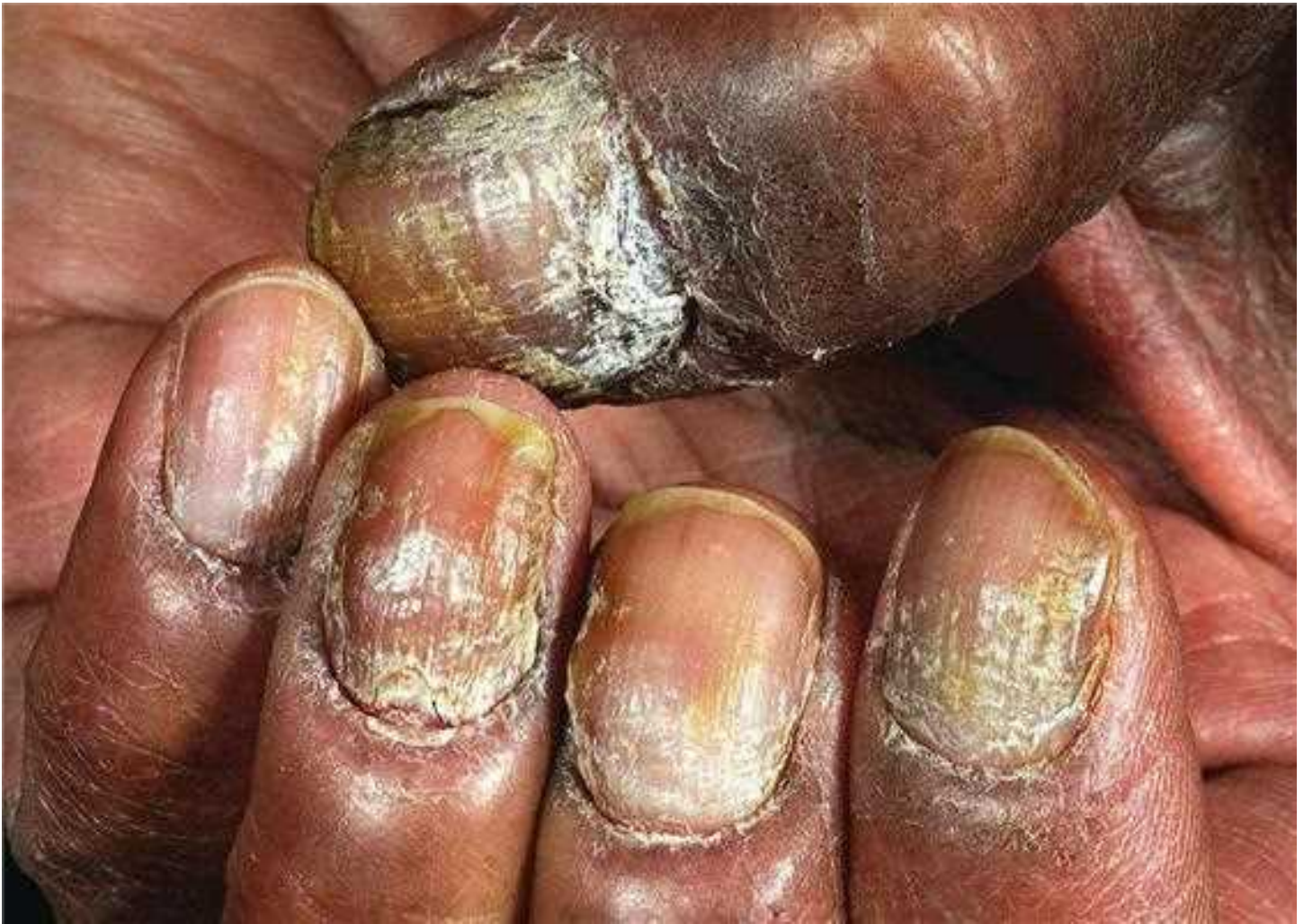

Figure 16.16 Candida onychomycosis.

Topical treatment should be considered for a single nail or very mild distal nail-plate onychomycosis. Agents available include amorolfine and ciclopirox olamine 8% nail lacquer solutions, sodium pyrithione, bifonazole/urea, imidazoles, and allylamines.

Diseased nail plates may be ‘dissolved’ using 40% urea preparations (Canespro[®]) applied carefully to the nail plate, occluded with clingfilm left on overnight and then scraped off before repeating each night for about two weeks. This helps to physically remove the infected nail without the need for medications or surgery. As the nail plates regrow, a topical antifungal such as amorolfine should be used twice weekly to prevent re-infection. Systemic therapy with terbinafine 250 mg daily for 16 weeks (toenails) or 8 weeks (fingernails) is usually considered first line. Terbinafine continues to be effective for many months after stopping the drug, and the abnormal nails should be seen to ‘grow out’ with time. Pulsed itraconazole (200 mg twice daily for one week per month, for a total of four months) is also highly effective. Care should be taken to avoid drug interactions with itraconazole.

Chronic paronychia occurs around the nails of individuals involved in ‘wet work’ who repeatedly put their hands in water (such as child carers, chefs, doctors, dentists, nurses, and hairdressers). Other predisposing factors include diabetes, poor peripheral circulation, removal of the cuticle, and artificial nails. There is erythema and swelling of the nail fold,

often on one side with brownish discolouration of the nail. Pus may be exuded. There is usually a mixed infection including *C. albicans* and bacteria.

Pushing back the cuticles should be avoided. This is commonly a long-term condition, lasting for years. The hands should be kept as dry as possible, an azole lotion applied regularly around the nail fold, and in acute flares a course of erythromycin prescribed. Oral itraconazole (one week per month for three months) or fluconazole (one dose per week for three months) can be used to treat severe infections.

Yeast infections

Candida infection may occur in the flexures of infants, elderly, or immobilised patients, especially under the breasts and abdominal skin folds. This should be differentiated from (i) psoriasis, which does not usually itch; (ii) seborrhoeic dermatitis, a common cause of a flexural rash in infants; and (iii) contact dermatitis/discoid eczema. *Candida* intertrigo is symmetrical and 'satellite' pustules or papules outside the outer rim of the rash are typical ([Figure 16.17](#)). Yeast, including *C. albicans*, may be found in the mouth ([Figure 16.18](#)) and vagina of healthy individuals. Clinical lesions in the mouth – white buccal plaques or erythema – may develop. Predisposing factors include general debility, impaired immunity (including human immunodeficiency virus [HIV]), diabetes mellitus, endocrine disorders, and corticosteroid treatment. Vaginal candidosis or thrush is a common (occasionally recurrent) infection of healthy young women, leading to itching, soreness, and a mild discharge.

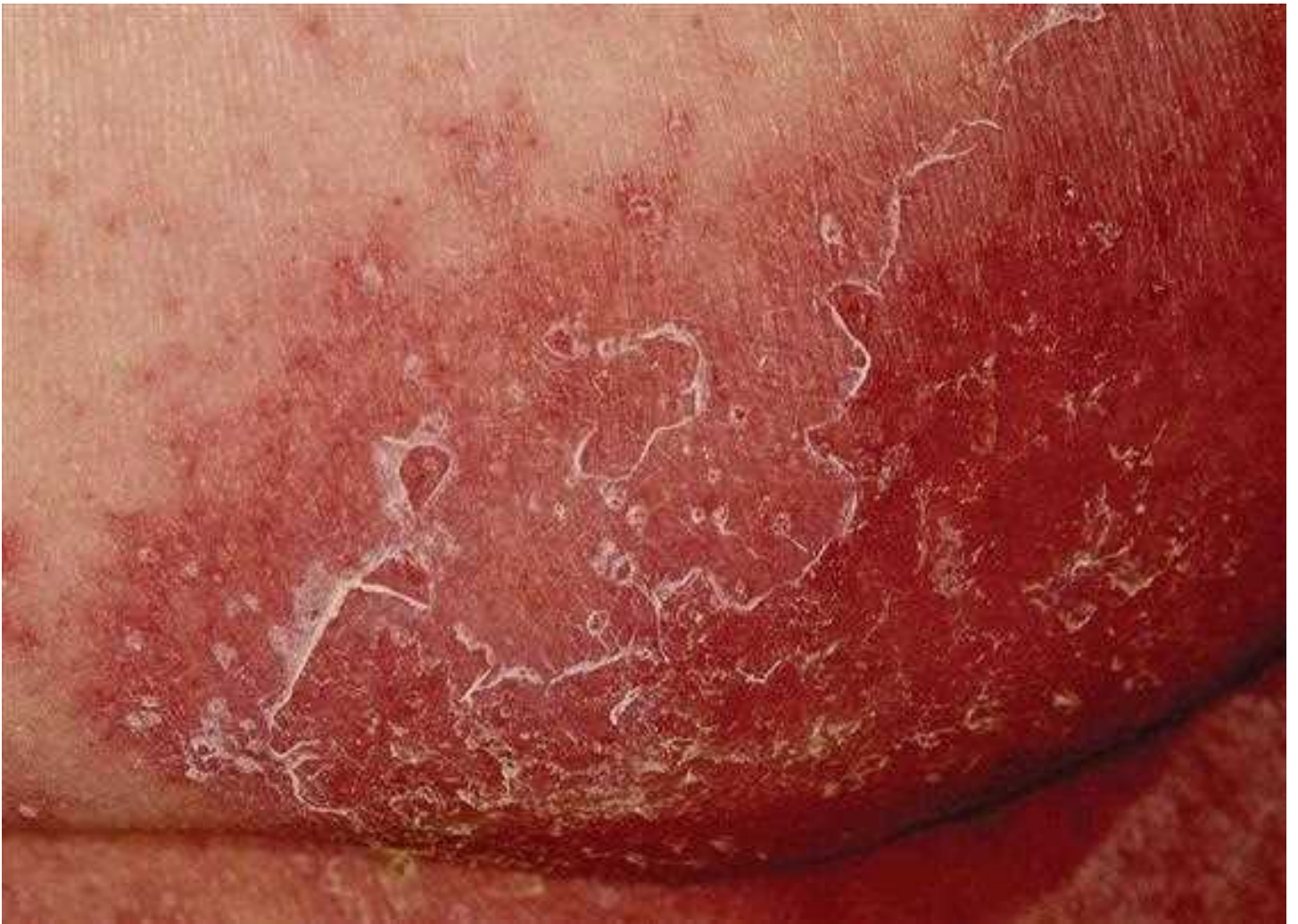

Figure 16.17 Candida infection in the groin.

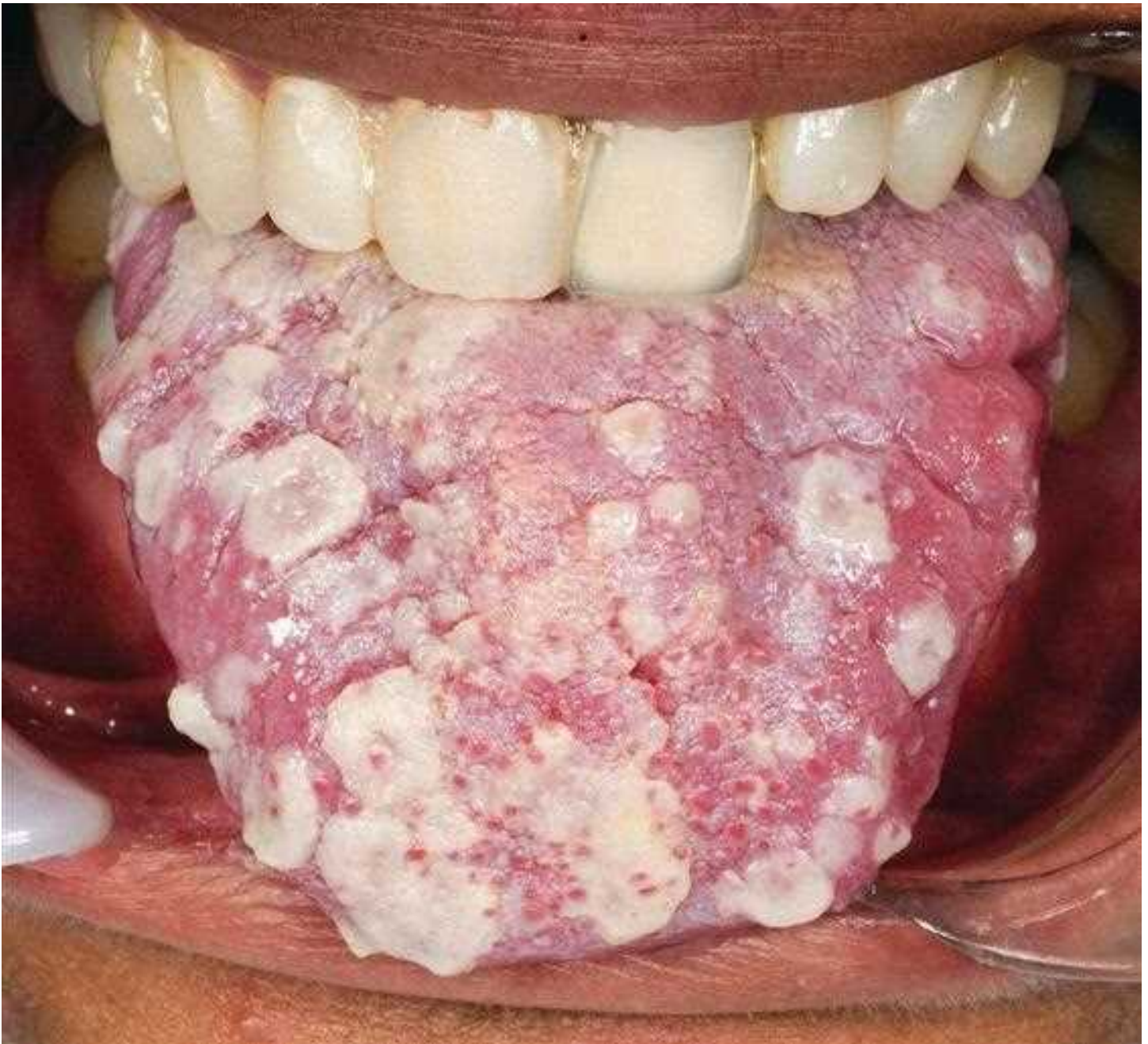


Figure 16.18 *Candida albicans* stomatitis.

The majority of superficial *Candida* infections can be treated using topical antifungals including clotrimazole, miconazole, and nystatin in various formulations including pastilles, lozenges, oral gel, mouthwashes, pessaries, creams, and lotions. Many patients find systemic treatments more convenient such as fluconazole 150 mg as a single dose or itraconazole 200 mg twice for one day. Some drugs interact with azole drugs, the main ones being terfenadine, astemizole, digoxin, midazolam, cyclosporin, tacrolimus, and anticoagulants.

Deep fungal infections

Fungal infections of the deeper tissues are rare in healthy individuals and usually only affect those who have underlying medical problems or are immunocompromised by illness or

medication. However, implantation of fungi into the skin through trauma may precipitate a chronic deep localised infection in otherwise healthy individuals. Fungal infections that involve the deeper skin tissues include histoplasmosis, cryptococcosis, sporotrichosis, *Fusarium* spp. ([Figure 16.19](#)), and *Penicillium marneffe*. In HIV patients, papules resembling molluscum contagiosum may be the earliest feature of deep fungal infections with *P. marneffe* and histoplasmosis. In the immunocompromised, neutropenic, and diabetic ketoacidosis patients, severe life-threatening infections may result from mucormycosis species such as *Rhizopus* (found in mouldy bread). These fungi usually infect the facial sinus and may spread to the brain. Initially, symptoms can mimic sinusitis (nasal stuffiness) followed by facial swelling and black pus followed ultimately by necrotic tissue.

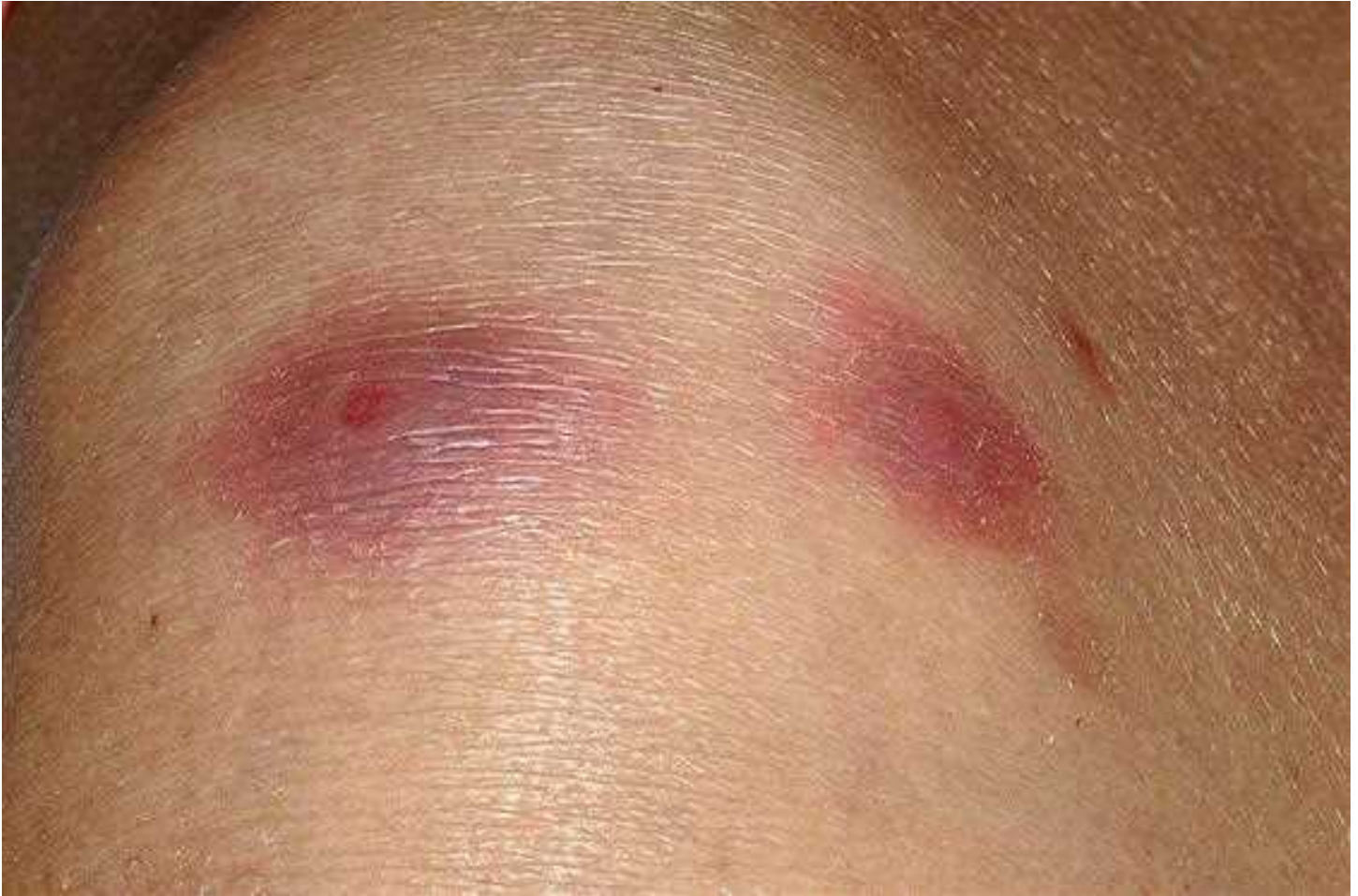

Figure 16.19 *Fusarium* infection in a bone marrow recipient.

In tropical countries, deep fungal infections are more common. These are described in [Chapter 18](#). They should be considered in any patient from a tropical country with chronic indurated and ulcerating lesions ([Figure 16.20](#)).

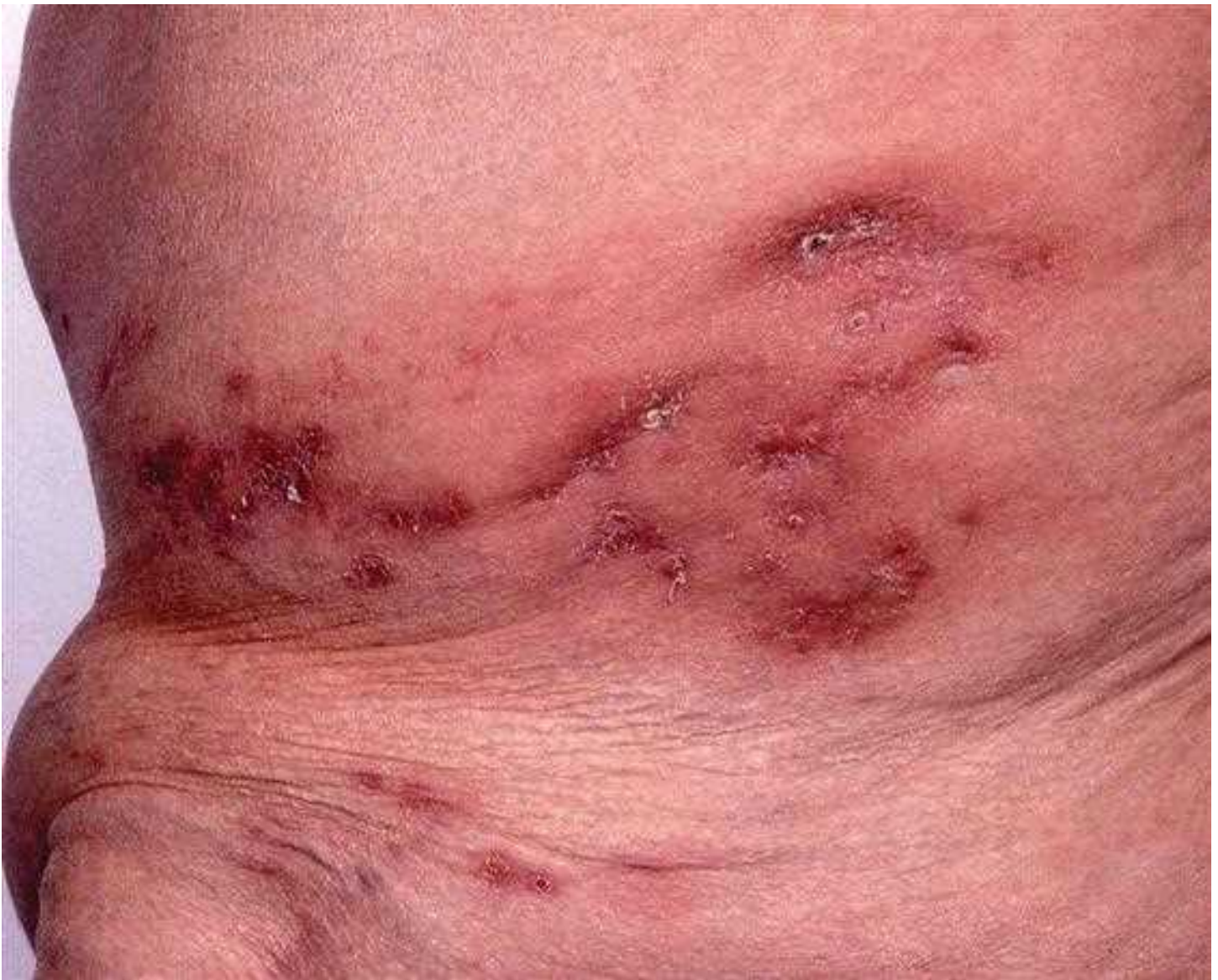

Figure 16.20 Deep fungal infection.

| Fungal condition | 1st Line treatment | 2nd Line treatment |
|-------------------------|---|---|
| Tinea pedis | Terbinafine 1% cream BD 2–4 wk | Terbinafine 250 mg OD 2 wk, Itraconazole 200 mg BD for 1 wk, fluconazole 50–100 mg once/week for 2 wk |
| Tinea cruris/corporis | Terbinafine 1% cream OD/BD 2–4 wk | Terbinafine 250 mg OD for 2 wk, Itraconazole 100 mg OD for 1 wk, fluconazole 50–100 mg once/week for 2–4 wk |
| Tinea capitis | Terbinafine OD for 4 wk (dose based on weight <20 kg 62.5 mg, 20–40 kg 125 mg, >40 kg 250 mg/day) | Griseofulvin 10–20 mg/kg per day for 6–8 wk, Itraconazole 3–5 mg/kg/day for 8 wk |
| | | |

| | | |
|------------------------------|--|---|
| Pityriasis versicolor | Selenium sulfide or ketoconazole shampoo applied to affected area for 5 min repeated daily for 2 wk, Terbinafine 1% cream, ciclopirox cream, ketoconazole 2% cream BD for 2 wk | Ketoconazole 200 mg OD for 2 wk, Itraconazole 200 mg OD for 2 wk, fluconazole 300 mg once week for 2 wk |
| Seborrhoeic dermatitis | Ketoconazole 2% shampoo/cream to treat affected skin (daily until clear then twice weekly to prevent relapse), hydrocortisone 1% or protopic 0.1% BD until rash clears then twice weekly ketoconazole to prevent relapse | Itraconazole 200 mg OD for 7 d, then 200 mg for 2 d each month (to prevent relapse), Betamethasone scalp application daily until itching and scaling subside, then maintenance with azole (topical or oral) |
| Onychomycosis (dermatophyte) | Terbinafine 250 mg OD 2–4 mo (plus/minus topicals) Topical treatment with amorolfine, efinaconazole, ciclopirox, 40% urea paste | Itraconazole 200 mg BD for 1 wk per month for 2–3 /12, fluconazole 150–300 mg once/week for 3–6 mo |

Systemic antifungal drugs

Severe or disseminated cutaneous fungal infections may require prolonged treatment with a systemic antifungal drug. Oral preparations available include terbinafine, which can be used to treat widespread dermatophyte infections (scalp, nails, skin), and sporotrichosis.

Itraconazole is effective against candidiasis, seborrhoeic dermatitis, pityriasis versicolor, aspergillosis, histoplasmosis, and blastomycosis. Griseofulvin is mainly used to treat tinea capitis but may also be used to treat tinea corporis. Voriconazole is effective against invasive candidiasis and aspergillosis. Recent evidence suggests that it is also beneficial in treating *Fusarium* infections. Voriconazole is available as an oral preparation and is therefore useful for outpatient management. Posaconazole is used as prophylaxis against invasive fungal infections post bone marrow transplantation, for severe *Candida* infections, chromoblastomycosis, and zygomycosis. Liposomal amphotericin B is often used empirically to treat presumed fungal infections, disseminated *Candida*, aspergillosis, *Cryptococcus*, and histoplasmosis. Caspofungin may be used as empirical therapy in febrile neutropenic patients and for the management of disseminated aspergillosis and candidaemia.

Further reading

Goering, R., Dockrell, H., Zuckermann, M. et al. (2012). *Mim's Medical Microbiology*, 5e. Saunders.

Richardson, M.D. and Warnock, D.W. (2012). *Fungal Infection: Diagnosis and Management*,

4e. Wiley-Blackwell.

CHAPTER 17

Insect Bites and Infestations

Rachael Morris-Jones

Guy's and St Thomas' NHS Foundation Trust, London, UK

OVERVIEW

- Bites can cause a local skin reaction and/or systemic disease in humans through the transmission of parasites, bacteria, or viruses.
- Biting insects (including mosquitoes, midges, bedbugs, fleas, sandflies, mites, ticks, and lice) cause erythematous pruritic lesions on exposed skin, usually in groups/clusters.
- A generalised anaphylactic reaction to an insect sting can be life-threatening. Patients known to be at risk should carry a preloaded syringe of adrenaline to use when reactions occur.
- Worldwide, scabies is the most common infestation. Female mites burrow through the skin, resulting in intense itching.
- Other infestations include lice (which may transmit trench fever and typhus). Pubic lice may be associated with other sexually transmitted diseases.
- Cutaneous larva migrans occurs when larvae from the dog/cat hookworm penetrate human skin, causing a superficial creeping eruption.

Insect bites and stings

When insects bite, they inject their saliva into the skin and ingest blood, which usually causes localised areas of discomfort and itching ([Figure 17.1](#)), which may be clustered or in a linear distribution ([Figure 17.2](#)). Stinging insects inject venom through the sting that causes a more severe local reaction. More serious effects are due to (i) anaphylactic reactions from the bite/sting or (ii) the introduction of infectious diseases.

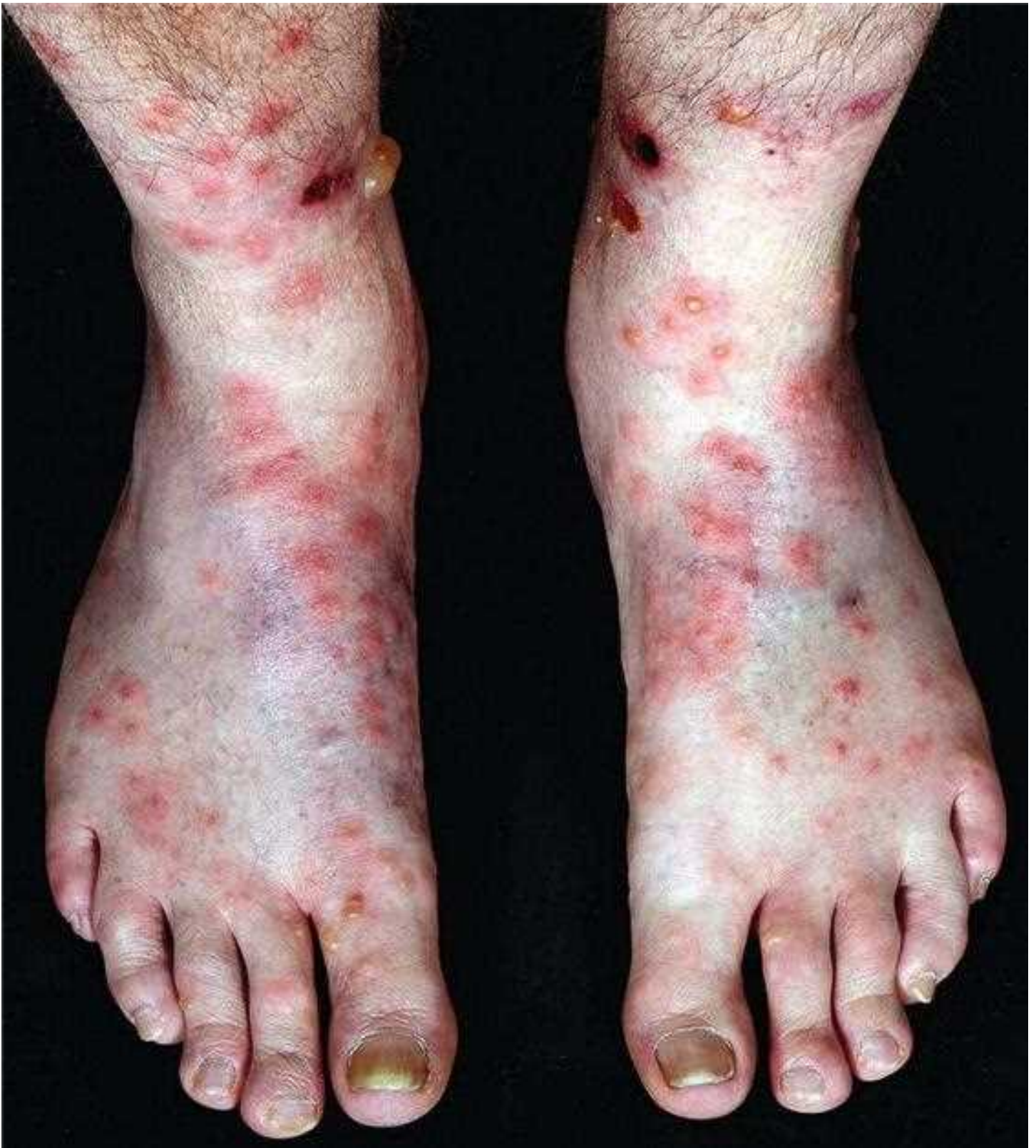

Figure 17.1 Severe bed bug bites.

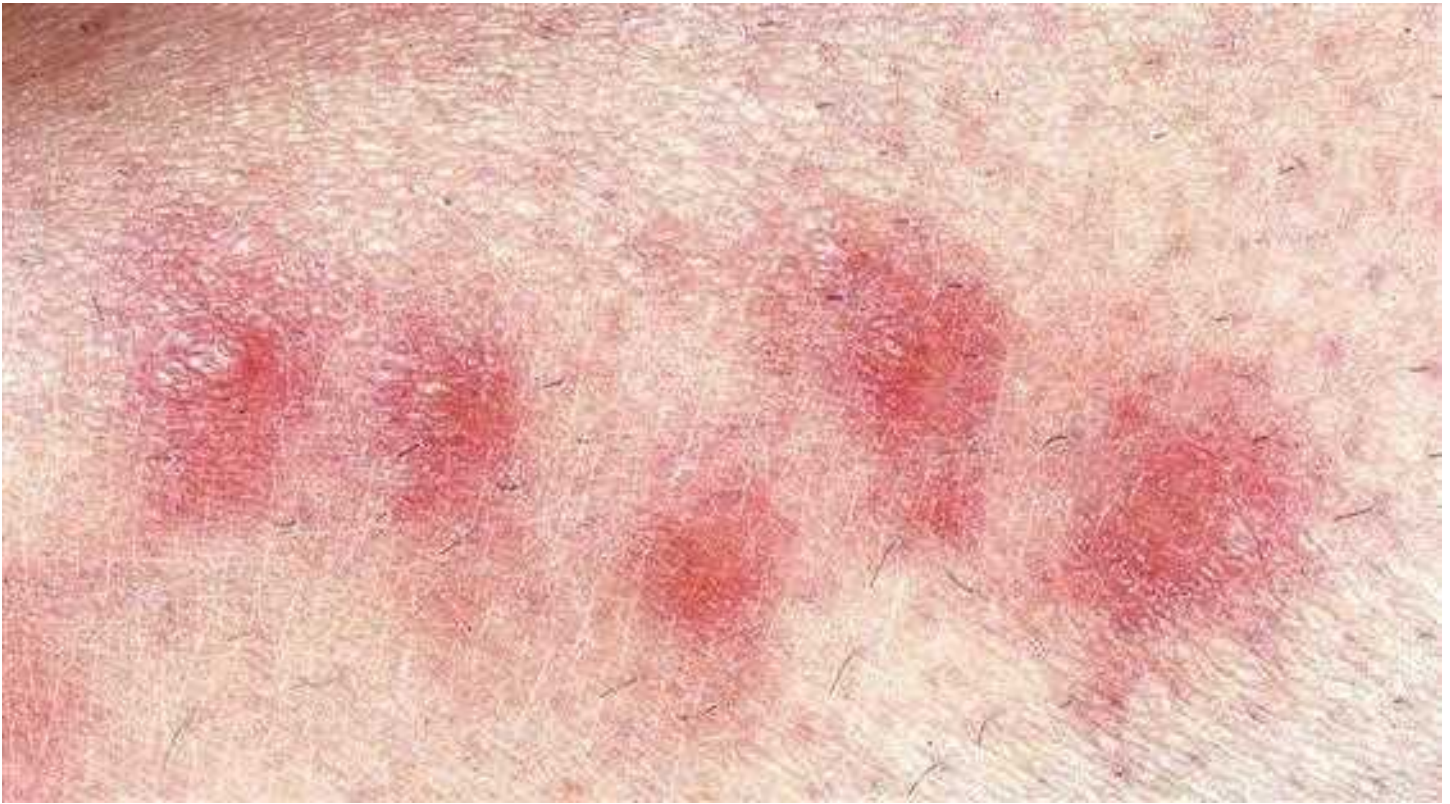

Figure 17.2 Linearity of configuration of insect bite reactions.

Most cases of bites from fleas, midges and mosquitoes are readily recognised ([Box 17.1](#)) and cause few symptoms apart from discomfort/itching. Occasionally, an allergic reaction confuses the picture, such as large bullae ([Figure 17.3](#)). Persuading patients that their recurrent itchy spots are due to flea bites can be difficult and they may reject the suggestion ([Box 17.2](#)). Some patients develop a persistent insect bite reaction which lasts for many months ([Figure 17.4](#)).

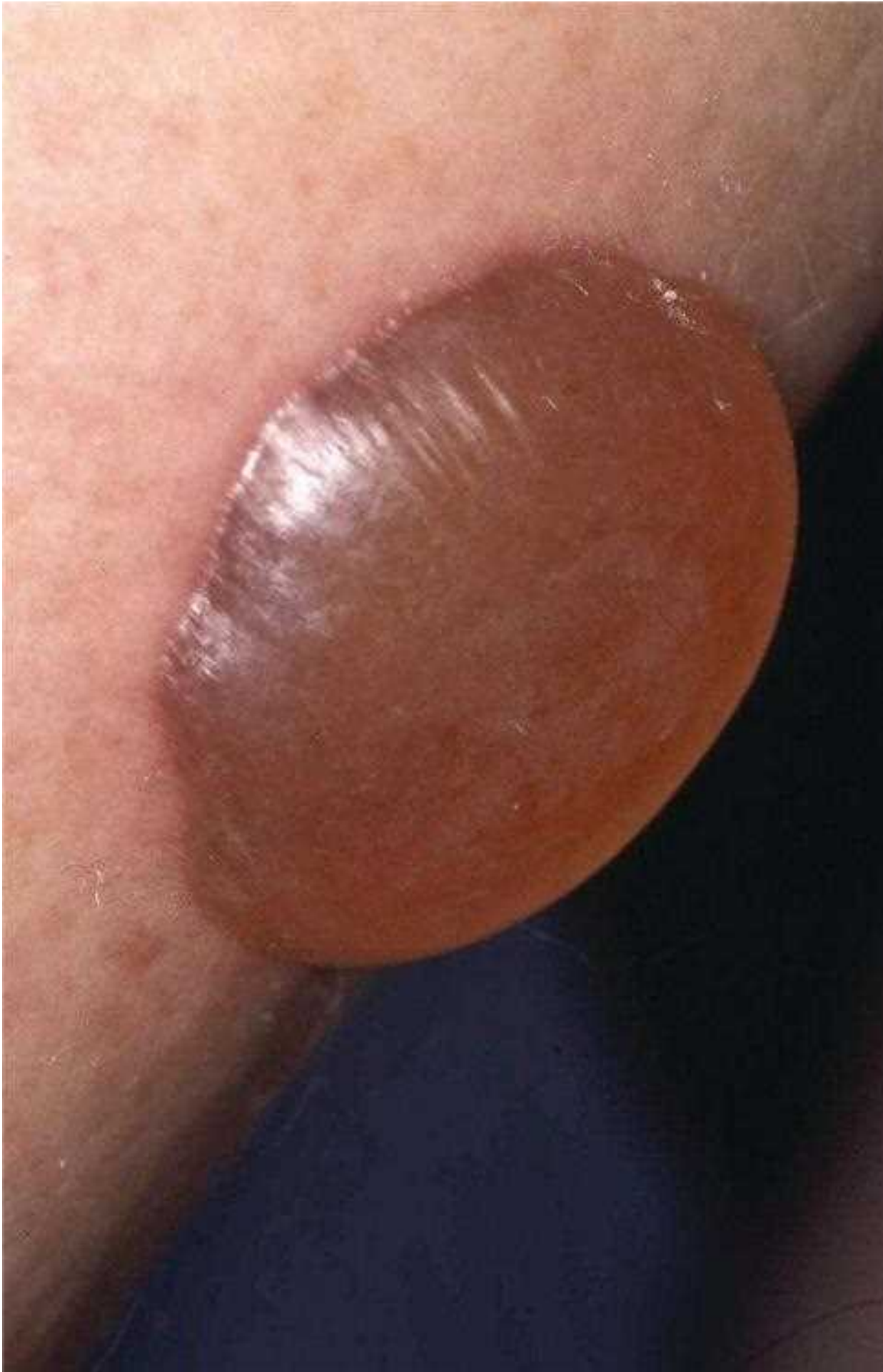

Figure 17.3 Bulla bite reaction.

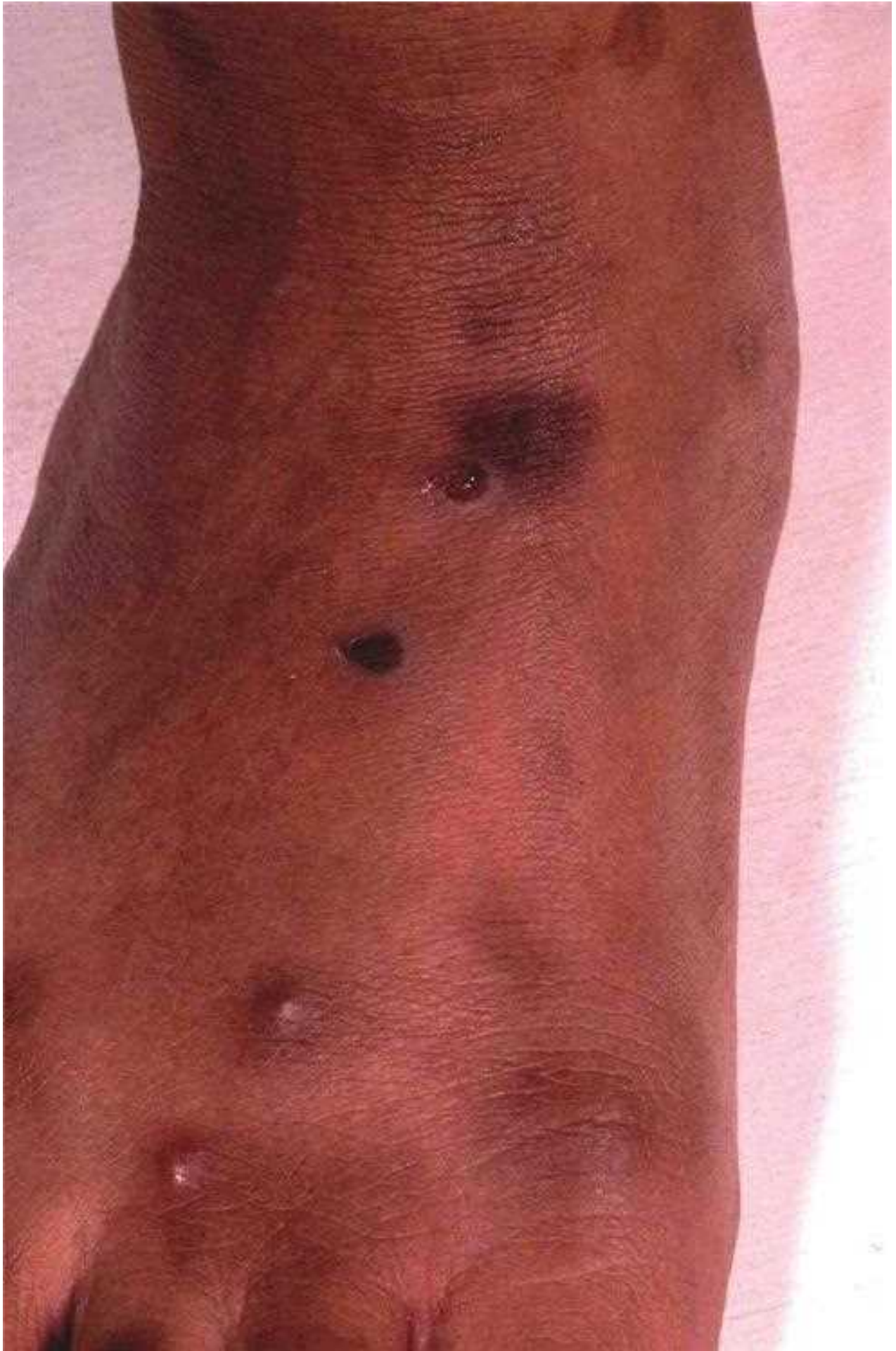

Figure 17.4 Persistent insect bite reaction.

Box 17.1 Clinical features of bites

- Exposed skin sites, especially lower limbs
- Clustering or linear groups of lesions
- Papules, nodules, urticated lesions
- Blisters or ulceration
- Excoriations with secondary bacterial infection.

Box 17.2 Risk factors for bites

- Outdoor activities
- Travel
- Poor-quality accommodation
- Contact with animals
- Recent death of a family pet.

Delusions of parasitosis (DoP)

Patients are convinced they have an infestation with parasites when they do not; the term *pseudoparasitic dysesthesia* may helpfully be used with patients. Those affected (usually women over the age of 50 years) often bring samples in jars of ‘insects’ ([Figure 17.5](#)). Morgellons is virtually identical to DoP except that patients believe that threads of cotton are parasites/spirochetes in their skin. Examination in most cases shows these to be pickings of keratin, cotton, or thread. Sympathy and tact should help reassure the patient and help build confidence; derision and disbelief will tend to trigger seeking a second opinion elsewhere. Two-thirds of patients have the unshakable belief that they are infested with parasite. Application of topical creams and bandaging may help heal the affected excoriated skin; however, antipsychotic drugs are usually required to treat the psychosis and should be prescribed in conjunction with advice from a psychiatrist. Drugs such as risperidone (start with 0.5 mg daily and build up slowly each week, usually 2–4 mg OD is sufficient) can be of benefit, but care must be taken because of potential side effects, particularly if the patient has

epilepsy or cardiovascular disease. More recently, aripiprazole (2 mg for two weeks, then increasing by 2 mg every two weeks up to 12 mg daily) has been shown to be effective. Antidepressants including citalopram have also shown benefit especially in those with concomitant depression.

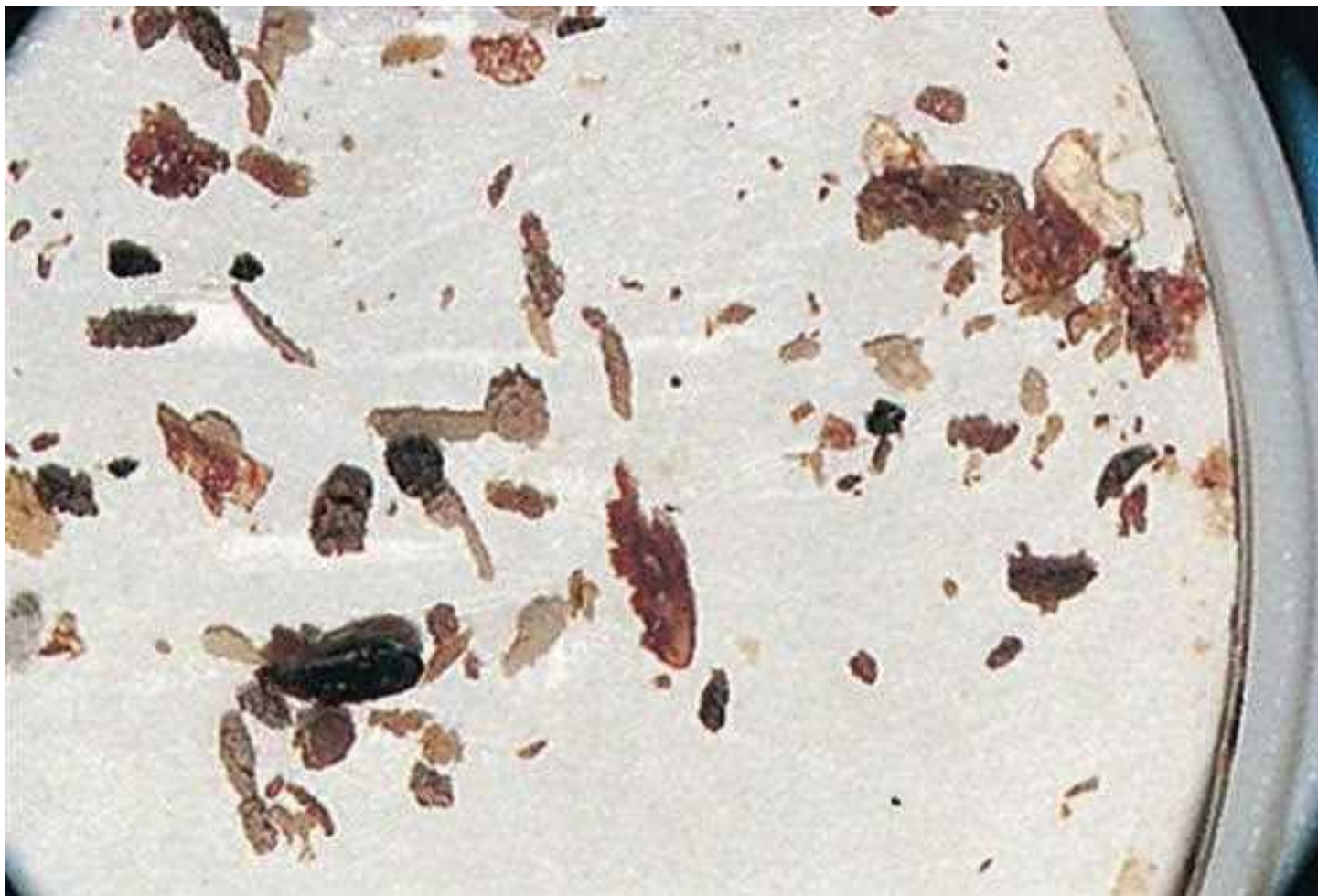


Figure 17.5 Parasitophobia specimens.

Allergic reaction to bites

Commonly, insect bite reactions cause local irritation, and rarely (often to stings rather than bites) a generalised anaphylactic reaction may occur. For localised allergic reactions oral antihistamines and topical steroids are effective and for more generalised reactions oral antihistamine, intramuscular (IM) adrenaline (injected into the lateral thigh), and systemic steroids may be required. In those identified as having severe reactions to stings they should be given a self-injectable epinephrine pen to use in subsequent severe reactions.

Management of bite reactions

- Over-the-counter preparations can be used in the majority of cases, such as bite-soothing spray, lidocaine, and hydrocortisone ointment.

- Antihistamine creams (crotamiton and doxepin) or tablets (cetirizine and desloratadine) can help reduce itching.
- If blisters are present, they can be deflated with a sterile needle.
- Topical steroids such as Betnovate ointment twice daily can be applied to reduce inflammation, swelling, and itching.
- If bite reactions are secondarily infected, topical or oral antibiotics may be needed. Topical fucidin ointment or Fucibet cream (a combination steroid and antibiotic) can be used twice daily. Flucloxacillin usually covers secondary staphylococcal infections (erythromycin in penicillin-sensitive patients).
- In very severe cases, a short course of oral prednisolone may be needed (30 mg daily for five days).

Prevention of bites

Keep the skin covered with clothing (especially dark colours), wear insect repellent (WHO recommends Icaridin (Autan[®], chemical KBR 3023) and DEET (*N,N*-diethyl-metoluamide)), and sleep under bed nets off the ground.

Insect bites transmitting parasites

The identity of the biting insect can be valuable information if a parasitic infection is suspected. Insects that bite humans include mosquitoes, midges, bed bugs, fleas, sand flies, mites, ticks, and lice. Each insect has its own specific distribution, preferred location, seasonal activity, and preferred skin sites. All these factors can help pinpoint the offending insect (see [Table 17.1](#)). It may therefore be significant to know where the patient has been and his or her activities. Travel to tropical areas raises the possibility of parasite infection, while Lyme disease may occur from walking in endemic areas. Handling grain at harvest time may lead to harvest mite (*Pyemotes* spp.) bites.

Table 17.1 Skin lesions associated with insect bites.

| Rash morphology | Differential diagnosis | Vectors (organisms) |
|------------------------|---|---|
| Maculopapular | Human typhus Rocky mountain spotted fever Scrub typhus Relapsing fever | Human louse (<i>Rickettsia</i>) Ticks (<i>Rickettsia</i>) Mites (<i>Rickettsia</i>) Lice/ticks (<i>Borrelia recurrentis</i>) |
| Vesicular | Rickettsial pox | Mouse/louse (<i>Rickettsia</i>) |
| Annular | Lyme disease | Tick (<i>B. burgdorferi</i>) |
| Nodules (pruritic) | Onchocerciasis | Blackfly (<i>Filaria, Onchocerca volvulus</i>) |
| Nodules (ulcerating) | Leishmaniasis | Sand fly (<i>Leishmania</i>) |
| Necrotic lesions | Tick typhus | Tick (<i>Rickettsia</i>) |
| Facial flushing | Yellow fever/dengue | <i>Aedes</i> mosquito (<i>Arbovirus</i>) |

Lyme disease

Tick bites can lead to infection with *Borrelia burgdorferi*, causing arthropathy, fever, and a distinctive rash (erythema chronicum migrans) ([Figures 17.6](#) and [17.7](#)). The bite may not be recalled by the patient. The tick needs to stay on the skin for many hours to take the blood meal and transmit the disease. If the patient is unwell and has visited an area where Lyme disease is endemic (parts of the United States and Europe) or gives a history of a tick bite, then check serology for *B. burgdorferi*. Do not wait for the results, however, but treat with doxycycline 100 mg twice daily for 10–30 days. Children under eight years and pregnant or breastfeeding women can be given amoxicillin or azithromycin.

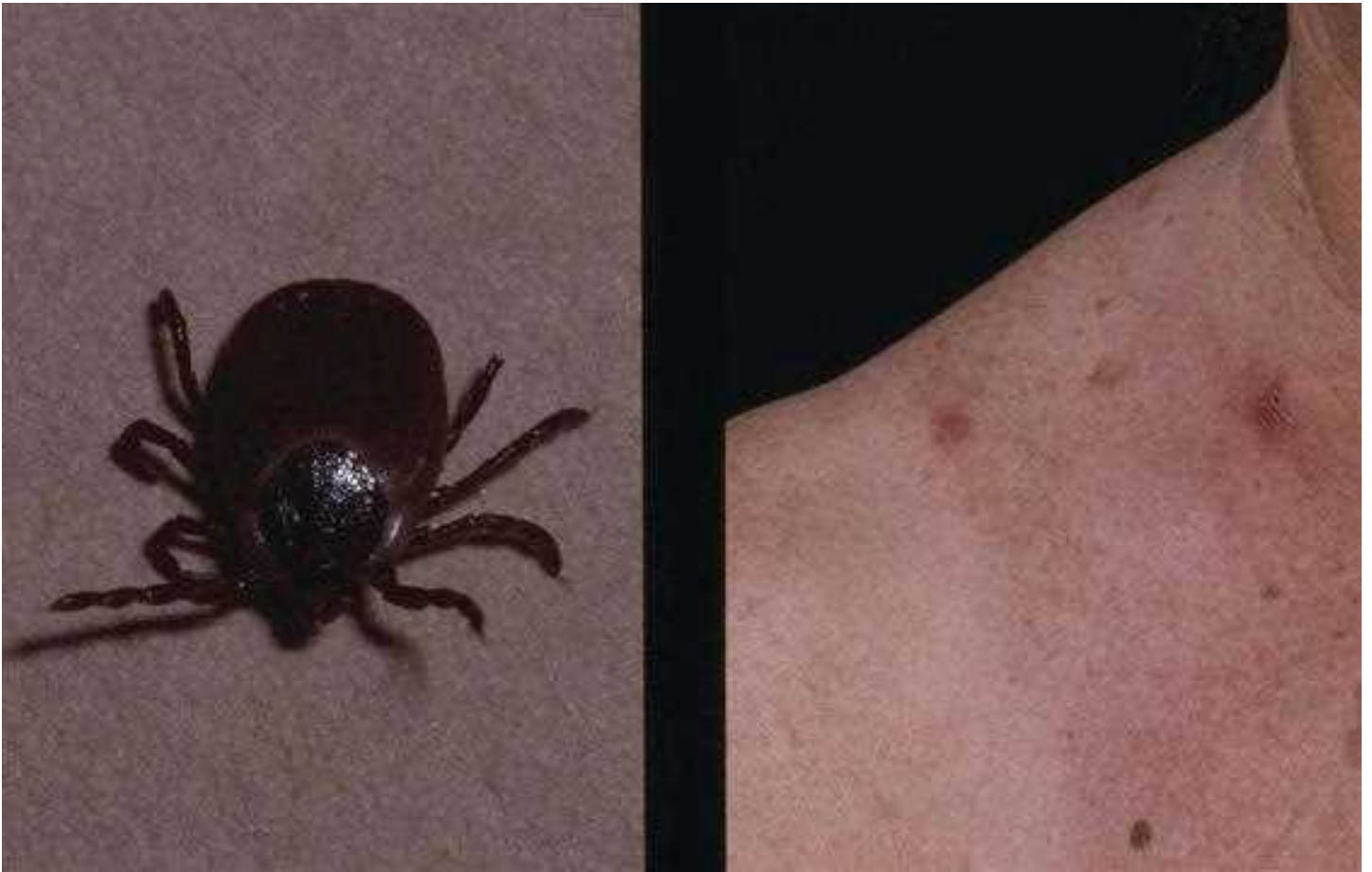

Figure 17.6 Tick and bite reaction.

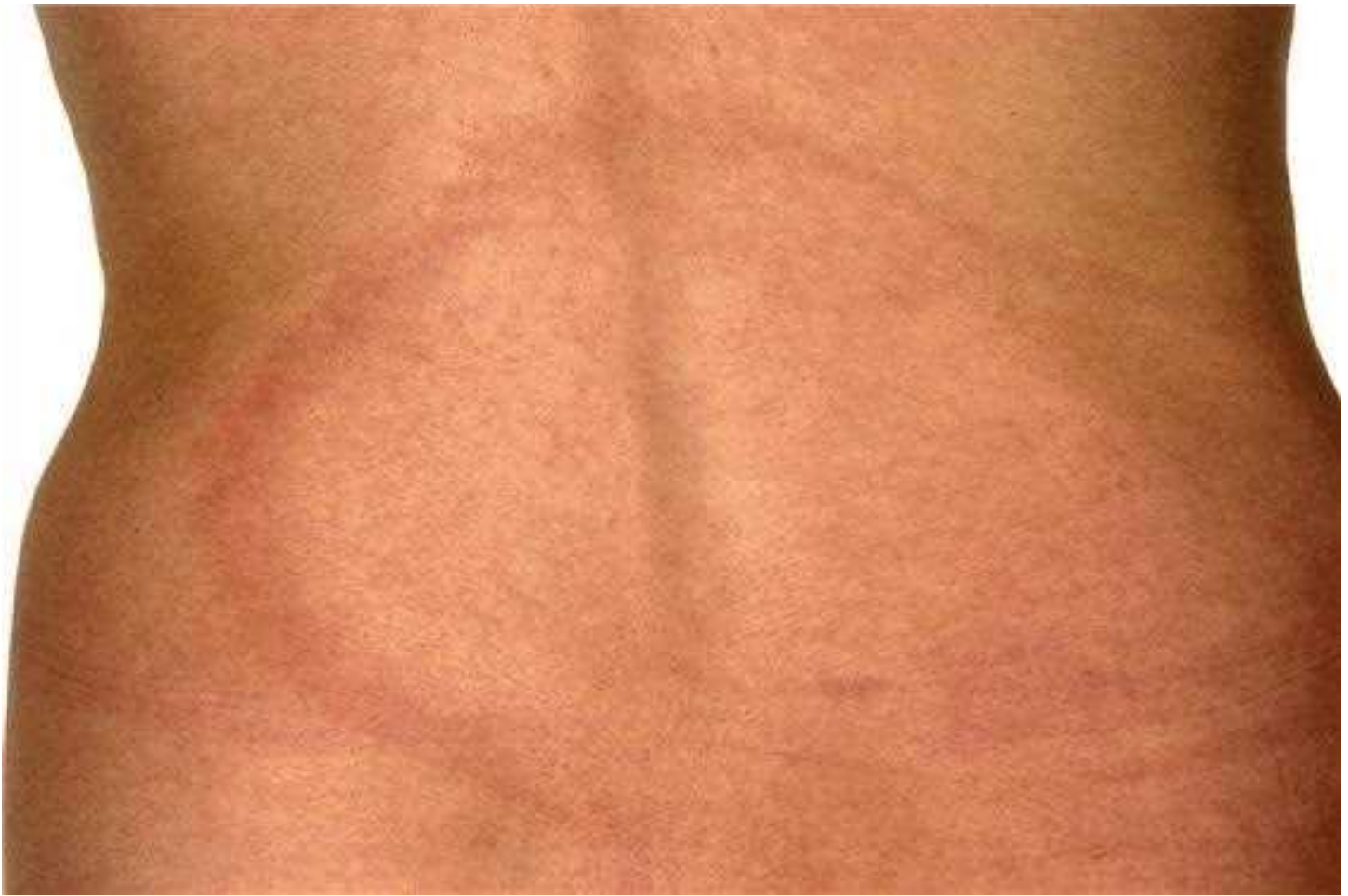

Figure 17.7 Erythema chronicum migrans in Lyme disease.

Spider bites

Bites from spiders found in the tropics and subtropics can be quite severe ([Figure 17.8](#)). The bite of the brown recluse spider (found in parts of the United States) can become necrotic, resembling pyoderma gangrenosum (i.e. a necrotic ulcerated lesion). Some spiders inject venomous neurotoxins that may be fatal – for example, bites from the ‘black widow’ (*Latrodectus mactans*), ‘fiddleback’ (*Loxosceles veclusa*), and *Atrax* species found in Australia. European spiders may cause a painful bite reaction, but they are not venomous. However, with increasing transportation of fresh produce from tropical/subtropical countries, there are incidents of venomous spiders arriving by ship in consignments of fruit to non-endemic areas.

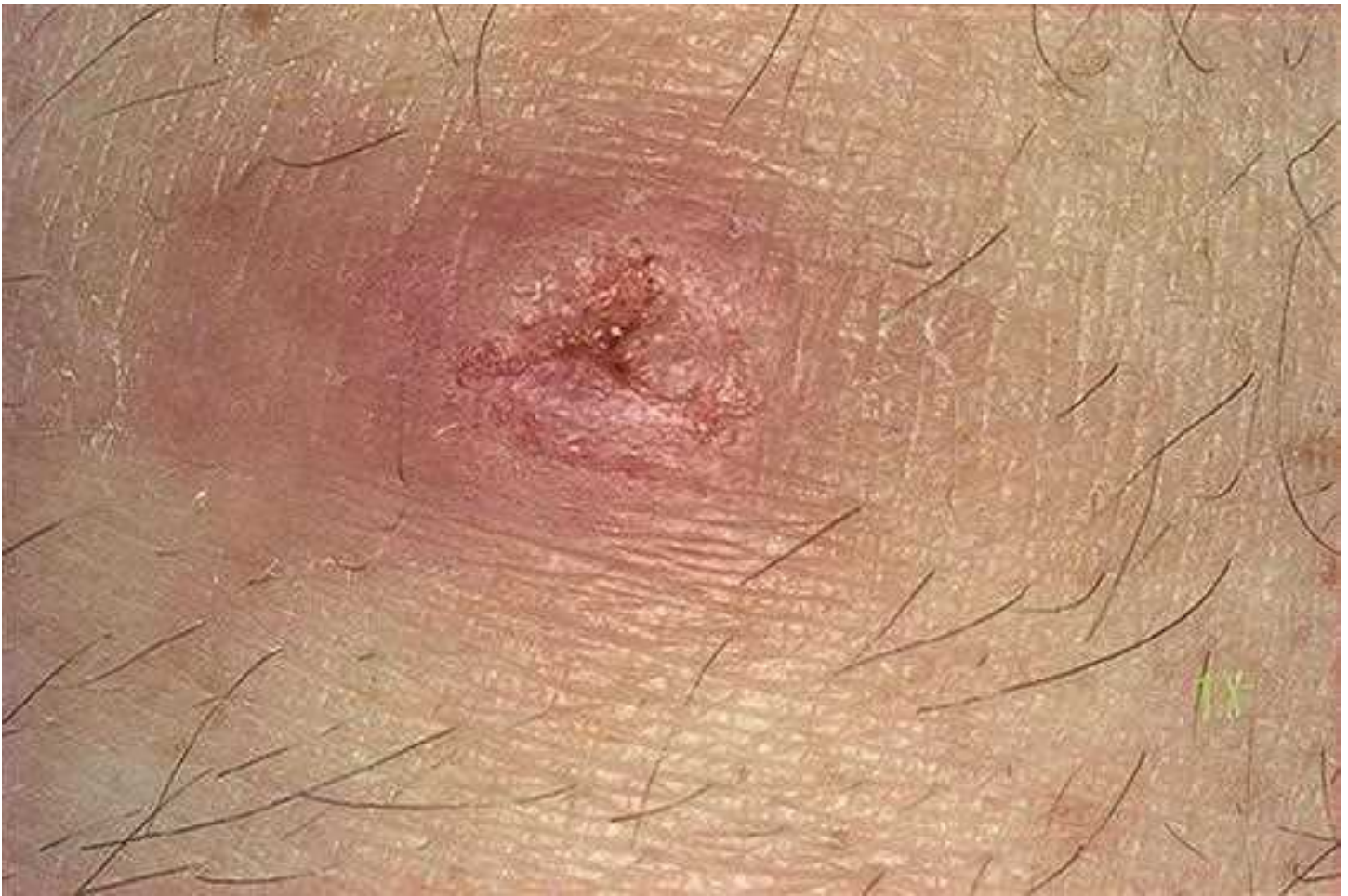

Figure 17.8 Spider bite (Nigeria).

Wasp and bee stings

The Hymenoptera are a large order of insects, which inject venom through the sting apparatus. Both bee and wasp venom contain histamine, mast cell-degranulating peptide, phospholipase A₂, and hyaluronidase. Local reactions are usually insignificant but generalised systemic reactions with massive respiratory tract oedema can be fatal.

Treatment

Mild local reactions can be treated with oral antihistamines. If anaphylaxis occurs, then an epinephrine autoinjection can be given (currently available in two fixed doses: 0.15 and 0.30 mg) immediately if available. In the emergency room, epinephrine is given IM (1 : 1000 adrenaline, 500 µg in 0.5 ml IM given in the lateral thigh to children >12 years and adults, children 6–12 years 300 µg IM, children <6 years 150 µg IM), repeated every five minutes if necessary. Consider giving additional IV fluids, chlorpheniramine (chlorphenamine), and hydrocortisone. IV adrenaline should only be given by experienced specialists.

Desensitisation with venom extract carried out in a specialised unit is effective in those sensitive to bee venom.

Infestations

Scabies (*Sarcoptes scabiei*)

The most common infestation worldwide is scabies (recognised as a Neglected Tropical Disease by the World Health Organization), which causes intense itching that characteristically keeps those affected awake at night. The female mite burrows into the epidermis and lays eggs which hatch into larvae within a few days. See [Box 17.3](#).

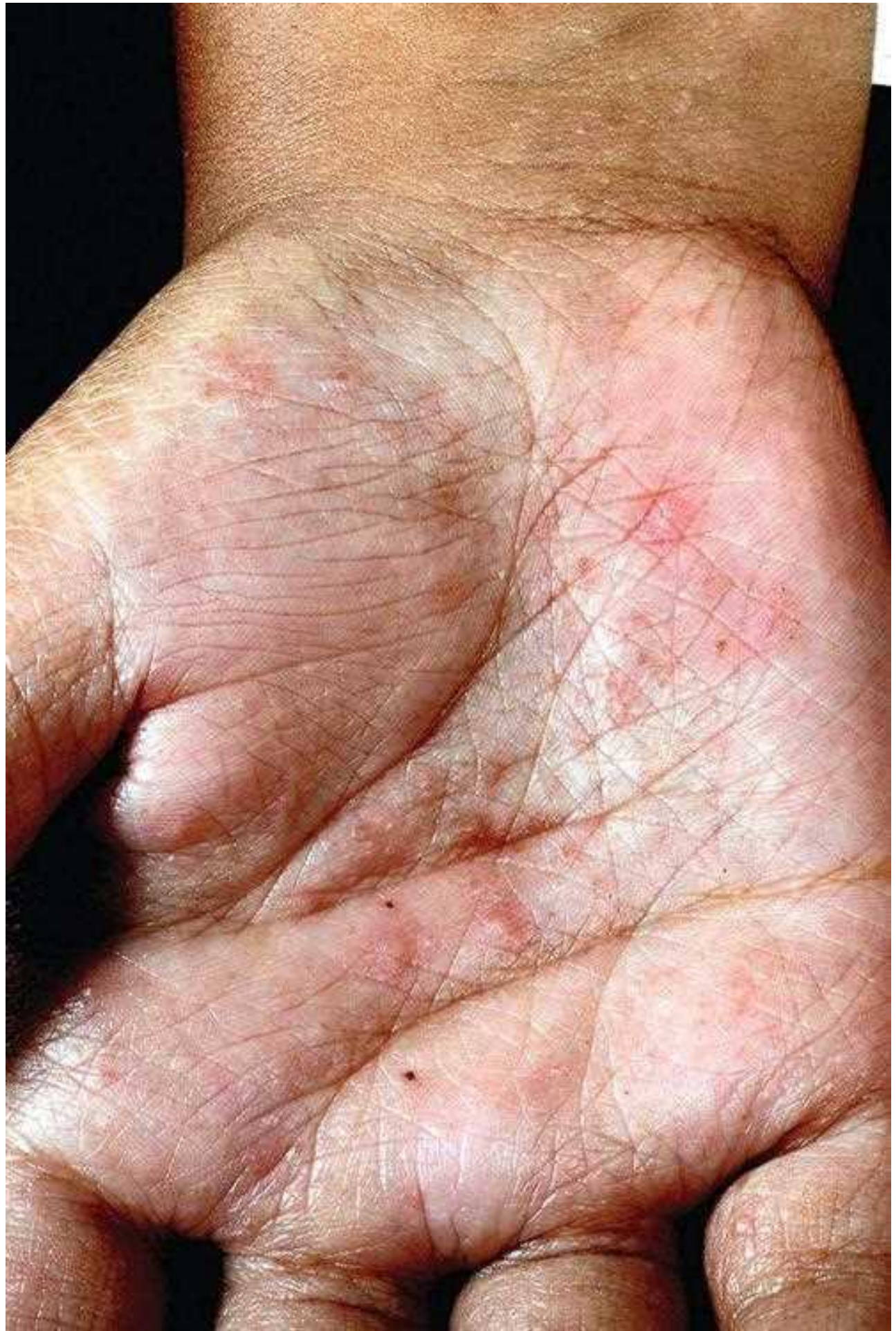Transmission occurs because of close personal contact (at least 15 minutes of skin-to-skin contact) with an infected individual. The first symptoms of itching occur two weeks later when the immune system reacts to the proteins in the mites, eggs, and faeces in the skin. Most infestations in immunocompetent individuals carry 10 adult mites, but in crusted scabies mite numbers will be in the hundreds because of failure of the host's immune system.

[Box 17.3](#) Scabies – points to note

- There may be very few burrows, even though the patient has widespread itching.
- The distribution of the infestation is characteristically the fingers, wrists, nipples, abdomen, genitalia, buttocks, and ankles.
- Close personal contact is required for infestation to occur – for example, within a family, through infants in playgroups, and through regular nursing of elderly patients.
- Itching may persist even after all mites have been eliminated; itching papules on the scrotum and penis are particularly persistent.

Diagnosis

Scabies infestations may be difficult to diagnose because of the wide variation in clinical presentations. However, key points in the history include several individuals in the same household/institution/classroom/ward being affected simultaneously by a rash that is intensely itchy at night. Clinically, burrows can be seen, especially in the finger-web spaces and on the genitals. Burrows are linear palpable ridges on the skin with a black speck indicating the position of the mite ([Figure 17.9](#)), which can be teased out of its burrow using a sterile needle and mounted onto a microscope slide. Patients often have a widespread papular rash, which is due to a reaction to the infestation, with multiple excoriation marks which can become secondarily infected with staphylococcus.



[Figure 17.9](#) Scabies burrows and papules in a child.

Scabies in children

Babies and young children infested with scabies characteristically present with erythematous cutaneous papules and nodules in the axillae and on the soles of the feet ([Figures 17.10](#) and [17.11](#)). It is not unusual for the lesions to blister. Classic burrows are rarely seen in this age group.

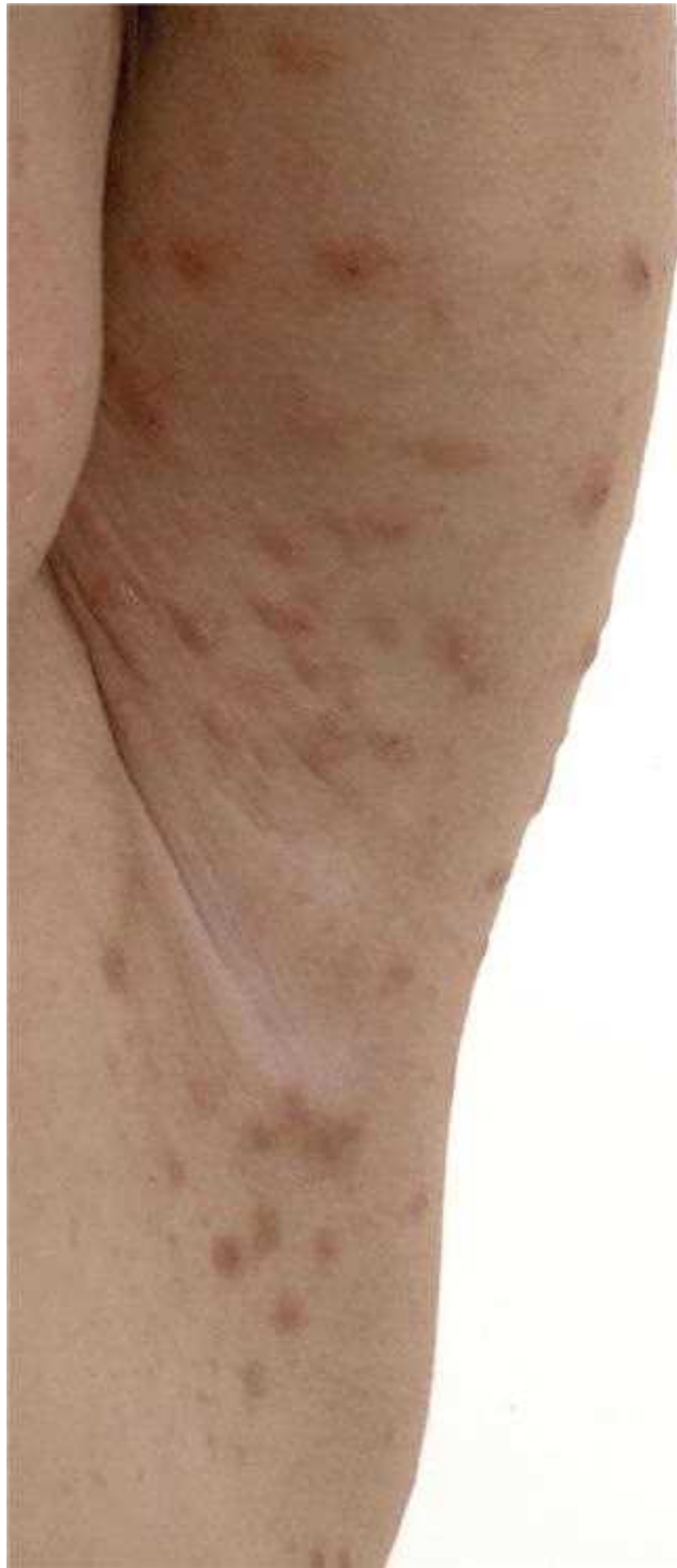

Figure 17.10 Scabies nodules in a child.

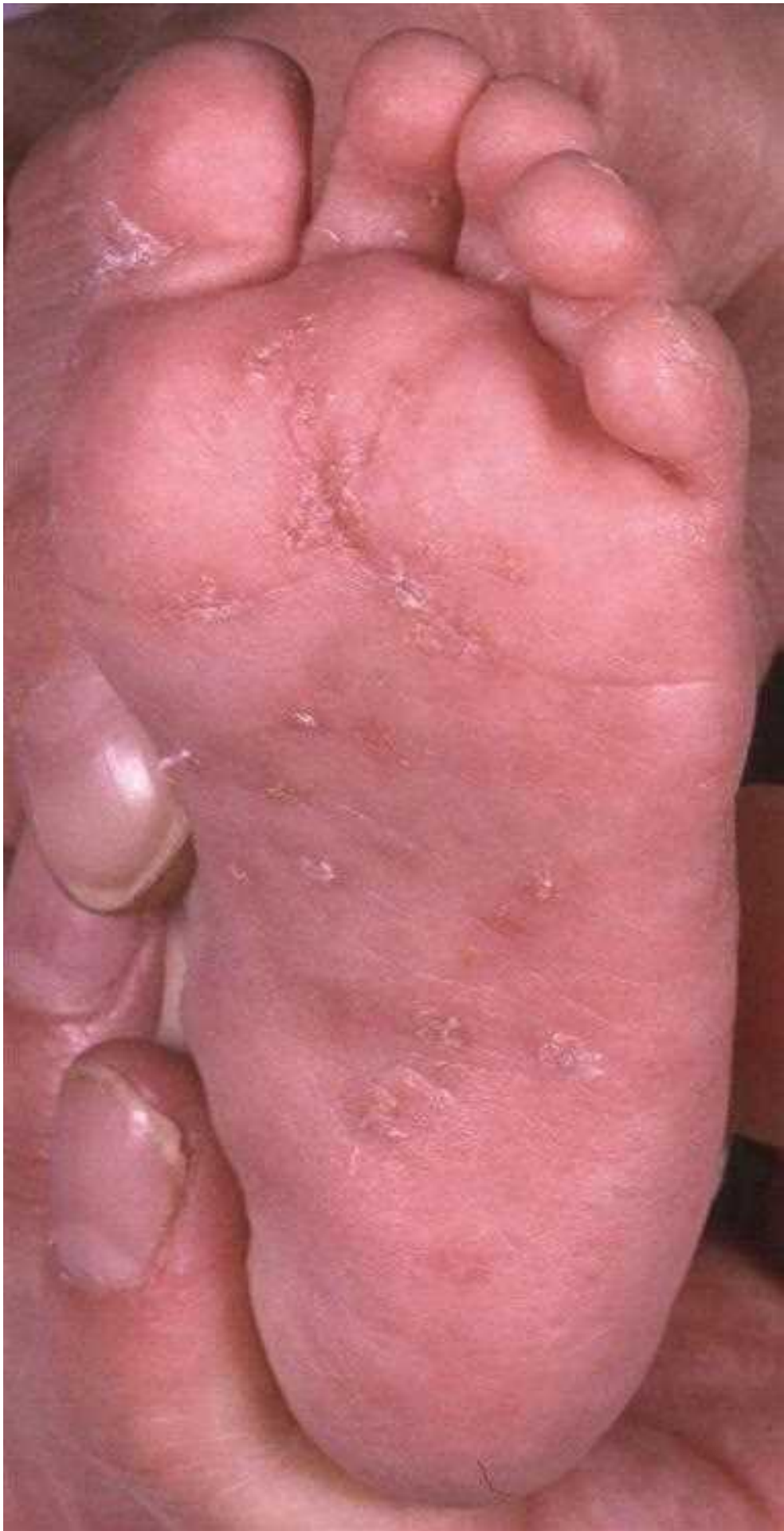

Figure 17.11 Scabies on sole of an infant.

Crusted scabies

Crusted scabies can look similar to dry scaly skin rashes such as psoriasis and eczema, and consequently can be misdiagnosed. Patients are usually immunosuppressed or elderly and do not complain of itching, as their immune cells are not reacting against the mite proteins. Consequently, mite numbers are usually in the hundreds. Clinically patients have a crusted fine scaling on the skin, which is superficial with very little erythema (unlike psoriasis and eczema) ([Figure 17.12](#)). If the diagnosis is missed, then numerous close contacts such as nurses and carers develop classic scabies and small outbreaks can occur.

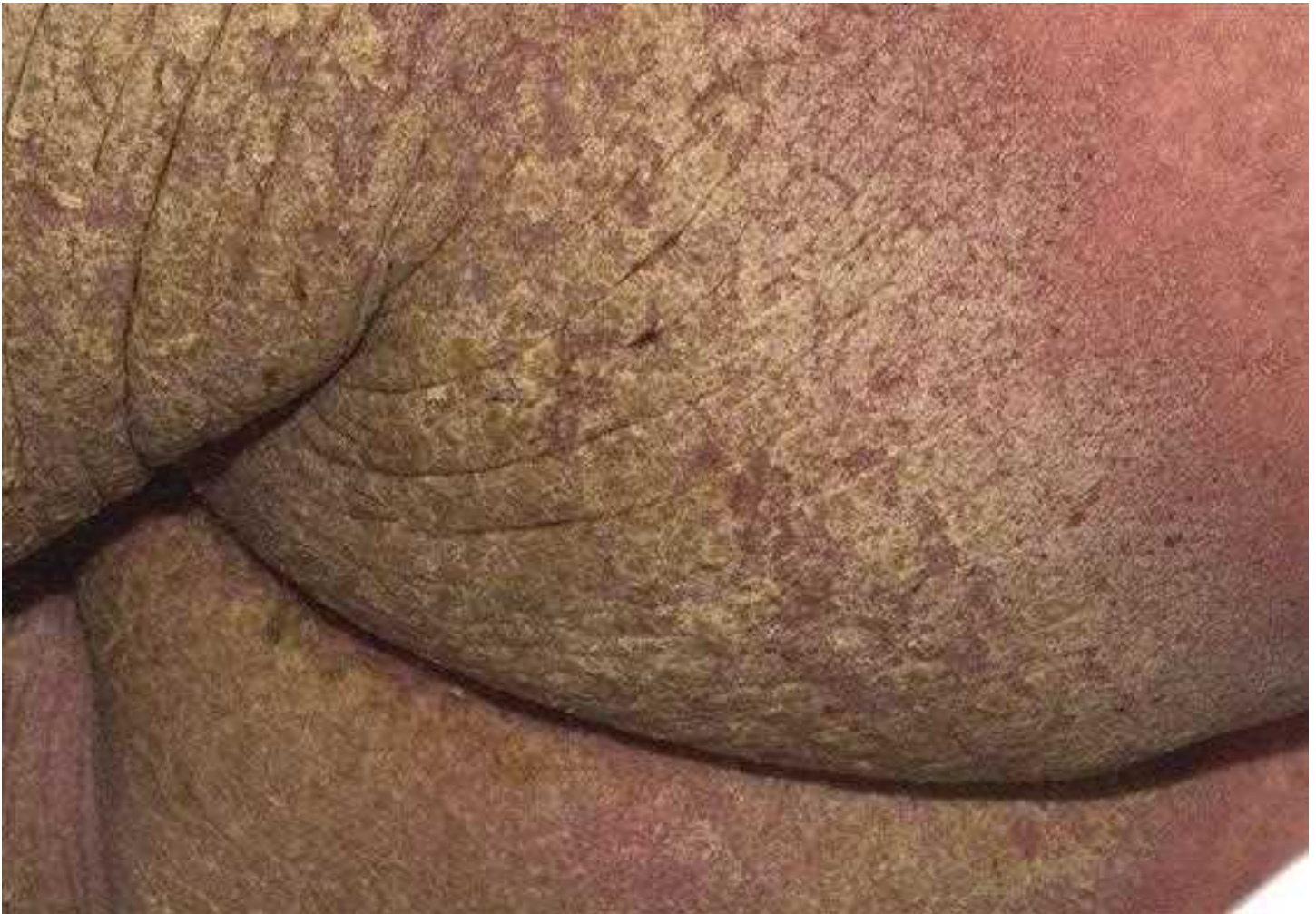

Figure 17.12 Crusted scabies on buttocks.

Management

A full explanation of how to use topical therapy is essential if infestations are to be successfully managed. The most common cause of treatment failure is incorrect use of insecticides. Patients should be told that they and all their close personal contacts need to be treated at the same time, the lotions should be applied from the neck downwards (although the head and neck of babies should also be treated), the treatment left on overnight, and then

repeated after seven days. They should pay attention to the web spaces and genital areas. They should reapply the lotion after washing their hands ([Box 17.4](#)).

Towels, bedding and underwear should be washed. Patients should be advised that the skin itching will take six to eight weeks to subside. Persistent itching often leads patients to conclude that the mites are still active, and they subsequently treat themselves repeatedly, leading to an irritant dermatitis. The itching resolves when the mites, eggs, and faeces have been removed from the skin by the host's immune cells.

Box 17.4 Management of scabies

- First-line treatment for scabies is 5% permethrin cream left on overnight, two applications seven days apart. Adults apply from neck downwards; babies/infants apply to all the skin.
- Second line is 0.5% malathion lotion left on overnight (applied as above).
- Ivermectin 0.2 mg/kg, two doses seven days apart (named-patient basis, UK) can be given to immunocompromised patients and those with crusted scabies (avoid in patients <15 kg and in pregnancy). A new single dose oral agent (phase III trials) moxidectin is expected to be approved for use soon.
- If you suspect genuine resistance (i.e. the treatment has been carried out according to your instructions), then switch to a different class of insecticide.
- Pruritus can be alleviated with menthol in aqueous cream, crotamiton, or doxepin. In severe cases, a topical steroid can be applied twice daily to settle persistent nodular skin reactions.
- If permethrin and malathion are not available, then 10% sulfur in yellow soft paraffin is effective and safe; 25% benzyl benzoate emulsion may also be used.

Lice

Head lice

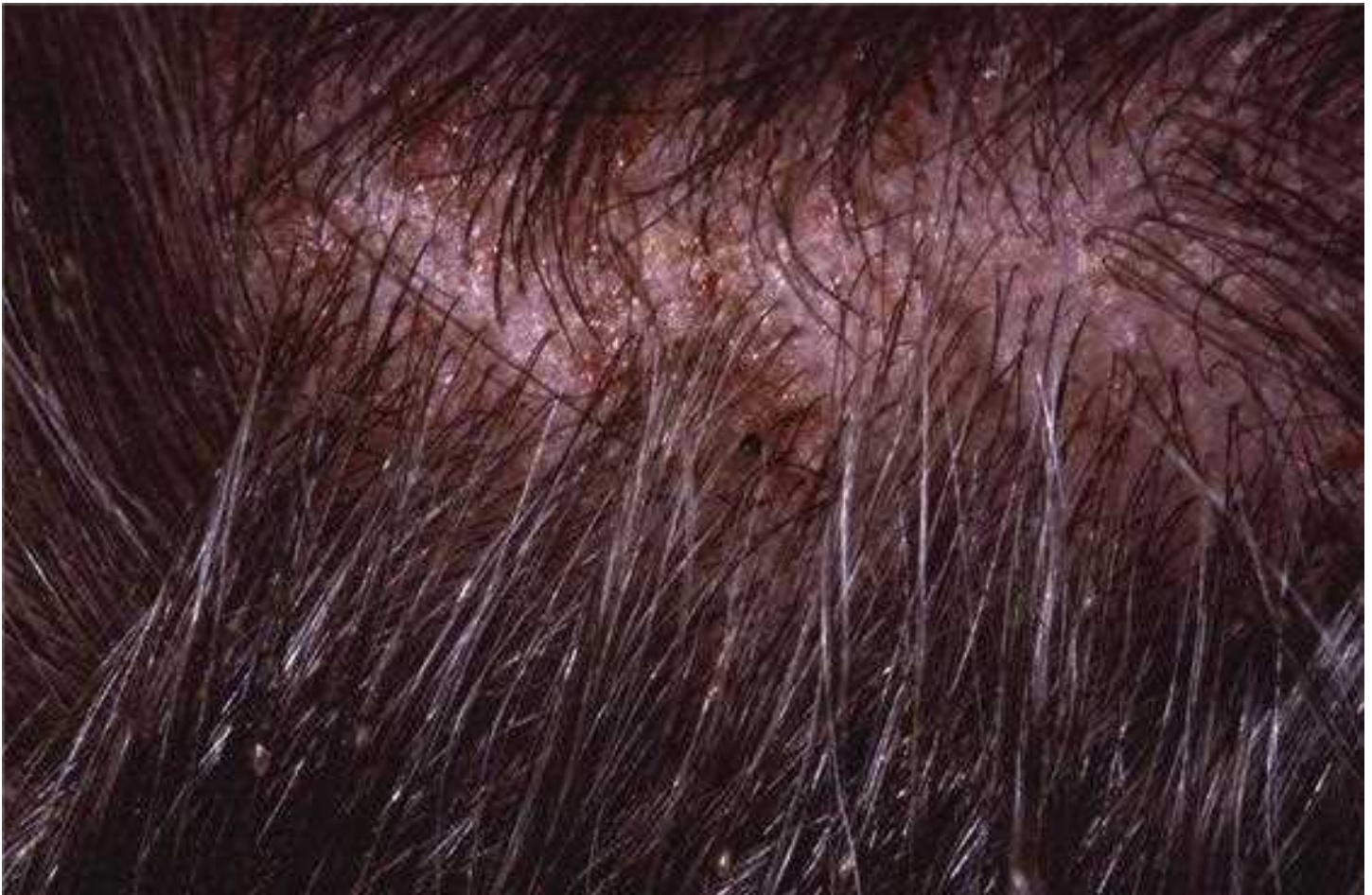Head lice have infested humans for thousands of years. They have a worldwide distribution and can affect anyone. Children are the most common hosts. The exact prevalence is difficult to estimate with 0.1–66% of schoolchildren shown to be infected in different areas of rural Africa and 11% in Australia.

Lice are transmitted by head-to-head contact, and on combs, brushes and hats. Girls are more commonly affected than boys; this is thought to be due to their close contact with others during play. Mild itching may be the only symptom of head lice. Careful inspection of the hair close to the scalp may reveal adult lice and nits (white empty egg cases) in infested

individuals ([Figure 17.13](#)). Patients may develop an itchy irritant-looking dermatitis on their upper back and neck area ([Figure 17.14](#)). Fine-toothed combs can aid detection.

Management

- Only treat individuals with live lice visible on the scalp. Fine-toothed nit-combs can be used to comb out lice and eggs over a basin ('bug-busting'). An application of hair conditioner usually allows the comb to pass more easily through the hair. Wet combing alone (30 minutes every 3 days for 2 weeks) has been shown to be inferior to insecticides, but in highly motivated families it can be very successful.
- First-line treatment is dimethicone 4% gel (an inert silicone that physically kills the lice through obstruction of its homeostatic workings) applied to dry hair and left on overnight (eight hours) and repeated after seven days (70–92% effective in studies).
- Second line is permethrin 1–5% crème rinse applied to dry hair and left on overnight. This should be repeated after seven days.
- Alternative agents include phenothrin 0.5% or malathion 0.5% (applied as above).
- Combinations of insecticides and bug-busting (wet combing) can be used.



[Figure 17.13](#) Head lice.

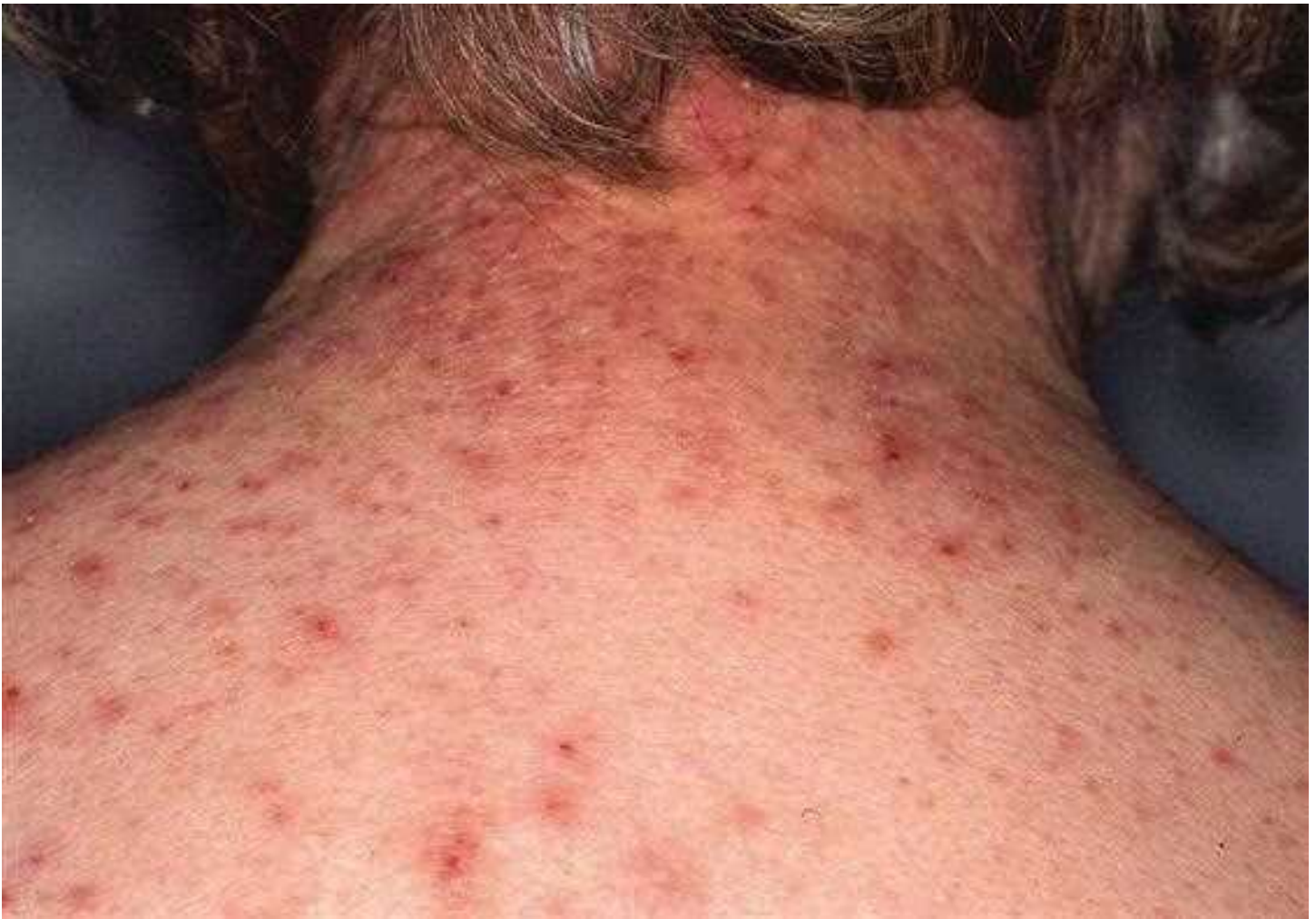

Figure 17.14 Pediculosis (head lice) causing an irritant rash on the posterior neck and upper back.

Body lice

Body lice are the vectors of several human pathogens including *Bartonella quintana* (agent of trench fever, bacillary angiomatosis, and endocarditis) and *Rickettsia prowazekii* (agent of typhus). Body lice tend to affect individuals from poorer economic backgrounds and those sleeping rough. The lice live in the host's clothes and bite the skin. Close inspection, especially of the clothing seams, reveals the adults and eggs. Infested individuals have a widespread papular eruption with excoriations. If the patient has a fever or constitutional symptoms, then the possibility of louse-borne systemic infection should be raised.

Management

- Wash clothing in hot water, ‘tumble-dry’, or place infested clothes in a sealed plastic bag for two weeks to kill adults and eggs.
- Treat the skin reactions with a moderately potent topical steroid, plus topical antibiotic if secondarily infected with bacteria.
- Take blood for culture and serology if louse-borne systemic disease is suspected. Refer

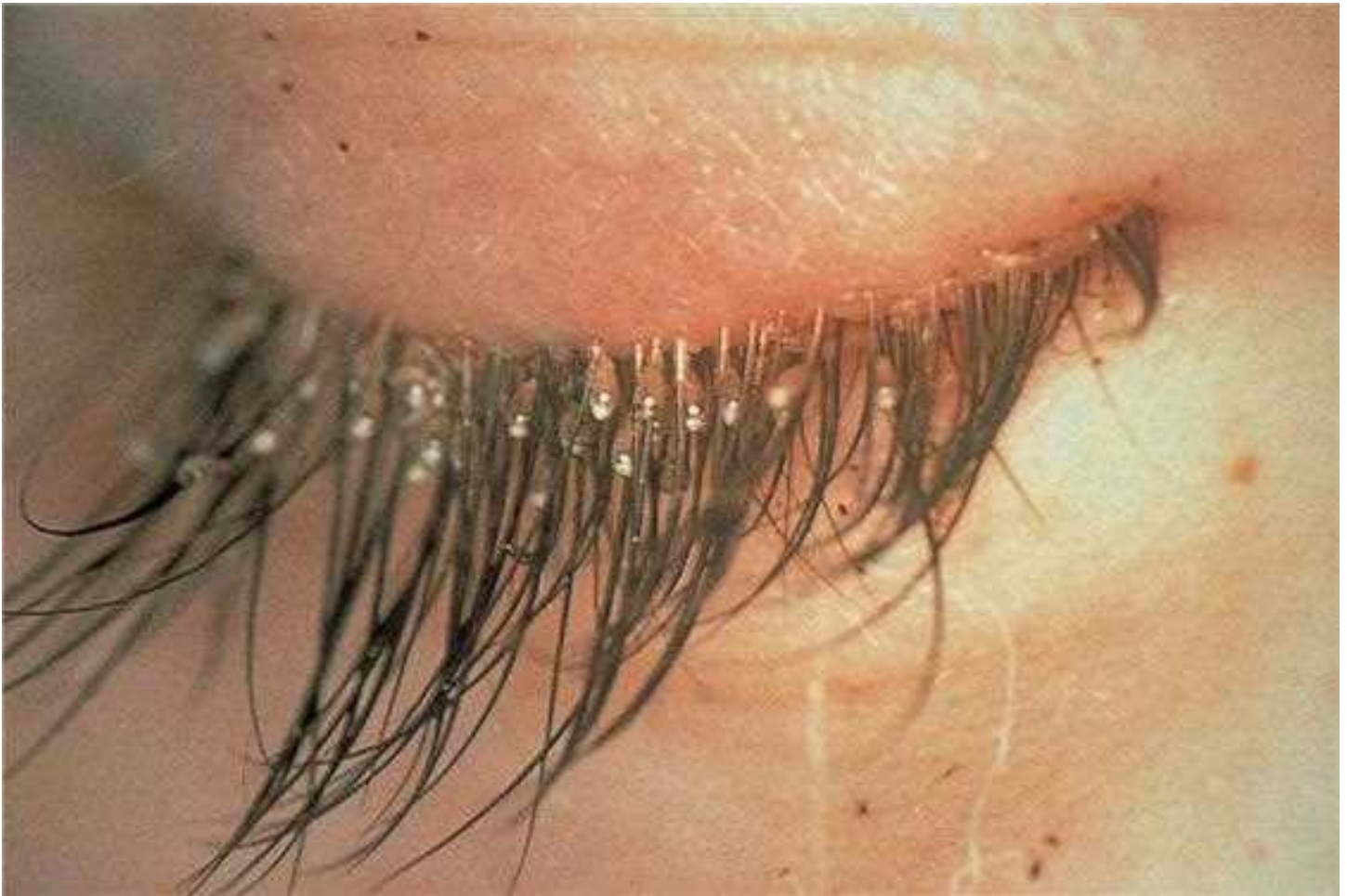
to cardiologists if endocarditis is suspected.

Pubic lice

These lice prefer the sparser hair-bearing sites on the skin such as the pubic, axillary, and eyelash areas ([Figure 17.15](#)). The so-called crab lice are slow-moving and are spread by close personal contact. Check the patient for other sexually transmitted diseases.

Management

- Use topical permethrin 5% cream or 0.5% malathion to the skin from the neck downwards, left on overnight, repeated after seven days.
- If the eyelashes are involved use petrolatum only, as insecticides can damage the eyes.



[Figure 17.15](#) Pubic lice on eyelashes.

Cutaneous larva migrans

Larvae from nematodes such as the dog/cat hookworm (*Ancylostoma caninum*) and *Strongyloides* parasites accidentally penetrate human skin and then wander aimlessly, unable to invade the deeper tissue, causing a superficial creeping eruption ([Figure 17.16](#)). In their animal host, the larvae eventually make their way to the gut to complete their lifecycle. Treat

the patient with albendazole 400 mg daily for three days or ivermectin as a single dose of 0.2 mg/kg body weight.

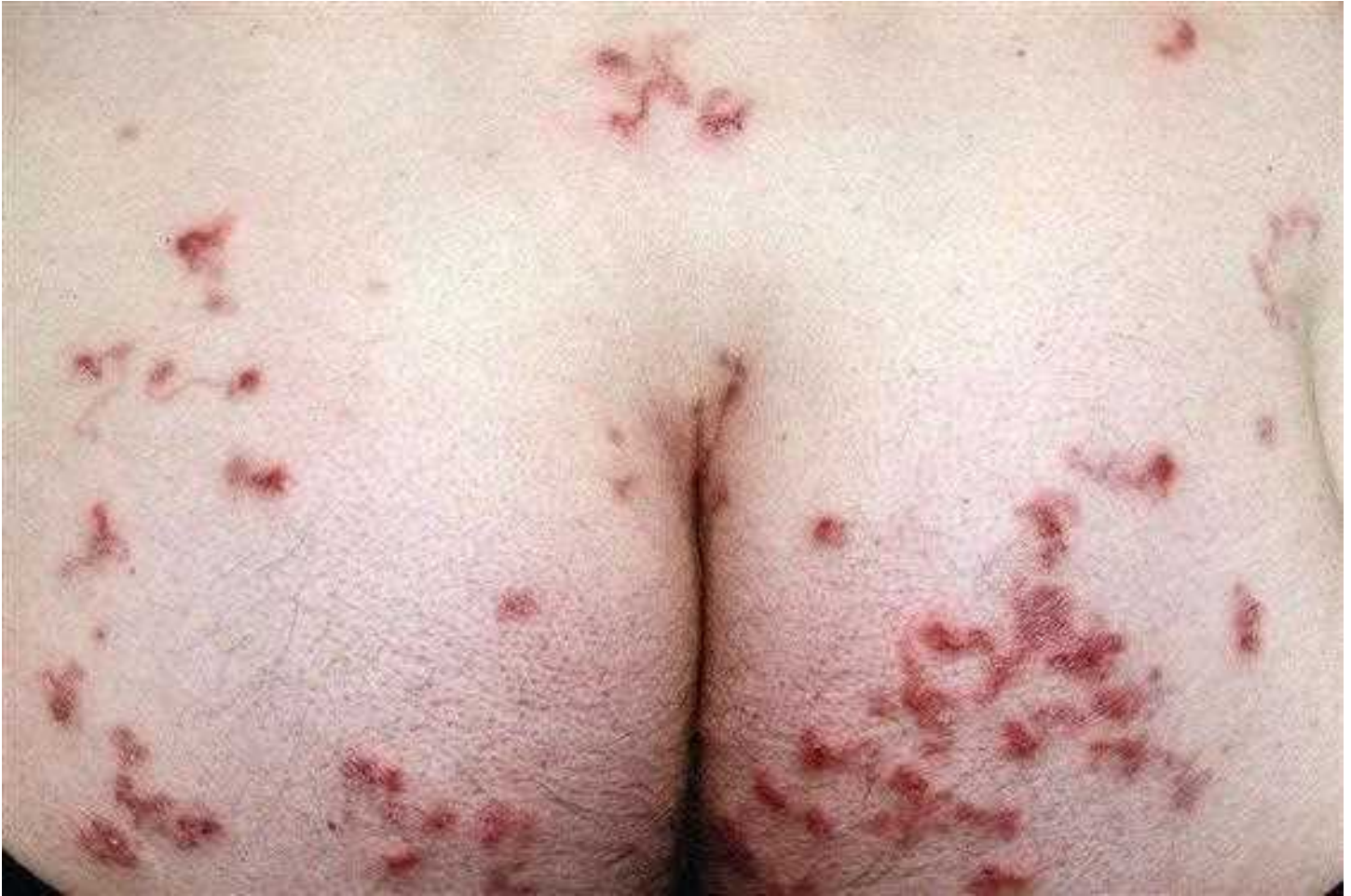

Figure 17.16 Cutaneous larva migrans.

Further reading

www.dermnet.com.

www.phmeg.org.uk.

CHAPTER 18

Tropical Dermatology

Rachael Morris-Jones

Guy's and St Thomas' NHS Foundation Trust, London, UK

OVERVIEW

- The majority of tropical diseases are due to infections and infestations, a large proportion involving the skin.
- Hot, humid conditions in the tropics and frequent lack of effective health care mean that skin diseases are common and recurrent.
- Pyogenic bacteria commonly involve the skin, causing impetigo and erysipelas.
- The intensity and type of immune response to tropical diseases such as leprosy and leishmaniasis determine the clinical manifestations.
- Cutaneous fungal infections can be very florid, persistent, and recurrent.
- In deep fungal infections, there is chronic inflammation in the subcutaneous tissues. These include chromoblastomycosis, mycetoma, blastomycosis, and histoplasmosis.
- The most common infestations affecting the skin are scabies and lice. Others include tungiasis, myiasis, onchocerciasis, loiasis (*Loa loa*), and dracunculiasis.

Introduction

Tropical dermatology is a diverse topic covering a multitude of different skin diseases, many of which are infections and infestations. This chapter concentrates on tropical diseases involving the skin (bacterial, viral, protozoan, helminth, and arthropod related). Health workers in the tropics and subtropics may be familiar with many of the cutaneous presentations in the local population. However, due to the relative ease of world travel, more visitors who are immunologically naïve may present locally with atypical features or florid disease. In addition, when these individuals return home they can present to their family medical practitioner, who may be unfamiliar with tropical skin diseases.

Hot, humid conditions in the tropics and subtropics provide an ideal environment for the proliferation of many organisms. Up to 50% of the local population is estimated to be affected by a skin disease in the tropics, the majority being infections or infestations such as impetigo, tinea, and scabies. Many of these conditions are amenable to treatment. However, the hot and humid conditions, overcrowding, and the lack of resources mean that skin

diseases are common and frequently recurrent. Local simple therapies can be very effective and may be administered by medical officers. Health care infrastructure in the tropics is improving, although many areas still suffer from lack of basic medicines and trained healthcare personnel.

Many tropical dermatoses have distinctive clinical features. Skin changes may result from the presence of the organisms, ova, or larvae or a reaction in the skin to disease at a distant site.

Bacterial Infections

Individuals living and travelling in the tropics are prone to *Staphylococcus aureus* infections on the skin in the form of impetigo (see [Chapter 13](#)). Bacterial infections may arise secondary to minor trauma or may be superimposed on any other skin disease. Clinical features include erythema, exudates, vesicles/bullae, and crusting. Impetigo is highly contagious, and many family members may be infected.

Deeper infections mainly caused by *Streptococcus* result in erysipelas or cellulitis, which may be accompanied by systemic symptoms. The face and limbs are most frequently affected. Deep infections may occur following minor trauma or impaired barrier function due to pre-existing skin diseases such as tinea, scabies, atopic, or irritant dermatitis.

The skin changes are characterised by marked erythema and tissue swelling. The patient may have systemic symptoms such as fever, rigours, and malaise. Individuals who do not have immediate access to antiseptics or antibiotics may develop severe skin changes and ultimately bacteraemia.

Leprosy

Leprosy is caused by *Mycobacterium leprae*, which results in a chronic granulomatous infection of the skin and peripheral nerves. Leprosy is endemic in Africa, south-east Asia, the Indian subcontinent, and South America. Aerosols from the nasal mucosa are thought to be the mode of transmission between humans, but animal reservoirs do exist (nine-banded armadillo, chimpanzees, and some monkeys). The incubation period is highly variable (6 months to 40 years), with a mean of 4–6 years.

There is a spectrum of clinical disease ([Figure 18.1](#)) depending on the patient's cell-mediated immunity to *M. leprae*. Patients whose immune systems respond poorly have clinical disease characterised by numerous skin lesions with numerous mycobacteria (multibacillary). Patients whose immune systems are responding well to the infection have very few mycobacteria present (paucibacillary) in isolated skin lesions. These two ends of the spectrum are referred to as *tuberculoid leprosy* (TT) (good immune response) and *lepromatous leprosy* (LL) (poor immune response). Clinical intermediates exist, and these are termed *borderline* cases ([Figures 18.2–18.5](#)).

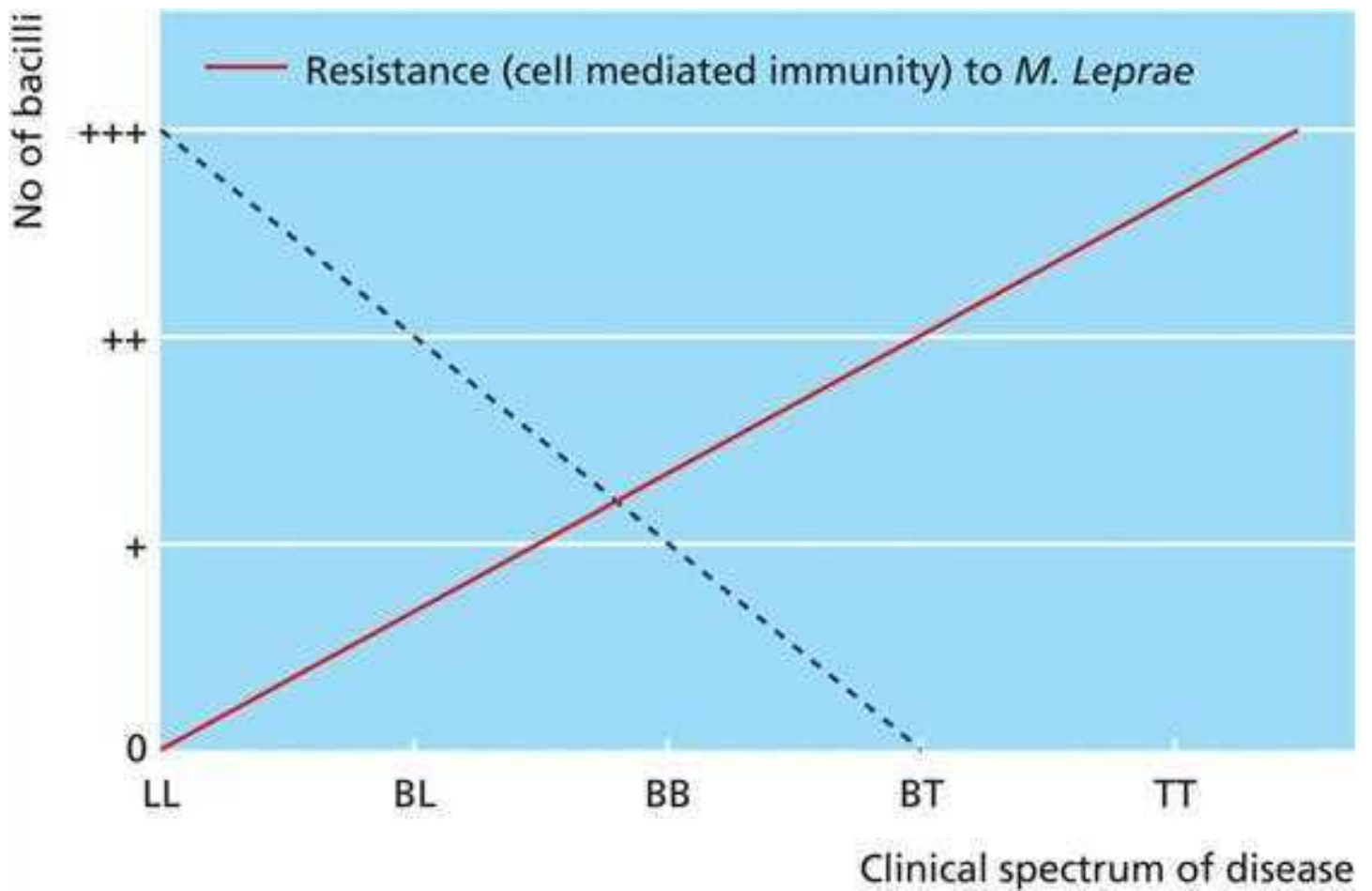


Figure 18.1 Spectrum of clinical disease in leprosy. BB, mid-borderline leprosy; BL, borderline lepromatous leprosy; BT, borderline tuberculoid leprosy; LL, lepromatous leprosy; TT, tuberculoid leprosy.

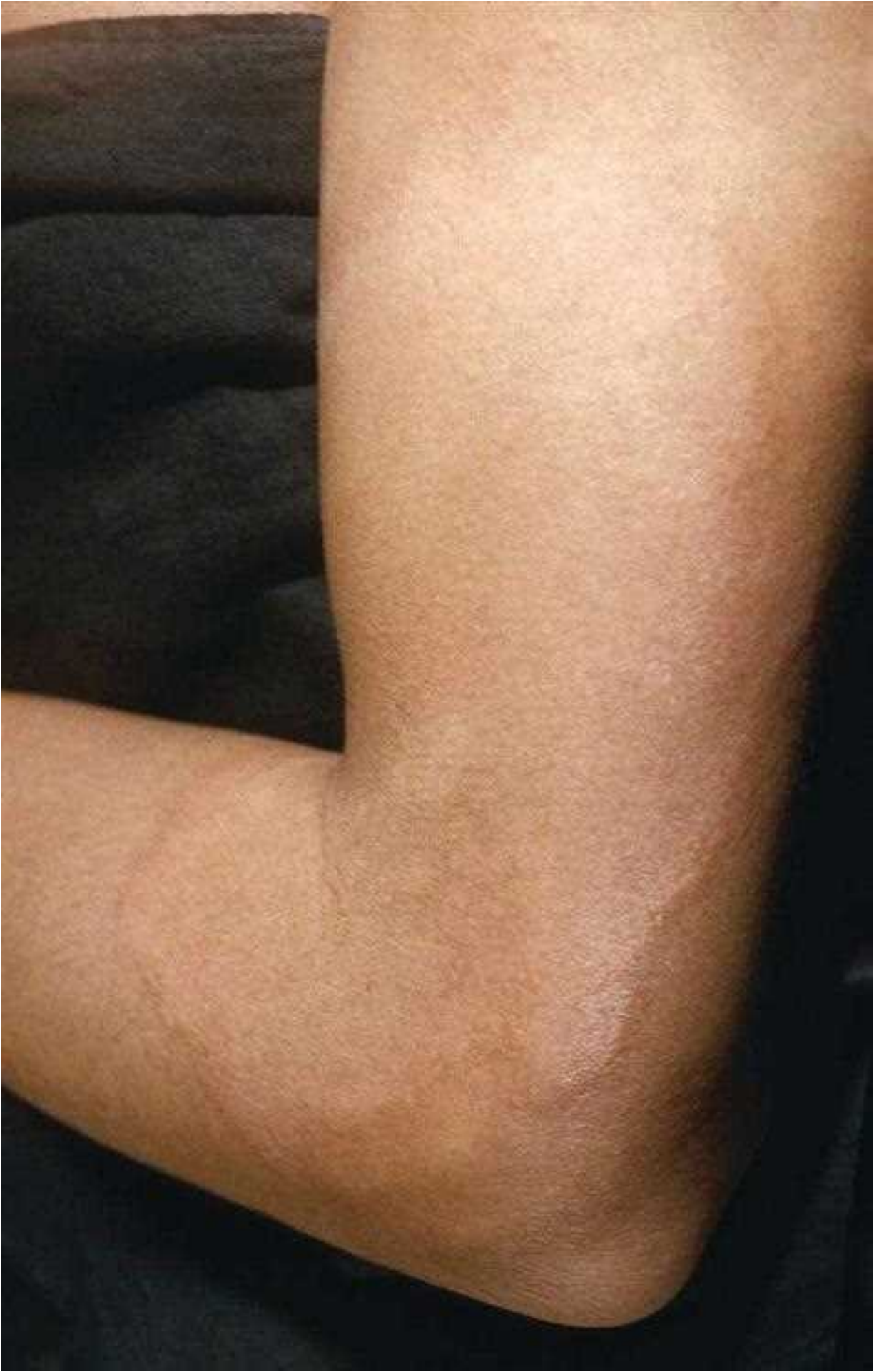

Figure 18.2 Tuberculoid leprosy: hypopigmented patches.

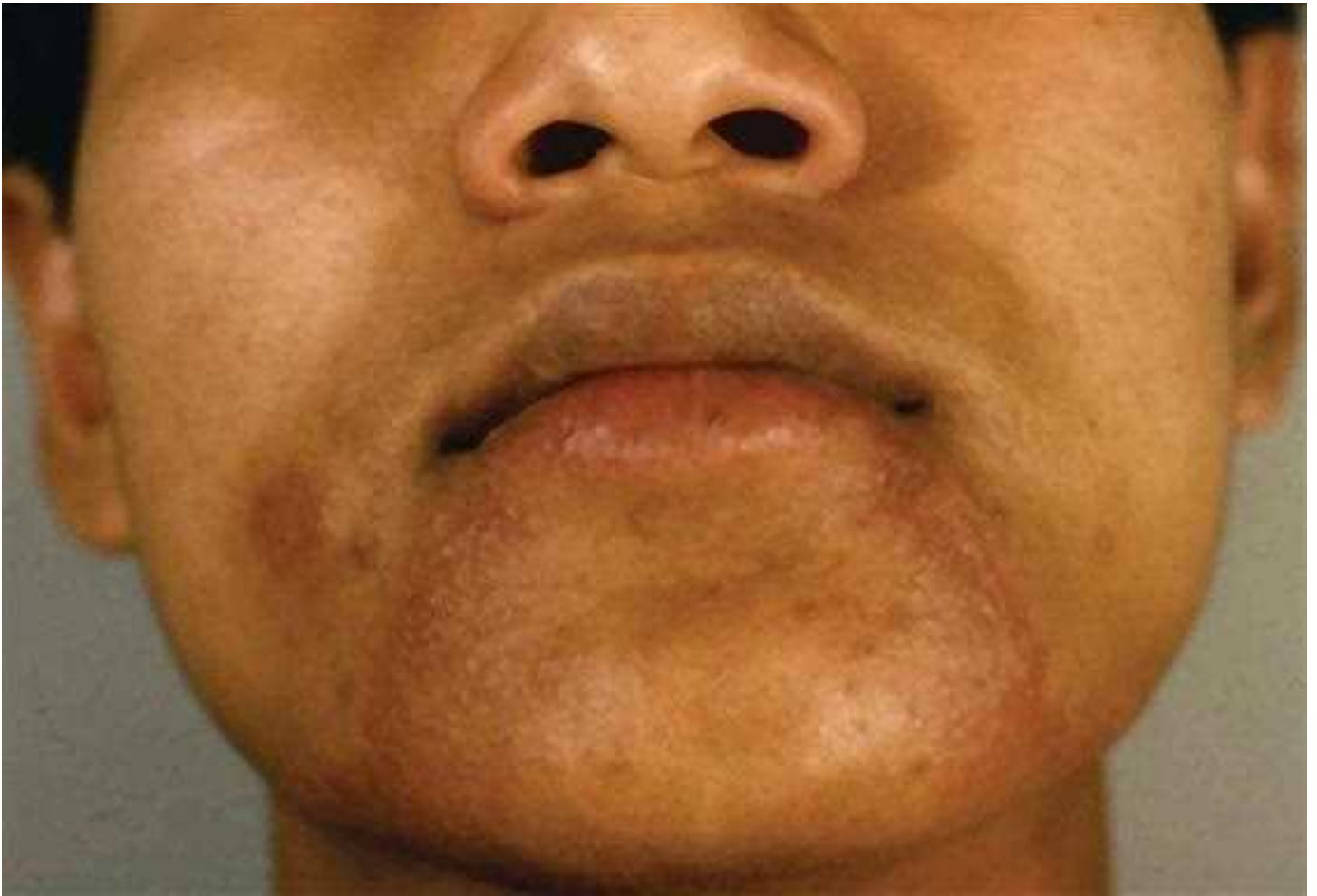

Figure 18.03 Tuberculoid leprosy.

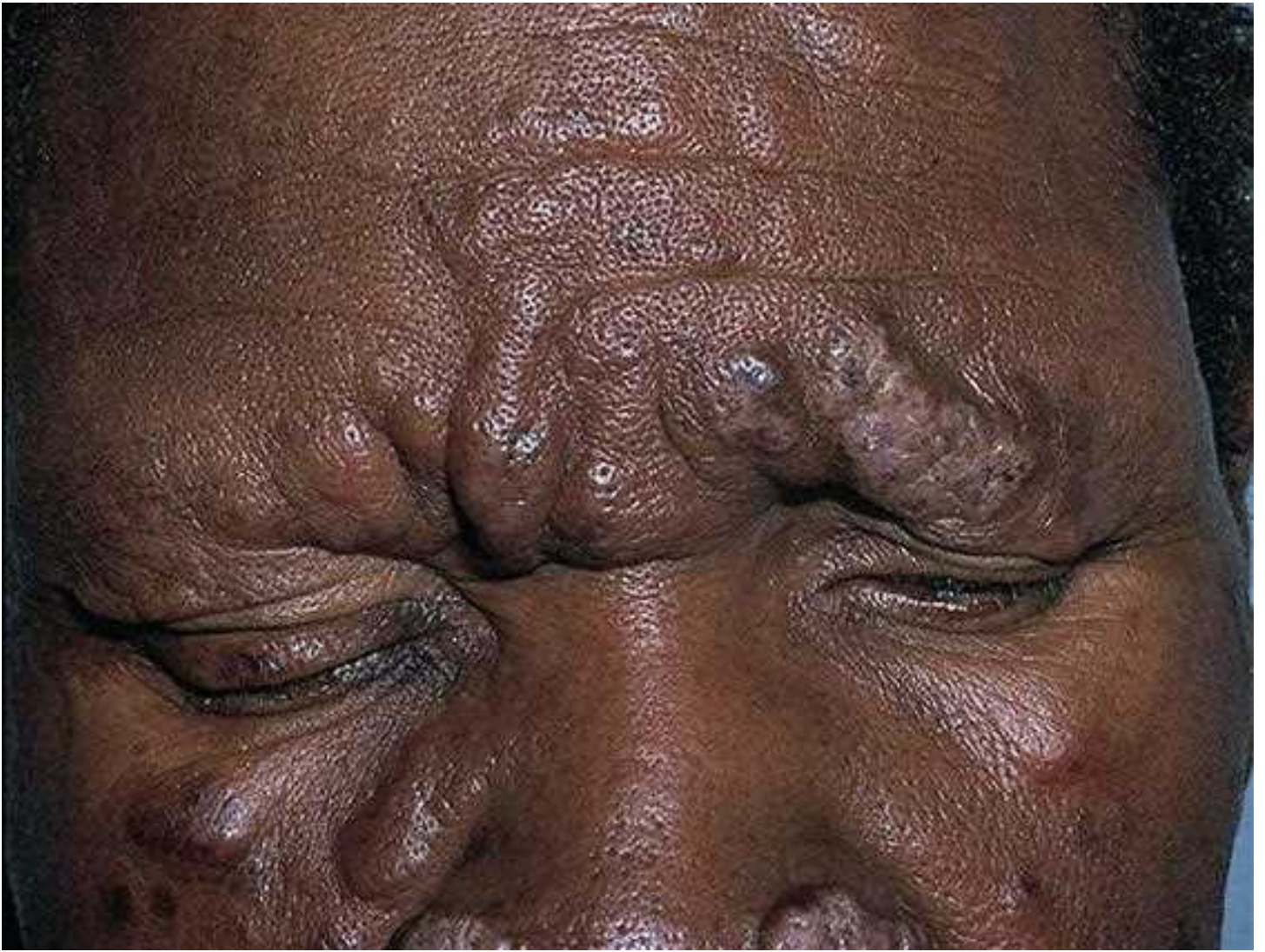

Figure 18.04 Lepromatous leprosy.

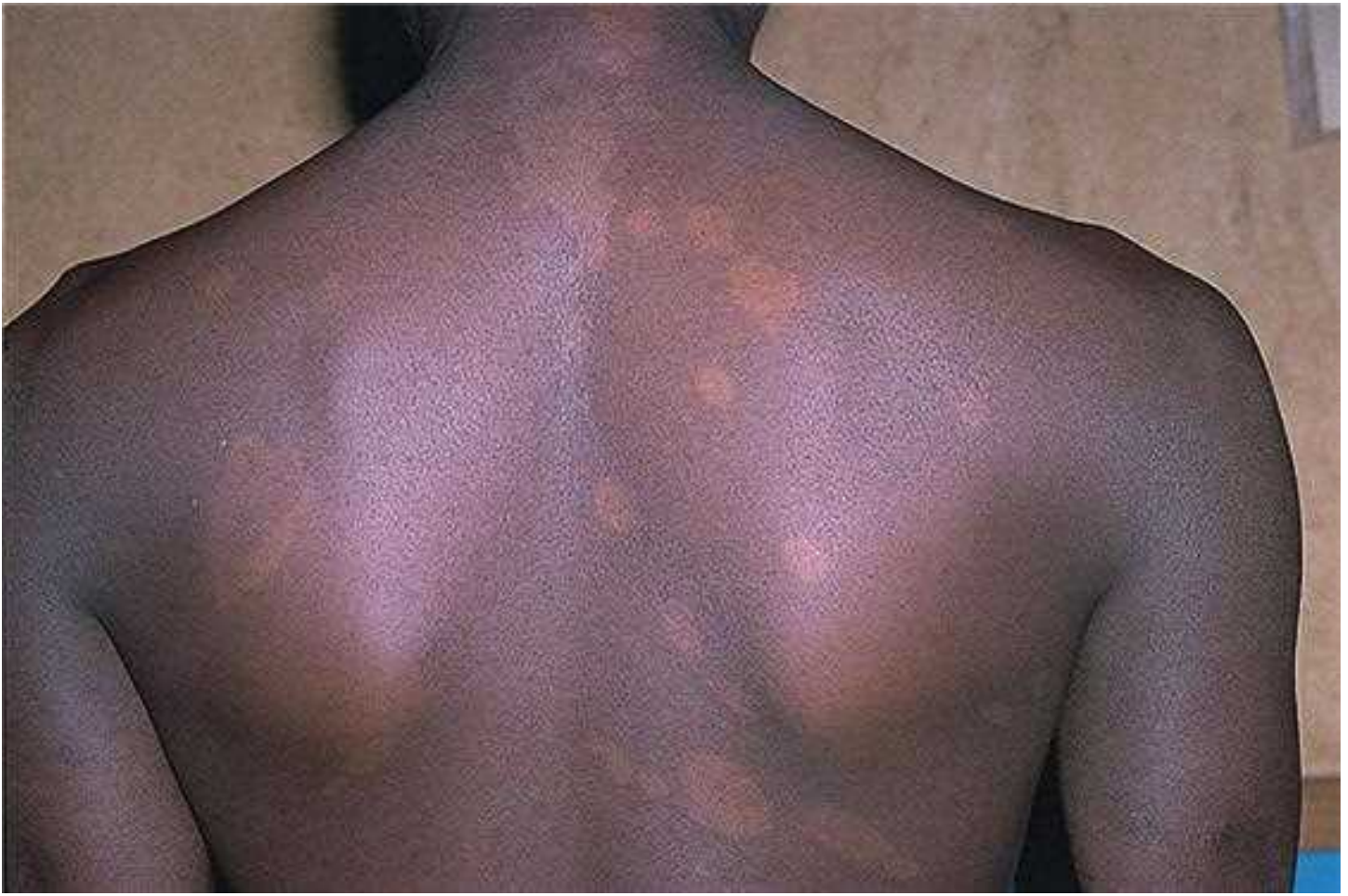

Figure 18.5 Borderline leprosy.

Diagnosis

Typical clinical findings are as follows.

- In tuberculoid leprosy (TT), there is a single anaesthetic patch or plaque with a raised border.
- In lepromatous leprosy (LL), there are widespread symmetrical shiny papules, nodules, and plaques, which are not anaesthetic.
- In borderline leprosy (BT, BB, BL), there are varying numbers of lesions, few in BT and numerous in BL. They may be widespread but are asymmetrical. BB is mid-borderline leprosy.
- Palpably enlarged cutaneous nerves (great auricular nerve in the neck, the superficial branch of the radial nerve at the wrist, the ulnar nerve at the elbow, the lateral popliteal nerve at the knee and the sural nerve on the lower leg).
- Glove and stocking sensory loss leads to secondary changes through trauma such as blisters, erosions, and ulcers (neuropathic) on anaesthetic fingers/toes.
- Deformity due to invasion of the peripheral nerves with leprosy bacilli, a leprosy reaction or recurrent trauma to anaesthetic limbs.

Slit skin smears measure the numbers of bacilli in the skin (bacterial index, BI – see [Box 18.1](#)) and the percentage of these that are living (morphological index, MI).

Box 18.1 Bacterial index (BI)

| | |
|----|--|
| 0 | No bacilli seen |
| 1+ | 1–10 bacilli in 100 oil immersion fields |
| 2+ | 1–10 bacilli in 10 oil immersion fields |
| 3+ | 1–10 bacilli in 1 oil immersion field |
| 4+ | 10–100 bacilli in an average oil immersion field |
| 5+ | 100–1000 bacilli in an average oil immersion field |
| 6+ | >1000 bacilli in an average oil immersion field |

Treatment

Paucibacillary leprosy (BI of 0 or 1+):

- rifampicin 600 mg once a month
- dapsone 100 mg daily
- for six months.

Multibacillary leprosy (BI of 2+ or more):

- rifampicin 600 mg once a month
- clofazimine 300 mg once a month
- clofazimine 50 mg/day
- dapsone 100 mg/day
- for 12 months.

An estimated 20–40% of patients with leprosy develop immunologically mediated reactions (most common in borderline leprosy cases) that can permanently damage nerve function. These so-called ‘reversal reactions’ can be type 1 (T1R delayed hypersensitivity) or type 2 (T2R immune complex mediated). Type 1 reactions are characterised by marked inflammation and oedema in skin lesions, acral oedema, and acute neuritis manifested by nerve pain/sudden onset of loss of sensation/function. Urgent treatment with 40–60 mg oral prednisolone daily should be given and then tapering doses over three to six months, in addition to the anti-lepromatous therapy. Type 2 reactions resemble erythema nodosum but are generally more widespread and the erythematous nodules may be superficial as well as deep and may ulcerate. Neuritis may accompany the erythema nodosum leprosum, systemic

upset (fever, malaise), photophobia, and iritis, and so on. Patients should be treated promptly with aspirin and oral prednisolone.

Cutaneous leishmaniasis

Leishmaniasis affects approximately 12 million people worldwide and is found in over 80 countries (in the 'Old World' in Africa, Asia and Europe and in the 'New World' in Central and South America). Leishmaniasis is caused by *Leishmania* protozoan parasites transmitted by the bite of the female sandfly (usually at night). Rarely in human's transmission via blood transfusion, congenital passage and sexual intercourse have been reported. Animal reservoirs include dogs, rodents, foxes, and jackals. Clinically, leishmaniasis is classified into cutaneous, mucocutaneous, and visceral, depending on the parasite's ability to proliferate at a specific temperature. Therefore, the amastigote parasites may remain in the skin or be carried by macrophages to internal organs. There are many distinct species of *Leishmania* parasites, each restricted to a geographical region ([Box 18.2](#)).

Box 18.2 Cutaneous leishmaniasis

New World (Americas)

Leishmania tropica mexicana, *Leishmania amazonensis*, *Leishmania (Viannia) braziliensis* and *guyanensis* (cutaneous + mucocutaneous)

Old World

L. tropica, *Leishmania major*, *Leishmania aethiopica* (mucocutaneous), *Leishmania infantum* (cutaneous + visceral)

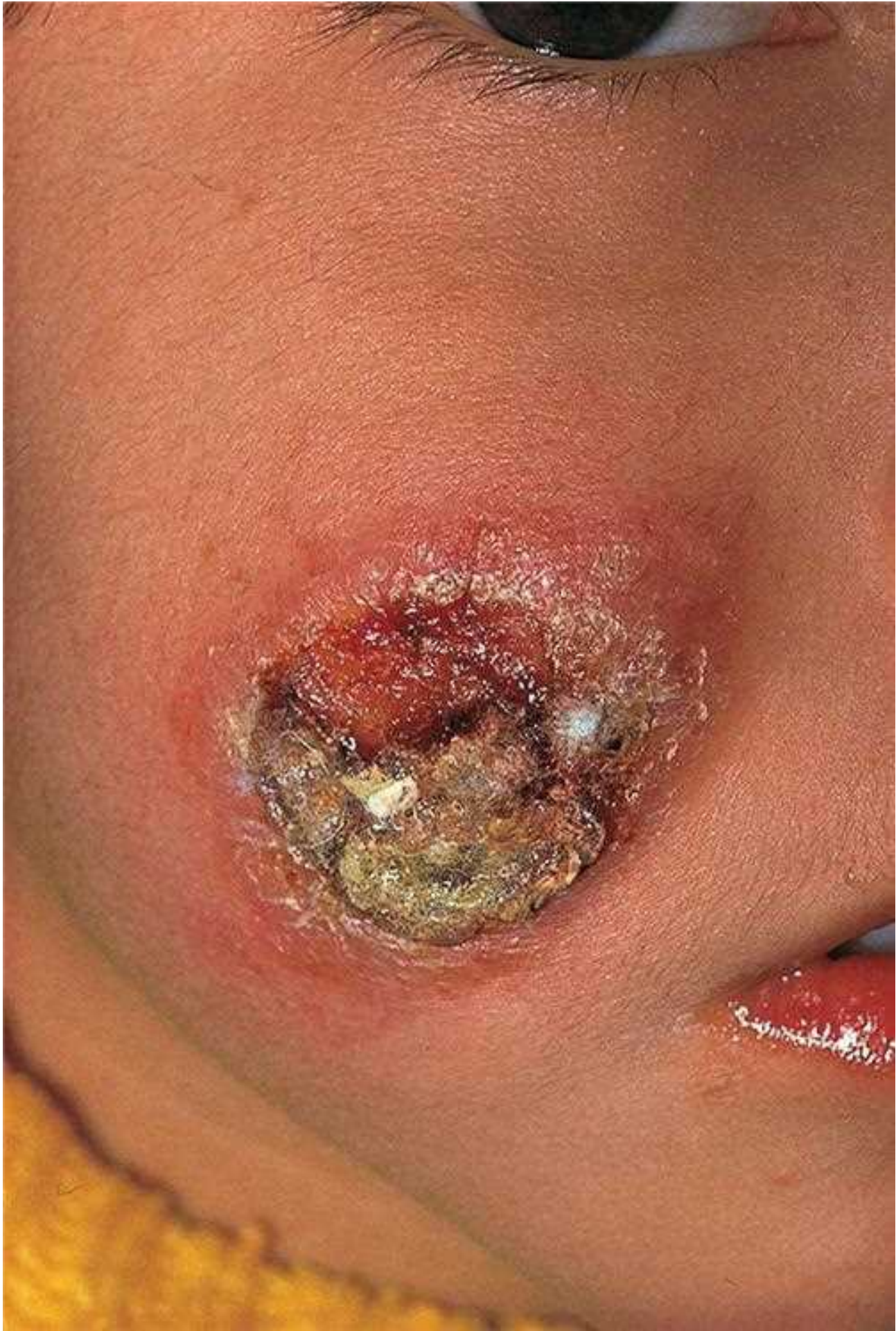Cutaneous lesions usually on exposed skin sites develop within weeks of the sandfly bite. Children are more frequently affected than adults. Several family members may be affected simultaneously, often bitten by the same sandfly. Painless erythematous papules leading to nodules and eventually ulceration can classically be seen. The clinical presentation varies according to the host's nutritional state, their immunity and the *Leishmania* species involved. Spontaneous resolution may occur after 2–10 months, but latent reactivation after several years in an area of minor skin trauma means leishmaniasis can be an unpredictable disease.

Mucosal involvement may occur in isolation or concurrently with cutaneous lesions, and in some cases, there may be a delay of up to 20 years between the appearance of cutaneous and mucosal lesions. Mucosal lesions may be painful and can lead to nasal obstruction, congestion, tissue destruction, and bleeding.

Acute leishmaniasis

A red nodule similar to a boil ('Delhi boil', 'Balkan sore') occurs at the site of the bite. The

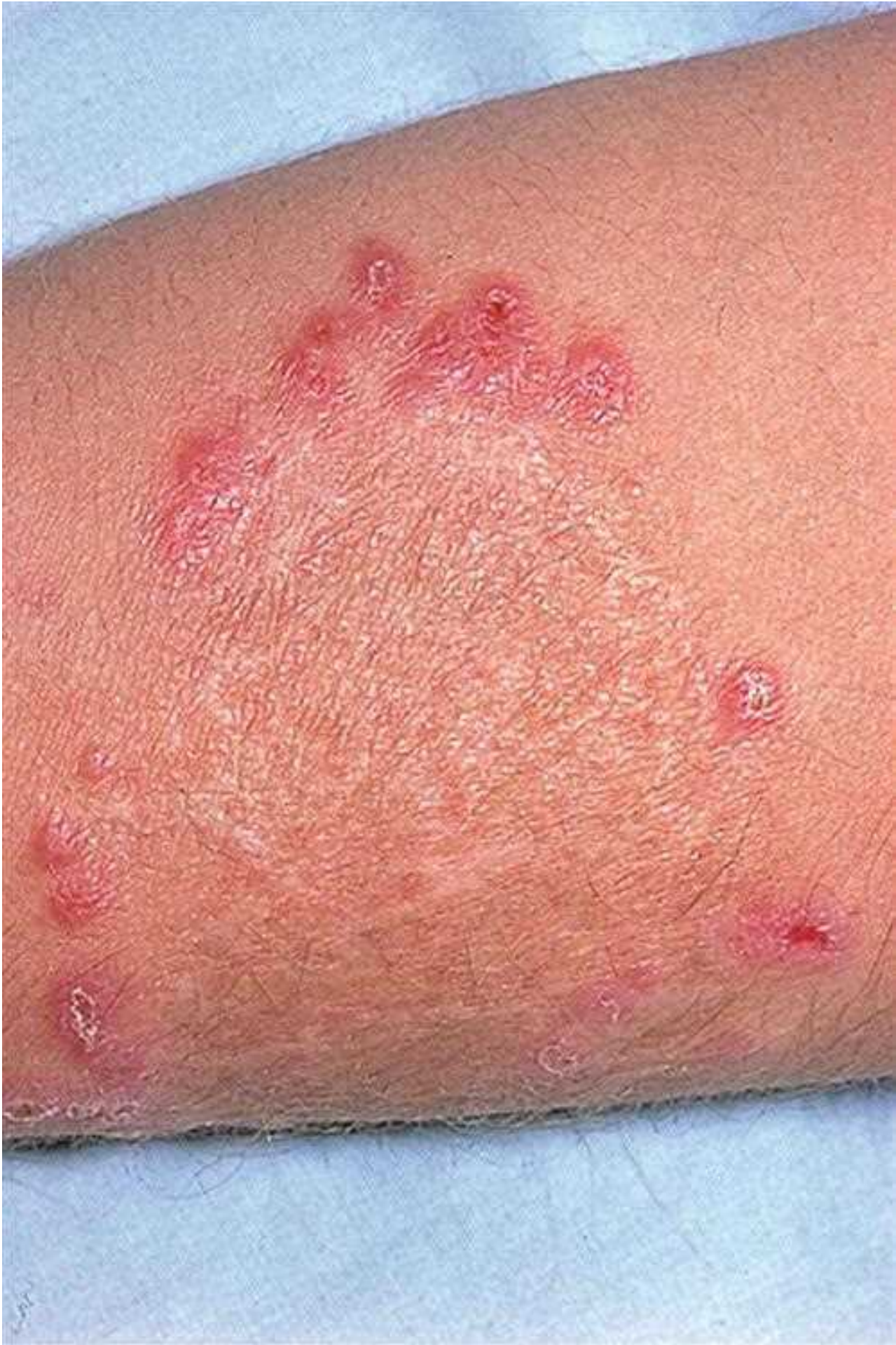nodules enlarge and may ulcerate (moist and exudative or dry and crusted) ([Figure 18.6](#)). Lesions usually heal spontaneously after approximately one year, leaving a pale cribriform scar.



[Figure 18.6](#) Acute leishmaniasis.

Chronic leishmaniasis

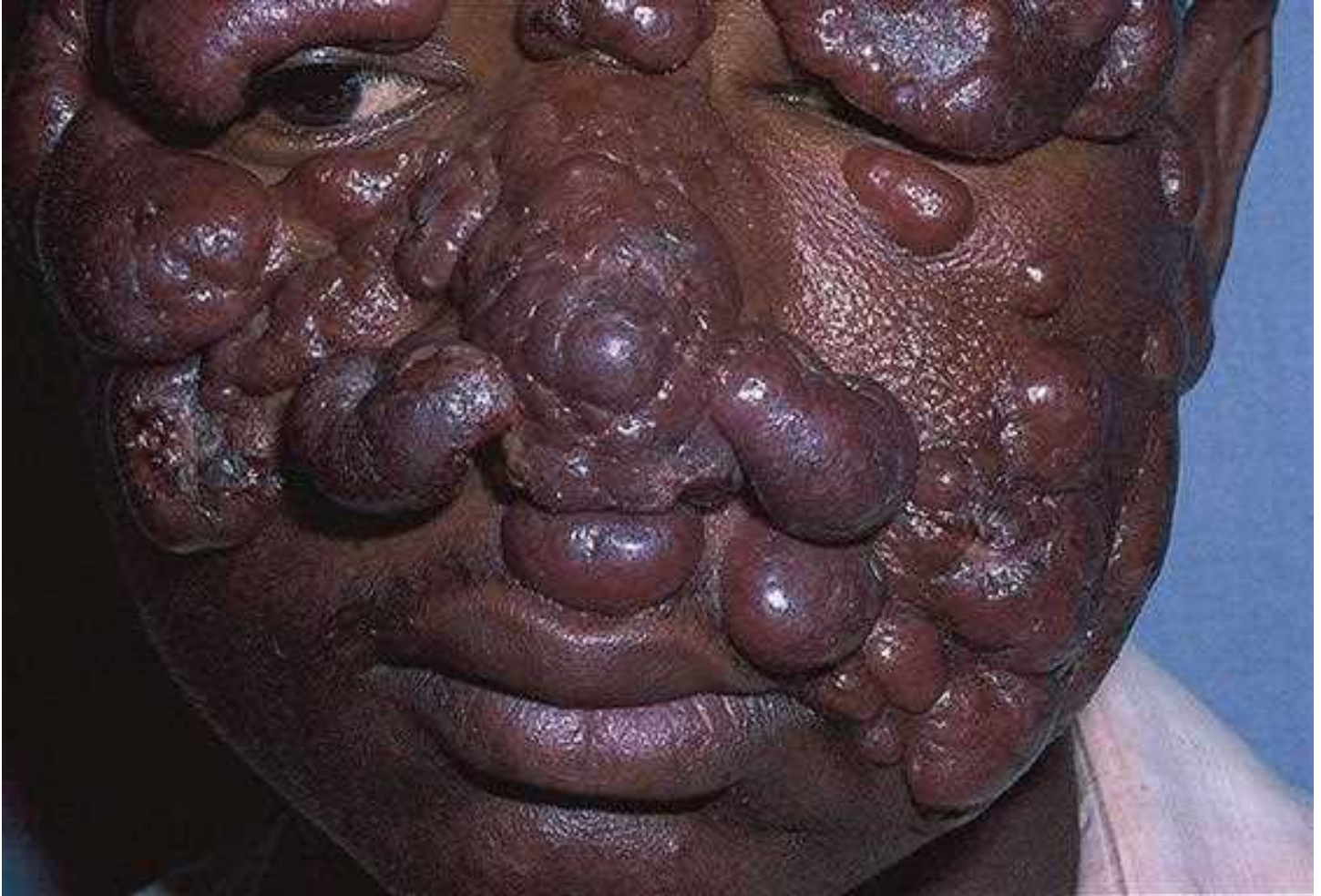In a patient with good cell-mediated immunity, after the acute leishmaniasis has healed, new granulomas appear at the edge of the scar; these do not heal spontaneously ([Figure 18.7](#)).



[Figure 18.7](#) Chronic leishmaniasis.

Diffuse cutaneous leishmaniasis

This is leishmaniasis in a patient with no immunity to the organism (equivalent to LL). Extensive skin nodules occur with numerous organisms ([Figure 18.8](#)).



[Figure 18.8](#) Diffuse cutaneous leishmaniasis.

Diagnosis

Diagnosis is usually made from a history of travel to an endemic area and clinical appearances of the lesions. Skin biopsy stained with Giemsa will demonstrate the parasites in over 50% of cases, and modern polymerase chain reaction (PCR) techniques can be useful in determining the species responsible which can help guide management.

Leishmaniasis skin testing is used in some countries where killed parasites are injected into the dermis and the reaction measured at 48 hours. This is, however, not positive in acute infections and in endemic areas is often positive in over 70% of the population. If visceral leishmaniasis is suspected, then serology testing with an indirect fluorescent antibody test (IFAT)/Western blot or ELISA can be highly specific and sensitive.

Treatment

A proportion of cutaneous lesions will heal spontaneously or resolve following simple treatments such as cryotherapy, heat treatment, or surgery.

Pentavalent antimonials sodium stibogluconate (Pentostam) or meglumine antimoniate are the main therapeutic agents used to treat cutaneous leishmaniasis in most countries. Intralesional stibogluconate can be injected into the affected skin (1–3 ml injected around the active edge of the lesion – repeated fortnightly over approximately six to eight weeks is highly effective) or local applications of paromomycin can be effective for isolated cutaneous lesions. Systemic stibogluconate i.v./i.m. (200 mg test dose followed by 20 mg/kg daily) should be used until healing occurs (usually two to three weeks, although some experts consider four treatments sufficient).

Amphotericin B deoxycholate and liposomal amphotericin B (AmBisome) 0.5–3 mg/kg given on alternate days have been shown to be highly effective but must be administered intravenously and can be expensive. WHO advocate 20 mg/kg in total and may be given in a smaller number of doses. An alternative agent is pentamidine 2–4 mg/kg on alternate days (maximum 15 doses). Miltefosine is the first highly effective oral preparation for the treatment of leishmaniasis. A 28-day treatment course leads to 90% cure rates. It is currently used in India, Colombia, and Germany, and although it is generally well tolerated, it is teratogenic. There is some evidence that itraconazole and ketoconazole can be effective for treating leishmaniasis.

Superficial fungal infections

The warm, moist conditions in the tropics and subtropics are ideal for the survival and proliferation of fungal species in the environment and on the skin. Cutaneous fungal infections can be very florid, persistent, and recurrent ([Figure 18.9](#)). There are also many fungal infections that are specifically found in the tropics. These include tinea imbricata, tinea nigra, piedra, and favus ([Table 18.1](#)).

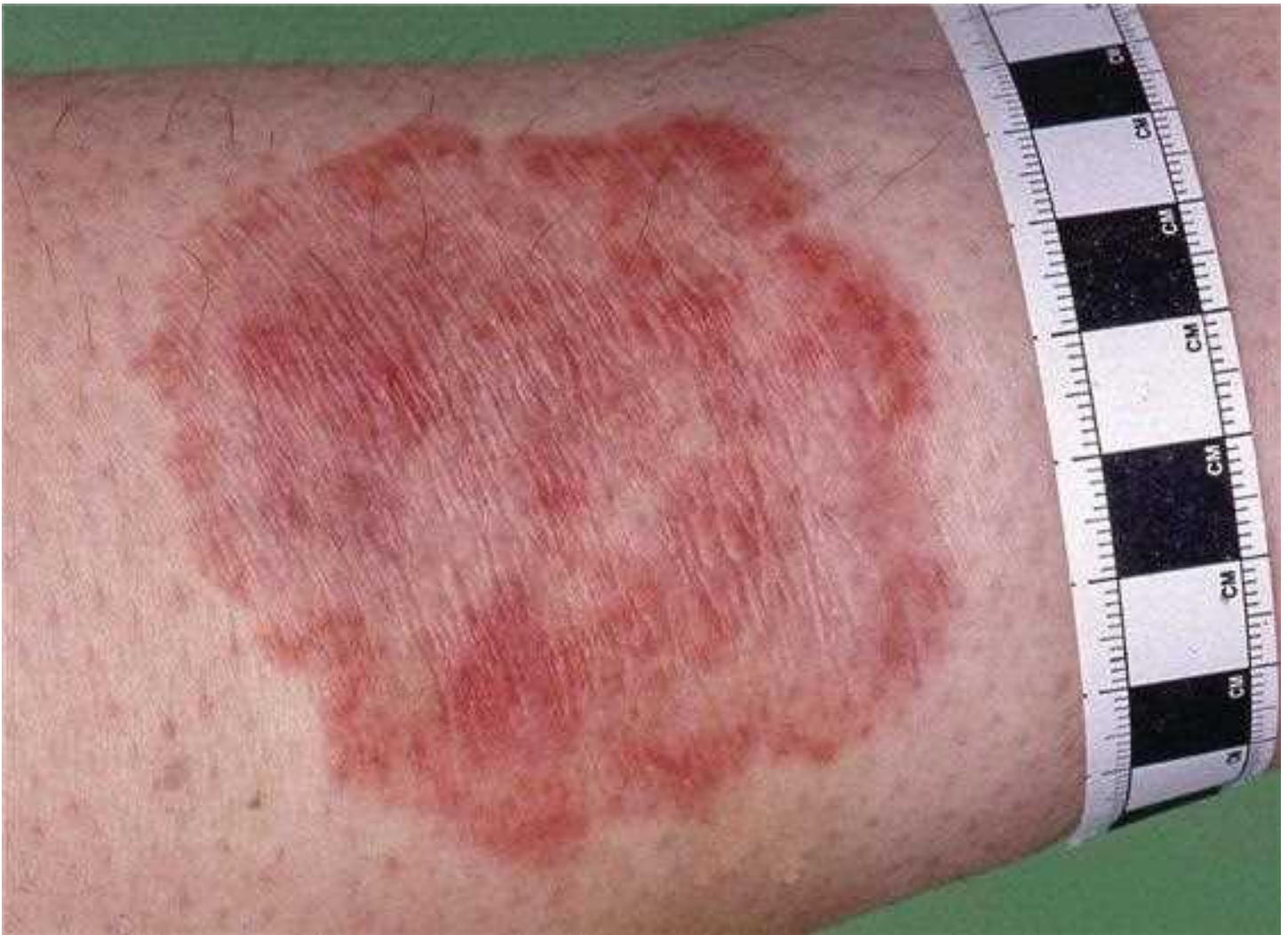

Figure 18.9 Superficial fungal infection.

Table 18.1 Tropical fungal infections of the skin.

| | |
|---|---|
| Superficial cutaneous infection | Black/white piedra, tinea nigra, <i>Malassezia</i> yeast |
| Cutaneous infection | Tinea, <i>Trichophyton</i> , <i>Scytalidium</i> , <i>Candida</i> |
| Subcutaneous infection | Sporotrichosis, chromoblastomycosis, mycetoma |
| Systemic infection with cutaneous signs | <i>Fusarium</i> , <i>Penicillium marneffeii</i> , <i>Histoplasma</i> , lobomycosis, blastomycosis |

Superficial dermatophyte fungal infections (see [Chapter 16](#)) generally present with itching. Lesions often expand slowly from a small focus on the skin to form rings or annular lesions, where the edge is active and there is central clearing. The margins are usually palpable and the lesions scaly.

Tinea imbricata due to *Trichophyton concentricum* is characterised by superficial concentric scaling rings spreading across the trunk ([Figure 18.10](#)). The condition is frequently chronic and relapsing. It occurs mainly in Central/South America and Asia. Topical Whitfield's

ointment may be effective or oral griseofulvin or terbinafine.

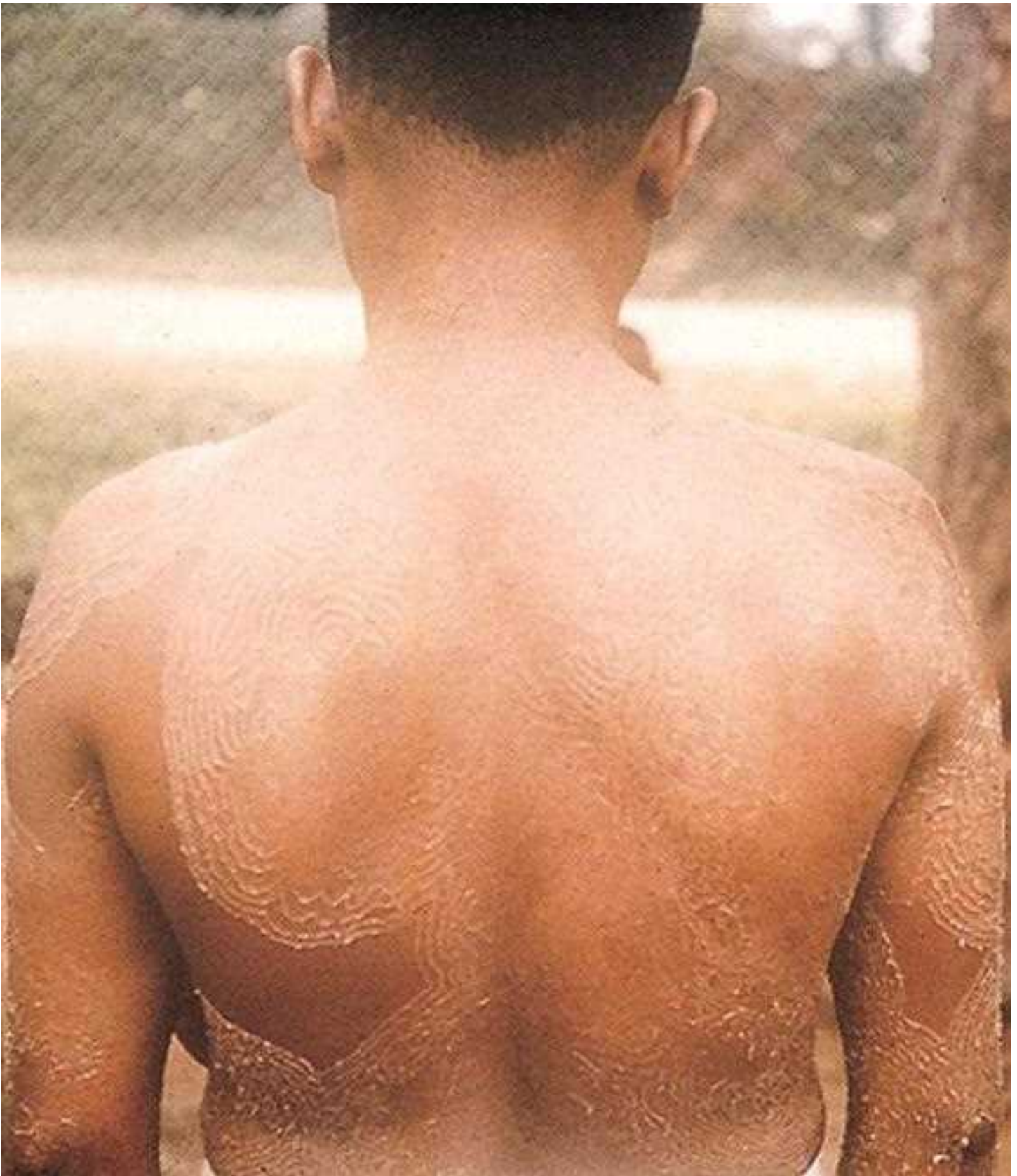


Figure 18.10 *Tinea imbricata*.

Tinea nigra caused by *Cladosporium werneckii* occurs in the tropical areas of America, Asia,

and Australia. The pigmented fungus invades the stratum corneum usually through contact with contaminated soil, vegetation, or sewage. Hyperpigmented brown or black macules are seen most commonly on the palms and soles. Treatment with keratolytic agents (salicylic acid preparations and topical retinoids) can be effective due to the very superficial nature of the infection. Topical antifungals such as terbinafine, miconazole, ketoconazole, and clotrimazole are also effective.

Piedra is a fungal infection of the hair producing hard nodular lesions on the hair shaft. The lesions may be black (due to *Piedraia hortae*) or white (due to *Trichosporon beigeli*). The nodules consist of clumps of fungal hyphae that can be difficult to remove from the hair shaft when the fungus is pigmented. Hair removal has traditionally been used to clear infections. Salicylic acid, formaldehyde preparations, and antifungal creams are also effective. Re-infection rates are high.

Favus is most commonly seen in North/South Africa, Brazil, Pakistan and the Middle East and rarely in Europe (Poland). Favus is caused by an endothrix fungus – *Trichophyton schoenleinii* – which causes a thick yellow crust (honeycomb appearance) usually on the scalp, but nails and glabrous skin may also be affected. The confluent areas of yellow adherent crusts are frequently secondarily infected with bacteria and have an unpleasant odour. Erythematous areas of scarring occur that must be differentiated from lichen planus and other causes of scarring alopecia. Prolonged systemic treatment with griseofulvin, terbinafine, or itraconazole is usually effective.

Deep fungal infections

In these conditions, there is chronic inflammation in the subcutaneous tissues, leading to granulomatous and necrotic nodules.

Mycetoma (madura foot)

This is a chronic granulomatous infection of the dermis and subcutaneous fat caused by various species of fungus (eumycetoma) or bacteria (actinomycetoma). Endemic areas include Asia, Africa, and South America. Mycetoma most commonly occurs on the foot of an agricultural worker, but any skin site can be affected. Traumatic implantation is thought to be the mode of transmission of the organism into the subcutis. Patients most commonly present with a swollen foot and multiple discharging sinuses ([Figure 18.11](#)). The infective 'grains' can be seen as tiny dark or pale bodies within the discharging purulent exudate. These can be teased out with a sterile needle and identified by microscopy and culture. Many fungal species (*Acremonium*, *Fusarium*, *Aspergillus*, *Madurella*, *Exophiala*) and actinomycetes bacteria (*Nocardia*, *Actinomadura*, *Streptomyces*) have been implicated in the aetiology of mycetoma. Identification of the organism is important as this guides treatment.

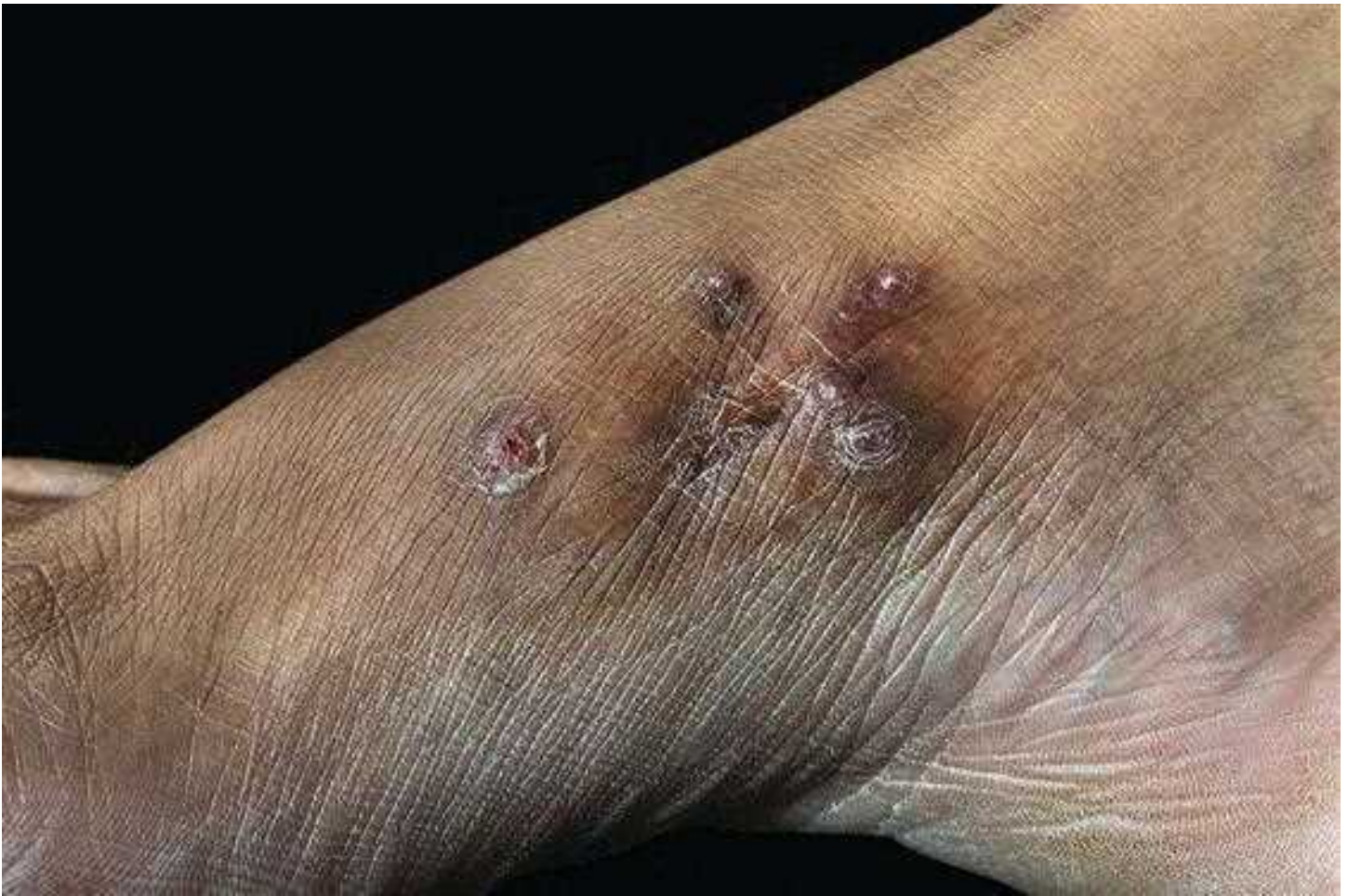

Figure 18.11 Madura foot.

Diagnosis

- Examination of the discharging grains (colour will give a clue as to the cause).
- Culture of the grains to identify the causative fungus or bacterium.
- If no grains can be found, a skin biopsy may be needed.
- Radiological imaging may demonstrate bone involvement.

Treatment

Fungal mycetoma

A combination of medical and surgical treatment is frequently recommended for these difficult infections.

- Surgical excision of affected tissue if disease is limited. Amputation if extensive.
- Ketoconazole (200–400 mg daily) or itraconazole (200 mg twice daily) for at least 12 months. In addition, the newer agent posaconazole 800 mg daily for up to 34 months has been shown to be highly effective.

Bacterial mycetoma

Two drugs may be used for a synergistic effect.

- Sulfamethoxazole/trimethoprim mixture 960 mg twice daily (for up to two years).
- Other agents include dapsons, streptomycin, rifampicin, amikacin, and imipenem.

Chromoblastomycosis

This is a chronic granulomatous condition that mainly affects the legs. Chromoblastomycosis results from traumatic implantation of a variety of parasitic fungi including *Fonsecaea*, *Cladosporium*, and *Phialophora* into the skin. The disease is characterised by large spreading verrucous nodules or plaques from the site of implantation ([Figure 18.12](#)). In some cases, the whole of the lower leg can be affected, with blockage of lymphatic ducts leading to an elephantiasis-type appearance.

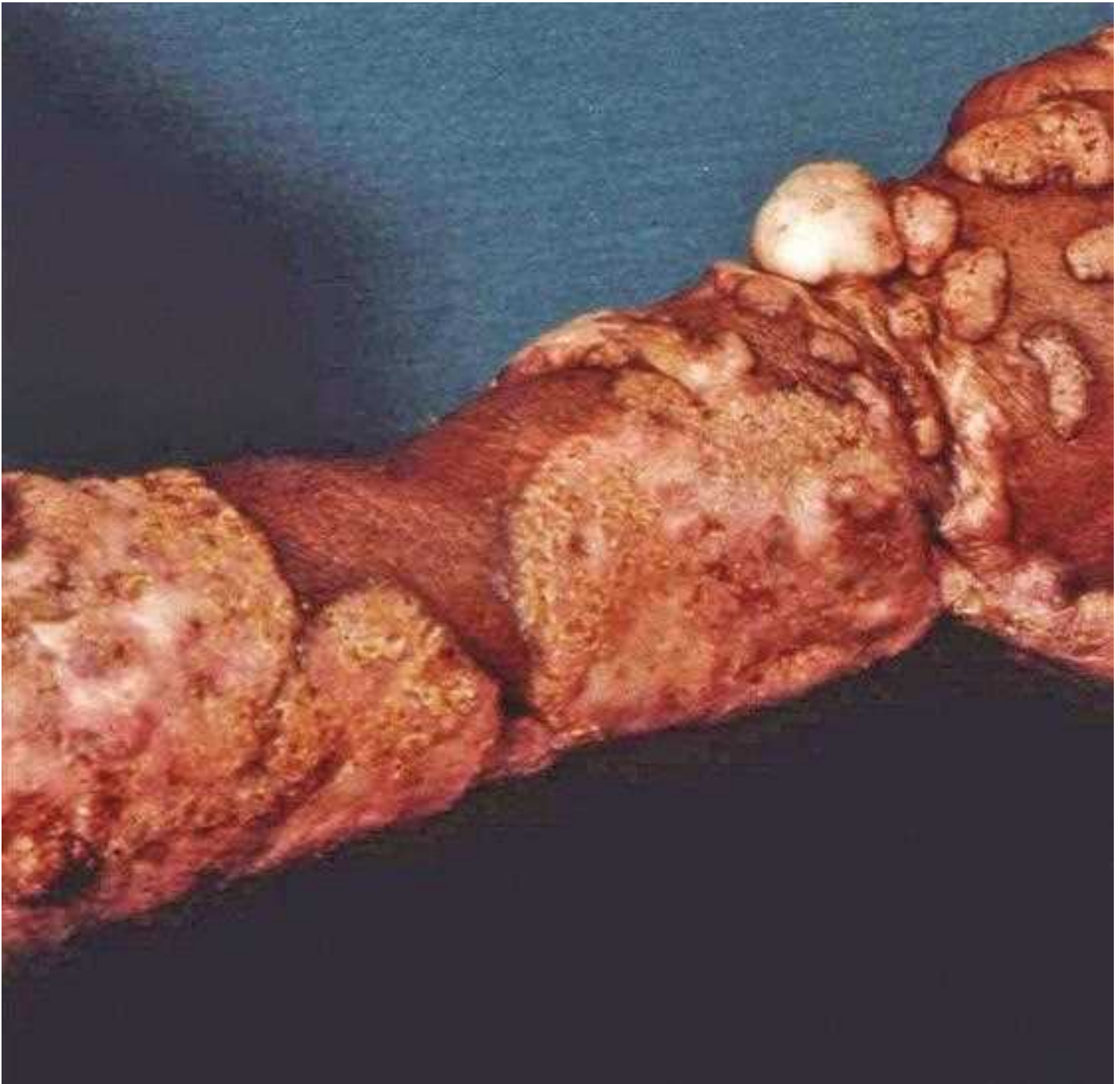

Figure 18.12 Chromoblastomycosis.

Diagnosis is usually straightforward with typical fungal Medlar (thick walled sclerotic) bodies being visualised on microscopy from a scraping or skin biopsy. Treatment has been extremely difficult in the past; cryosurgery has been used with some success as has itraconazole 200 mg twice daily. However, recent reports of cure rates around 80% with posaconazole 800 mg daily (in divided doses) are highly encouraging. Healing usually occurs with depressed pale scarring. In refractory cases surgery may be required.

Blastomycosis

The spores of the fungus *Paracoccidioides brasiliensis* are most commonly inhaled, leading

to respiratory infection; however, skin lesions occur in 20% of patients, leading to single or multiple cutaneous nodules. Skin lesions most commonly affect the face/neck and extremities and appear as violaceous papules/nodules ([Figure 18.13](#)) that expand and may ulcerate, with studded pustules around the edge of the lesions. The differential diagnosis of the skin lesions includes tuberculosis and other mycoses such as sporotrichosis, chromoblastomycosis, and coccidioidomycosis. Blastomycosis most commonly occurs in Central and South America. In suspected cases, patients should be investigated with a chest X-ray, sputum culture, bronchoscopy, skin biopsy (Periodic acid Schiff (PAS) stain), and serological tests if available. Treatment options include itraconazole 200 mg three times a day for three days and then twice daily for six months, or liposomal amphotericin B 3–5 mg/kg/day for two weeks initially before switching to oral itraconazole.

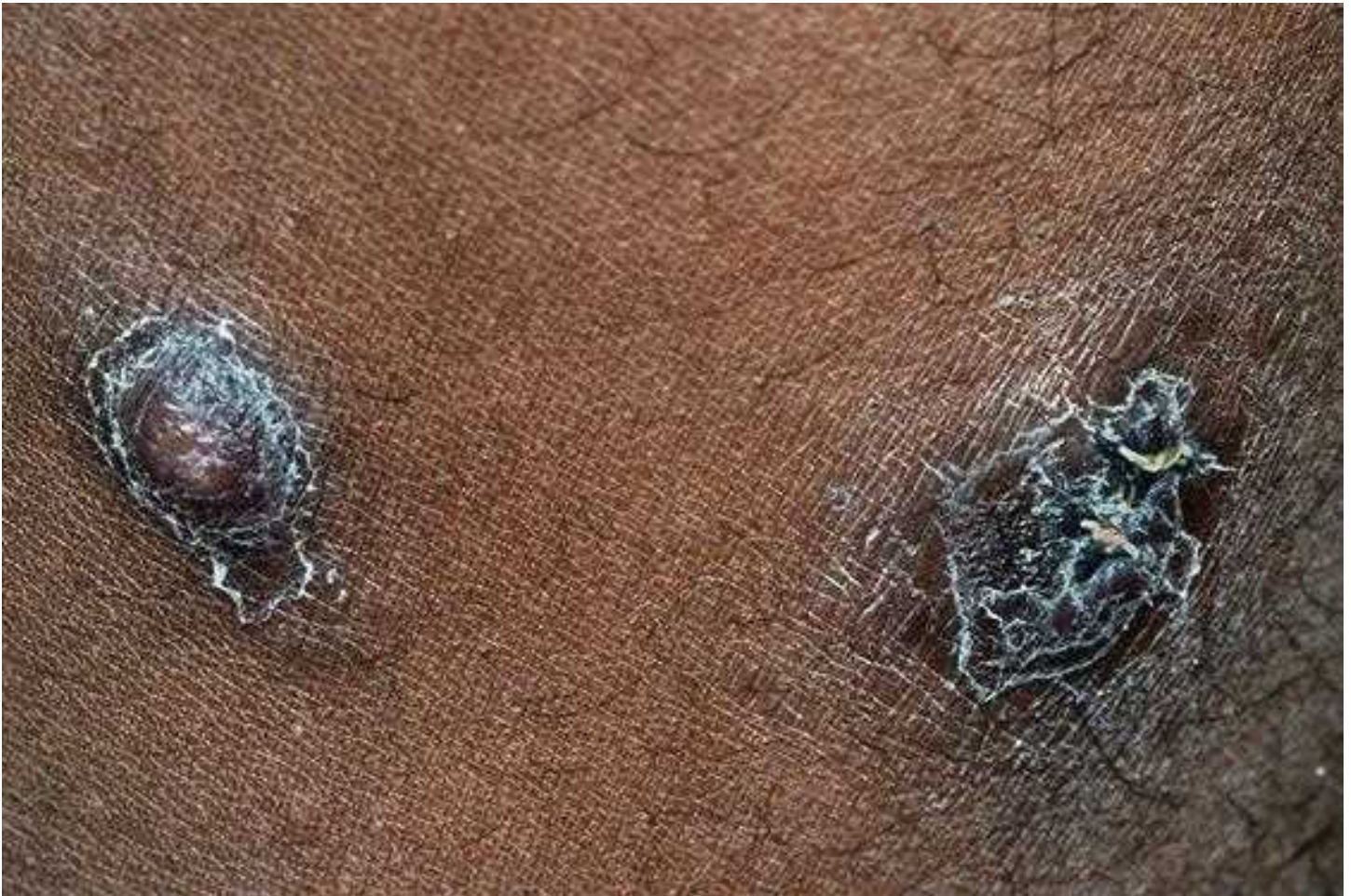
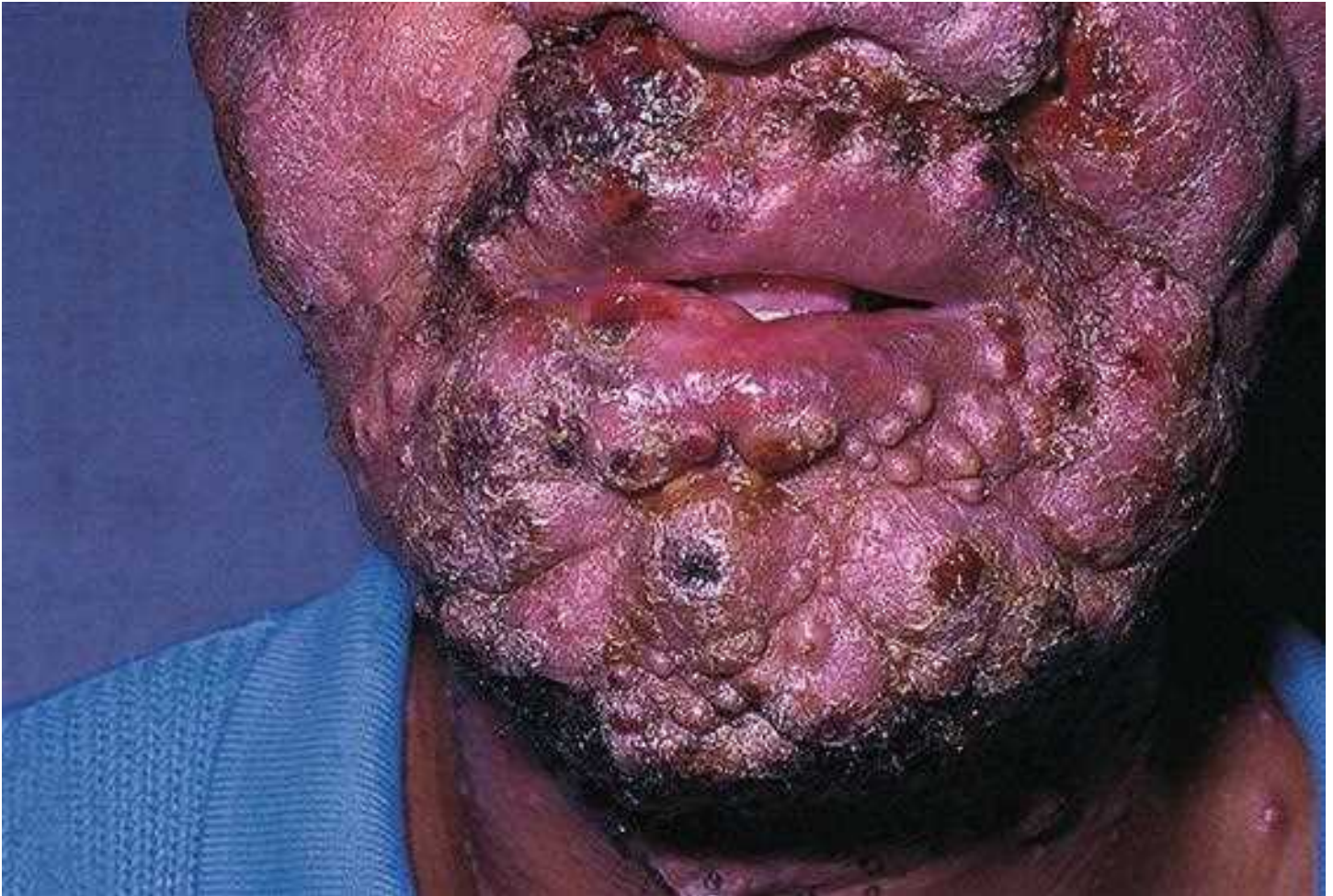
Figure 18.13 *Paracoccidioides brasiliensis* causing disseminated disease in a young patient.

Histoplasmosis

Histoplasma capsulatum is the fungal organism responsible for histoplasmosis. Two forms of the fungi exist: *H. capsulatum* var. *capsulatum* and *H. capsulatum* var. *duboisii*. The former, mainly in North/Central America and Eastern Asia, causes respiratory disease, and the latter causes skin and bone disease in West Africa. In endemic areas up to 80% of the local population has been infected; however, most of the infections are asymptomatic with spontaneous resolution. Disseminated disease can occur in immunocompromised individuals,

the elderly and young children. The cutaneous form leads to nodules and ulcers at the site of traumatic implantation that can progress to deeper tissues, leading to bony involvement. The disease is usually treated with itraconazole 100–400 mg daily for three months or amphotericin B ([Figure 18.14](#)).



[Figure 18.14](#) Histoplasmosis in HIV infection.

Infestations

Tungiasis

Invasion of the skin by sand fleas (*Tunga penetrans*) causes tungiasis in tropical areas of Africa, America, and India. Pregnant female fleas (measuring 1 mm across) burrow into the plantar skin, especially under the toes and toenails ([Figure 18.15](#)). A marked inflammatory reaction occurs at the skin site, leading to encapsulation of the parasite. Clinically, lesions can appear white with a black central dot – not dissimilar to a plantar wart. Dermoscopy can help visualise the central plugged opening of the flea's burrow. The release of flea eggs through the central opening may be seen if one is lucky.

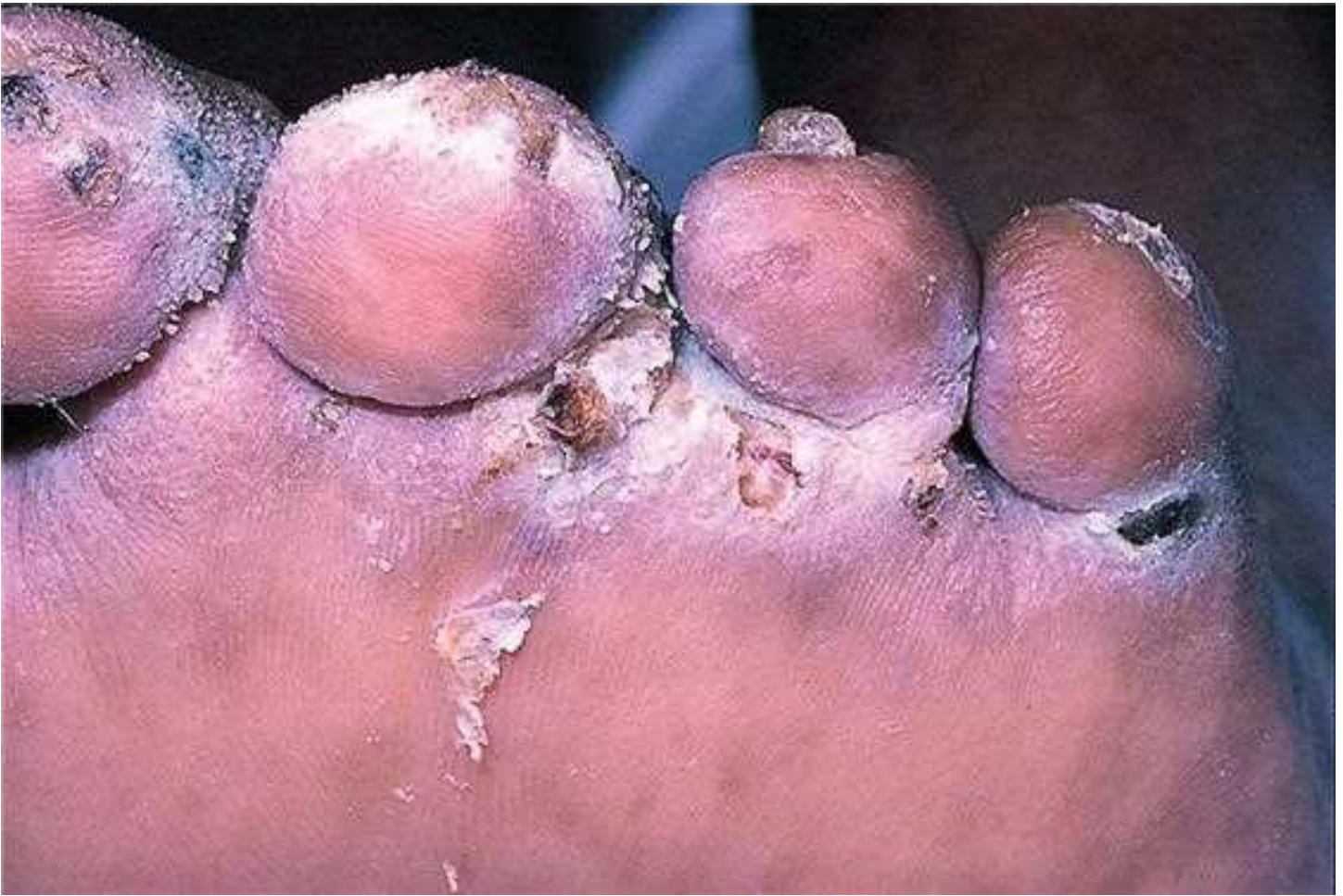

Figure 18.15 Tungiasis.

The disease can usually be prevented by wearing shoes and keeping skin exposure to a minimum. (Vaseline with 10% kerosene applied daily can prevent the tunga flea from penetrating.)

Removal of the flea is both diagnostic and therapeutic. The flea can be winkled out with a pin or sterile needle (most individuals in endemic areas perform this themselves). If the fleas are very extensive, soak the feet in kerosene or treat with a single dose of ivermectin 200 µg/kg body weight.

Subcutaneous myiasis

Invasion of the skin by the larvae of the tumbu (mango) fly (*Cordylobia anthropophaga*) in sub-Saharan Africa causes myiasis. The fly lays her eggs on dry soil or clothes laid out to dry; these hatch out two days later, and the larvae can survive up to two weeks waiting for an opportunity to invade a new host animal. When the clothes are worn, the larvae burrow into the skin, causing a red painful or itchy papule/nodule, predominantly on the trunk, buttocks, and thighs.

Other flies that cause myiasis:

- *Dermatobia hominis*. Tropical bot fly, in Mexico, Central and South America, with

tender nodules developing on the scalp, legs, forearms, and face. The bot fly lays her eggs on the abdomen of a blood-sucking insect (usually a mosquito) and when that insect subsequently takes a blood meal the eggs hatch and penetrate the skin through the bite site or broken skin. Larvae are able to 'grab' onto hair while the mosquito is feeding, leading to a high proportion of myiasis infestations affecting the scalp skin.

- *Aucheronia* sp. Congo floor maggot, in Central and southern Africa; bites of the larvae cause intense irritation.
- *Callitroga* sp. In Central America, causing inflamed lesions with necrosis.

Preventative measures include ironing clothes before wearing them to kill the eggs.

Treatment of skin lesions with an application of petroleum jelly or grease (applied in a thick layer – left in place for 30–60 minutes under an occlusive dressing) causes the larvae ([Figure 18.16](#)) either to suffocate or crawl out of the skin.

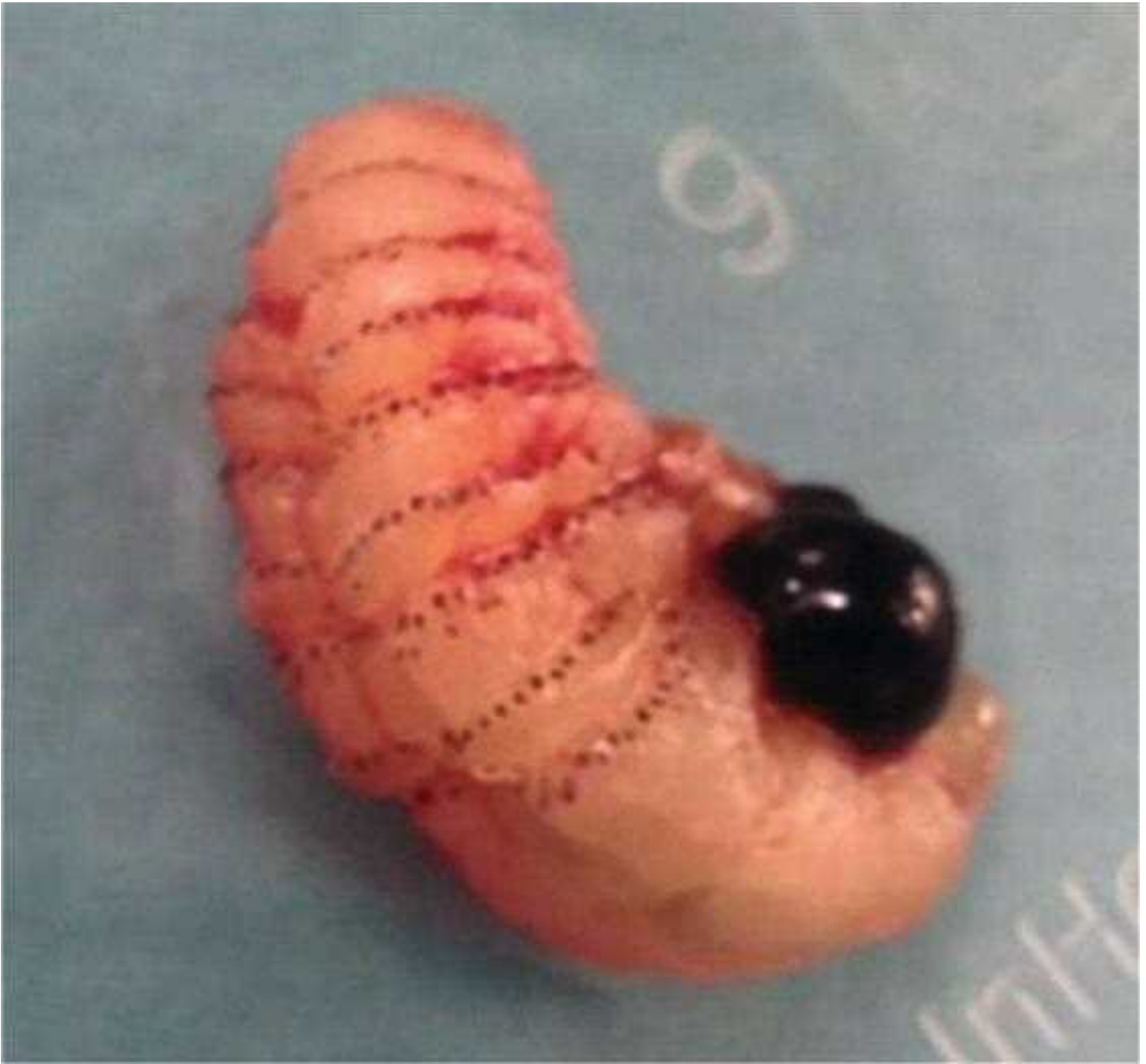

Figure 18.16 Myiasis: larva.

Filariasis

Thread-like helminths ('filum' from the Latin: thread) cause an infestation in humans when transmitted by insect vectors such as mosquitoes. There are many distinct species of filarial worms that live in the lymphatics and connective tissue. The basic life cycle starts in humans when the fertilised eggs develop into microfilariae. These are taken up by insect vectors (intermediate hosts) in which further development occurs; the mature stages are then inoculated back into humans when the insects bite.

Three diseases are caused by filarial worms.

- Lymphatic filariasis due to *Wuchereria bancrofti*, which liberate microfilariae into the

bloodstream.

- Onchocerciasis due to *Onchocerca volvulus*. The microfilariae are liberated into the skin and subcutaneous tissues.
- Loiasis due to *L. loa*, in which microfilariae are found in the blood.

Lymphatic filariasis affects 120 million people in 73 countries (34% in sub-Saharan Africa). The adult worms can live for up to four to six years in the lymphatic vessels leading to dilatation, tortuosity, and malfunction. Lymphoedema results in the draining tissues, usually the legs, genitalia, and breasts ([Figure 18.17](#)). Individuals may be asymptomatic for long periods with adult worms producing thousands of microfilariae each day. These are picked up by mosquitoes when they take a blood meal and are passed on to the next host when they feed again.

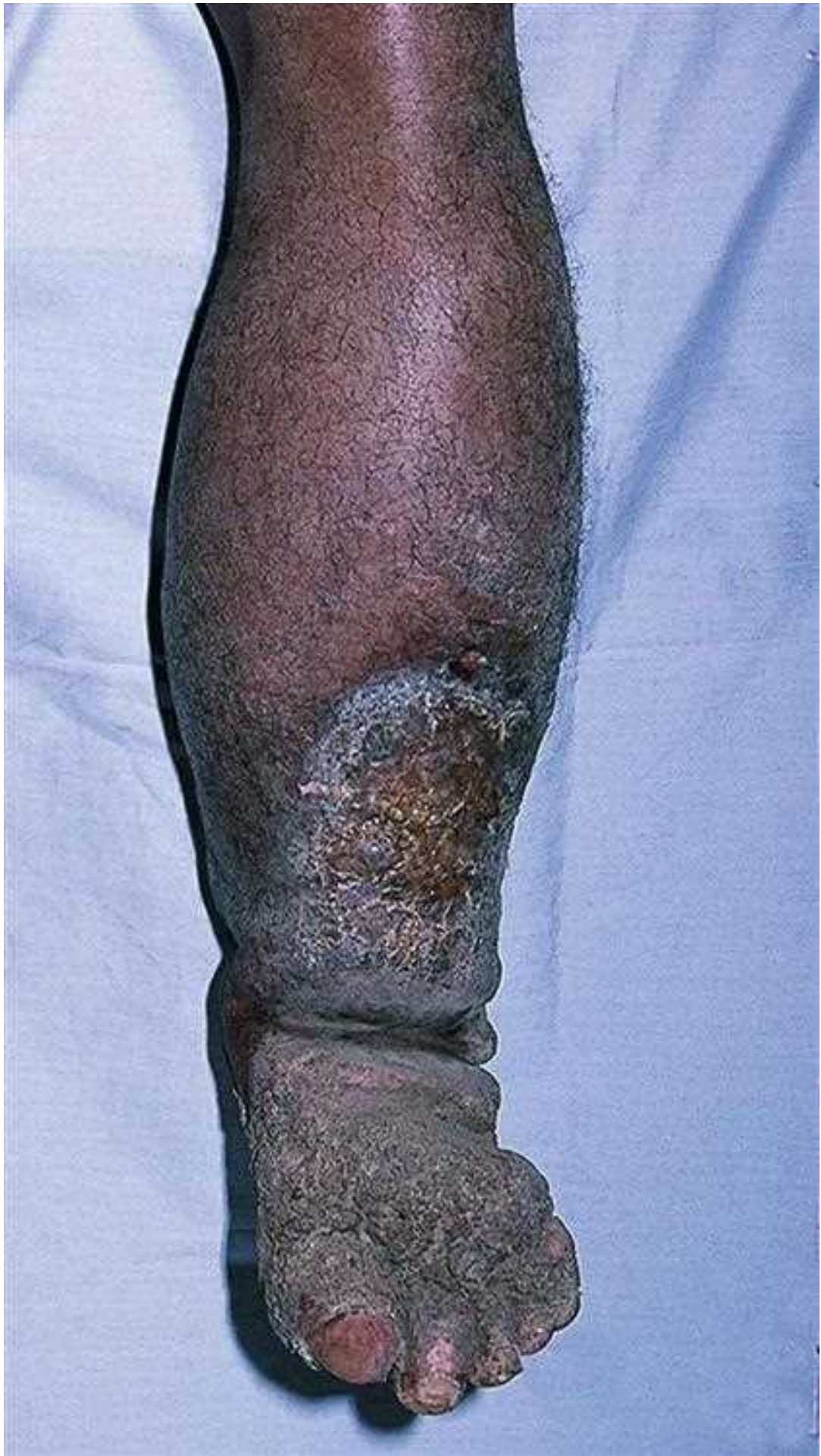

Figure 18.17 Lymphoedema of the legs in filariasis.

The diagnosis can be confirmed by examining a thick blood smear taken at midnight. More convenient detection of filarial antigens can be done at any time and takes just five minutes to complete. Fingerprick blood is placed on an immunochromatographic filariasis card to detect circulating *W. bancrofti* antigens. PCR techniques are highly sensitive and can detect one microfilaria in 1 ml of blood.

Treatment

In endemic areas, the whole community should be treated with a single dose of two of the following three drugs once a year for four to six years:

- Ivermectin 400 µg/kg body weight
- diethylcarbamazine (DEC) 6 mg/kg body weight
- albendazole 600 mg.

The chronic lymphoedema can be improved by keeping the legs moving and raising the legs when sitting, and secondary bacterial infection can be prevented by regular washing and moisturising of the skin.

Podoconiosis is a non-filariasis cause of lymphoedema of the lower legs in people exposed to red volcanic soil high in silicates. Endemic areas include the highlands of Ethiopia, parts of India and Central America. The aetiology is thought to be a combination of genetic predisposition and chronic exposure to certain soil types of bare skin of the feet. The most commonly affected are those working the land who do not wear shoes. The resultant inflammation in the skin causes damage to the lymphatics, which lead to a 'mossy' appearance of the foot with papules, nodules, swelling, and marked lymphoedema which may be uni- or bilateral. Treatment includes washing the feet, compression, and getting patients into shoes (those made initially need to be custom made to fit the enlarged feet). Prevention through education and getting local populations to wear shoes should help reduce the incidence of this neglected tropical disease.

Onchocerciasis

Onchocerciasis (river blindness) occurs in Africa south of the Sahara and in Central America. It is due to *O. volvulus* transmitted by the bite of blackflies *Simulium damnosum* which breed by fast-flowing rivers. The inoculation of microfilariae by the bite of a blackfly causes intense local inflammation and is followed by an incubation period of one to two years. The adult worms live in nodules around the hips and in themselves cause no harm. However, they produce thousands of microfilariae each day which travel to the skin and eyes. In the skin, they produce a very itchy rash which looks similar to lichenified eczema. On the lower legs, there is often spotty depigmentation ([Figure 18.18](#)). Involvement of the eyes causes blindness.

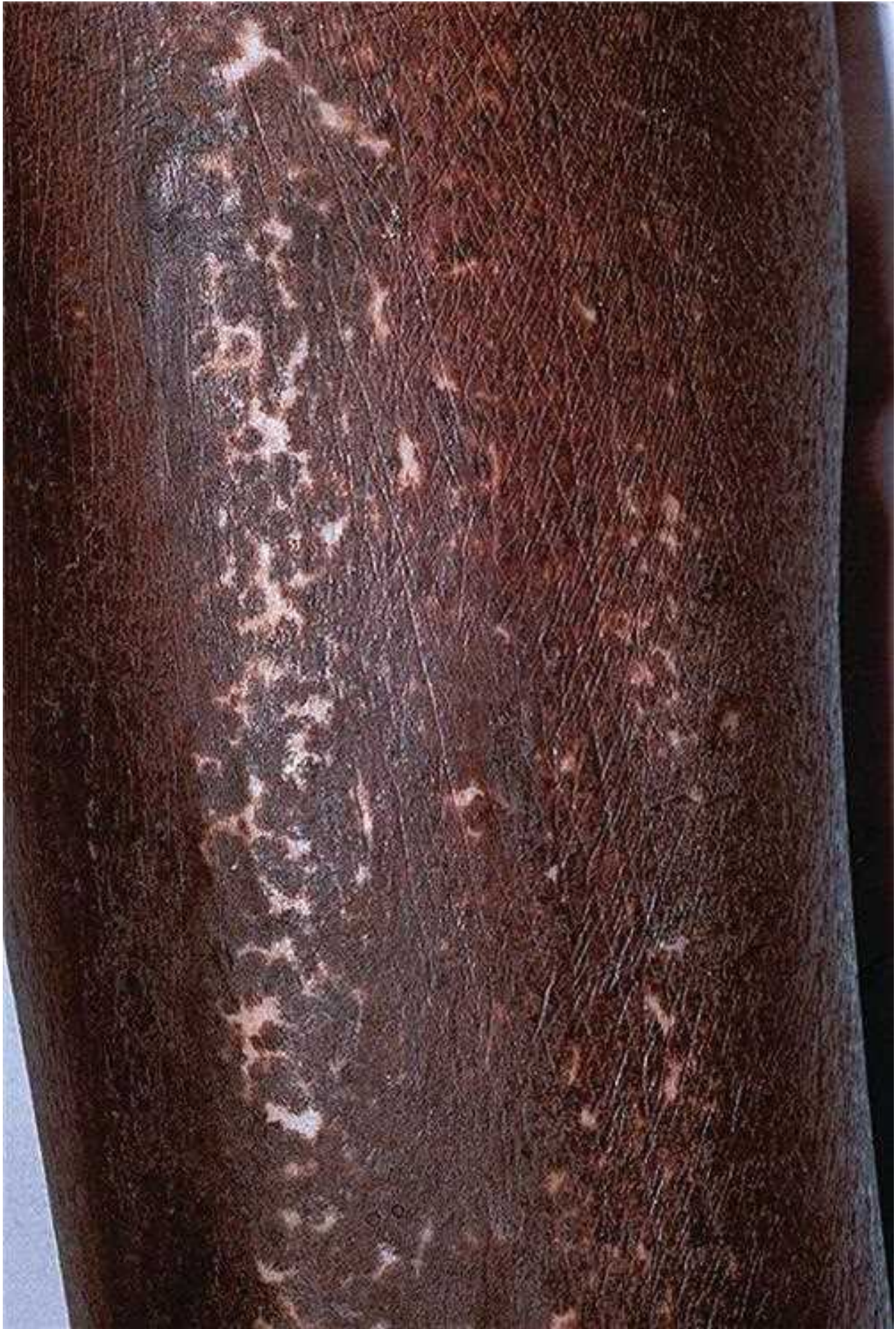

Figure 18.18 'Leopard skin' in onchocerciasis.

Risk factors for being infected

- Living, working, or playing near fast-flowing rivers.
- Not wearing enough clothes so that the skin is exposed to insect bites.
- The construction of dams leading to less breeding of blackflies within the dam itself but increased breeding in the dam spillways.

Diagnosis

The microfilariae can be demonstrated by skin snips or slit-lamp examination of the eyes. Skin snips are usually taken from six sites (iliac crests, scapulae, and calf bilaterally). Very superficial samples of skin (without drawing blood) are taken and placed in saline; within an hour the microfilariae can be seen on microscopy. Removal of a skin nodule can reveal the adult worms. PCR to show parasite DNA and ELISA tests are now available in some countries.

Treatment

Spray the breeding areas with insecticides. An annual dose of ivermectin (400 µg/kg for four to six years) should be taken by all those living in endemic areas to prevent the release of microfilariae from the adult worms. In addition, doxycycline 100 mg daily for six weeks helps kill the adult worms or sterilise the females by killing the symbiotic bacteria *Wolbachia* in their gut, leading to lower worm burdens.

Loiasis (*Loa loa*)

Loiasis occurs in the rain forests of Central and West Africa. It is transmitted by mango flies, deer, and horseflies. The adult worms live in the subcutaneous tissues, where they can be seen in the skin and under the conjunctivae. The microfilariae are only found in the blood. Hypersensitivity to the worms shows itself as swelling of the skin, particularly of the wrists and ankles (Calabar swellings), which are itchy and erythematous.

Diagnosis

- Thick blood film to look for microfilariae (sample taken between 10 a.m. and 2 p.m.).
- Adult worms can be identified by soft-tissue ultrasound examination.
- Immunoassay for antigen detection may be the most reliable test.

Treatment

- First give pre-treatment with albendazole 200 mg with a fatty meal twice daily for three weeks before considering treatment with ivermectin or DEC. A single dose of

ivermectin 400 µg/kg body weight can be given but there is a risk of encephalopathy if the microfilariae numbers are high.

- DEC should be avoided unless microfilariae numbers are low or the patient has been pre-treated with albendazole, as this can cause death as a result of a reaction to toxins from the rapid destruction of the microfilariae.

Dracunculiasis

Dracunculus medinensis or 'Guinea worm' is a nematode that infests the connective tissue of humans. It is acquired from drinking fresh water containing the intermediate host, a copepod (*Cyclops*) that contains the parasitic larvae. From the gastrointestinal tract, the female mature nematode migrates to the subcutaneous tissue, usually of the lower leg. Papules develop at the skin site containing the female worm and numerous microfilariae which are released on contact with water. Treatment consists of very carefully extracting the worm by winding it onto a stick (a few centimetres per day) over several weeks (adults can be 1 m long). Symptomatic treatment of secondary infection and allergic reactions is also required. If the adult worm dies in the extremity it may become encased in calcium, causing chronic pain and leg swelling.

To prevent exposure to the larvae, water should be filtered or boiled before drinking. Swimming in fresh water in endemic areas should be avoided, in order to break the life cycle.

Further reading

Schaller, K.F. (2013). *Colour Atlas of Tropical Dermatology and Venerology*. Springer-Verlag.

Tyring, S.K., Lupi, O., and Hengge, U.R. (2017). *Tropical Dermatology*, 2e. Elsevier.

CHAPTER 19

Hair and Scalp

Kapil Bhargava and David Fenton

St John's Institute of Dermatology, Guy's and St. Thomas' Hospitals, London, UK

OVERVIEW

- Changes to the structure of the hair follicle or the hair cycle lead to many common hair disorders.
- Hair loss, or alopecia, has a significant psychological impact on affected individuals.
- Hair disorders may indicate underlying systemic disease.
- Hair loss can be classified into scarring and non-scarring types. These two categories these may be subdivided into diffuse, localised, or patterned hair loss.
- Common types of non-scarring alopecia include androgenetic alopecia, female pattern hair loss, alopecia areata, telogen effluvium, and tinea capitis.
- Scarring alopecia is less common and maybe classified as either lymphocytic or neutrophilic disorders, which may be localised to the scalp or systemic.
- Excess hair growth of hair should prompt consideration of underlying systemic disease.

Introduction

To the present-day human hair plays a significant role in the beliefs and ideals of society, and consequently in the self-image of individuals. The loss of hair or development of excess unwanted hair often causes marked psychological distress. In addition to the psychological impact, hair disorders may indicate underlying localised or systemic disease.

The hair follicle and hair cycle

The hair follicle is the structural unit responsible for the formation of a hair fibre. The size and shape of the follicle determines the shape of the hair fibre. The follicle is a dynamic structure responding to internal and external stimuli allowing variation in the production of the hair fibre in line with age, sexual maturity, and seasonal variation. Androgens are the main hormonal regulator of human hair growth.

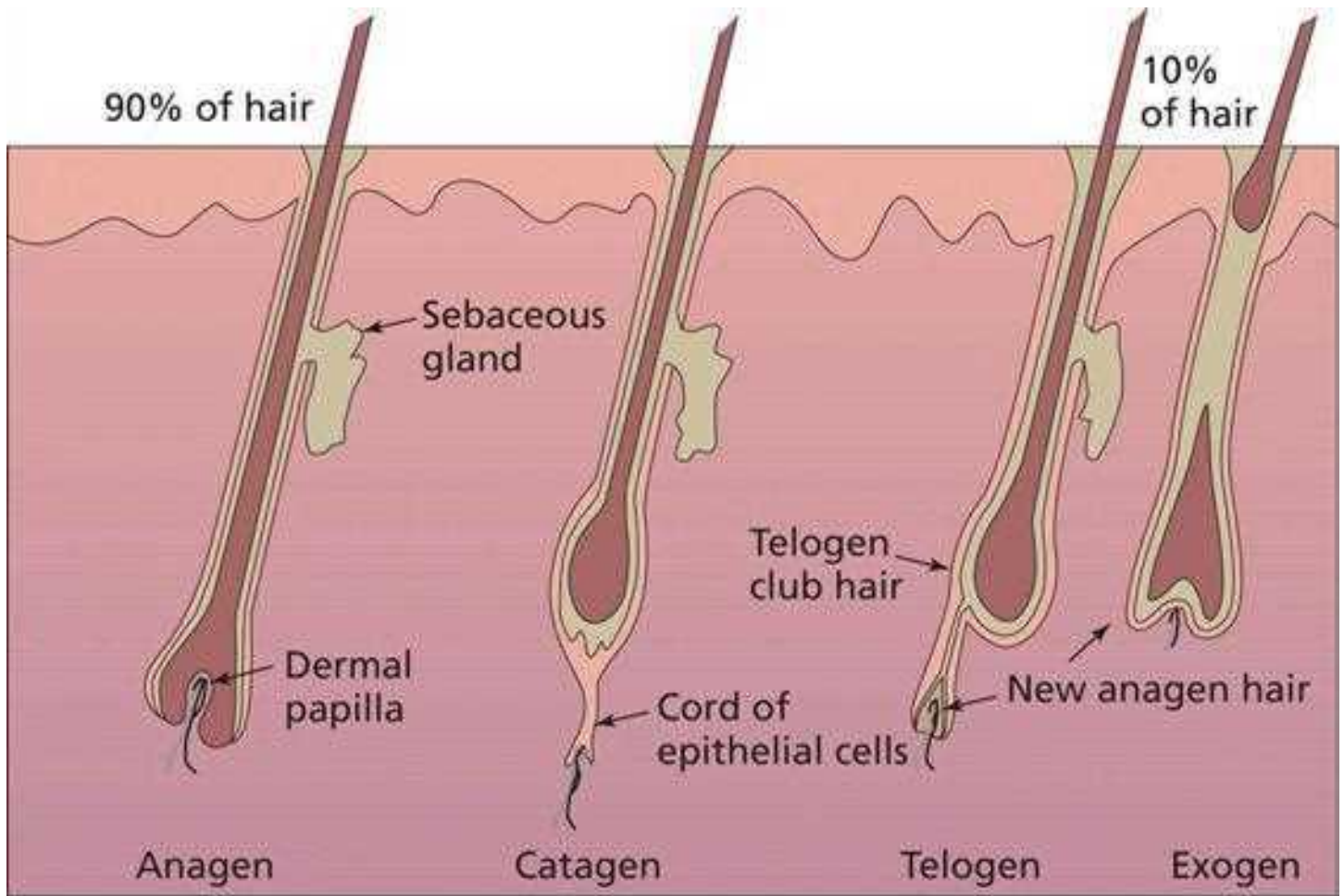
The hair fibre is a modified type of keratin and is produced by the hair matrix. Three types of

hair occur in humans:

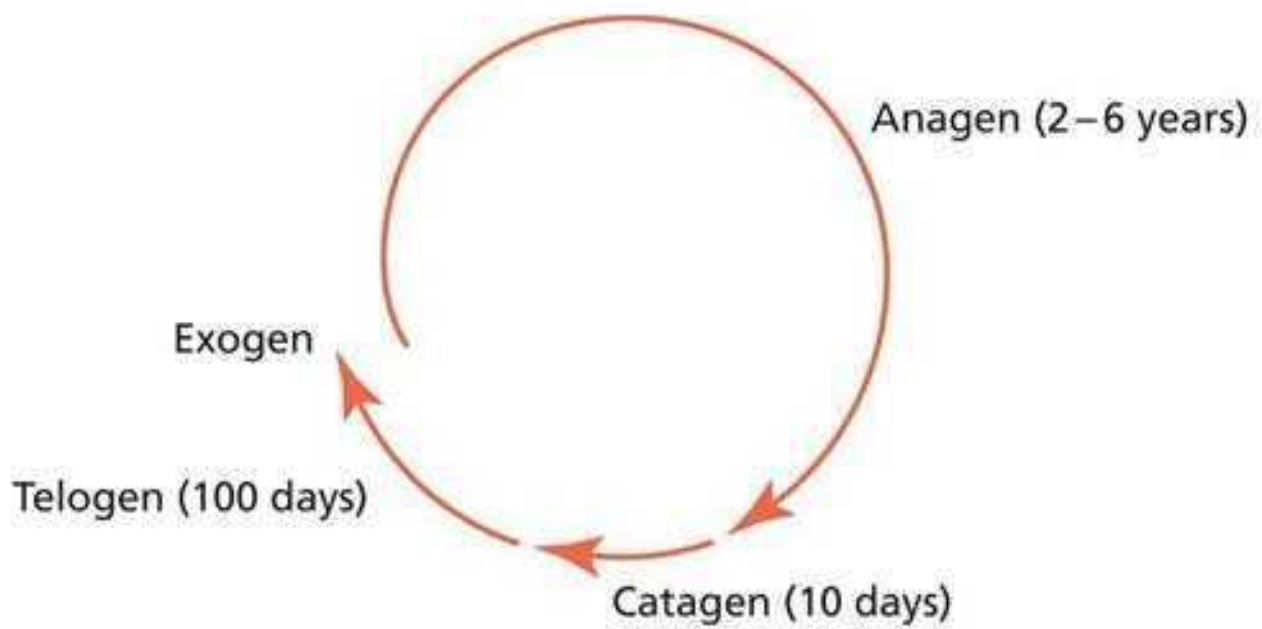
1. Lanugo hair covers the foetus in utero and is normally shed before birth. This is long and silken. It may be observed in adults with various forms of hypertrichosis.
2. Vellus hair covers the whole body (sparing the palms and soles only) and is short, fine, and non-pigmented.
3. Terminal hair is limited to the eyebrows, lashes, and scalp until puberty. Following puberty, secondary terminal hair develops in the axillae, pubic region, and on the central chest in men in response to androgens. It is coarser than vellus hair and tends to be darker and longer.

The hair cycle governs the growth of the hair fibre within the follicular unit. There are four phases ([Figure 19.1](#)).

1. *Anagen*. The active growth phase. This is genetically pre-determined and typically lasts for two to six years on the scalp, but only weeks to months on the extremities resulting in the different lengths of hair fibres commonly seen.
2. *Catagen*. The short growth arrest phase with cessation of protein and pigment production and regression of the follicle, lasting typically two to three weeks on the scalp.
3. *Telogen*. The resting phase, lasting approximately three months on the scalp, is, however, more frequent on the body.
4. *Exogen*. The controlled shedding phase which has been recently described.



(a)



(b)

Figure 19.1 (a) Diagrammatic cross-section of hair at various growth phases. (b) Hair growth cycle.

The ratio of anagen to telogen hairs on the scalp is approximately 9 : 1, reflecting the fact that only a few hairs at a time are in telogen phase. Changes to the structure of the follicle or the hair cycle leads to the common clinical hair disorders.

Hair loss

Hair loss or alopecia can be classified into scarring and non-scarring types based on presence of histopathologic fibrosis of the hair follicle, resulting from the causative pathological process. Scarring can often be clinically observed as loss of visible follicular ostia on the scalp. These two categories can then be sub-classified into diffuse, localised, or patterned hair loss.

Non-scarring alopecias

Male pattern hair loss

Androgenetic alopecia (AGA) is synonymous with male pattern (or pattern) baldness and is the most prevalent form of hair loss, affecting about 50% of Caucasian males to some extent by the age of 50. It is an androgen-dependent, genetically determined trait in which there is progressive, age-related, decline in the size and activity of hair follicles.

Locally and systemically derived dihydrotestosterone (DHT), the more potent metabolite of testosterone, is the key hormone driving hair loss. The conversion of testosterone to DHT is mediated by the enzyme 5- α reductase.

Hairs get finer and shorter, with hair loss is observed in a characteristic pattern, hence the term patterned hair loss. Initially this is observed over the temples (fronto-temporal recession) or vertex in men and may progress to leave a horseshoe distribution of hair over the lower parietal and occipital scalp. Hair in these regions remains as the follicles are unresponsive to androgen mediated miniaturisation. The Norwood-Hamilton classification is illustrated in [Figure 19.2](#), although variation is common.

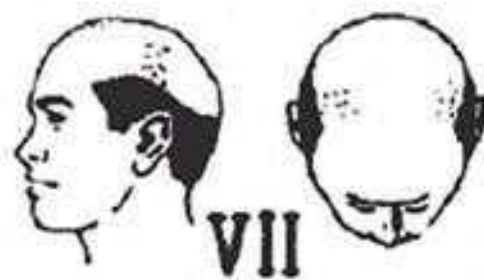

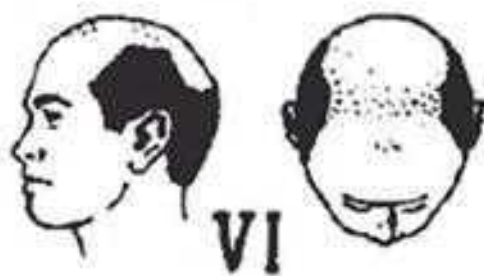

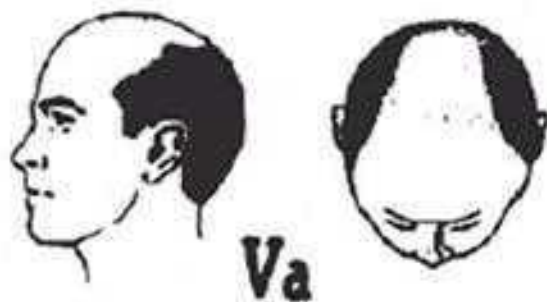
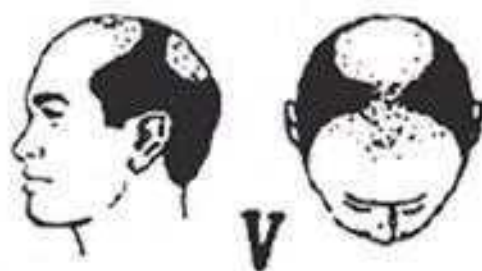


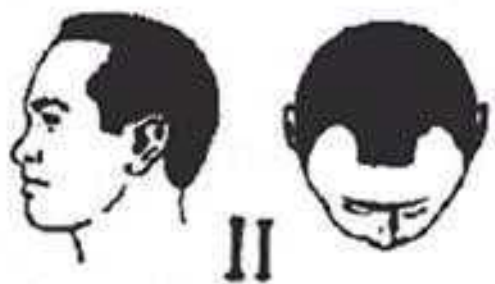

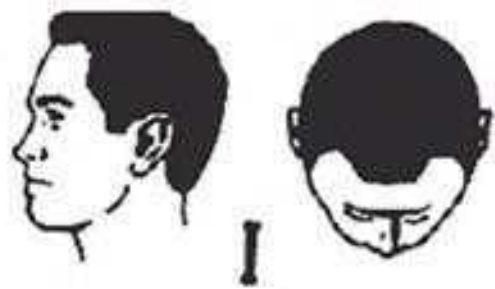


Figure 19.2 Norwood's classification of male pattern balding.

Source: Norwood OT (1975) Male pattern baldness: classification and incidence. *South Med J*; 68: 1359–1365.

There is currently no cure for AGA; however, treatments may reduce the rate of progression and to a lesser extent encourage regrowth. Oral finasteride and topical Minoxidil are licensed for use in AGA.

Minoxidil 5% lotion or foam applied twice daily provides improvement in around 60% of men after use for at least four to six months. It is important to stress the long-term nature of treatment as cessation leads to loss of any positive benefit within four to six months. Adverse effects include skin irritation and hypertrichosis of the face.

Finasteride is a 5 α -reductase inhibitor and reduces circulating and localised scalp DHT levels. Oral dosing of 1 mg daily may slow hair loss and improve growth in two-thirds of men. The improvement peaks at 12 months. However, continued long-term treatment is required to maintain the benefit. There is a small increased incidence of sexual dysfunction manifesting as reduced libido, impotence, and/or ejaculatory dysfunction. In addition, there are reports of male breast cancer and potential depression in a small number of individuals.

Surgical hair transplantation can provide durable cosmetic benefit. It involves the redistribution of hair from androgen insensitive sites (at the occipital scalp) to the balding area. Donor hairs are harvested as individual follicles from the back of the scalp (follicular unit extraction [FUE]) or are divided from strip of surgically removed scalp tissue (follicular unit transplantation [FUT]). In principle, there needs to be adequate donor follicular units relative to the size of the bald area to be efficacious and pre-operative consideration of future areas of hair loss is important.

Female pattern hair loss

Female pattern hair loss (FPHL) is a broad term for the non-scarring progressive decrease in central scalp density that occurs in women post-puberty ([Figure 19.3](#)). There is a bimodal onset: post-puberty to late twenties and the second peak post-menopause. More than 50% of women over the age of 50 years will experience this and it is often emotionally devastating.




Figure 19.3 Ludwig patterns of hair loss.

Source: Ludwig E. Classification of the types of androgenetic alopecia (common baldness) occurring in the female sex. *Br J Dermatol.* 1977; 97: 247–54.

Women often notice a widening of their parting initially and a reduction in the density and volume of the hair on the top of the scalp progressively. The frontal hairline is often retained. As in men, over time, the follicles become smaller, producing shorter and finer hairs.

Three broad patterns are noted ([Figure 19.4](#)). Most women will have normal circulating androgen levels, but these should be checked in individuals with FPHL, particularly if young at onset, in the case of a Hamilton (male) pattern type of loss or in women where there may be other signs of androgenisation suggesting gonadal (e.g. polycystic ovarian syndrome) or rarely adrenal disorders. Chronic telogen effluvium is the main differential and may co-exist.

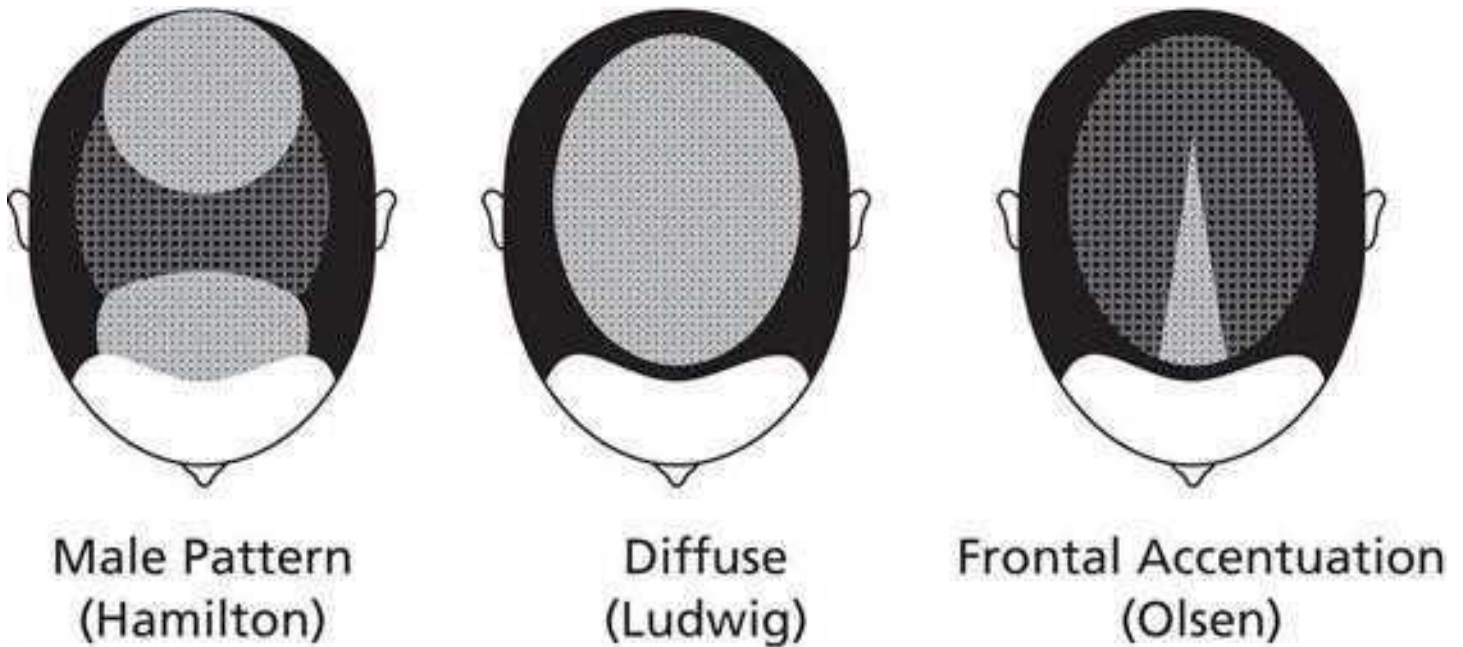


Figure 19.4 Patterns of hair loss in female pattern hair loss.

Source: Olesen ES (2004) Pattern hair loss in men and women. In: Olsen EA, ed. Hair Disorders: Diagnosis and Treatment. McGraw-Hill, New York.

Minoxidil 5% foam provides benefit in about two-thirds of women, with the majority experiencing a reduction in the rate of progression. Once daily use of the 5% foam is at least as good as 2% lotion twice daily and is less likely to interfere with hair styling.

Combined oral contraceptive pills (COCP) or hormone replacement therapy (HRT) with low androgenic progestogens can also be used, but sustained use is required to maintain the benefit, which requires careful risk-benefit evaluation.

Anti-androgens such as cyproterone acetate are most useful in women with hyperandrogenism. Spironolactone is being increasingly used although high doses are often needed. Efficacy of finasteride and dutasteride is more controversial. A double-blind trial has shown finasteride 1 mg daily is ineffective in women with FPHL. All therapies are contraindicated in pregnancy and long-term therapy is needed to maintain benefit.

Hair transplantation is an option where medical therapy fails. FPHL tends to be more diffuse than male pattern loss which may limit the size of the donor area.

Alopecia areata (AA)

Alopecia areata (AA) is an organ-specific autoimmune disease, which leads to non-scarring alopecia. It affects 0.15% of the population and can affect any hair-bearing part of the body. Extensive involvement may lead to total scalp hair loss (alopecia totalis), total body hair loss (alopecia universalis) or localised hair loss over the lateral and occipital scalp margin (ophiasis).

AA typically presents with smooth round or oval patches of non-scarring hair loss on the scalp ([Figure 19.5](#)). Exclamation mark hairs, when present, are diagnostic of AA. These

characteristic hairs break at their distal point as they taper and lose pigment proximally, giving them the appearance of an exclamation mark and occur at the periphery of patches of alopecia ([Figure 19.6](#)). Nail abnormalities, predominantly pitting or roughening (trachyonychia), may occur in association with this condition ([Figure 19.7](#)). Other organ-specific autoimmune disorders such as vitiligo and thyroiditis are more common in patients with AA. Investigation of associated diseases is usually indicated if symptomatic.

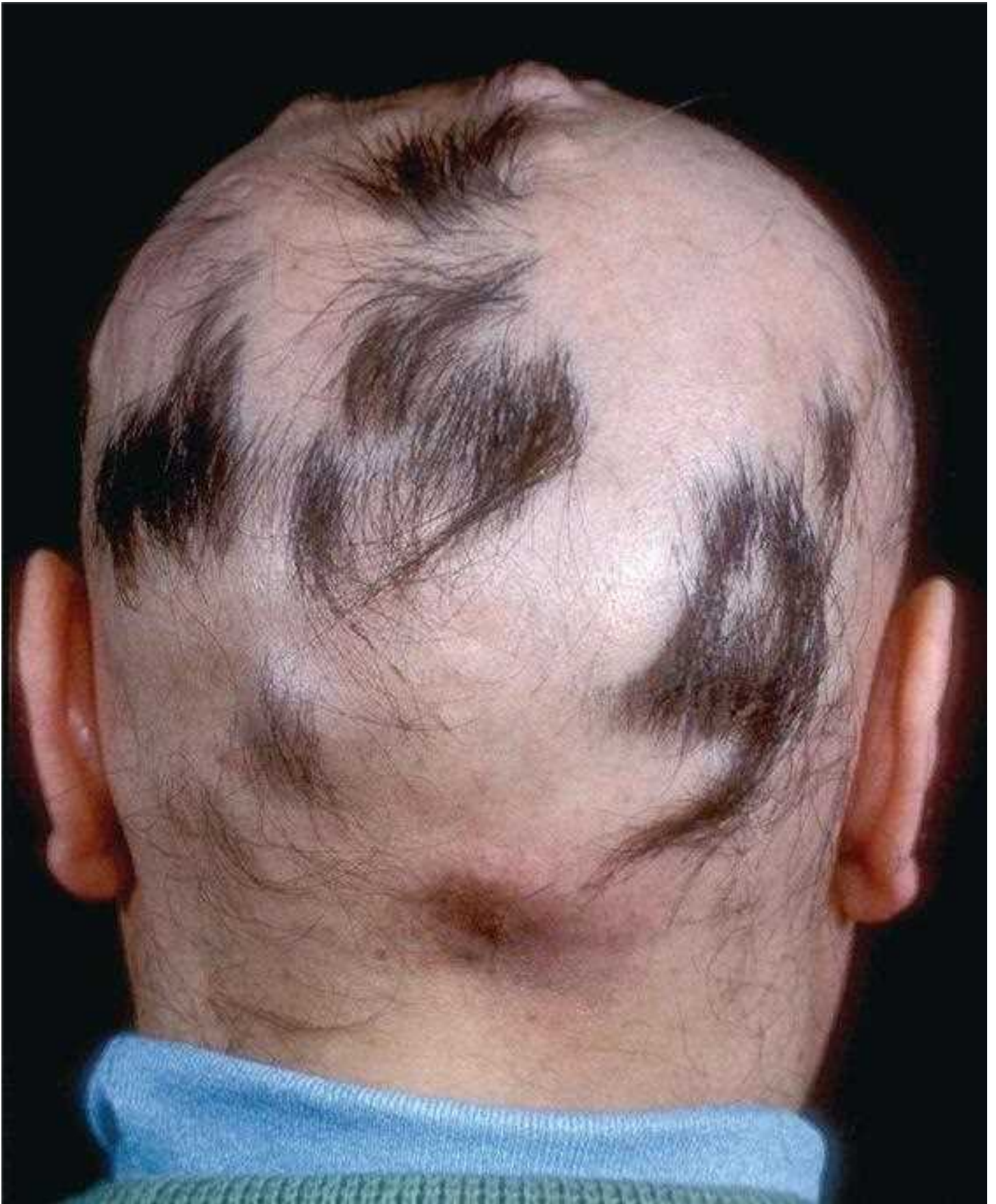

Figure 19.5 Alopecia areata.

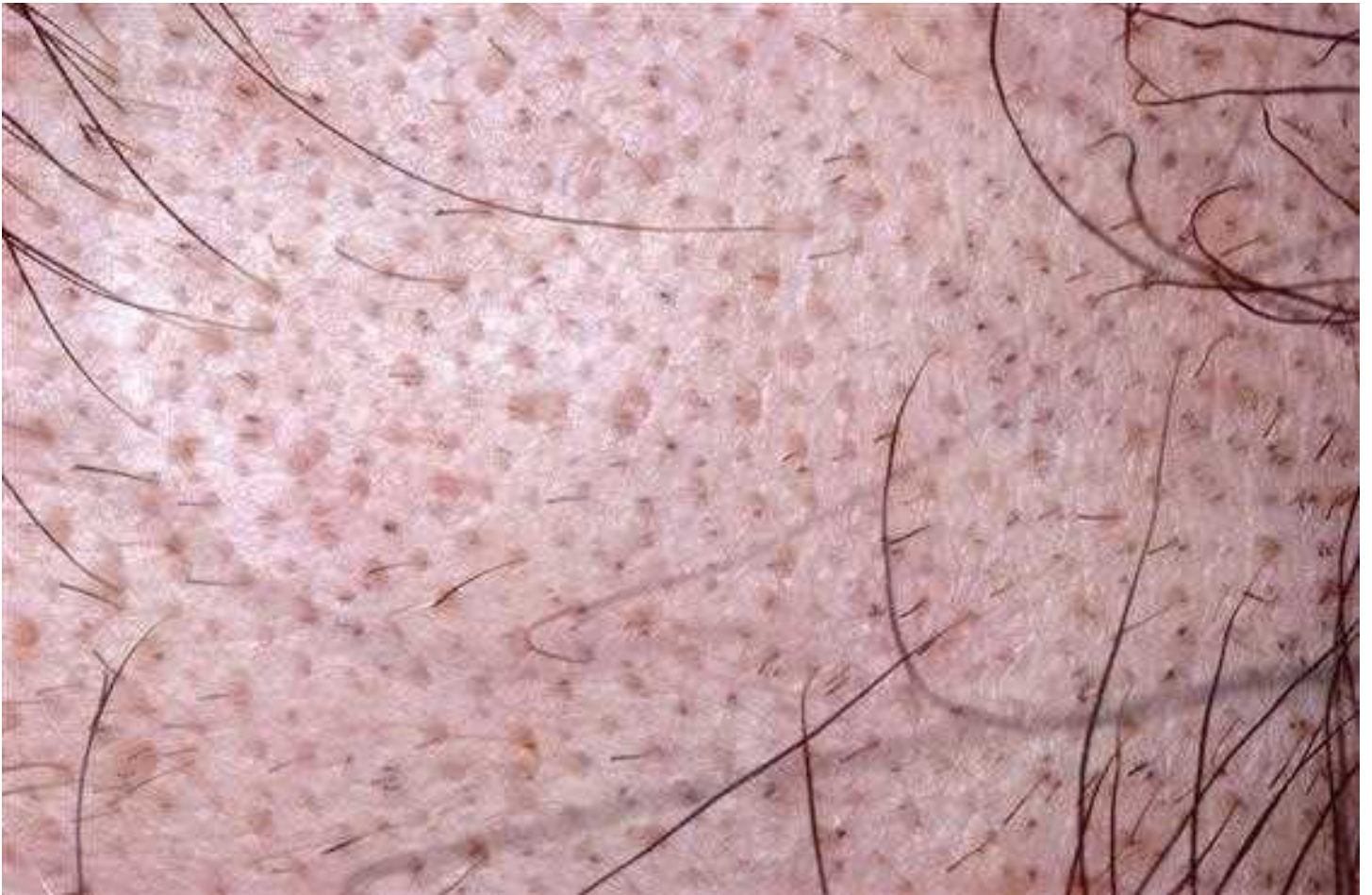


Figure 19.6 Exclamation mark hairs.

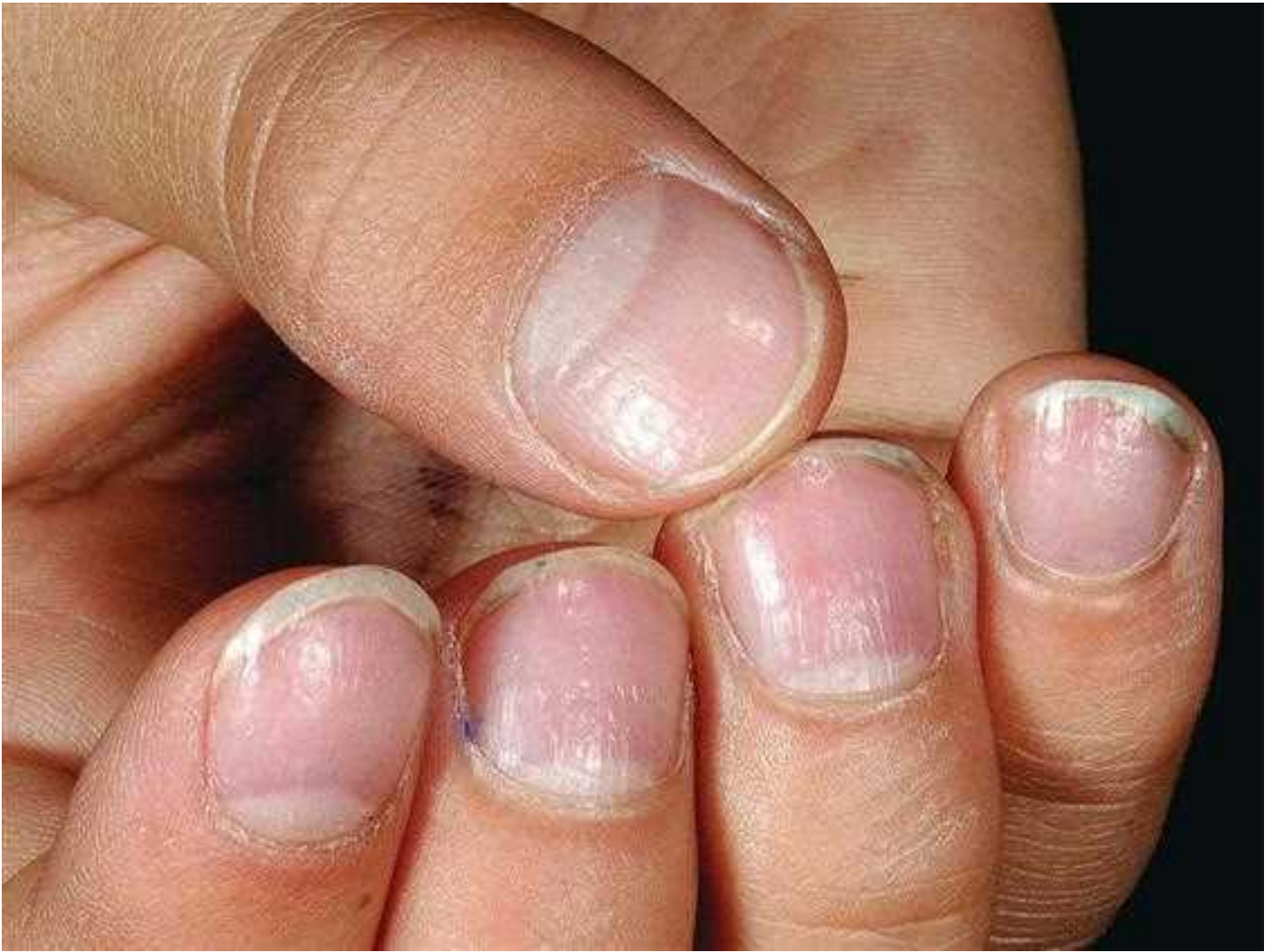

Figure 19.7 Nail pitting associated with alopecia areata.

The age of onset is usually in the first two decades. The course of AA is difficult to predict. Poor prognostic markers include

- childhood onset of disease
- atopy
- ophiasis (band of alopecia in occipital region)
- nail dystrophy
- family history of other autoimmune disorders
- presence of autoantibodies.

Trichotillomania maybe considered in the differential diagnosis of small patches and the uncommon diffuse presentation of AA (AA incognita) may be mistaken for a telogen effluvium or AGA. A careful history, examination of associated features and a scalp biopsy, where there is diagnostic difficulty, are helpful in these cases.

In AA, the hair follicle is not injured and maintains the potential to regrow hair. Indeed, the

majority of isolated patches spontaneous regrow if given enough time. However, many patients will get further patches. There is no cure for AA and no universally proven treatment to stimulate hair regrowth. It is unclear if any of the treatment options available alter the course of the disease. Treatment is therefore guided by the impact of the condition on the individual and their comfort with the risks and benefits of the treatment options. For some individuals, even with extensive hair loss, no treatment is a good choice. Psychological support is an integral part of the therapeutic approach.

Current treatments include the following.

Topical therapies. Potent topical corticosteroids can be used on the scalp for two to three months on localised patches of alopecia. Up to 20% of patients experienced significant regrowth with clobetasol propionate 0.05%. Topical calcineurin inhibitors can be used as an alternative as long-term continuous use of potent topical steroids may cause skin atrophy.

Intralesional corticosteroids. Many patients with small patches of loss respond to intralesional corticosteroid injections. Risks aside from the discomfort include skin atrophy.

Systemic corticosteroids. Short courses remain an option for more extensive loss than cannot be managed with intralesional therapy. Long-term use is not advised due to the myriad of adverse effects.

Psoralen with ultraviolet A (PUVA). The authors do not recommend this treatment due to the high relapse rate and the increased risk of malignancy from repeated courses of treatment.

Contact sensitisation. This may be performed using either irritants (dithranol or retinoids) or allergens (diphencyprone). Inducing and maintaining a low-grade eczematous reaction can be beneficial especially in patients with larger areas of scalp hair loss.

Systemic immunosuppressants. Cyclosporin, methotrexate and azathioprine have response rates of between 25% and 70%. Continued use is required to maintain benefit and careful consideration of the risk and benefits of this approach including the potential drug related side effects need to be undertaken.

Janus kinase inhibitors (JAK inhibitors). These group of drugs are showing promise in clinical trials and are expected to have higher rates of regrowth compared to existing therapy, At the time of writing these were not approved for the treatment of AA.

Other non-scarring alopecias

Telogen effluvium

In the normal scalp, each hair follicle passes through the growth cycle independently, or

asynchronously. However, following various stimuli a large proportion of hair follicles may enter the resting phase (telogen) at the same time (synchronously) resulting in diffuse shedding approximately three months after the triggering event. This is usually an acute self-limiting phenomenon, resolving within six months; however, chronic telogen effluvium may occur if it remains persistent. Patients may describe excessive hair shedding or it ‘falling out by the roots’, and when chronic, they notice a reduction in the hair volume.

[Table 19.1](#) lists the common causes of a telogen effluvium. Acute telogen effluvium is most commonly seen in a post-partum setting. Ultimately the condition will resolve once the precipitating factor has been removed. Patients with a chronic telogen effluvium often seek medical advice and in addition to a detailed history and examination thyroid function, ferritin, vitamin B12, folate, and zinc levels may be considered. Iron replacement should be implemented to achieve serum ferritin of at least 70 µg/l.

[Table 19.1](#) Causes of telogen effluvium.

| |
|---|
| Hormonal (e.g. pregnancy and post-partum, initiation or cessation of hormonal contraceptives and HRT) |
| Nutritional (e.g. protein, calorie, vitamin, or mineral deficiency) |
| Acute weight changes |
| Drugs (e.g. β -blockers, anti-coagulants, retinoids, immunisation) |
| Systemic disease (e.g. thyroid dysfunction, chronic inflammatory diseases, malignancy) |
| Stress (e.g. major surgery or trauma) |

Tinea capitis

Tinea capitis (see [Chapter 16](#)) is a fungal infection which causes patchy usually non-scarring hair loss associated with short broken-off hairs, scaling, and erythema of the underlying skin ([Figure 19.8](#)). It occurs almost exclusively in children. The most common fungi causing disease in urban areas are *Trichophyton tonsurans* (spread from human to human by direct contact) and *Microsporum canis* (caught from kittens or puppies). The diagnosis can be confirmed by taking hair pluckings and performing microscopy to look for spores inside the hair shaft; culture identifies the underlying organism. Scalp brushings can be taken, and the bristles directly inoculated into the culture medium. Tinea capitis due to *M. canis* fluoresces green under Wood's light.

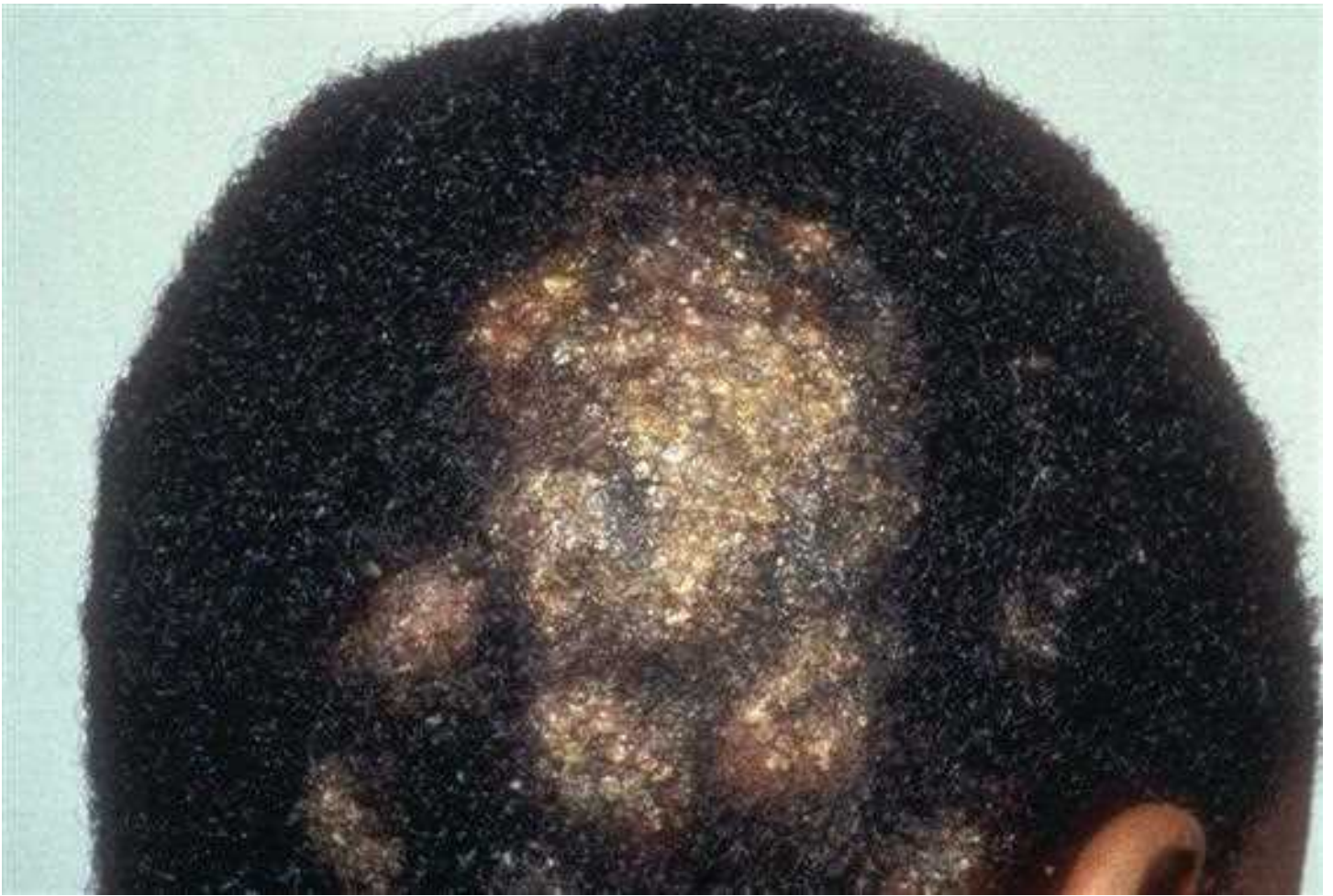

Figure 19.8 Tinea capitis.

Kerion formation ([Figure 19.9](#)) is an inflamed, boggy, pustular lesion on the scalp that may result from tinea infections (cattle ringworm in rural areas and human *T. tonsurans* in urban areas). This swelling will resolve with systemic antifungal treatment and should not be surgically drained. When severe this can lead to a scarring alopecia.

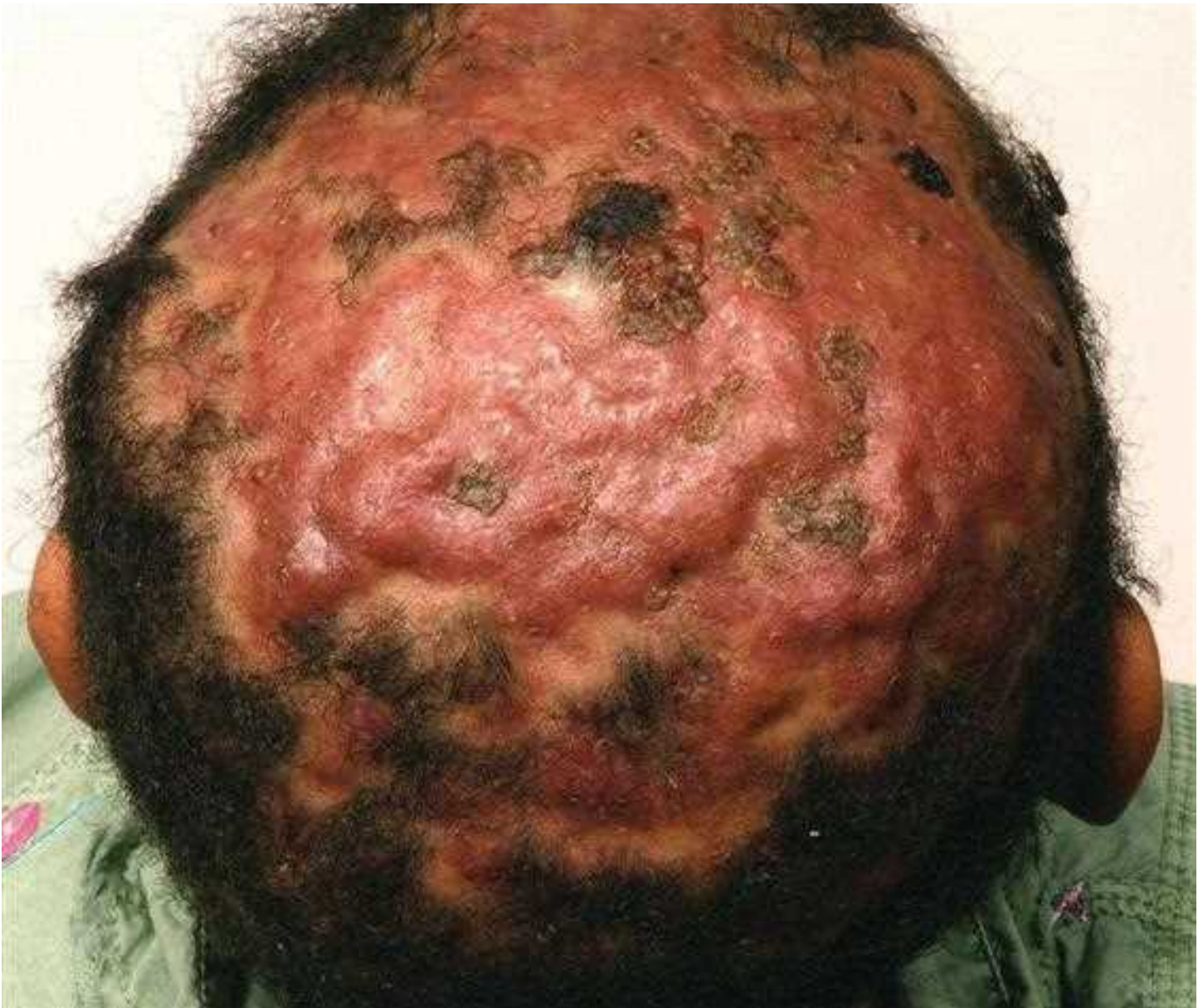

Figure 19.9 Kerion.

Oral griseofulvin or terbinafine may be given daily for four to six weeks. Secondary bacterial infection should be treated with appropriate antibiotics (usually flucloxacillin to cover for *Staphylococcus aureus*). If infection is due to *M. canis*, itraconazole treatment is superior to terbinafine and it is important that the affected pet is also treated.

Scarring alopecias

Scarring alopecias are characterised by permanent hair loss due to replacement of hair follicles by scar tissue. Scarring alopecia may be primary or secondary, depending on whether the hair follicle acts as the primary target or is damaged incidentally by non-follicular targeted events. Permanent alopecia may also occur in conditions not traditionally classified as scarring processes such as in traction alopecia or trichotillomania in which follicular drop-out may occur with chronicity.

Primary causes

These are best considered according to the underlying pathological process, particularly the type of inflammatory cell that predominates. A skin biopsy can be very helpful in establishing a diagnosis.

Lymphocytic disorders

Discoid lupus erythematosus and lichen planopilaris are both causes of scarring alopecia associated with a lymphocytic inflammatory infiltrate histologically. Both conditions may present either just localised to the scalp or have wider cutaneous or systemic involvement.

Discoid lupus presents with patches or plaques erythema, scaling and the presence of follicular plugging ([Figure 19.10](#)). Atrophy, volume loss, and dyspigmentation may occur with time.

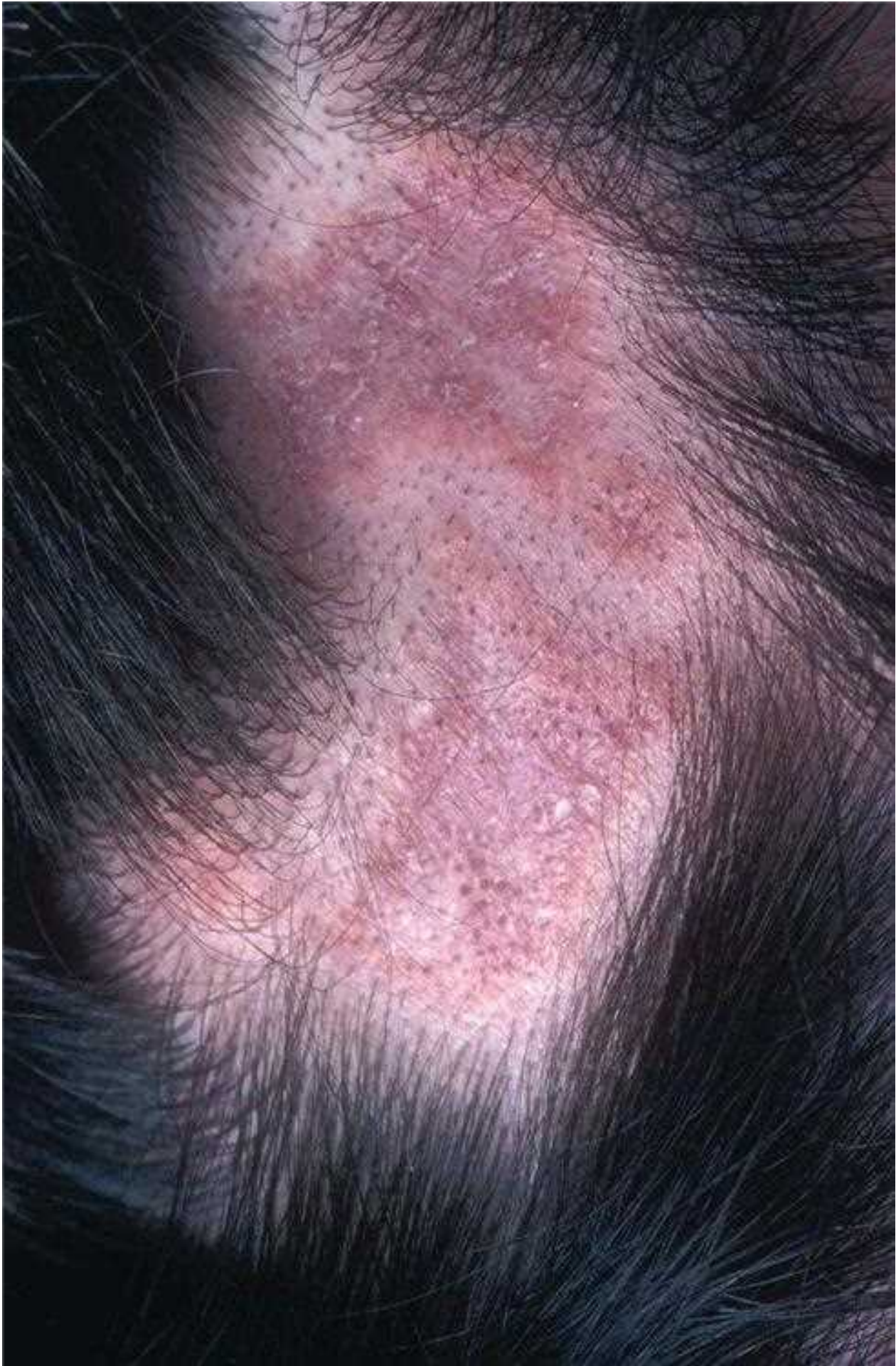

Figure 19.10 Discoid lupus erythematosus.

Classic lichen planopilaris is characterised clinically by central or multifocal perifollicular erythema and hyperkeratosis, usually at the hair margin of an alopecic patch ([Figure 19.11](#)). Frontal fibrosing alopecia is an increasingly prevalent variant, which affects predominantly postmenopausal women. This is characterised by progressive frontotemporal recession associated with complete or partial alopecia of the eyebrows and body hair. The body hair loss may precede the scalp loss by many years.

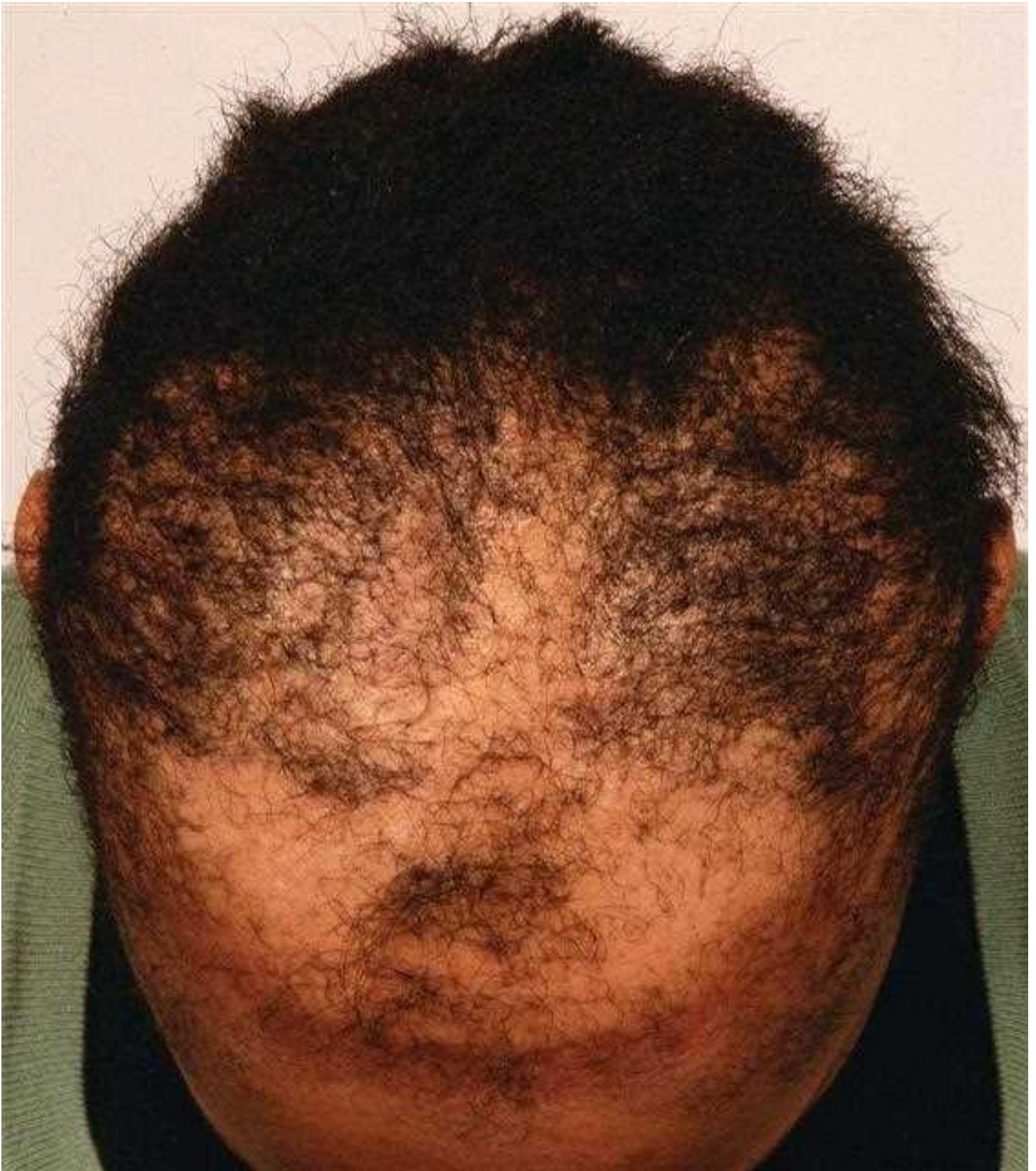


Figure 19.11 Lichen planopilaris.

A skin biopsy with direct immunofluorescence is helpful in confirming the underlying diagnosis in those patients where there is doubt about the diagnosis. Treatment options include topical, intralesional or systemic corticosteroids, oral antimalarials, retinoids, or systemic immunosuppressants.

Pseudopelade of Brocq is the label given to patients with a non-inflammatory scarring alopecia on the central scalp ([Figure 19.12](#)) in the absence of any other underlying pathology on biopsy. It is indistinguishable from end-stage lichen planopilaris.

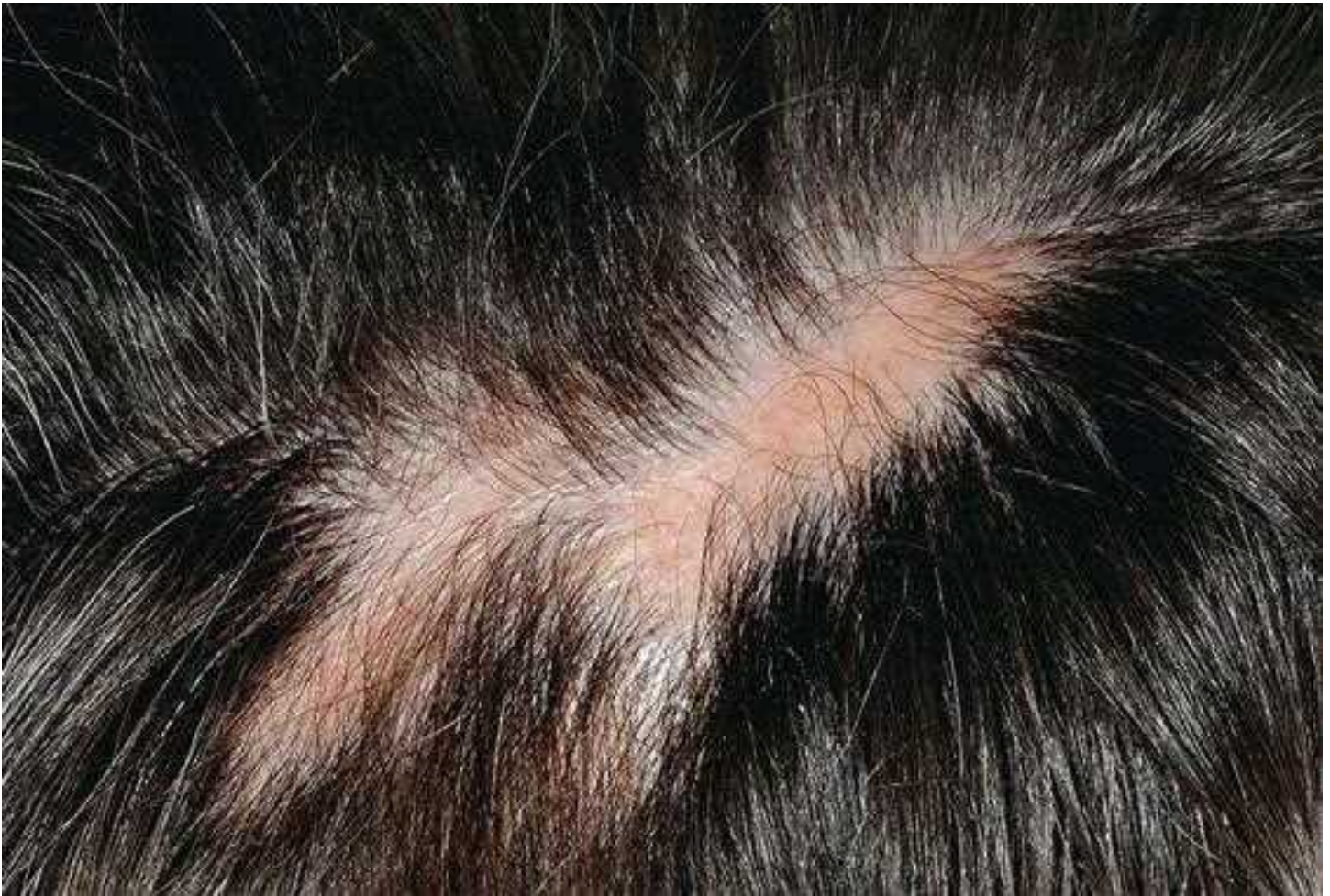

Figure 19.12 Pseudopelade of Brocq.

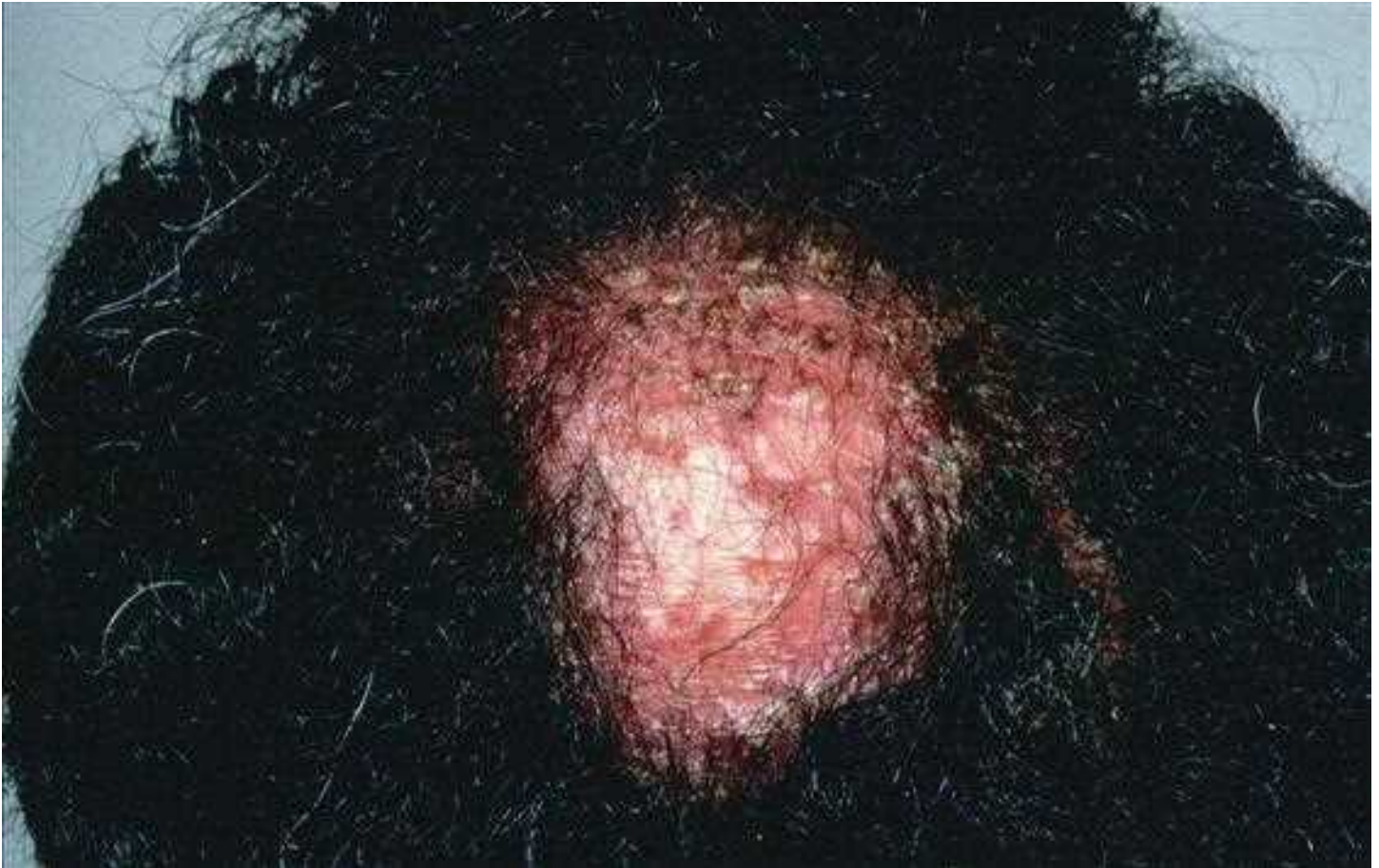Central centrifugal cicatricial alopecia (CCCA) is seen in women of African descent. It commonly presents with asymptomatic loss in the mid scalp or vertex and progressively enlarges centrifugally. It is associated with hot comb and chemical relaxant; however, a definite causal link has not been established. The condition may progress despite cessation of these practices; however, cessation is encouraged. Topical steroids and tetracycline antibiotics can be considered. Traction alopecia is a non-inflammatory scarring alopecia usually presenting with frontal or temporal hair loss. Hair styling resulting in chronic tight pulling of the hair, for example, tight braiding, weaves, or pony tails is causative and can result in permanent hair loss over time.

Neutrophilic disorders

Dissecting folliculitis presents with multiple recurrent boggy nodules, typically on the vertex or occiput, which frequently discharge purulent exudate. Superficial pustules are often seen during active episodes. This condition is mostly seen in young men of African descent and may be associated with acne and hidradenitis suppurativa. Treatment options include oral

antibiotics (usually tetracyclines), oral corticosteroids, dapsone, and isotretinoin.

Folliculitis decalvans is a rare form of chronic folliculitis which is characterised by follicular postulation, exudative crusting and tufting (multiple hairs emerge from a single follicle) ([Figure 19.13](#)). Invariably *S. aureus* is detected and topical and oral antibiotics with antistaphylococcal activity form part of the therapy. Rifampicin 300 mg twice daily and clindamycin 300 mg twice daily for 12 weeks can be helpful, though antiseptic shampoos and topical steroids are required with these and other antibiotics.



[Figure 19.13](#) Folliculitis decalvans.

Secondary causes of scarring alopecia

Many secondary causes of scarring alopecia exist ([Table 19.2](#)). Treatment is directed at the cause.

Table 19.2 Causes of scarring alopecia.

| |
|---|
| <i>Primary</i> |
| Lichen planopilaris |
| Discoid lupus erythematosus |
| Pseudopelade of Brocq |
| Central centrifugal cicatricial alopecia and traction |
| Dissecting folliculitis |
| Folliculitis decalvans |
| <i>Secondary</i> |
| Post-traumatic |
| Burns |
| Radiotherapy |
| Neoplasia (e.g. squamous cell carcinoma, lymphoma, and sarcoma) |
| Infection |
| Bacterial (e.g. folliculitis, acne keloidalis and syphilis) |
| Viral (e.g. herpes zoster) |
| Fungal (e.g. with kerion formation) |

Excessive hair

Excessive hair growth is common in women with more than 40% of women experiencing unwanted hair during their lifetime. Two patterns of hair overgrowth are recognised: hirsutism and hypertrichosis.

Hirsutism

This is defined as increased growth of the terminal hairs in androgen-sensitive areas such as the face, upper back, shoulders, and upper abdominal regions in females ([Figure 19.14](#)). The presence of terminal hair in a male distribution is not necessarily a sign of disease, and the determination of whether a patient has hirsutism must take into account the normal pattern of hair growth for the patient's racial origin. The patient's cultural and social background plays a major factor in determining how much facial and body hair is cosmetically acceptable.

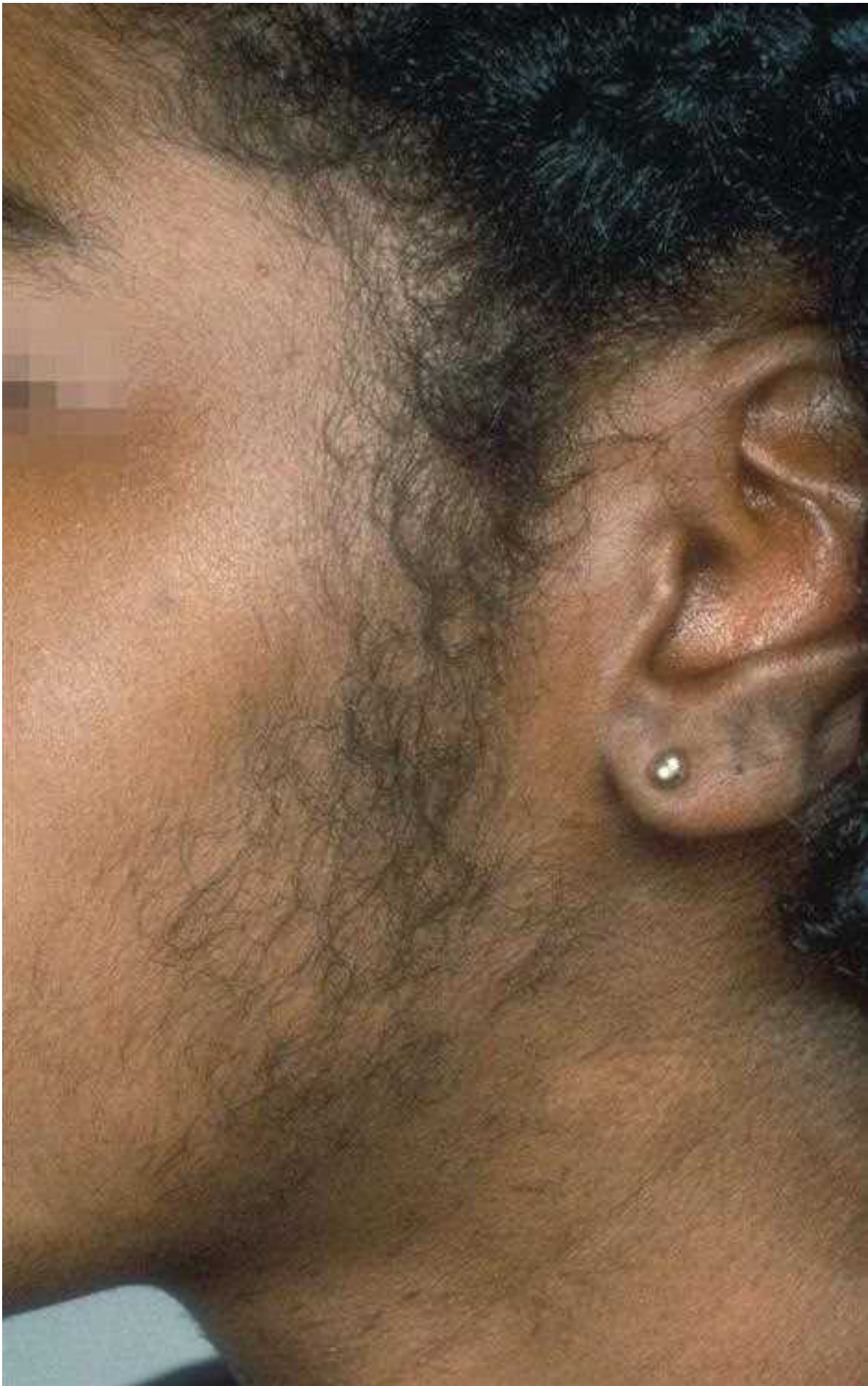

Figure 19.14 Hirsutism.

The assessment of the patient with hirsutism must include a history and examination to identify an underlying androgen/endocrine abnormality. Acne, seborrhea, alopecia, amenorrhoea, and signs of virilisation are important to consider. A list of the causes of hirsutism is given in [Table 19.3](#).

Table 19.3 Causes of hirsutism.

| |
|--|
| <i>Ovarian</i> |
| Polycystic ovarian syndrome |
| Ovarian tumours |
| <i>Adrenal</i> |
| Congenital adrenal hyperplasia |
| Cushing's disease |
| <i>Central</i> |
| Prolactinoma |
| <i>Androgen therapy</i> |
| Idiopathic (racial and familial, with a wide spectrum of normal variation) |

Management

While racial hypertrichosis is most common, pathologically more than 90% of premenopausal patients with hirsutism will have polycystic ovarian syndrome. Investigations should include a free androgen index and total testosterone. If the latter is normal idiopathic hirsutism is more likely but does not rule out androgen excess from another origin. Virilisation or rapid onset of symptoms should prompt more detailed investigation.

Treatment is aimed at addressing the underlying cause. Cyproterone acetate, drospirenone containing COCPs, and spironolactone are all commonly used. Topical eflornithine has been shown to reduce the unwanted facial hair and works synergistically with laser hair removal. Physical and chemical epilation, electrolysis, and laser epilation are commonly used methods for removal of unwanted hair. The 755 nm alexandrite and 800 nm diode laser are commonly used devices in women with Fitzpatrick I-III/IV skin types, but the 1064 nm Nd:YAG is preferred for women with darker skin types. Intense pulse light (IPL) treatment is an additional option. Dark hair on fair skin is optimal and blond, red and white hairs are not effectively removed with laser treatment.

Hypertrichosis

This describes the excessive growth of hair in any part of the body and may be localised (e.g. Becker's naevus) or generalised ([Figure 19.15](#)). Causes may be congenital or acquired;

important systemic diseases associated with hypertrichosis include hyperthyroidism, porphyria, and anorexia nervosa. Drugs which commonly cause hypertrichosis are listed in [Table 19.4](#).

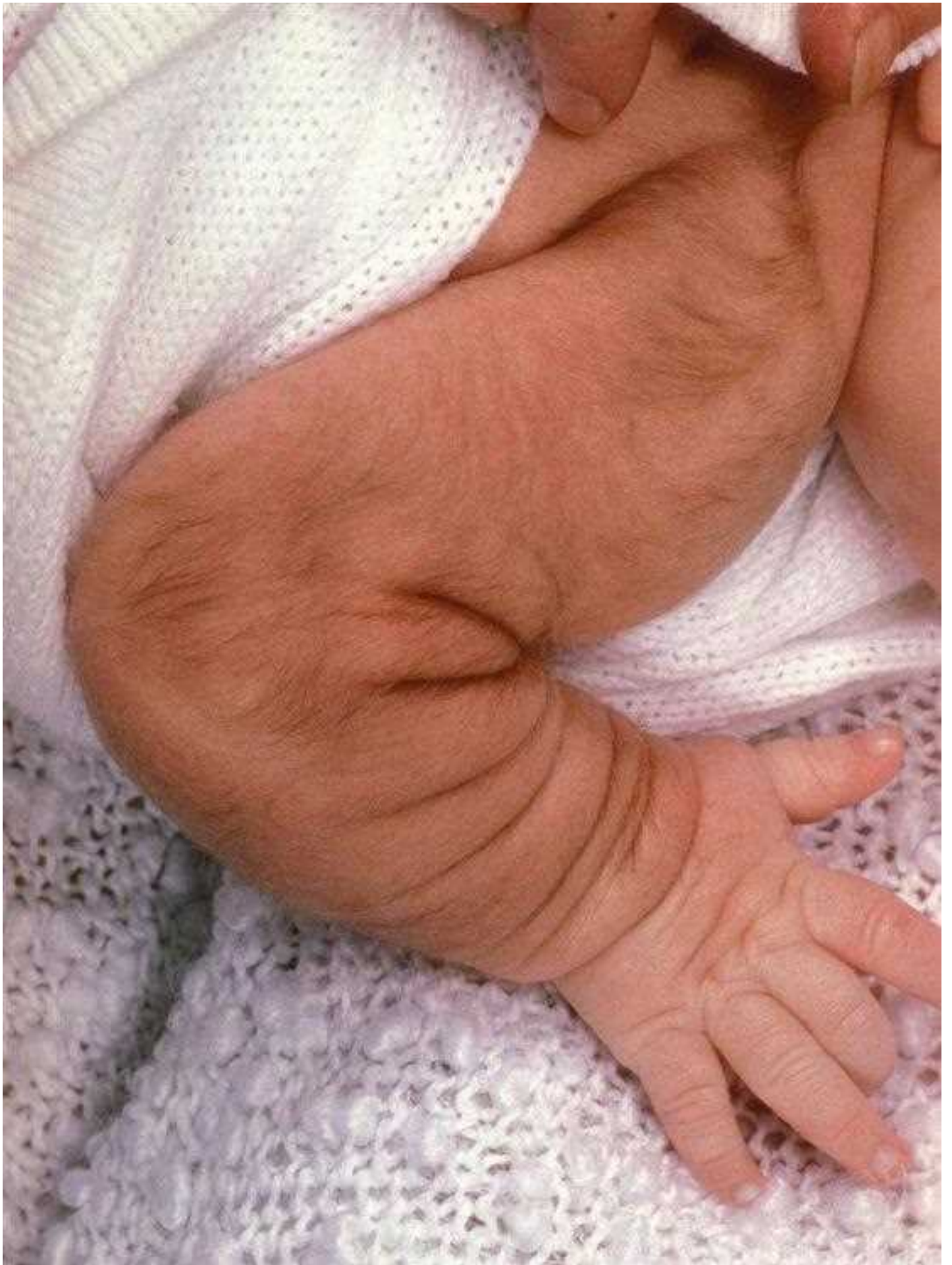

Figure 19.15 Hypertrichosis.

Table 19.4 Hypertrichosis due to drugs.

| |
|---------------|
| Streptomycin |
| Ciclosporin |
| Minoxidil |
| Diazoxide |
| Phenytoin |
| Penicillamine |
| Psoralens |

Treatment is directed at the underlying cause and stopping any implicated drug, where possible. Symptomatic approaches include depilation using creams, shaving, and waxing.

Cosmetic hair growth

Eyelash growth can be cosmetically enhanced using bimatoprost or latanoprost ophthalmic solutions, which are both prostaglandin analogues. Continued use required to maintain benefit and adverse effects include lowering of intraocular pressure and pigmentation of the eyelids or iris.

Skin disease involving the scalp

Scalp involvement is a prominent feature of numerous skin conditions. The most common inflammatory dermatoses with scalp involvement are psoriasis and seborrhoeic dermatitis ([Figures 19.16](#) and [19.17](#)). Reassuringly, these conditions are rarely associated with permanent hair loss. Both are chronic conditions and may require maintenance therapy. Patients with scalp psoriasis benefit from combination treatments including coal tar (shampoos), topical steroids (+/- vitamin D analogues) and preparations to lift the adherent scalp such as oil or salicylic acid pomades. Systemic treatments are seldom required for scalp involvement.

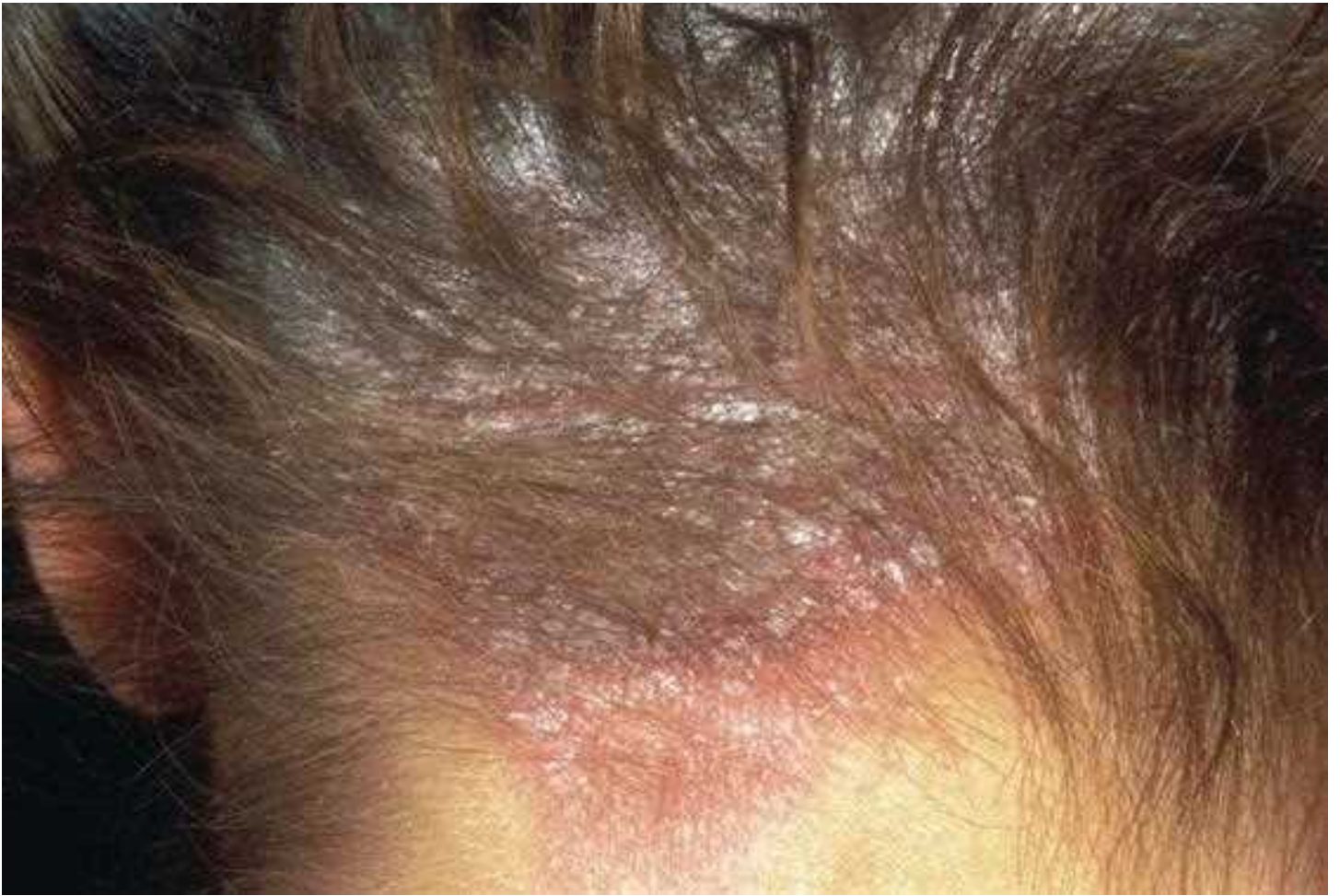

Figure 19.16 Scalp psoriasis.

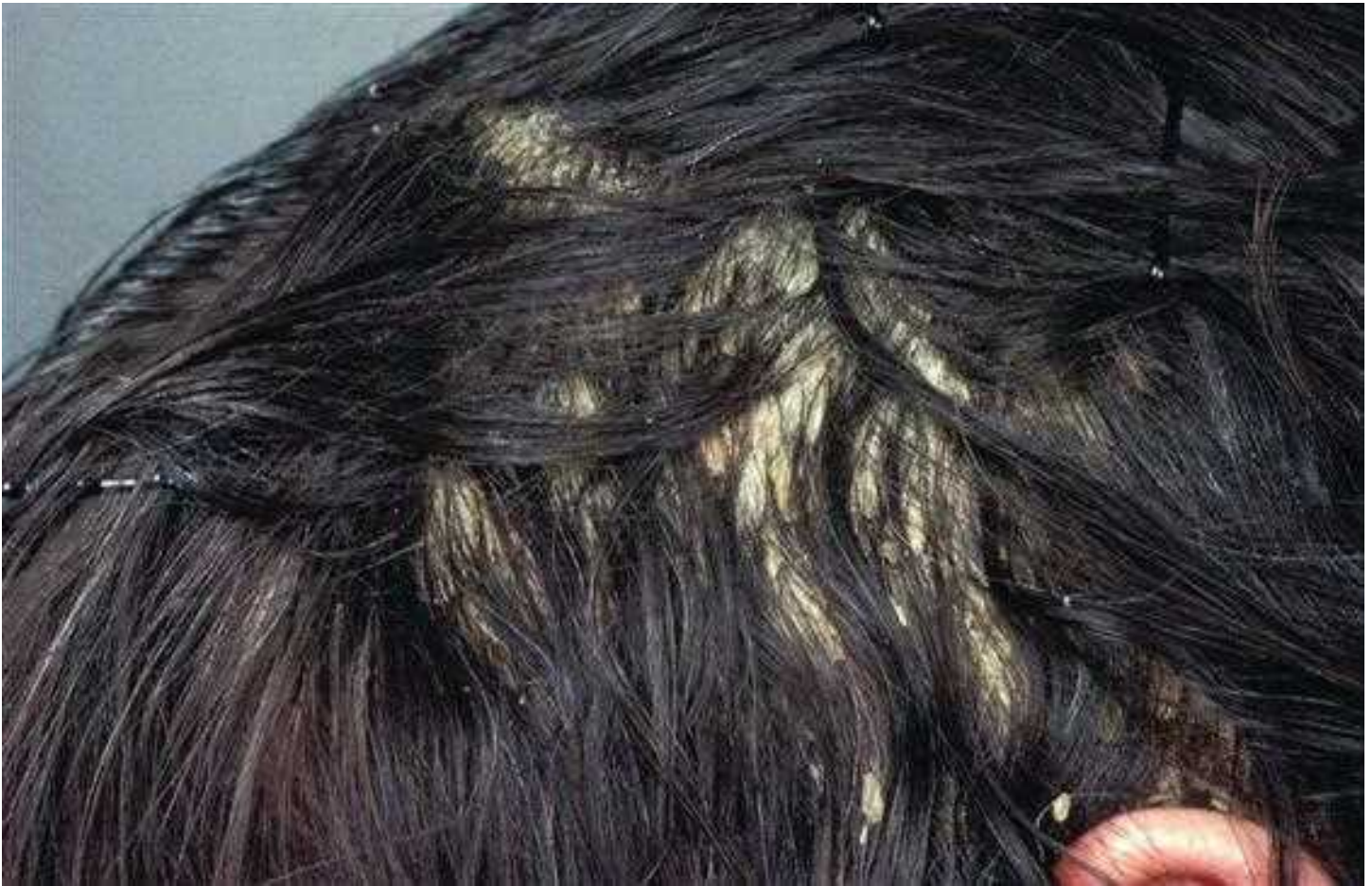

Figure 19.17 Pityriasis amiantacea.

Seborrhoeic dermatitis is probably due to an altered host immune response to commensal *Malassezia* yeast. This causes erythema and scaling of the scalp. Seborrhoeic dermatitis often responds to shampoos containing ketoconazole or zinc pyrithion. Topical steroids may be required in more inflammatory cases.

Atopic eczema, allergic contact dermatitis commonly to paraphenylenediamine (PPD) found in black hair-dye and immunobullous disorders such as pemphigus vulgaris may also involve the scalp.

Further reading

Dawber, R.P.R. and Van Neste, D. (2004). *Hair and Scalp Disorders: Common Presenting Signs, Differential Diagnosis and Treatment*, 2e. London: Taylor and Francis.

McMichael, A.J. and Hordinsky, M.K. (2008). *Hair and Scalp Diseases: Medical, Surgical and Cosmetic Treatments (Basic and Clinical Dermatology)*. New York: Informa Health-care.

CHAPTER 20

Diseases of the Nails

David de Berker

United Bristol Healthcare Trust, Bristol, UK

OVERVIEW

- Nails are ectodermal derivatives composed of keratin which grow forward from a fold of epidermis over the nail bed. Fingernails grow at approximately 1 mm/week and toenails 1 mm/month.
- The attachment of the nail plate to the underlying nail bed can be affected by excess keratin, inflammatory changes, or infection, which causes the nail plate to lift: onycholysis.
- Thickening of the nail plate may occur as a result of inflammatory, traumatic, and infective conditions.
- Transverse ridges are seen in psoriasis and eczema. Beau's line is a transverse depression affecting most of the nails due to a severe illness or physiological stress.
- Changes in the shape of the nail include clubbing, which is due to swelling and increased vascularity of the tissues surrounding the nail. Koilonychia is a 'spoon-shaped' deformity of the nail that may be associated with iron deficiency.
- Infection and inflammation adjacent to the nail results in paronychia that may be acute or chronic.
- Colour changes in the nail can arise through alteration of the nail bed or the nail plate and sometimes both. These include leukonychia (whitening of the nails) and black discolouration from subungual bleeding.
- Longitudinal brown streaks often occur in those with racially pigmented skin. In Caucasians, isolated brown streaks in the nail may be due to a dysplastic naevus, and involvement of the nail fold suggests a subungual melanoma.

Introduction

In humans, the main function of the nails is to protect the distal soft tissues of the fingers and toes from the physical trauma of everyday life.

The nail is derived from the ectoderm and is largely composed of keratin ([Figure 20.1](#)). The nail plate grows forward from a fold of epidermis over the nail bed, which is continuous with the matrix (lunual or half moon) proximally. Nail keratin is derived mainly from the matrix

with contributions from the dorsal surface of the nail fold and the nail bed.

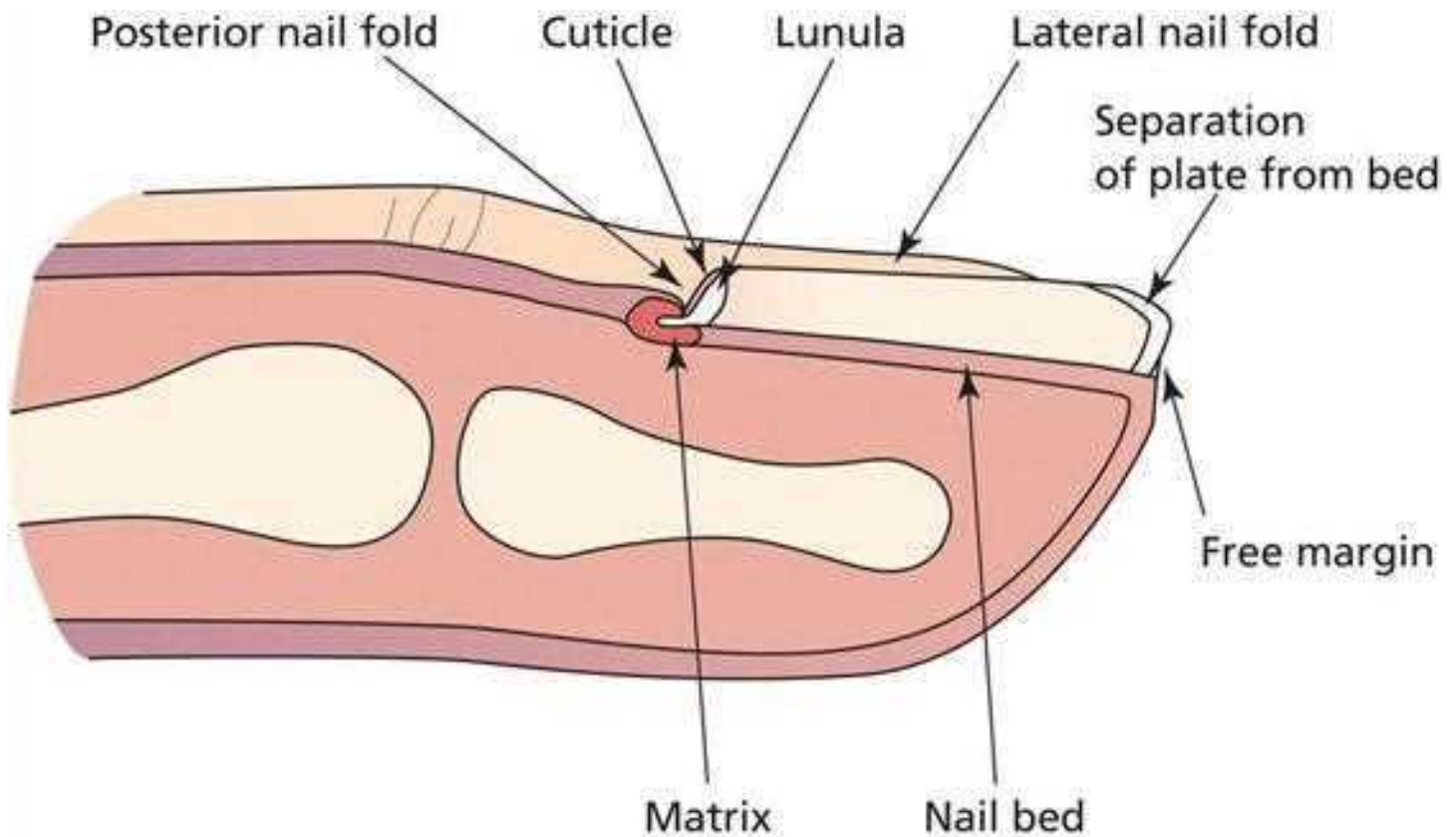


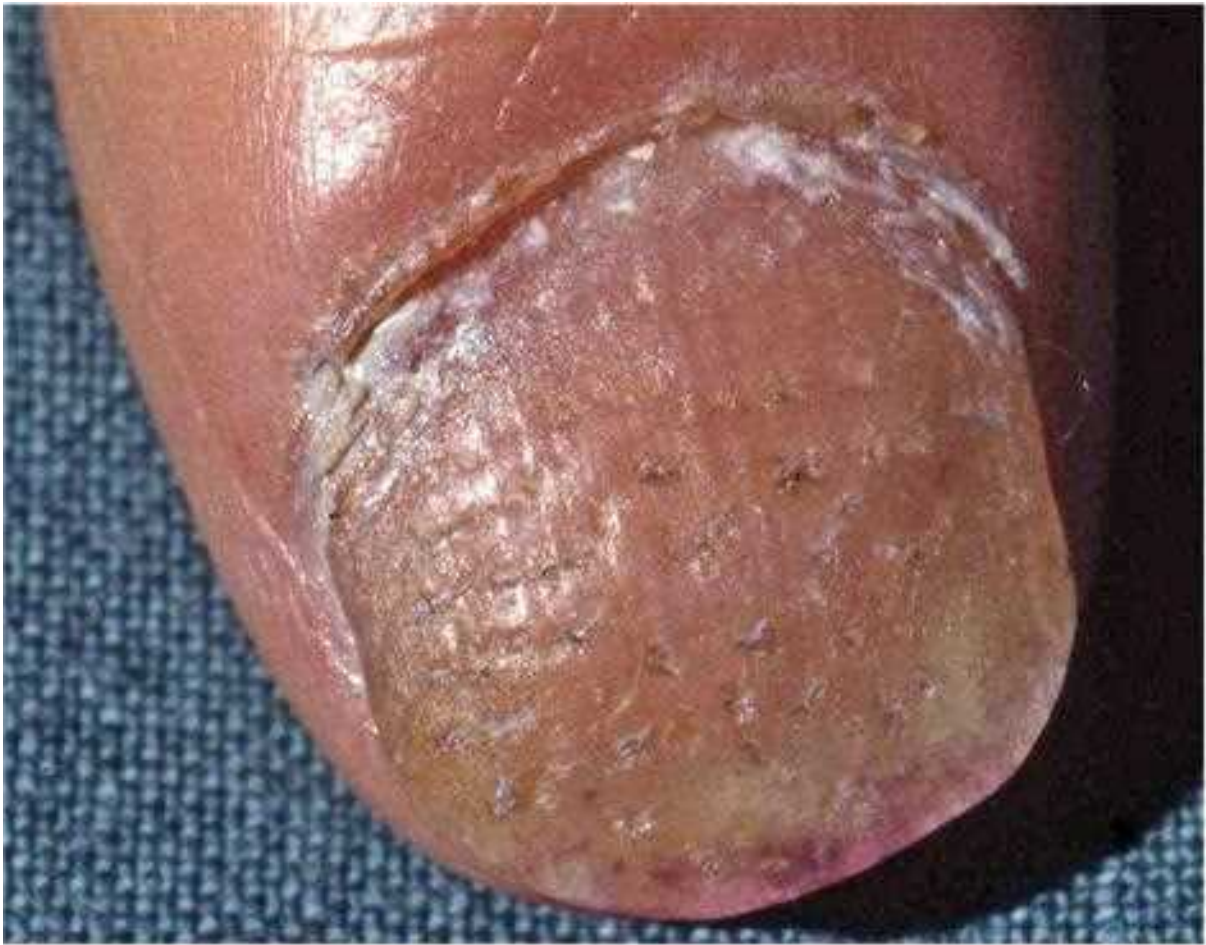Figure 20.1 Section through finger.

The nail grows slowly for the first day after birth and then more rapidly until it slows in old age. The rate of nail growth is greater in the fingers than the toes, particularly on the dominant hand. It is slower in women but increases during pregnancy. Fingernails grow at approximately 0.8 mm/week and toenails 0.25 mm/week.

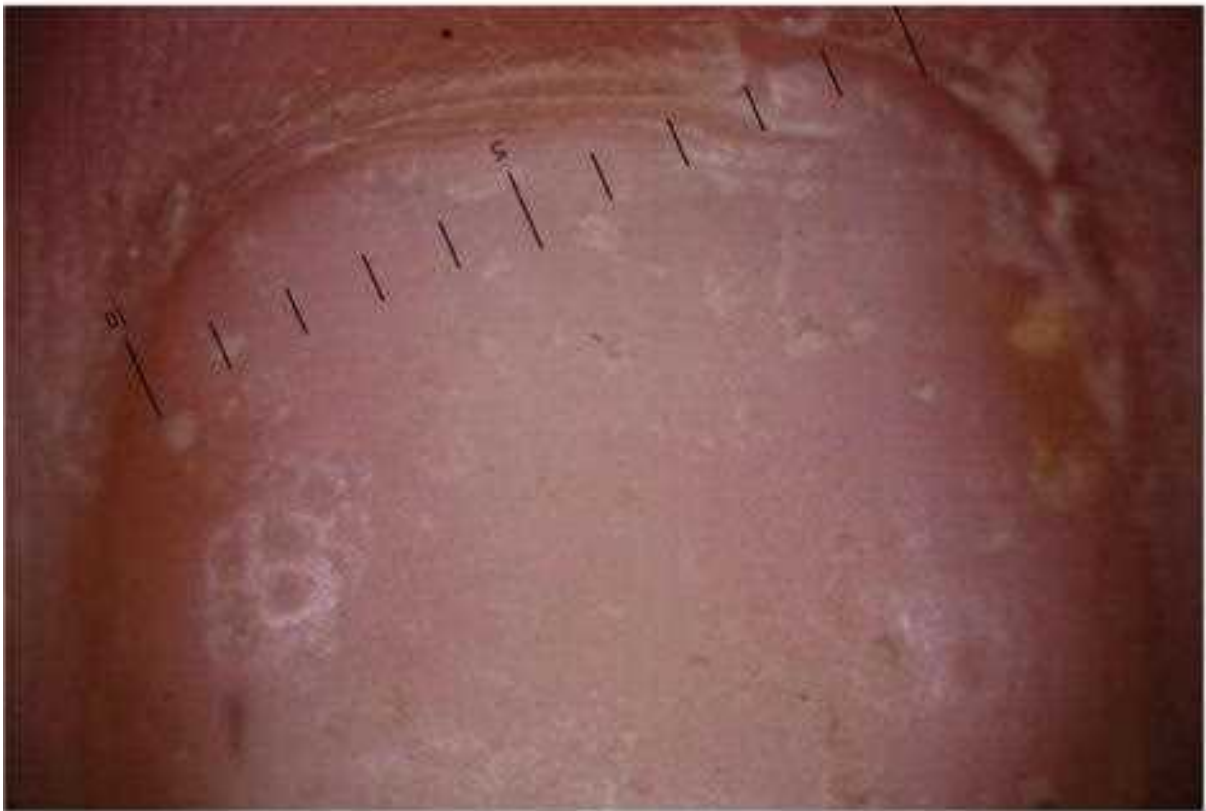Changes of shape, surface, and attachment

Pitting

This is seen clinically as small surface depressions of the nail plate that result from a loss of the parakeratotic scale such as occurs in psoriasis ([Figure 20.2a,b](#) showing nail pitting and appearances with a dermatoscope). The scale develops through inflammatory diseases affecting the proximal nail matrix including psoriasis, eczema, lichen planus, and alopecia areata.



(a)



(b)

[Figure 20.2](#) (a) Pitting of nail and (b) pitting of nail appearance with dermatoscope.

Subungual hyperkeratosis

Where scaling occurs beneath the nail in the distal nail bed, the compacted scales build up to produce dense subungual hyperkeratosis. This is most commonly seen in psoriasis, eczema, and fungal nail disease. In the toes, it may be part of a reaction to trauma or generalised hyperkeratosis.

Oily spot

This sign is specific to psoriasis and reflects the presence of a patch of psoriasis in the nail bed with no connection to the free edge. There is a small pool of discolouration of the nail, giving an oily appearance.

Onycholysis

Nail plate attachment to the nail bed may partially or completely be lost. This can be due to an inflammatory, neoplastic, traumatic, or infective process of the nail bed, altering its biological function and nail plate attachment. Acute trauma usually settles with re-adherence. Forms of chronic trauma include manicure where the person uses a sharp instrument to remove subungual debris from beneath the nail ([Figure 20.3](#)). This form of trauma may be a sole cause of onycholysis or may be a factor in association with a skin disease, such as psoriasis. Systemic causes of onycholysis include thyrotoxicosis.

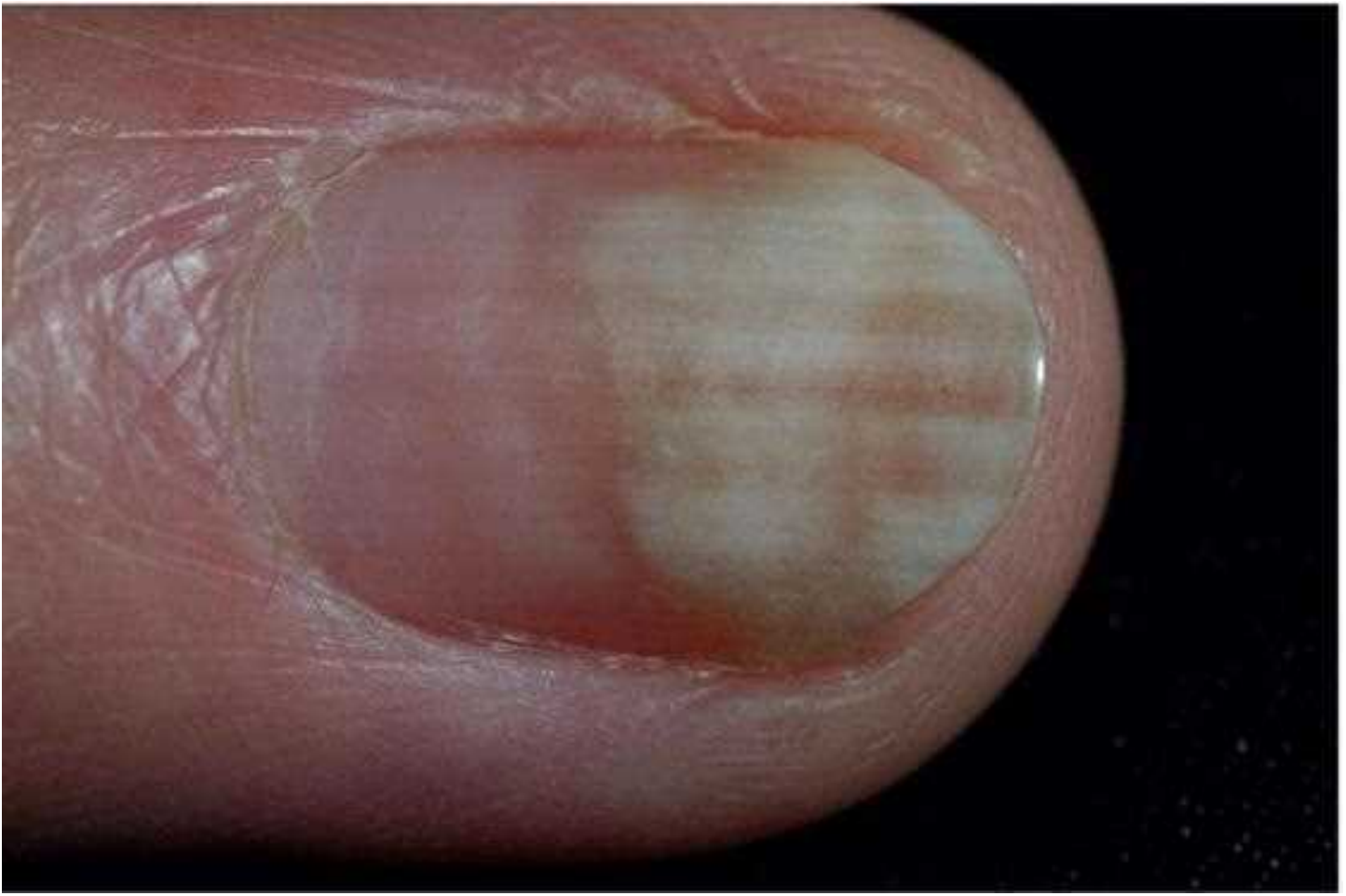

Figure 20.3 Onycholysis due to manicure beneath the nail.

Chronic onycholysis becomes vulnerable to secondary infection with microbes that thrive in warm damp spaces. These are mainly *Candida* spp. and *Pseudomonas pyocyanae*. Such microbes may contribute to the persistence of the split from the nail bed and will increase discomfort and malodour.

Nail plate thickening

The nail plate thickens and becomes yellow in a wide range of diseases and also as part of normal ageing on the toes. Eczema, psoriasis, lichen planus, and yellow nail syndrome are the main inflammatory diseases with this effect. Fungal infection can result in the same problem, although as in all the inflammatory diseases it may be possible to make a distinction between thickening due to increase of subungual keratin and thickening due to change in the nail plate ([Figure 20.4](#)). Chronic trauma can cause thickening, where the response of the nail is analogous to that of the skin in general. This is seen in hammer toe, where the free edge of the toe is directed downwards to act like a piano string hammer at each step. This force transmits back to the nail matrix and results in thickening of the nail.

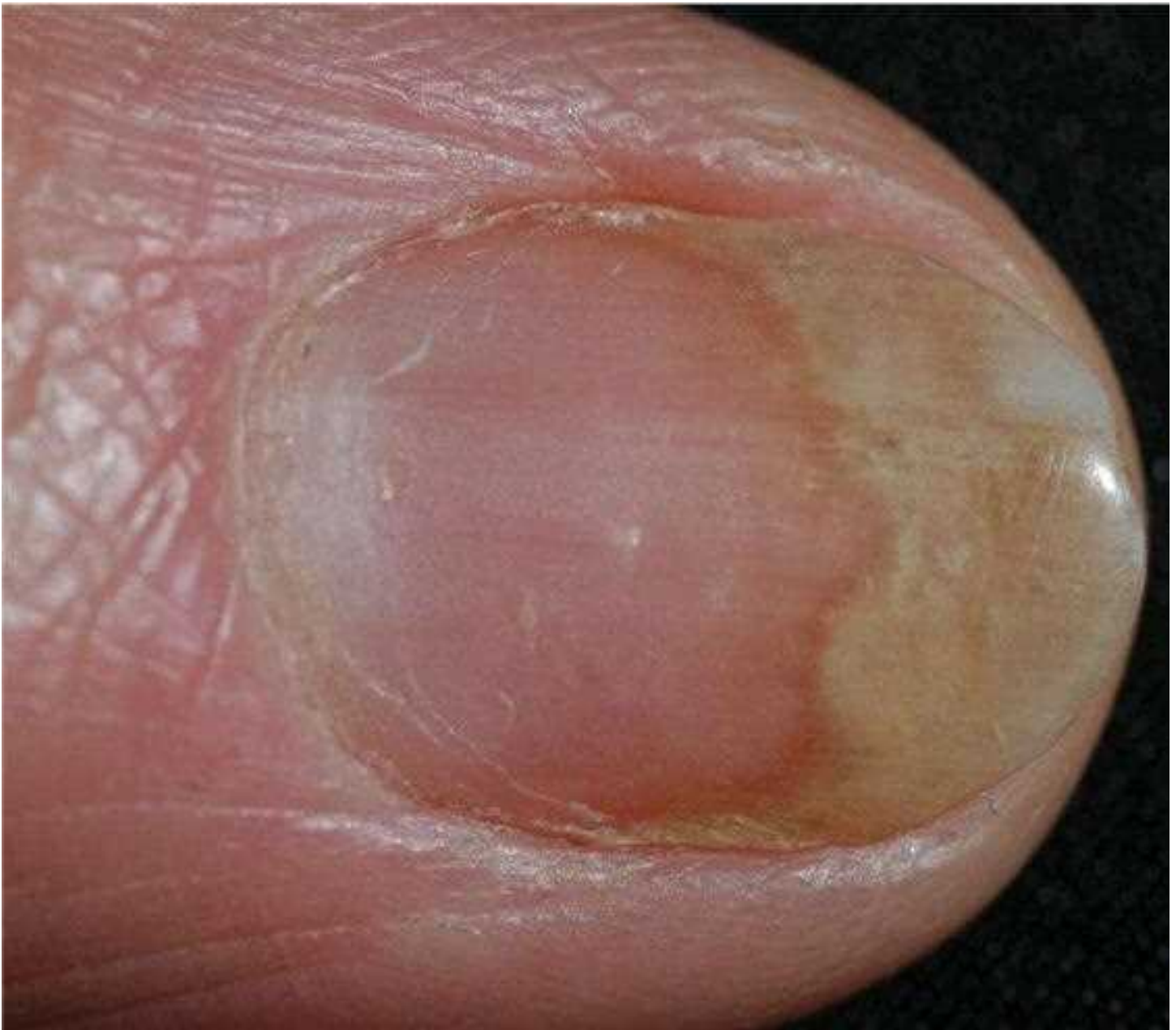

Figure 20.4 Onycholysis and hyperkeratosis of nail plate in psoriasis.

Transverse ridges

These are most commonly seen in psoriasis and eczema where there is inflammation of the proximal nail fold and secondary change of nail matrix function. Isolated digital trauma may cause a similar, but solitary, transverse ridge.

Irritant dermatitis (eczema)

This is a significant cause of chronic paronychia. Common factors are a low threshold for an irritant reaction, such as background atopy or skin problems elsewhere, in combination with an occupational irritation of the skin at the base or sides of the nail. The resulting inflammation spreads to involve the nail matrix. When further combined with damp or wet work (which is a common form of irritant) there is a disposition to secondary infection with

Candida spp.

Beau's line

A substantial general physiological disturbance can result in a solitary episode of reduced nail matrix function. If this reduction falls short of complete matrix shut down, then there is a partial-thickness transverse break in the nail plate. This will normally affect many nails at once, with subsequent nail growth marking out the time of recent disturbance such as a date in a calendar record of the preceding months. This was originally identified by Joseph Beau, a Parisian cardiologist who termed it *retrospective semiology*, from the Greek, meaning to study signs and symbols. While it is most commonly thought to be an indicator of past physiological changes, it is also seen in people who have a severe deterioration in their eczema or psoriasis as well as less common diseases, such as bullous pemphigoid.

Nail loss (onychomadesis)

Where the nail matrix inflammation is global and severe, it may be sufficient to precipitate nail shedding and interruption of nail matrix nail plate production entirely. This can be a result of severe inflammatory skin disease or an episode of trauma. The latter is particularly the case when there is substantial bleeding beneath the nail, which separates the nail from the nail bed.

Longitudinal splits

A single split on one nail with no other nail or skin disease is most likely to represent an area of focal matrix damage ([Figure 20.5](#)). This can be due to acute trauma with scarring, chronic trauma from underlying or overlying mass or a dysplastic process destroying a small area of nail matrix such that it does not produce nail. Such presentations need close examination and imaging and may require surgical exploration and sampling. Where longitudinal splits are multiple, they are usually a result of a generalised inflammatory or degenerative process. The most typical of these are lichen planus and ageing, respectively. Ageing is a non-specific process, where there is a loss of nail substance and increased fragility, giving rise to splits. These are usually only manifested in the distal few millimetres of nail. A hybrid between inflammation and degeneration is seen in the genodermatosis Darier's disease, where distal nicks in the nail may extend proximally to be markedly destructive ([Figure 20.6](#)). This is usually seen in combination with other signs specific to this disease.



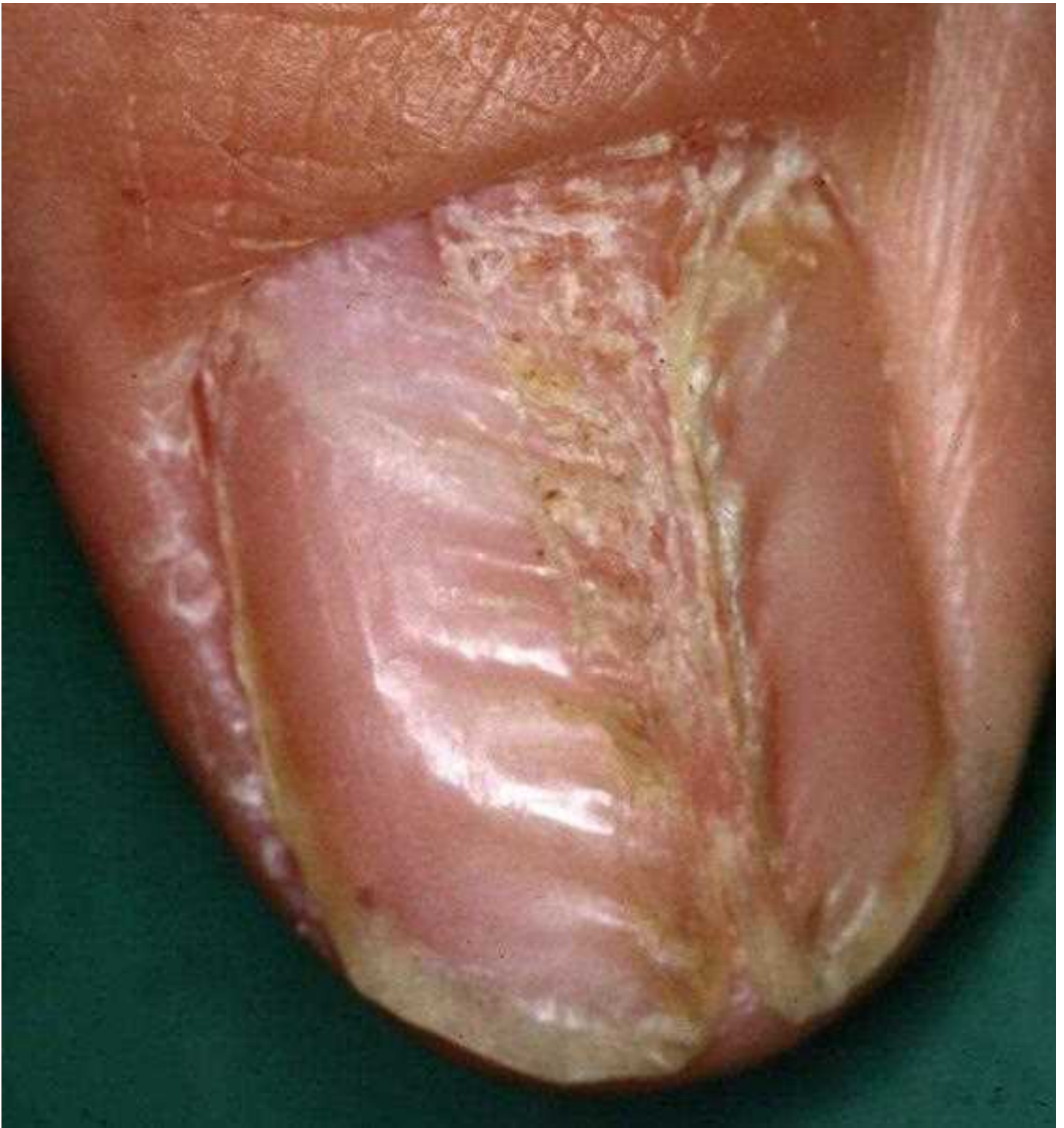
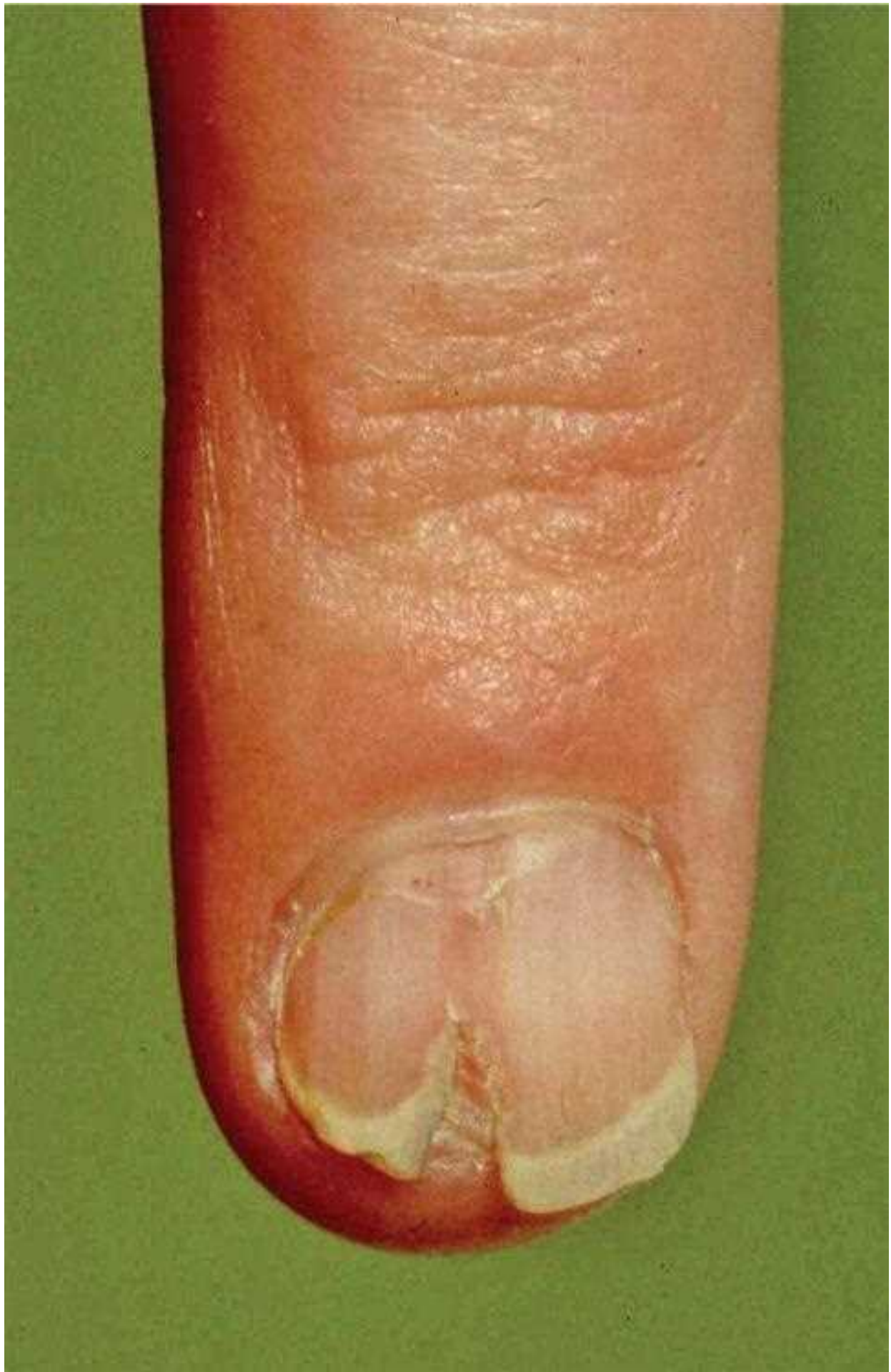
Figure 20.5 Longitudinal ridge and partial split termed canaliform dystrophy of Heller. Matrix inflammation with nail fold trauma can play a part.



[Figure 20.6](#) Darier's disease.

Transverse (lamellar) splits

This is seen in the distal section and free edge of the nail. It is most common in childhood mainly in the big toes and where there is thumb sucking. It can also be seen in middle age and beyond, probably as part of a degenerative process. It represents a loss of adherence between the lamellae of the nail plate, which is made up of a tier of over 100 cells in the vertical axis. As the nail reaches the free edge, it is vulnerable to the action of solvents penetrating the free edge and promoting loss of cohesion between the lamellae.

Pustules in the periungual skin

This is more strictly a periungual sign, but with significance to the nail. Pustules can be sterile or reflect infection. In the acute presentation, it is always wise to assume infection until proven otherwise. Infective causes are typically through minor trauma and pyogenic bacteria such as *Staphylococcus aureus* where the red and swollen digit will also have one or more pustules. This is an acute paronychia.

Herpes simplex can produce a similar appearance although the pustules are smaller, more numerous and clustered and have a vesicular character. *Candida* can also result in pus, but usually with a more indolent course. Sterile pustules are usually due to psoriasis. There may be less pain and associated inflammation than with the acute infective disease and multiple digits might be involved as well as other body sites. The pustules gradually resolve, leaving a brown residue. In some instances, sterile psoriatic pustules can affect the nail unit either as part of more generalised pustular psoriasis or as variants of palmo-plantar pustulosis or acrodermatitis or Hallopeau.

Koilonychia

This term refers to a 'spoon-shaped' deformity of the nail. This is seen in normal infants, mainly of their toenails. In older people, it may be a manifestation of iron deficiency anaemia. It is also a non-specific feature of diseases where there is atrophy of the nail unit. Where the nail plate is thin, it can dip centrally, which is seen in variants of lichen planus.

Clubbing

Clubbing is a change in the shape of the nail secondary to chronic swelling of periungual tissues with increased vasculature. There is an increase in the transverse and longitudinal curvature ([Figure 20.7](#)). At the base of the nail, where it meets the proximal nail fold, the angle with the nail fold is lost because of the swelling and the consistency is 'boggy'. It is a change due to systemic or inherited factors, which means that it affects all nails, although the changes in the toes are less obvious than in the digits of the hands. Where cyanotic heart disease or fibrotic or cavitating pulmonary disease is the underlying cause, the nail bed may be cyanosed. Idiopathic variants, or where inflammatory bowel and liver disease are causal,

can be a normal pink colour.

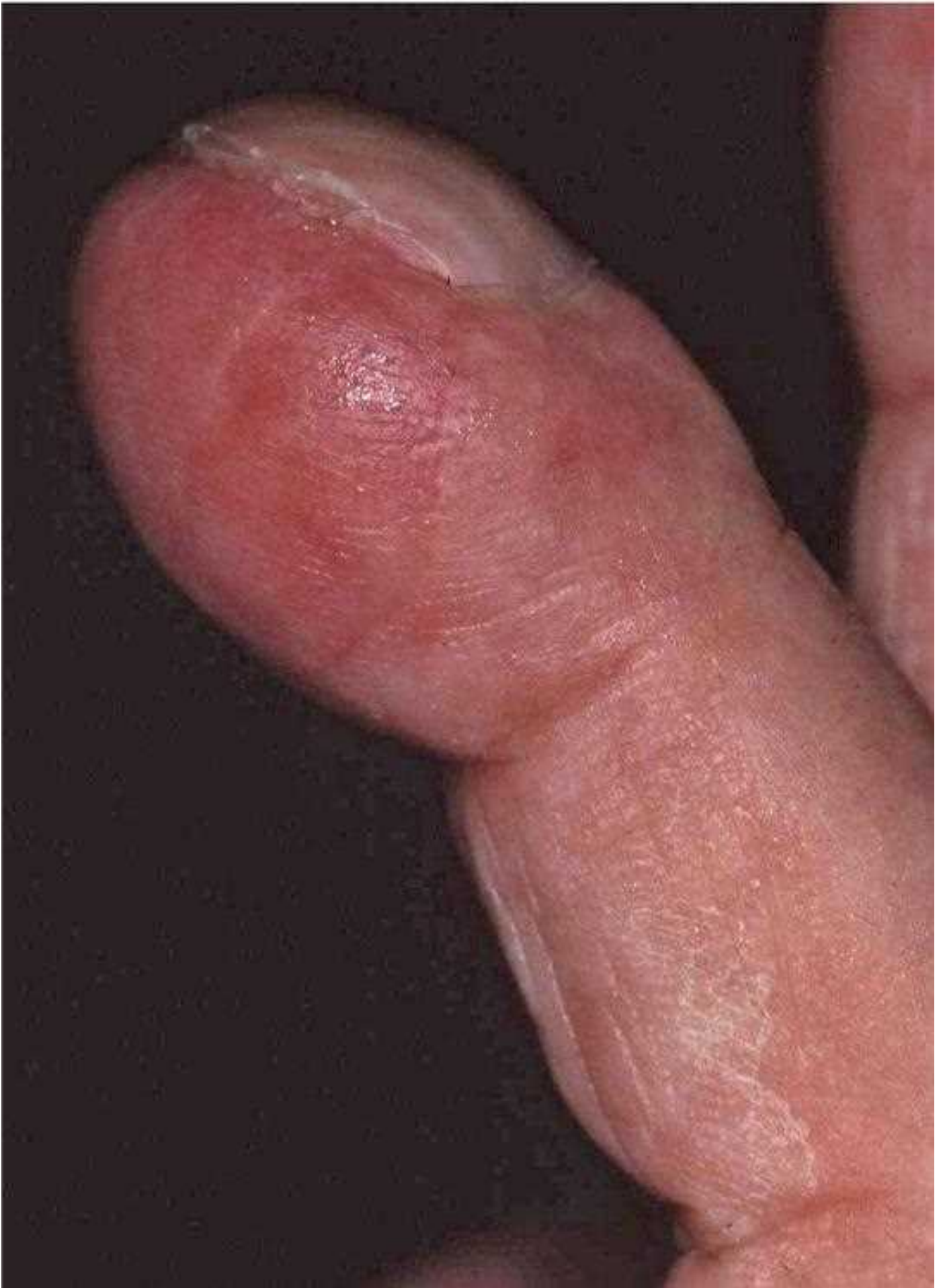

Figure 20.7 Clubbing with loss of the angle between the proximal nail fold and the base of the nail.

Changes of colour

Colour changes in the nail can arise through alteration of the nail bed or the nail plate and sometimes both. Dermoscopy is a useful tool for evaluating pigment of the nail unit.

Nail bed changes

Leukonychia

Whitening of the nail is classified according to the origin of the colour change. Apparent leukonychia ([Figure 20.8](#)) reflects changes in the vascular state of the nail bed. Most commonly, this is oedema or loss of normal vascular pigment, as seen in hypoalbuminaemia with cirrhosis of the liver. True leukonychia is where the substance of the nail plate is altered so that it appears white whether it is *in situ* or avulsed. Biologically, this comes about for two reasons.

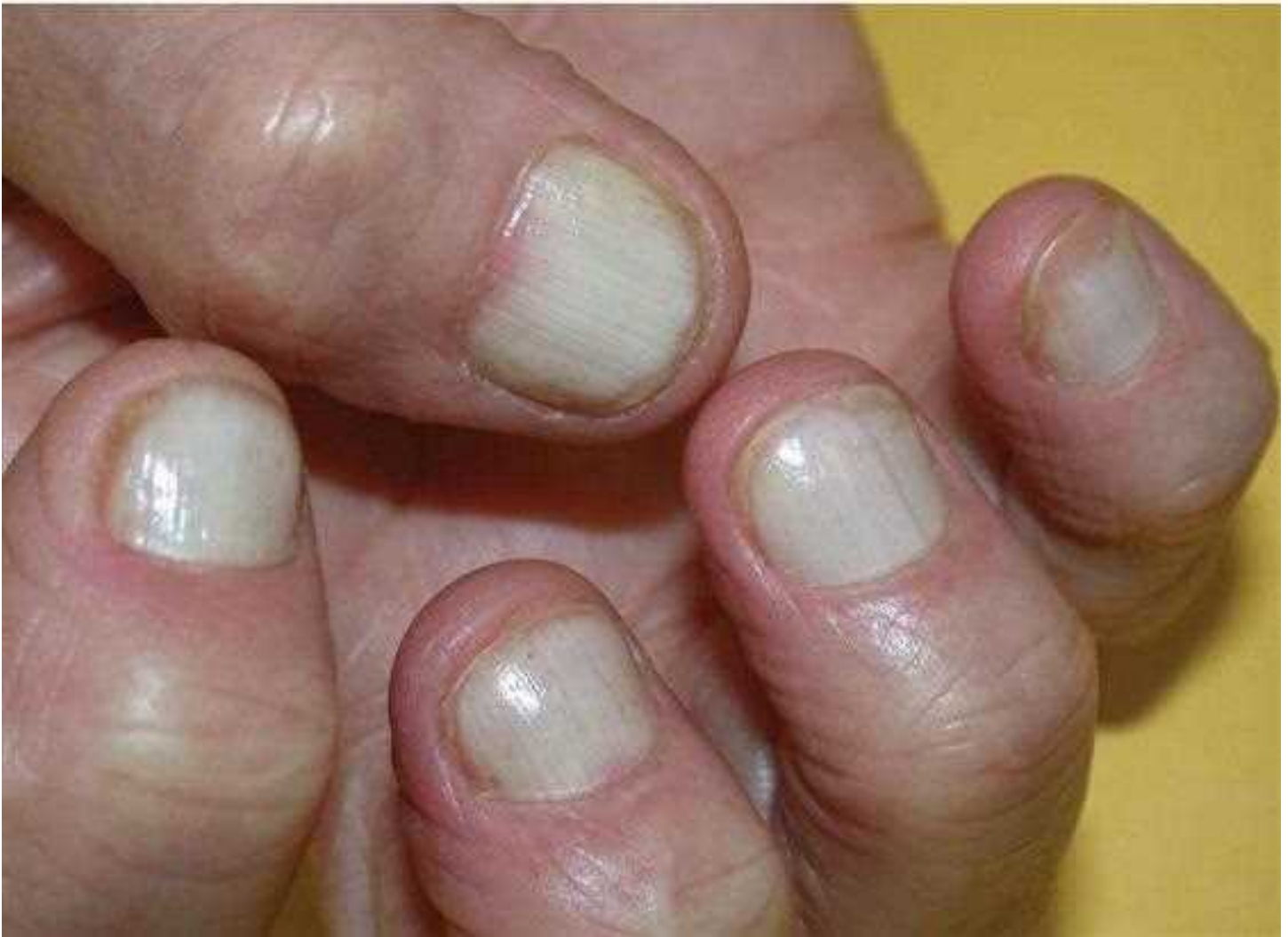

Figure 20.8 Apparent leukonychia.

Firstly, there may be alteration of the nail after it has been formed and the most common cause of this is fungal infection. Secondly, abnormal nail plate production may result in white nail. This occurs most commonly in a punctuate or transverse linear pattern, and has little significance. It does not represent lack of calcium. There is also a familial variant where the entire nail may be white.

Apparent leukonychia occurs in hypoalbuminaemia and old age.

Red lunula is seen in inflammatory joint disease, cardiac failure, blue cyanotic heart or respiratory diseases. It can fluctuate and may not represent a fixed sign.

Grey colour can be caused by mepacrine.

Purple/black discolouration results from subungual bleeding.

Nail plate changes

Patchy brown discolouration is seen in the 'yellow nail syndrome', fungal infection, and psoriasis. Drugs may cause more uniform changes in colour; for example, tetracycline may

produce yellow nails, antimalarials a blue discolouration, and chlorpromazine a brown colour.

True leukonychia is seen with fungal infection (superficial white onychomycosis), trauma, and autoimmune nail disease. Mees lines are a form of true leukonychia seen as white transverse band on the nail. They arise when poisons such as chemotherapy are administered on an intermittent basis. The rhythm and approximate timing of doses of chemotherapy can be determined by the position of the white transverse line.

Yellow nail syndrome is associated with respiratory and sinus disease. Prolonged repeated use of nail varnish causes alteration of nail keratin, termed *granulation*. This gives a yellow appearance ([Figure 20.9](#)).

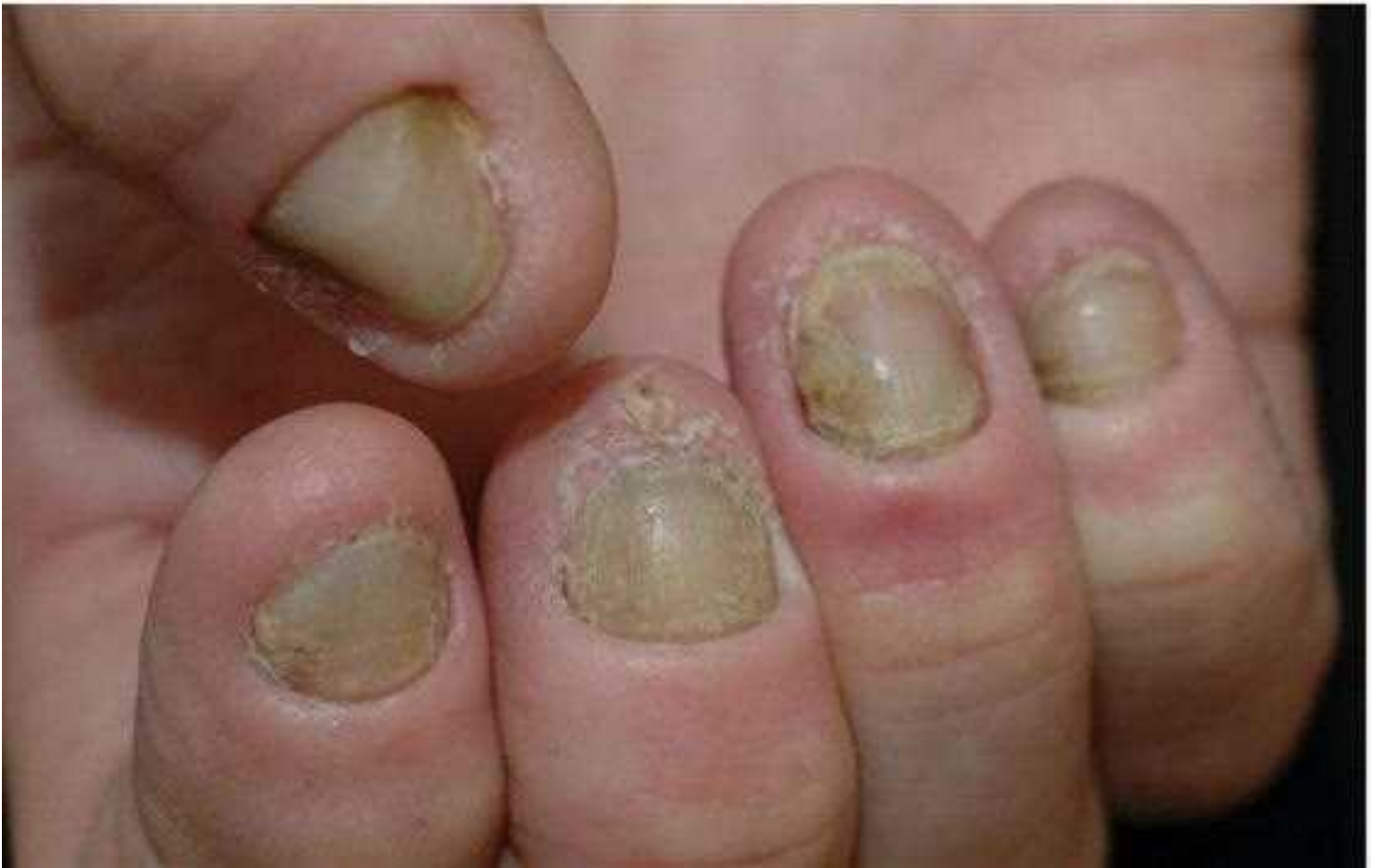

Figure 20.9 Yellow nail syndrome.

Thickened nail occurs from trauma, chronic inflammation, some dysplastic processes, or fungal infection.

Brown colour or melanonychia refers to a brown streak in the nail due to pigment production in the nail matrix ([Figure 20.10](#)). The melanin source may be benign or malignant. People with naturally dark skin often have prominent benign multiple brown streaks. If a pale-skinned person has a melanonychia, it is more exceptional and may represent a malignant process (melanoma). Slight discolouration of the nails may be seen in Addison's disease caused by adrenal insufficiency.

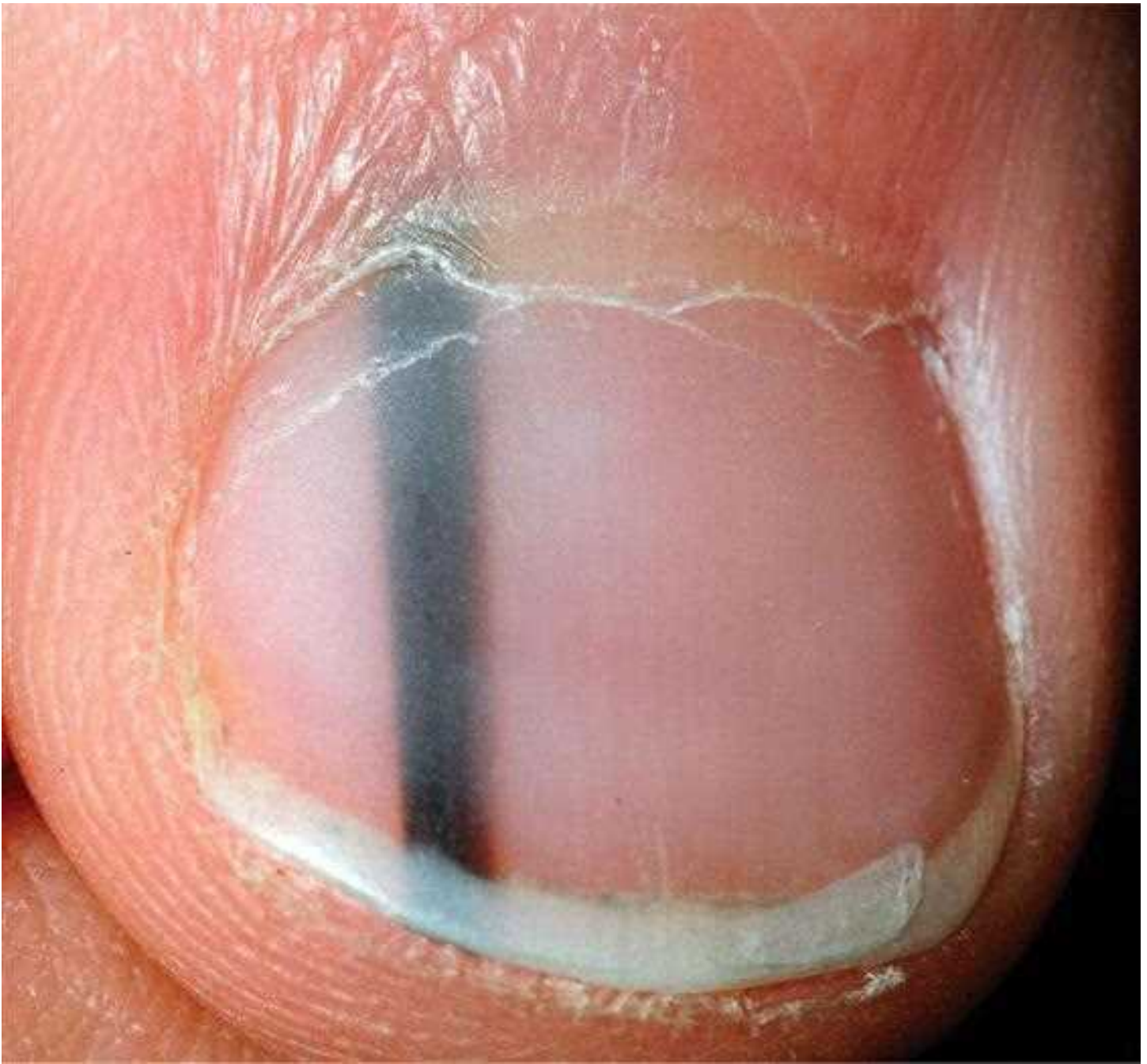


Figure 20.10 Linear melanonychia.

Minocycline and zidovudine can result in melanonychia.

Longitudinal pigmented streaks result from increased melanin deposition in the nail plate ([Box 20.1](#)).

Box 20.1 Pigmented streaks in nails

Single

Melanocytic naevi or lentigo

Subungual melanoma

Trauma

Multiple

Racial

Drugs

Addison's

Longitudinal brown streaks are frequently seen in individuals with racially pigmented skin. This is rare in Caucasians and while it may still represent a benign process it is important that isolated brown streaks in the nail of pale-skinned people are seen by a specialist for an expert diagnosis to exclude the possibility of subungual melanoma. This is associated with Hutchinson's sign, in which pigmentation extends into the surrounding tissues, particularly the cuticle. Adrenal disease may rarely be associated with longitudinal streaks.

Common dermatoses and the nail unit

Psoriasis is one of the most common dermatoses with nail involvement. About 80% of people with psoriasis will have some nail features at some point in the course of their disease. The features include pitting, transverse ridges, onycholysis, oily spots, subungual hyperkeratosis ([Figure 20.11](#)), and chronic paronychia. At times, disease may be sufficiently severe as to result in loss of function through pain and the inability to sustain pressure or undertake fine manipulation.

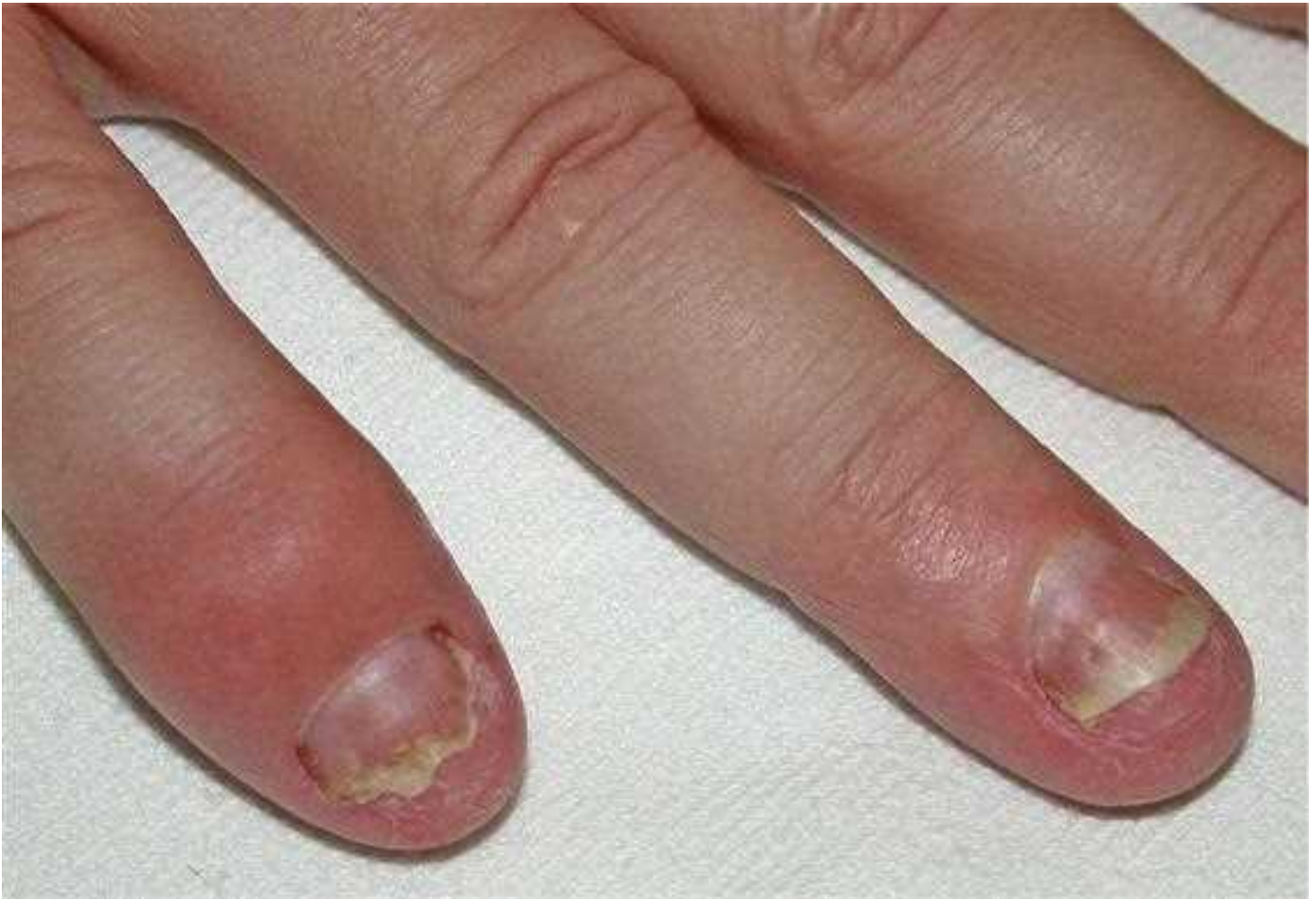

Figure 20.11 Nail psoriasis with onycholysis, pitting, and arthritis of the distal interphalangeal joint of the little finger.

Eczema may be associated with brittle nails that tend to split. Thickening and deformity of the nail occurs in eczema or contact dermatitis, sometimes with transverse ridging. Pitting can also be seen. Nail bed changes are less common than in psoriasis, although allergic contact sensitivity where allergen is sequestered beneath the nail can produce dramatic acute and chronic nail bed disease ([Figure 20.12](#)).

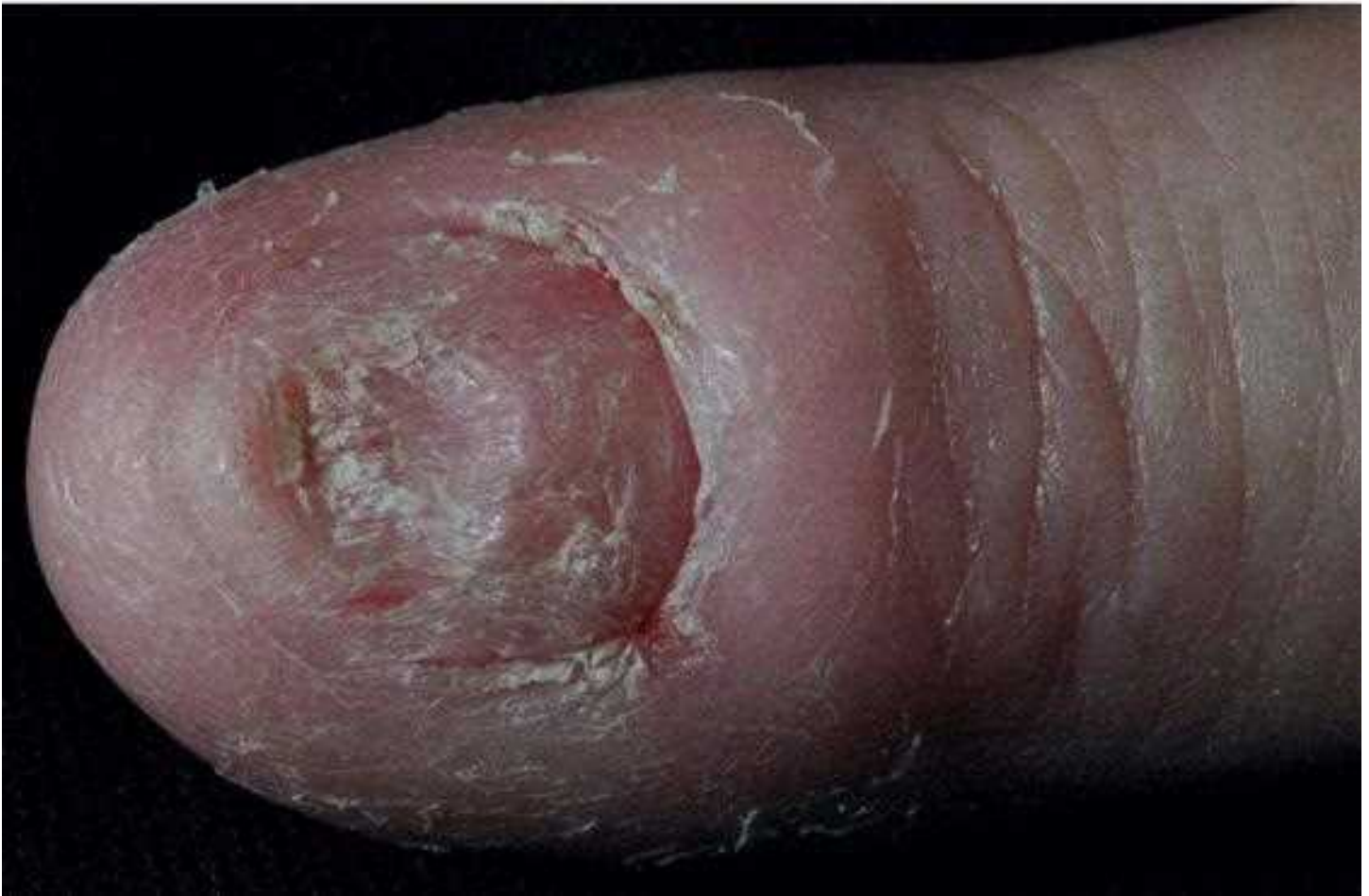

Figure 20.12 Eczema causing inflammatory matrix changes and compounded by picking with surrounding eczema and loss of intact nail.

Lichen planus can result in many features mimicking psoriasis, but in its most characteristic form produces atrophy of the nail plate which may completely disappear. The cuticle may be thickened and grow over the nail plate, known as *pterygium formation* ([Figure 20.13](#)).

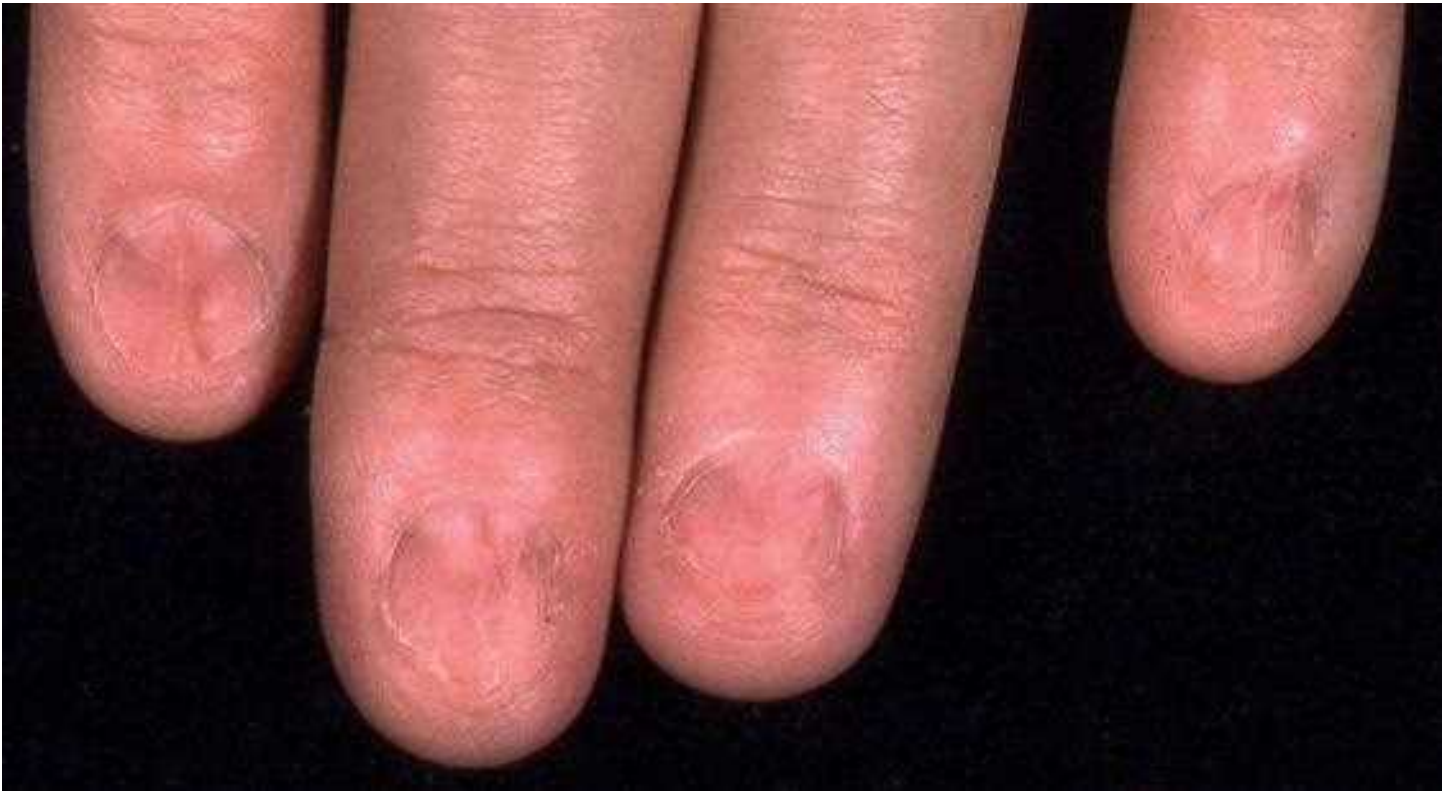

Figure 20.13 Lichen planus.

Alopecia areata is associated with changes in the nails in about 30% of cases. Features include ridging, pitting, leukonychia, and friable nails. Where the nails are friable, it is referred to as *trachyonychia* and may involve any or all of the nails – known as *20-nail dystrophy* ([Figure 20.14](#)).

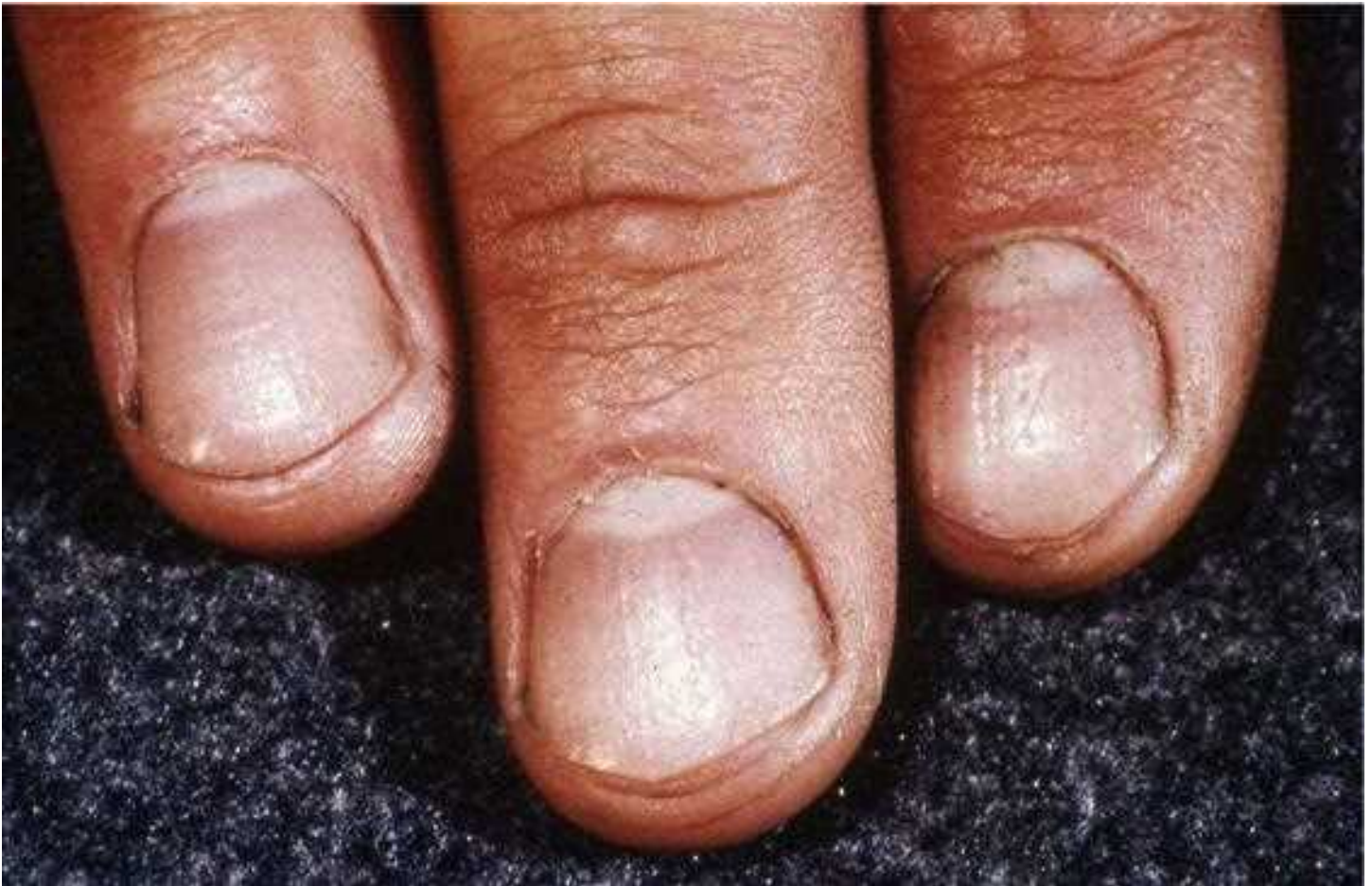

Figure 20.14 Nail dystrophy with alopecia areata comprising multiple small, regular, pits.

Darier's disease is associated with dystrophy of the nail and longitudinal streaks which end in triangular-shaped nicks at the free edge (see [Figure 20.6](#)). On the skin, there may be the characteristic brownish scaling papules on the central part of the back, chest, and neck. These are made worse by sun exposure.

Autoimmune conditions such as pemphigus and pemphigoid may be associated with a variety of changes including ridging, splitting of the nail plate and atrophy and shedding in some or all of the nails.

Discolouration of the nail and friability are associated with *lupus erythematosus* ([Figures 20.15](#) and [20.16](#)).

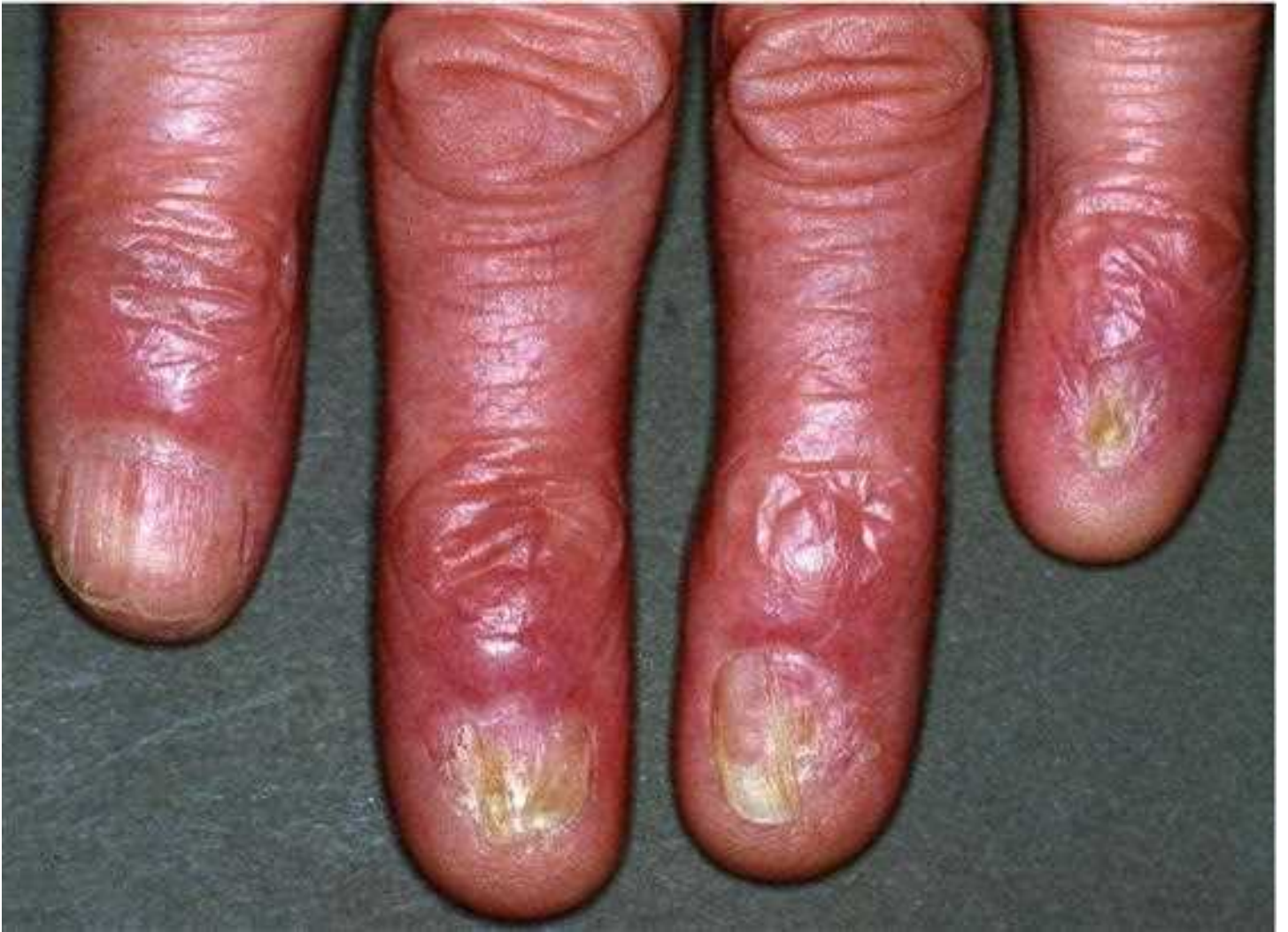

Figure 20.15 Dystrophy due to lupus.

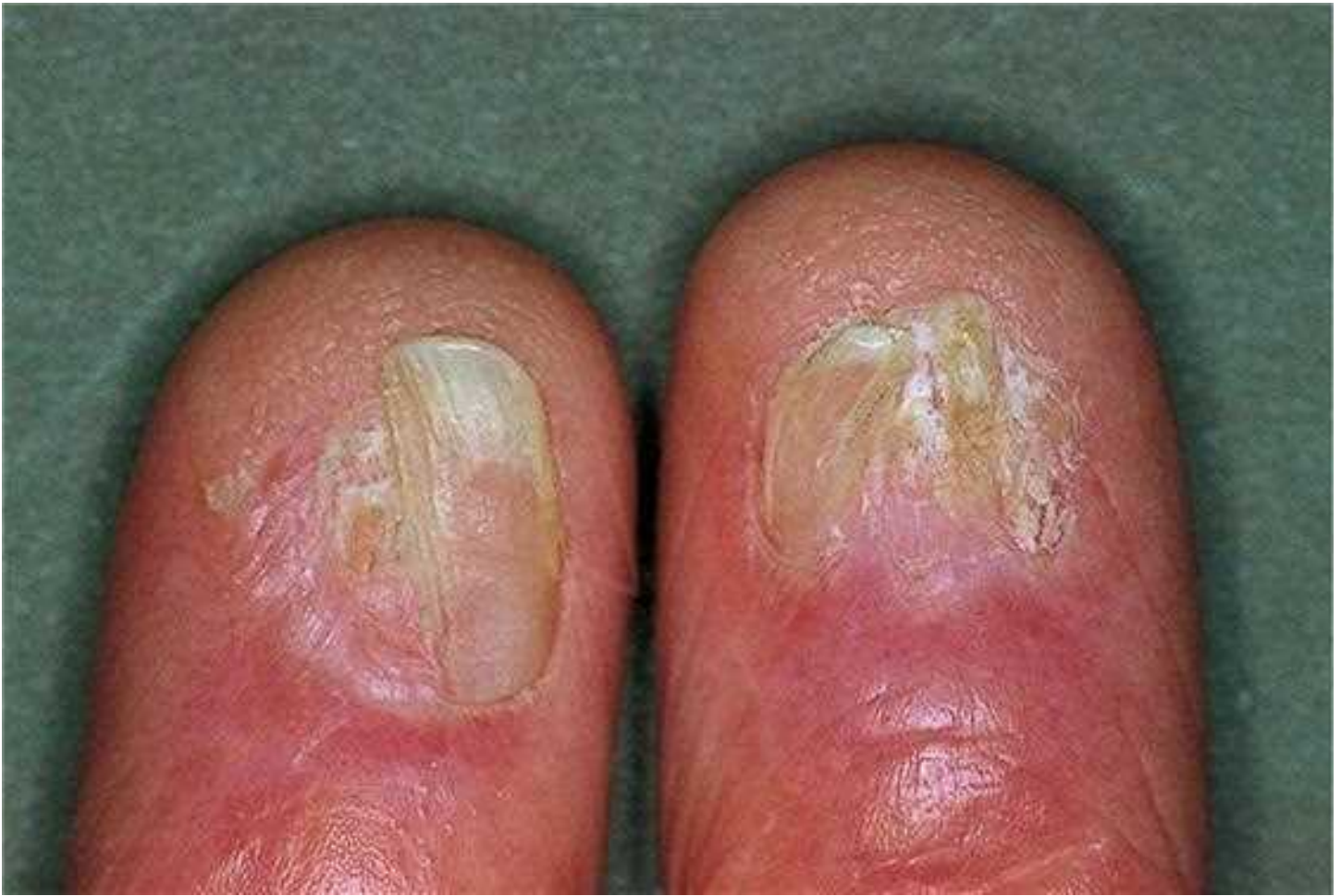

Figure 20.16 Pterygium formation with lupus.

Infection

Bacterial infection of periungual tissues

Infection of the nail unit may affect the soft tissues or the nail plate. The proximal and lateral nail folds are typically affected by *S. aureus* or less commonly *Streptococcus* or gram-negative organisms. Treatment is with drainage of any pus collection and systemic antibiotics, modified after initiation depending on culture results.

The nail bed may become infected as a result of onycholysis ([Figure 20.17](#)). *Candida* and *Pseudomonas* are the most common agents, where their growth is promoted by the damp warm character of the onycholytic space. Treatment may entail clipping back the nail to expose the nail bed, avoidance of wet work, drying beneath the nail with a hair dryer daily and the use of antimicrobials. Topical antimicrobial treatment can be the use of gentamicin eye drops beneath the nail, or as part of a long-term regimen to prevent relapse, undertaking daily five-minute soaks with vinegar or sodium hypochlorite solution. Ultimately, cure relies on management of the onycholysis.

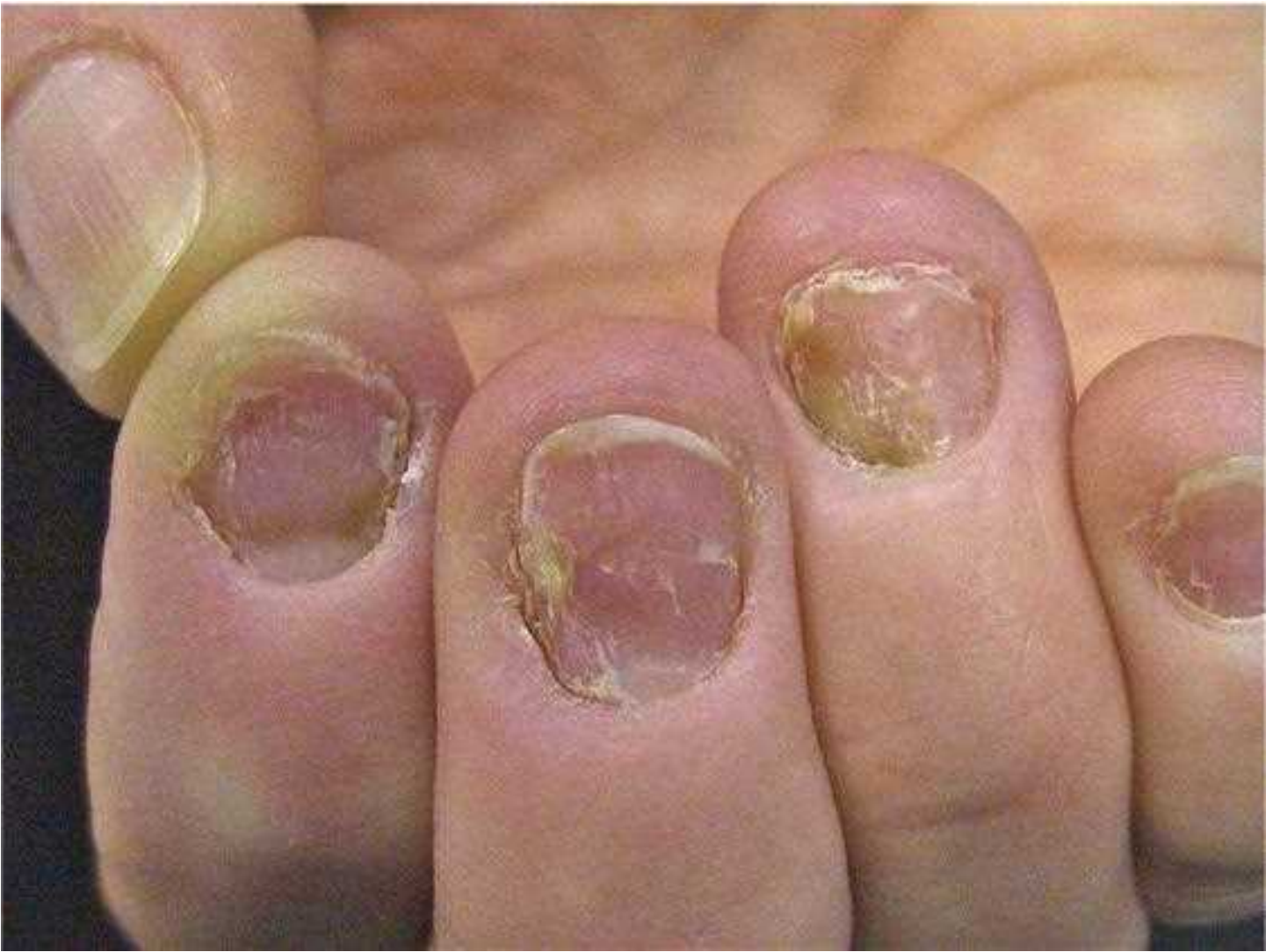

Figure 20.17 Chronic paronychia with alteration of nail plate shape, loss of cuticle and discolouration secondary to nail fold inflammation and microbial colonisation.

Fungal nail infection

Nail plate infection with dermatophyte fungi is mainly associated with nail bed involvement and typically occurs in a previously traumatised nail. Dermatophyte nail fungal infection is usually of the toenails rather than the fingernails and involvement of nearby skin should be sought and treated, especially between the fourth and fifth toes. It is important to confirm the presence of fungus before considering treatment as nail psoriasis, eczema, and trauma can all look similar. The diagnosis is confirmed by taking generous clippings of the nail plate and subungual debris for microscopy and culture ([Figure 20.18](#)). Positive culture is a prerequisite for systemic treatment. In some settings, polymerase chain reaction is used to identify the fungus, although it will not determine whether the fungus is alive and hence viable.

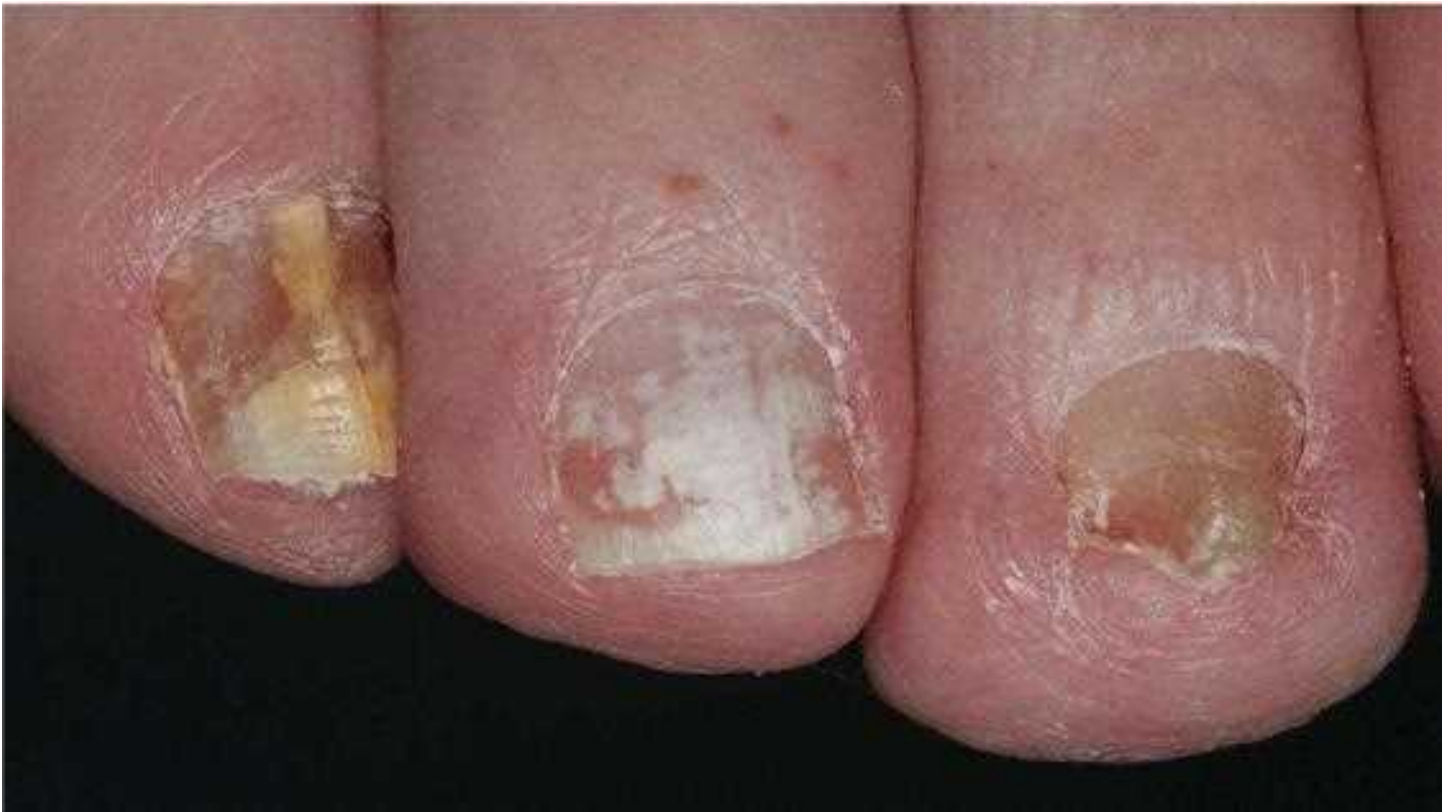

Figure 20.18 Fungal infection with superficial pattern (fourth toe) and distal and subungual pattern on the little toe.

Culture will determine if the fungus is a dermatophyte such as *Trichophyton rubrum*, or a non-dermatophyte. The latter are more difficult to treat effectively and therapy should be guided by a dermatologist or someone with specialist knowledge of onychomycosis.

Treatment of dermatophyte onychomycosis is optional based on patient preference and clinical factors. Systemic treatment with terbinafine is likely to ultimately achieve a normal nail in about 50% of patients. This figure will be slightly increased by concomitant use of topical amorolfine lacquer weekly.

Trauma

Acute trauma is usually either a crush or leverage injury. Crush injury is typically associated with subungual bleeding. Where this involves more than 50% of the nail area, drainage is indicated to relieve pain and reduce the risk of compression injury to the matrix with long-term changes to nail growth. An opened red-hot paper clip or a nail drill, usually available in emergency departments, can be used. Leverage injuries lead to complete or partial lifting of the nail plate, with nail avulsion in the latter instance. It is best to clean the nail and return it *in situ* to act as a dressing to the wounded nail bed. It will need to be held in place by a dressing or cyanoacrylate glue. It will eventually drop off when the new nail generates beneath.

Chronic trauma of the toenails is typically due to poorly fitting footwear, where the free edge

of the nail is brought into repeated contact with the shoe. This is most marked when the footwear is pointed or there is a high heel, creating a force on the foot downwards into the toe of the shoe. Trauma between toes and footwear can also arise with well-fitting shoes in activities such as step aerobics, hill walking (downwards), skiing, and long-distance running. The initial effect of chronic trauma is asymptomatic bleeding. Later, there is thickening and yellow discolouration of the nail. Over many years, the shape of the nail matrix is altered and the nail may grow upwards and lose nail bed attachment. With marathon running, it is not uncommon for people to shed nails after the event.

Chronic trauma of the fingernails arises through 'habit tic' picking ([Figure 20.19](#)), manicure or occupational repetitive trauma, such as cardboard box assembly.

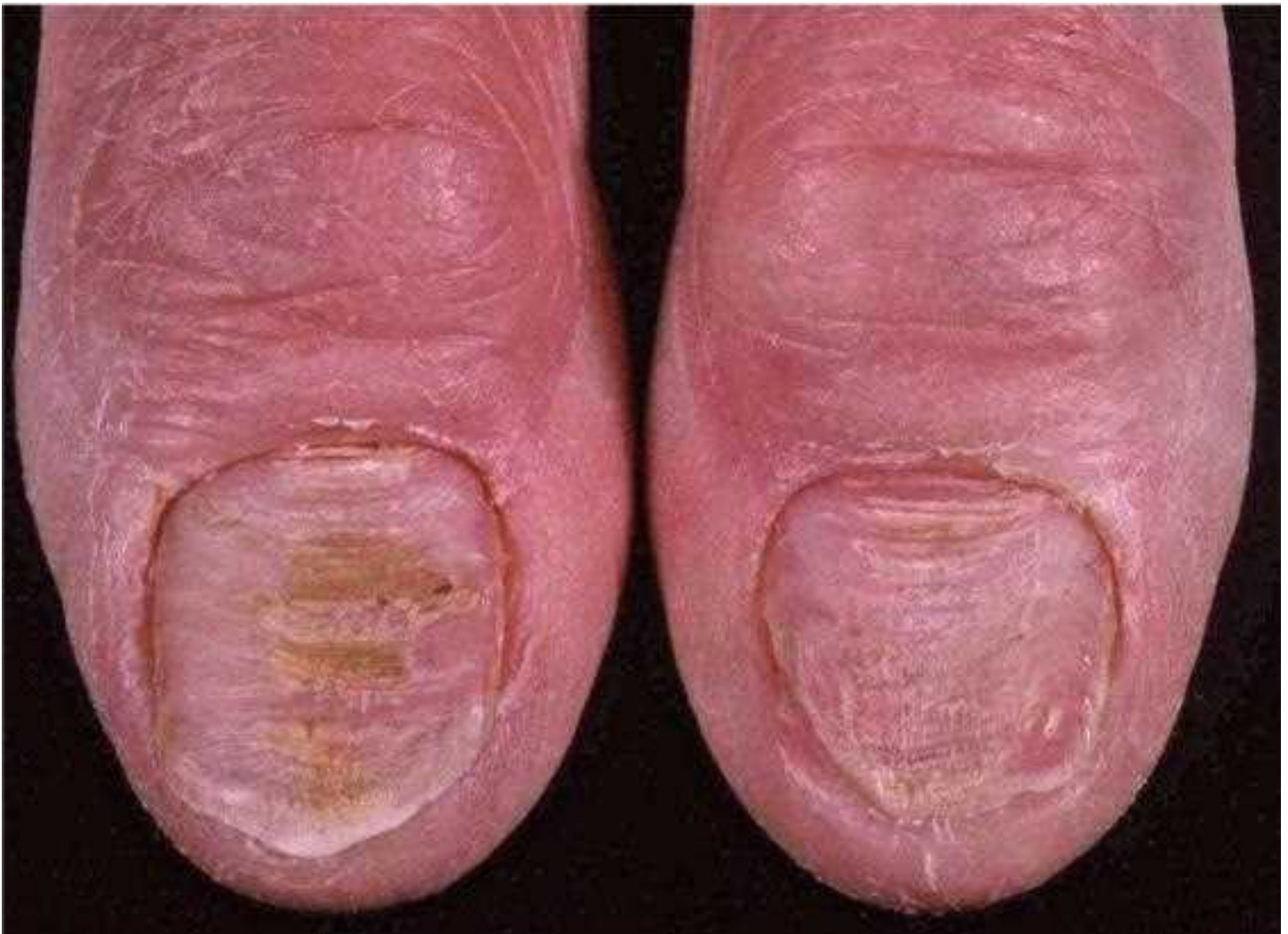

Figure 20.19 Chronic rubbing trauma to the proximal nail fold leads to a 'habit tic' pattern of longitudinal dystrophy.

In all instances of chronic trauma, management relies on identification of the cause and its avoidance. For some patterns of self-inflicted trauma, it may not be not easy to persuade the patient of their role in the process. Physical protection of the nail and nail fold with occlusive dressing, sometimes supplemented with steroid ointment, can be helpful in instances of fingernail problems.

General diseases affecting the nails

Nail changes in systemic illness

Acute illness

Acute illness results in a transverse line of atrophy known as a *Beau's line*. Shedding of the nail, onychomadesis, may occur in severe illness.

Chronic illness

Clubbing affects the soft tissues of the terminal phalanx with swelling and an increase in the angle between the nail plate and the nail fold. There is chronic swelling of periungual tissues with increased vasculature associated with an increase in the transverse and longitudinal curvature of the nail (see [Figure 20.7](#)). At the base of the nail, the angle with the nail fold is lost due to the swelling, and the nail fold has a 'boggy' consistency. It is due to systemic or inherited factors, which means that it affects all nails, although the changes in the toes are less obvious than in the digits of the hands. It is associated with chronic fibrotic, infective, or malignant respiratory disease, cyanotic heart disease, and occasionally inflammatory bowel disease. It can be hereditary and may be unilateral in association with vascular abnormalities.

Cyanosis – Where cyanotic heart disease or fibrotic or cavitating pulmonary disease is the underlying cause, the nail bed may be cyanosed. In idiopathic variants, or where there is underlying inflammatory bowel and liver disease, it can be a normal pink colour.

Splinter haemorrhages occur beneath the nail and are usually the result of minor trauma. They are also associated with a wide range of general medical conditions including subacute bacterial endocarditis and severe rheumatoid arthritis.

Lesions adjacent to the nail

Viral warts are the most common tumour arising in the nail folds (see [Chapter 14](#)) and nail bed with secondary effects on the nail plate. In childhood, these usually resolve without treatment. In adults, resolution is less predictable. Topical, surgical, laser, and chemotherapeutic options are available but all have a significant failures rate with possible complications of pain, infection, and scarring in the more aggressive treatments.

Myxoid pseudocysts arise through damage to the synovial capsule, which allows escape of synovial fluid in the subcutaneous tissue. This is usually secondary to osteoarthritis although it can be caused by specific trauma. The fluid collects on the dorsal aspect of the digit, beneath the proximal nail fold but above the matrix, or beneath the matrix. Where the location impinges on the nail matrix, nail plate growth will be altered to reflect the pattern of pressure ([Figure 20.20](#)). Careful ligation of the defect in the synovial capsule can be curative, but has a relatively high failure rate in the toes.

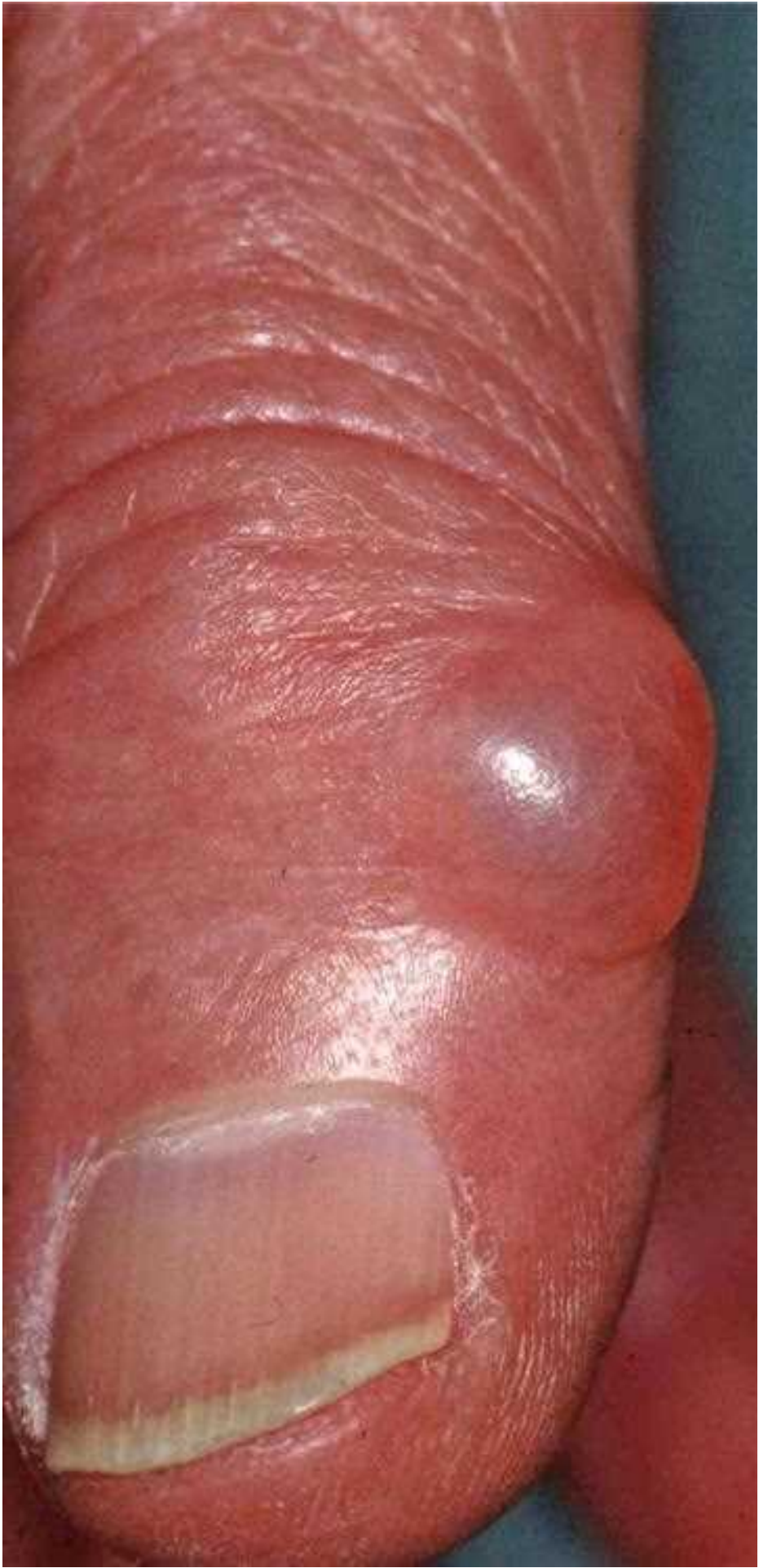

Figure 20.20 Muroid cyst, also called *myxoid pseudocyst*.

Naevi may occur adjacent to the nail and a benign melanocytic naevus can produce a pigmented streak.

Melanoma ([Figure 20.21](#)) typically arises from a pigmented lesion located in the nail matrix, which contributes pigment to the nail plate and consequently creates a dark longitudinal streak in the nail. It can be difficult to distinguish from a benign naevus in the early stages. As it progresses, it often causes pigmentation of the cuticle, Hutchinson's sign. Further evolution is associated with destruction of the nail plate such that it causes nail splits or loss. Sometimes, subungual melanoma is amelanotic so that there are no pigmentary changes, and any rapidly growing soft tumour should raise suspicions of this condition. There are some similarities with pyogenic granuloma, which means pyogenic granulomas should usually be histologically confirmed as such. Melanoma of the nail unit is usually detected later than melanoma at other sites such that it is thicker and hence more advanced. This lends it a worse prognosis.

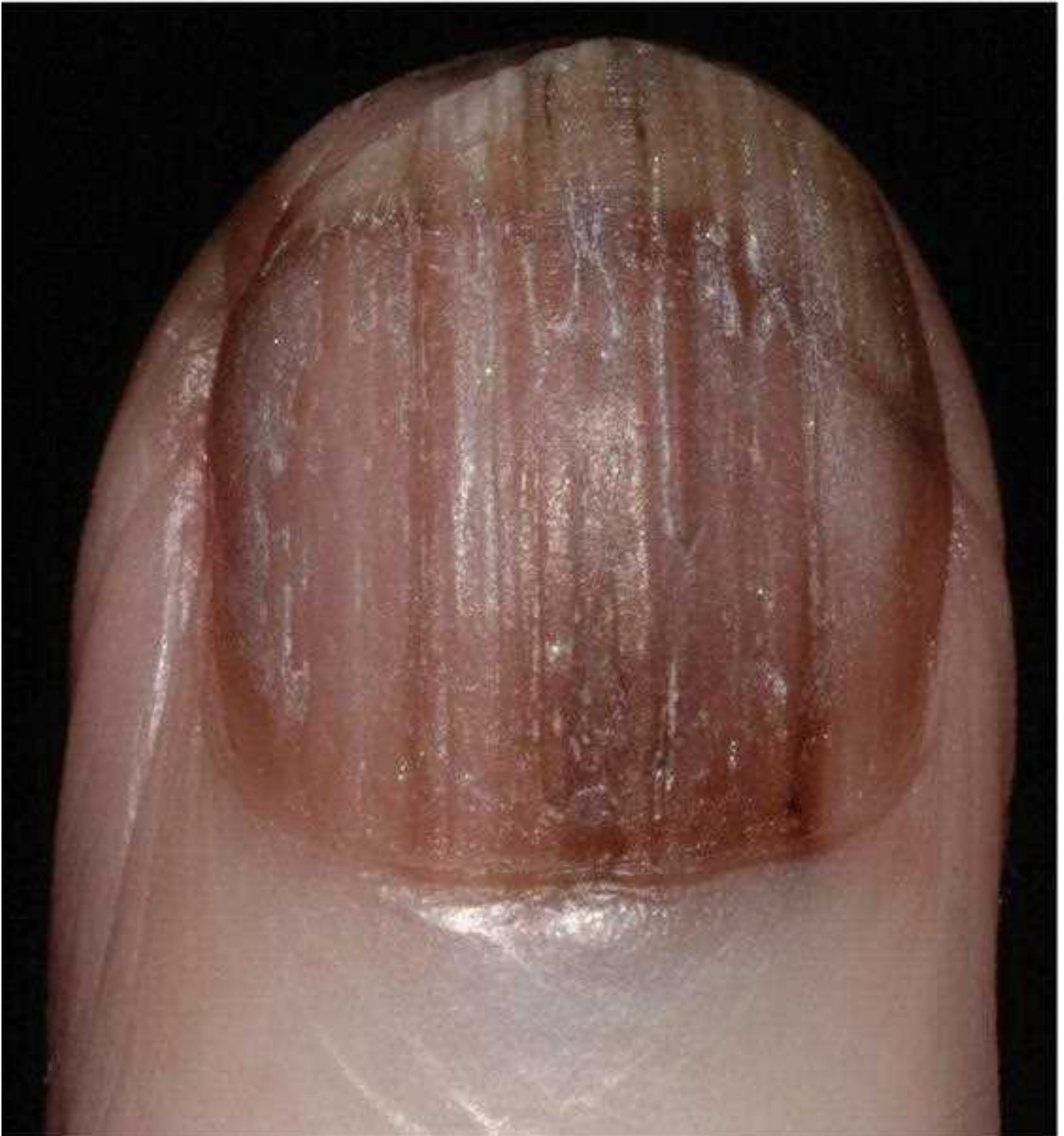

Figure 20.21 *In situ* melanoma with progressive pigmentation of nail plate.

Squamous cell carcinoma (SCC) most commonly presents as *in situ* disease, which represents Bowen's disease. It can involve the nail fold, nail bed and matrix. In the nail bed and matrix it alters nail adherence and nail plate production respectively. In the nail fold, altered texture and splitting can be a feature and pain is common. Human papilloma virus 16 and 18 are thought to drive SCC formation in the nail (similar to SCC that develop in the perineum and oropharynx). Immune suppression can predispose to the disease, resulting in more than one

digit affected and leaving patients vulnerable to relapse after treatment. The most common treatment is surgery, with a preference towards Mohs micrographic surgery, where preservation of part of the nail unit can be an option for limited disease.

Subungual exostosis can cause a painful lesion under the nail ([Figure 20.22](#)). It is confirmed by X-ray examination. Lateral and plane views are needed to ensure that a subtle bony protuberance is not missed. A large part of the pathology is the cartilaginous cap, which is radiolucent and means that the pathology is clinically larger than the evidence on X-ray.

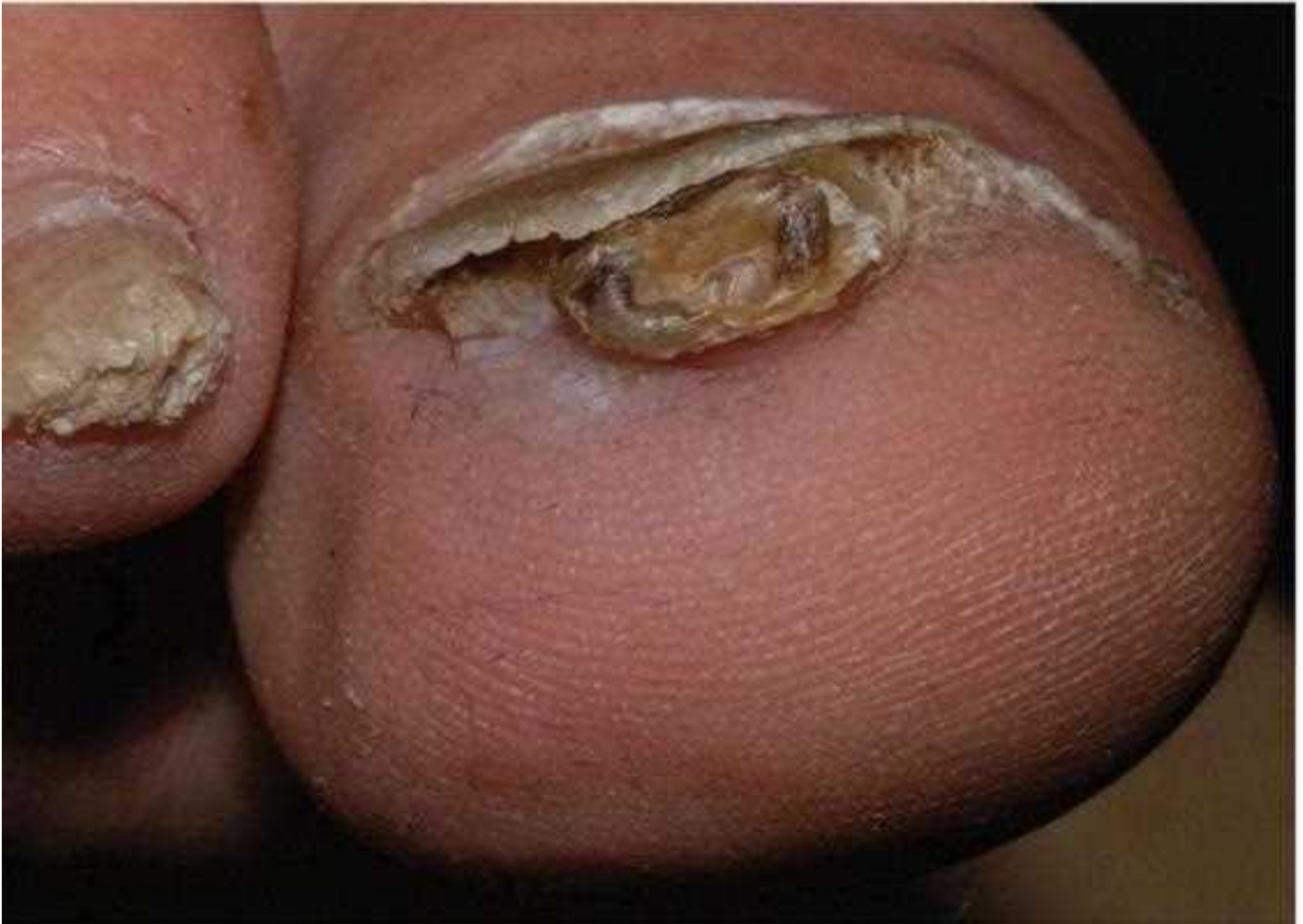

Figure 20.22 Subungual exostosis of the big toe.

Glomus tumours arise as dermal tumours beneath the nail. They are characterised by pain which is worse in the cold and at night. Pain can be diminished by elevating the limb. When the tumour is in the nail bed there may be minimal or no clinical changes. When it is located beneath the matrix, pressure upon the matrix will alter matrix function. This causes a red streak in the nail, which ultimately may wear through the nail and produce a split. Treatment is by surgical excision.

Periungual fibrokeratomas appear as firm fibrous lumps that may be spherical or elongated. Nail growth is altered by pressure on the nail matrix. They are associated with tuberous sclerosis but this is unlikely with single lesions in an adult. However, a full examination and

family history should be carried out to ensure that the diagnosis has not been missed. Patients presenting with multiple tumours are more likely to have tuberous sclerosis. Surgery can be effective in fibromas causing functional impairment or pain.

Treatment of nail conditions

Inflammatory and infective nail conditions often occur when there has been inadequate hand or foot care. The principles of care of the nails are as follows.

- Keep nails short. Do not cut toenails too short for fear of precipitating ingrowing nail.
- Dry hands and feet carefully after washing, especially between digits and under rings.
- Wear gloves when undertaking wet work, gardening, or work entailing contact with solvents or abrasive materials.
- Ensure well-fitting footwear with a high 'box' (the space at the end to accommodate the toes).
- Use emollients to prevent drying of the skin and treat tinea pedis early with topical antifungal creams.

Tumours require surgical management, which is best provided by a dermatological surgeon or a plastic or orthopaedic surgeon with expertise in hand or foot surgery.

Severe systemic inflammatory diseases can be associated with nail changes that may be severe enough to affect function and quality of life. In these instances, systemic therapies such as ciclosporin, methotrexate, retinoids, prednisolone, or biologics may be warranted. The nature of nail growth suggests that the benefit of therapy may not be seen for two to three months, but once the inflammatory disease is suppressed it is possible to discontinue therapy and await further improvement. Systemic therapy may be given as pulses which make it possible to reduce the risk of side effects and to maximise cost benefit.

Nail cosmetics

Nail cosmetics can provide a useful means of concealing aspects of nail disease not responding to treatment. Pitting can be hidden by coloured nail lacquer or filled with acrylic gel. Lacquer will also conceal onycholysis. However, once the nail plate starts to have structural changes such as splits or reduction in nail bed attachment, any form of artificial nail is at risk of causing additional problems. The most common is exacerbation of onycholysis as the adherent artificial nail acts as a lever that pulls the residual nail further from the nail bed. Other problems include subungual infection due to the crevices created with the imperfect adherence of the artificial nail. Removal of the artificial nail can also result in further disintegration of the diseased nail plate.

Further reading

Baran, R., de Berker, D.A.R., Holzberg, M. et al. (2019). *Baran and Dawber's Diseases of the Nails and Their Management*, 5e. Oxford: Wiley-Blackwell.

CHAPTER 21

Genital Dermatoses

Fiona Lewis

St John's Institute of Dermatology, Guy's and St. Thomas' Hospitals, London, UK

OVERVIEW

- Genital dermatoses are common but may be missed without careful examination.
- Specific disorders affect this site e.g. lichen sclerosus and lichen planus.
- The typical features of cutaneous disease are often altered on the genital skin and treatment needs to be modified.
- Specialised management is important to prevent complications and functional issues.

Introduction

The genital site in both sexes is complex as it contains keratinised skin and non-keratinised mucosa. There are specific diseases that affect the area but it may also be involved as part of disease elsewhere. The clinical appearances of easily recognisable disease on the rest of the skin are often altered because of the moist environment. Irritants, friction, and the specific bacterial flora can aggravate skin disease. Treatment requires modification as some topical treatments that prove useful at extra-genital sites can be very irritant on the genital skin. As a general principle, ointments are always preferable to creams, and once-daily application of any topical steroid treatment is sufficient. Simple ointment-based emollients can be used as a soap substitute.

History and examination

A full history should include all the usual questions in a general dermatological history but in any patient with genital symptoms additional topics must be covered. A sexual history, effects on micturition, bladder, or bowel symptoms and a full obstetric and gynaecological history in women must be included.

The examination should be performed with good lighting and magnification if needed. A methodical approach to include all the areas, including the perianal skin, should be adopted. Speculum examination of the vagina is needed in those with erosive disease or intra-epithelial neoplasia. Further examination of the skin, mouth, scalp, and nails may give useful diagnostic information.

The appearance of the genitalia can vary significantly, and it is very important to know the normal variants of the vulva and penis as this will avoid unnecessary investigation or surgical excision.

Angiokeratomata are common in both sexes. They are most commonly seen on the labia majora and scrotum ([Figure 21.1](#)). They are benign vascular tumours with overlying keratotic epithelium, measuring 1–3 mm in diameter and frequently multiple. No treatment is required.

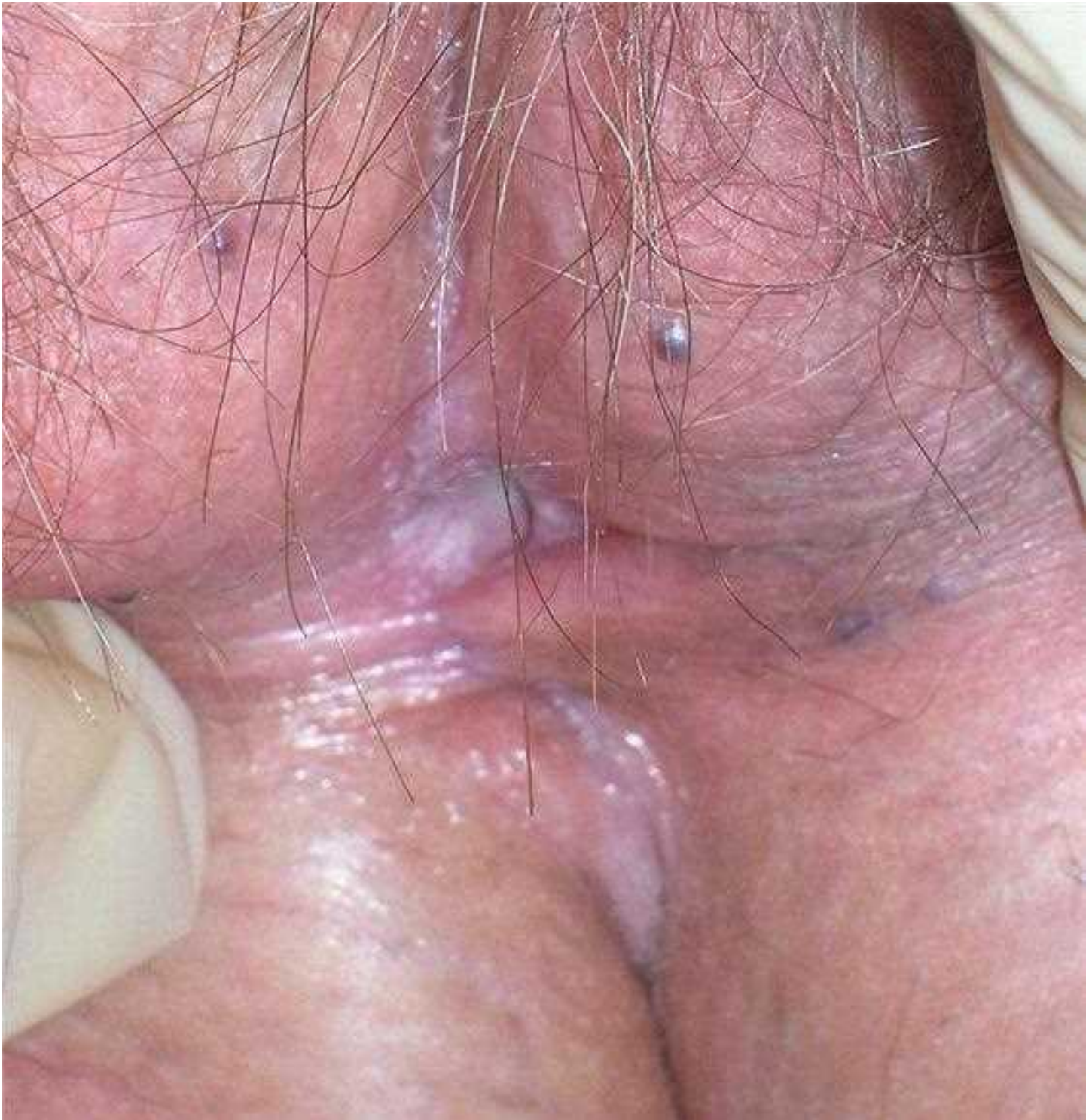

Figure 21.1 Angiokeratomas, multiple small vascular lesions on labia majora.

Vestibular papillae are small rounded projections seen at the vestibule in up to 50% of premenopausal women. They are not human papillomavirus (HPV) related, do not cause symptoms and require no treatment.

Fordyce spots are sebaceous glands that can be very prominent in young women. They are seen on the inner labia minora as small yellow spots. *Hart's line* is the junction between the keratinised skin and non-keratinised mucosa.

Pearly penile papules occur in up to 20% of young men and are seen in the coronal sulcus. The histology is that of an angiofibroma.

Eczema

Several types of eczema can affect the genital skin and it is important to distinguish between them. Atopic eczema often spares the genital area.

Treatment of eczema in the genital area is with regular emollients and a mild topical steroid as needed.

Seborrhoeic eczema – this is the most common endogenous eczema seen in the genital area. Patients usually have a history of this elsewhere with scalp and facial lesions.

Irritant eczema – this is a very common problem in children and in older women with urinary incontinence. Diffuse erythema is seen over the outer vulva or the shaft of the penis. It frequently affects the perianal skin where symmetrical erythema sometimes with scaling is seen on the buttocks. It is frequently aggravated by excessive washing, particularly if irritant cleansing solutions are used.

Allergic contact dermatitis – common allergens at this site include fragrances, preservatives, antibiotics, caine local anaesthetics used in topical treatments, and rubber accelerators. In the acute presentation, the skin may be severely inflamed ([Figure 21.2](#)) with weeping and eroded areas. Secondary bacterial infection is often a problem. If suspected, the patient requires patch testing to try to identify the cause. Treatment is with avoidance. Topical steroids and emollients will be needed initially with potassium permanganate soaks 1 : 10000 if wet and eroded.

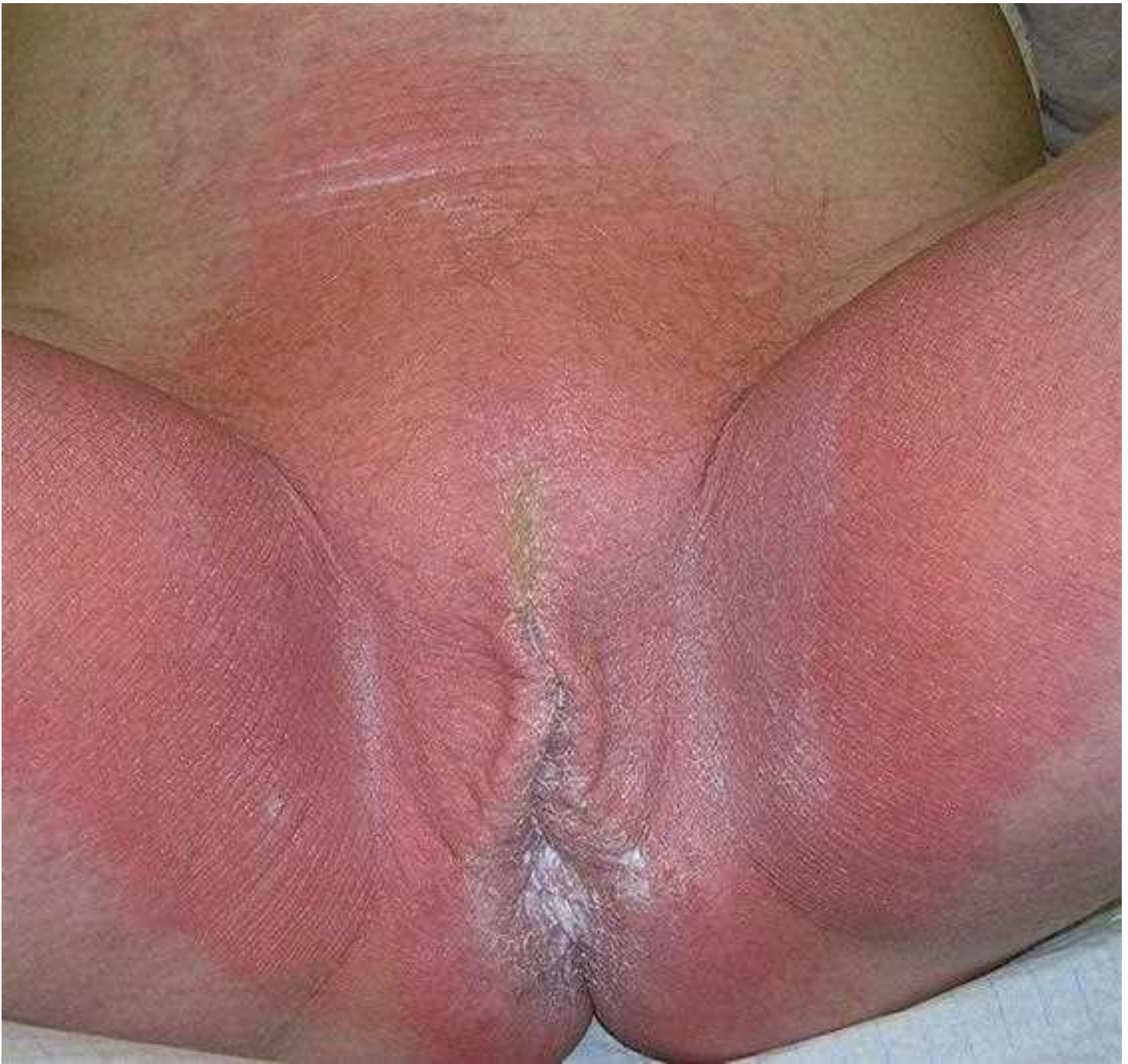

Figure 21.2 Extensive erythema in acute allergic contact dermatitis.

Lichen simplex

Lichen simplex is the end result of the itch-scratch cycle. Intense itch, often enough to disturb sleep, and the resulting rubbing leads to extensive lichenification of the involved skin. The genital area is a common site for this condition and until treated, it often spreads to involve the perianal region. Lesions are mostly seen on the labia majora ([Figure 21.3](#)) and scrotum. Treatment is with emollients and potent topical steroids on a reducing regimen for two to three months. In those where perianal involvement is predominant, patch testing should be considered.

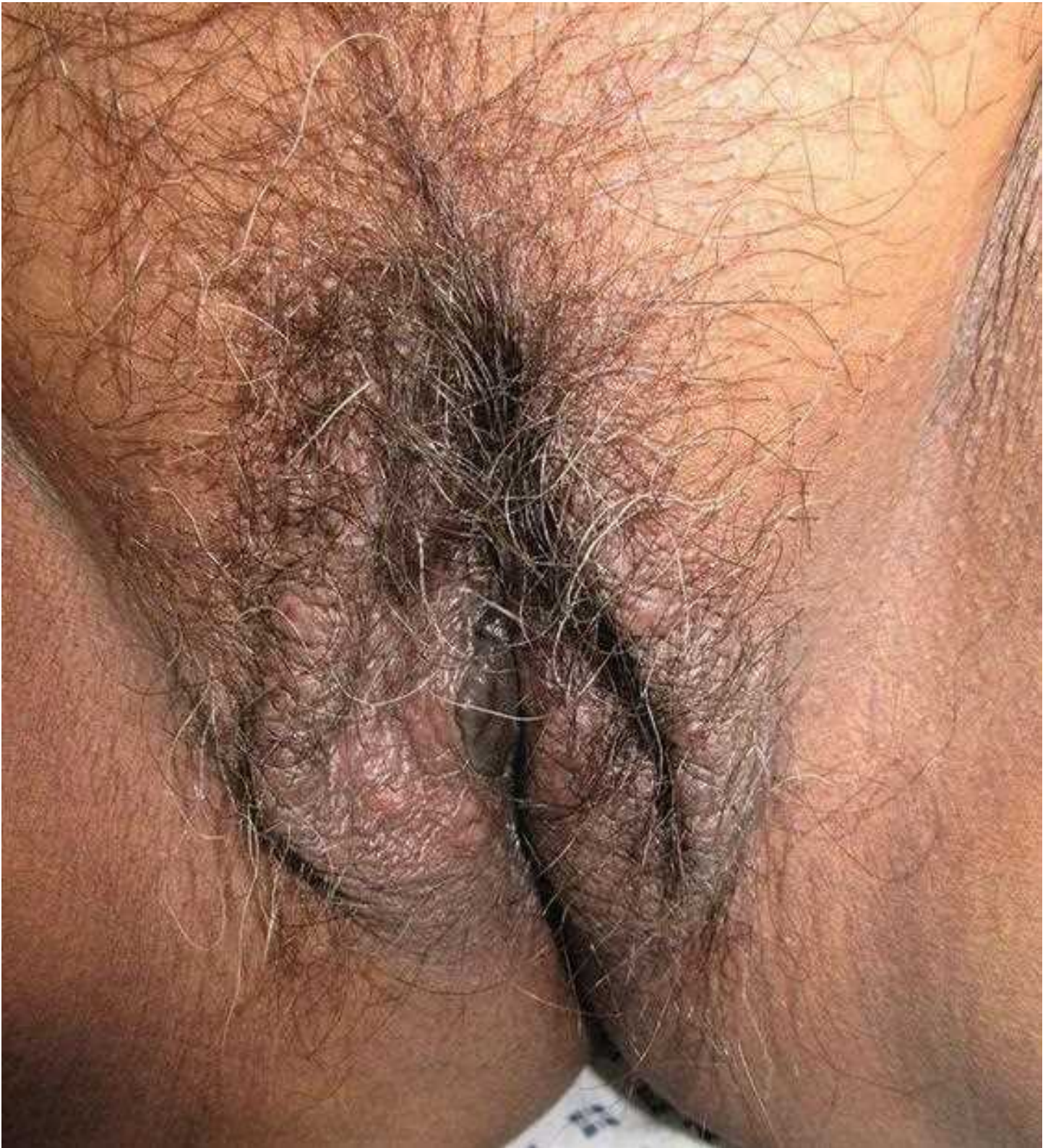

Figure 21.3 Lichen simplex with lichenification and excoriation of labia majora.

Balanitis and balano-posthitis

Balanitis is the term used to describe inflammation of the glans penis and *posthitis* is inflammation of the foreskin. There may be an underlying infection (e.g. *Candida*,

Streptococcus) or dermatosis but most cases are non-specific, and no primary cause is found. Treatment is with bland emollients and a mild topical steroid used as needed.

Psoriasis

Psoriasis can involve the ano-genital skin in isolation or as part of generalised disease. The classic silvery scaling is lost at flexural sites due to the moist environment and it presents, with well-defined erythematous plaques, sometimes with minor scaling at the spreading edge ([Figure 21.4](#)). Itching is the main symptom but fissuring is common, leading to soreness and dyspareunia in both sexes. In females, the outer labia majora and mons pubis are generally affected. In men, the glans, shaft of the penis, and scrotum are most commonly involved. Extension to the perianal skin and gluteal cleft is common in both sexes.

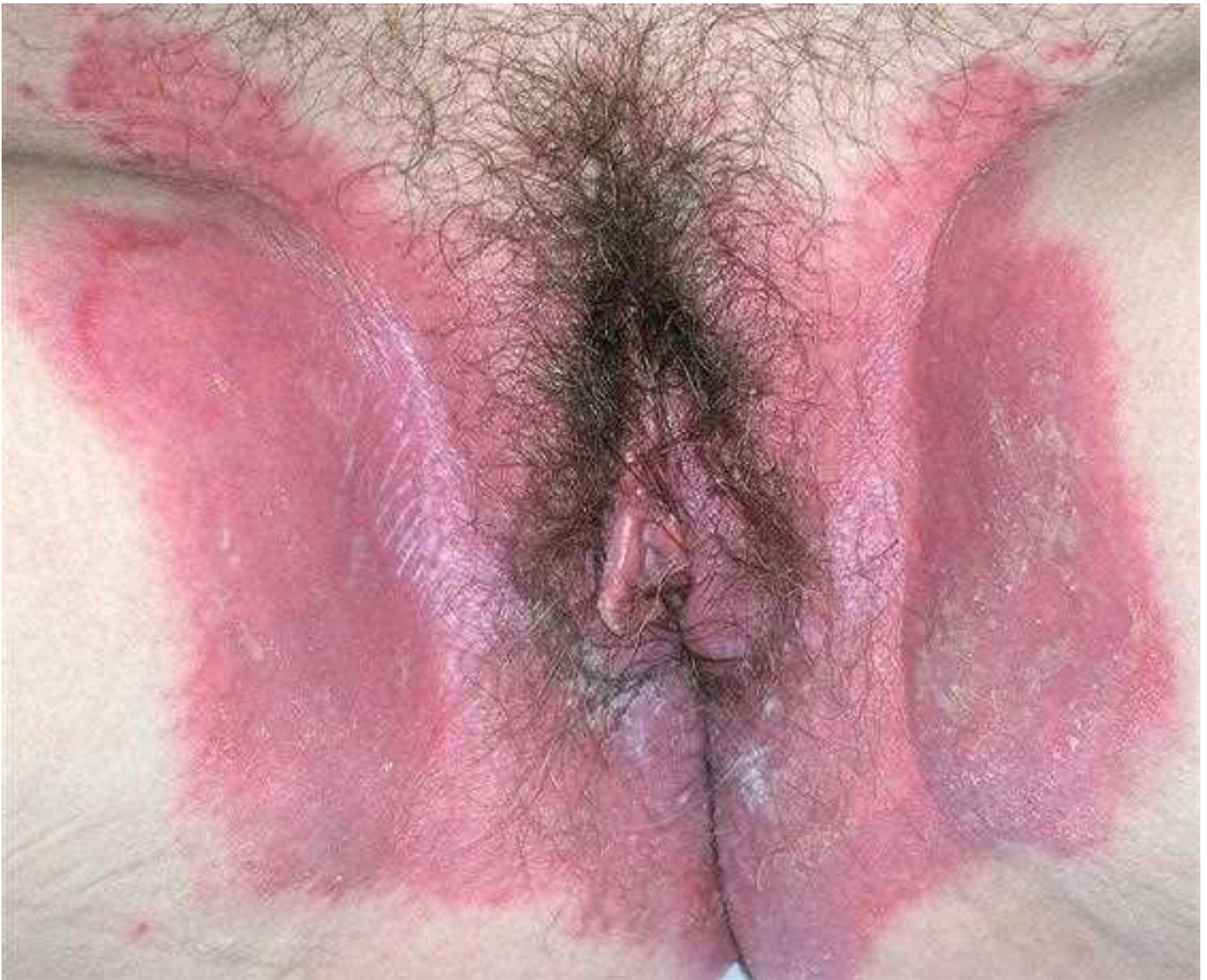

Figure 21.4 Vulval psoriasis with well-defined plaques affecting labia majora and inguinal folds.

Topical treatments for psoriasis need to be modified in the genital area as several of these used at other sites are too irritant on the ano-genital tissues. Regular emollients and a moderately potent topical steroid used on a reducing regimen over four to six weeks is helpful. Treatment is usually required intermittently to maintain control of the disease. Calcineurin inhibitors are sometimes helpful as topical steroid-sparing agents but are rarely sufficient alone to treat the problem.

Lichen sclerosus

Lichen sclerosus (LS) is the most common dermatosis to affect the genital area. It occurs in both sexes but is much more common in females, where there are two peaks of incidence, one in childhood (about three to five years of age) and the second in adults post menopause. About 20% of cases will start in the reproductive years.

The aetiology is not known. Genetic factors may be involved, but previous theories of an infective trigger with *Borrelia burgdorferi* have not been substantiated, and are not thought to be relevant. There is clinical evidence for the role of urine under occlusion in males, with a dysfunctional meatal valve.

In women, but not in men, there is a link with other autoimmune conditions such as hypothyroidism and pernicious anaemia but this is not necessarily a causative factor.

Histology shows a dense band of collagen under a thinned epidermis. There is a marked lymphocytic infiltrate in the dermis which is pushed down more deeply in the later stages of the disease.

In females, the predominant symptom is pruritus. If the skin fissures, this can be painful and perianal fissuring in children gives rise to the very common symptom of constipation. Narrowing of the introitus can cause dyspareunia. In males, the major symptoms relate to phimosis in the uncircumcised and problems with intercourse and micturition.

The classic clinical appearance is white sclerotic patches. These mainly affect the inner labia majora and minora ([Figure 21.5](#)), clitoral hood and perineum. Ecchymosis is pathognomonic of LS and is due to rupture of superficial dermal vessels. In some patients this can be dramatic and is common in children, leading to the erroneous diagnosis of child sexual abuse. Alteration of the normal architecture with resorption of the labia minora and sealing of the clitoral hood ([Figure 21.6](#)) can occur until treatment is started. Fusion of the inner labia majora may then narrow the introitus. LS does not affect the vagina.

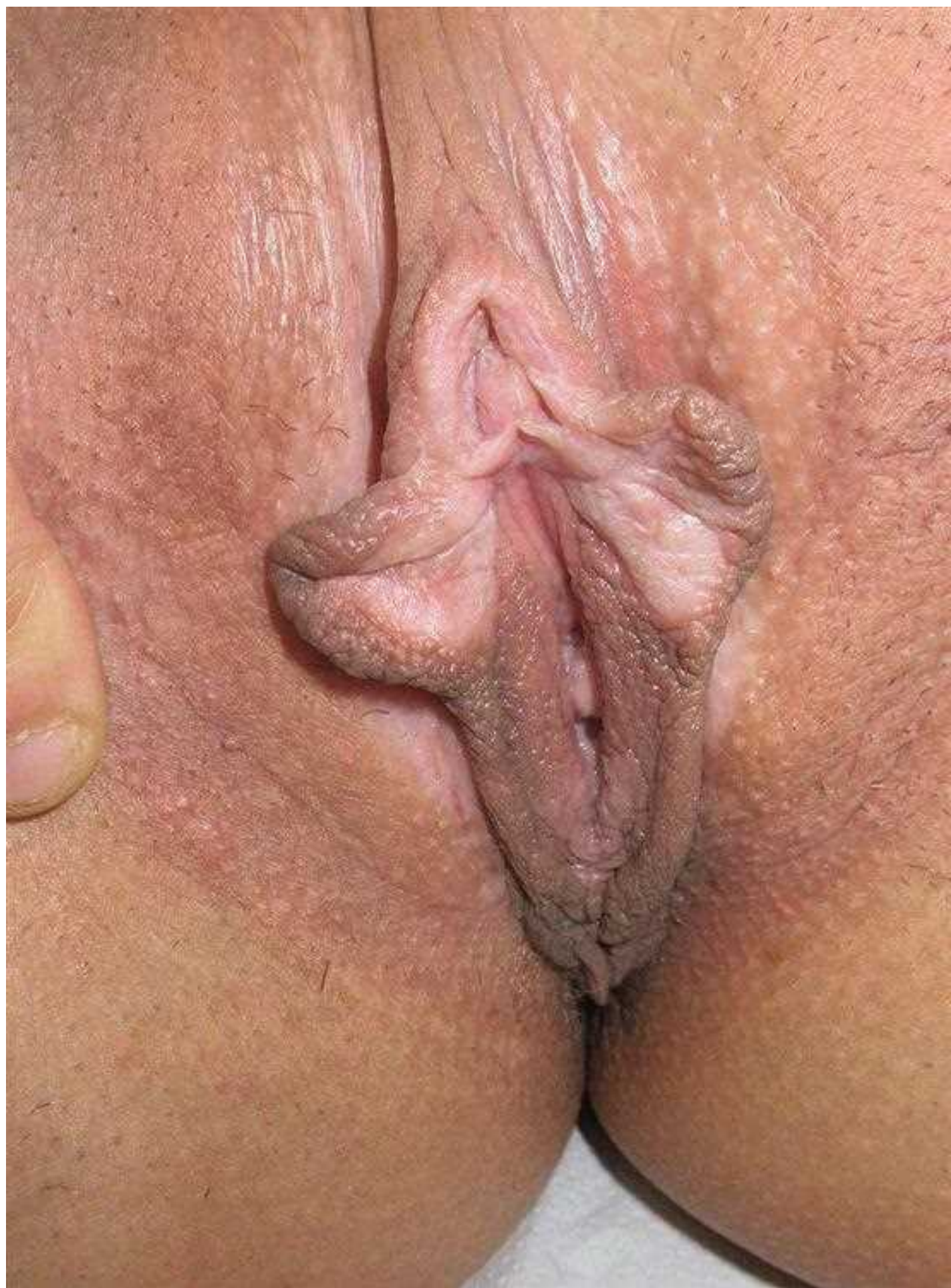

Figure 21.5 Vulval lichen sclerosus with white sclerotic plaques on inner labia minora and clitoral hood.

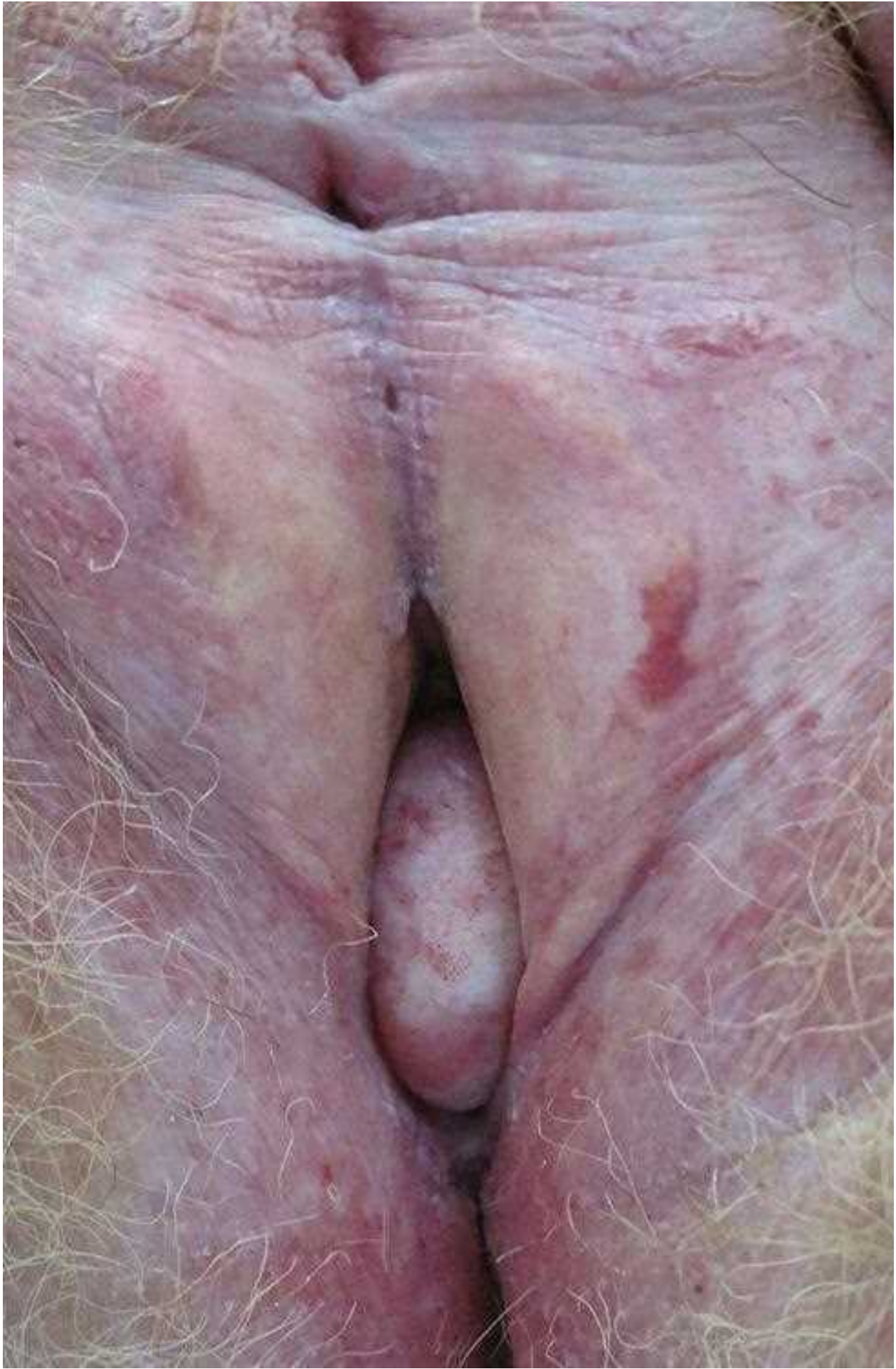

Figure 21.6 Vulval lichen sclerosus – architectural change with loss of labia minora and narrowing of the introitus. Ecchymosis is also seen.

In males, lesions are most common on the glans (**Figure 21.7**) and inner foreskin resulting in phimosis. In the circumcised male, obliteration of the coronal sulcus may be seen. Stenosis of the urinary meatus requires expert urological assessment.

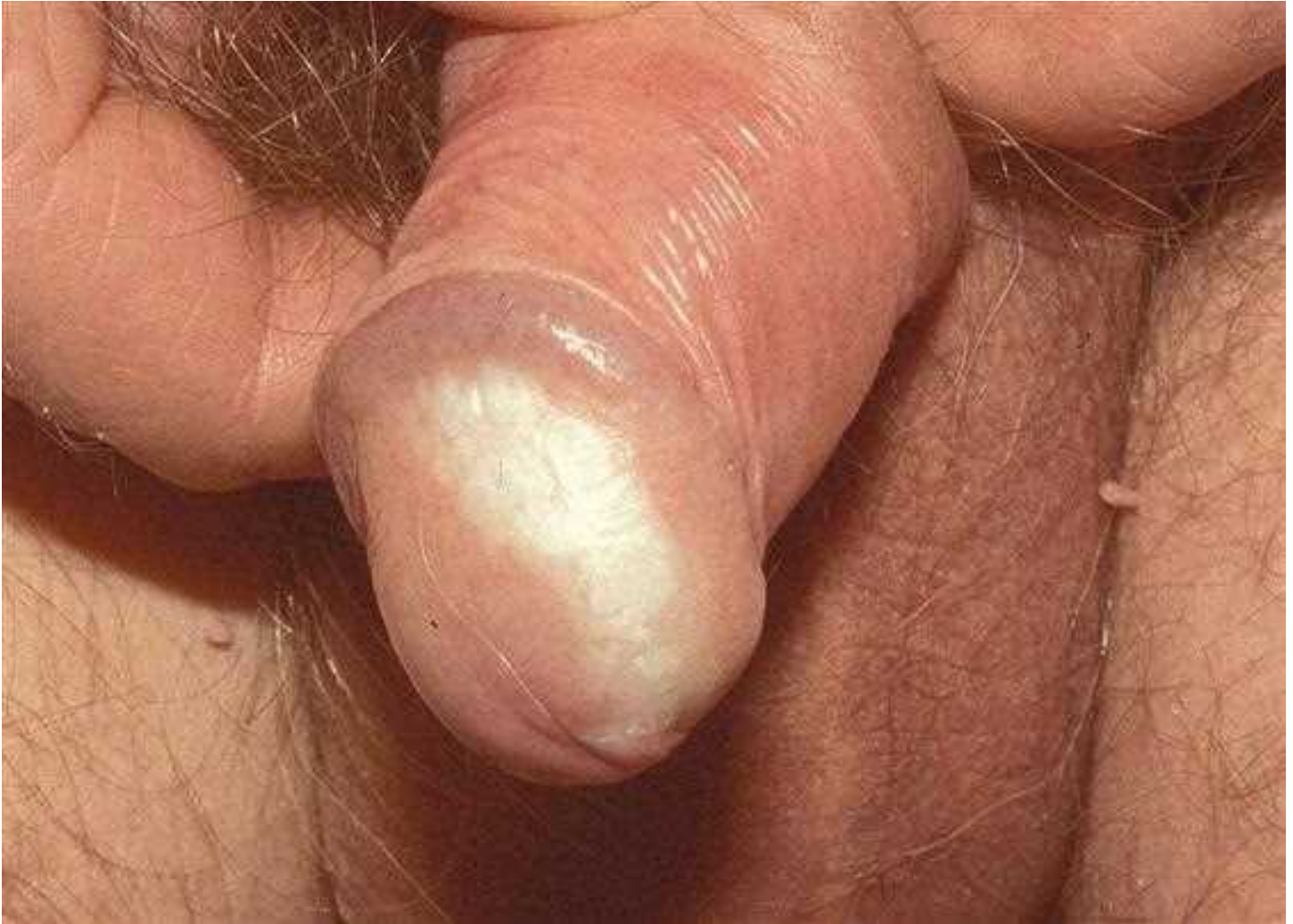

Figure 21.7 Lichen sclerosus affecting the glans penis.

The differential diagnosis of LS includes lichen planus (LP), mucous membrane pemphigoid and vitiligo. Some patients with LS also have vitiligo at the same site.

There is overwhelming evidence for the use of an ultra-potent topical steroid such as clobetasol propionate 0.05% ointment as the treatment of choice for LS in both adults and children. A three-month tapering induction regimen of once daily for a month, alternate days for the second month and then twice weekly is used. Thereafter, the treatment should be tailored to maintain control of symptoms and signs. Unfortunately, scarring cannot be reversed with treatment but should stop progressing once treatment is started, hence the importance of early diagnosis and treatment. Circumcision in males can be very helpful in those who have phimosis. However, surgery is not undertaken in women unless there is

severe scarring causing functional problems or a malignancy has developed.

There is a 3–4% risk of developing a squamous cell carcinoma (SCC) in LS. However, appropriate management and good control of disease reduces this significantly. Those who do develop problems usually have atypical features with hyperkeratosis being a particular risk. These patients often respond poorly to treatment and should be monitored carefully in a specialist clinic. Any atypical areas should be biopsied.

Lichen planus

LP is one of the inflammatory dermatoses where genital involvement is frequent. In those who present with classic cutaneous LP, genital lesions will be found in about 25% of men and 50% of women. Three main types of LP occur on the genital skin.

1. *Classic (papulosquamous) LP*. The lesions are very similar to the flat-topped violaceous papules seen elsewhere. These are generally seen on the shaft of the penis and the outer labia majora, but can affect the mucosal surfaces and Wickham's striae are often seen at the edge. Oral lesions are common in this type. The lesions may be pruritic but can be asymptomatic.
2. *Erosive LP*. The lesions in erosive LP are erythematous glazed areas seen at the vestibule ([Figure 21.8](#)) or on the glans penis ([Figure 21.9](#)). Scarring can lead to alteration of the normal anatomy. A variant of erosive LP is recognised – the vulvo-vaginal-gingival or peno-gingival syndrome. Erosions on the walls of the vagina can lead to vaginal scarring preventing intercourse. The patients may have disease at other sites including the lacrimal ducts, auditory meati, and oesophagus.
3. *Hypertrophic LP*. This is rare but is important as there is a risk of malignant change in this type of LP. Thickened nodules develop which are extremely itchy.

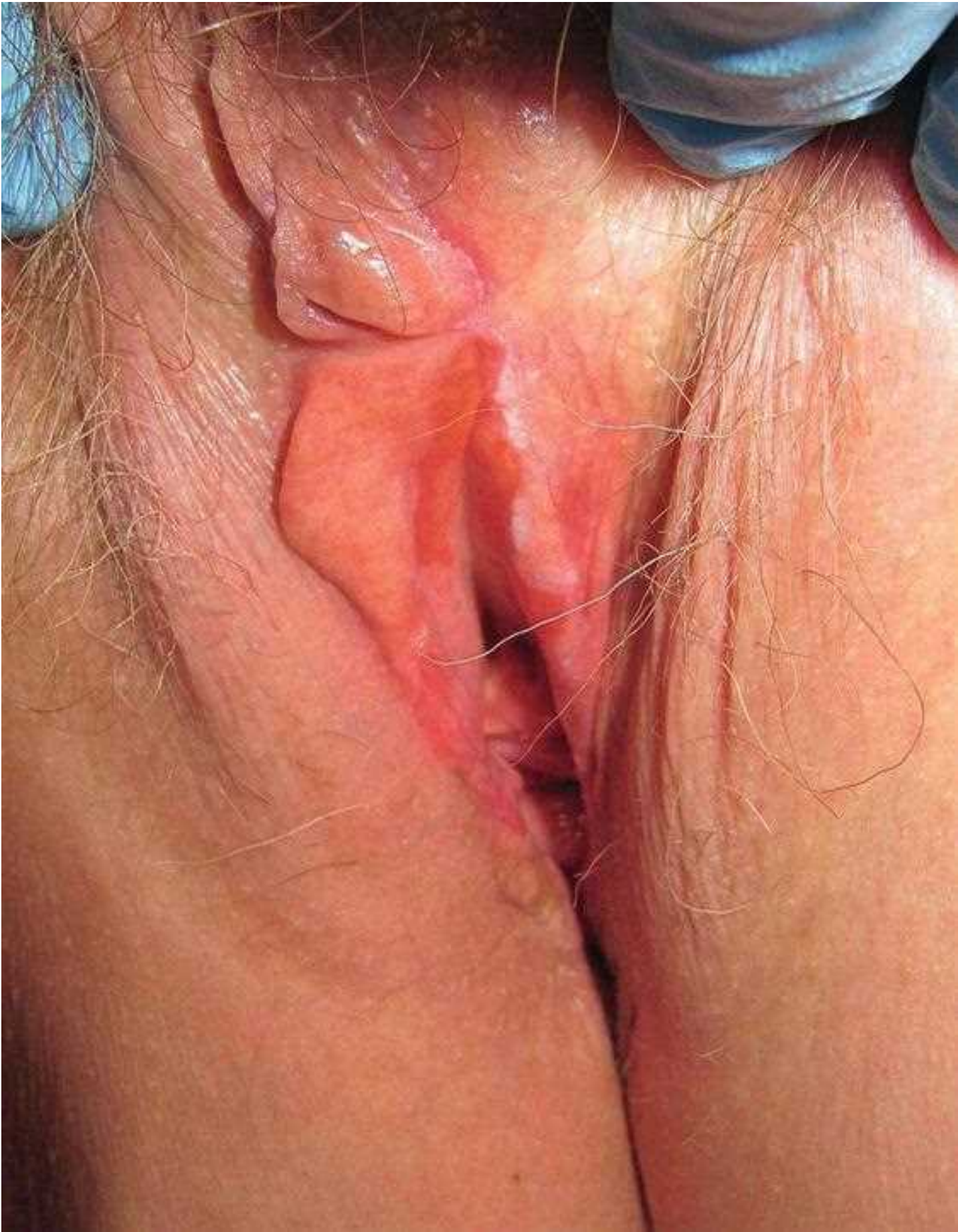

Figure 21.8 Erosive vulval lichen planus with vestibular erosions and architectural change.

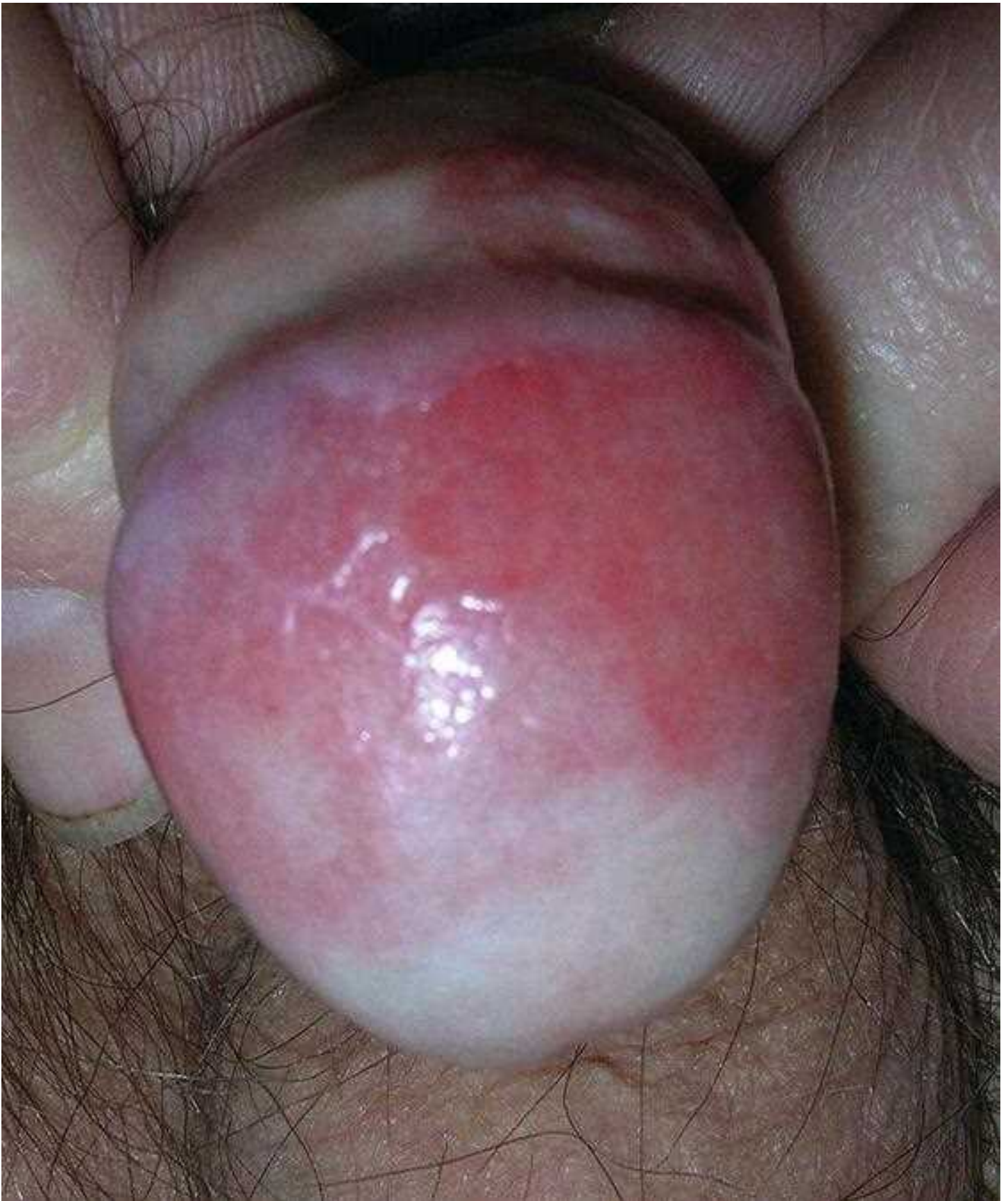

Figure 21.9 Erosive lichen planus of glans penis.

The first-line treatment of LP is an ultra-potent topical steroid used initially for three months as for lichen sclerosus. Patients often require ongoing treatment and those with erosive LP need specialist management to monitor and treat potential complications from scarring. Systemic agents including hydroxychloroquine and mycophenolate have been used.

Other inflammatory dermatoses

Autoimmune bullous disease

Pemphigus vulgaris and bullous pemphigoid can involve the genitalia as part of more generalised disease. Mucous membrane pemphigoid is a specific entity which specifically involves mucous membranes. The immunofluorescence pattern is identical to that seen in bullous pemphigoid. Scarring can occur similar to that seen in LS and LP.

Linear IgA disease is uncommon but the childhood form (chronic bullous disease of childhood) usually starts on the genital and peri-genital skin. Crops of blisters, often in an annular pattern, are seen. Deposition of IgA in a linear pattern at the basement membrane zone is diagnostic.

Manifestations of systemic disease

Behçet's disease

Behçet's disease is a multisystem syndrome without any diagnostic tests and so the diagnosis is clinical supported by scoring systems. Oral ulceration is always present and at least two other manifestations must be present. These include genital ulceration, arthritis, ocular lesions, folliculitis, and pathergy. The genital ulcers occur on the labia majora, scrotum, and glans penis. They are typically larger than aphthae and heal with scarring.

Crohn's disease

Crohn's disease of the ano-genital skin can occur with or without gastrointestinal involvement. Deep 'knife-cut' fissures, ulcers, oedema are characteristic features. Perianal and natal cleft involvement with tags and fissures is common. Treatment includes oral antibiotics, systemic immunosuppression, and biologics such as adalimumab and infliximab. Patients need multidisciplinary care.

Acrodermatitis enteropathica

This eruption with characteristic erythematous, eroded lesions around the peri-oral and genital skin occurs mainly in children and is due to zinc deficiency. The cutaneous lesions resolve rapidly with zinc supplementation.

Reiter's syndrome

This is a reactive triad of arthritis, conjunctivitis, and psoriasiform circinate lesions (circinate

balanitis) preceded by an infection such as *Shigella* or non-gonococcal urethritis. It is extremely rare in females.

Acanthosis nigricans

The typical hyperpigmented, velvety plaques may affect the inguinal folds but lesions are likely to be present at other sites.

Ulcers

The investigation of a patient presenting with a genital ulcer starts with a good history. In addition to the usual information, details of the sexual history and travel are particularly important as several sexually transmitted infections can present with ulceration. The causes of genital ulcers are seen in [Table 21.1](#).

Table 21.1 Causes of genital ulceration.

| | |
|--------------------------------------|--|
| Infection – sexually transmitted | Syphilis, chancroid, herpes simplex, lymphogranuloma venereum, donovanosis |
| Infection – non-sexually transmitted | Epstein–Barr virus, herpes zoster, tuberculosis, amebiasis |
| Drug eruptions | Erythema multiforme, toxic epidermal necrolysis, fixed drug eruption |
| Inflammatory | Behçet's syndrome, Crohn's disease, Lipschutz ulcer, aphthae |
| Trauma | Trauma, dermatitis artefacta |
| Malignancy | SCC, BCC, cutaneous lymphoma, melanoma |

Aphthous ulcers

Aphthous ulcers, identical to those seen in the mouth occur on the vulva, but are rarely seen in males. Painful superficial ulcers with an erythematous rim and sloughy base are seen primarily on the inner labia majora. Healing occurs within a few days but a moderately potent topical steroid once daily can aid resolution.

Lipschutz ulcer

These acute ulcers are only seen in young females. Large, painful ulcers appear on the inner labia majora and rapidly enlarge over about 24 hours. There is frequently a history of an upper respiratory tract infection or flu-like illness in the preceding 10 days and they are probably a reactive phenomenon. A short course of prednisolone 10–15 mg/day for a week is very helpful together with adequate pain relief. Healing without scarring occurs in about three weeks.

Drug eruptions

The genital skin can be involved in severe drug eruptions such as erythema multiforme and toxic epidermal necrolysis. A fixed drug eruption may present on the genital skin, more commonly in males. Bullae and ulceration can occur. The problem may be intermittent as it is often related to medication taken as needed e.g. non-steroidal anti-inflammatory drugs, fluconazole.

Pigmentation

Changes in the normal pigmentation of the genital skin are common. Post-inflammatory hypo- or hyperpigmentation is often seen, particularly after classic type LP and psoriasis. Genital lentigines can be seen as part of rare syndromes e.g. LAMB (lentigines, atrial myxoma, and blue naevi).

Melanosis

Melanosis is common on the genital skin and occurs in males and females. There is an increase in the melanin in the basal melanocytes but no increase in the numbers of melanocytic cells. The appearances are often alarming with very dark, irregular areas of pigmentation which may be multiple ([Figure 21.10](#)). A biopsy should always be done as the histological features are characteristic. There is no evidence of progression to melanoma.

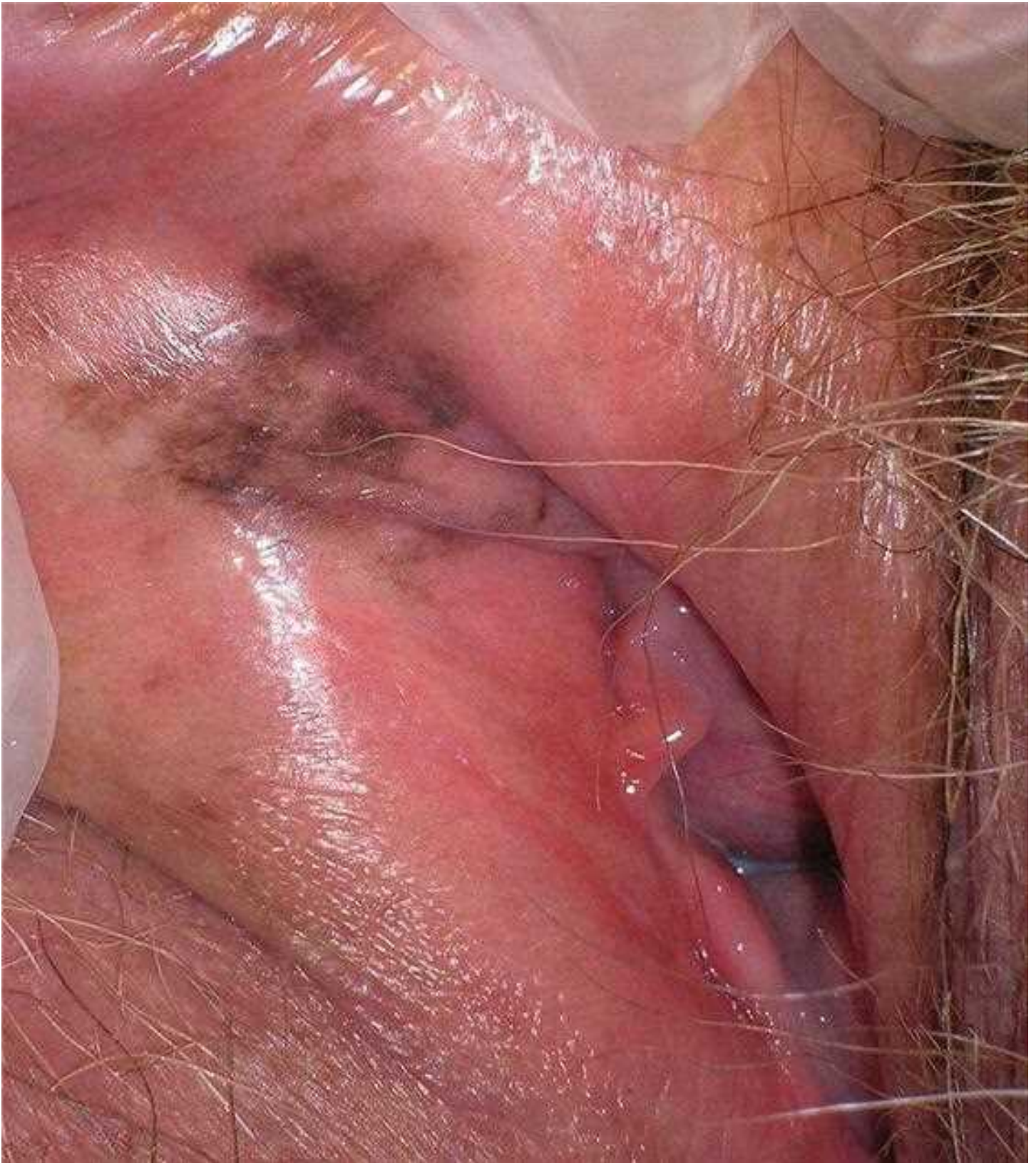

Figure 21.10 Vulval melanosis – irregular pigmentation inner labia.

Genital naevi

Naevi at genital sites are often atypical both in their clinical and histological appearances. Expert histological examination is vital to prevent the mis-diagnosis of melanoma.

Infections

Common genital infections will be discussed here but in any patient where a sexually transmitted infection is suspected or confirmed, referral to a genito-urinary clinic for diagnosis, management, and contact tracing should be done.

Pubic lice

Infection with pubic lice causes intense pruritus. Egg cases may be seen on the pubic hair. Treatment is with topical permethrin.

Scabies

The genital skin is frequently involved in scabies and the inflamed, pruritic papules on the shaft of the penis or outer labia majora are characteristic of the infestation. Treatment is with topical permethrin.

Candidiasis

Candida species are part of the normal flora in females and infection occurs when the balance of the flora is upset e.g. after antibiotics or in immunosuppressed patients. Over 90% of candidiasis is caused by *Candida albicans*. A cheesy discharge is seen, with marked pruritus and soreness if the skin fissures. Generally topical treatment with azole compounds will be sufficient but for those with a dermatosis where the infection is secondary, oral treatment with fluconazole 150 mg stat dose is more effective.

Herpes simplex infection

Groups of painful vesicles which resolve within seven days are typical. The infection is not always sexually transmitted and both herpes simplex viral (HSV) 1 and 2 viruses are seen. The problem is recurrent in some patients and a prolonged course of aciclovir 200–400 mg bd can be helpful. In immunosuppressed patients, herpetic lesions can be atypical and mimic malignancy.

Human papilloma virus (HPV) infection

Many different HPV types affect the ano-genital area. Types 6 and 11 cause 90% of genital warts and types 16 and 18 are associated with the majority of vulva intra-epithelial neoplasia (VIN). The incidence of both warts and VIN has been shown to be reduced dramatically in vaccinated populations. Genital warts are usually small warty papules but they may become confluent and can be very widespread in immunosuppressed patients. Treatments involve cryotherapy, imiquimod, or surgical ablation.

Intra-epithelial neoplasia

There are two pathways to the development of malignancy on the genital skin. The most common type is related to the oncogenic types of HPV, mainly 16 and 18, which can cause cellular changes leading to VIN or penile intra-epithelial neoplasia (PeIN). Known risk factors are immunosuppression and smoking. Several terms have been used to describe this previously such as Bowenoid papulosis, erythroplasia of Queyrat, etc. These terms should no longer be used. In females, the term high risk squamous intra-epithelial lesion has recently been introduced.

The lesions of HPV-associated intra-epithelial neoplasia are often polymorphic in appearance, ranging from flat pigmented macules to widespread erythematous and warty hyperkeratotic plaques ([Figure 21.11](#)). They are sometimes unifocal, but more commonly multifocal and similar changes can be found in the vagina, cervix, and perianal skin ([Figure 21.12](#)). These areas should be examined routinely, and management of these patients needs a multidisciplinary approach with gynaecologists, urologists, and colo-rectal surgeons.

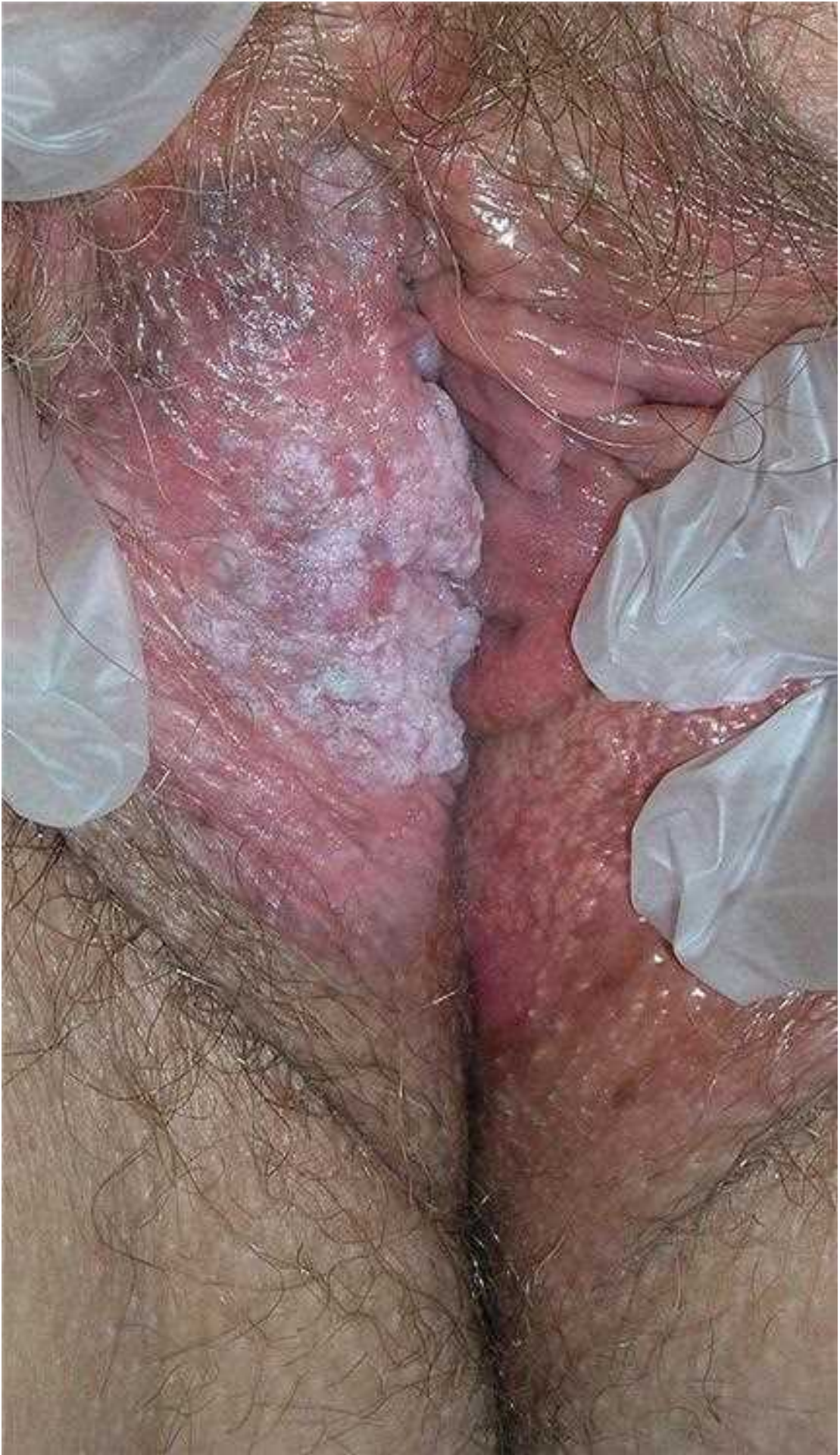

Figure 21.11 Vulval intra-epithelial neoplasia with white hyperkeratotic plaques.

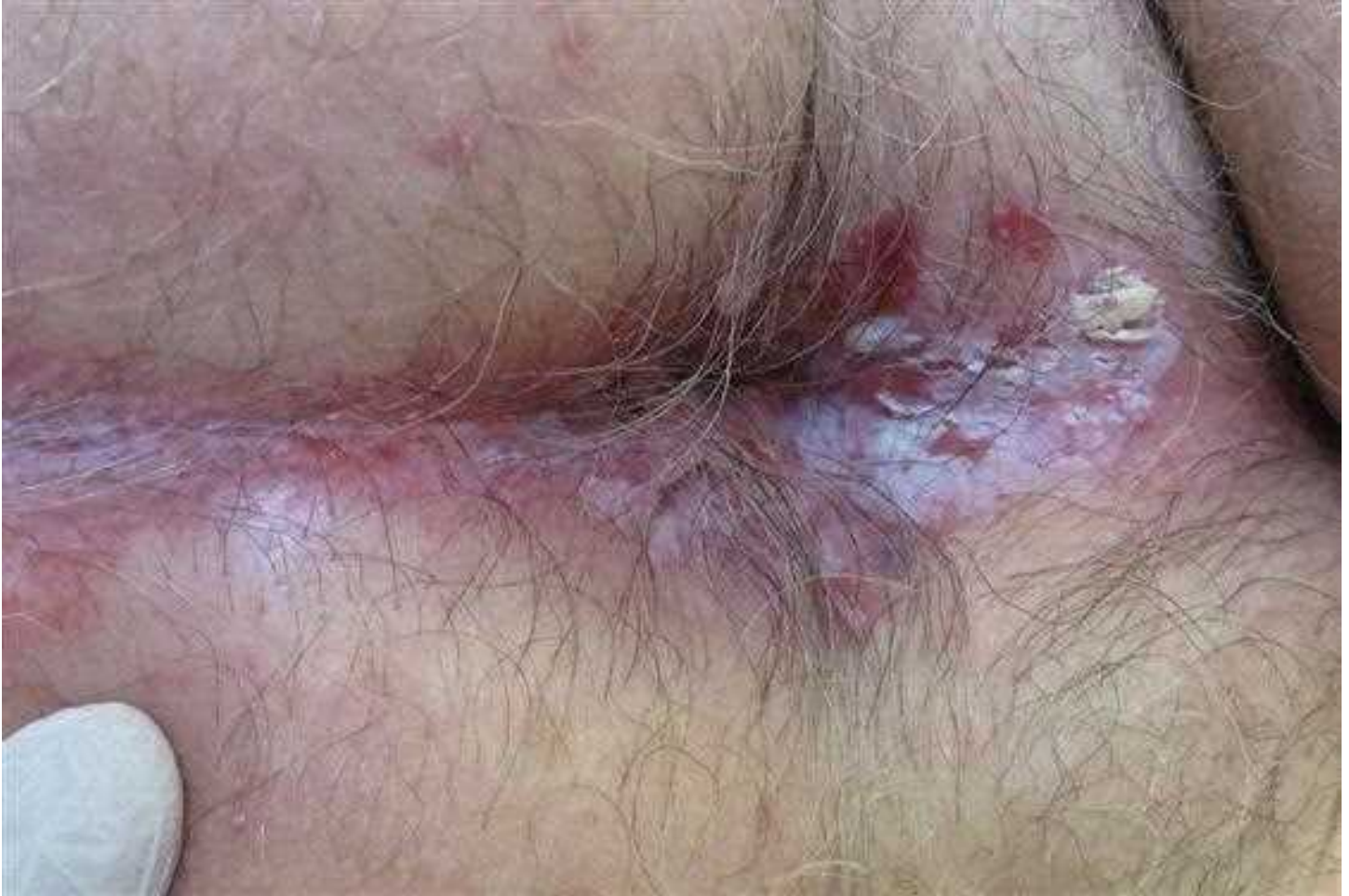

Figure 21.12 Perianal HPV-associated intra-epithelial neoplasia.

Treatments includes surgery for smaller unifocal lesions or medical treatment for larger multifocal areas with 5% imiquimod. Patients should be referred to a specialist clinic.

The second pathway is the development of malignancy on a background of a chronic inflammatory disorder such as lichen sclerosus or LP. This is much less common and differentiated VIN or PeIN may be seen initially, but this may be difficult to diagnose histologically and very clear clinico-pathological correlation is vital. These patients usually have atypical clinical features with hyperkeratosis and erosions and do not respond to treatment as well as those with uncomplicated disease. There are subtle changes at the basal layer but the rest of the epidermis is differentiating normally. There is a very high risk of those with differentiated VIN or PeIN progressing to an invasive SCC and these lesions should always be excised.

Extra-mammary paget's disease

Paget's disease is an in situ adenocarcinoma and disease of the nipple is well known. The genital area is the most common site involved with extra-mammary Paget's disease (EMP)

and although rare, affects females much more than males. It usually occurs in the elderly and the diagnosis is often delayed so that patients may have extensive disease at presentation.

The clinical appearance is that of erythematous moist plaques which can mimic other inflammatory dermatoses. However, the plaques are often asymmetrical and in patients where a clinical diagnosis of psoriasis is made but who do not respond to treatment, there should be a low threshold for biopsy.

Histology is diagnostic but clinico-pathological correlation is important as the histological differential diagnosis includes Bowen's disease and melanoma. Specific immunohistochemistry shows cytokeratin 7 and 20, but negative S100.

In contrast to mammary Paget's, which has a very high risk of associated breast cancer, only about 20% of patients with EMP will have an associated neoplasm which may involve the genital, gastrointestinal, or renal tracts. Investigation for this should be undertaken when EMP is diagnosed.

The treatment is challenging as disease is often extensive and recurrence rates with surgery, even with reported clear margins, can be up to 60%. Topical 5% imiquimod can be extremely useful in these patients if tolerated. Radiotherapy and photodynamic therapy are alternatives.

Vulval and penile pain

Patients with conditions that erode, fissure, or ulcerate will present with pain and appropriate treatment for the underlying problem should resolve the symptoms. However, neuropathic pain can affect the genitalia where the skin looks normal and there is nothing seen to explain the symptoms of burning, discomfort, and pain. Itch is not a symptom. This has been studied more in females than males where it is termed vulvodynia. This is defined as 'pain in the vulva of more than three months duration with no obvious inflammatory, infective, or neurological cause'.

There are two classic symptom patterns but there may be overlap between the two in some patients.

1. *Localised provoked vulval pain* – These patients are usually young, with a gradual onset of pain with pressure on the vulva i.e. with sexual intercourse or inserting tampons. Wearing tight clothing or touching the area gives a similar pain. Removing the pressure resolves the pain. Most women localise the symptoms to the vestibule, hence the term 'vestibulodynia'. The diagnosis can be confirmed by touching the vestibule with a cotton tip where the symptoms are easily reproduced.
2. *Generalised spontaneous vulval pain* – These patients tend to be older and the pain is generalised affecting the whole vulva and is often constant although may fluctuate in severity. It may radiate to the buttocks and thighs. There are no provoking factors.

In both groups, there is a strong association with other conditions including irritable bladder, irritable bowel syndrome, fibromyalgia, migraine, and temporo-mandibular joint

dysfunction.

Treatment should be targeted at the neuropathic nature of the problem and involves local anaesthetic preparations, nerve modulating agents e.g. tricyclics, gabapentin. Expert physiotherapy can be helpful for those with secondary vaginismus.

Further reading

Bunker, C.B. and Porter, W.M. (2016). Dermatoses of the male genitalia. In: *Rook's Textbook of Dermatology*, 9e (ed. C.M. Griffiths, J. Barker, T. Bleiker, et al.). Chichester: Wiley-Blackwell.

Lewis, F.M., Bogliatto, F., and van Beurden, M. (2016). *A Practical Guide to Vulval Disease – Diagnosis and Management*. Wiley-Blackwell.

Lewis, F.M., Tatnall, F.M., Velangi, S.S. et al. (2018). British Association of Dermatologists guidelines for the management of lichen sclerosus, 2018. *British Journal of Dermatology* 178 (4): 839–853.

CHAPTER 22

Benign Skin Tumours

Rachael Morris-Jones

Guy's and St Thomas' NHS Foundation Trust, London, UK

OVERVIEW

- Skin cells can proliferate in a benign controlled manner, known as *hyperplasia*, or as an uncontrolled, dysplastic growth to produce cancer.
- Benign skin lesions are common and generally have a well-defined appearance. Any sudden increase in size, irregularity, or bleeding may suggest malignant change.
- Benign skin lesions are usually asymptomatic but may bleed persistently (pyogenic granuloma) or cause pain (poroma). Some benign tumours are disfiguring and cause psychological problems.
- Benign pigmented tumours include seborrhoeic keratoses, freckles (lentigines), and skin tags.
- Pigmented naevi may be congenital or acquired. The vast majority remain benign. However, change in colour, texture, size, or new satellite lesions developing may indicate malignant change.
- Benign vascular lesions include port wine stain, cavernous haemangioma, and naevus flammeus neonatorum.
- The most common acquired vascular lesions are spider naevi, Campbell de Morgan spots (cherry haemangiomas) and pyogenic granulomas.

Introduction

Any cell within the skin can proliferate to form a benign lump or skin tumour. In general, a proliferation of cells can lead to hyperplasia (benign overgrowth) or dysplasia (malignancy/cancer). This chapter considers benign lesions, which are harmless, but may cause symptoms such as pain, itching, and bleeding or may be a cosmetic nuisance. Many benign skin lesions are pigmented, which can lead to an elevated level of anxiety for patients and occasionally medical staff as they may be confused with melanoma.

Pattern recognition plays a valuable role in the correct diagnosis of benign skin lesions. The clinical features of any lesion can be a useful guide to distinguishing the benign from the malignant. However, if there is uncertainty as to the nature of any skin lesion after clinical

examination then a diagnostic biopsy for histology is essential. The adage ‘if in doubt cut it out’ may be appropriate if there is diagnostic uncertainty.

Benign cutaneous lesions are almost universally present on the skin of adults and are therefore so common that most are ignored and are never brought to medical attention. Nonetheless, the sudden appearance of new lesions, itching/pain, bleeding, or the unsightly nature of lesions may bring them to the attention of the affected individual and thus the local practitioner. Reassurance is usually all that is needed. However, in some instances benign skin lesions need removal, for example, if they bleed persistently (pyogenic granulomas), they repeatedly catch on clothing (protuberant benign moles) or they cause pain (poroma on the foot). Some individuals are deeply affected by the cosmetic appearance of their benign skin lesions and these may therefore need removal on psychological grounds.

From a medical practitioner's point of view, we need to decide whether a lesion can be safely left or should be treated. This chapter concentrates on the correlation between clinical and pathological features of common benign tumours which should ease their diagnosis ([Table 22.1](#)). [Chapter 23](#) examines premalignant and malignant skin tumours.

Table 22.1 Differential diagnosis of common benign skin tumours.

| Clinical features | Differential diagnoses |
|--------------------------|--|
| Pigmented | Seborrhoeic keratoses, dermatosis papulosa nigra, freckles (lentigines), solar lentigo, melanocytic naevus, blue naevus, Mongolian blue spot, dermatofibroma, apocrine hidrocystomas |
| Vascular | Naevus flammeus, strawberry naevus, port wine stain, spider naevi, Campbell de Morgan spots, pyogenic granuloma |
| Papules | Skin tags (fibroepithelial polyps), milia, sebaceous gland hyperplasia, dermatosis papulosa nigra, syringomas, trichoepitheliomas, apocrine hidrocystomas |
| Nodules | Dermatofibroma, lipoma, angioliipoma, epidermoid cyst, pilar cyst, pilomatrixoma, poroma, intradermal naevus, apocrine hidrocystomas |
| Plaques | Naevus sebaceus, epidermal naevus, inflammatory linear verrucous epidermal naevus (ILVEN), seborrhoeic keratoses |

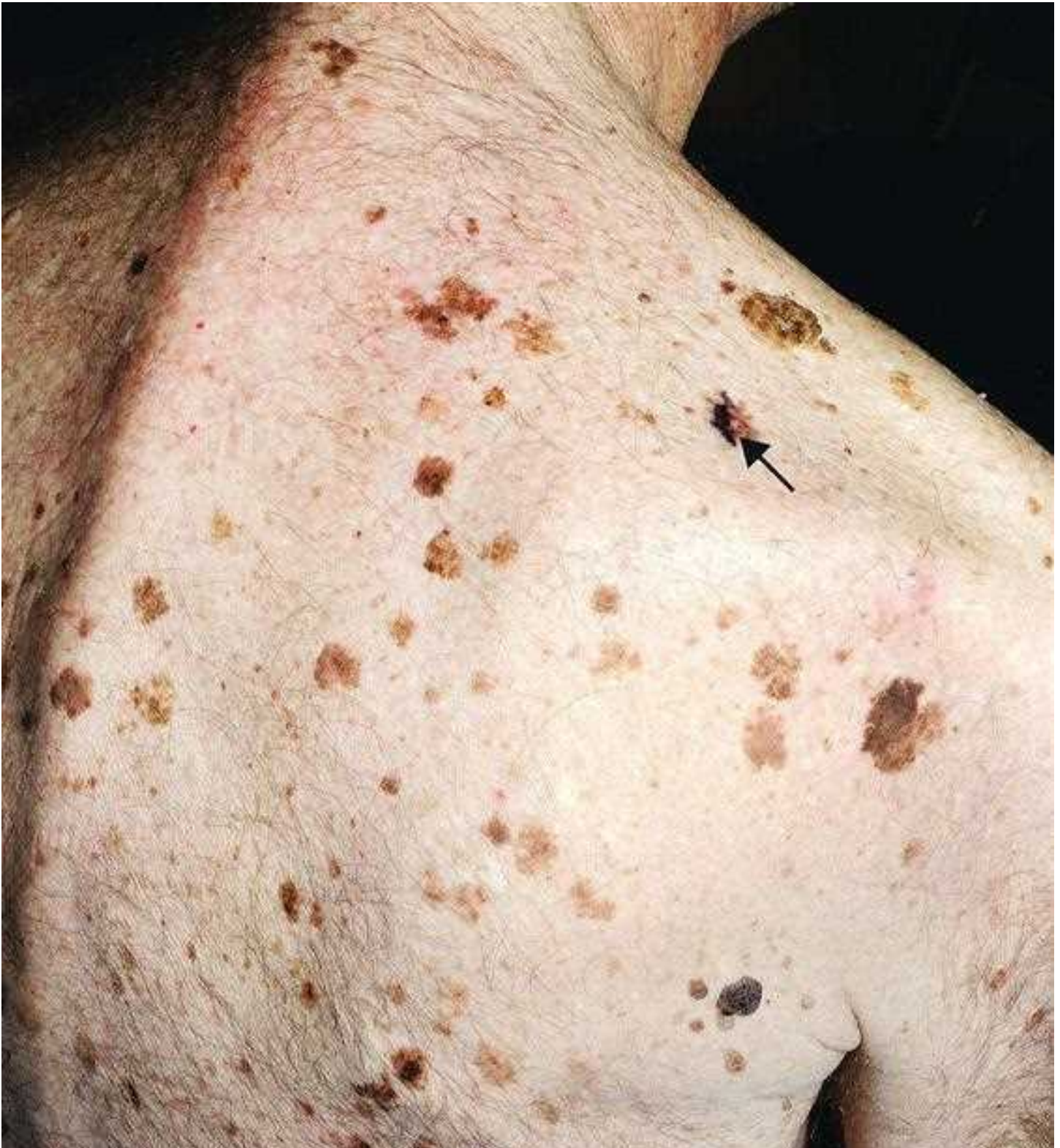Pigmented benign tumours

Seborrhoeic keratoses

Seborrhoeic keratoses are more common with increasing age. Lesions are most frequently seen on the trunk, face, and neck in sizes varying from 0.5 to 3.0 cm in diameter. Seborrhoeic keratoses may be barely palpable, protuberant, or pedunculated. They always have a warty dull surface. Colours are highly variable from pale tan through to dark brown ([Figure 22.1](#)).

When deeply pigmented, inflamed, or growing they can appear to mimic some malignant characteristics which may cause anxiety. Seborrhoeic keratoses, however, have some characteristic features, which include:

- well-defined edge ([Figure 22.2](#))
- warty, papillary surface, often with keratin plugs
- raised above surrounding skin to give a 'stuck on' appearance.



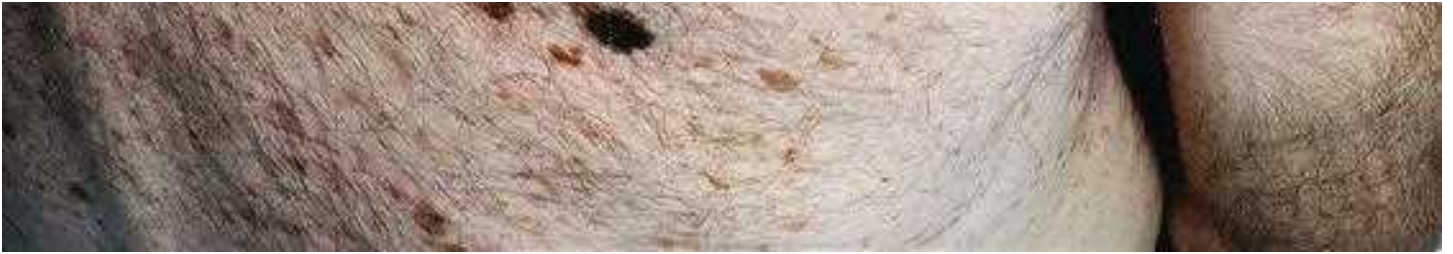
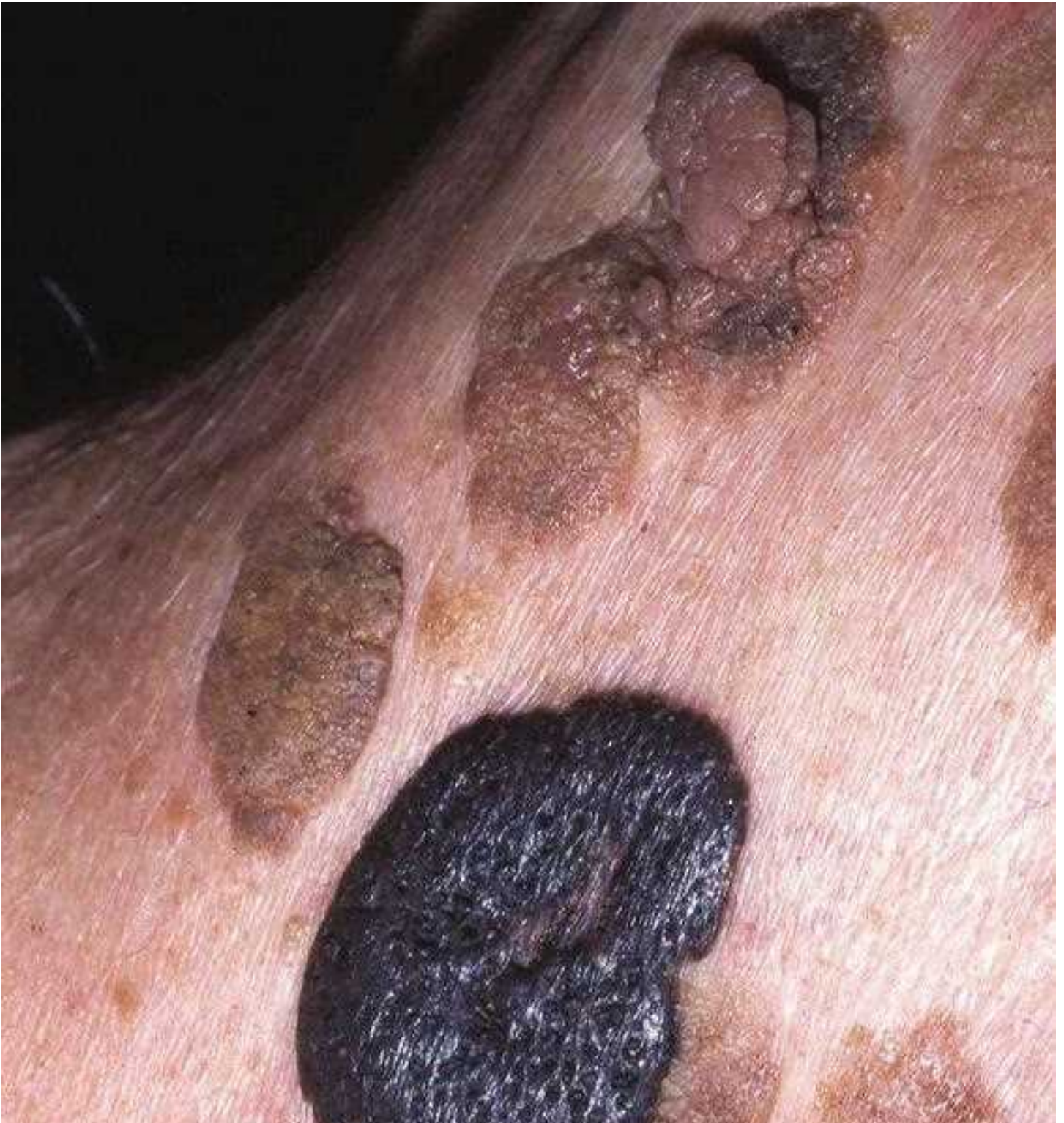
Figure 22.1 Seborrheic keratoses on the trunk, there is a melanoma on the right upper shoulder (shown by the arrow).



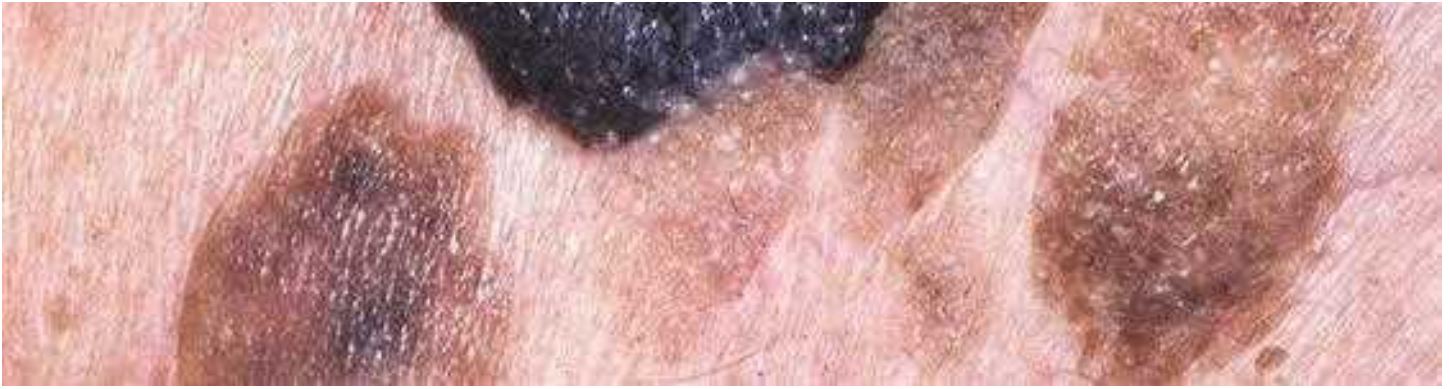
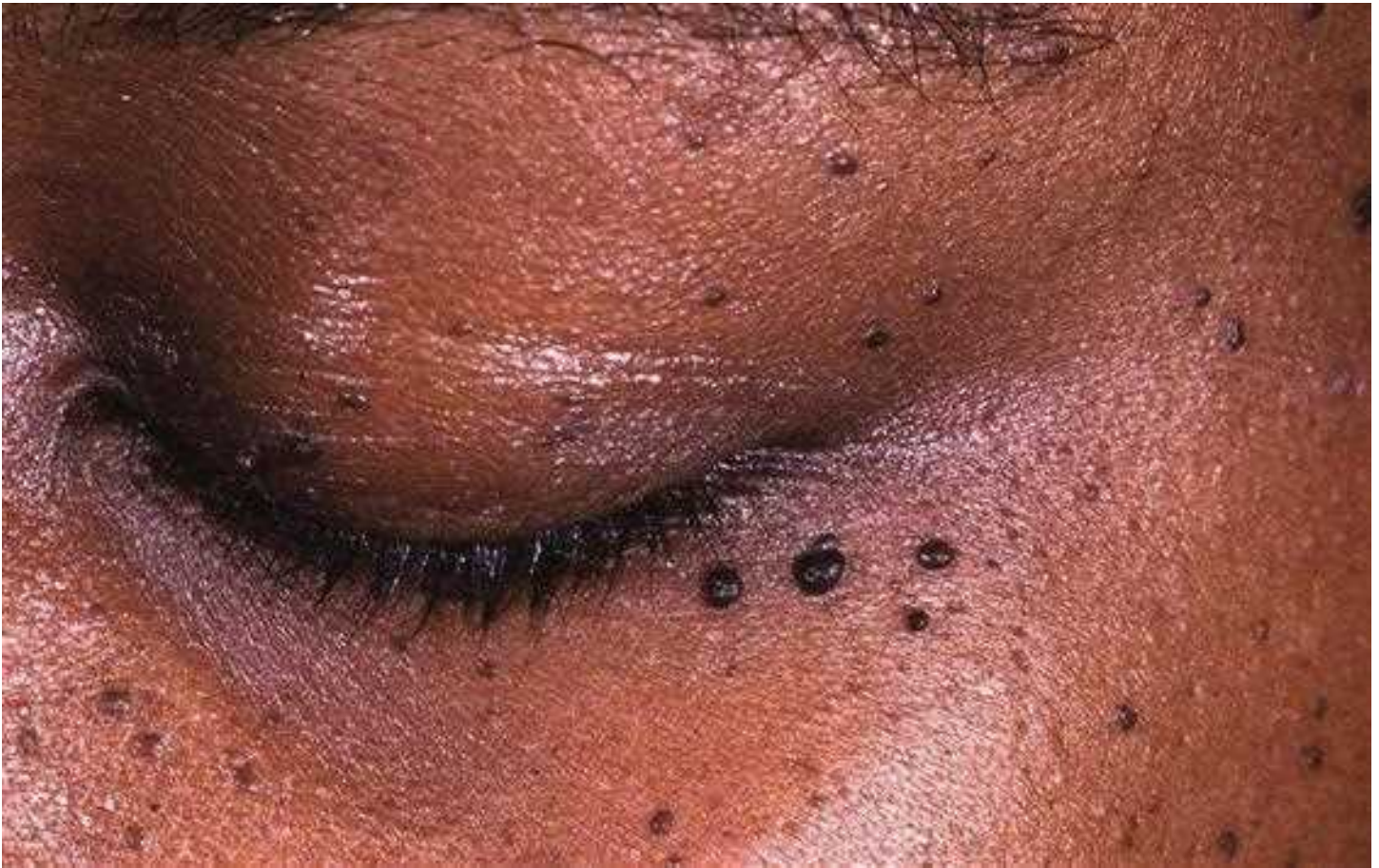
Figure 22.2 Seborrheic keratoses.

Dermatosis papulosa nigra (DPN)

These lesions are usually multiple small pigmented papules seen on the face of adults with black skin ([Figure 22.3](#)). Dermatitis papulosa nigra (DPN) is very common with up to one-third of individuals with skin type VI affected. Frequently, there is a strong familial tendency towards the condition. Typically, the lesions occur on the cheeks, forehead, neck, and chest. Histologically they resemble seborrheic keratoses; however, some experts think they arise from a developmental defect in the follicular unit. No treatment is needed, but if patients find the lesions cosmetically unacceptable then light electrodesiccation and gentle curettage can effectively remove lesions. New ones will inevitably form, however (see [Chapter 24](#)).



[Figure 22.3](#) Dermatitis papulosa nigra.

Skin tags

Skin tags may be pigmented but are usually straightforward to diagnose. They are frequently multiple and more commonly occur at sites of occlusion where the skin may be rubbed by skin or clothing/jewellery in the axillae, neck, groin, and under the breasts ([Figure 22.4](#)). If they are catching on clothing and so on, they can be removed by 'snip/shave' under local anaesthetic.

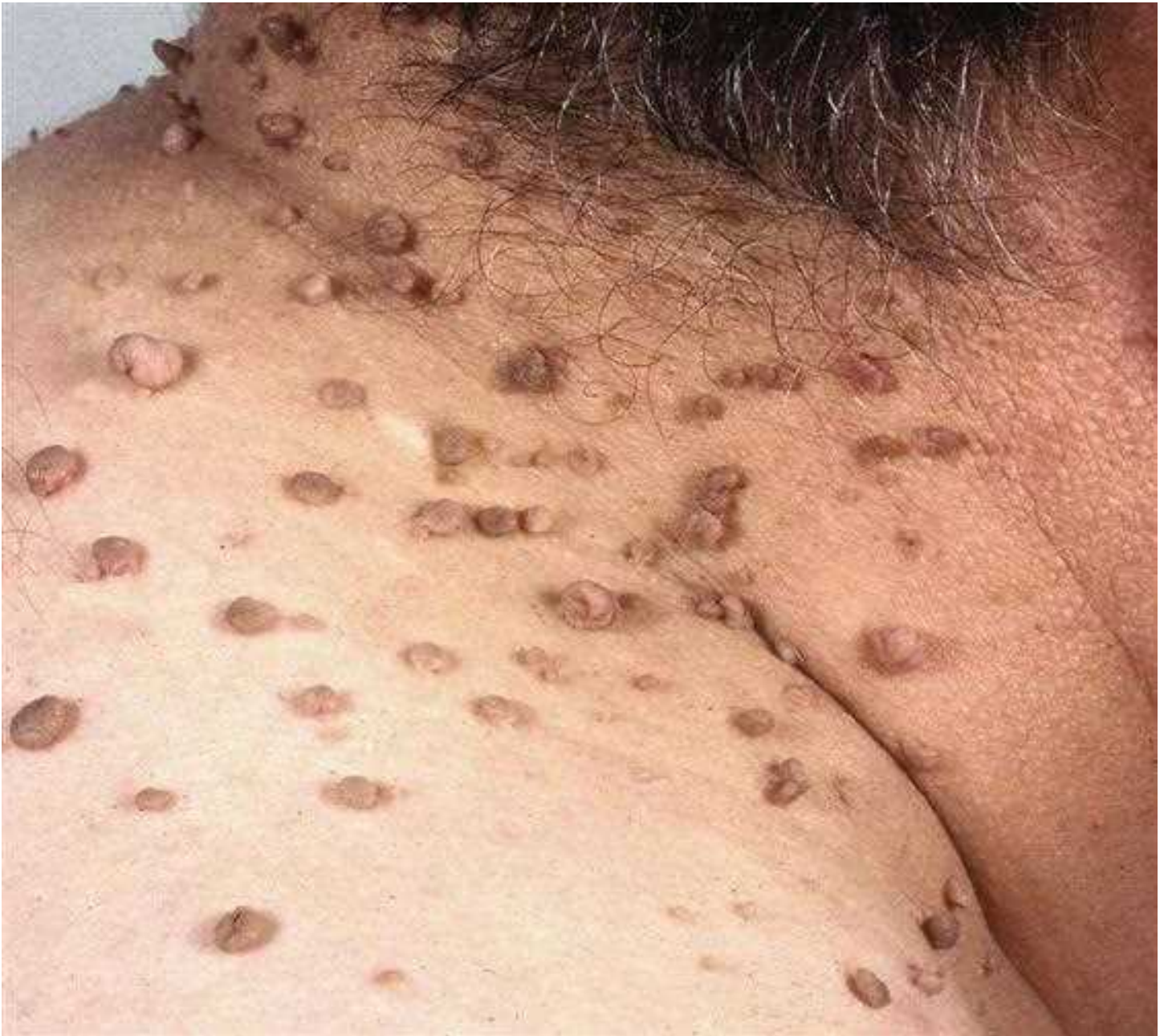

Figure 22.4 Skin tags.

Lentigines (freckles)

Patients often refer to solar-induced freckles as ‘sun spots’ or ‘liver spots’. Lentigines are small macular well-demarcated pigmented lesions that usually occur on sun-exposed skin ([Figure 22.5](#)). They first appear in childhood and generally increase in number with increasing age. Lentigines are more common in individuals with fair rather than dark skin types. The colour of the lentigines varies from pale tan to almost black, which usually corresponds to the amount of melanin pigment produced by the increased number of melanocytes. In contrast to moles where the melanocytes form nests (naevi), the melanocytes in lentigines line up along the basement membrane.

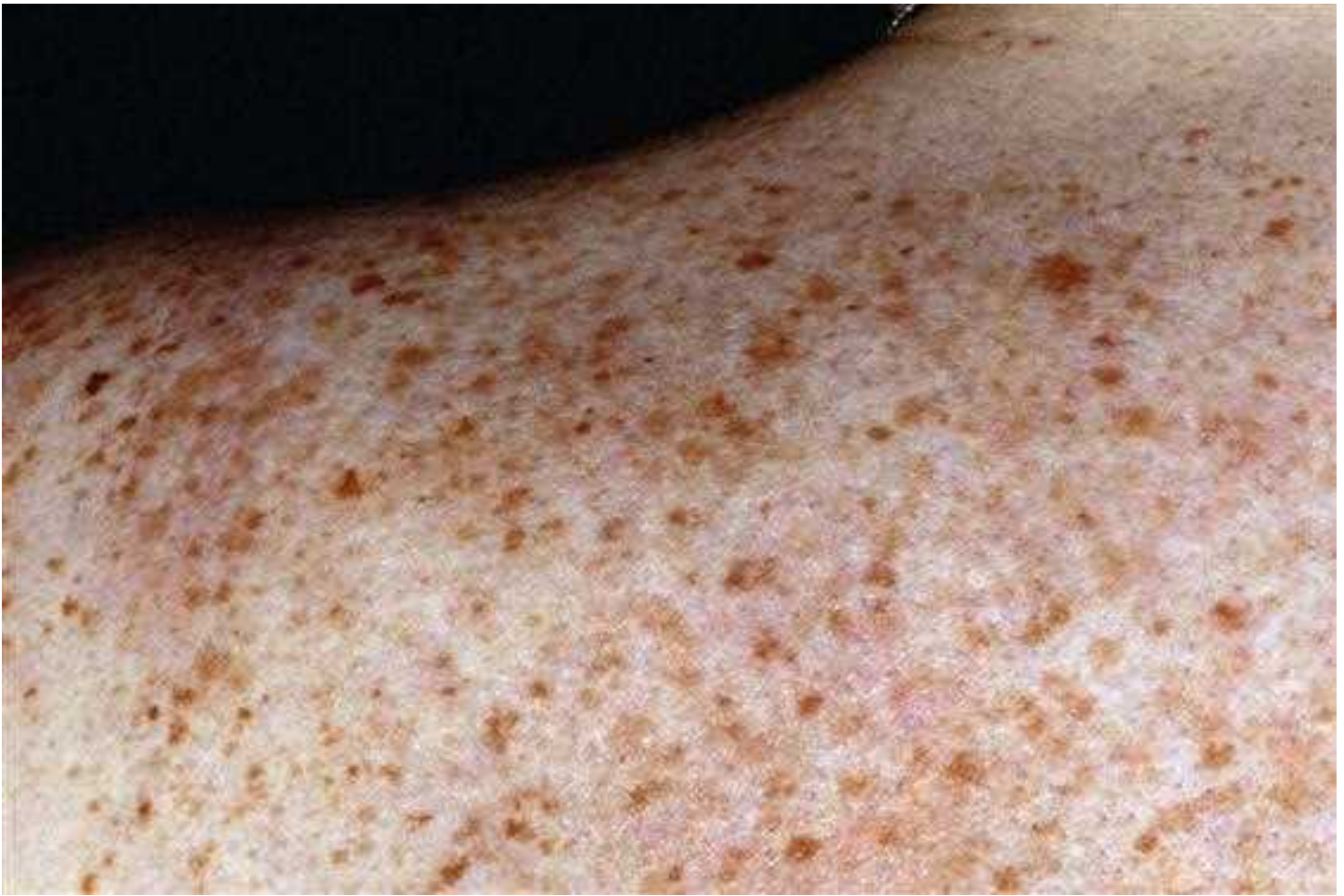

Figure 22.5 Lentigines on upper back.

Benign lentigines may also occur on the lip and genital mucosa. Labial lentigines may be associated with Peutz–Jeghers syndrome (an inherited condition with gastrointestinal polyps), Laugier–Hunziker syndrome (which has associated nail pigmentation) and LAMB (lentigines, atrial myxoma, mucocutaneous myxomas, and blue naevi). In LEOPARD syndrome (lentigines, electrocardioconduction defects, ocular hypertelorism, pulmonary stenosis, abnormal genitalia, retardation of growth and deafness) lentigines are characteristically seen on the neck and trunk. No treatment is usually required for lentigines; however, treatment with liquid nitrogen/laser may help them fade.

Melanocytic naevi

Most moles are benign and can be safely ignored. However, knowing which are potentially harmful or malignant can be difficult for inexperienced practitioners. Clinical features of benign moles will be considered in this chapter to aid their diagnosis. Malignant moles are considered in [Chapter 23](#).

The term *naevi* is derived from the Greek word meaning ‘nest’. A proliferation of melanocytes forms these nests at different levels in the skin resulting in moles. If the nests of melanocytes are confined to the dermoepidermal junction, then the mole is referred to as

junctional naevus, if they are in the dermis only, ‘intradermal naevus’ and if present in the epidermis and dermis, ‘compound naevus’. Naevi may be congenital (‘birth mark’) or acquired, usually in early childhood. The number of moles usually remains static in adulthood with a decline after the sixth decade.

Congenital melanocytic naevi

Between 1% and 2% of neonates have a congenital naevus present at birth. Similar lesions can appear during the first two years of life that look histologically identical to congenital moles. Melanocytes are derived from neural crest cells; during embryogenesis they migrate into the skin and the central nervous system. Congenital naevi are hamartomas that are thought to result from an anomaly of melanocyte development or migration and a high proportion of them contain somatic *BRAF* V600E mutations. Congenital naevi are classified according to their size: small are less than 1.5 cm, medium 1.5–19.9 cm, large 20–40 cm and giant greater than 40 cm in diameter. Congenital naevi usually grow in proportion to the growth of the child, and their colour varies from pale brown to black. With increasing age congenital naevi often develop hair and become more protuberant ([Figure 22.6](#)).

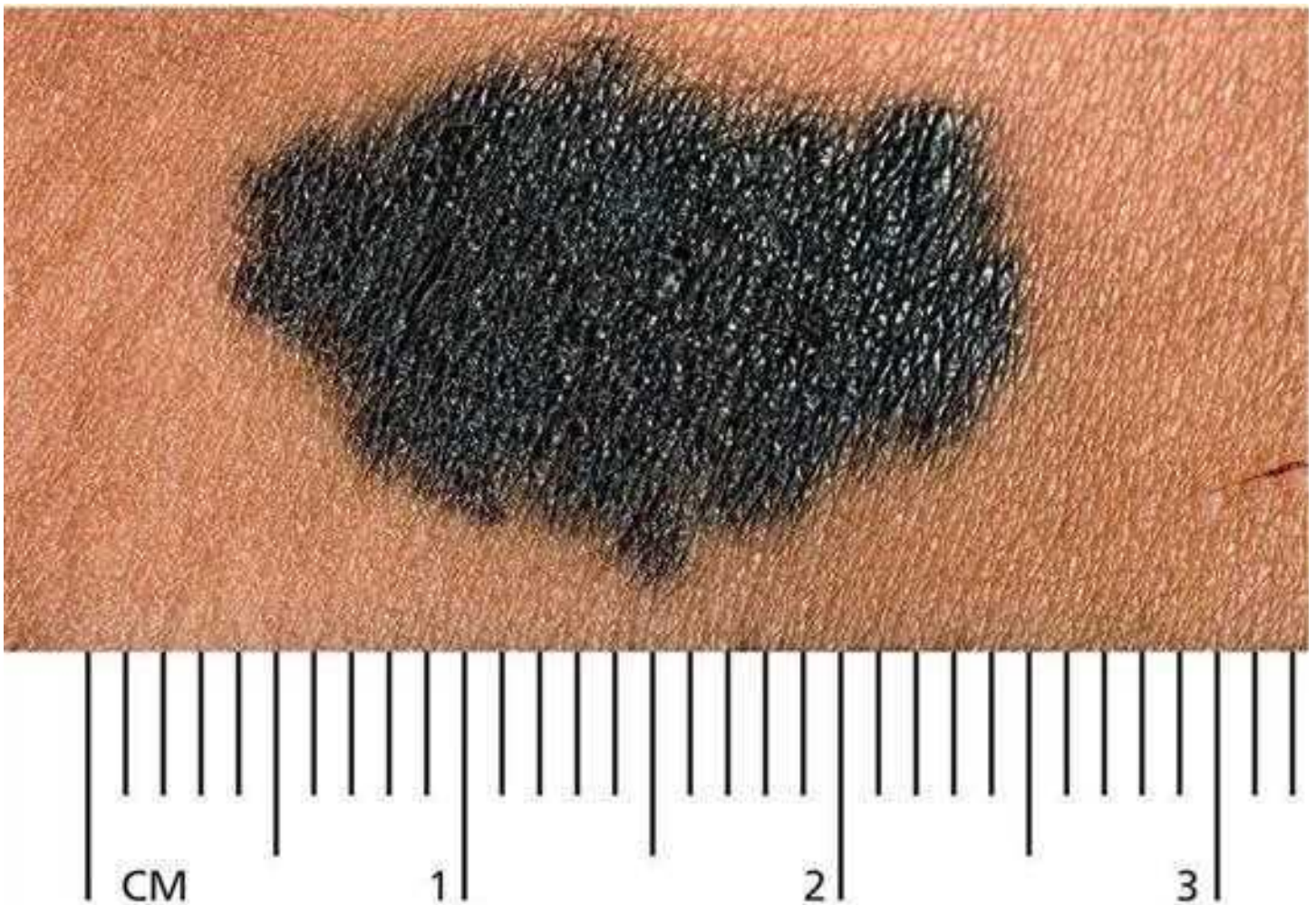

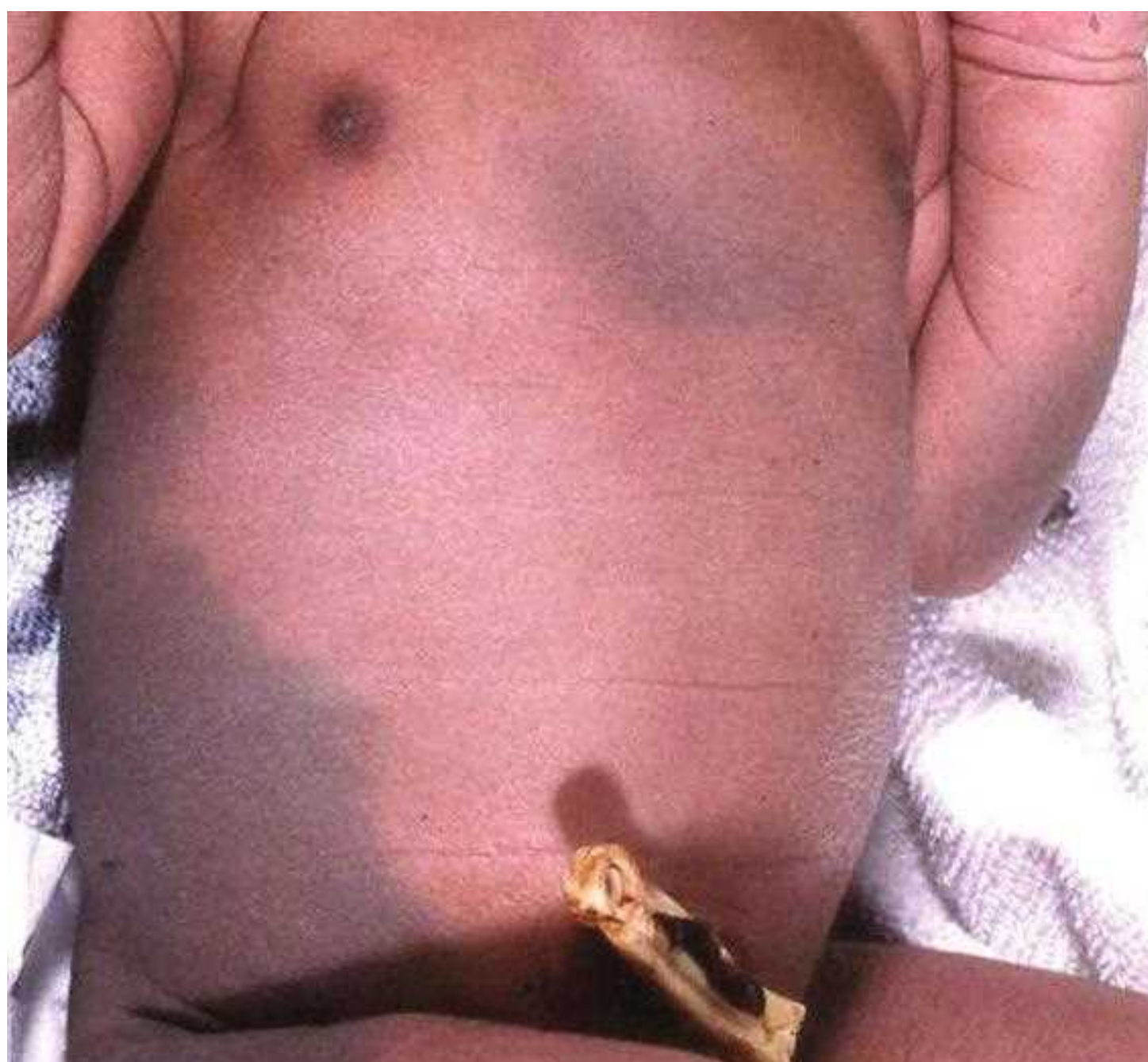Figure 22.6 Congenital melanocytic naevus.

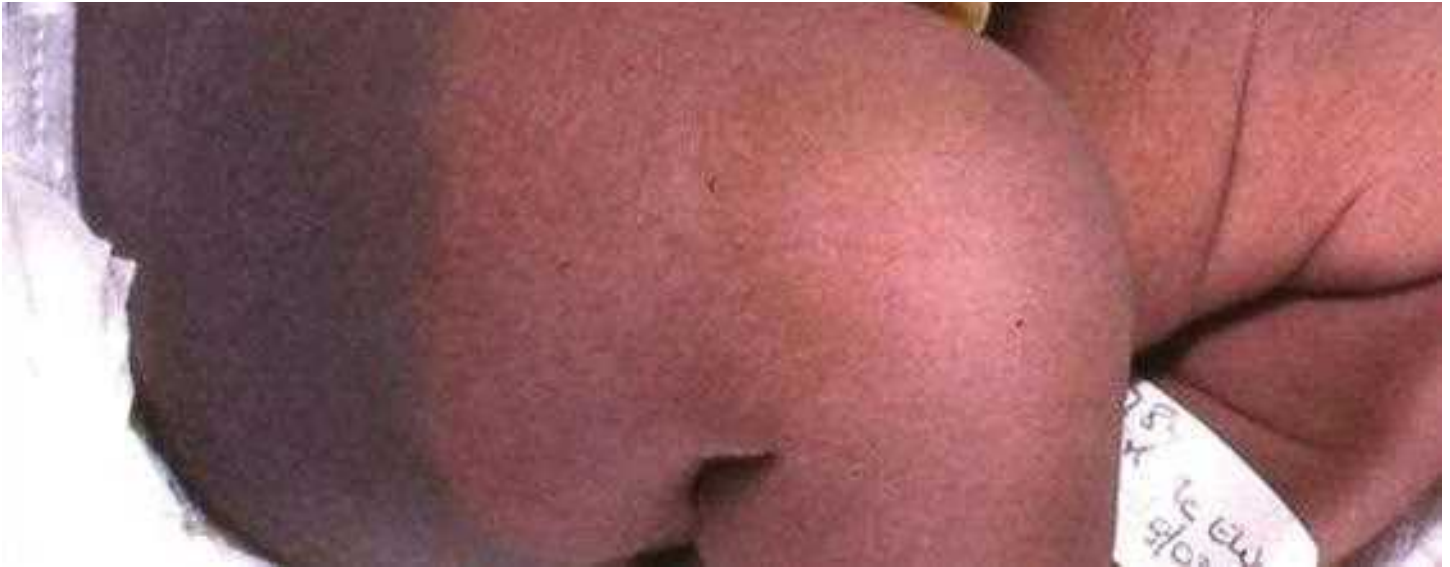Giant naevi can cover a considerable area of the trunk and buttocks, such as the bathing trunk

naevi. The clear majority of them have the somatic gain-of-function mutations in *NRAS* and are more likely than small congenital melanocytic naevi to undergo malignant change (2–5%, with 50% of the risk occurring before age five years).

The majority of congenital naevi are, however, benign. If malignancy is suspected due to a sudden change in size, colour, border, and development of new satellite lesions, then surgical excision would be indicated. Surgical removal of very large lesions may be difficult, and tissue expanders, staged operations and skin grafting are often needed. Attempts at curettage or laser removal have both been advocated as alternatives to excision, but recurrence is more likely.

Mongolian blue spots (Congenital dermal melanocytosis) are benign congenital skin lesions that result from collections of melanocytes deep in the skin, usually present on the back. The lesions are macular and large and may be multiple. The condition is most common in black and Asian skin ([Figure 22.7](#)). The lesions usually fade by age two years.





[Figure 22.7](#) Mongolian blue spot.

Acquired melanocytic naevi

These are moles usually acquired during childhood. The main stimulus to their formation is thought to be solar radiation and a genetic susceptibility. These moles have a variable appearance determined by the depth of the melanocytes and the cellular type.

Junctional naevi are flat macules with melanocytes proliferating into nests that sit along the dermoepidermal junction ([Figure 22.8](#)).

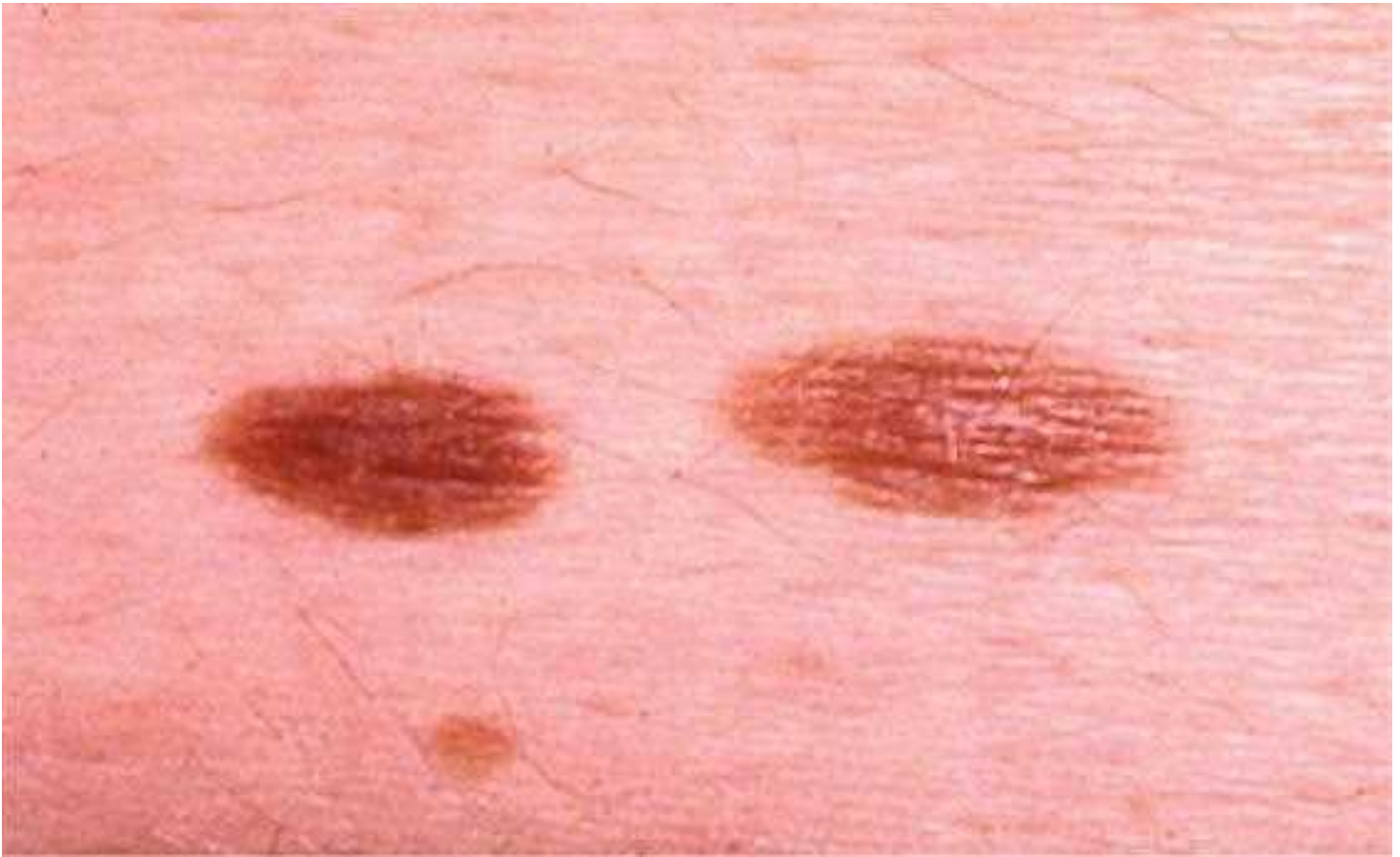

Figure 22.8 Junctional naevus.

Compound naevi have clusters of melanocytes at the dermoepidermal junction and within the dermis. These naevi are raised and pigmented ([Figure 22.9](#)). The surface of the naevus may be thrown into folds because of the melanocyte proliferations, giving a papillary appearance.

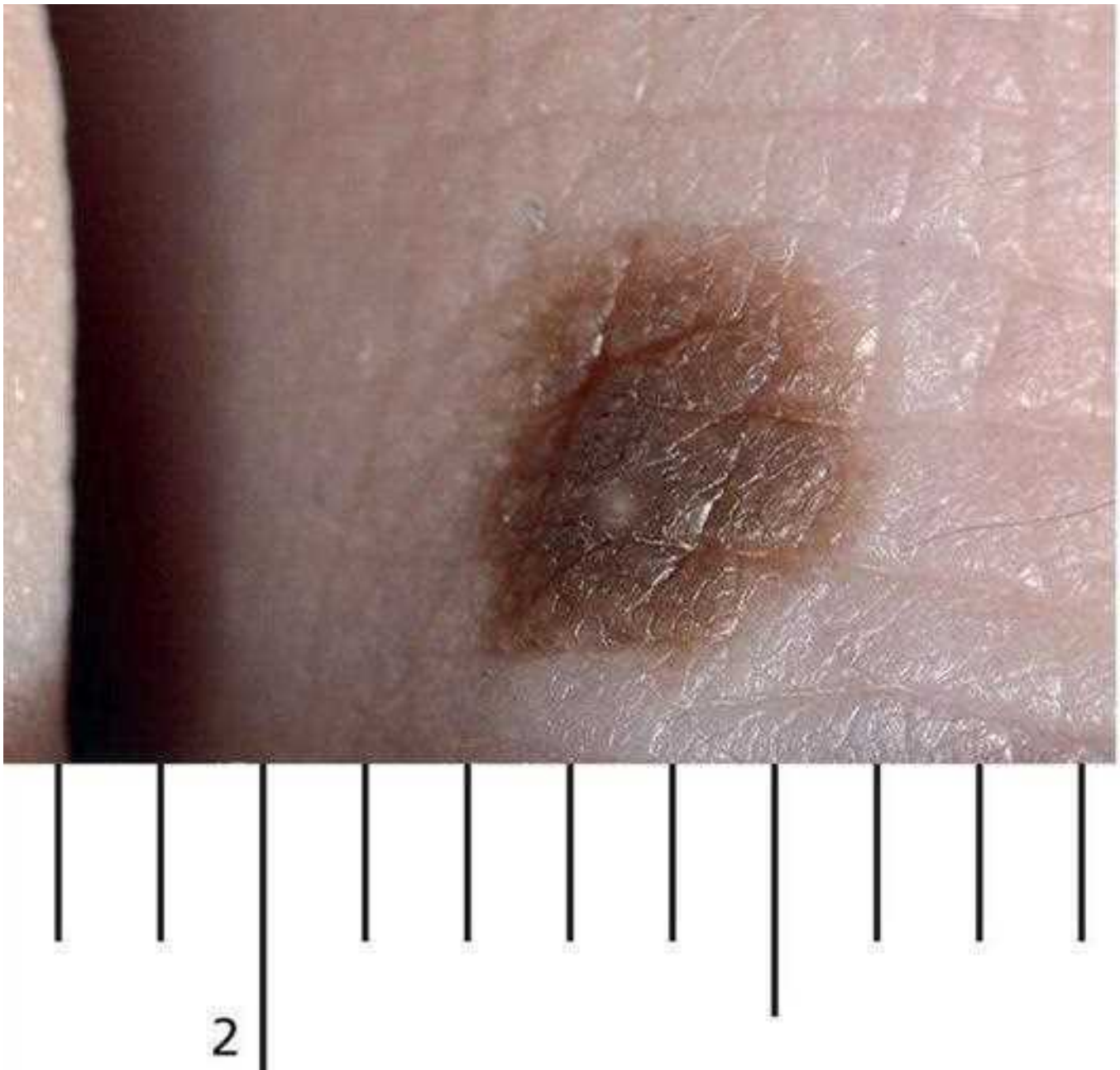
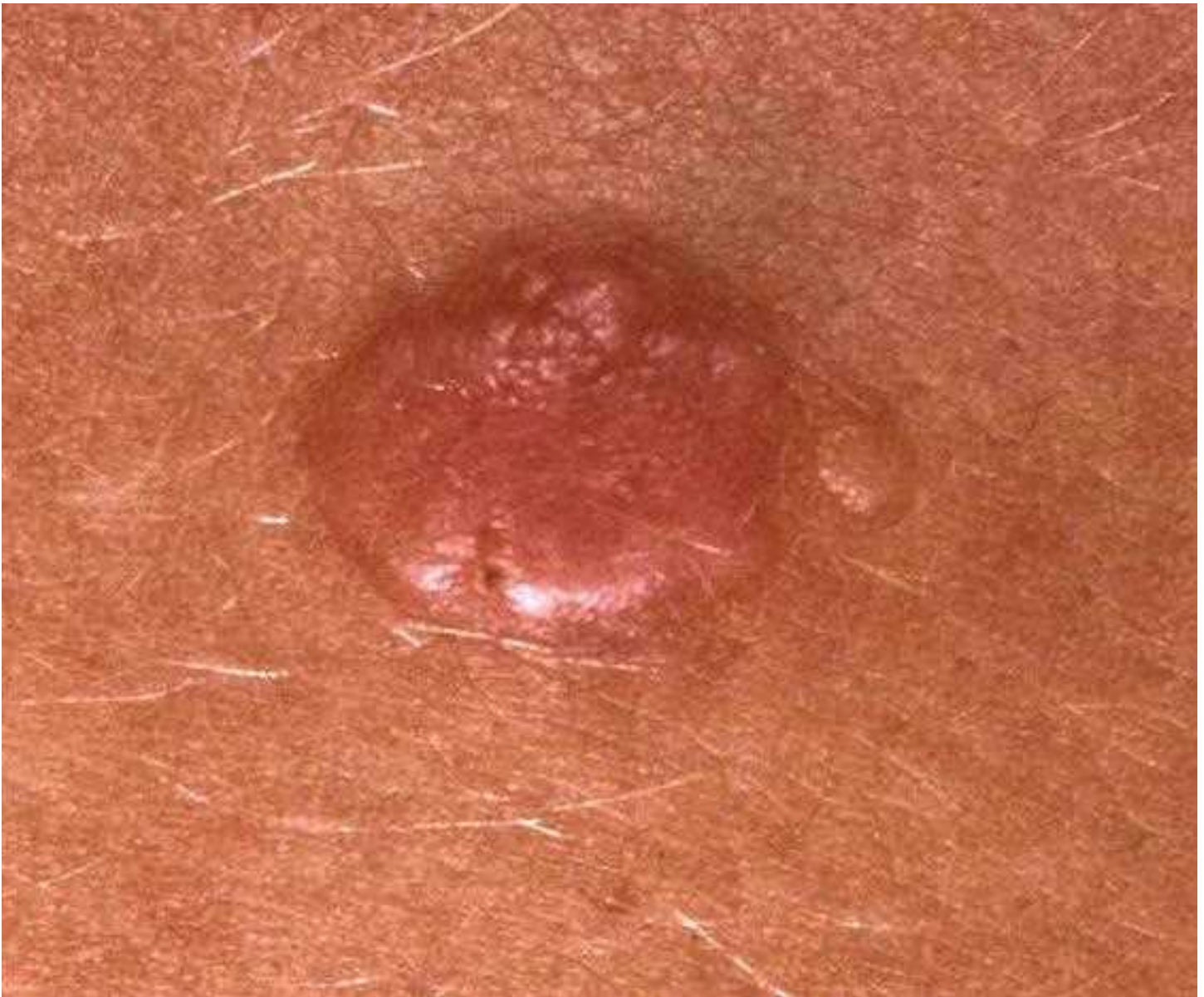

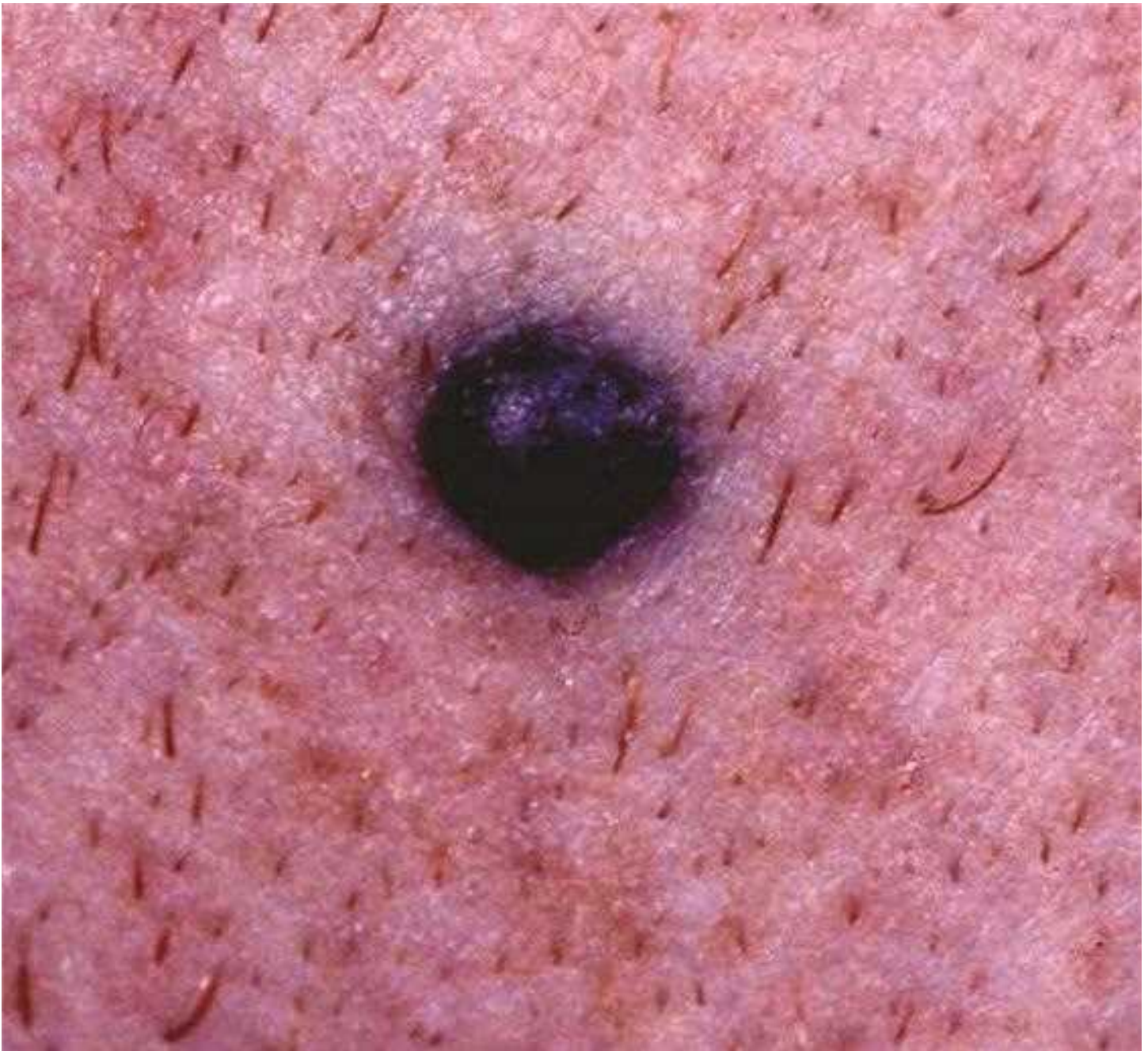Figure 22.9 Compound naevus.

In a purely *intradermal naevus*, the junctional element is lost, and nests of melanocytes are found within the dermis alone. These naevi are frequently non-pigmented and most commonly occur on the face ([Figure 22.10](#)). These moles are raised from the skin surface and may catch on clothing or may cause a cosmetic problem – they may be treated by ‘shave’ of the top portion of the mole under local anaesthetic.



[Figure 22.10](#) Intradermal naevus.

Blue naevus is a benign collection of deeply pigmented melanocytes situated deep in the dermis, which accounts for the deep slate-blue colour ([Figure 22.11](#)).



[Figure 22.11](#) Blue naevus.

Spitz naevus presents as a fleshy pink or pigmented papule in children most commonly on the face or lower legs ([Figure 22.12](#)). It is composed of large spindle cells and epitheloid cells with occasional giant cells, arranged in nests which histologically can resemble melanoma.

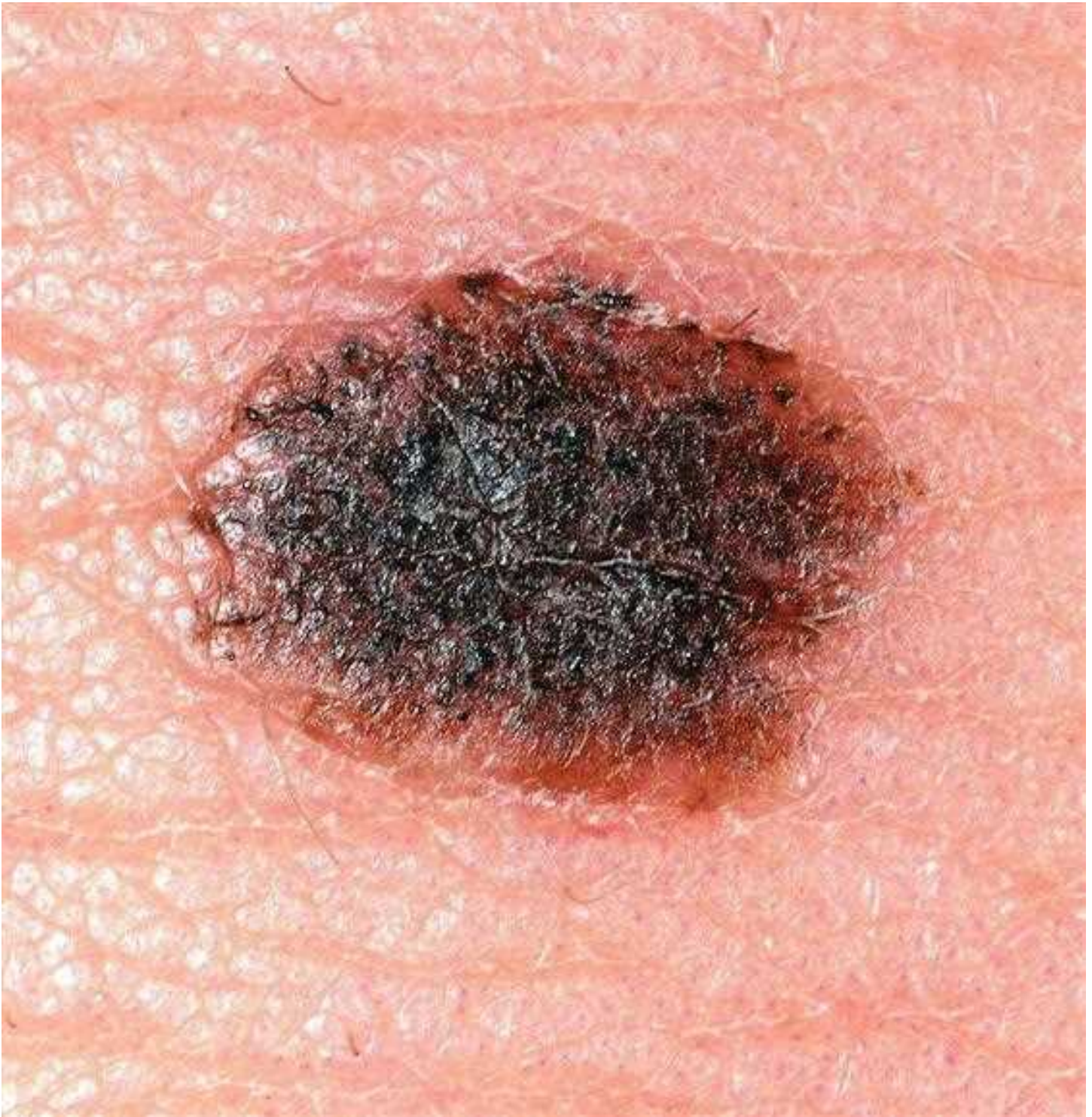

Figure 22.12 Spitz naevus.

Halo naevus consists of a melanocytic naevus with a surrounding halo of depigmentation ([Figure 22.13](#)). Patients may have several halo naevi simultaneously. They are thought to be associated with the presence of antibodies against melanocytes, which can cause the entire naevus to disappear eventually.

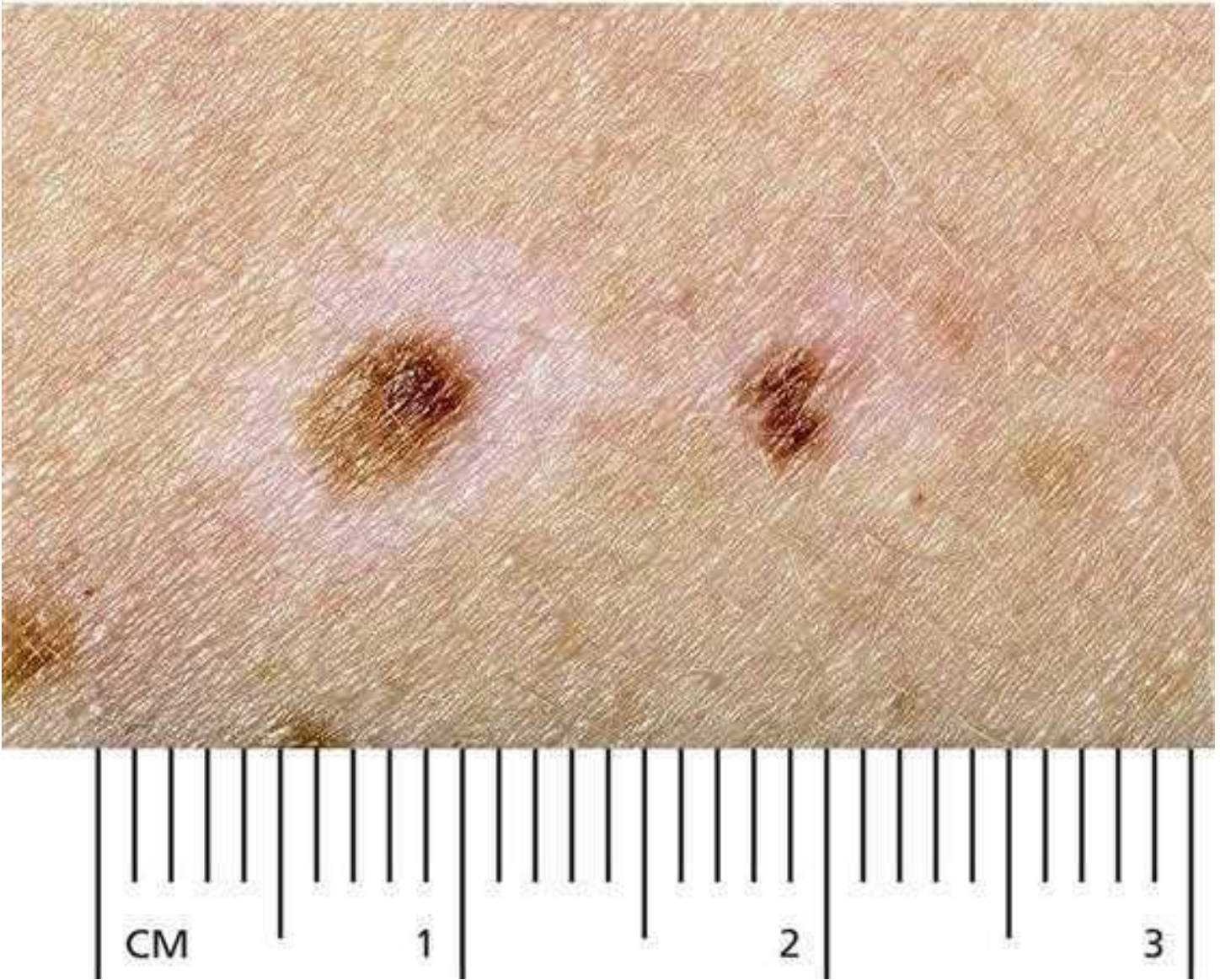
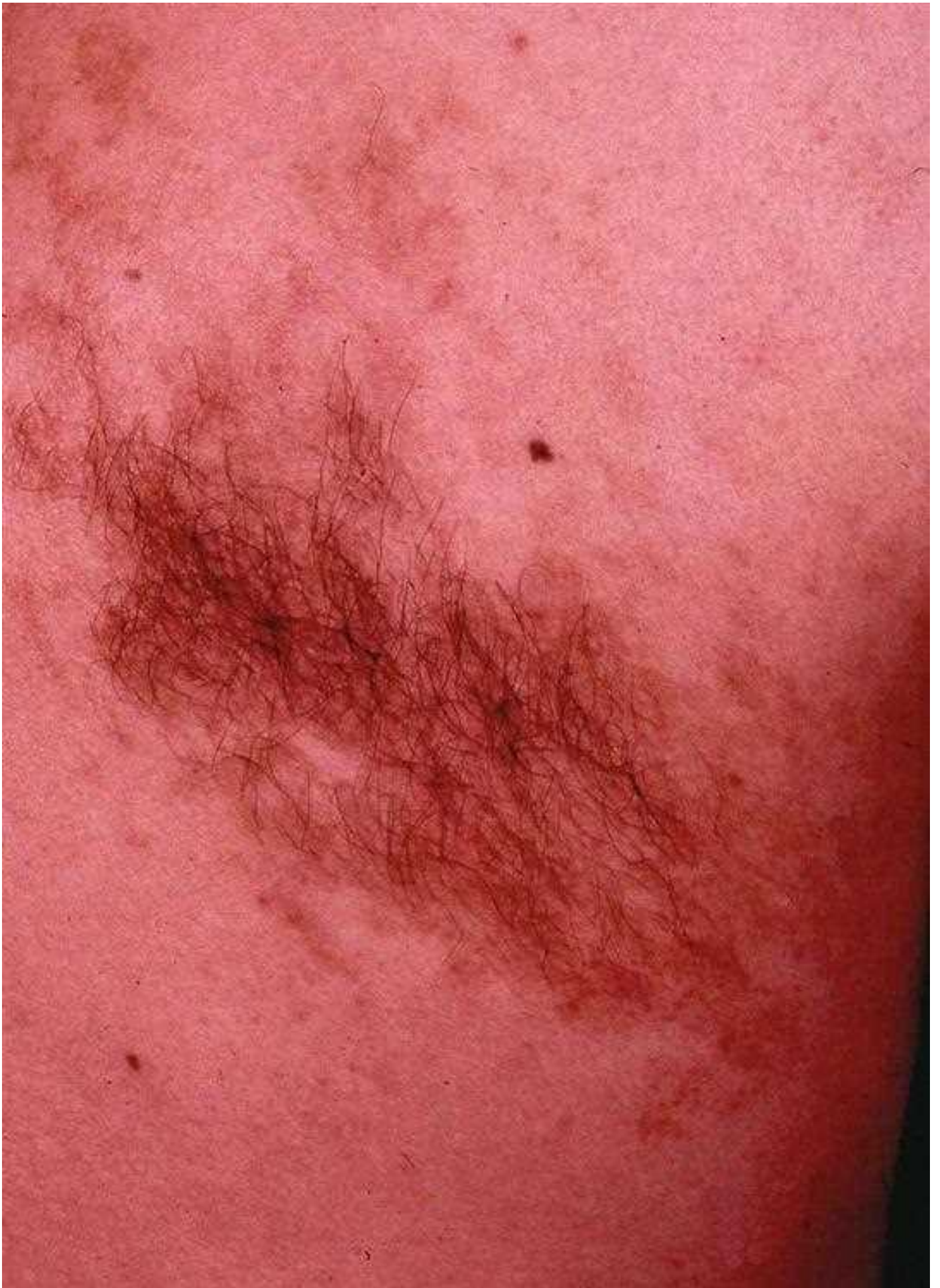
Figure 22.13 Halo naevi.

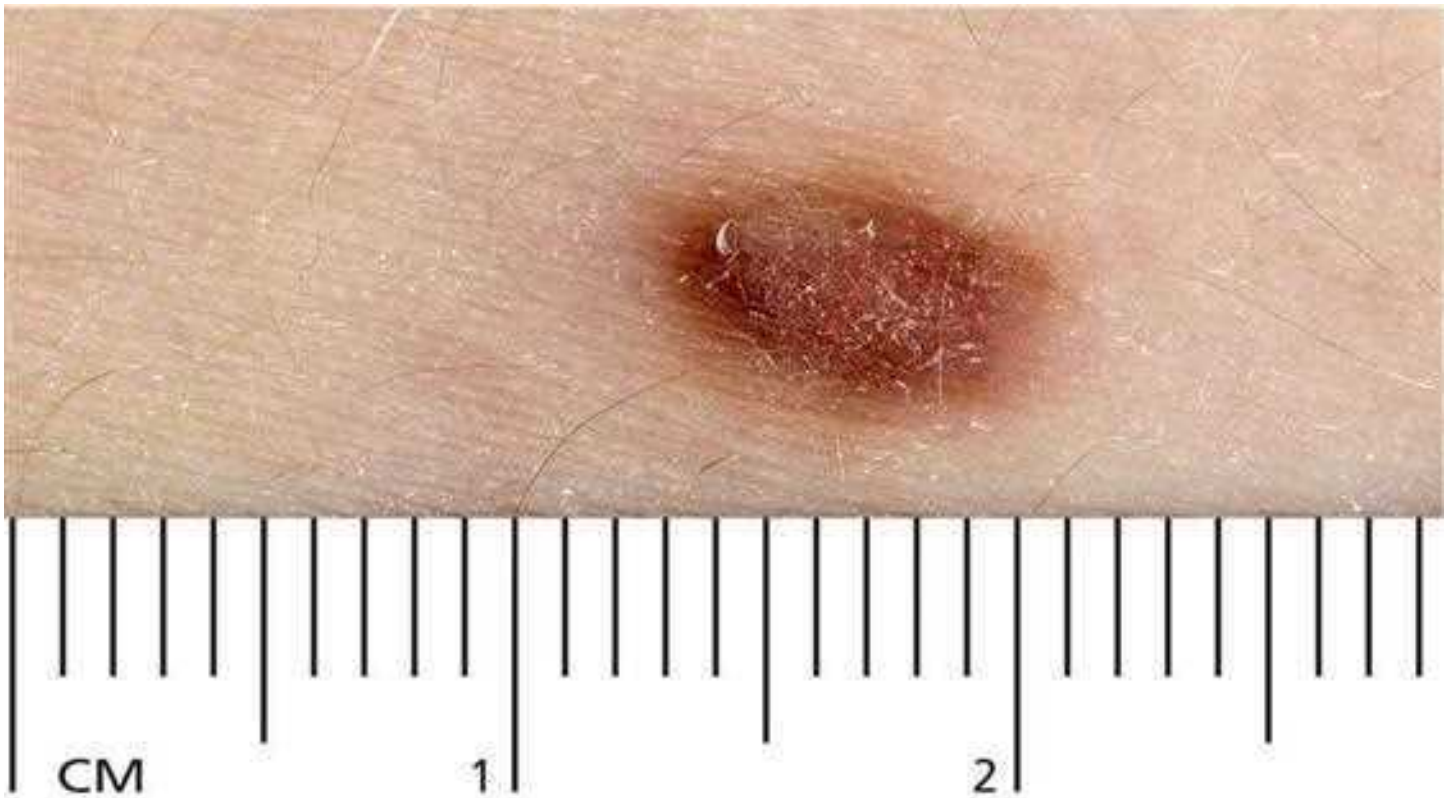Becker's naevus is an area of increased pigmentation, often associated with increased hair growth, which is usually seen on the upper trunk or shoulders ([Figure 22.14](#)). They are more common in males and most frequently appear around puberty therefore androgen stimulation has been hypothesised as the cause.



[Figure 22.14](#) Becker's naevus.

Dermatofibroma (benign fibrous histiocytoma)

These are firm discrete nodules arising in the dermis, usually on the legs of women. Initially lesions may appear red or light brown but usually mature into a firm brown papule with a ring of darker peripheral pigment ([Figure 22.15](#)). Lesions may be itchy or even painful. The underlying pathophysiology is poorly understood; some authors believe they arise at the site of insect bites or minor trauma while others believe them to be a true benign tumour of fibroblasts. They can be excised under local anaesthetic if they are problematic, but a linear scar will result from surgery.



[Figure 22.15](#) Dermatofibroma.

Benign vascular tumours

The most common benign vascular malformations and tumours are described and their management options discussed.

Naevus flammeus neonatorum refers to 'stork marks' or 'salmon patches' present at birth most commonly at the glabella, eyelids, and nape of the neck ([Figure 22.16](#)). Up to one-third of neonates are affected. Lesions on the neck persist for life; however, facial lesions usually fade or completely disappear by the age of two years.

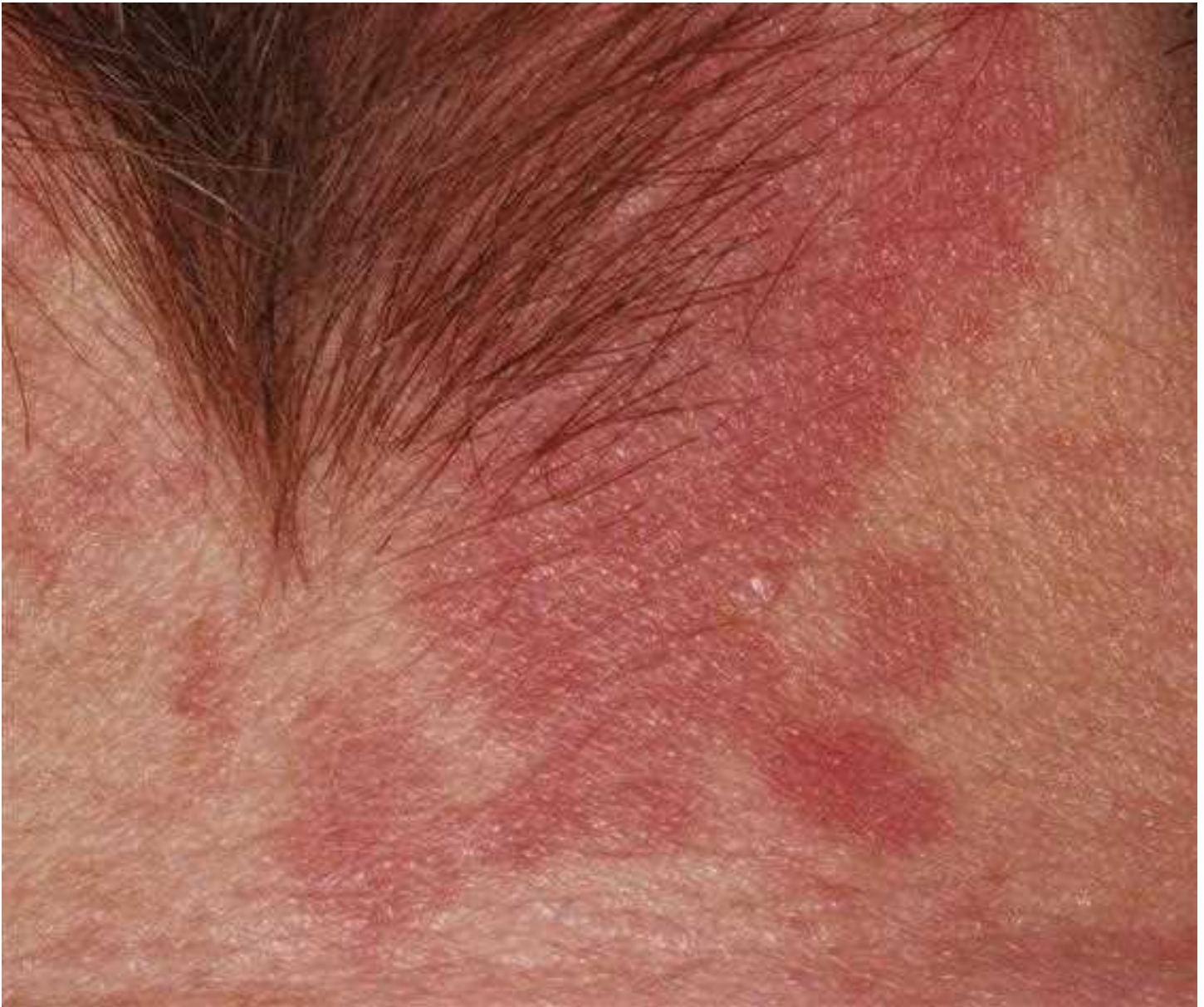

Figure 22.16 Naevus flammeus neonatorum.

Port wine stains are capillary malformations of the superficial dermal blood vessels that are present at birth. Therefore, they are not strictly neoplasms but are discussed here for convenience. They most commonly occur on the head and neck. Lesions may initially be of a pale pink colour but darken with increasing age through red to purple. Capillary malformations increase in size proportionally with the growth of the child and tend to persist. Port wine stains on the face are usually unilateral with a sharp midline border ([Figure 22.17](#)). In time, the affected area becomes raised and thickened due to a proliferation of vascular and connective tissue. If the area supplied by the ophthalmic or maxillary divisions of the trigeminal nerve is affected, there may be associated angiomas of the underlying meninges with epilepsy – Sturge–Weber syndrome. Patients should have a magnetic resonance imaging (MRI) scan with gadolinium enhancement to visualise neural involvement. Klippel–Trenaunay syndrome usually presents with a capillary malformation associated with limb overgrowth and varicosities. In addition, lesions of the limb may be associated with


arteriovenous fistulae: the so-called Parkes–Weber syndrome.

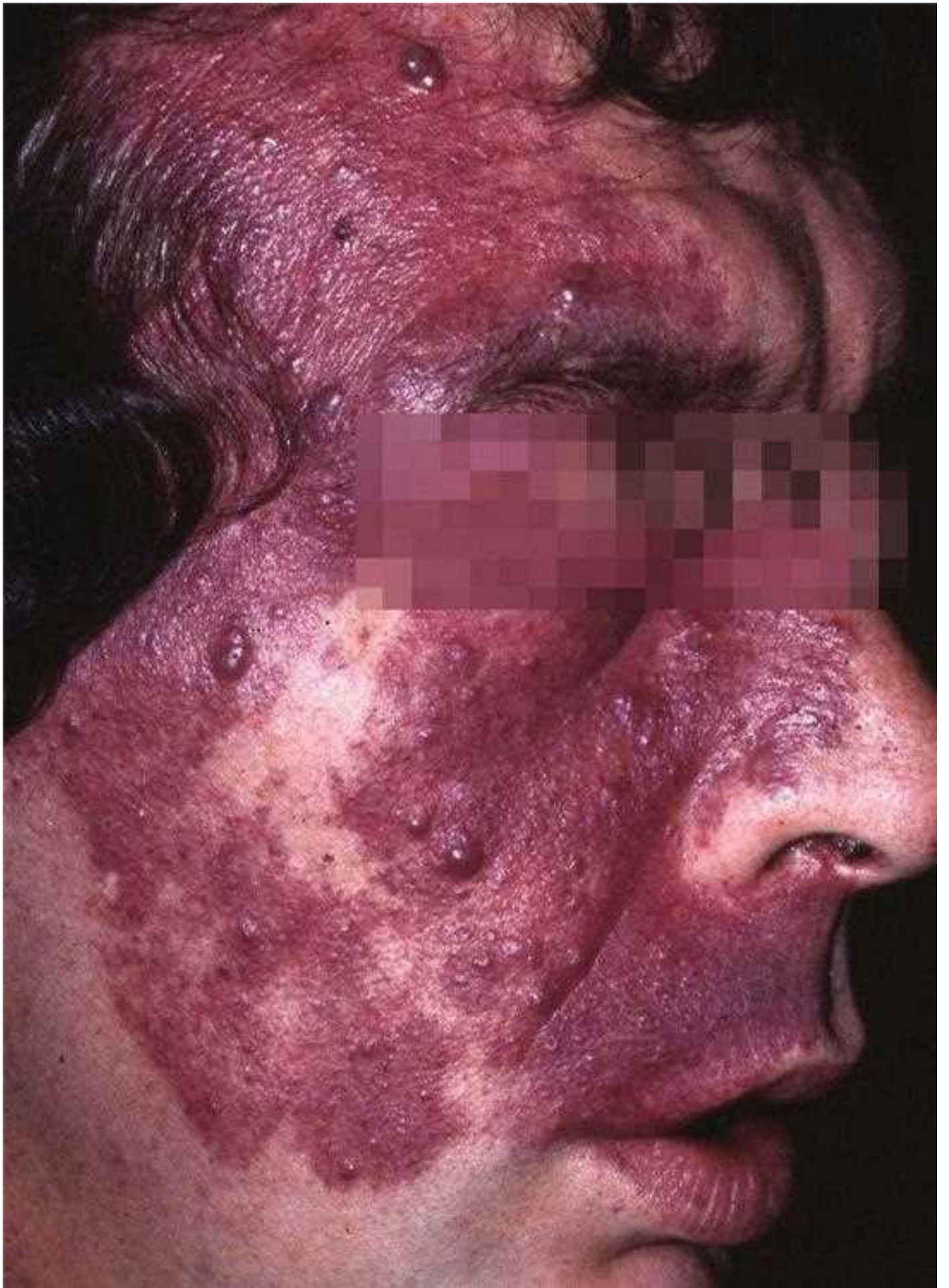
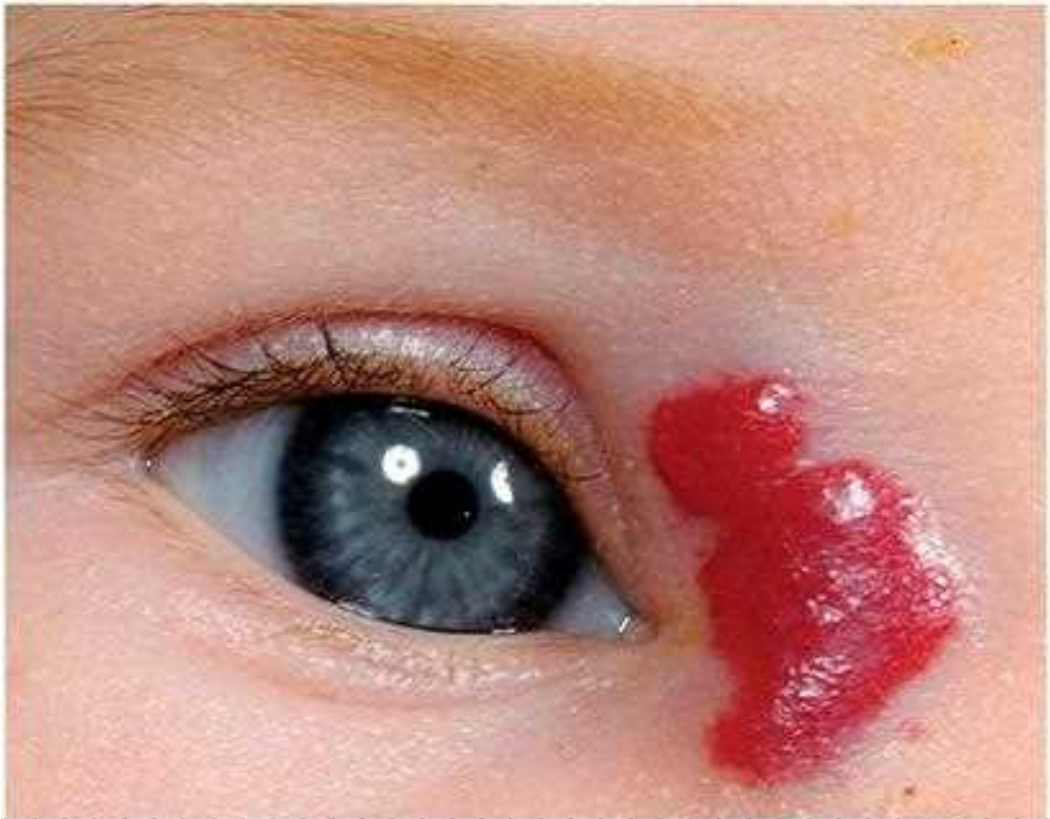
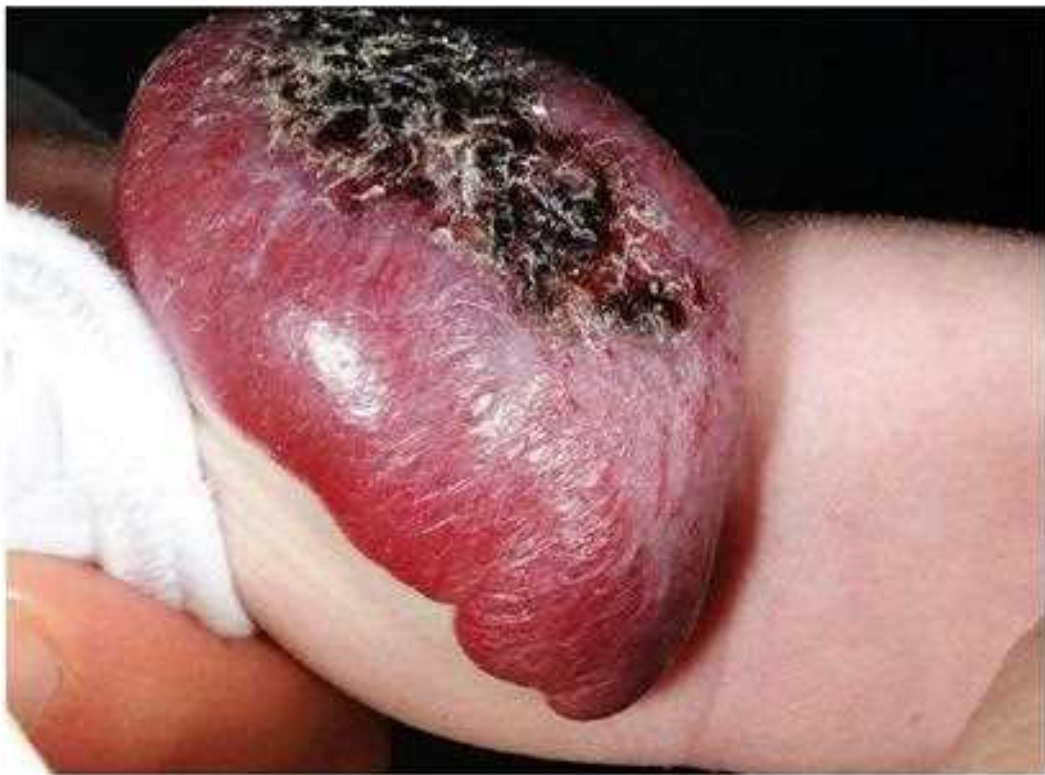Figure 22.17 Sturge–Weber syndrome.

Capillary malformations may be treated with a pulsed dye laser which targets oxyhaemoglobin (see [Chapter 25](#)). The ideal age for treatment is difficult to determine. Some experts feel laser treatment should be undertaken before the first birthday, but a general anaesthetic may be necessary, therefore waiting until an age when a child can ‘cooperate’ may be advocated. The outcome of laser treatment depends on the size, location, and depth of vessels in the skin, but most lesions require multiple treatments. Patients can be offered cosmetic camouflage.

Infantile haemangiomas (IH) (strawberry naevi) are true benign vascular neoplasms which grow out of proportion to the growing neonate. They are present in up to 10% of neonates and usually appear at birth or during the first few weeks of life and rapidly enlarge at around six months of age ([Figure 22.18a](#)). The exact cause is unknown; however, several theories exist including speculation that they may arise from endothelial cells breaking away from the placenta. Risk factors for developing IHs include female infant, Caucasian, pre-term/low birth weight, multiple gestations, older mother, and placental anomalies/bleeding. Lesions may be single (80%) or multiple and are more common in infants whose mothers underwent chorionic villous sampling. Clinically, a soft vascular swelling is found, most commonly on the head and neck. The lesions resolve spontaneously in time and do not require intervention unless recurrently bleeding/ulceration or interference with visual development occurs. Oral propranolol (1–3 mg/kg/day) or atenolol is the current treatment of choice to shrink down haemangiomas that are life-threatening, affect function/development or are ulcerated and bleeding ([Figure 22.18b](#)). The first dose is usually given with cardiac and blood pressure monitoring. The site and size of the haemangioma will determine the length of the treatment course needed to shrink the lesion; however, up to age 12 months may be needed to prevent regrowth on cessation. Alternative interventions include laser treatment, prednisolone, and sclerotherapy (see [Chapter 25](#)).



(a)



(b)

Figure 22.18 (a) Cavernous (strawberry) haemangioma and (b) ulcerating and bleeding cavernous haemangioma suitable for treatment with systemic β blockers.

Spider telangiectasia (angiomata) consist of a central arteriole with fine radiating 'legs' (smaller vessels) coming from it ([Figure 22.19](#)). They are more common in children and women. Large numbers may raise the possibility of liver disease or an underlying connective tissue disorder such as systemic sclerosis. They may fade spontaneously or if needed can be treated with a pulsed dye laser or hyfrecation.

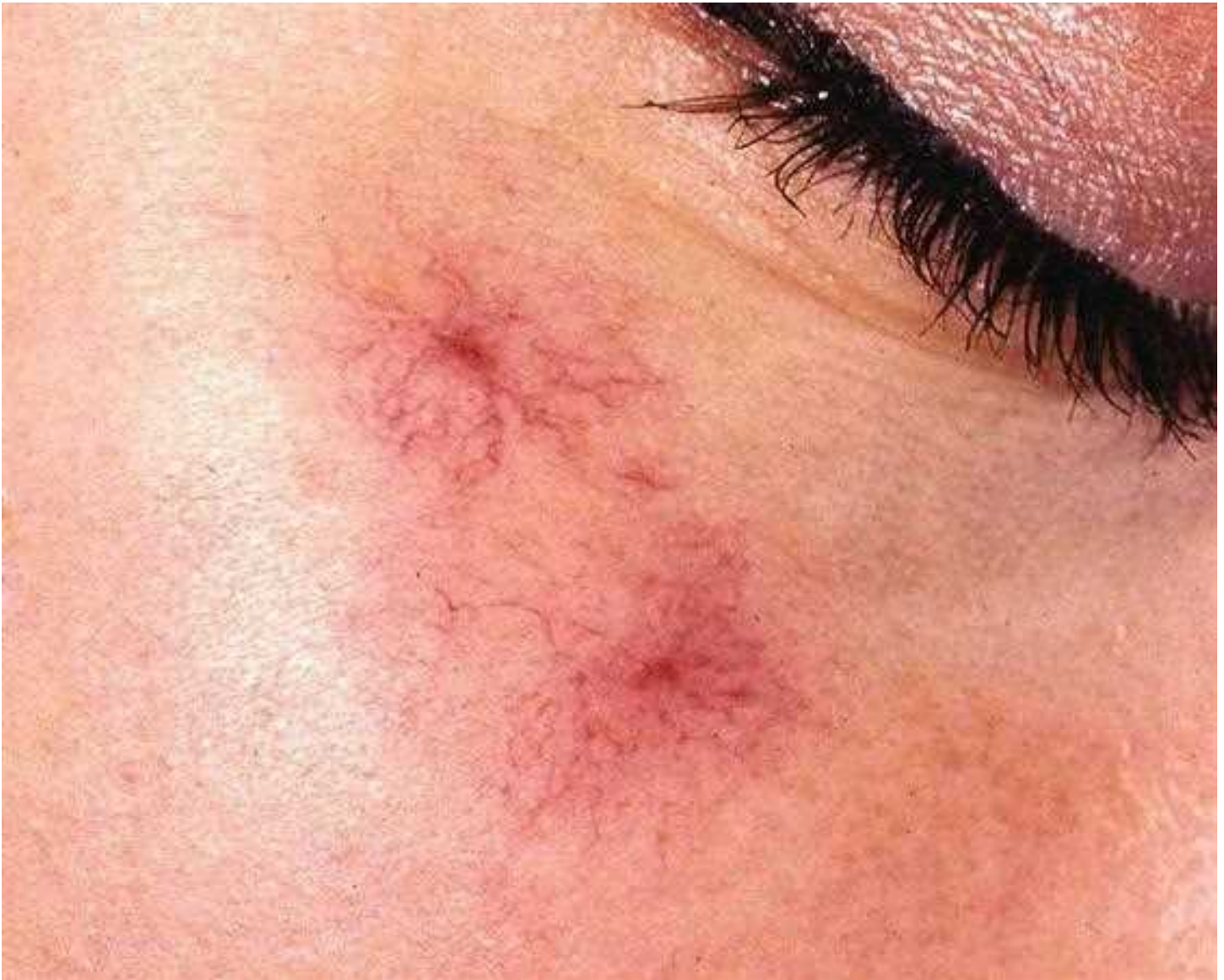

Figure 22.19 Spider telangiectasia.

Campbell de Morgan spots (cherry angiomas) are discrete red papules 1–5 mm in diameter. They are mature capillary proliferations that occur in up to 50% of adults, are usually multiple and occur most frequently on the trunk ([Figure 22.20](#)).

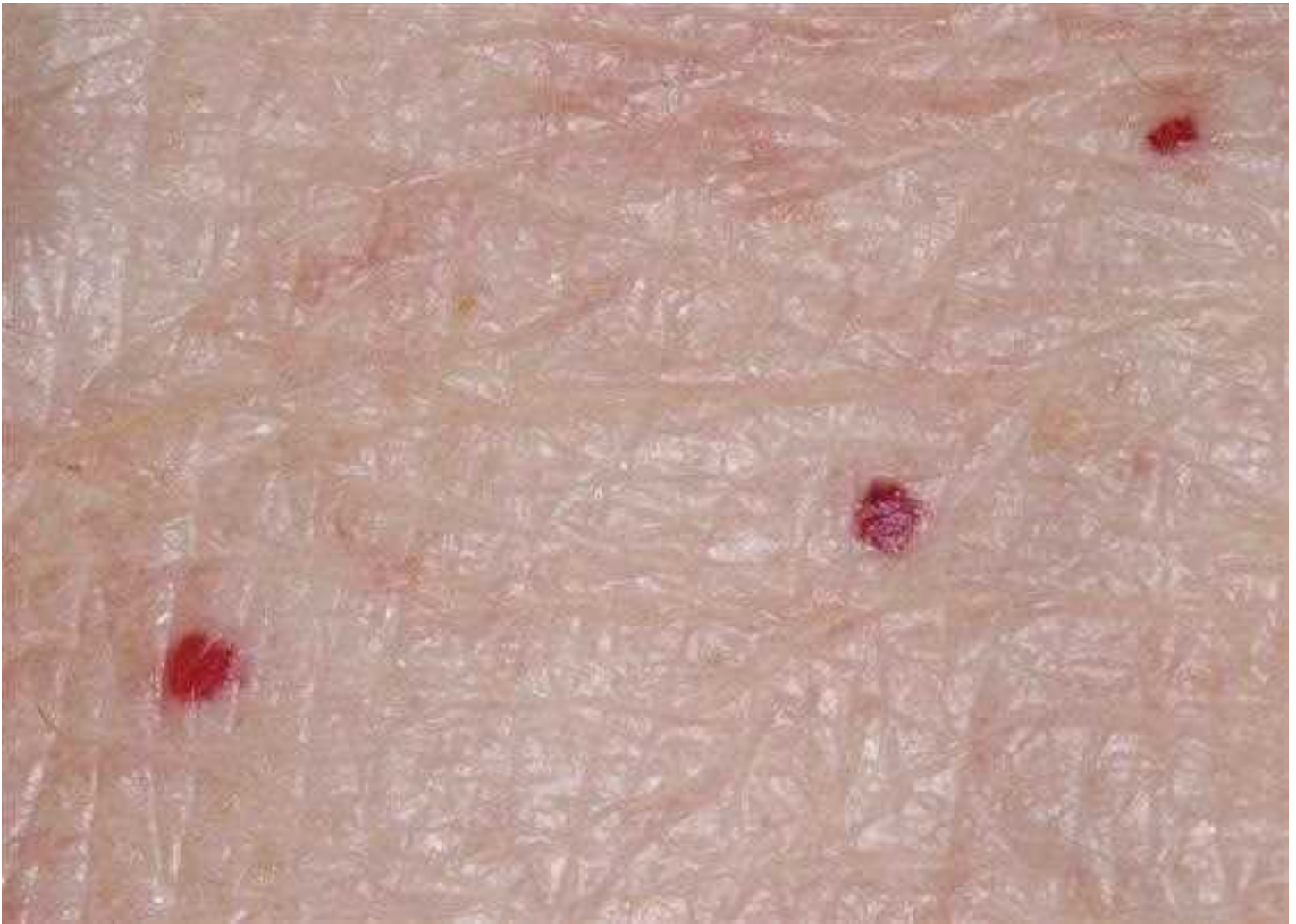

Figure 22.20 Campbell de Morgan angiomas.

Pyogenic granuloma is poorly named as it is not infectious but a lobular capillary haemangioma. The usually single vascular lesion grows rapidly and easily bleeds with minor trauma ([Figure 22.21a](#)). The bleeding can be profuse and recurrent. Lesions may arise at the site of trauma, often on the digits. Multiple eruptive pyogenic granulomas can arise secondary to medications ([Figure 22.21b](#)) such as oral retinoids, tacrolimus BRAF/tyrosine kinase/epidermal growth factor receptor inhibitors. Although benign, pyogenic granulomas need to be removed surgically by curettage and cauterization (under plain lignocaine local anaesthetic at digital sites) as they rarely resolve spontaneously (see [Chapter 24](#)). Lesions removed should always be sent for histological analysis to ensure distinction from amelanotic melanoma, which may have a similar clinical appearance.

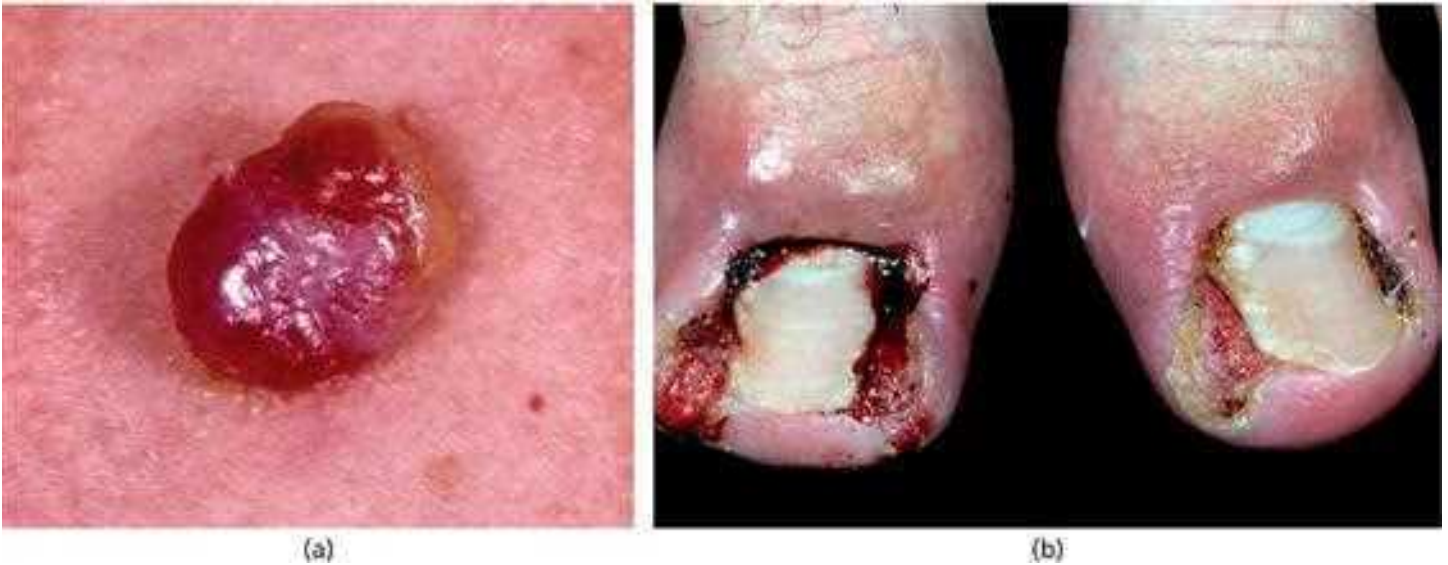

Figure 22.21 (a) Pyogenic granuloma. (b) Multiple eruptive pyogenic granulomas.

Benign tumour papules

These commonly include skin tags (fibroepithelial polyps – see above), DPN (see above), syringomas, trichoepitheliomas, apocrine hidrocystomas, milia, and sebaceous gland hyperplasia.

Syringomas are benign adnexal tumours of the eccrine glands. Lesions are usually multiple, slow-growing, small and flesh-coloured and usually appear on the face around puberty ([Figure 22.22](#)). The trunk and groin areas may also be affected. Treatment on cosmetic grounds is surgical with shave removal or cauterization of the lesions.

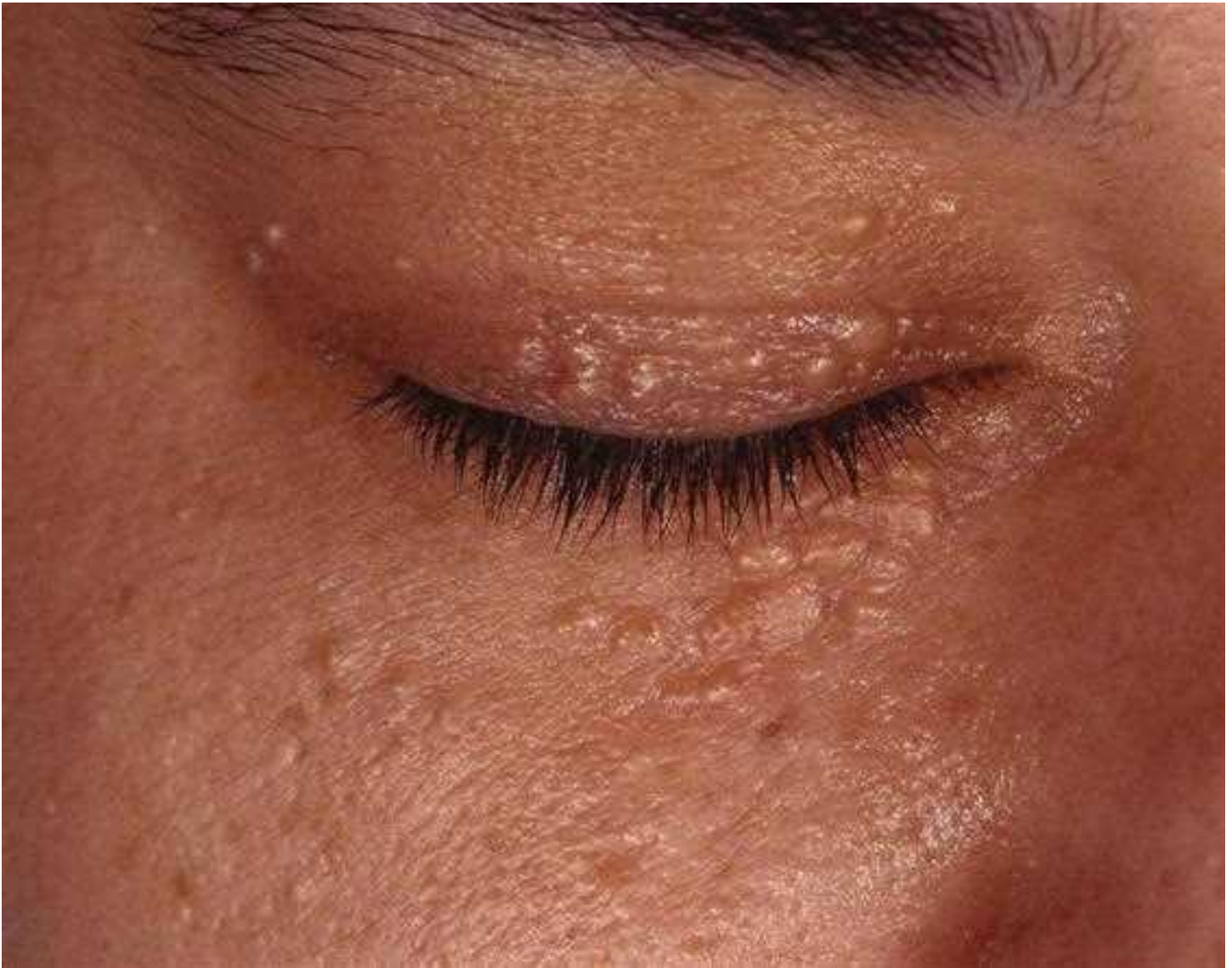

Figure 22.22 Syringomas.

Trichoepitheliomas are benign adnexal tumours of hair follicle origin. These may resemble syringomas or basal cell carcinomas as they are small and often occur on the face and scalp ([Figure 22.23](#)). Surgical removal or laser treatment can help to alleviate the cosmetic appearance, but lesions tend to be multiple and may recur.

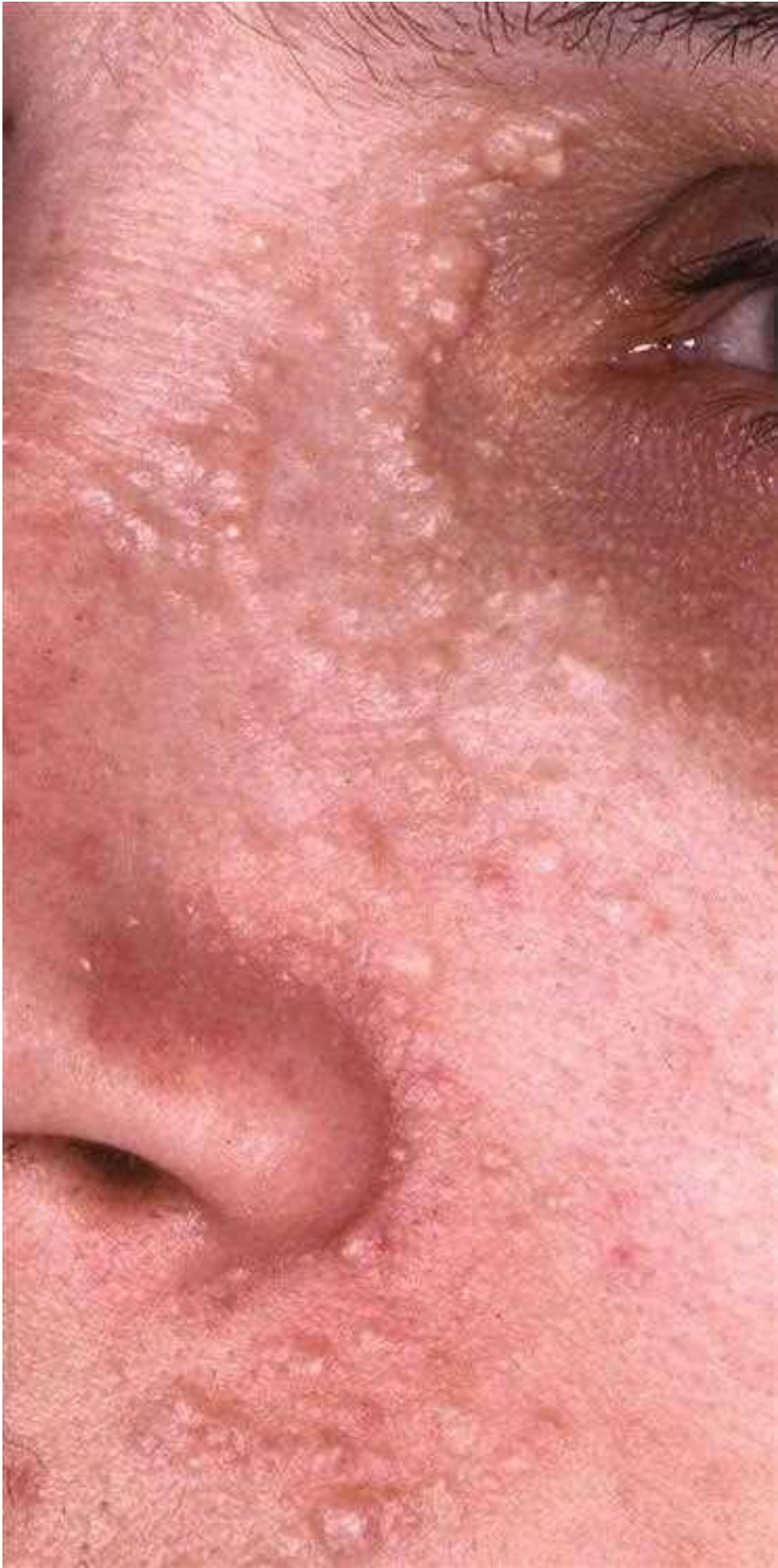

Figure 22.23 Trichoepitheliomas.

Apocrine hidrocystoma are benign adnexal tumours of apocrine glands that form papules or nodules around the eyes. Lesions are solitary or multiple and may be translucent ([Figure 22.24](#)) or pale through to black (lipofuscin pigment).

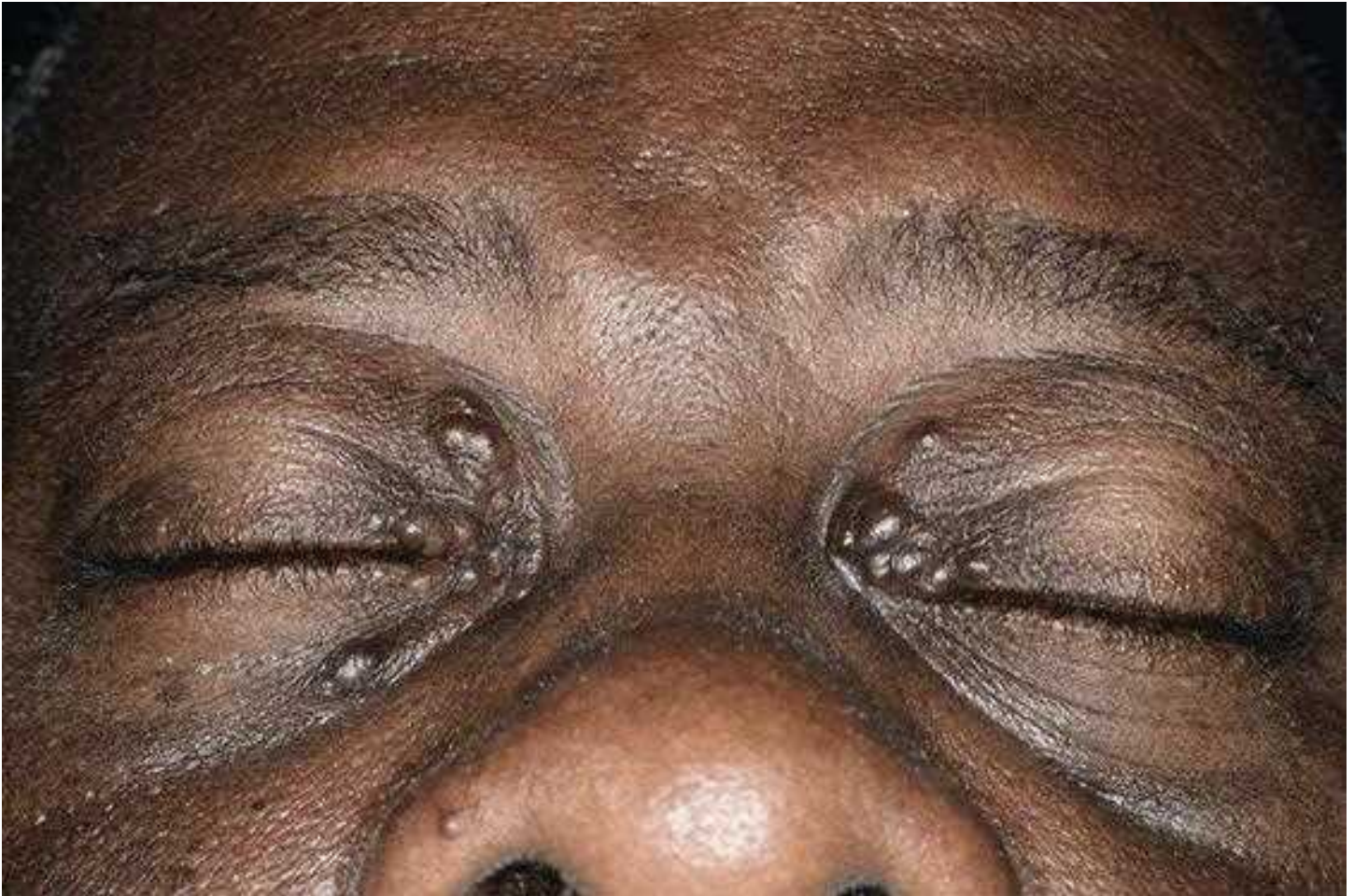

Figure 22.24 Apocrine hidrocystomas.

Milia are small keratin cysts consisting of small white papules found on the cheek and eyelids. Milia are common on the cheeks of newborns, and secondary milia may occur following skin trauma or inflammation ([Figure 22.25](#)). These minute cysts are harmless and require no treatment. They can be removed under topical anaesthetic with a sterile needle.

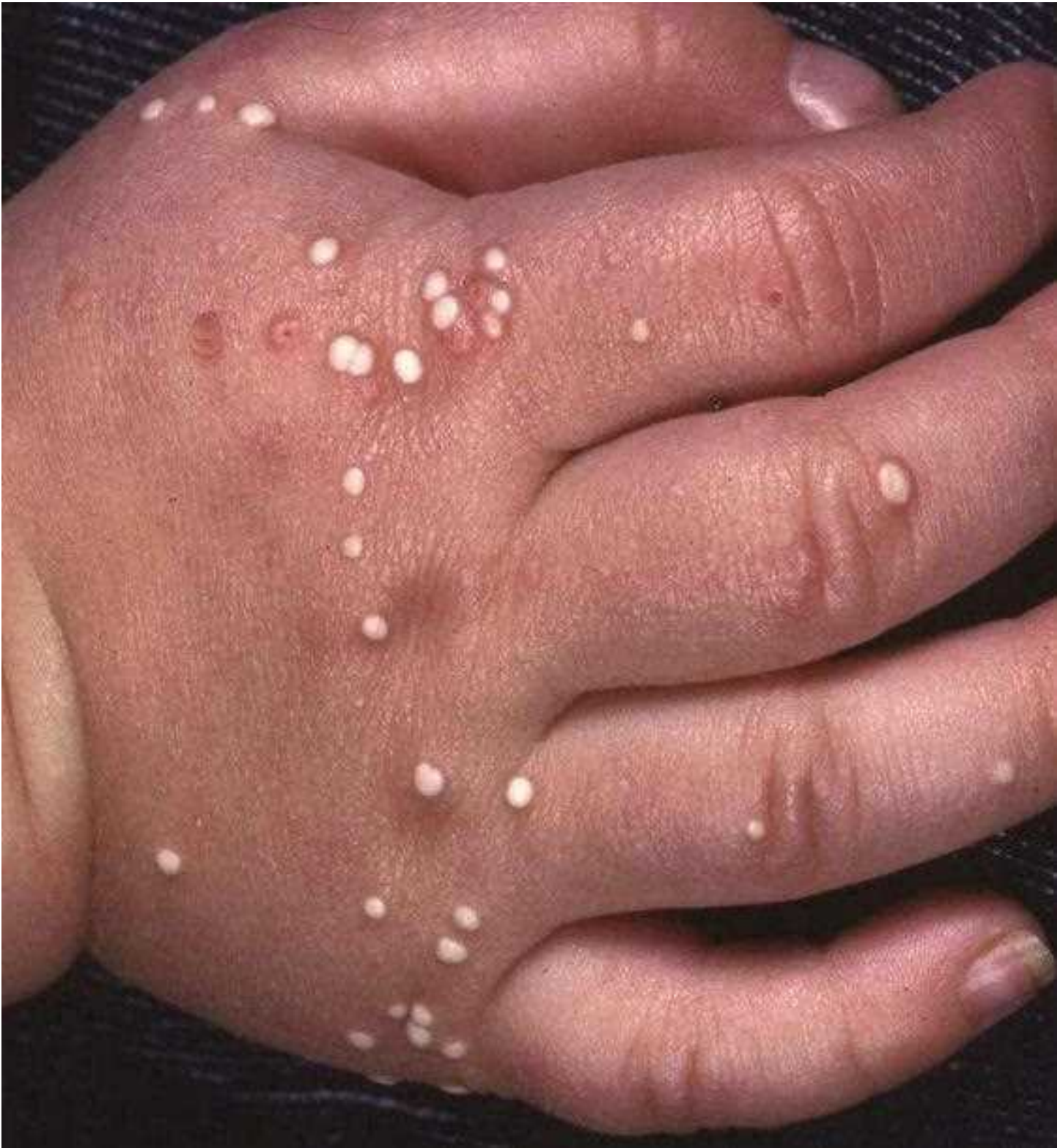

Figure 22.25 Milia.

Sebaceous gland hyperplasia is a benign hamartomatous enlargement of the sebaceous glands and therefore not a tumour. However, these small papules are not infrequently confused with benign skin tumours and basal cell carcinomas, and therefore are discussed here ([Figure 22.26](#)). Turnover of sebocyte cells within the glands decreases with increasing age, leading to hyperplasia. This is particularly prominent in patients who are

immunosuppressed with ciclosporin. There is an increased frequency of sebaceous gland hyperplasia reported with Muir–Torré syndrome. Patients develop sebaceous adenomas/carcinomas in association with systemic malignancies.

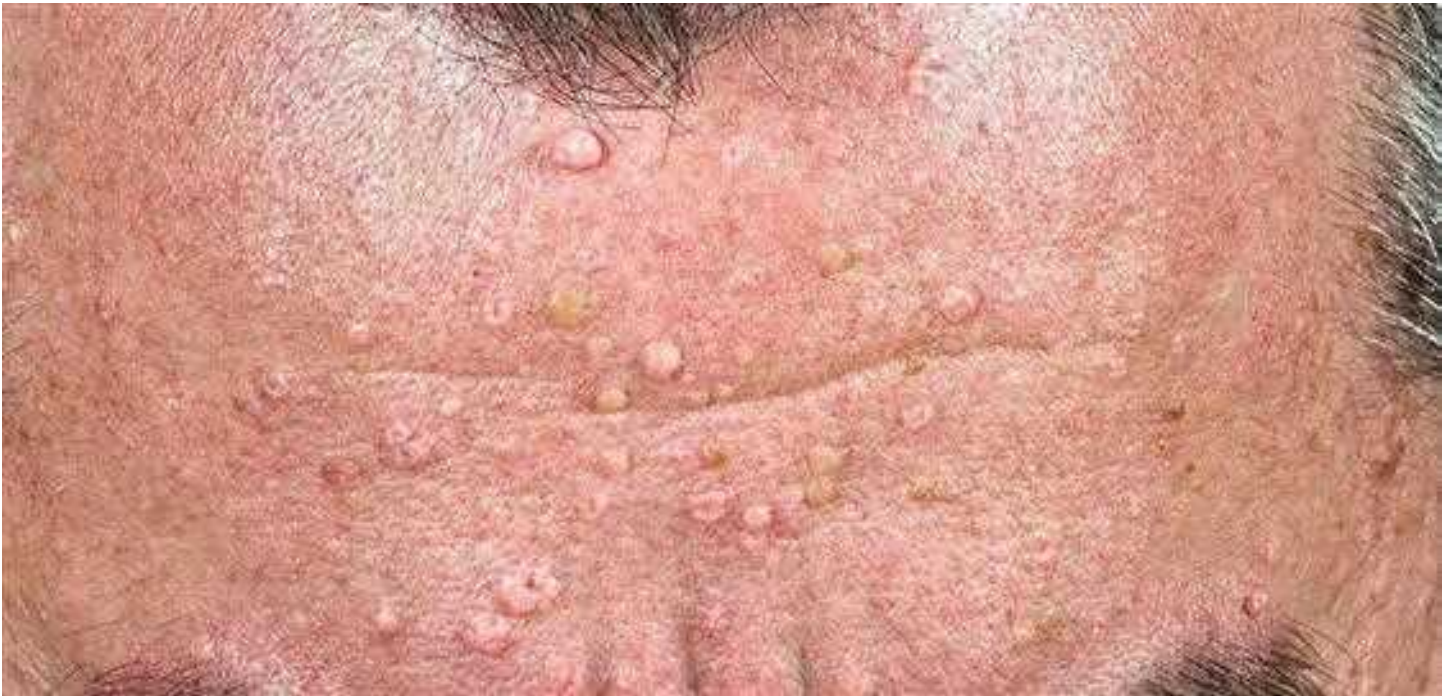
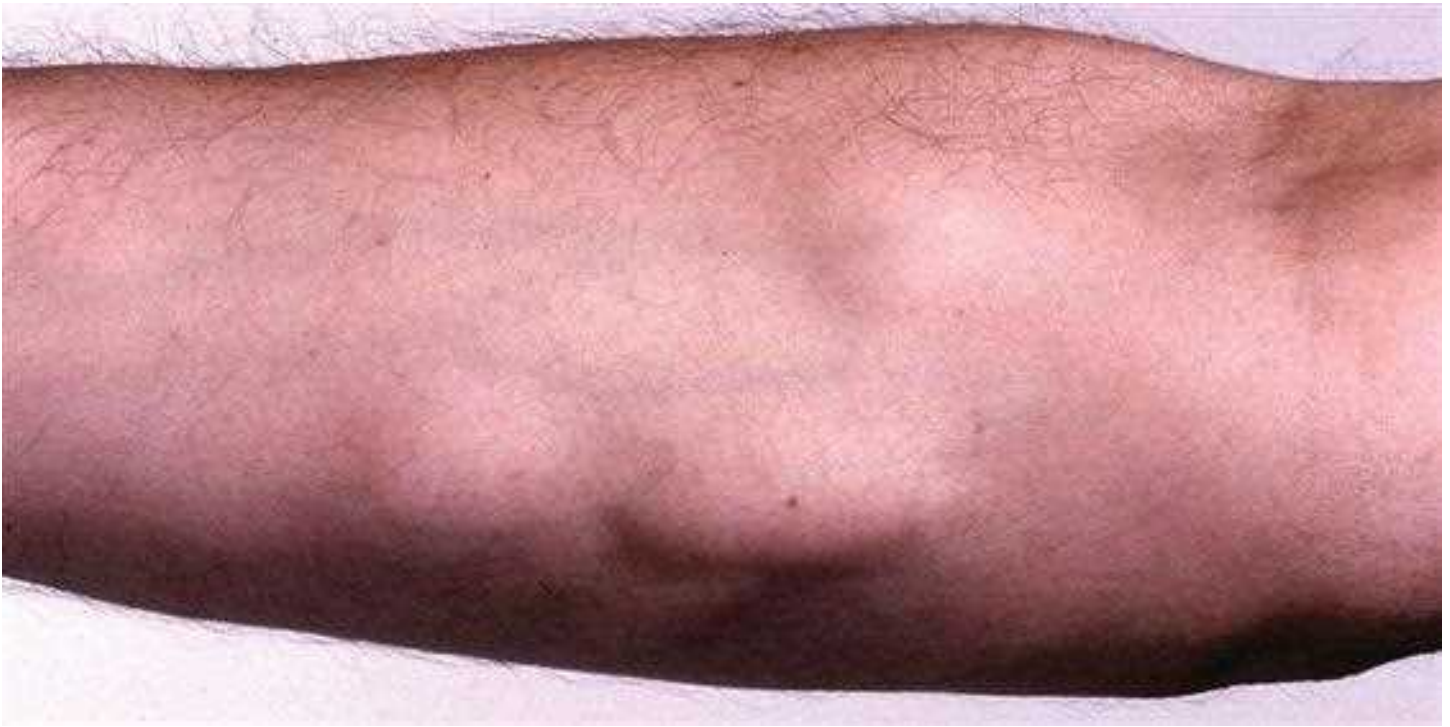
Figure 22.26 Sebaceous gland hyperplasia.

Benign tumour nodules

Lipomas are common slow-growing benign subcutaneous tumours of fat. They may be congenital or acquired, single or multiple ([Figure 22.27](#)). Lipomas are usually asymptomatic, but they may classically cause pain when they are associated with Dercum's disease (postmenopausal women who may be obese, depressed, or alcoholic with multiple painful lipomas on the lower legs). *Angiolipomas* may also be painful.



[Figure 22.27](#) Lipoma.

Benign painful tumours in the skin: 'BENGAL'

- Blue rubber bleb naevus
- Eccrine spiradenoma
- Neurilemmoma/neuroma
- Glomus tumour
- Angiolipoma
- Leiomyoma ([Figure 22.28](#)).

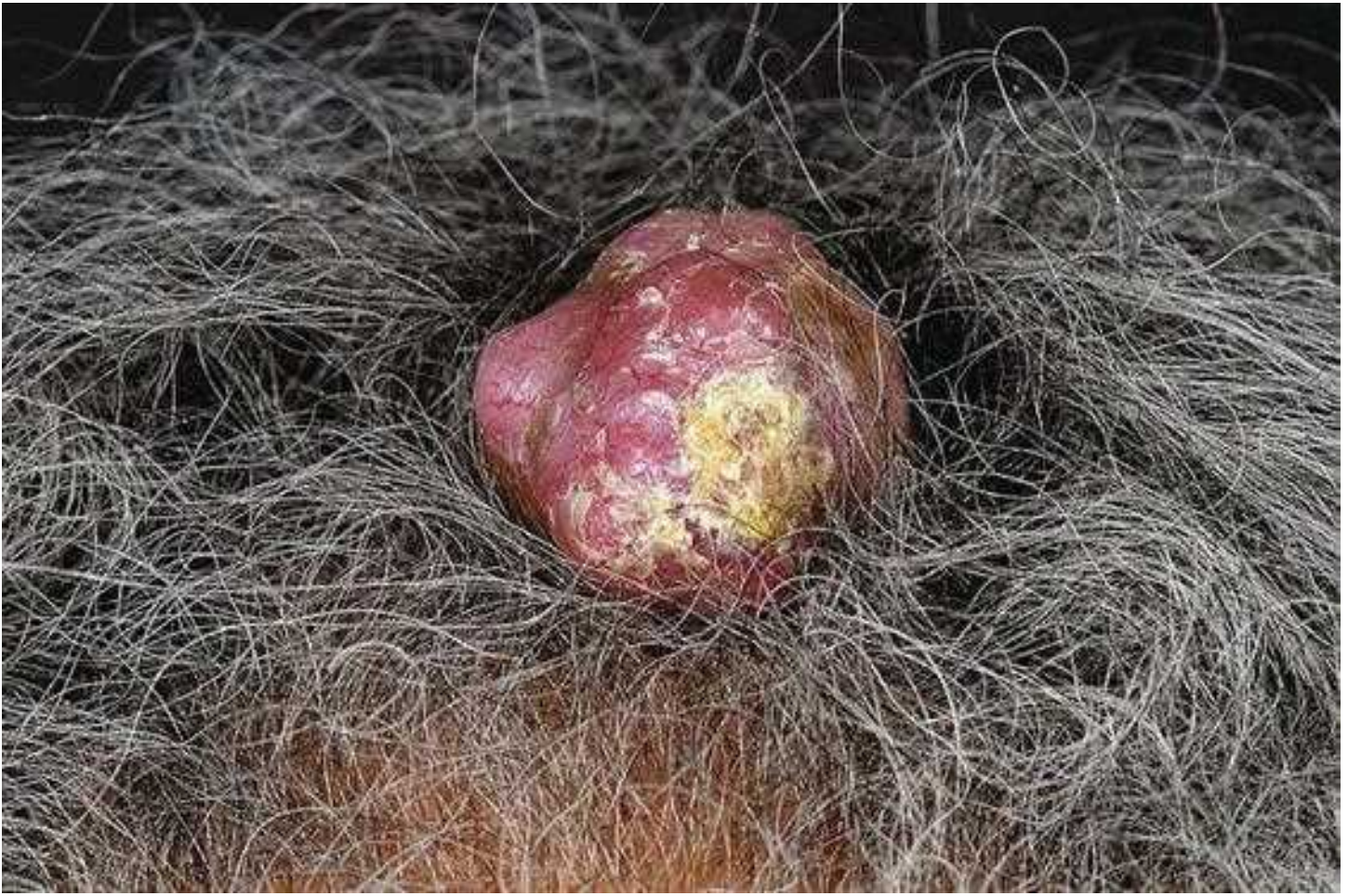

Figure 22.28 Leiomyoma on scalp vertex.

Epidermoid cysts (previously called *sebaceous cyst*) are common. They are soft, well-defined, mobile swellings usually on the face, neck, shoulders, or chest. There may be an obvious central punctum ([Figure 22.29](#)). Epidermoid cysts arise due to a proliferation of epidermal cells in the dermis derived from the hair follicle. They may become inflamed or infected causing discomfort and discharge (thick yellow material that has a bad odour) but are generally asymptomatic. If cysts are troublesome they can be completely excised or removed by punch extrusion (see [Chapter 24](#)).

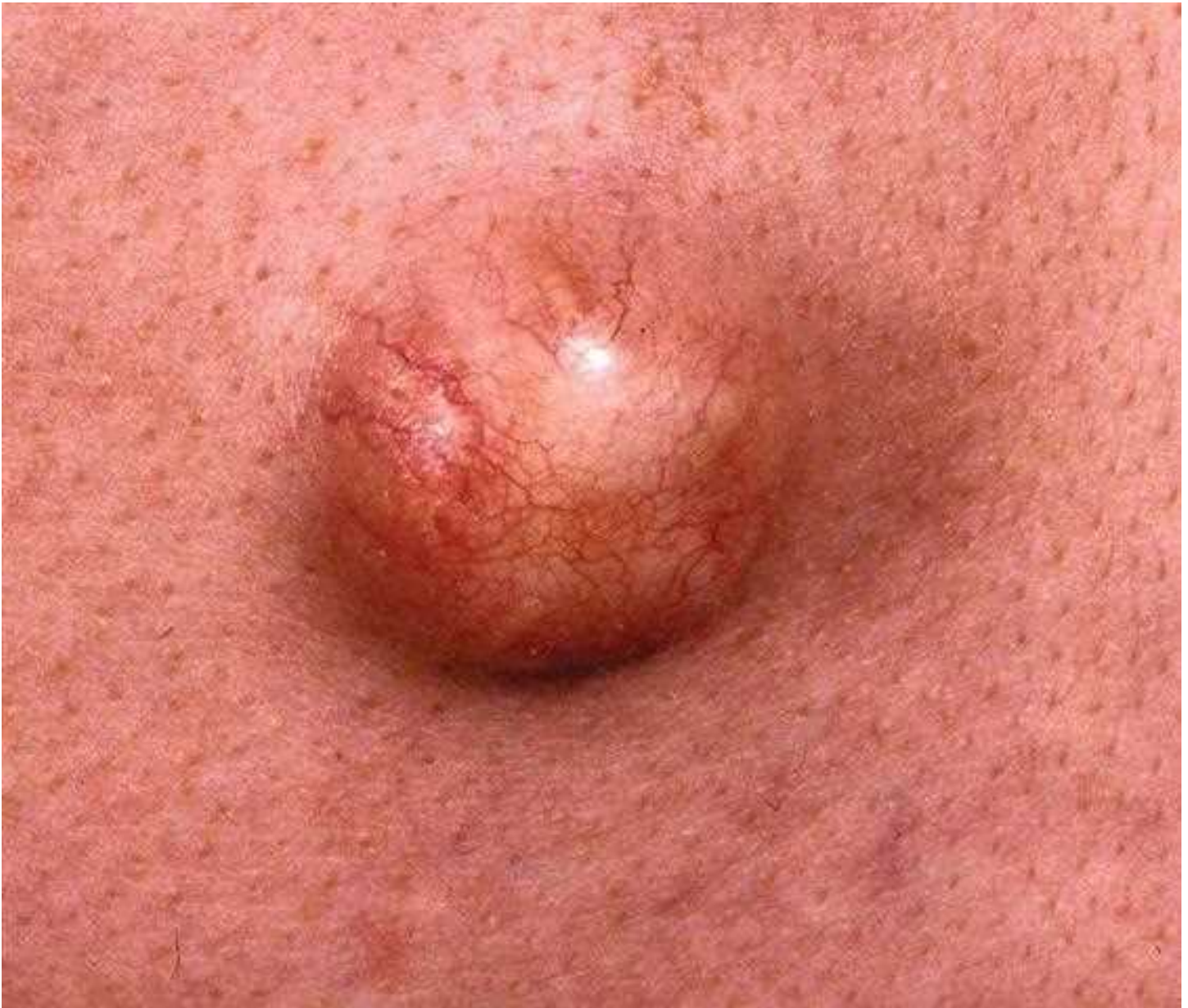

Figure 22.29 Epidermoid cyst.

Pilar cysts on the scalp are very common and frequently multiple. Clinically, they can resemble epidermoid cysts, but they do not have a punctum. They are derived from hair follicles. Surgical removal may be necessary in some cases, when the tumour usually ‘shells out’ very easily.

Pilomatrixoma is a benign tumour of the hair matrix. A very hard slow-growing lump usually presents on the head/neck of a child (can also occur in adults). Lesions may be a few centimetres in diameter. Multiple lesions may indicate an underlying syndrome. Spontaneous regression may occur but is rare as most lesions are excised for histological analysis.

Poromas can be apocrine or eccrine-derived benign tumours of the skin. These nodular lesions are flesh-coloured and slow-growing, they may be painful ([Figure 22.30](#)). Rarely lesions undergo malignant transformation. Surgical excision of poromas is the treatment of choice.

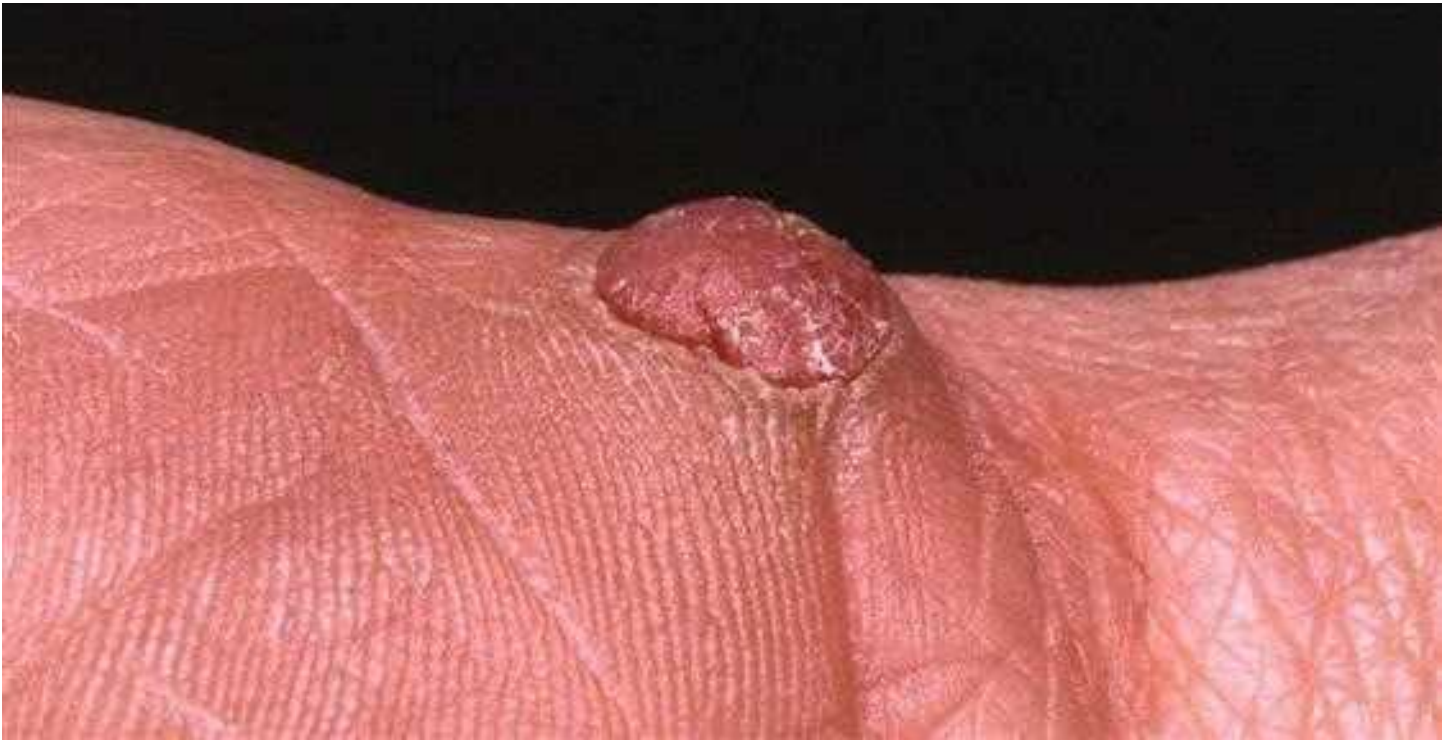

Figure 22.30 Eccrine poroma.

Keloid scar is a benign tumour of dermal fibroblasts that form at the sites of skin trauma – which may be minor such as a graze/burn, or secondary to inflammatory conditions such as chickenpox/acne or may result from deliberate skin piercing ([Figure 22.31](#)) or indeed any kind of surgery. Keloid scars are more common in pigmented skin and younger age. Keloid scars proliferate beyond the site of injury and they do not regress, unlike hypertrophic scars.

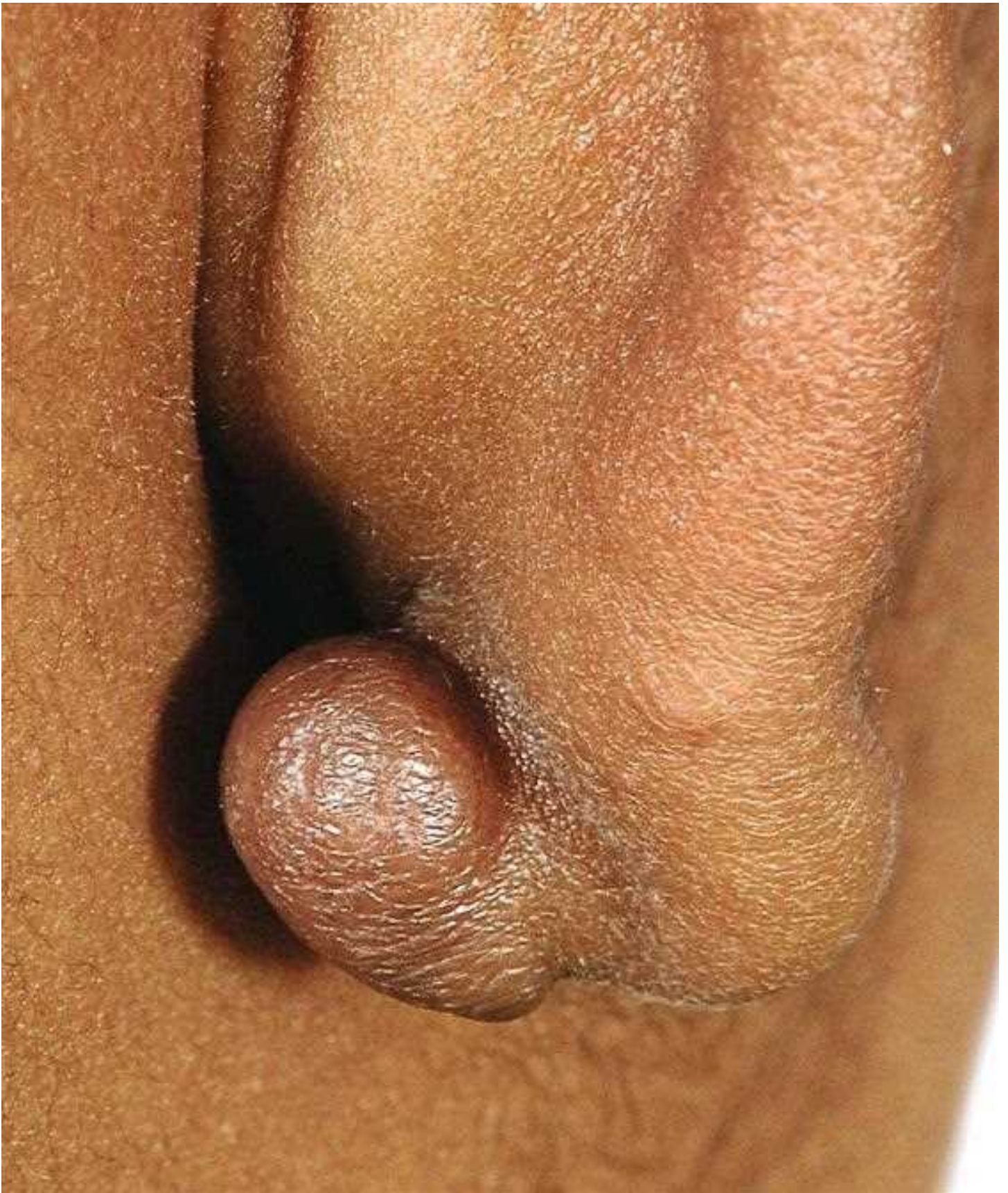
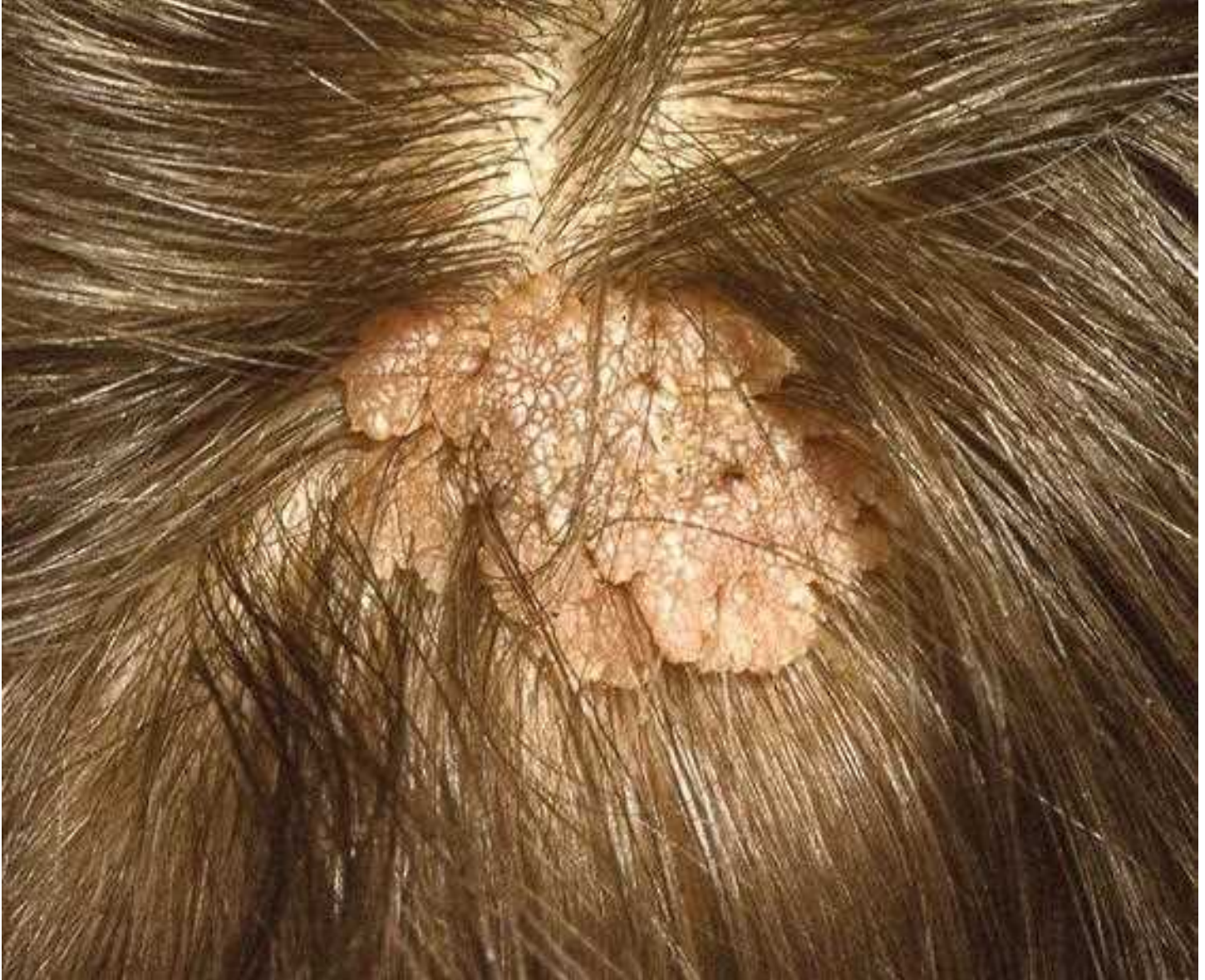
Figure 22.31 Keloid scar secondary to ear piercing.

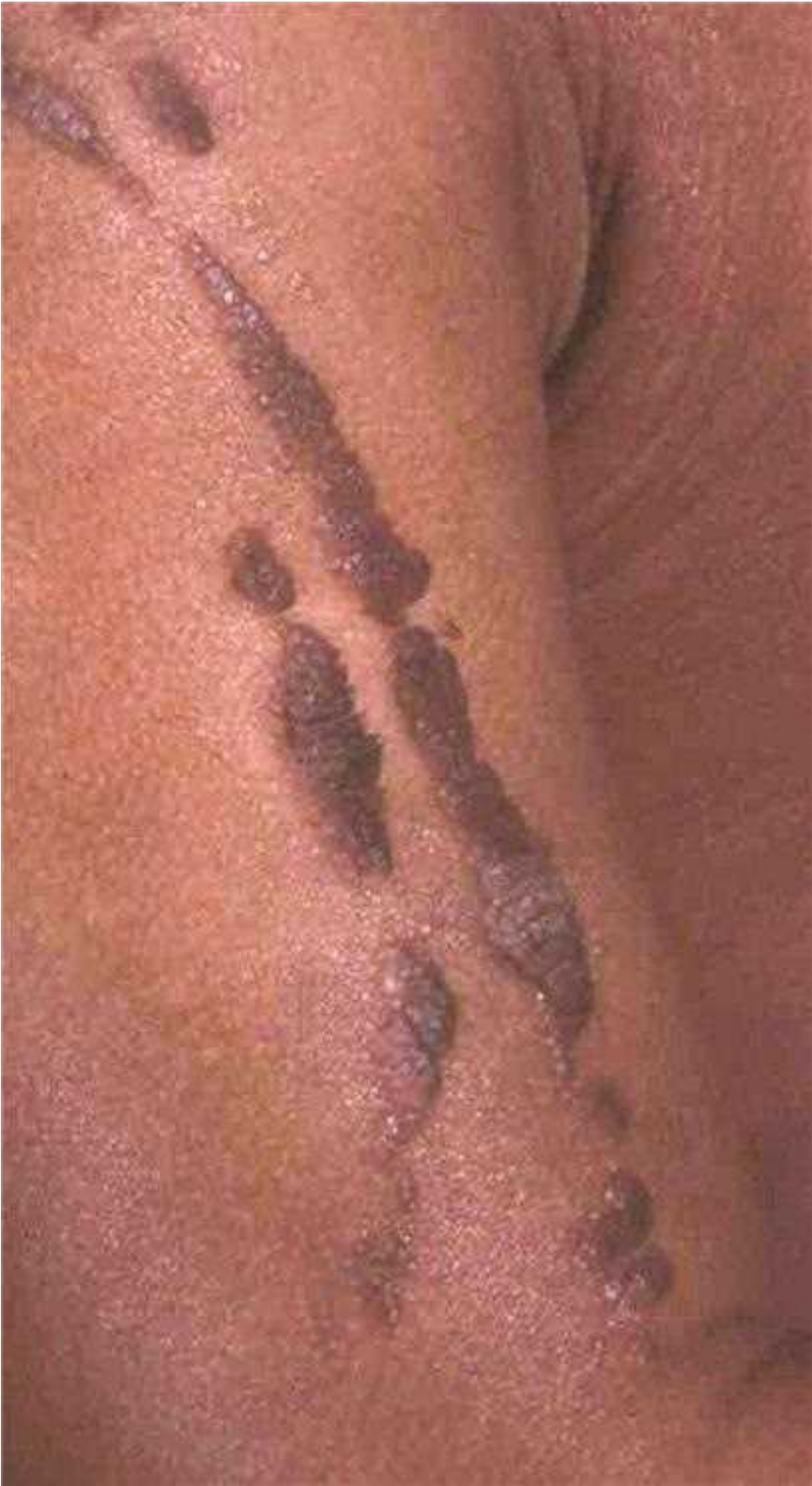Benign tumour plaques

Naevus sebaceous is a warty, well-defined plaque of 0.5–2 cm in diameter that mainly occurs on the scalp. Lesions may be present at birth or appear during childhood and slowly increase in size. In neonates, a hairless yellow plaque may be seen on the scalp ([Figure 22.32](#)). As the lesion matures, it may become verrucous and occasionally a trichoblastoma may develop within it. This is a benign tumour that may be misdiagnosed histologically as a basal cell carcinoma. Very large lesions may be associated with internal disorders.



[Figure 22.32](#) Naevus sebaceous.

Epidermal naevi are congenital hamartomas that may be linear or clustered and appear as warty brown papular lesions on the skin ([Figure 22.33](#)), they tend to darken and thicken with time.



[Figure 22.33](#) Epidermal naevus.

Inflammatory linear verrucous epidermal naevus (ILVEN) may be present at birth or appear during the first five years of life, most commonly on the lower limb or trunk. Lesions are warty and brown and are usually linear or clustered. Lesions may become red and inflamed and may be mistaken for eczema ([Figure 22.34](#)). Topical steroids and emollients may help to relieve itching and dryness.

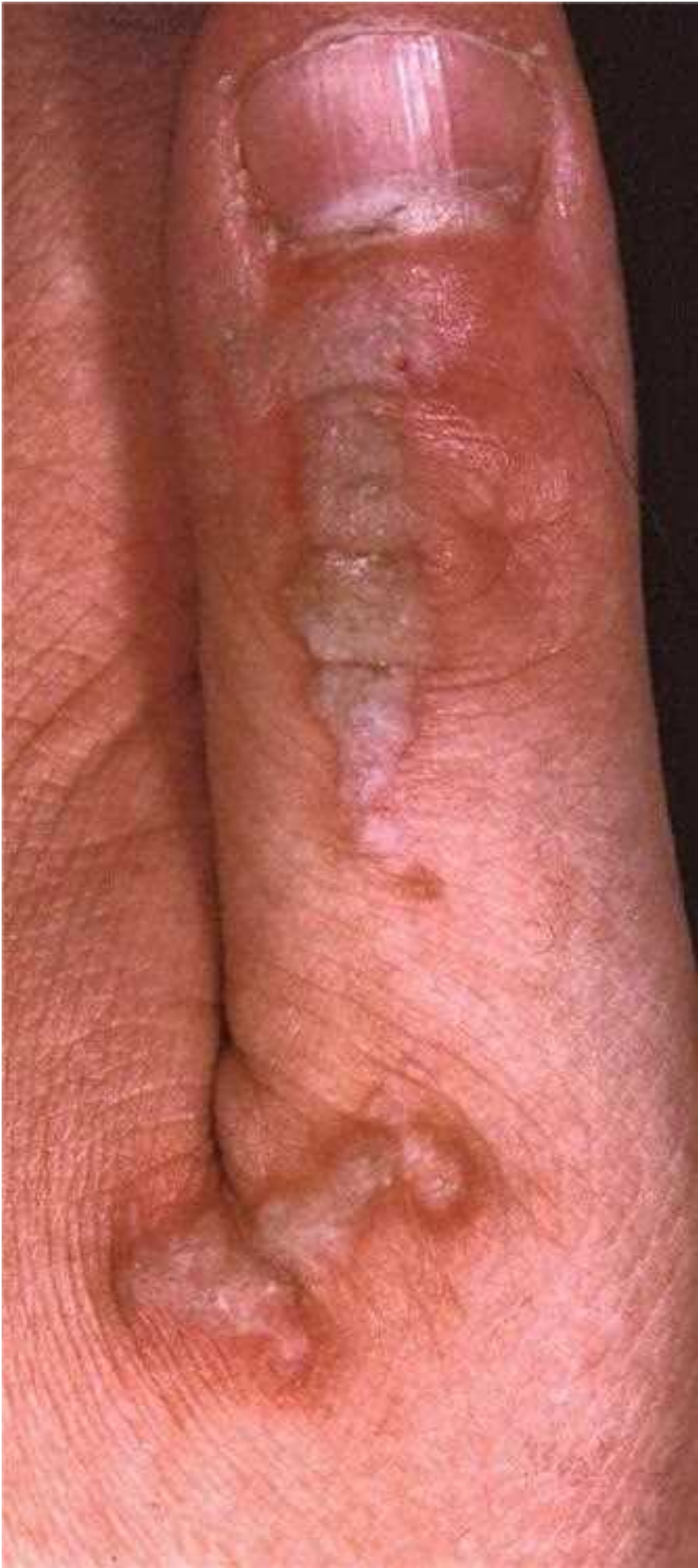

Figure 22.34 Inflammatory linear verrucous epidermal naevus (ILVEN).

Further reading

Baykal, C. and Yazganoglu, K.D. (2014). *Clinical Atlas of Skin Tumours*. Springer.

<https://patient.info/doctor/benign-skin-tumours>

CHAPTER 23

Premalignant and Malignant Skin Lesions

Rachael Morris-Jones

Guy's and St Thomas' NHS Foundation Trust, London, UK

OVERVIEW

- Skin cancer is the commonest human cancer in the world.
- In premalignant lesions, there is abnormal growth of cells but not complete dysplastic change. This occurs in actinic keratoses and Bowen's disease.
- Squamous cell carcinoma (SCC) develops in previously normal skin or pre-existing lesions such as actinic keratoses or Bowen's disease.
- Basal cell carcinoma (BCC) is the most common cancer in humans. Clumps of dysplastic basal cells form nodules that expand and break down to form an ulcer with a rolled edge.
- Ultraviolet light is a recognised carcinogen leading to skin cancer.
- Melanoma is a malignant tumour of melanocytes. A major risk factor is high-intensity UV exposure, particularly in childhood.
- Melanoma occurs in various forms; superficial spreading melanoma is the most common. Other types include lentigo maligna melanoma, nodular melanoma, acral melanoma, and amelanotic melanoma.
- The prognosis of melanoma depends on the depth of invasion.

Introduction

Malignancies of the skin are among the most common cancers known to man. In benign tumours, there is a proliferation of well-differentiated cells with limited growth, whereas in a malignant tumour, the dysplastic cells are undifferentiated and expand in an uncontrolled manner. The carcinogenic effect of the sun is thought to play a key role in many types of skin cancer. One hundred years ago, a tanned skin indicated outdoor work. Nowadays, many individuals deliberately seek the sun for the purposes of tanning. Longer holidays, cheap flights and a fashion to be tanned and an increasing 'hole' in the ozone layer may all have contributed to the doubling of melanoma incidence over the past decade.

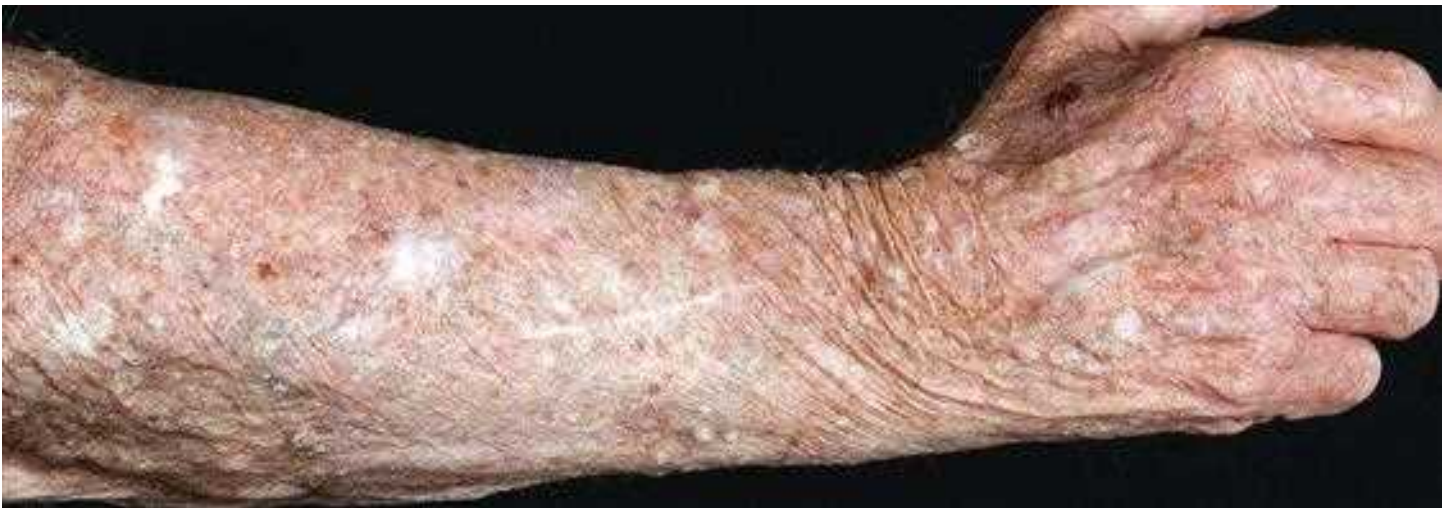High-intensity ultraviolet (UV) light can lead to sunburning episodes in fair-skinned individuals, and this is thought to be a risk factor for melanoma, the most serious form of skin cancer.

However, recently there has been an increasing global awareness concerning the dangers of strong sunlight. Public health campaigns such as ‘slip slop slap’ (‘*slip* on a shirt, *slop* on sunscreen and *slap* on a hat’) in Australia have been very successful at modifying people's behaviour in the sun. Skin cancer is deemed by many to be a ‘preventable’ form of cancer. The visible nature of skin cancer means detection should be straightforward by the trained eye, although histological confirmation is essential. Early recognition of malignant skin tumours by medical practitioners is essential in order that patients suffer minimal morbidity and avoid skin-cancer-induced mortality.

Premalignant skin tumours

Actinic keratoses

Actinic keratoses (AKs) occur on exposed skin, particularly in those who have worked outdoors or have been exposed to short intervals of high-intensity UV. AKs occur on the face (including the lip), dorsal hands, distal limbs, and bald scalp, particularly in those with fair/sun-damaged skin and increasing age ([Figure 23.1](#)). Clinically, their appearance varies from a rough area of skin to a raised keratotic lesion. They have an irregular edge and they are usually less than 1 cm in diameter. Histologically, AKs have altered keratinisation, which may lead to dysplasia and eventually invasive squamous cell carcinoma (SCC). Malignant change may be suspected in an AK that suddenly grows rapidly, becomes painful or inflamed.



[Figure 23.1](#) Sun-damaged skin with multiple actinic keratoses.

Management

Treatment with liquid nitrogen (cryotherapy/cryosurgery) by a medical practitioner is usually effective for individual lesions with cure rates of around 70% (see [Chapter 24](#)). Efficacy is less effective for very hyperkeratotic lesions and those on the forearms/hands. Various topical preparations that can be applied by patients themselves are currently available. 5-Fluorouracil (5-FU) 5% cream (Efudix[®]) and 0.5% solution (Actikerall[®]) are useful in treating large areas

of sun-damage with multiple AKs and is applied once daily for four to six weeks. The 5-FU kills any dysplastic keratinocytes and therefore produces brisk inflammation at the application site. Patients may therefore need to stop using the cream for a few days during the treatment course if discomfort is severe. Currently, 5-FU appears to be the most cost-effective treatment for AKs.

Imiquimod 5% (Aldara[®]) is an immunomodulatory preparation that recruits immune cells to the area of skin where it is applied, which then attack the dysplastic cells. Imiquimod is applied three times a week for four months. 3.75% imiquimod (Zyclara[®]) has recently been launched and should be used daily for two weeks, one week off and then treatment repeated for a further two weeks. There is some evidence that memory T-cells are induced by this therapy, resulting subsequently in lower numbers of clinical AKs.

Topical non-steroidal anti-inflammatory diclofenac (Solaraze[®]) has been shown to be effective against small AKs if it is used regularly twice daily for three months. This treatment seems to produce less skin irritation than 5-FU or imiquimod.

Ingenol mebutate gel (Picato[®]) is a recent addition to the treatment choice for AKs. It is a cytotoxic agent derived from milkweed plants that is formulated in two concentrations 0.015% (for the face once daily for three consecutive days) and 0.05% (for the trunk and limbs once daily for two consecutive days). Its effects are mediated by a brisk inflammatory reaction at the site, and the rates of clearance are reported between 34% and 42%. At 1-year follow-up, relapse rates are reported to be around 50%.

Photodynamic therapy (PDT) (see [Chapter 25](#)) has been shown to be as effective as 5-FU in the treatment of AKs. PDT is carried out by a medical practitioner rather than the patients themselves and can treat large areas of skin. The main limitation of PDT is usually the patient's ability to tolerate the burning pain felt in the skin during delivery of the treatment. Daylight PDT can also be used, with the advantage of treating larger areas of skin simultaneously and there is less pain and 'downtime'. Cosmetic outcomes for the treatment of AKs are reported to be best with photodynamic therapy and imiquimod as opposed to 5FU and cryotherapy. Any lesions not responding to the above measures should be biopsied to check for invasive malignancy.

Bowen's disease

Bowen's disease is SCC in situ; SCC occurs in the epidermis with no evidence of dermal invasion. Bowen's disease is more common in the elderly and is seen most frequently on the trunk and limbs. Risk factors for Bowen's disease include solar radiation, human papillomavirus warts (HPV 16), radiotherapy, ingestion of arsenic in 'tonics' and exposure to chemicals. Clinically, Bowen's disease is characterised by well-defined, erythematous patches with slight crusting ([Figure 23.2](#)). Lesions enlarge slowly and may reach up to 3 cm in diameter. After many years, invasive carcinoma may develop. Bowen's disease may be confused with a patch of eczema or superficial basal cell carcinoma (BCC). Erythroplasia of Queyrat is a similar process occurring on the glans penis or prepuce.

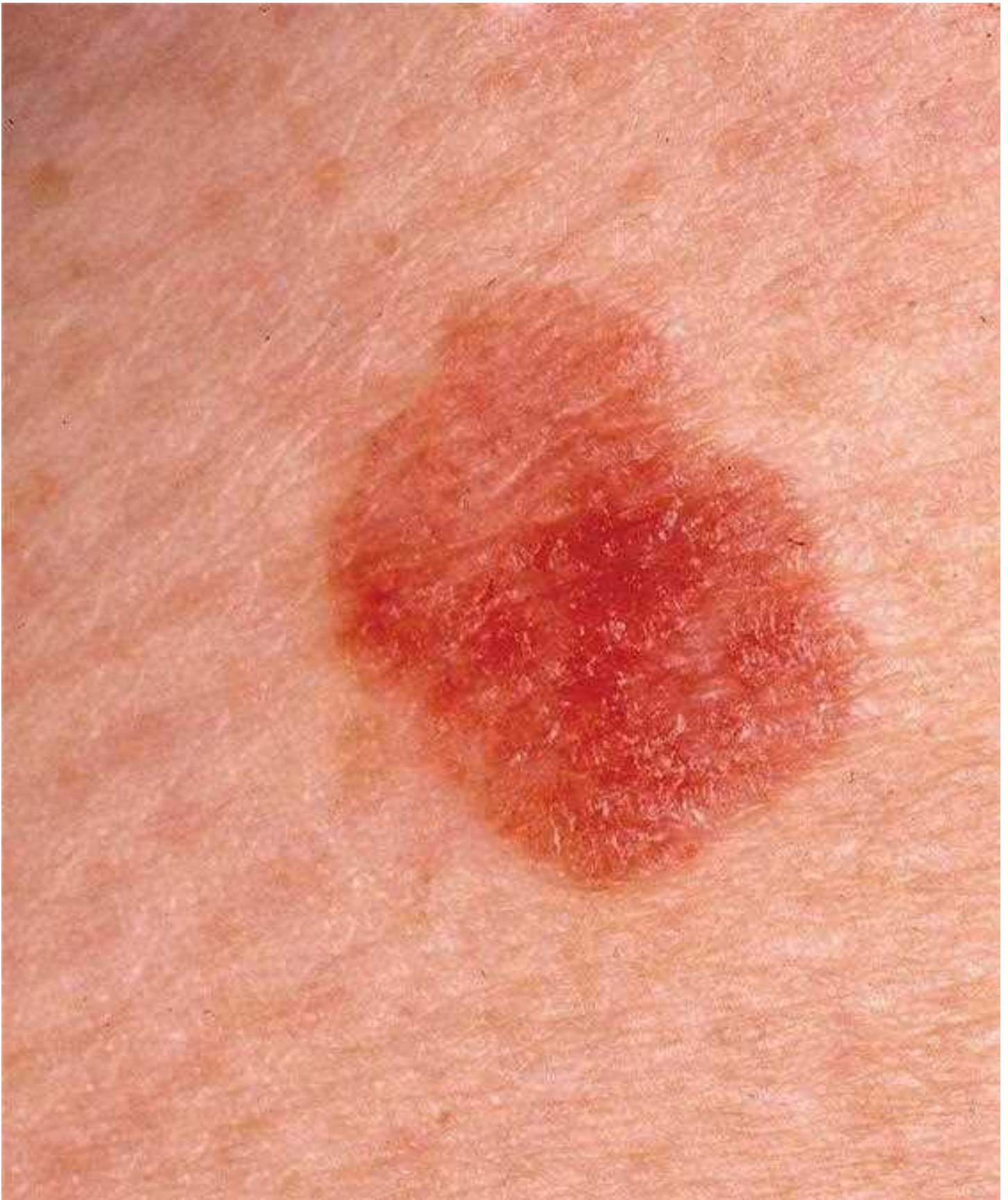

Figure 23.2 Bowen's disease.

Skin biopsy can confirm the diagnosis histologically. Management includes excision, curettage and cauterization, cryotherapy, 5-FU, imiquimod 5% and PDT (see [Chapters 24](#) and [25](#)).

Malignant skin tumours

Basal cell carcinoma (BCC)

This is the most common cancer in humans with a lifetime risk of around 30%. Known risk factors for BCC include increasing age, fair skin, high-intensity UV exposure, radiation, immunosuppression, previous history of BCCs and congenital disorders such as Gorlin's syndrome. Sun-exposed skin in the 'mask area' of the face is most frequently affected. Typically, lesions start as small papules that slowly grow. Lesions often have a 'pearly' shiny translucent quality. Colour varies from clear to deeply pigmented. The tumour is composed of masses of dividing basal cells that have lost the capacity to differentiate any further. As a result, no epidermis is formed over the tumour and the surface breaks down to form an ulcer, the residual edges of the nodule forming the characteristic 'rolled edge'. Once the basal cells have invaded the deeper tissues the rolled edge disappears.

Types of BCC

Nodular lesions appear as small papules or nodules with a rolled edge ([Figure 23.3](#)) and frequently a central depression that may become ulcerated. The nodules are pearly and may have dilated telangiectatic vessels on their surface. The histological features of BCC show collections of basaloid tumour cells ([Figure 23.4](#)), the pattern of which determines the histological type (i.e. nodular, superficial, morphoeic, cystic, etc.). Determining the tumour type histologically prior to definitive treatment ensures that the most appropriate management plan can be devised for each patient. If the initial tumour is incompletely excised/inadequately treated, then the BCC can recur ([Figure 23.5](#)). Many BCCs on the face are now treated routinely with Mohs' micrographic surgery to ensure that the tumour is fully resected (see [Chapter 24](#)) at the primary procedure.

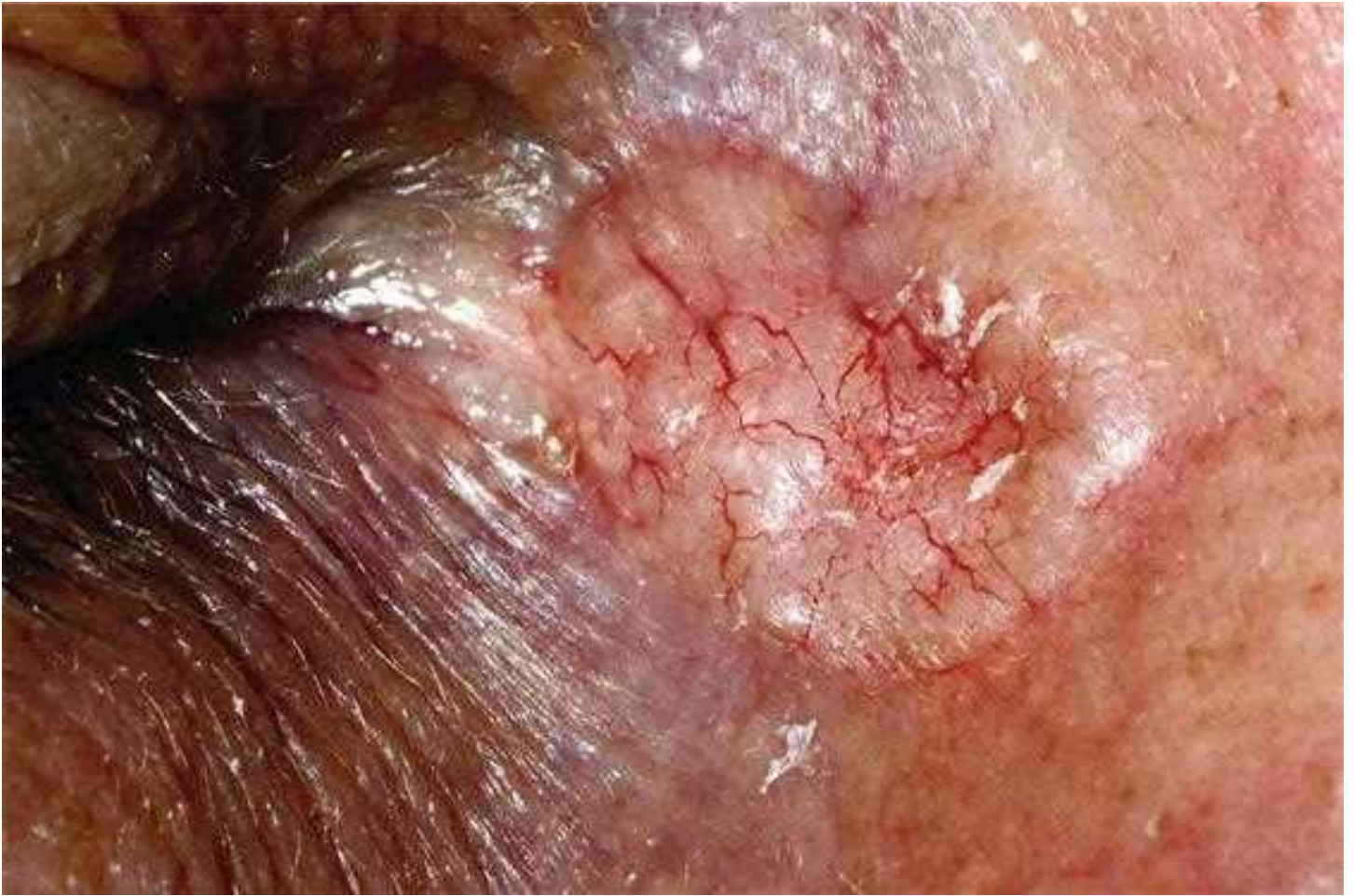

Figure 23.3 Nodular-type basal cell carcinoma inner canthus of the eye.

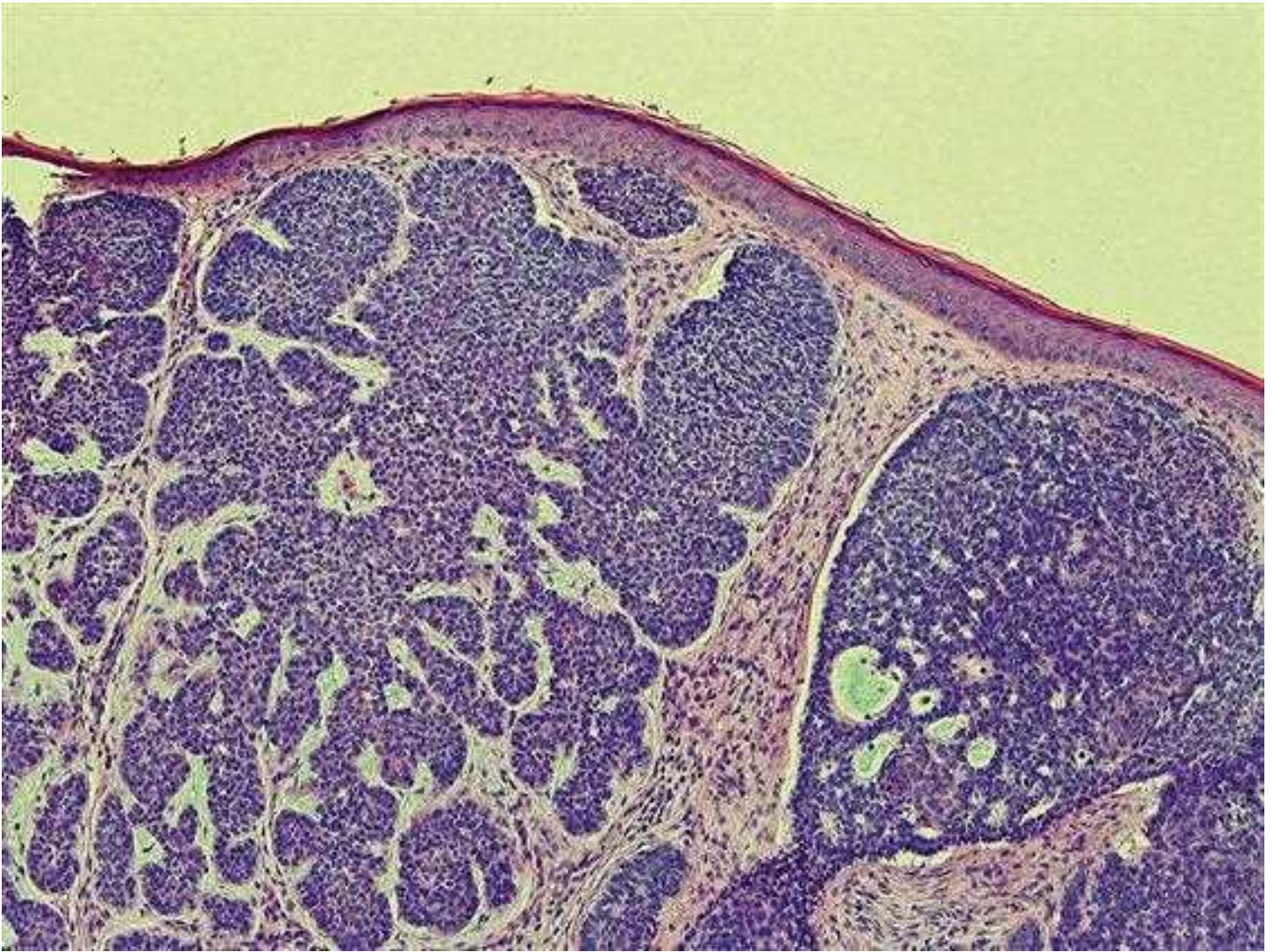


Figure 23.4 Nodular basal cell carcinoma histology.

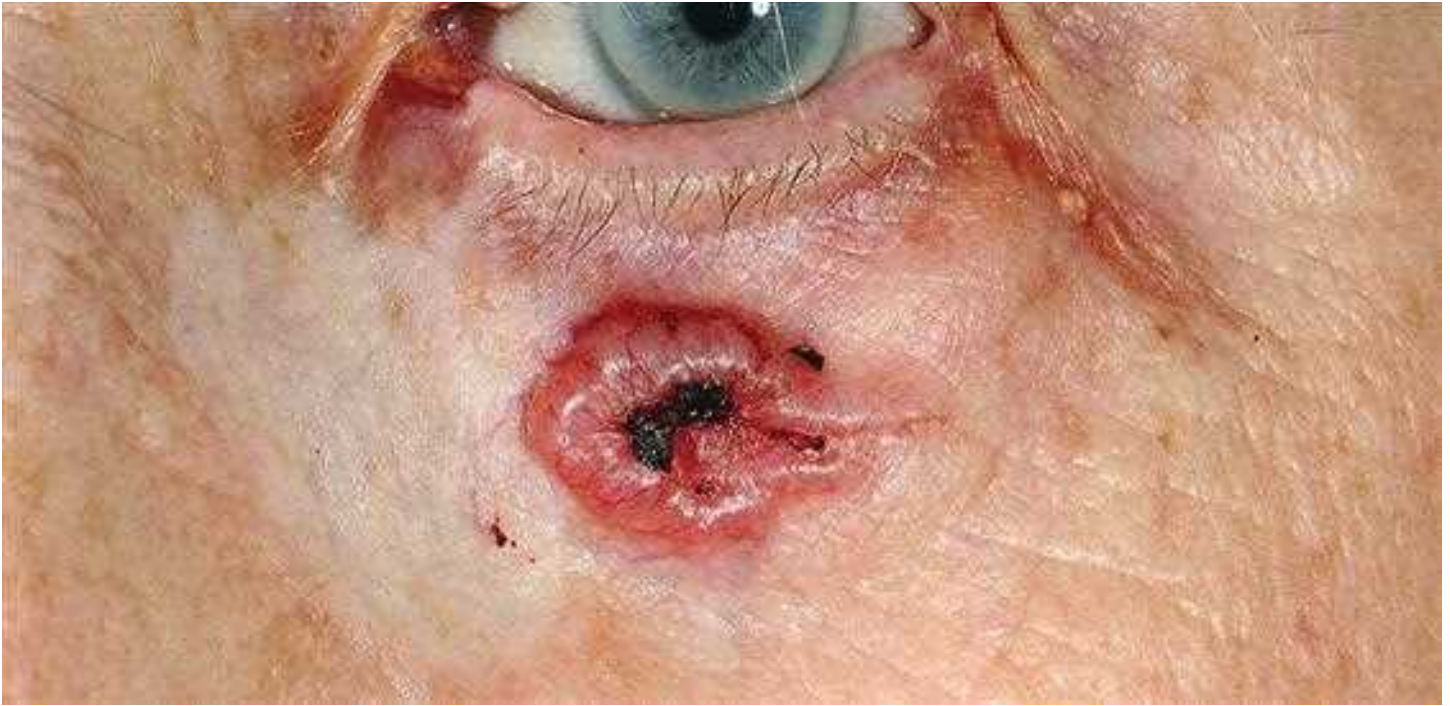


Figure 23.5 Recurrent nodular basal cell carcinoma arising in a hypopigmented scar.

Superficial lesions appear as an erythematous patch on the skin, often on the trunk. They may be mistaken for a patch of eczema or tinea but are not usually pruritic and slowly enlarge ([Figure 23.6](#)). A firm ‘whipcord’ edge may be present.

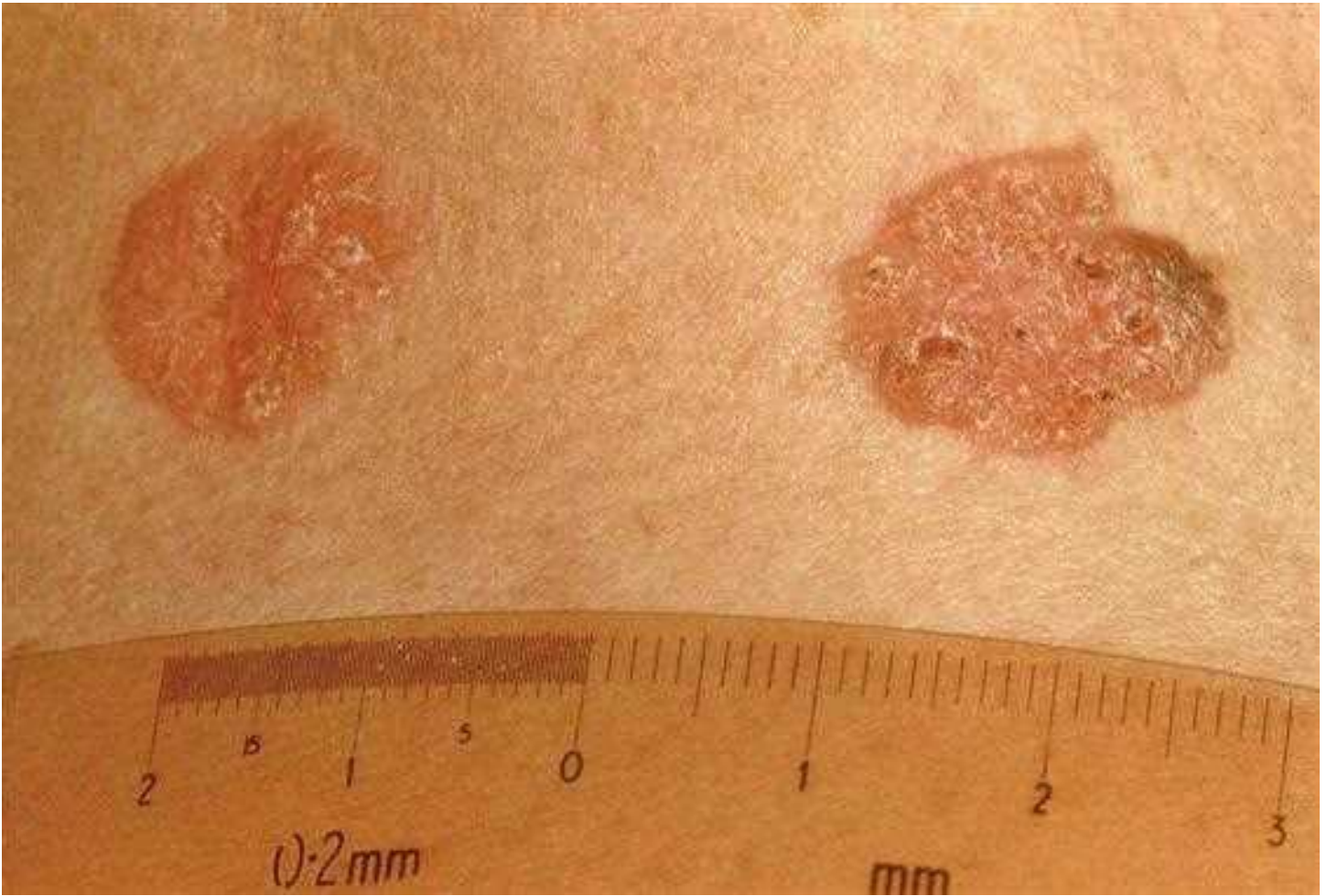

Figure 23.6 Superficial basal cell carcinoma.

Pigmented lesions can lead to confusion with naevi, seborrhoeic keratoses and melanoma ([Figure 23.7](#)).

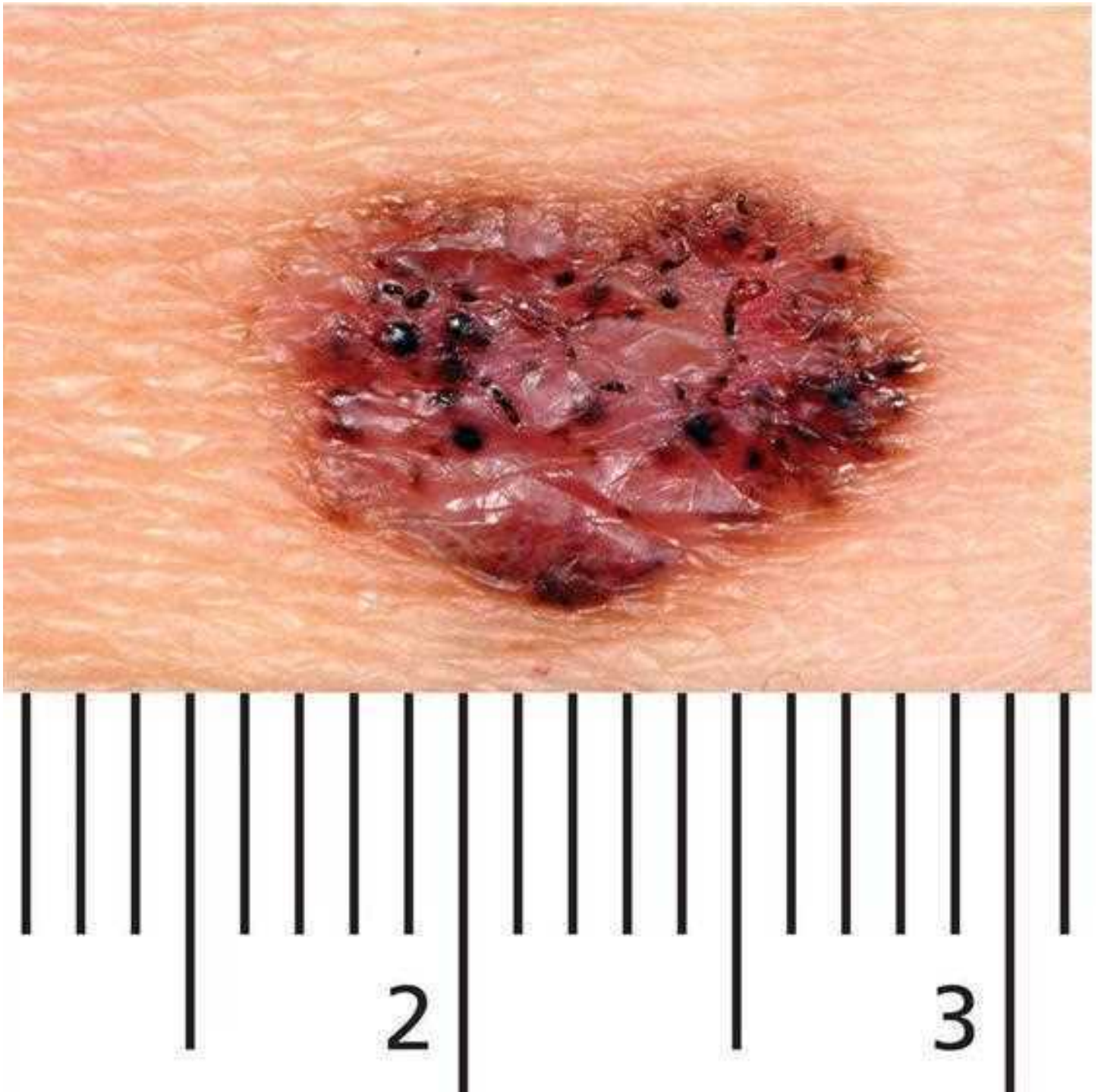

Figure 23.7 Pigmented basal cell carcinoma.

Morphoeic or sclerosing type appears as a superficial atrophic scar in the skin. There is loss of the normal skin markings and the edge is usually indistinct ([Figure 23.8](#)). This can lead to incomplete excision of these infiltrative BCCs and therefore Mohs' micrographic surgery may be indicated (see [Chapter 24](#)) to ensure surgical cure.

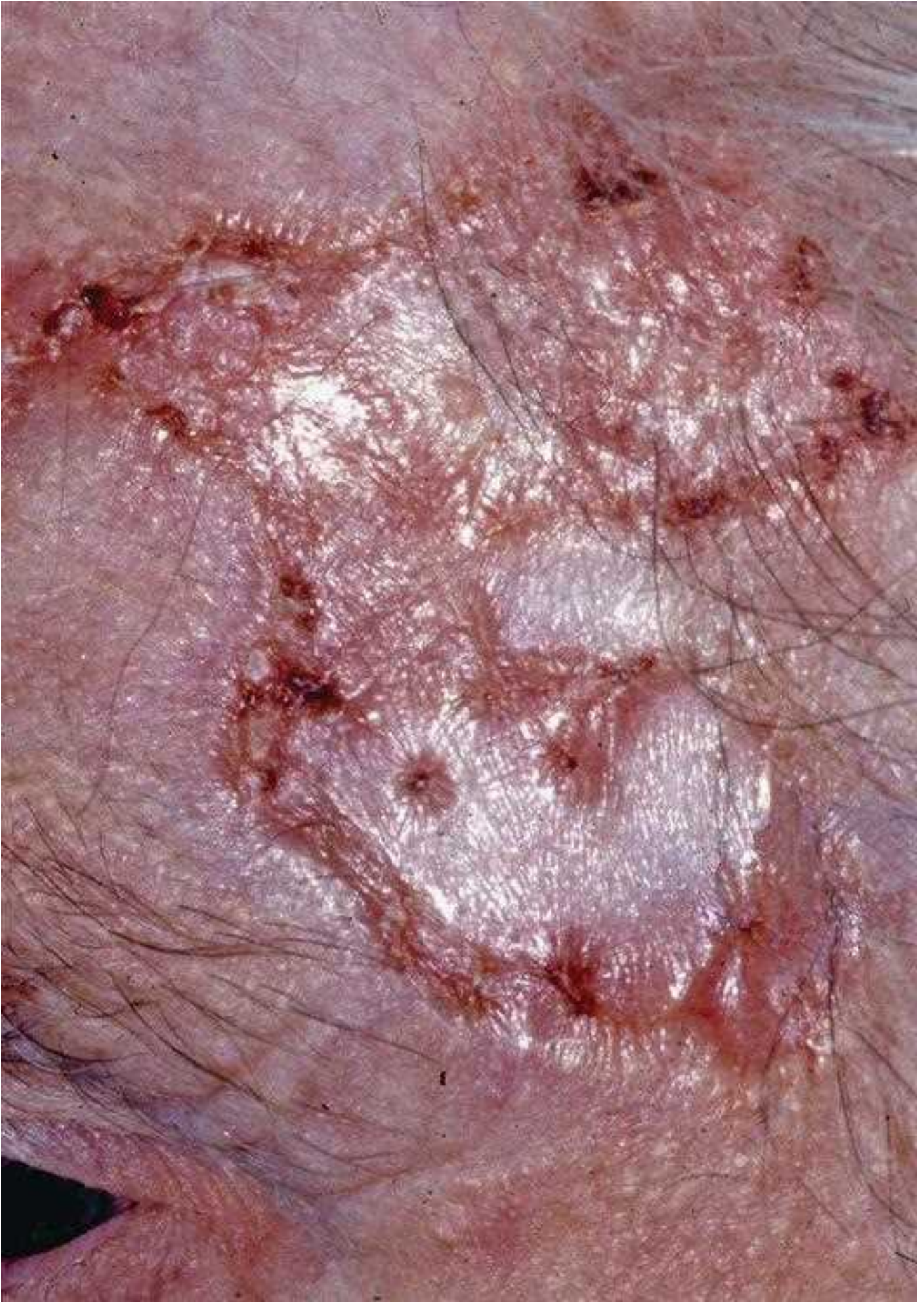

Figure 23.8 Morphoeic basal cell carcinoma.

Management of BCC's

The growth pattern determined histologically usually guides management, so most tumours are biopsied prior to definitive treatment. The site and the size of the BCC, comorbidities, and patient preference all guide what treatment option is most suitable. Treatment options include excision (including Mohs' micrographic surgery), excision and grafting, curettage and cautery, radiotherapy, cryotherapy, imiquimod 5% and PDT for large superficial BCCs (see [Chapters 24](#) and [25](#)). For advanced or metastatic BCCs unsuitable for surgery/radiotherapy oral Vismodegib (Erivedge™) 150 mg daily can be taken. Erivedge has been shown to shrink 30–40% of tumours by blocking the abnormal signalling found in the Hedgehog pathway (present in 90% of BCCs).

Decisions as to the optimum therapy for each individual patient is complex and is therefore frequently discussed with the patient at a multidisciplinary skin cancer meeting including dermatologists, plastic surgeons, oculoplastic surgeons, oncologists, and specialist cancer nurses.

As a rule, surgical scars will improve with time compared to radiotherapy sites which tend to deteriorate cosmetically. Mohs' micrographic surgery is becoming the 'gold standard' for complete excision of BCCs on the face/scalp, particularly those near the eyes and other vital structures where identifying clear tumour margins is essential to preserve normal tissue and function. Large nasal tip lesions may be more optimally treated with radiotherapy as this can be a difficult site for grafting.

Squamous cell carcinoma (SCC)

SCC is the second commonest skin cancer after BCC. Risk factors for SCC are similar to BCCs but in addition SCC may develop in any chronic wound or scar (Marjolin's ulcer), and HPV is thought to play a significant role in the pathogenesis. Transplant recipients who are medically immunosuppressed seem to be particularly susceptible to the development of SCCs which may be HPV mediated.

Dysplastic proliferations of abnormal keratinocytes may arise de novo or in pre-existing skin lesions such as AKs or Bowen's disease. By definition, SCCs have invasive tumour cells within the dermis. Seventy percent of lesions occur on the head and neck. Clinical suspicion of an SCC arises when lesions are rapidly growing, painful, and markedly hyperkeratotic ([Figures 23.9–23.11](#)). SCCs are usually nodular with surface changes including crusting, ulceration, or the formation of a cutaneous horn. Some lesions can be verrucous and therefore mistaken for viral warts, or indeed arise from a chronic viral wart. High risk sites for metastases include SCC on the lip, ear, hands/feet, and genitalia.

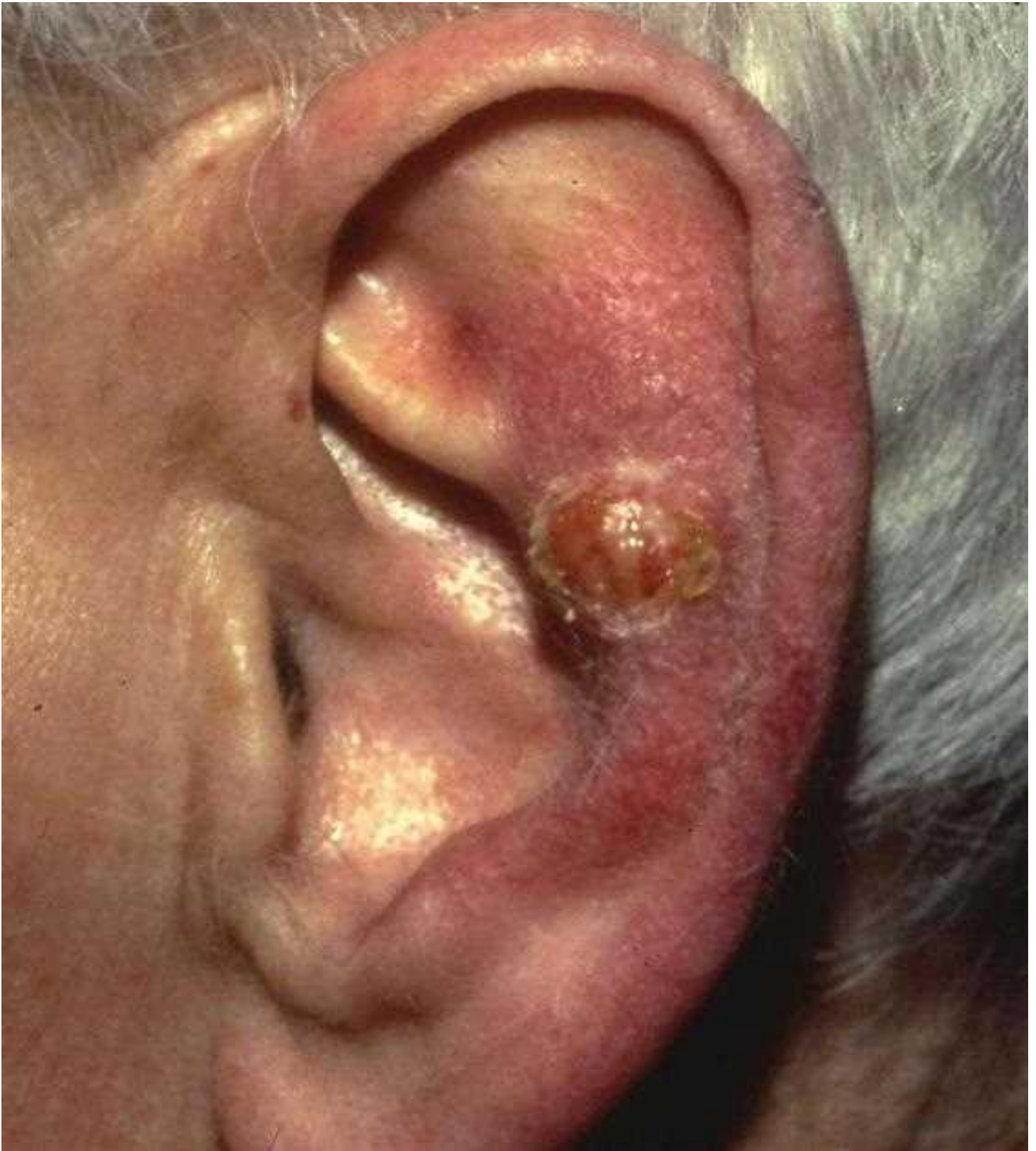

Figure 23.9 Squamous cell carcinoma: initial stages on the pinna.

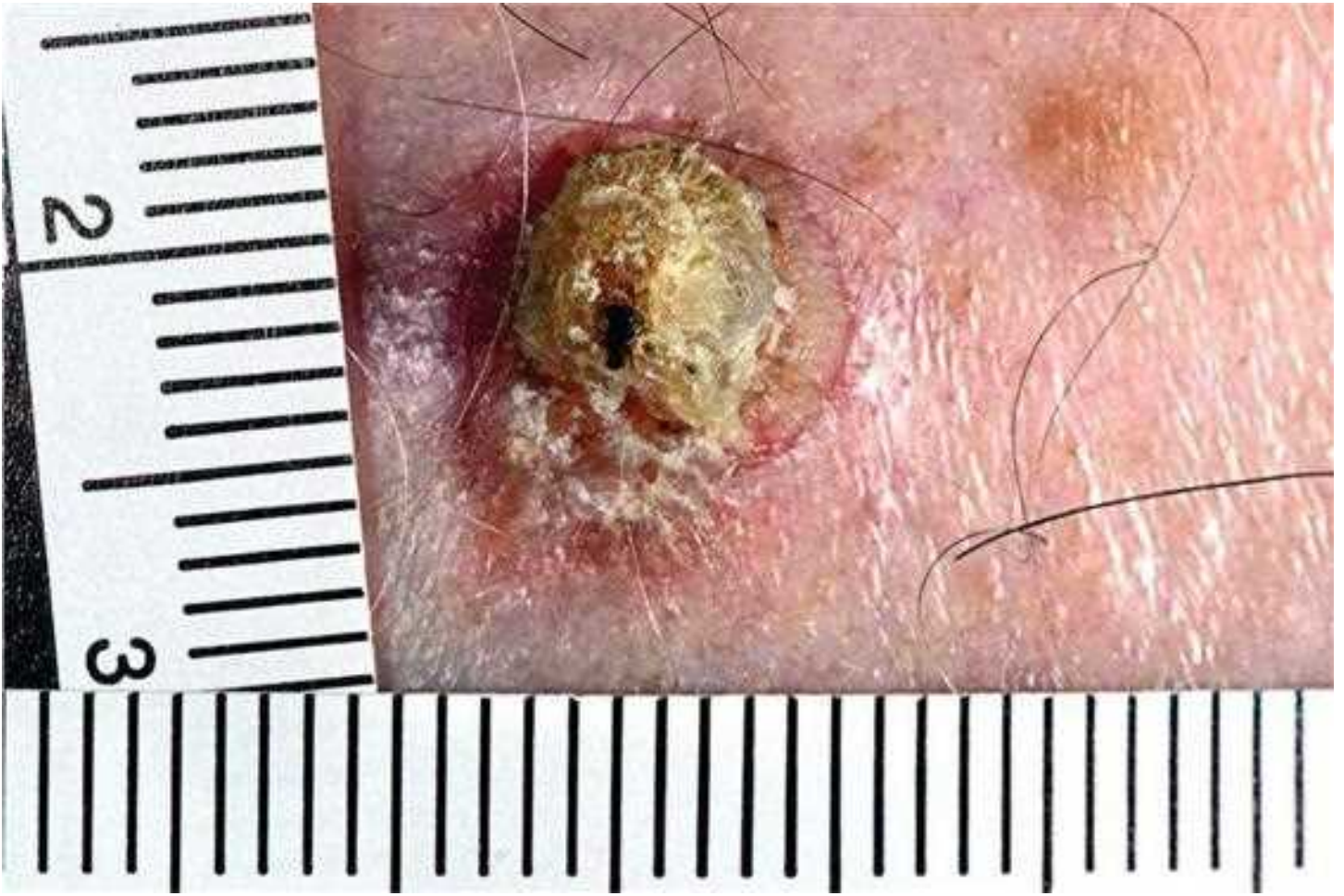

Figure 23.10 Hyperkeratotic rapidly enlarging squamous cell carcinoma on the scalp.

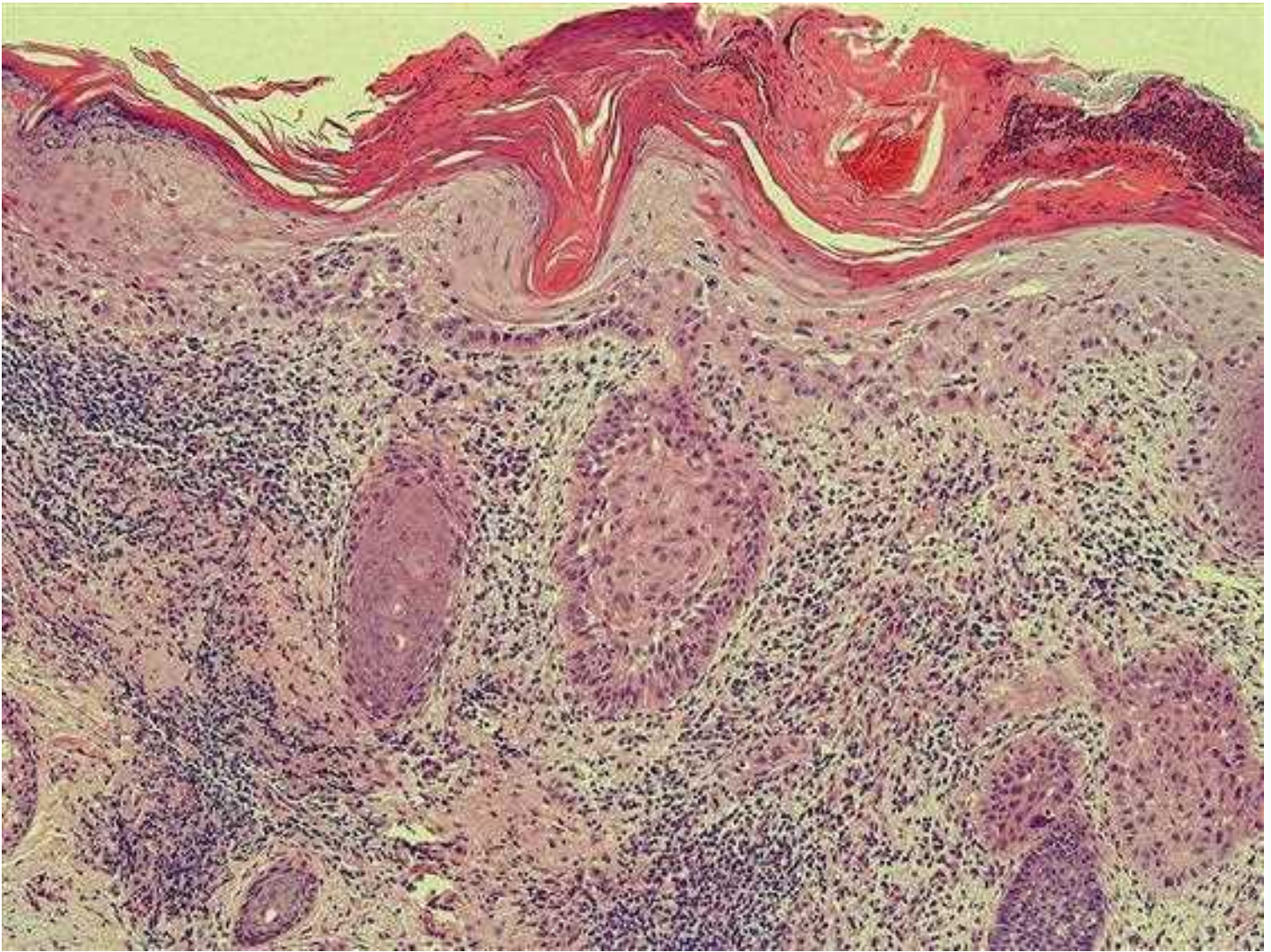


Figure 23.11 Squamous cell carcinoma histology.

Keratoacanthoma is thought to be a variant of SCC, and current thinking dictates these should be treated as if they are indeed SCCs. These lesions typically appear rapidly over a few weeks and have a characteristic central crater within the nodule ([Figure 23.12](#)). They may spontaneously regress, leaving a significant scar which has led to debate about their exact nature and how they should be managed. Histologically, they look malignant and most specialists feel comfortable treating them as for an SCC.

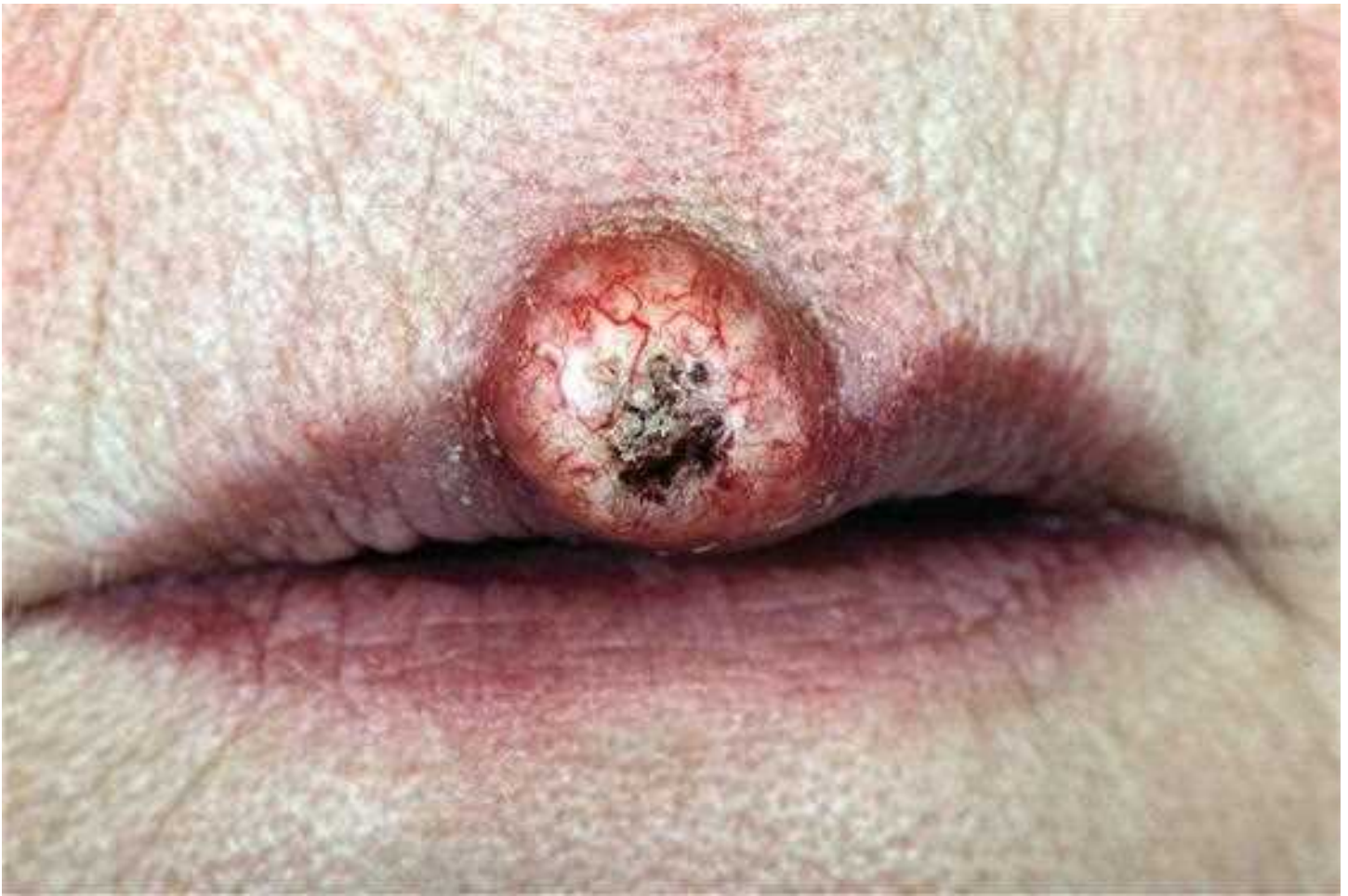

Figure 23.12 Keratoacanthoma-like squamous cell carcinoma on the lip.

Regional lymph nodes should be palpated to look for local metastases for any lesions suspicious of an SCC; in addition, involvement of other organs such as the liver, lung, or brain may occur. A computed tomography (CT) scan may be indicated for very large or aggressive lesions before decisions concerning management.

Management of SCC's

Management of these patients should ideally be discussed at a multidisciplinary team meeting with the patient (see section on management of BCC).

Surgical options. Ideally lesions should be excised with a 4–6 mm margin. Skin grafting may be required depending on the size of the lesion and the site. Tumour curettage and cauterization (three passes over the affected area) can be highly successful in experienced hands.

Medical options. Radiotherapy can provide excellent results for tumours not amenable to surgery. Radiotherapy does, however, involve multiple trips to the hospital and symptoms of pain at the site during healing. In patients who develop multiple SCCs such as renal transplant patients, secondary prophylaxis with oral retinoids may be considered. These have been shown to reduce the number of new lesions appearing if taken indefinitely.

Moles/naevi: benign or malignant?

The term *naevus* (mole) is derived from the Greek word meaning ‘nest’, which is formed by a proliferation of melanocytes. Benign moles generally develop minor changes over the years as they mature (becoming slightly more protuberant). More rapid changes can occur during pregnancy. However, rapid change may indicate transformation into melanoma. The ABCDE acronym is a useful guide for assessing the malignant potential of a mole: *asymmetry*, *border* (irregular), *colour* (irregular), *diameter* (>0.5 cm), *evolving* ([Box 23.1](#)). Any symptoms such as pain, crusting, ulceration, or bleeding may also indicate malignant transformation. Patients can be educated about what changes to look for in their own moles, particularly the ‘ugly duckling sign’ which has been shown to be very helpful. A medical practitioner should always try to examine all the patient's skin and look for any mole that ‘stands out from the crowd’ (ugly duckling sign).

Box 23.1 The ABCDE of malignant pigmented lesions

- *Asymmetry*. If you draw an imaginary line through the centre of a mole in any axis and both halves match then the mole is symmetrical and likely to be benign. (Asymmetry can be the first sign of melanoma).
- *Border*. Benign moles usually have an even, regular outline. Any indentations such as scalloped edges may indicate malignant change, such that one part of the mole is growing.
- *Colour*. Variation in colour may be a sign of dysplasia or malignant change in a mole. Melanomas may be intensely black and show variable colour within a single lesion from white to slate blue with all shades of black and brown. Amelanotic melanomas show little or no pigmentation.
- *Diameter*. Apart from congenital naevi, most benign moles are less than 1 cm in diameter. Any lesion growing to over 0.5 cm should be carefully checked. However, some melanomas are small – 0.1–0.2 cm.
- *Evolving*. A mole changing over time.

Dysplastic naevi

These are moles that look atypical (‘funny-looking moles’). They are often deeply pigmented and have an irregular margin ([Figure 23.13](#)). Clinically and histologically, they have features of very early malignant change and therefore could progress to melanoma. Thirty percent of superficial spreading melanomas are thought to arise from pre-existing moles, 70% of melanomas appear de novo.

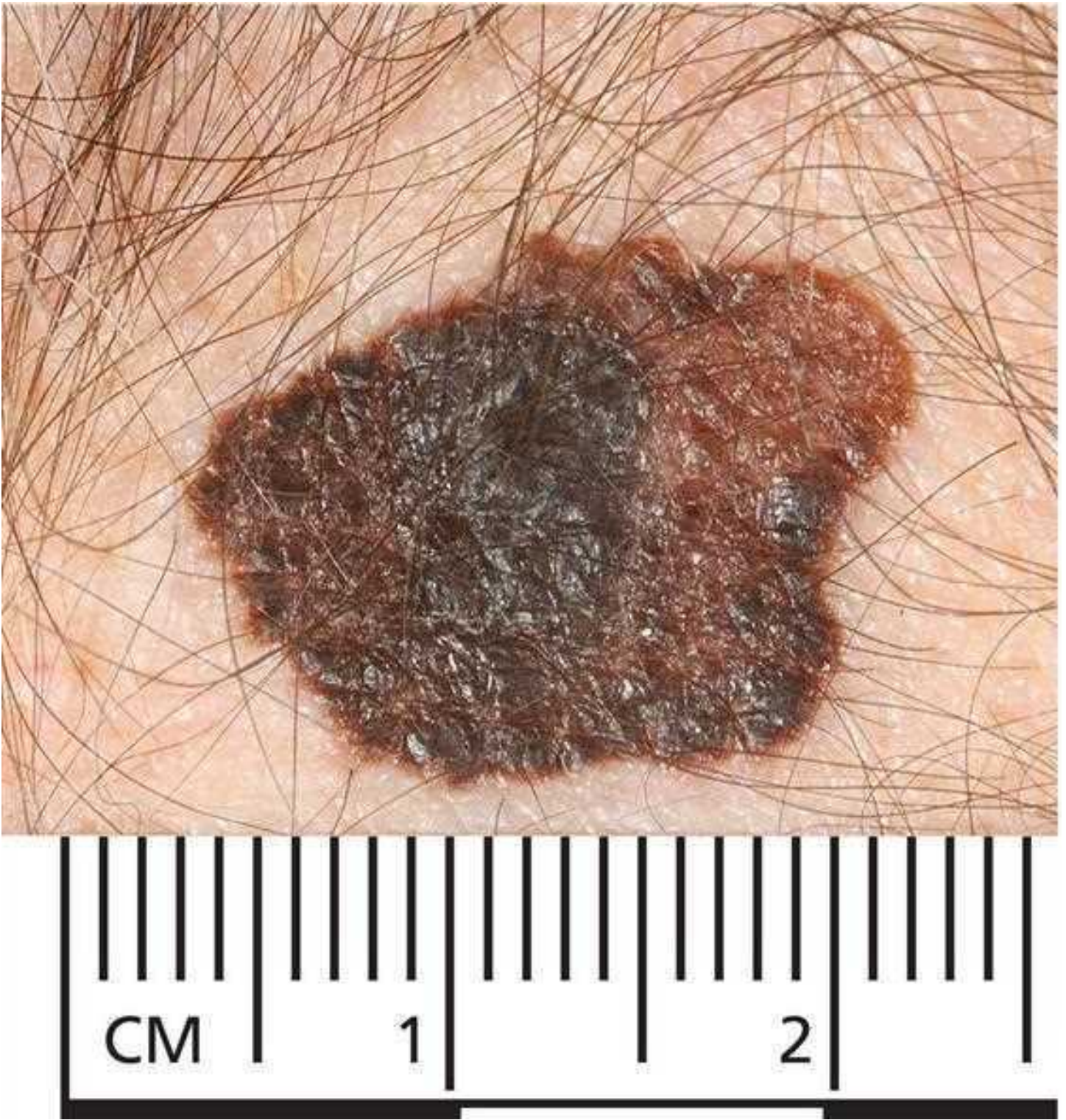

Figure 23.13 Dysplastic naevus.

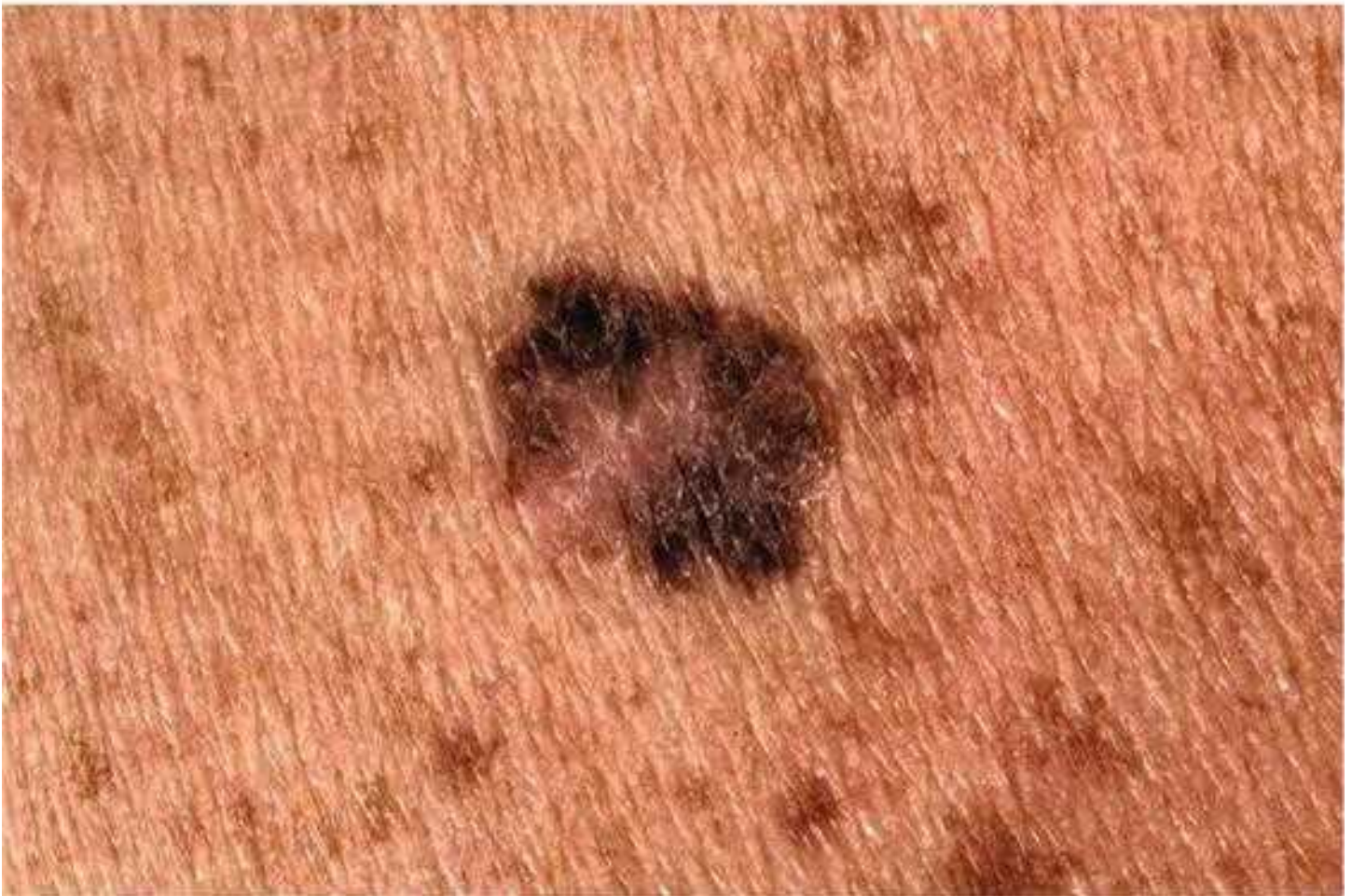
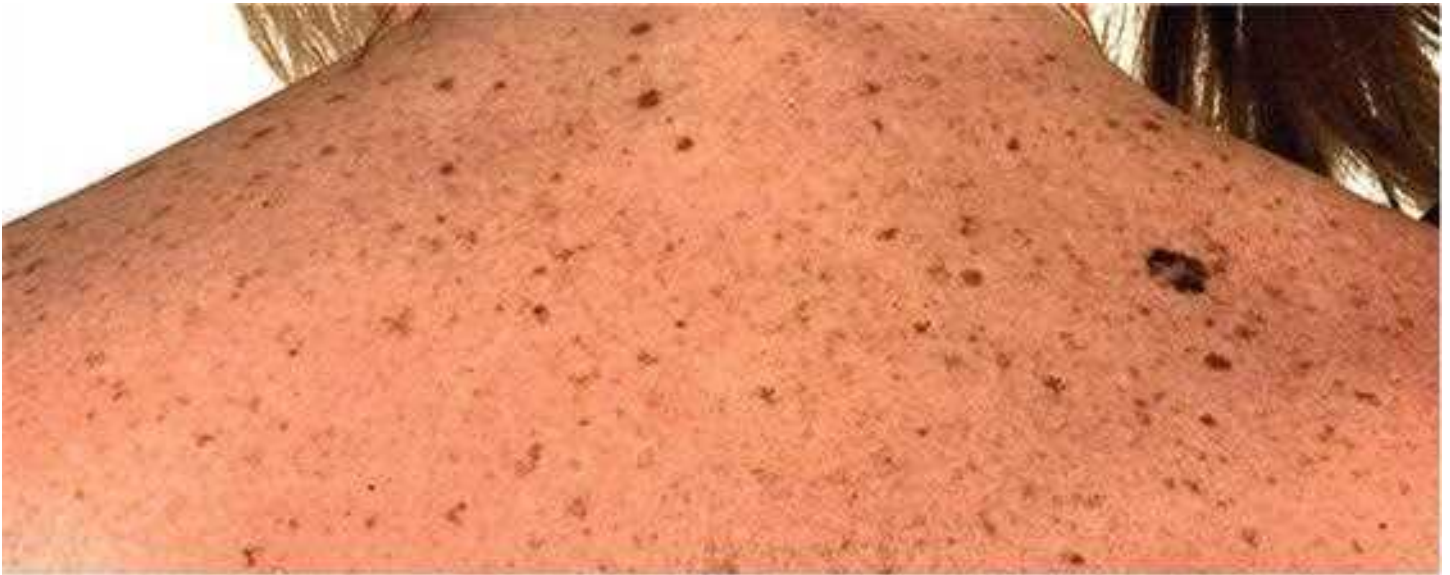
Figure 23.14 Superficial spreading melanoma on the right upper back.

Some patients have multiple atypical moles and may have the so-called *dysplastic naevus syndrome*. Usually, there is a family history of dysplastic moles. During adolescence, these patients acquire multiple pigmented moles most frequently on the trunk. Compared to normal moles, these naevi are larger and their pigment more heterogeneous. These patients often need regular monitoring by a skin specialist.

Melanoma

Melanoma is an invasive malignant tumour of melanocytes. Melanoma accounts for 4% of skin tumours but is responsible for 75% of skin cancer deaths. Most cases occur in white adults over the age of 30. Females are more commonly affected than males in the USA, but this trend is reversed in Australia. Solar radiation is a known carcinogen and is the main risk factor for melanoma, especially intermittent unaccustomed and high-intensity UV exposure particularly in childhood. Other risk factors include light skin tones, poorly tanning skin, red or fair-coloured hair, light-coloured eyes, female sex, older age, a personal or family history of melanoma, and congenital defect of DNA repair (xeroderma pigmentosum). The presence of giant congenital melanocytic naevi, one to four dysplastic naevi, multiple common moles, actinic lentiginosities, and change in a mole are additional risk factors for melanoma.

Incidence

The incidence of melanoma has tripled over the past 20 years. In Australia, 1 in 35 women and 1 in 25 men will develop melanoma during their lifetime. In Europe, there are 63 000 new cases of melanoma diagnosed each year, accounting for 2% of all cases. In the USA, the lifetime risk of developing melanoma is estimated to be 1 in 60.

Sun exposure

The highest incidence of melanoma occurs in countries near the equator with high-intensity UV throughout the year. However, skin type and the regularity of exposure to sun are also important. The incidence is higher in fair-skinned people who have concentrated high-intensity exposure on holiday than those with darker skin types who have regular exposure throughout the year. Sunburning episodes are thought to be a risk factor for melanoma. The most frequent site of melanoma in women is the legs while in men it is the trunk. This is thought to be a direct consequence of behaviour in the sun, that is women expose their legs and men remove their shirts.

Pre-existing moles

It is rare for ordinary moles to become malignant but giant congenital naevi and multiple dysplastic naevi are more likely to develop into melanoma. Thirty percent of melanomas are thought to arise from pre-existing moles.

Types of melanoma

Clinically, there are five main types of melanoma.

Superficial spreading melanoma is the most common type. It is common on the back in men and on the legs in women. As the name implies the melanoma cells spread superficially in the epidermis, becoming invasive after months or years. The margin and the surface are irregular, with pigmentation varying from brown to black ([Figure 23.14](#)). There may be surrounding inflammation and signs of regression – pale areas within

it/around it ([Figure 23.15](#)). Nodules may appear within the tumour when it becomes invasive, which worsens the prognosis.

Lentigo maligna melanoma occurs characteristically on the face of elderly people. Initially, patients may have single or multiple solar lentigos which are benign and common but can look suspicious. However, over the years patients may develop a slowly growing, irregular, and larger pigmented macule (lentigo maligna) ([Figure 23.16a](#)), which if very large can be treated with imiquimod over many months rather than extensive surgery ([Figure 23.16b](#)); however, if a nodule/darker colour develops within the pigmented patch then suspect lentigo maligna melanoma ([Figure 23.17](#)).

Nodular melanoma presents as a dark nodule from the start without a preceding in situ epidermal phase ([Figure 23.18](#)). It is more common in men than in women and is usually seen in people in their fifties and sixties. This tumour is in a vertical growth phase from the start and therefore has a correspondingly poor prognosis.

Acral melanoma occurs on the palm and soles and near/under the nails. Benign pigmented naevi may also occur in these sites and it is important to recognise early dysplastic change (ABCDE – as above). A very important indication that discolouration of the nail is due to melanoma is ‘Hutchinson's sign’: pigmentation of the nail fold adjacent to the nail ([Figure 23.19](#)). It is important to distinguish talon noir, in which a black area appears on the sole or heel because of trauma – for example, sustained while playing sport – causing haemorrhage into the dermal papillae. Paring the skin gently with a scalpel will reveal distinct blood-filled papillae.

Amelanotic melanoma. As the melanoma cells become more dysplastic and less well differentiated they lose the capacity to produce melanin and form an amelanotic melanoma ([Figure 23.20](#)). Such non-pigmented nodules may be regarded as harmless but in fact are highly malignant. A rare form but also highly malignant is the desmoplastic form of melanoma ([Figure 23.21](#)).

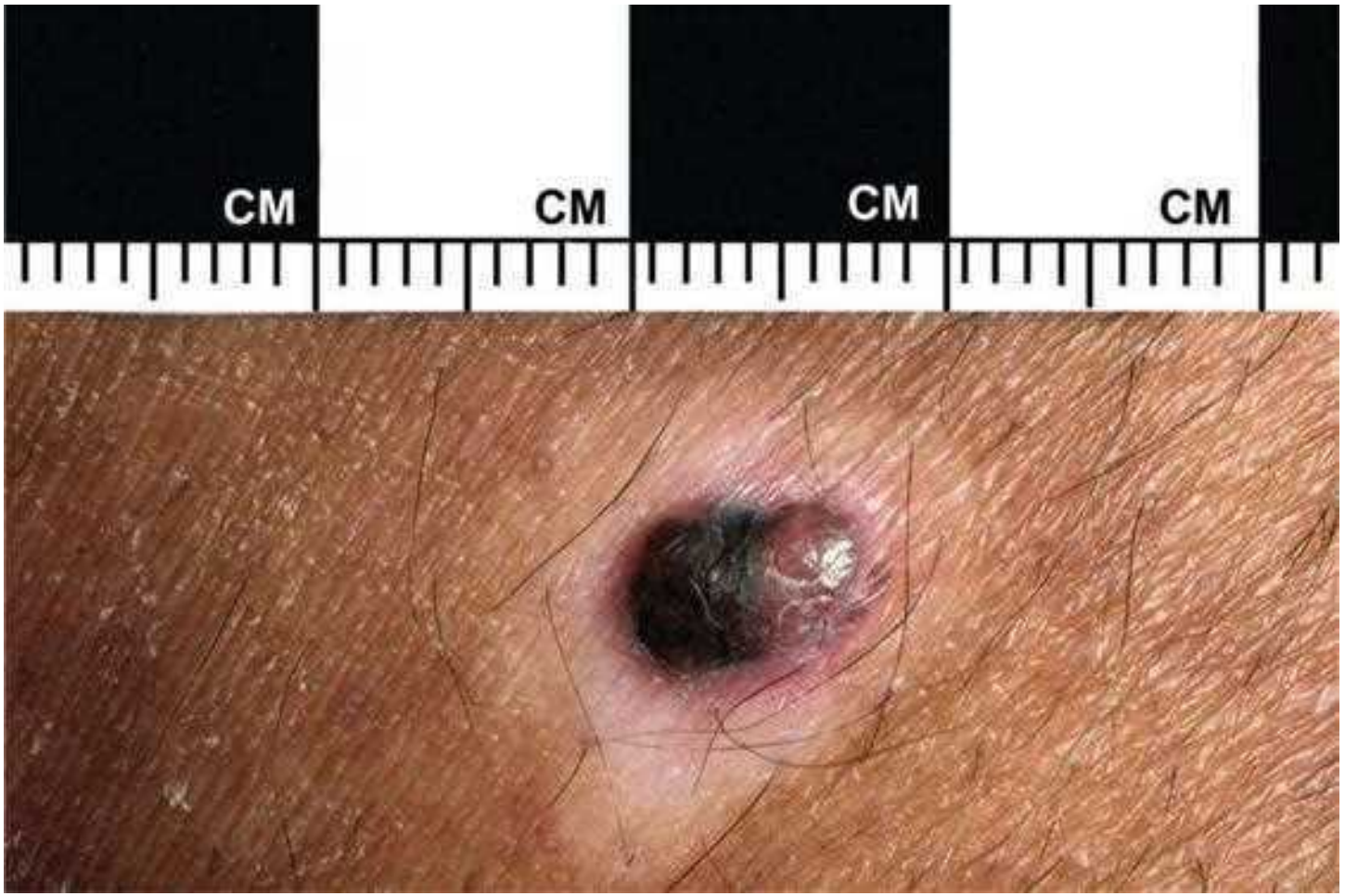
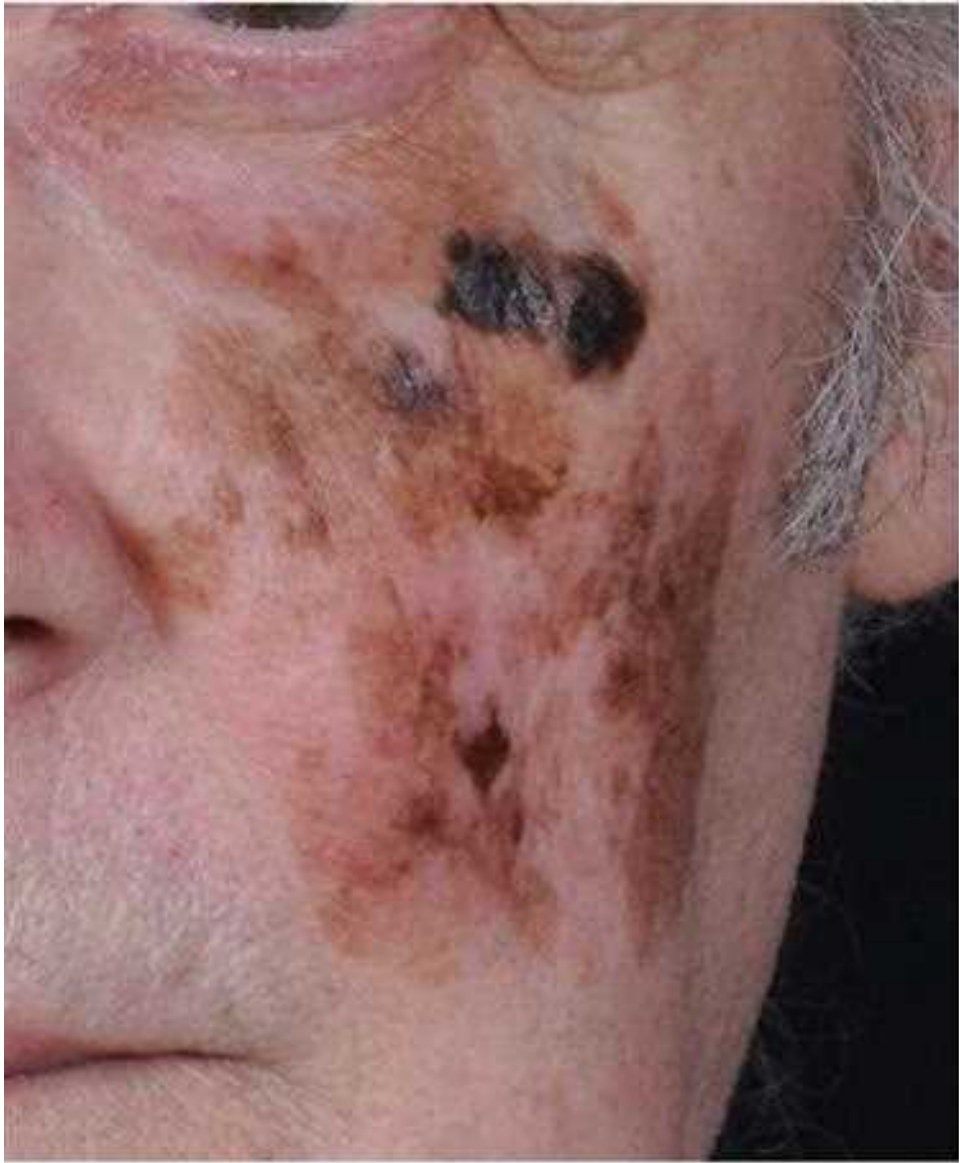
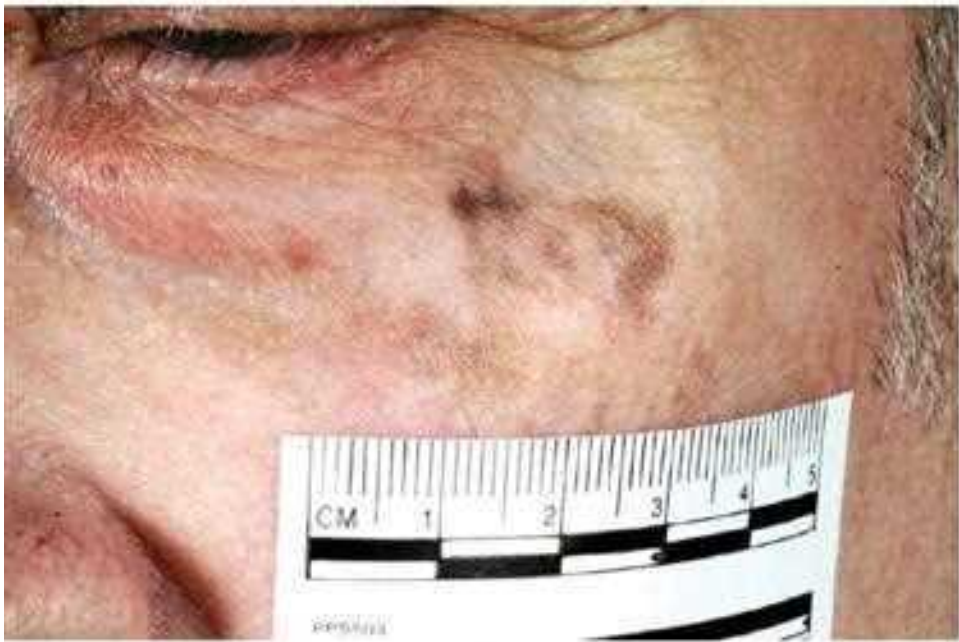
Figure 23.15 Melanoma with a pale area of regression around it.



(a)



(b)

Figure 23.16 (a) Lentigo maligna pre-imiquimod treatment and (b) lentigo maligna midway through treatment with topical imiquimod.

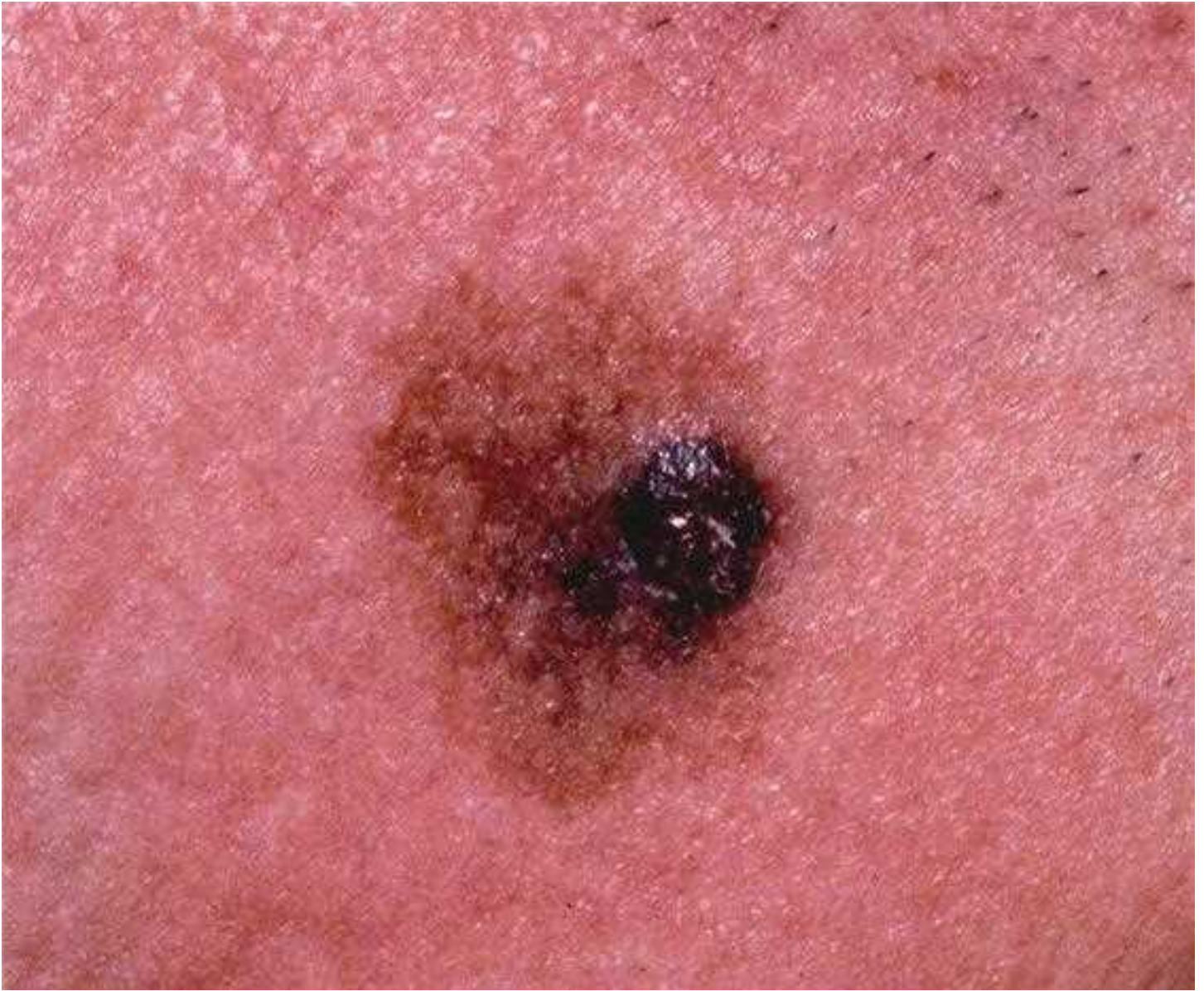
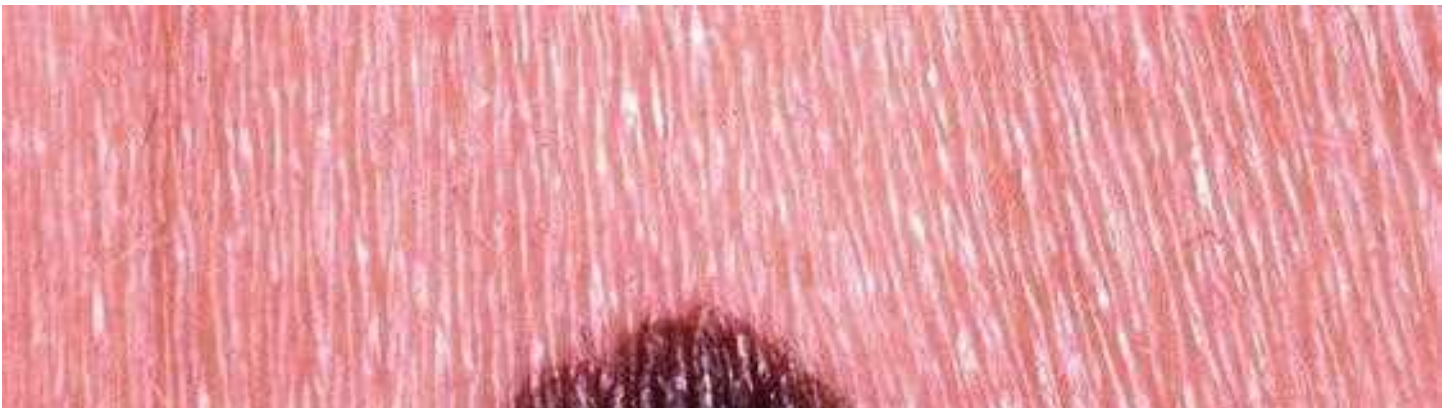
Figure 23.17 Lentigo maligna melanoma.



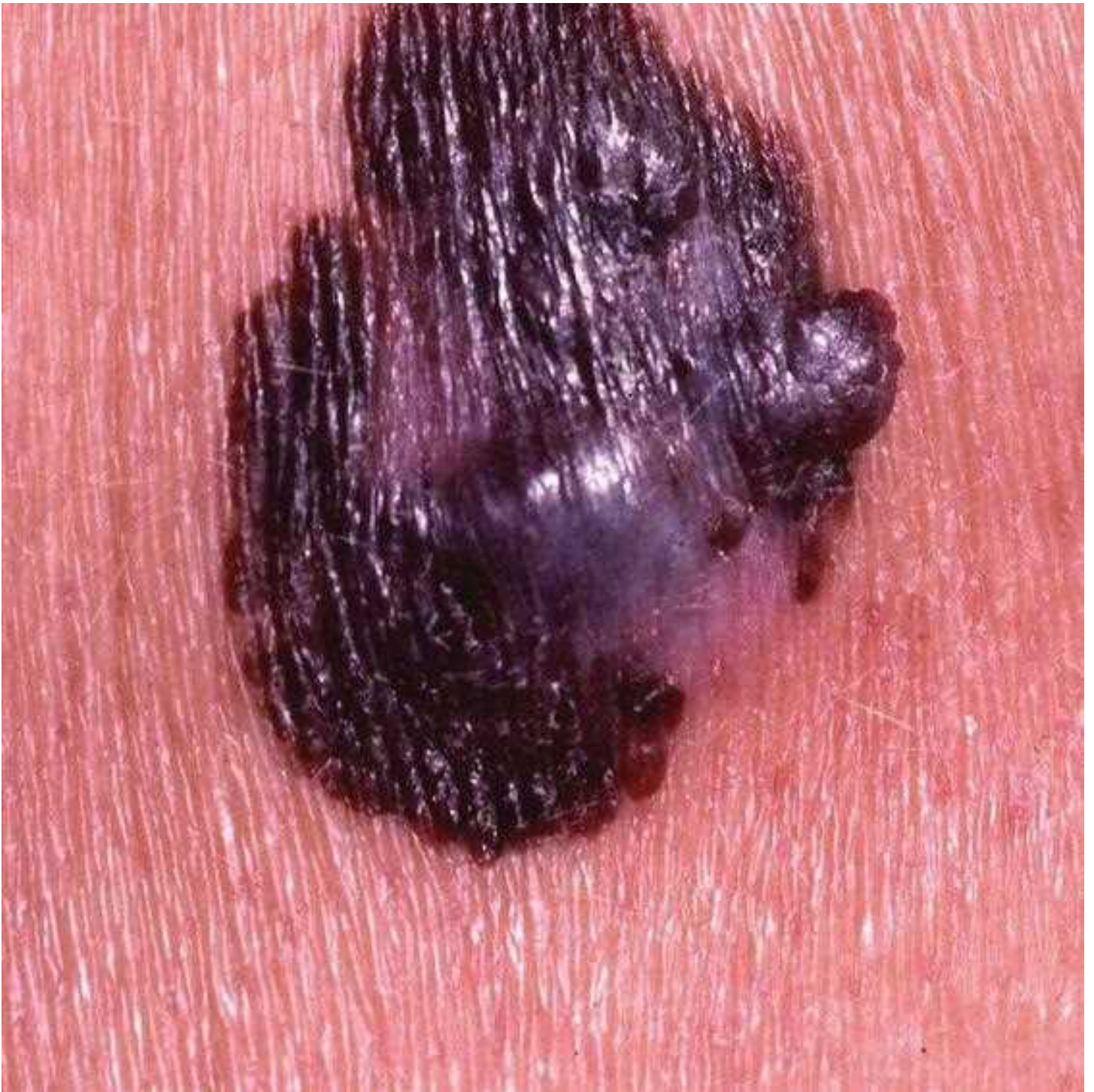

Figure 23.18 Nodular melanoma.

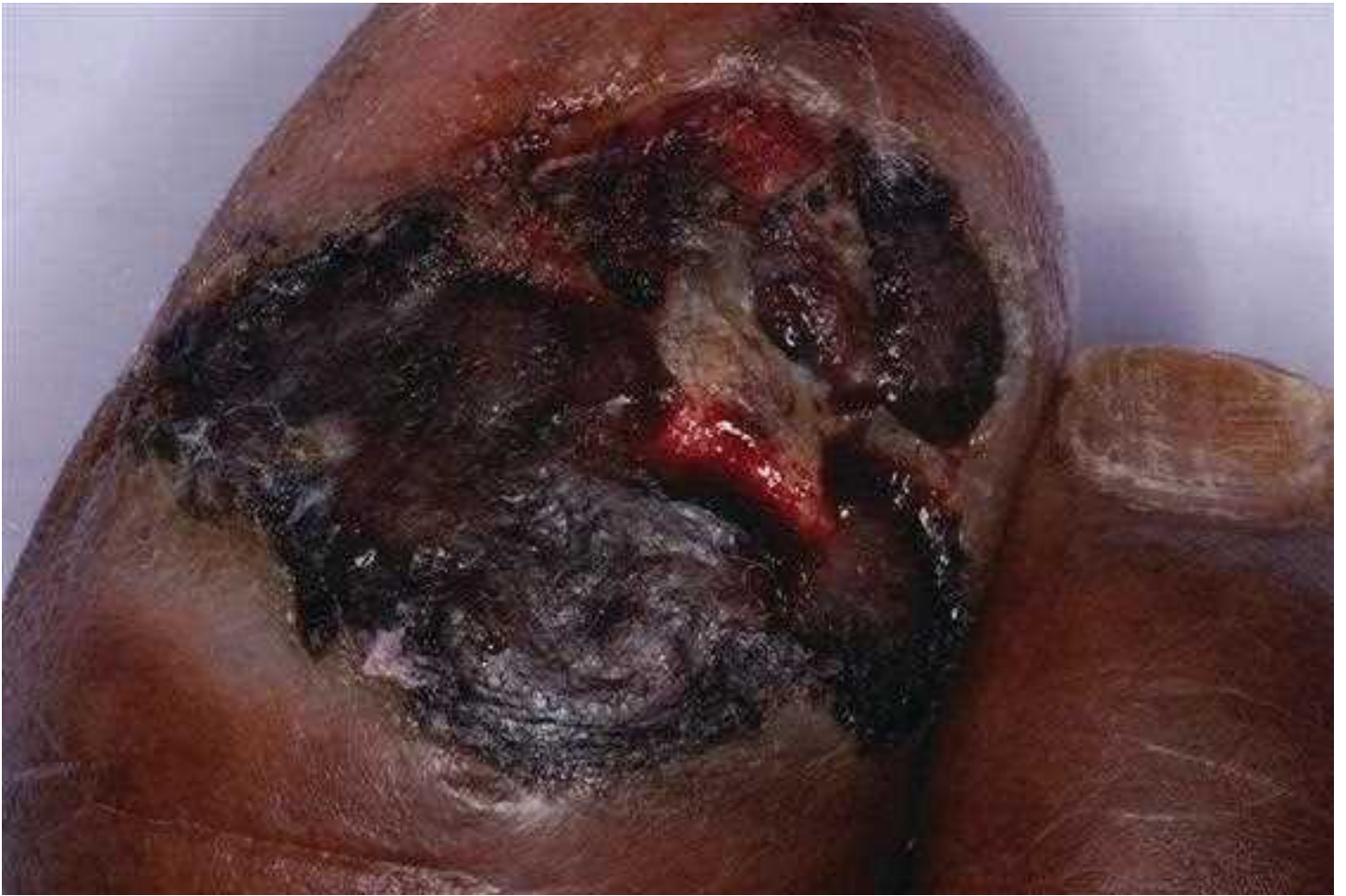

Figure 23.19 Acral melanoma.

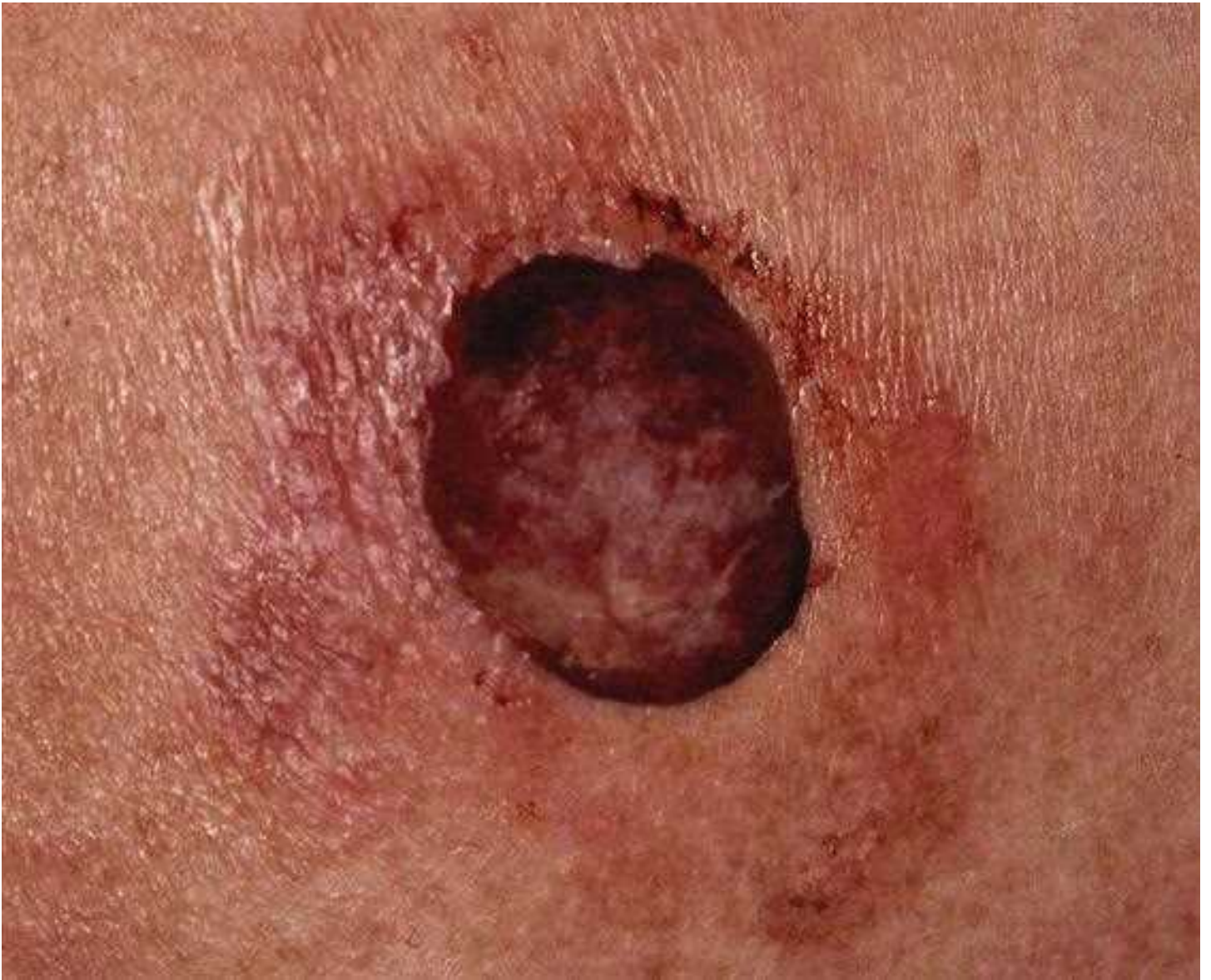

Figure 23.20 Amelanotic melanoma.

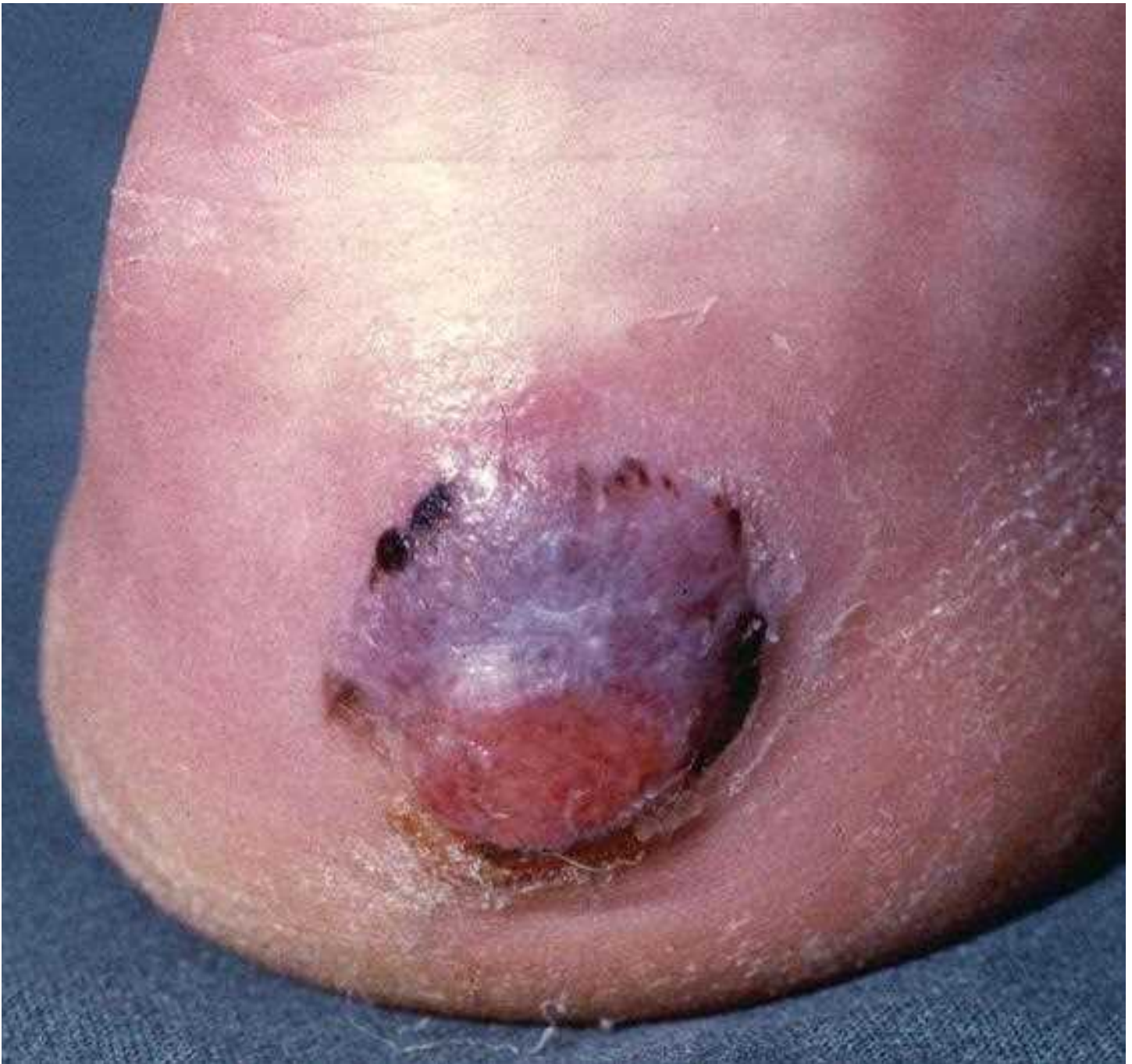

Figure 23.21 Desmoplastic melanoma.

Prognosis

Prognosis depends on the depth to which the melanoma has penetrated below the base of the epidermis seen histologically: the so-called Breslow thickness of the lesion. This is measured histologically in millimetres from the granular layer to the deepest level of invasion. The depth alone can give an indication of prognosis: Breslow of less than 1.5 mm is associated with a 90% 5-year survival, 1.5–3.5 mm with a 75% 5-year survival and greater than 3.5 mm with only a 50% 5-year survival. These figures are based on patients in whom the original lesion had been completely excised. A recent study in Scotland has shown an overall 5-year survival of 71.6–77.6% for women and 58.7% for men. Ulceration, lymph node involvement

and skin metastases are associated with a poorer prognosis and therefore accurate prognosis cannot be determined by Breslow thickness alone. Therefore, more accurate melanoma staging considers not only Breslow thickness but also ulceration, lymph node involvement, and metastases to distant organs. If melanoma is not recognised and excised, then melanoma satellites (small islands of melanoma nearby) may develop and ultimately metastases in transit ([Figure 23.22](#)) and/or distant metastases may spread haematogenously and via the lymphatics ([Table 23.1](#)).

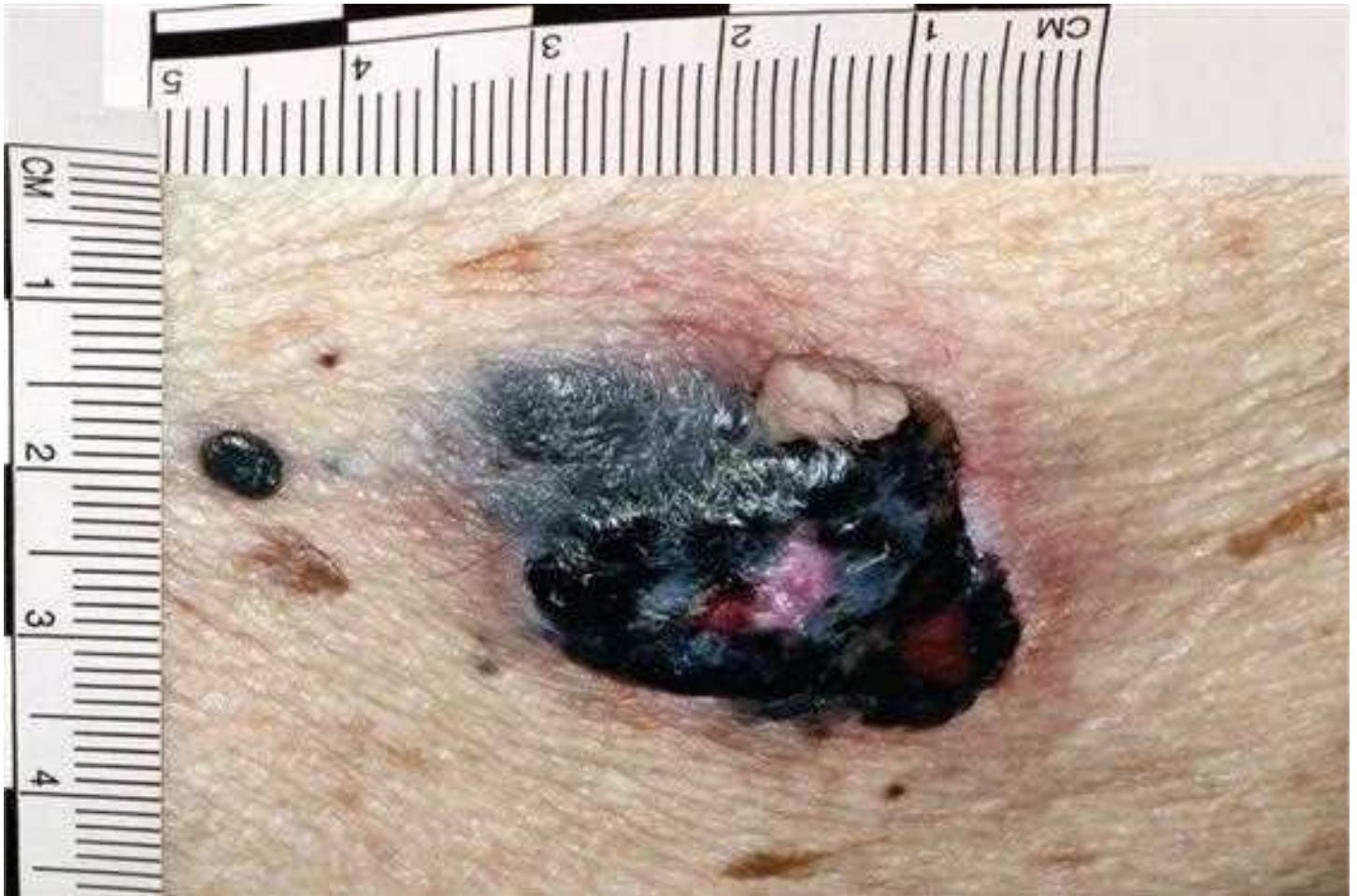

Figure 23.22 Ulcerating melanoma with satellites and in transit metastasis.

Table 23.1 Prognosis in melanoma according to staging.

| Melanoma stage | 5-year survival (%) |
|--|----------------------------|
| Stage 0 melanoma in situ, melanoma cells only in the epidermis, no invasion | 100 |
| Stage 1A melanoma with Breslow thickness ≤ 1 mm without ulceration/lymph node involvement | 95 |
| Stage 1 B melanoma with Breslow thickness ≤ 1 mm with ulceration/no lymph node involvement or 1.01–2 mm Breslow without ulceration/lymph node involvement | 91 |
| Stage 2 A melanoma with Breslow thickness > 1 mm to <2.01 mm without ulceration/metastases or 2.01–4 mm without ulceration/lymph node involvement | 77–79 |
| Stage 2 B melanoma 2.01–4 mm Breslow with ulceration/no lymph nodes or > 4 mm without ulceration/lymph nodes | 63–67 |
| Stage 2 C melanoma >4 mm Breslow with ulceration/no lymph nodes | 45 |
| Stage 3 A Any Breslow without ulceration/with 1–3 lymph node micrometastases | 63–70 |
| Stage 3 B Any Breslow with ulceration and 1–3 lymph node micrometastases or any Breslow without ulceration plus 1–3 lymph node macrometastases | 46–59 |
| Stage 3 C Any Breslow, without ulceration plus 1–3 macrometastases or ≥ 4 metastatic lymph nodes or melanoma satellites | 24–29 |
| Stage 4 melanoma with metastases in the skin, subcutaneous tissue or lymph nodes at distant sites or metastases in visceral organs | 7–19 |

Treatment of melanoma

If melanoma is suspected it should ideally be excised urgently in its entirety with initially just a 2-mm margin for histological analysis. Definitive treatment including wide local excision margins will be guided by the Breslow thickness (determined histologically) as well as any potential risk for lymph node involvement. The higher the Breslow thickness, the more likely that the draining lymph nodes may contain melanoma metastases. If a palpable lymph node is found on examination, then a fine needle aspiration or lymph node removal for cytology/histology respectively should be undertaken. If no lymph nodes are palpable but the Breslow thickness is greater than 1 mm, then the patient may be offered sentinel lymph node biopsy (SLNB) (this is the first draining node from the melanoma skin site), or ultrasound examination of the draining nodes.

Sentinel lymph node biopsy (SLNB)

The presence or absence of nodal metastases is a significant prognostic indicator. SLNB is therefore currently offered in some centres to patients who have a melanoma of greater than

1 mm Breslow thickness. SLNB is usually undertaken simultaneously with the wide local excision. To detect the sentinel nodes lymphoscintigraphy (which maps the lymphatics using technetium-99 m) is carried out, plus methylene blue dye is infiltrated around the excision scar and a gamma probe is used to identify positive nodes. All blue nodes and those with more than 10% radioactivity are identified as sentinel nodes. The sentinel lymph node/s are examined histologically for evidence of melanoma micrometastases. A false negative rate of between 4% and 12% is reported. If the sentinel lymph node is positive for melanoma then local lymph basin clearance and/or adjuvant therapy in a clinical trial is usually offered to the patient. Unfortunately, there is no evidence that undergoing SLNB and lymph basin clearance improves survival, but it is the most accurate currently available staging method.

Adjuvant therapies for melanoma

Patients with stage 4 disease (i.e. where melanoma has spread from its original skin site as satellite lesions in the skin or distant metastases) may be suitable to have adjuvant therapy (if complete surgical resection is not possible). Currently, there are three main types: immunotherapy, targeted therapy, and cytotoxic chemotherapy.

Immunotherapy with checkpoint inhibitors has been a recent advance in the adjuvant treatment of patients with known metastatic disease. Nivolumab, which targets programmed cell death protein 1 (PD-1), is currently the agent of choice following randomised trials which showed it had a better relapse-free survival (RFS) advantage (70% at 12 months) and lower adverse effect profile (14 vs 46%) over ipilimumab (50% RFS at 12 months). These results were irrespective of BRAF mutation status, stage 3 vs 4 disease, PD-1 status, extent of lymph node involvement and if ulceration was present/absent). Nivolumab was approved by the FDA as first-line treatment in this group of patients in December 2017 (either 240 mg every two weeks or 480 mg every four weeks). Ipilimumab is a monoclonal antibody that targets cytotoxic T-lymphocyte-associated protein 4 (CTLA-4).

Some trials look at combination treatment and show better survival rates when Nivolumab was given first and then ipilimumab, rather than either agent being given alone. However, there was also more toxicity in the sequential combination treatment group, which on occasion meant treatment needed to stop.

Targeted therapy currently involves detecting and targeting gene mutations within the patient's melanomas. 50% of melanomas have a single gene mutation in BRAF. BRAF is a human gene that makes a protein called B-Raf which is a cell growth signalling protein. Mutations in the BRAF gene therefore lead to switching on of tumour cell growth, and the melanoma becomes addicted to the actions of B-Raf, the so-called 'oncogene addiction'. These novel targeted therapies such as vemurafenib, dabrafenib, and trametinib block the production of B-Raf protein resulting in tumour shrinkage prolonging survival by an additional six months. However, despite the continuation of therapy the melanomas eventually start to grow again by finding alternative pathways to stimulate tumour growth. Side effects of BRAF inhibitors include photosensitivity, joint pains/fatigue, and an increase in non-melanoma skin cancers (in about 25% of patients on vemurafenib or dabrafenib due to

paradoxical activation of the mitogen activated protein kinase (MEK) pathway) that usually require surgical excision. Trametinib (MEK inhibitor) is also highly active against tumours containing BRAF mutations and are often given in combination with BRAF inhibitors to enhance overall survival rates.

Cytotoxic chemotherapy is now usually reserved as second or third line treatment for metastatic melanoma. High-dose interleukin-2 and interferon alpha treatment may help in some patients who are no longer responding to immune/targeted therapy, however there is no robust evidence showing increased overall survival.

Melanoma vaccines may provide hope for future patients with clinical trials currently underway in patients with stage 4 melanoma. Preliminary results show that by immunising patients with their own functionally mature dendritic cells that have been modified to produce interleukin-12p70 this switches on the production of cytotoxic T-cells which are directed against gp100 tumour antigen. This vaccination process boosts the patient's ability to kill tumour cells in a very specific way. Further larger studies are needed to assess response rates and 5-year survival data.

Cutaneous lymphoma

Cutaneous lymphoma results from abnormal T or B lymphocytes invading the skin.

Cutaneous T-cell lymphomas (CTCLs) are a heterogeneous group of disorders that account for 80% of primary cutaneous lymphomas (B-cell types 20%). The most common form of CTCL is mycosis fungoides (MF), which is more common with increasing age, male sex, and black skin. MF has a relatively good overall prognosis, but some individuals may have more aggressive disease. Clinically, MF may initially resemble eczema, psoriasis, or fungal infections. Patients have scaly erythematous patches and plaques on the skin, particularly on the trunk and buttock area ([Figure 23.23](#)). These may be itchy or asymptomatic. Lesions usually remain fixed and do not respond to mild topical steroids or antifungal creams. These lesions may remain stable for many years but eventually may transform to tumour stage disease when nodules may appear in long-standing plaques or arise de novo.

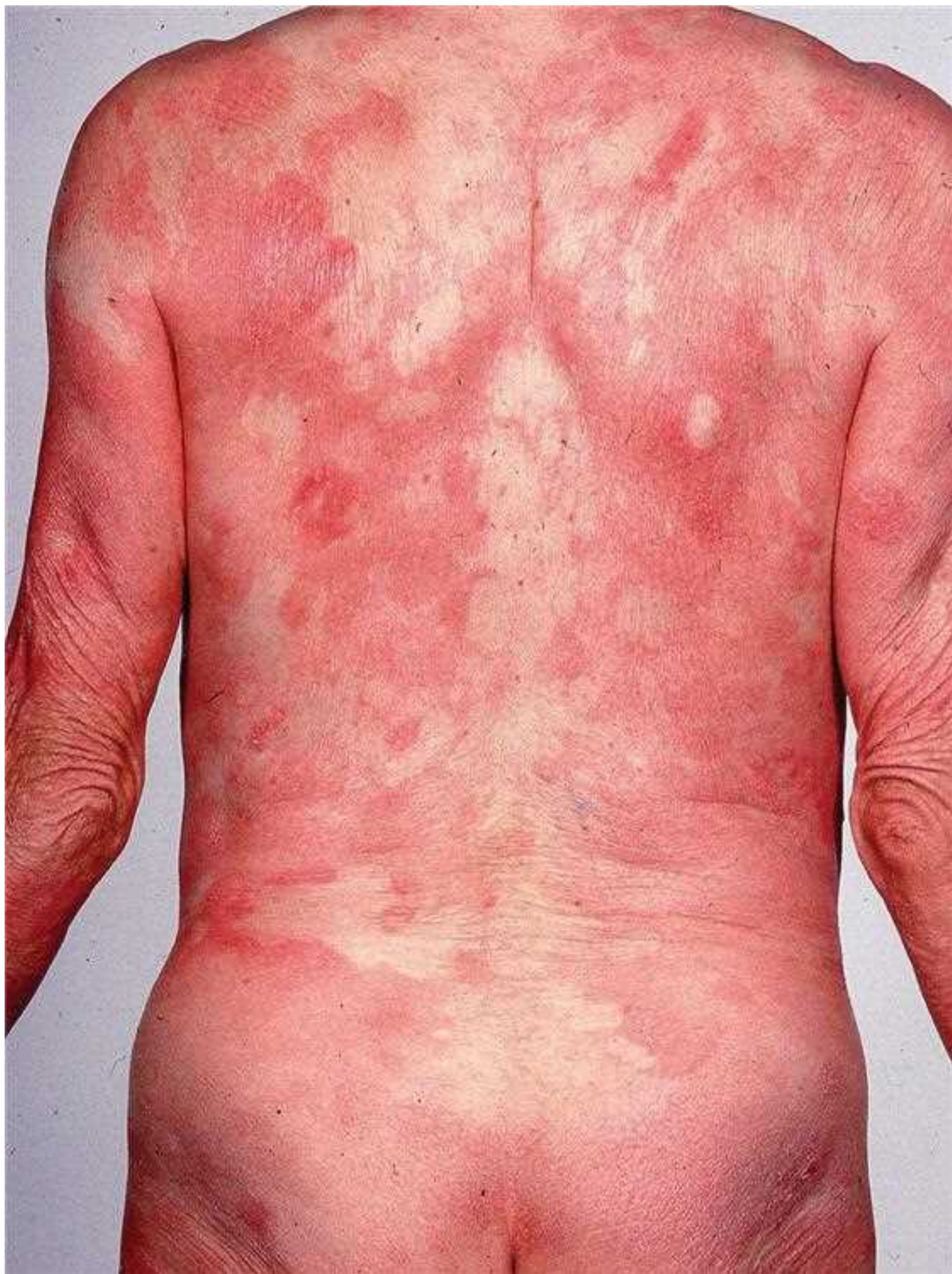

Figure 23.23 Mycosis fungoides.

Five percent of MF patients develop a generalised exfoliative erythroderma with lymphadenopathy and atypical peripheral T-cells (Sézary cells): the so-called Sézary syndrome. This is considered to be a more aggressive form of MF. A clone of malignant T-cells can be demonstrated in the skin, lymph nodes, and blood by T-cell gene rearrangement studies.

Management of early patch stage MF is usually with potent topical steroids, topical nitrogen mustard and phototherapy (psoralen ultraviolet A [PUVA]). Plaque or tumour stage disease may be managed with localised radiotherapy or for more extensive plaques/tumours total skin electron beam therapy.

Results from multiagent chemotherapy regimens have been disappointing. Over the past decade, an oral synthetic rexinoid (a subclass of retinoid that activates retinoid X receptors) bexarotene has been used to treat more advanced CTCL with an overall response rate of 75%. Adverse effects may prohibit optimal dosing in some patients who may develop hypothyroidism, raised triglycerides, abnormal liver function tests, glucose abnormalities, and neutropenia. Brentuximab vedotin (anti CD-30 antibody conjugated to a tubulin disrupting agent) can be effective at treating tumour stage disease. For erythrodermic MF in addition to the above agents alemtuzumab (anti CD52) can be of benefit.

Allogenic stem cell transplantation has been used in small numbers of patients with CTCL no longer responding to conventional therapies. High or conventional dose (non-myeloablative) chemotherapy with/without radiation therapy is given to patients prior to an infusion of donor stem cells. Small cases series report 75% of patients remaining disease free at five years; however, 25% of patients died from complications related to the stem cell transplant.

Primary cutaneous B-cell lymphomas (CBCL) arise from a malignant transformation of B-cells at different stages of their development, leading to different types including follicular, marginal zone, diffuse large B-cell 'other' and diffuse large B-cell on the leg (the latter has a worse prognosis). Clinically, lesions present as firm indurated papules, nodules, or plaques that may be erythematous, violaceous, or brown ([Figure 23.24](#)).

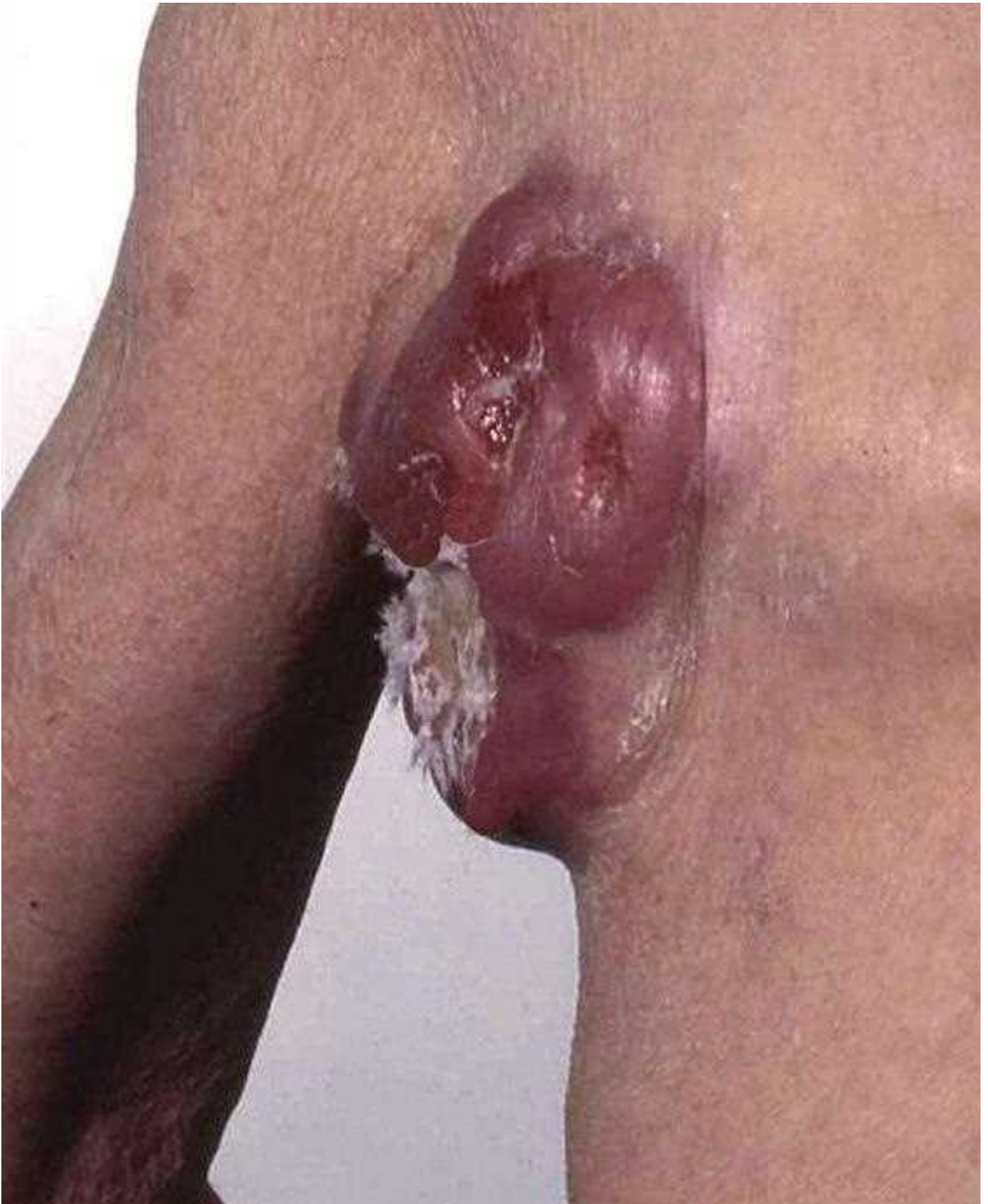

Figure 23.24 Primary cutaneous B-cell lymphoma.

Management of B-cell lymphoma depends on the type but as a general rule, low-grade

solitary lesions can be treated with surgical excision, localised radiotherapy, intralesional interferon alpha or intralesional rituximab. Multiple lesions can be treated with systemic rituximab. High-grade poor-prognosis CBCL may be managed with pegylated liposomal doxorubicin or CHOP chemotherapy (cyclophosphamide, hydroxydaunorubicin, oncovin (vincristine), and prednisolone).

Other cutaneous malignancies

Paget's disease of the nipple presents with unilateral non-specific erythematous changes on the areola/nipple spreading to the surrounding skin. The cause is an underlying adenocarcinoma of the ducts. It should be considered in any patient with eczematous changes in one breast that fail to respond to simple treatment ([Figure 23.25](#)). Extra-mammary Paget's can affect the axillae and groin.

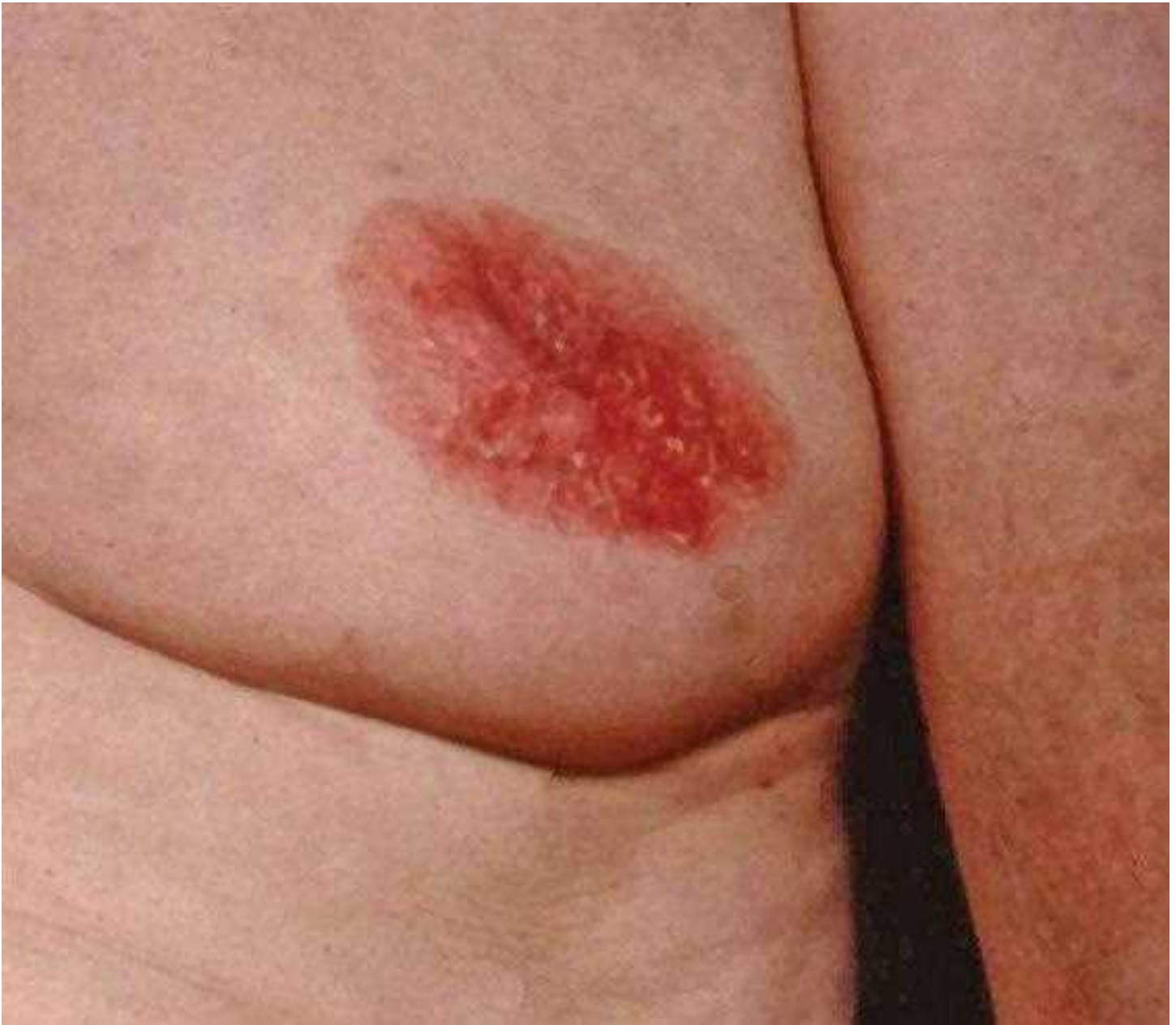

Figure 23.25 Paget's disease of the nipple.

Metastases from internal organs most commonly spread from cancers of the breast, lung, GI tract, renal tract, oral pharynx, larynx, and melanoma (originating from the retina and leptomeninges). Early recognition of cutaneous metastases may allow accurate and rapid diagnosis of internal malignancy and expedite possible curative therapies.

Further reading

Baldi, A., Pasquali, P., and Spugnini, E.P. (2013). *Skin Cancer: A Practical Approach*. Humana Press.

Rigel, D., Robinson, J.K., Ross, M. et al. (2011). *Cancer of the Skin: Expert Consult, 2e*. Saunders.

CHAPTER 24

Practical Procedures and Skin Surgery

Raj Mallipeddi

Dermatological Laser and Surgery Unit, St John's Institute of Dermatology, Guy's and St. Thomas' Hospitals, London, UK

OVERVIEW

- The object of physical treatments is to remove lesions and, if appropriate, to provide material for histological diagnosis.
- Destructive methods of treatment include cryotherapy, electrocautery, and laser treatment. Curettage both destroys the lesion and provides fragmented material for histology.
- Cryotherapy involves the use of extreme cold to destroy the affected tissue. Solid carbon dioxide, nitrous oxide, and ethyl chloride can all be used but liquid nitrogen is the most effective and commonly employed. It produces inflammation and may cause ulceration.
- Electrosurgery is the use of electric current to destroy tissue by heat in two forms: electrocautery using a heated element and electrodesiccation using a high frequency alternating current.
- Curettage is suitable for superficial lesions and is usually combined with electrocautery.
- Specimens for histology can be part of a lesion or the entire sample. Usually only part of the lesion is obtained by incisional, shave and punch biopsies, and therefore, the resulting specimens do not give information on the extent of the lesion as compared to full excisions.
- Surgical excisions require adequate training and knowledge of the management of skin lesions and correct surgical techniques to completely excise lesions while causing the least possible scarring.
- This chapter focuses on the more conventional procedures undertaken in general practice.

Introduction

Cryotherapy involves the destruction of tissues by extreme cold ([Box 24.1](#)). The tissue is frozen to subzero temperatures, which is then followed by sloughing of dead tissue. Several

mechanisms are involved including the osmotic effects of intracellular water leaving the cell and causing dehydration, intracellular ice formation disrupting the cell membrane and ischaemic damage due to freezing of vessels. Liquid nitrogen is most commonly employed, although various freezing agents are available such as solid carbon dioxide, nitrous oxide, and a mixture of dimethyl ether and propane. Unless otherwise stated, the rest of this section relates to liquid nitrogen cryotherapy.

Box 24.1 Cryotherapy – practical points

- Be confident of the diagnosis before treating any lesion with cryotherapy and if in doubt perform a biopsy or refer the patient to a specialist.
- Monitor the freeze time, spray in short bursts to maintain an ice-ball and stop when the desired freeze time is over.
- Warn patients about potential side effects including pain, redness, swelling, and blistering.
- Children do not tolerate cryotherapy well; therefore, consider alternative treatments.

The low temperature of liquid nitrogen (-196°C), ease of storage and relative low cost make it an effective and convenient cryogen. However, its low temperature also results in rapid evaporation and therefore it should be stored carefully in an adequately ventilated area and preferably in a pressurised container.

Application technique

The liquid nitrogen is best applied as a spray using a canister ([Figure 24.1](#)).

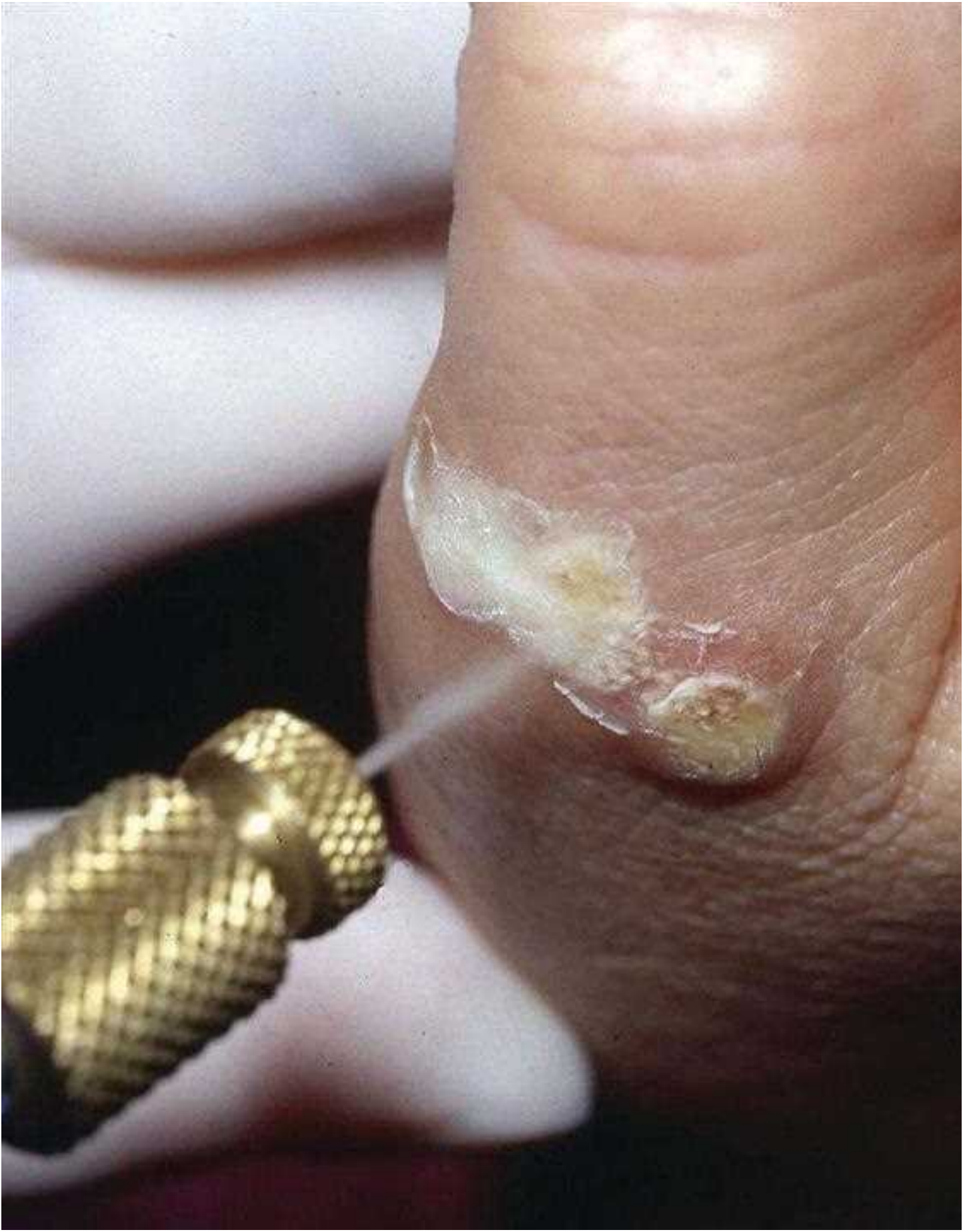

Figure 24.1 Cryotherapy.

An alternative method is to use a cotton bud that is immersed in liquid nitrogen and then applied to the lesion being treated, using moderate pressure until frozen. More than one application may be needed. A fresh cotton bud should be used for each patient to diminish the risk of transferring human papillomavirus. However, with this method there is an increase in temperature partly due to poor thermal capacity of the cotton and also warming when the cotton tip is transferred from the liquid nitrogen container to the patient's skin. The freeze time is important and will vary according to the lesion being treated.

Freeze time is counted from the moment the entire lesion becomes frozen white rather than simply from when spraying begins. Once spraying is complete, the rate of thawing of the tissue is a crucial factor as more tissue destruction occurs with rapid freezing and slow thawing. The 'freeze-thaw' cycle may be repeated to increase the degree of damage and the additional freeze has a greater penetration due to improved cold conductivity of the previously frozen tissue. Freeze times and the number of freeze-thaw cycles depend on the type of lesion (i.e. whether benign or malignant) as well as the size and thickness.

Risks and precautions

- Patients should be warned about reactions which can occur within the first 48 hours after treatment such as pain, redness, swelling, and blistering, so that they are not unduly alarmed. A potent topical steroid cream applied over the affected area for a few days can be used to limit this.
- Ulceration may occur, particularly on the lower limb if there is poor perfusion.
- Although secondary bacterial infection is rare, increased pain, redness or swelling after two to three days may be indicative of this.
- Later risks include scarring and, particularly in darker skin types, hypopigmentation, or hyperpigmentation. As would be expected, these are more of an issue with prolonged treatments.

Skin lesions suitable for freezing

Cryotherapy is usually initiated based on a clinical diagnosis without prior histological confirmation, and therefore, the clinician must be confident of the diagnosis. If there is any diagnostic doubt, consider a biopsy first or alternative treatment modality where histology can also be obtained. The following lesions are frequently treated with cryotherapy.

Viral warts

A single freeze lasting 10–30 seconds per treatment, which includes a 1–2 mm margin of normal skin, is often sufficient, although a double freeze-thaw cycle may improve clearance, particularly for thicker warts. Usually several treatments at two- to three-week intervals are necessary, and cryotherapy may be combined with topical therapies such as salicylic acid

preparations for increased efficacy. Paring down the wart with a blade before cryotherapy can also be helpful.

Seborrhoeic keratoses

A single freeze of between 5 and 20 seconds including a 1- to 2-mm margin of normal skin should be effective for most lesions. A frozen lesion once thawed for a few seconds can also be curetted off. Larger, thicker lesions may require prolonged freezing or repeat freeze–thaw cycles, thereby increasing pain and inflammation. In these circumstances, it may be better to curette and gently cauterise the area.

Papillomas and skin tags

A single freeze of 5–10 seconds may be sufficient, and it is helpful to stabilise the skin tag with metal forceps so that the liquid nitrogen is sprayed obliquely, avoiding non-lesional skin. An alternative method is to treat by compression with artery forceps dipped in liquid nitrogen.

Actinic keratosis

A single freeze of between 5 and 15 seconds including a 1- to 2-mm margin of normal skin is advised. When necessary, lifting away hard keratin to expose the underlying abnormal epithelium makes the freezing more effective. Rarely, a double freeze–thaw cycle may be needed but be aware that a lesion which does not respond to cryotherapy may be a squamous cell carcinoma.

Bowen's disease

This is an intraepidermal (in situ) form of squamous cell carcinoma, which can be effectively treated with a single freeze of up to 30 seconds including a 1- to 2-mm margin of normal skin. Again, a biopsy is necessary should there be any doubt about the diagnosis, and follow-up is essential to make sure the lesion has cleared and is not progressing.

Basal cell carcinoma

If cryotherapy is to be employed, it is best limited to the treatment of the superficial type of basal cell carcinoma (BCC), when lesions are primary (i.e. previously untreated), small (<1 cm in diameter) and well defined. The cure rate for other types of BCC is inferior with cryotherapy than with other forms of treatment such as excision. Two cycles of freezing lasting between 20 and 30 seconds, including a 3-mm rim of clinically normal skin, with a thaw time of 2 minutes is often effective.

Electrosurgery

This term describes the use of electricity to cause thermal tissue destruction. There are two

main forms of treatment: electrocautery and electrodesiccation.

Electrocautery

Heat from an electrically heated element causes thermal damage by direct transfer of heat. Remember that in this situation, the treating element is hot.

Electrodesiccation (diathermy or hyfrecation)

High frequency alternating current energy is converted to heat because of tissue resistance. The treatment electrode is cold as heat generation occurs within the tissue. Electrode contact with skin causes superficial tissue dehydration. A variation of electrodesiccation is electrofulguration in which the electrode is held 1–2 mm from the skin surface to cause superficial epidermal carbonisation. Furthermore, depending on the voltage of current used and electromagnetic waveform, the degree of tissue cutting (electro-section) and coagulation (electrocoagulation) can be modified. If only one treatment electrode is present, then alternating current variably enters and exits the tissue, with electrons being randomly dissipated into the environment, and this is known as a *monopolar* procedure. However, if there is also a second indifferent electrode that completes an electrical circuit, the procedure is termed *bipolar*. With alternating current, the treatment electrodes are not truly positive or negative poles, and the terms *mono-* and *biterminal* are more accurate.

In routine dermatology, electrocautery or electrodesiccation can be used as the sole treatment for vascular lesions such as spider naevi and telangiectasia, although a vascular laser may produce better results with a lower risk of scarring. However, it is more commonly used for haemostasis during skin surgery ([Figure 24.2](#)) or in combination with curettage (see below).

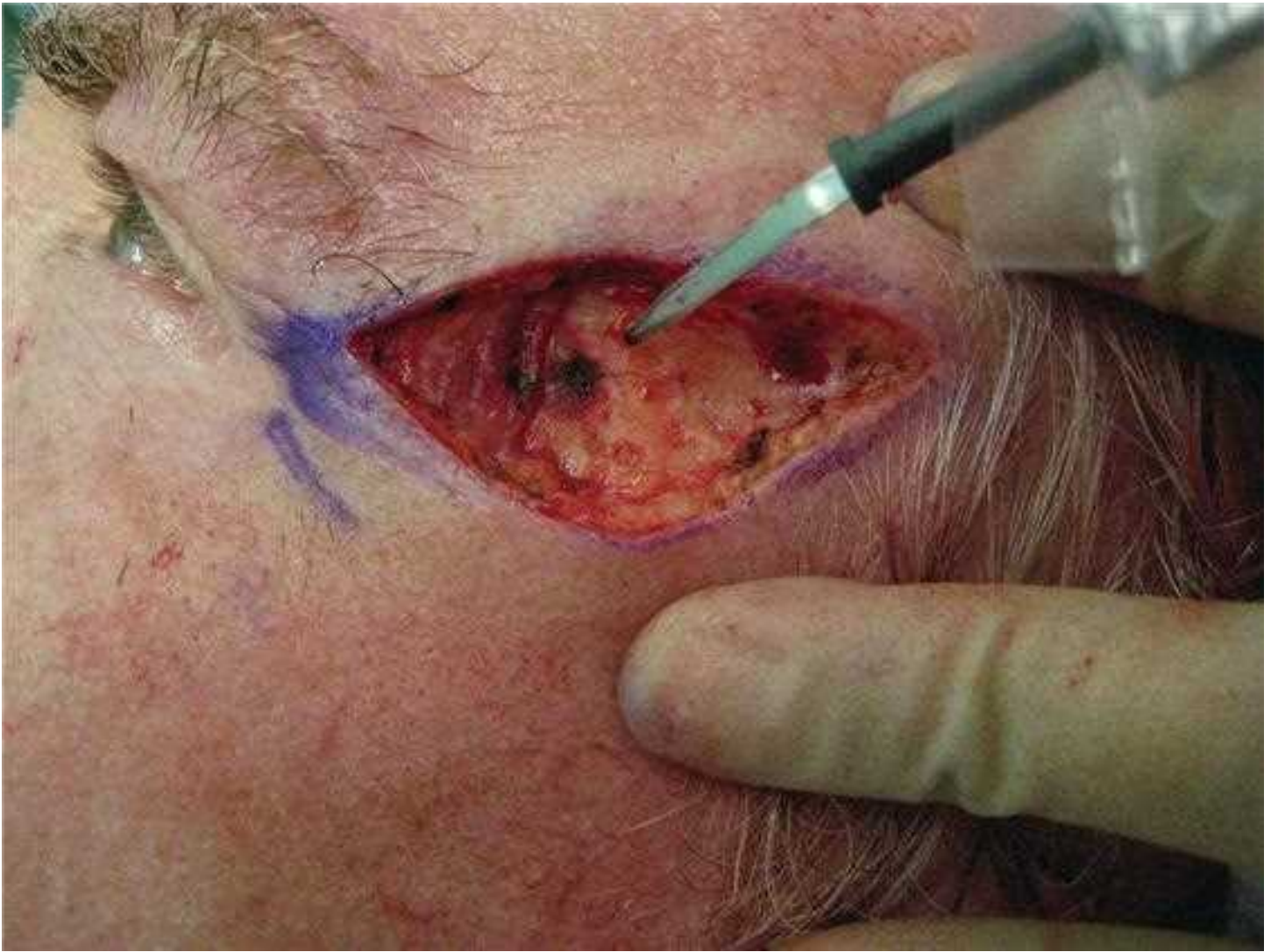
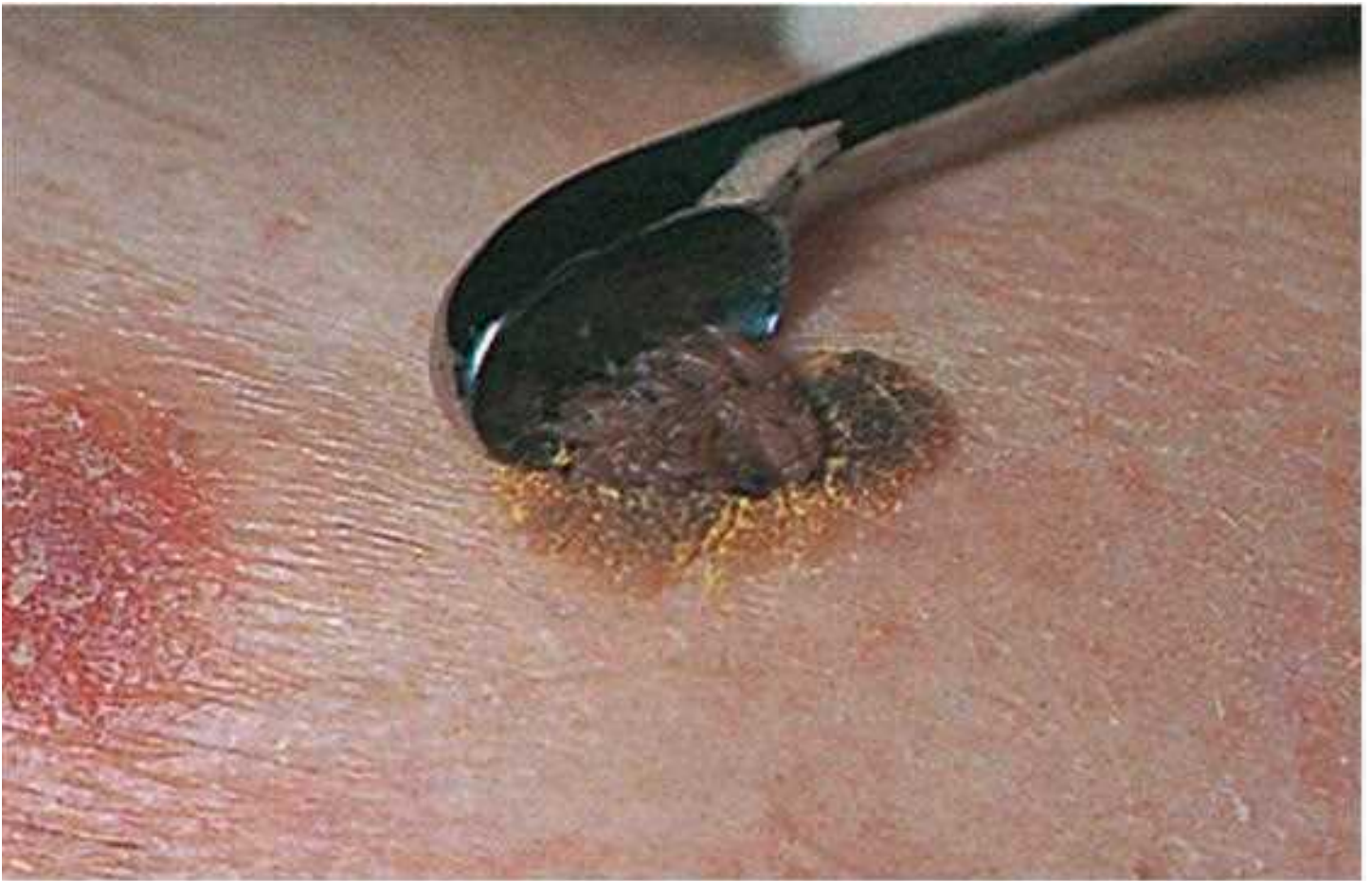

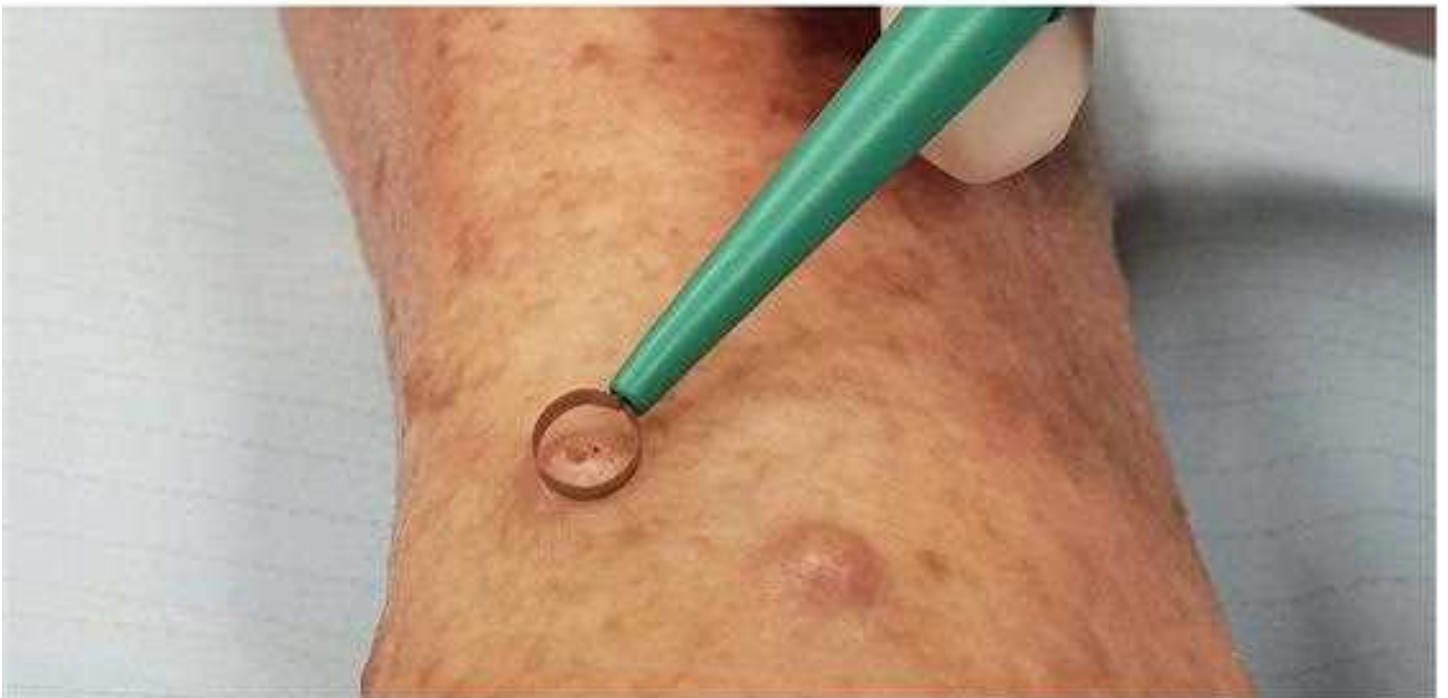Figure 24.2 Electrodesiccation during surgery.

Curettage

This is a simple method of removing superficial lesions, particularly in areas with thick underlying dermis such as the trunk and extremities ([Box 24.2](#)). A metal spoon or ring with a sharp edge is used to scrape away the lesion ([Figure 24.3a,b](#)). The advantage over cryotherapy is that a sample can be sent for histology, although completeness of removal cannot be accurately assessed. Curettage is combined with electrodesiccation or electrocautery to treat benign lesions such as seborrhoeic keratoses and xanthelasma as well as dysplastic lesions (actinic keratoses and Bowen's disease) and BCC. For curettage to work well, the lesion ideally should be softer than the surrounding unaffected skin.



(a)



(b)

Figure 24.3 (a) Spoon curettage. (b) Ring curettage.

Box 24.2 Curettage – practical points

- Use a curette which is of appropriate size for the lesion.
- Stretch the skin with the non-dominant hand and keep firm control of the curette to avoid unintended scraping of normal skin.
- Send the sample for histology but clearly state on the request that it is a curetted specimen.
- Consider shaving off the specimen first to provide a solid sample for diagnosis before commencing curettage and electrocautery. Pathologists prefer this to curetted fragments.

Lesions suitable for curetting include

- seborrhoeic keratoses
- solitary viral warts
- actinic keratoses and Bowen's disease
- cutaneous horns
- small BCCs.

Technique

The area under and around the lesion is injected with a local anaesthetic. Next, using the thumb and index finger of the non-dominant hand ensure that the skin around the lesion is taut, so that there is a firm base on which to curette. Curette off the lesion and then cauterise the base to achieve haemostasis as well as to destroy any remaining tumour. Avoid curetting normal skin. For BCCs, the process is repeated so that a total of two or three cycles of curettage and electrocautery/electrodessication is performed.

Risks and precautions

- Patients should be warned that the wound may take three to four weeks to heal and that although the resultant scar will hopefully be a flat, white patch, it could ultimately become indented (atrophic) or even be pink and raised (hypertrophic), especially with more aggressive treatment causing a deep wound.
- Ulceration may occur, particularly on the lower limb if there is poor perfusion.
- The types of BCCs best treated with this method are primary, nodular, small (<1 cm diameter), well defined and in non-high risk or cosmetically sensitive sites. Sites generally to be avoided include the area around the eyes, nose, lips, chin, ears, and hair-

bearing scalp.

- If curettage results in exposure of subcutaneous fat, then the procedure should be abandoned, and the area excised down to fat and usually sutured. This is because firstly it is not possible to distinguish accurately between soft tumour and fat, and secondly the outcome will be suboptimal in terms of wound healing and scarring, once the fat layer has been breached.

Diagnostic biopsies

Although in many circumstances a diagnosis can be confidently made on clinical examination alone, often it is important to secure a diagnosis with the aid of histopathology. For example, a melanocytic naevus may be proved on histology to be completely benign or, by complete contrast, a malignant melanoma. There are different methods of performing a diagnostic biopsy, each with its own advantages and disadvantages. The area to be biopsied must be adequately infiltrated with local anaesthesia before commencing the procedure.

Shave biopsy

This is appropriate for sampling or removing lesions which are limited to the epidermis and papillary dermis including seborrhoeic keratoses, nodular BCCs, and naevi. The skin is held taut and the lesion is gently sliced with either a scalpel blade or double-edged razor blade held horizontal to the skin surface. The angle of the blade controls the depth, but the aim should be to reach the mid-dermis. Haemostasis can be achieved with electrosurgery or aluminium chloride but firm pressure may suffice. One advantage of this technique is that sutures are unnecessary. However, this technique is not recommended for any suspicious naevus, which should be excised entirely.

Punch biopsy

The biopsy tool comes in sizes varying from 2 to 8 mm ([Figure 24.4](#)) and consists of a small cylinder with a cutting rim which is used to penetrate the epidermis by rotation between the operator's finger and thumb. The skin is held taut at 90° to the orientation of the relaxed skin tension lines ('wrinkle lines') so that an oval defect results, which is easier to close ([Figures 24.5–24.9](#)). The resulting plug of skin is lifted out with forceps and cut off as deeply as possible. Pressure and/or electrosurgery is required for haemostasis. The advantage over a shave biopsy is that the specimen obtained is of full thickness containing epidermis, dermis, and fat, but the area sampled is smaller. The punch biopsy tool can also be used to make holes over cysts and lipomas through which the contents can be extruded. Usually the defect left by the punch is sutured, although for smaller sizes (2 or 3 mm) secondary intention healing might be considered depending on the site.



Figure 24.4 Punch biopsy tools.

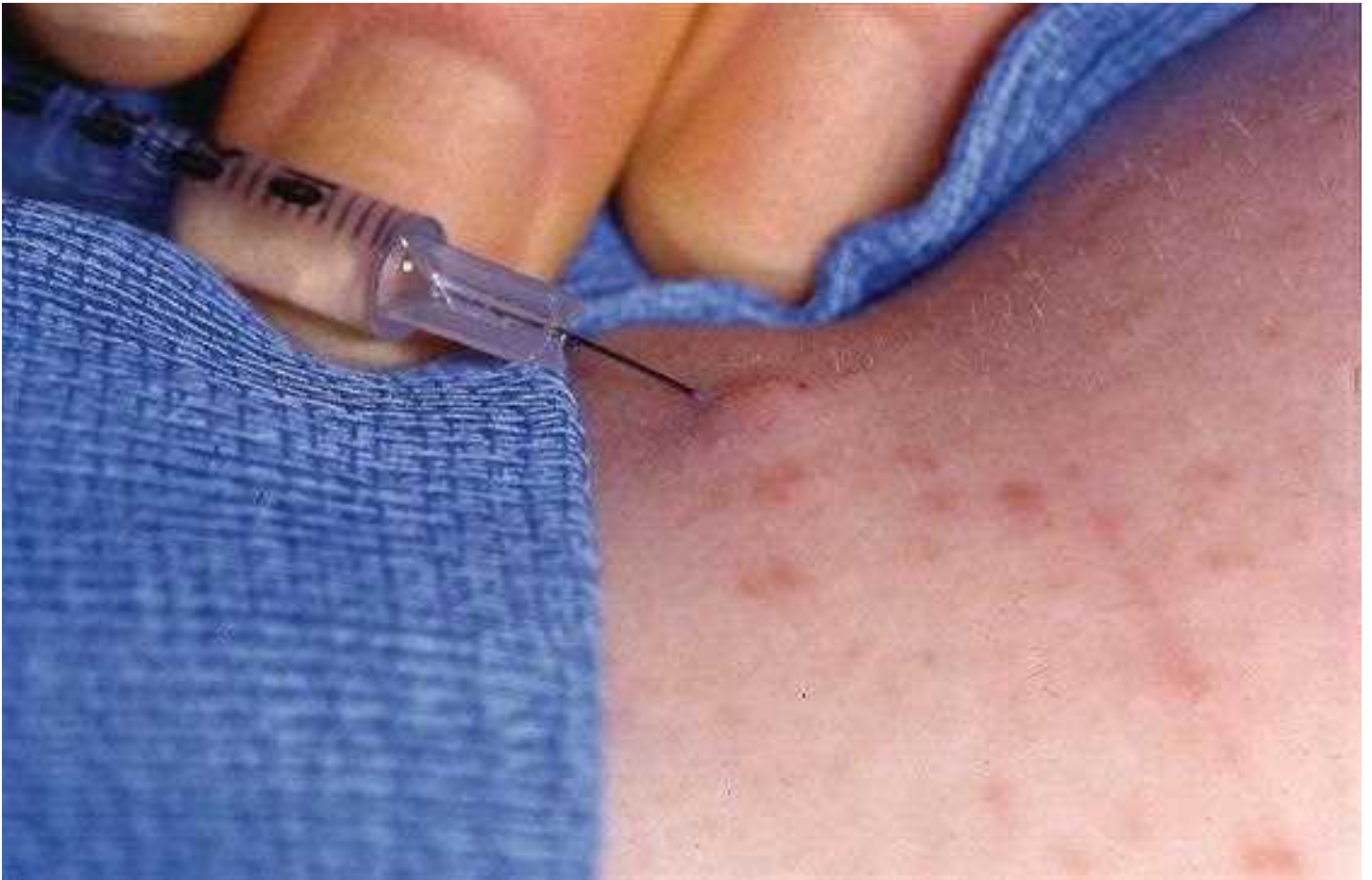

Figure 24.5 Punch biopsy: injecting local anaesthetic.

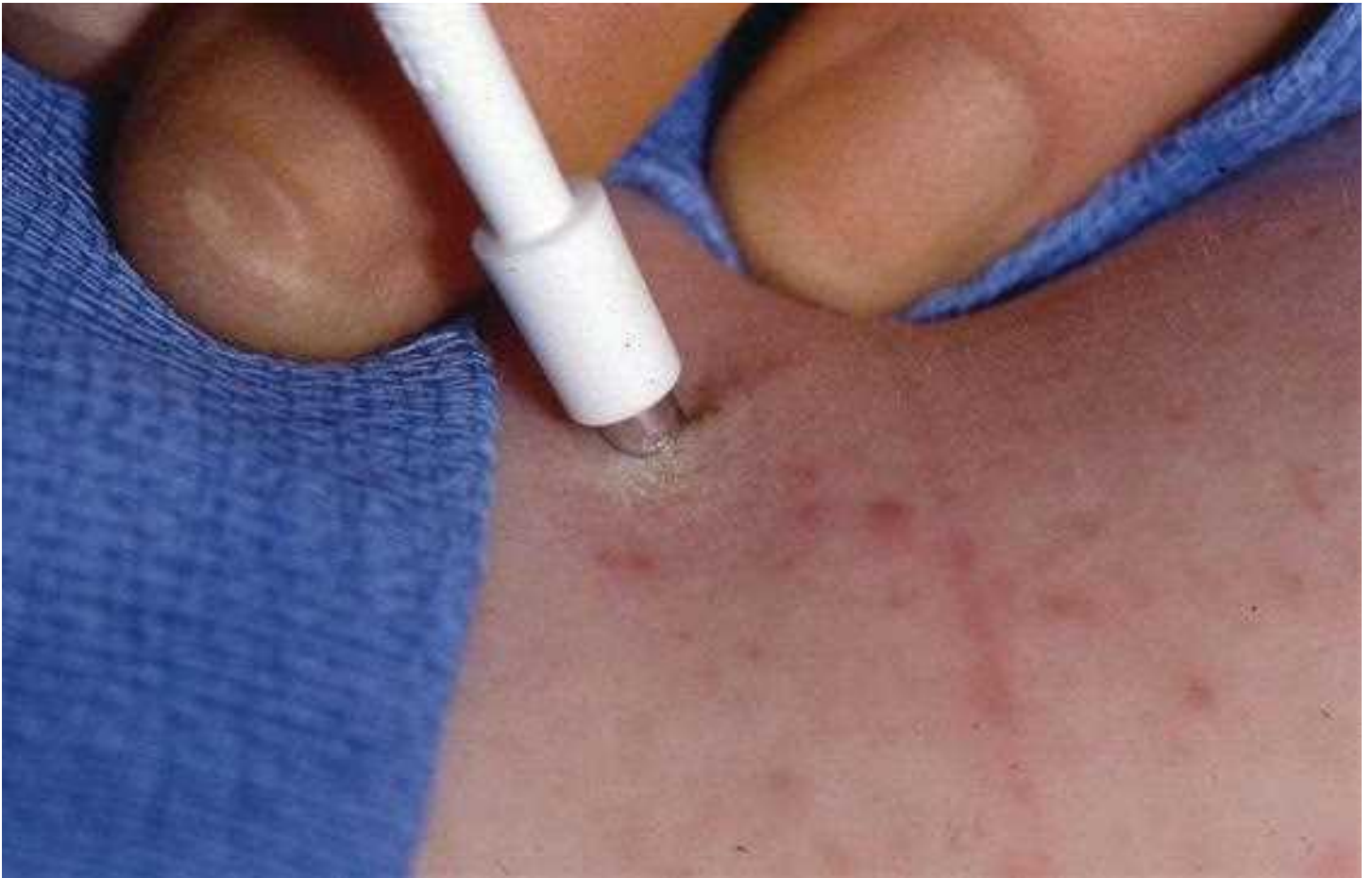

Figure 24.06 Punch biopsy: tool insertion.

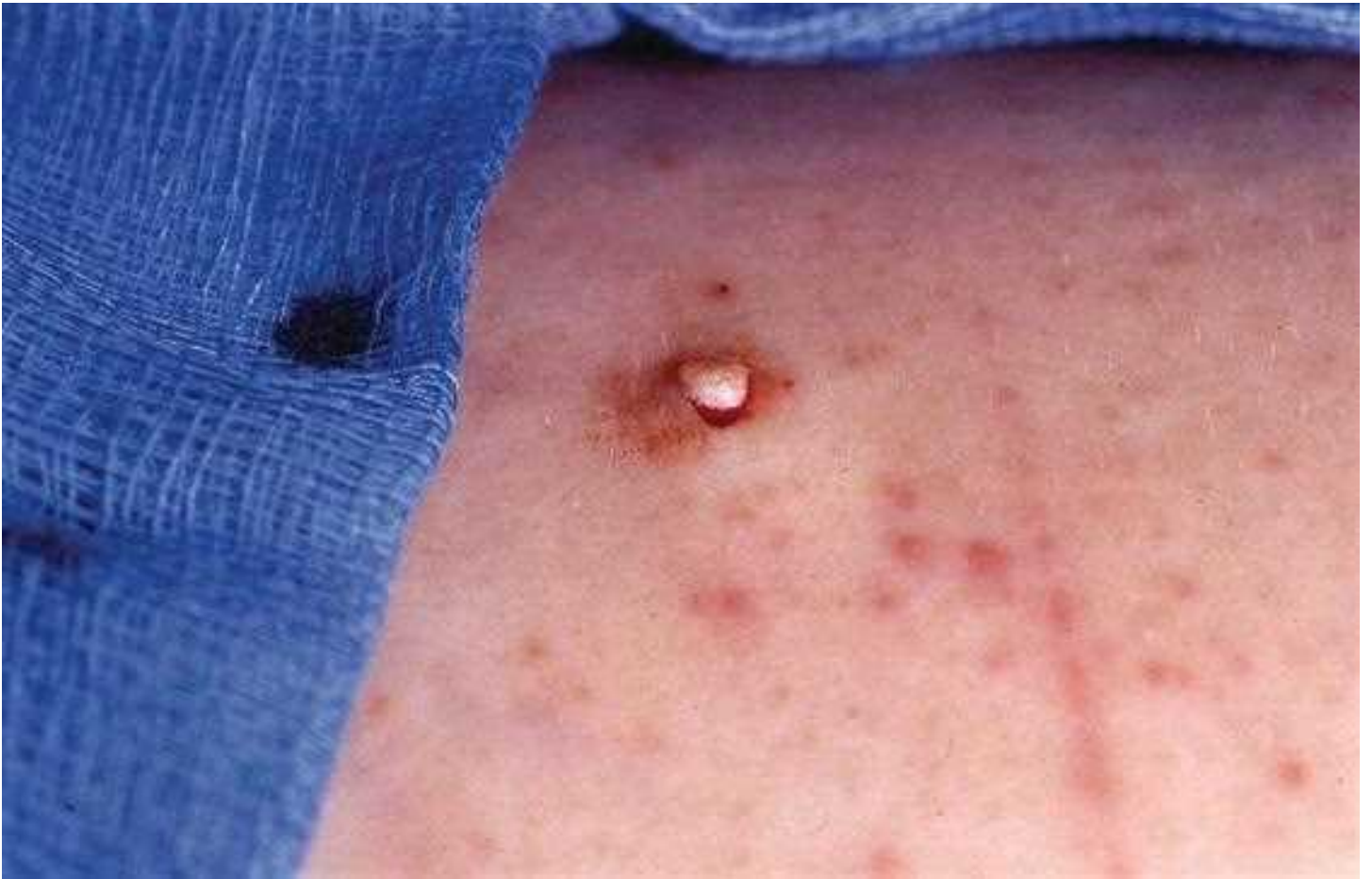

Figure 24.07 Punch biopsy: plug of skin.

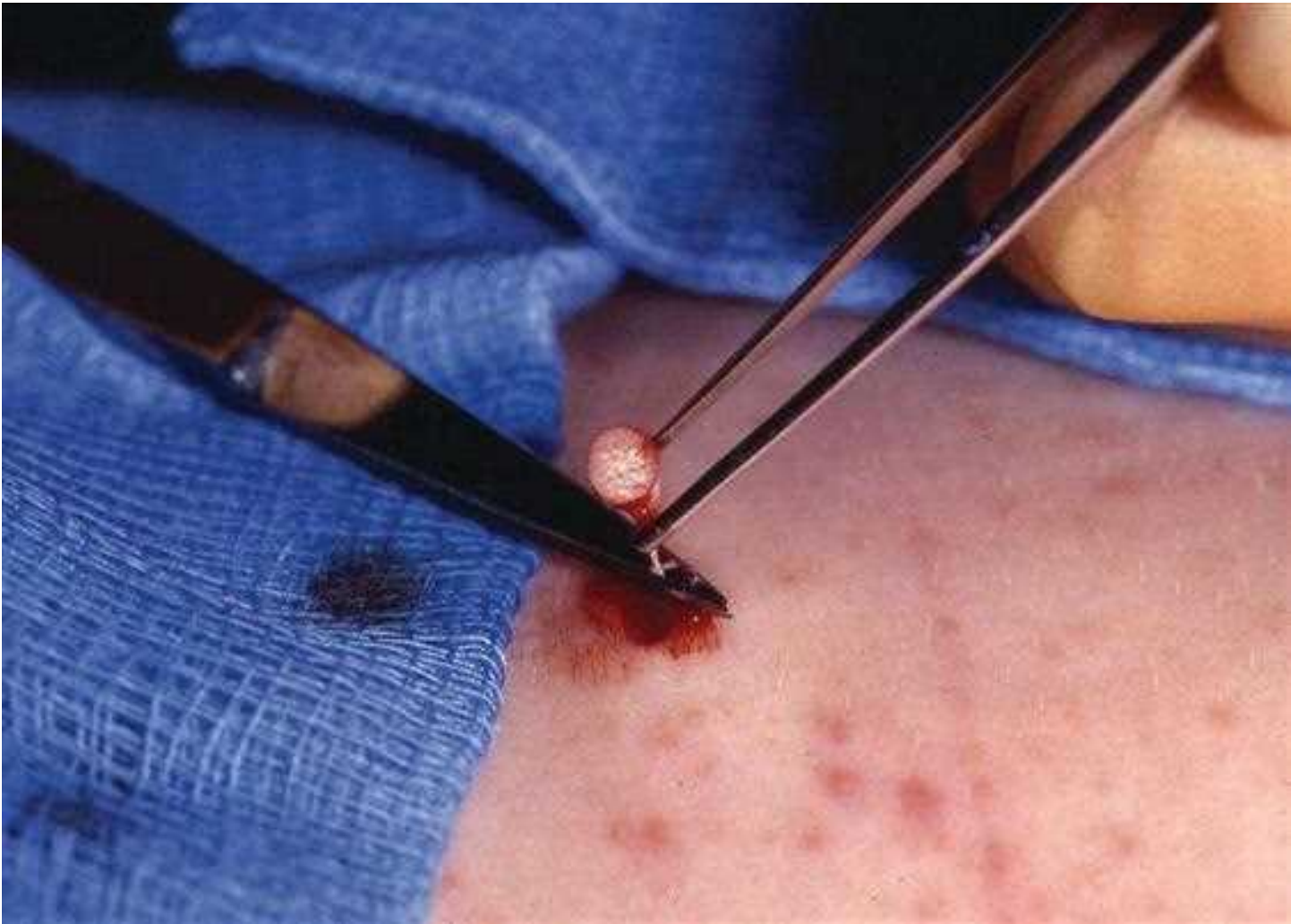

Figure 24.08 Punch biopsy: raising a plug of skin.

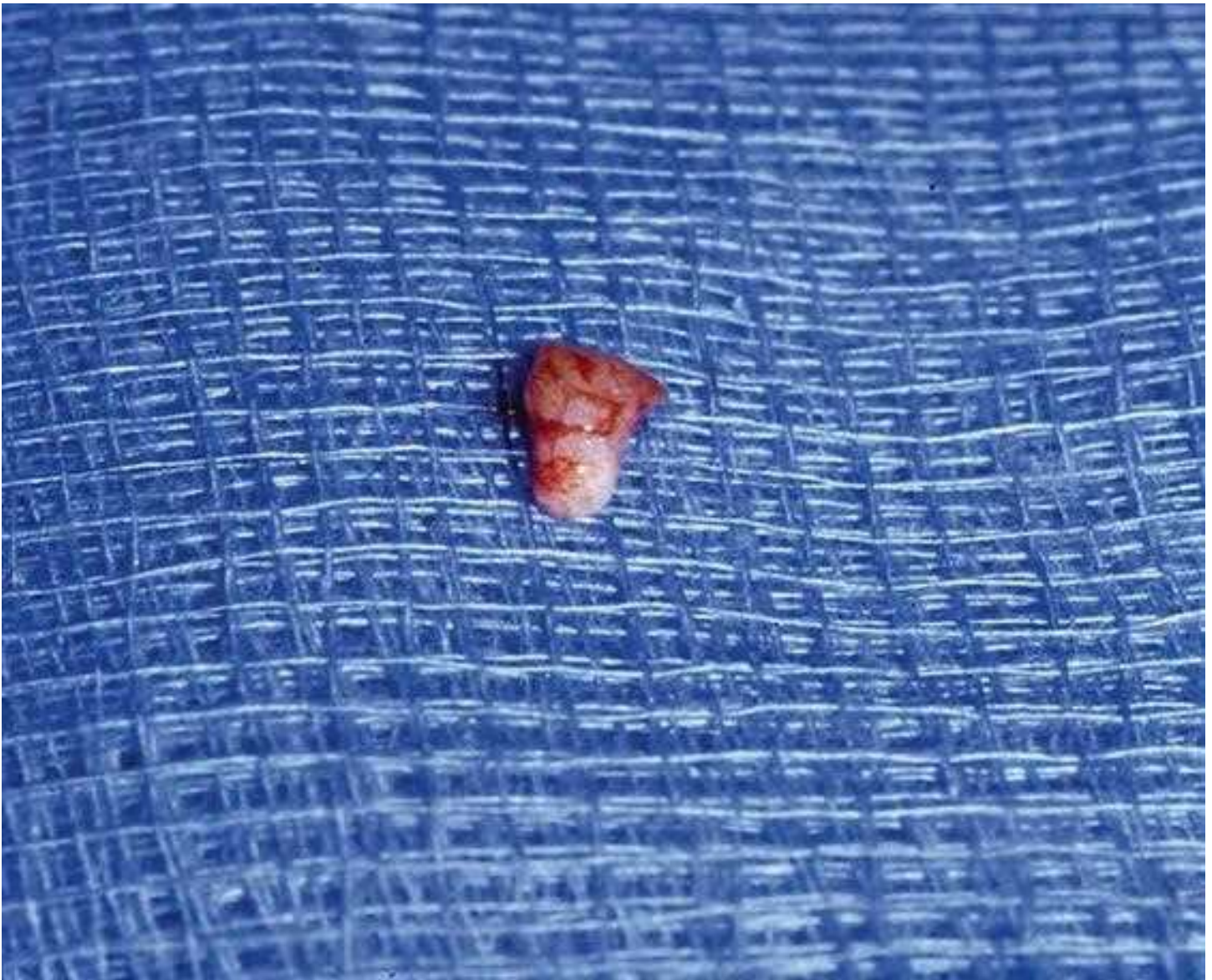

Figure 24.9 Punch biopsy: specimen taken.

Incisional biopsy

This is suitable for larger lesions and is taken across the margin of the lesion in the form of an ellipse. It is essential to include deeper dermis in certain conditions; for example, granuloma, or lymphoid infiltrate may not be near the surface. An adequate amount of normal tissue should be included, so that this can be compared with the pathological area and this also means there is enough normal skin to suture the incision together ([Figure 24.10](#)).

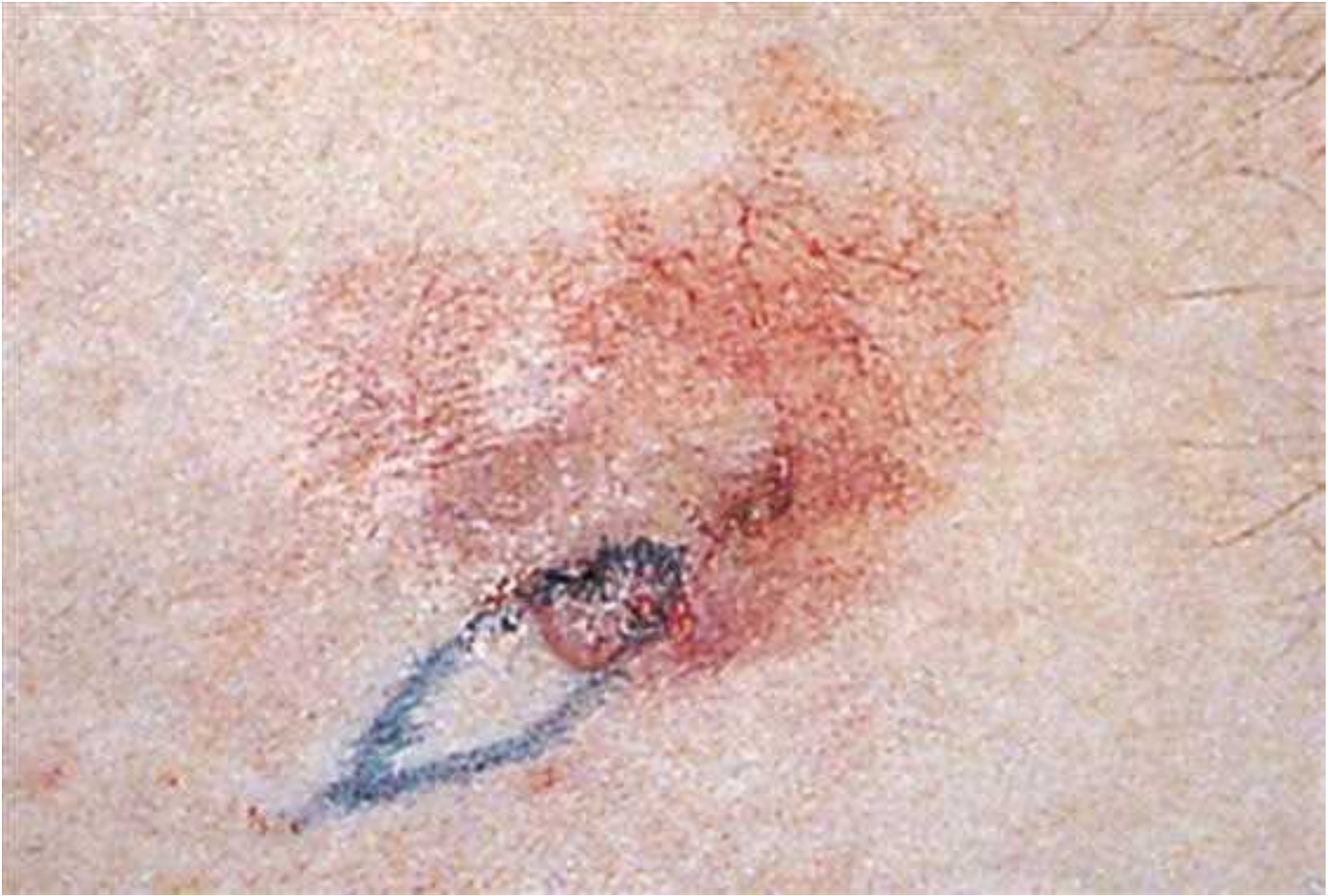

Figure 24.10 Incisional biopsy: marked area for sampling.

Surgical excision

Excision of skin lesions is both curative and diagnostic. It may be the best way of making a diagnosis if there are multiple small papules or vesicles, one of which can be excised intact. Incisions should follow tension or wrinkle lines ([Figures 24.11–24.13](#)).

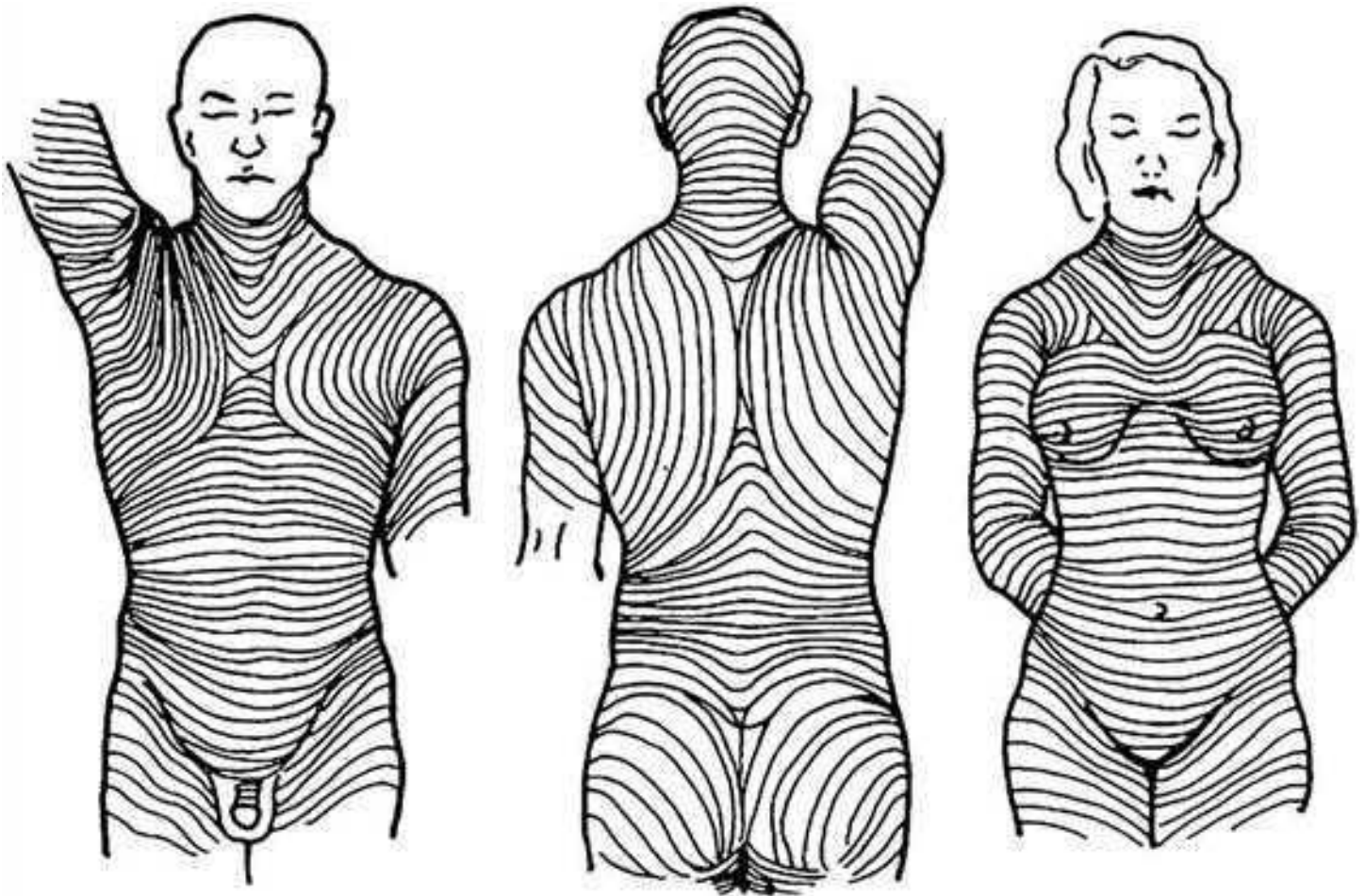


Figure 24.11 Surgical excision: 'skin wrinkle lines' of the trunk.

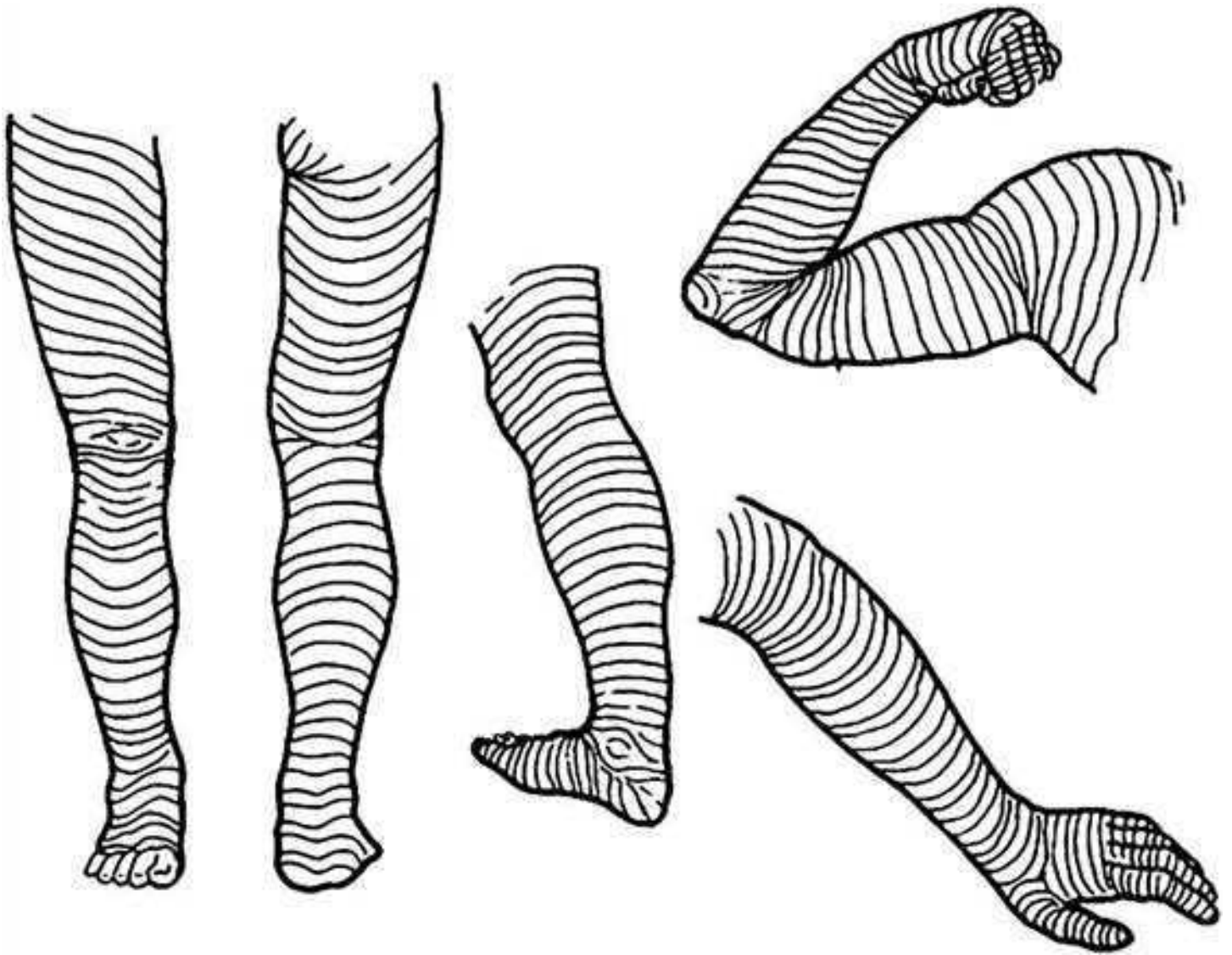

Figure 24.12 Surgical excision: 'skin wrinkle lines' of the limbs.

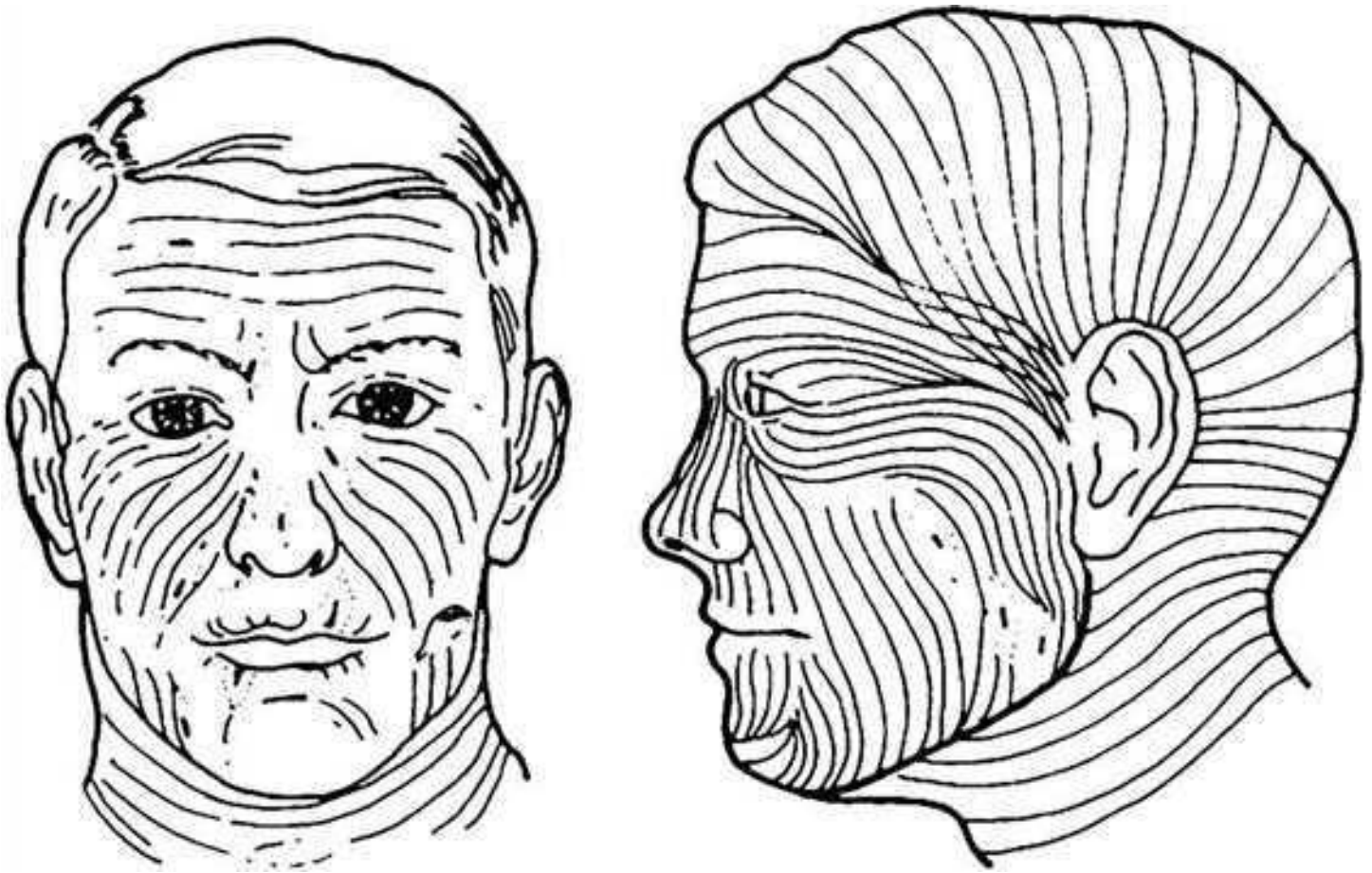


Figure 24.13 Surgical excision: ‘skin wrinkle lines’ of the face.

In the case of malignant lesions, it is particularly important that the whole lesion is adequately excised. The pathologist can report on the adequacy of excision, but this is hard to assess in lesions such as multifocal BCC where there are scattered collections of cells. If there is likely to be any doubt about the excision being complete, it is helpful to attach a suture to one end of the excised specimen so that the pathologist can describe which border, if any, extends over the excision margin.

Technique

The basic technique consists of making an elliptical incision ([Figures 24.14–24.16](#)) with the length three times the width and the angles at the poles about 30° to minimise the formation of standing cones of tissue, also known as *dog ears*. The long axis of the excision should be parallel to the ‘wrinkle lines’ of the skin or to the Langer lines. Although on most parts of the body these correspond closely, they are not exactly the same, as Langer lines correspond to the alignment of collagen fibres within the dermis. Scars parallel to these tend to heal better and be less obvious. Lesions excised on the sternal area, upper chest, and shoulders are more likely to result in keloid scar formation and may be best referred to a dermatological or plastic surgeon.

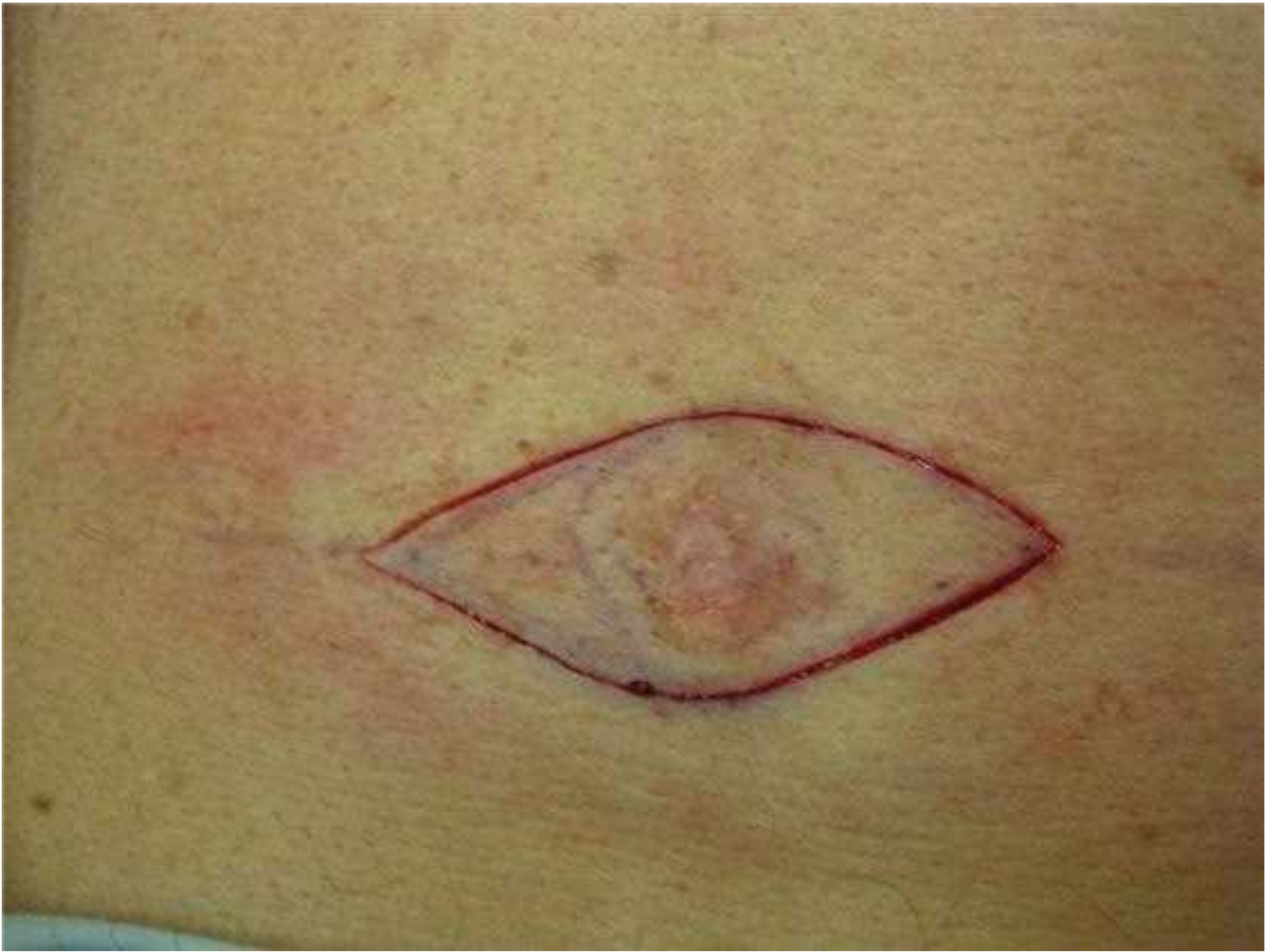

Figure 24.14 Surgical excision of BCC from lower back. Ellipse design including a 4-mm margin.

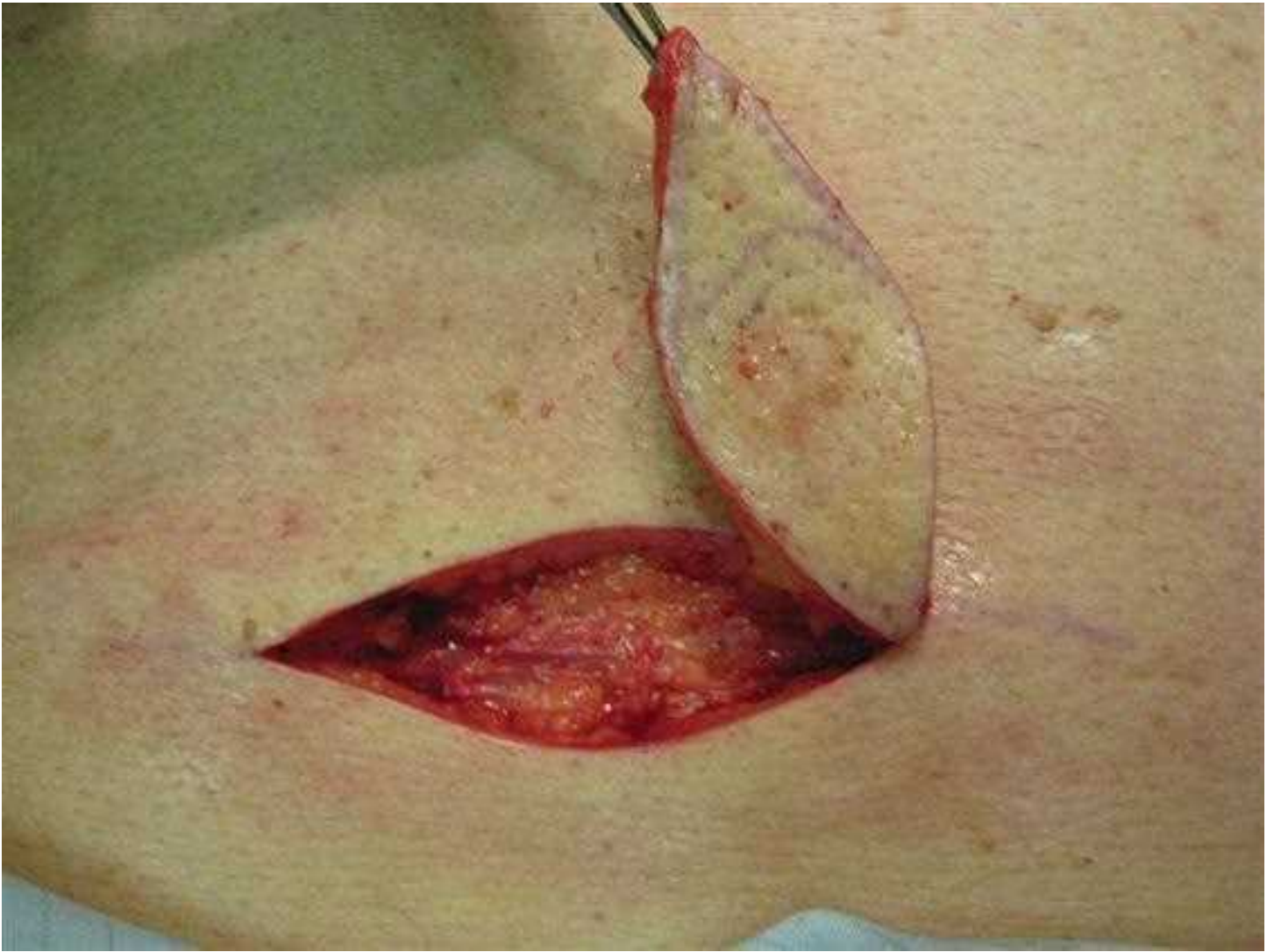

Figure 24.15 Surgical excision of BCC: removal of specimen illustrating the defect.

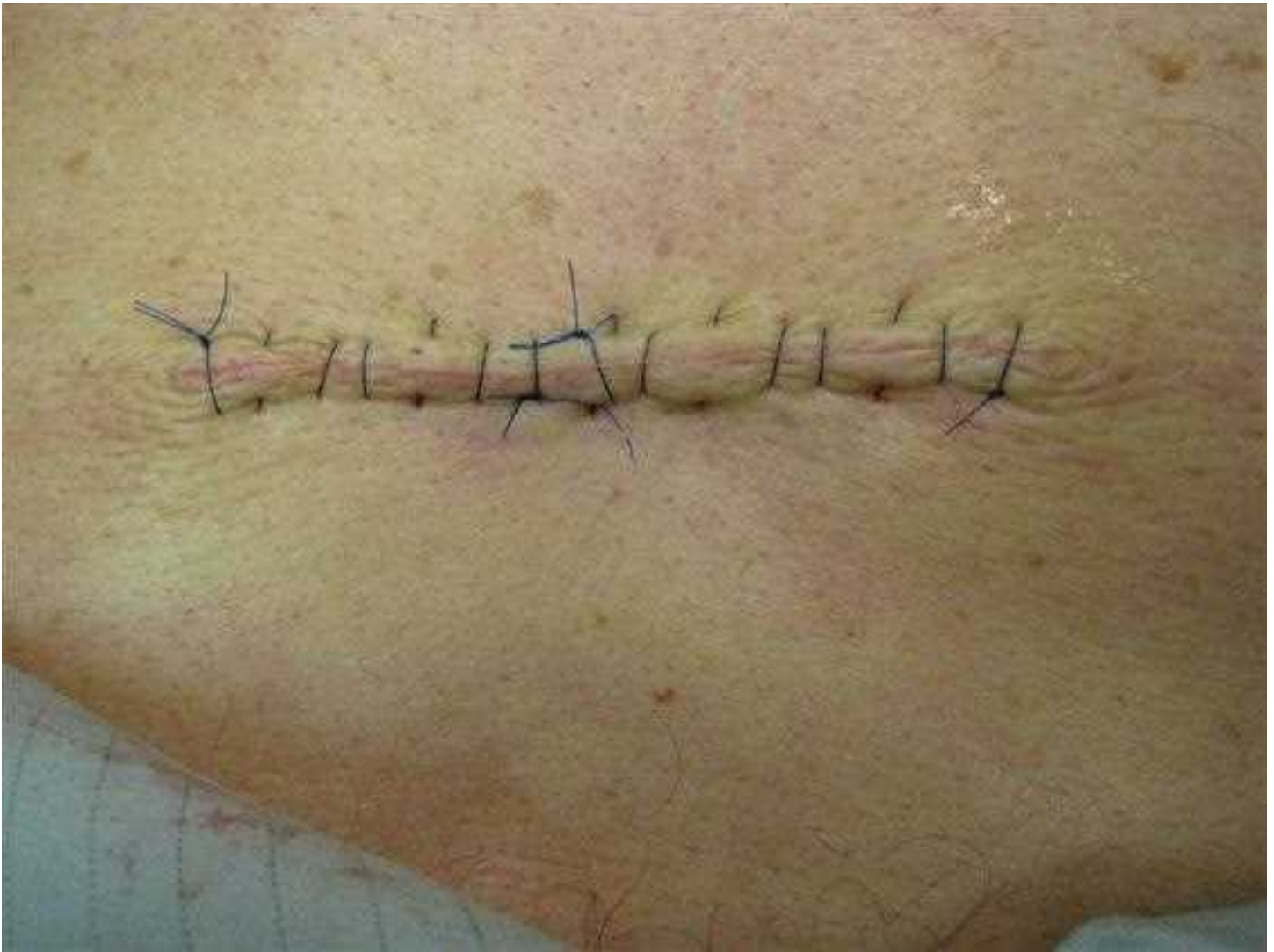

Figure 24.16 Surgical excision of BCC: after suturing, showing wound eversion.

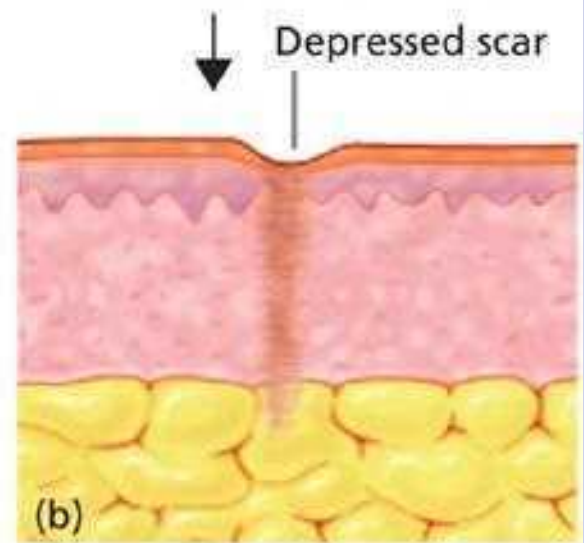
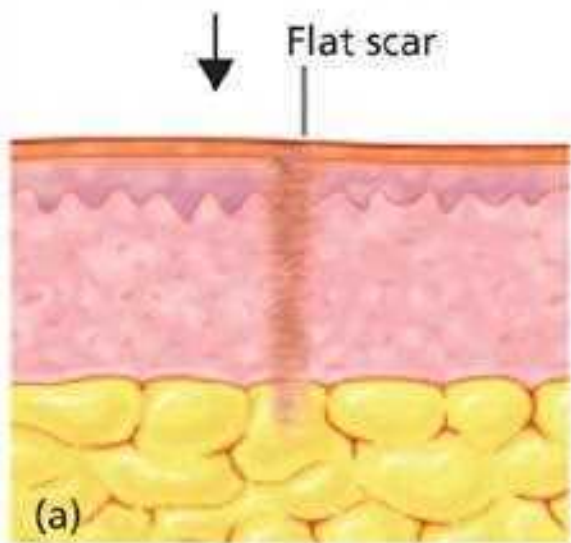
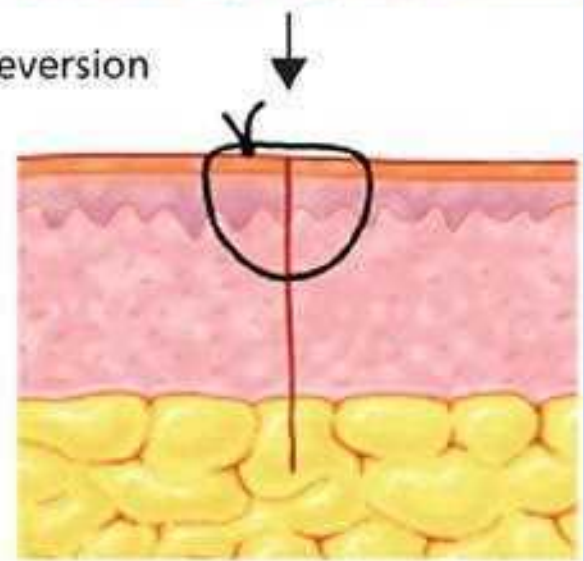
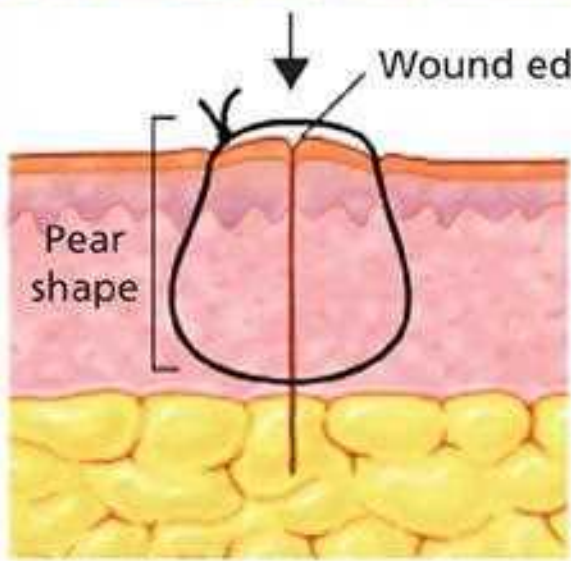
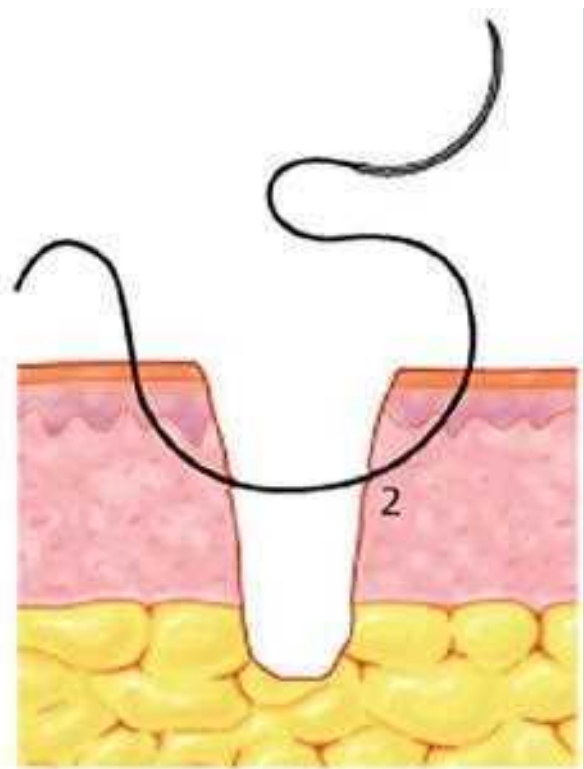
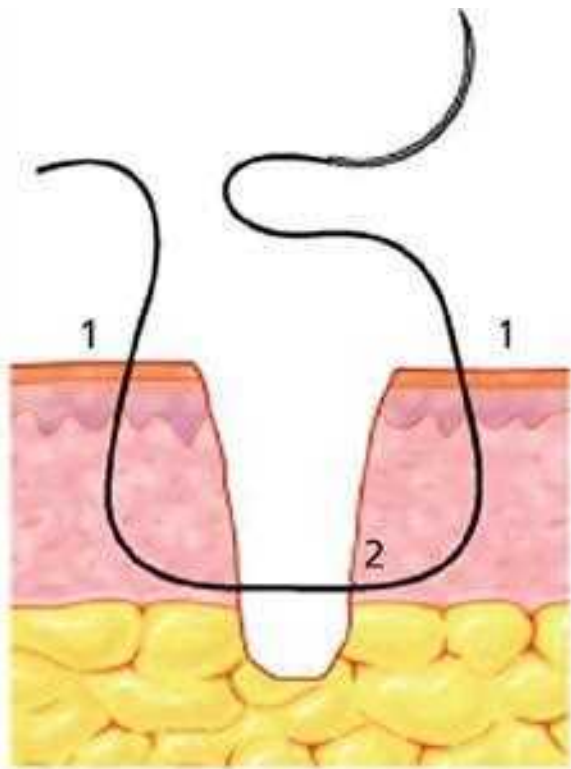
Box 24.3 Surgical excision

- After initially inserting the needle, withdraw the plunger of the syringe to check that the needle has not entered the blood vessels. Raising a small 'bleb' of local anaesthetic ahead of the needle point helps to prevent this.
- It is important to learn appropriate suturing techniques for different sites of the body and size of lesion.
- Warn the patient about the resultant scar and be careful to avoid deformities such as displacement of the eyelid (ectropion).
- Always send an excised lesion for histology as a considerable number of lesions considered likely to be benign clinically actually turn out to be malignant on histology.

Local anaesthetic is injected subcutaneously but close to the skin. The incision should be vertical rather than wedge shaped. Before suturing ([Box 24.4](#)) of the wound, undermining is often required to reduce wound tension. This involves dissection of the skin subdermally (blunt and/or sharp), although the depth will depend on the body site.

[Box 24.4](#) Suturing

- Correct suture placement is vital to optimise the cosmetic outcome of a wound ([Figures 24.17](#) and [24.18](#)).



(a)

(b)

Figure 24.17 Placement of epidermal sutures.

Source: Robinson et al. 2005. Reprinted with permission of Elsevier.

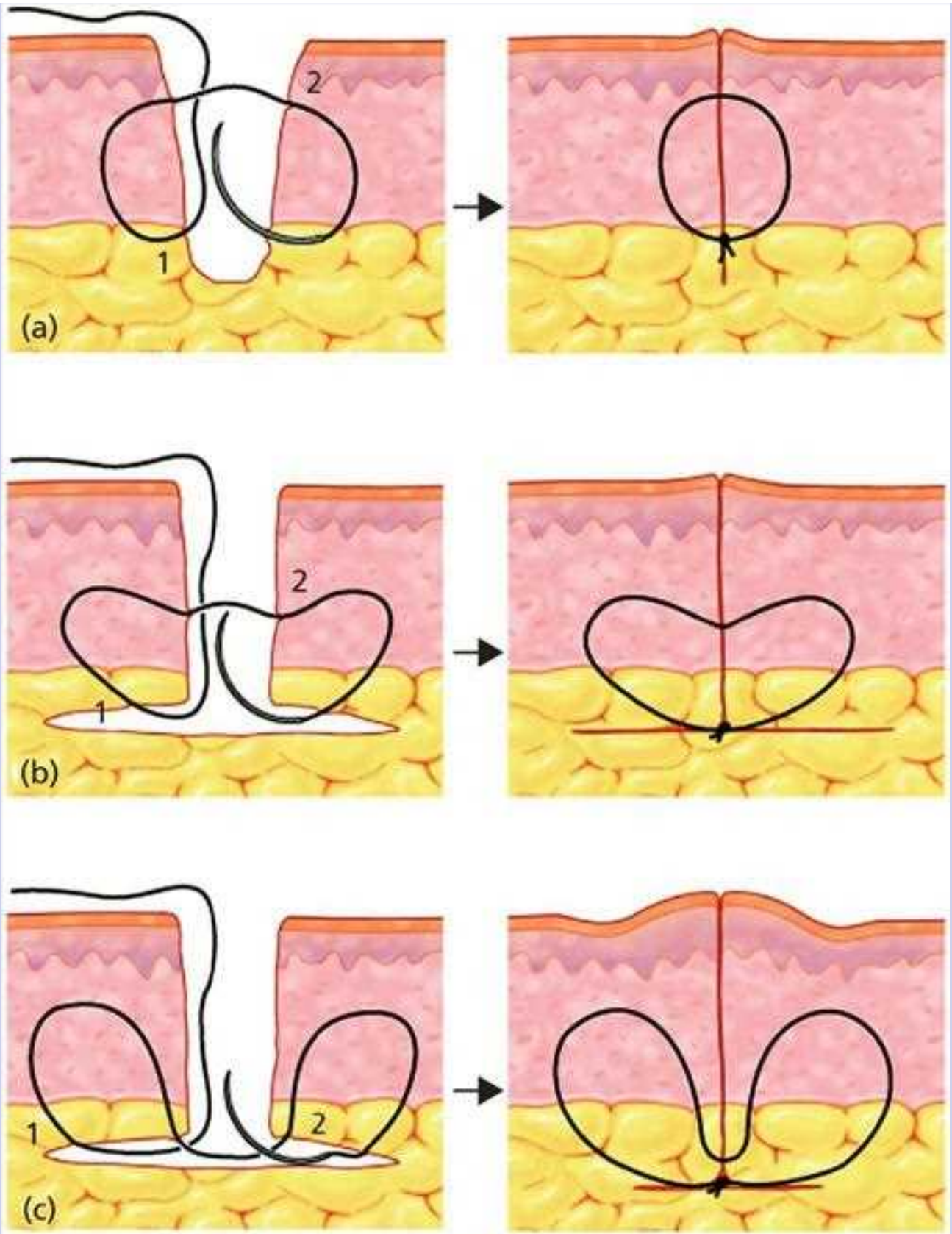


Figure 24.18 Methods of placing buried dermal sutures.

Source: Robinson et al. 2005. Reprinted with permission of Elsevier.

- Following an excision both subcutaneous sutures and epidermal sutures are placed.

- Subcutaneous sutures are absorbable such as Vicryl (Polyglactin 910, Ethicon Inc., Somerville, NJ, USA), which take up to 70 days for complete absorption whereas typical epidermal sutures such as nylon and polypropylene are non-absorbable and are removed between five days and two weeks depending on the site.
- Monofilament sutures cause less inflammation and trapping of serum than the braided variety but are harder to tie securely.
- Suture placement should result in wound eversion so that the resultant scar is less noticeable.

Where a wound cannot be closed directly (i.e. from side to side) or if direct closure does not produce the best aesthetic outcome then a cutaneous flap or skin graft may be appropriate. Flaps may be advancement, rotation, or transposition. Grafts are defined as full thickness if the entire epidermis and dermis is included, and split thickness if less than the entire dermis is included. These are outside the scope of this book.

Mohs micrographic surgery

For certain higher risk tumours (most commonly BCC and squamous cell carcinoma) Mohs micrographic surgery is the treatment of choice. Factors which determine a higher risk may include aggressive histology, ill-defined margins, large size (>2 cm), critical site such as eyes, lips, nose, and ears and recurrence following previous treatment. Unlike standard excision with pre-determined margins, the tumour is debulked and excised with a narrow clinical margin. The tissue is labelled with different coloured inks and mapped to the wound on the patient. In standard Mohs practice, the tissue is then processed for microscopic examination with frozen sections usually within one hour. Specially trained Mohs biomedical scientists and processing equipment are required in close proximity to the operating room/theatre. The sections in Mohs surgery are horizontal and therefore the entire margin is visualised as compared with conventional excision when they are vertical (like bread loaf slices) so that only a small percentage is analysed. The Mohs surgeon reads the slides and if tumour is still present within the tissue sections, takes more tissue precisely where it is still evident on the patient. This ensures that the tumour resection involves the least amount of normal tissue and yet achieves the highest likelihood of cure.

Further reading

Lawrence, C. (2002). *Introduction to Dermatological Surgery*, 2e. Oxford: Blackwell Science.

Lawrence, C.M., Walker, N.P.J., and Telfer, N.R. (2004). Dermatological surgery. In: *Rook's Textbook of Dermatology*, 7e, vol. 4 (ed. D.A. Burns, S.M. Breathnach, N.H. Cox and C.E.M. Griffiths), 78.5–78.7. Oxford: Blackwell Publishing.

Robinson, J., Hanke, C.W., Siegel, D.M. et al. (2015). *Surgery of the Skin – Procedural Dermatology*, 3e. Philadelphia: Elsevier Mosby.

CHAPTER 25

Lasers, Intense Pulsed Light, and Photodynamic Therapy

Alun Evans¹ and Saqib J. Bashir^{2,3}

¹ Bridgend, Wales, UK

² King's College Hospital, London, UK

³ Harley Street, London, UK

OVERVIEW

- Laser treatment uses high energy radiation at different wavelengths which can be directed at specific targets.
- Laser treatments should only be undertaken by those with appropriate training.
- It is essential to make sure that patients are carefully selected, are fully informed and have an adequate preoperative assessment.
- A variable level of pain is experienced by patients. Surface, local, or general anaesthesia is used as necessary.
- Different types of laser are used to target different tissues in the skin and therefore careful selection of the correct laser is essential. Lasers can target pigment (melanin, tattoo dyes), blood cells, hair follicles, or surface cells (resurfacing).
- Photodynamic therapy (PDT) involves the photoactivation of a topical chemical. It is commonly used to treat solar keratoses, Bowen's disease, and large superficial basal cell carcinoma.

Lasers in dermatology

Laser dermatology is an exciting and expanding field, offering new ways to treat a variety of skin conditions and diseases. The field overlaps concepts of medical dermatology, surgical dermatology, and photobiology and requires a broad understanding of these areas to deliver a highly successful laser practice.

This chapter will look at the interaction of light energy and skin tissue: the properties of the light and its delivery to the tissue need to be matched with the condition being treated. The different types of laser and light devices will be considered, as will the common indications for laser treatment and some more rare conditions that can benefit from laser.

Lasers versus intense pulsed light

Lasers and intense pulsed lights (IPLs) are the main devices that will deliver high energy light pulses to the skin. While there are important differences between the two types of device, the terms are often used interchangeably – for convenience, the term ‘laser’ is used in this chapter when referring to treatment.

The main difference between the two is that laser devices generate a specific wavelength of light, which is used to target a particular tissue component (e.g. melanin). In contrast, IPLs produce a broad spectrum of light. Most IPLs will have an interchangeable filter, so that only a very narrow range of light wavelength is actually emitted to the skin target. This allows the operator to change the filter depending on what type of lesion they are treating. IPLs tend to have a large handpiece with a window, which is applied directly to the skin surface. The beam is broad and not focused.

Laser devices create a laser beam of a single wavelength, which is a collimated, parallel beam of light energy. This can be focused very specifically on a target, for example on a small haemangioma. Laser beams are created when energy is passed through the laser medium, the electrons are excited, and then release energy to return to their resting state. This release of energy is in the form of the laser light, which can be focused on the skin target. Lasers emitted from one type of laser will have quite different tissue interactions compared to a laser from another type of laser – they have specific properties. For this reason, in clinical practice, lasers are often known by the lasing medium used, which can be a liquid (e.g. dye lasers), a gas (carbon dioxide), or a crystal (neodymium: yttrium aluminium garnet).

The advantages of a laser (over IPL) are that the single wavelength provides specificity in treatment, the collimated light means very precise aiming and they can produce very short pulses of light, currently picoseconds in clinical practice.

Laser treatment

Laser tissue interaction

Lasers emit a beam of light of a single wavelength, which can be selectively absorbed by a target of a certain colour, causing heating and subsequent lysis. This target is known as a *chromophore*, from the Greek word for ‘bearing colour’. The duration of the laser pulse is also set to be selective for the size of the chromophore. Larger targets such as hair follicles take longer to heat up and are slower to cool than smaller targets such as melanosomes. Lysis of the chromophore leaves a residue of smaller particles which are subsequently phagocytosed by macrophages. This concept of selective photothermolysis underpins laser science. [Table 25.1](#) shows which type of cutaneous disorders may be amenable to treatment with which lasers.

Table 25.1 Laser indications and selection.

| Tissue | Chromophore | Laser |
|---|--|--|
| <i>Vascular lesions</i> | Oxyhaemoglobin | Pulsed dye Nd:YAG KTP |
| Haemangioma Spider naevus Port wine stain Thread veins Scars Stretch marks | | |
| <i>Pigmented lesions</i> | Melanin Haemosiderin Tattoo pigments Foreign material | Q-switched Alexandrite Q-switched Nd:YAG Q-switched Ruby Pico-second lasers |
| Café au lait macule Congenital naevi Ephelis Melasma Solar lentigo Tattoos Drug/metal deposition Bruising/haemosiderosis | | |
| <i>Structural lesions</i> | Water | Carbon dioxide Erbium:YAG |
| Anti-ageing Lentigines Lines/wrinkles Scars Sebaceous hyperplasia Seborrhoeic keratosis Skin resurfacing Skin tightening Stretch marks Xanthelasma | | |
| <i>Hair</i> | Melanin | Alexandrite Diode Nd:YAG Ruby |

Laser selection

Given the concept selective photothermolysis above, the correct laser, or IPL filter, must be selected for each patient, depending on the type of lesion and also the patient's skin phototype. For example, vascular lesions, which contain blood are amenable to treatment by targeting the oxyhaemoglobin in the blood flowing in the lesion. The wavelengths typically used for this will be in the 500–600 nm range.

However, the selection of laser/IPL is also influence by the patient's skin Fitzpatrick phototype. Darker skin contains more melanin, which can also absorb the laser energy – in this case of a vascular lesion, a short wavelength laser (500–600 nm) would be absorbed by the melanin and maybe even burn a darker skinned patient. Therefore, a longer wavelength laser, such as the Nd:YAG which produces a beam of 1064 nm would be selected, as this can still target oxyhaemoglobin but has a lower melanin absorbance on the skin surface.

As well as selecting the type of laser (wavelength) the laser operator must also select the duration of the beam (milliseconds/nanoseconds/pico seconds) and the fluence of energy to be delivered (joules/watts). Guidance on this is out with the scope of the chapter and requires professional training. Some modern lasers will have standard presets for lesion types, although advanced practitioners would be expected to have a deeper understanding.

Preoperative assessment

Laser treatment should be preceded by a full medical history and dermatological examination.

Laser centres should offer a preoperative consultation by a qualified practitioner who can diagnose and manage skin disease and counsel the patient regarding the most appropriate therapy for their condition. It should always be borne in mind that laser treatment may not represent the optimum management for a patient and that patients are not infrequently referred with the wrong diagnosis. Careful patient selection for laser treatment has been shown to be associated with fewer adverse events, more realistic patient expectations, and higher levels of patient satisfaction. The process of patient selection and preparation and an understanding of the cutaneous biology of the lesions to be treated are as important as the laser treatment itself.

Key concepts that the laser practitioner must assess are:

- What is the dermatological diagnosis?
- Is laser an appropriate choice (time/cost/efficacy)?
- What are the target chromophores?
- What is the patient's skin type?
- What laser(s)/IPL filters are required?
- What are realistic outcomes?

- What steps are needed to minimise complications?

Other preoperative considerations are the use of depigmenting agents such as hydroquinones to help reduce complications of post-inflammatory hyperpigmentation and the use of sunscreen pretreatment to reduce the risk of laser-induced burns of tanned skin, depending on the wavelength used.

Patients should be provided with comprehensive written information relating to the laser treatment of their particular condition before obtaining informed consent. The consent form itself should detail possible complications of treatment ([Table 25.2](#)). Scarring may be more likely in certain areas such as the chest, shoulders, and back. It is sensible to perform a small test patch using the desired settings before starting laser treatment or increasing the energy (fluence).

Table 25.2 Possible complications of laser treatment.

| |
|--|
| Pain |
| Erythema |
| Bruising (vascular lasers) |
| Pigmentary change (hypo- or hyperpigmentation) |
| Blistering |
| Scarring |

Patients should avoid direct sunlight and use a high factor sun block before laser treatment to minimise the amount of pigment in the skin and reduce the risk of complications.

Perioperative anaesthesia

Patients experience varying amounts of pain during laser treatment, and anaesthesia must be adjusted to the needs of the individual patient and the procedure being undertaken. Some lasers have cooling devices attached, which provide a degree of anaesthesia, and many patients will undergo treatment without additional pain relief. Topical local anaesthetics (EMLA[®], Ametop[®]) may be applied under occlusion before treatment but for procedures such as resurfacing or extensive port wine stains local or regional anaesthesia will be required. General anaesthesia is reserved for treatment of young children and other special cases.

Post-operative care

A variety of differing aftercare regimes exist, and one may reasonably ask whether all patients need expensive topical therapies post laser. For non-ablative lasers (which have not caused a surgical wound), patients may prefer a cooling gel such as aloe vera which also has anti-inflammatory properties. Other soothing aftercare products include silicone-based creams, some of which may contain copper, thermal water, or other topical anti-inflammatory ingredients as well as a moisturiser or sunscreen.

When the skin surface is broken, thicker emollients such as white soft paraffin/liquid paraffin blends can form an effective skin barrier. These can be combined with antibacterial washes such as chlorhexidine in a lotion base (rather than a soap base).

Lesions around the mouth have a higher risk of infection, particularly *Staphylococcus aureus* and herpes simplex reactivation. In resurfacing cases, oral prophylactic antibiotics, and antivirals are prudent.

Sunscreens are often advised post laser treatment although their role is not clear in non-ablative treatments. In ablative treatments, there is shedding of the skin surface which may lead to increased penetration of light through a thinner skin surface. Hence, sun protection is considered important to attenuate post procedure hyperpigmentation. The advice regarding sunscreen for other non-ablative lasering may vary depending on the patient's likely exposure. What may be more important is ensuring that the patient is not tanned prior to the next treatment session, to enhance penetration of the laser and reduce the chance of burning.

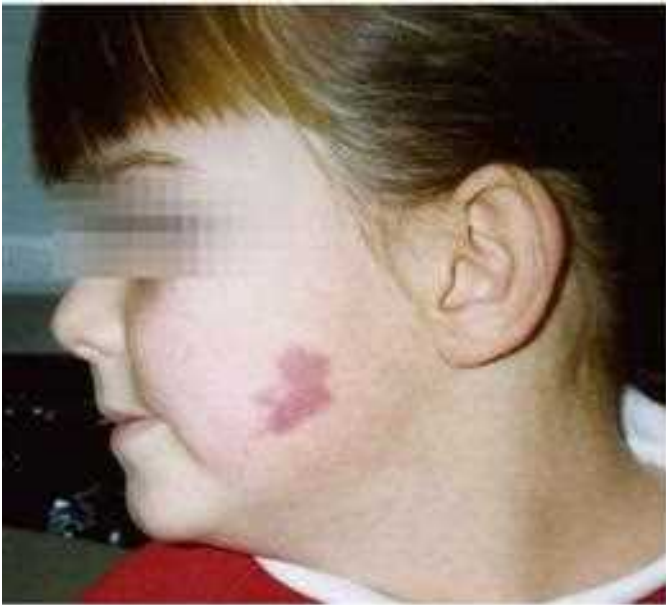Laser safety

The main dangers posed by lasers arise from the energy contained within the beam which can produce a thermal burn or ignite flammable materials. The eyes of the patient, operator, and assistants must be protected using goggles or eye shields specific to the type of laser being used. Other risks come from the high-voltage electricity and operator-dependent errors in technique. Those intending to operate lasers should have prior appropriate training.

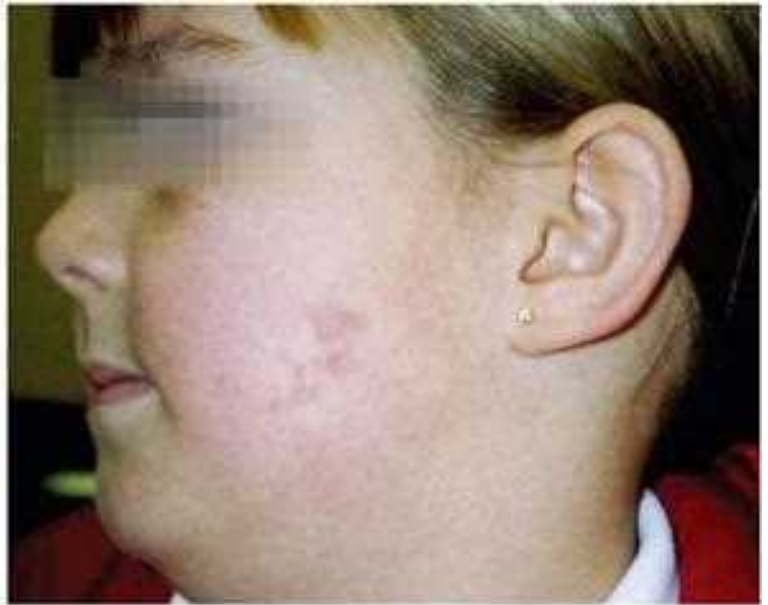Careful patient selection for laser treatment by highly qualified medical practitioners has been shown to be associated with a lower rate and better management of adverse events, more realistic patient expectations and higher levels of patient satisfaction. Preparation and selection of patients and an understanding of skin disease are crucial before selecting a suitable laser, if any. Laser centres should offer a preoperative consultation by a qualified practitioner who can diagnose and manage skin disease and counsel the patient regarding the most appropriate therapy for their condition.

Vascular lesions

There are numerous conditions which consist of fixed abnormal blood vessels in the skin including port wine stain ([Figure 25.1](#)), spider naevus, telangiectasia, and various types of haemangioma. The pulsed dye laser (585–600 nm) or the KTP laser (532 nm) is used to target oxyhaemoglobin within these vessels. The pulse duration is set so that larger vessels are targeted but the smaller normal vasculature of the skin remains intact. Lysis of the abnormal vessels quickly produces a well-demarcated bruise which may be quite prominent and lasts for up to 14 days ([Figure 25.2](#)). Repeated treatments, approximately eight weeks apart, will be necessary for most patients, and lesions such as port wine stains that evolve over time may require ongoing therapy.



(a)



(b)

Figure 25.1 Port wine stain (a) before and (b) after treatment with a pulsed dye laser.

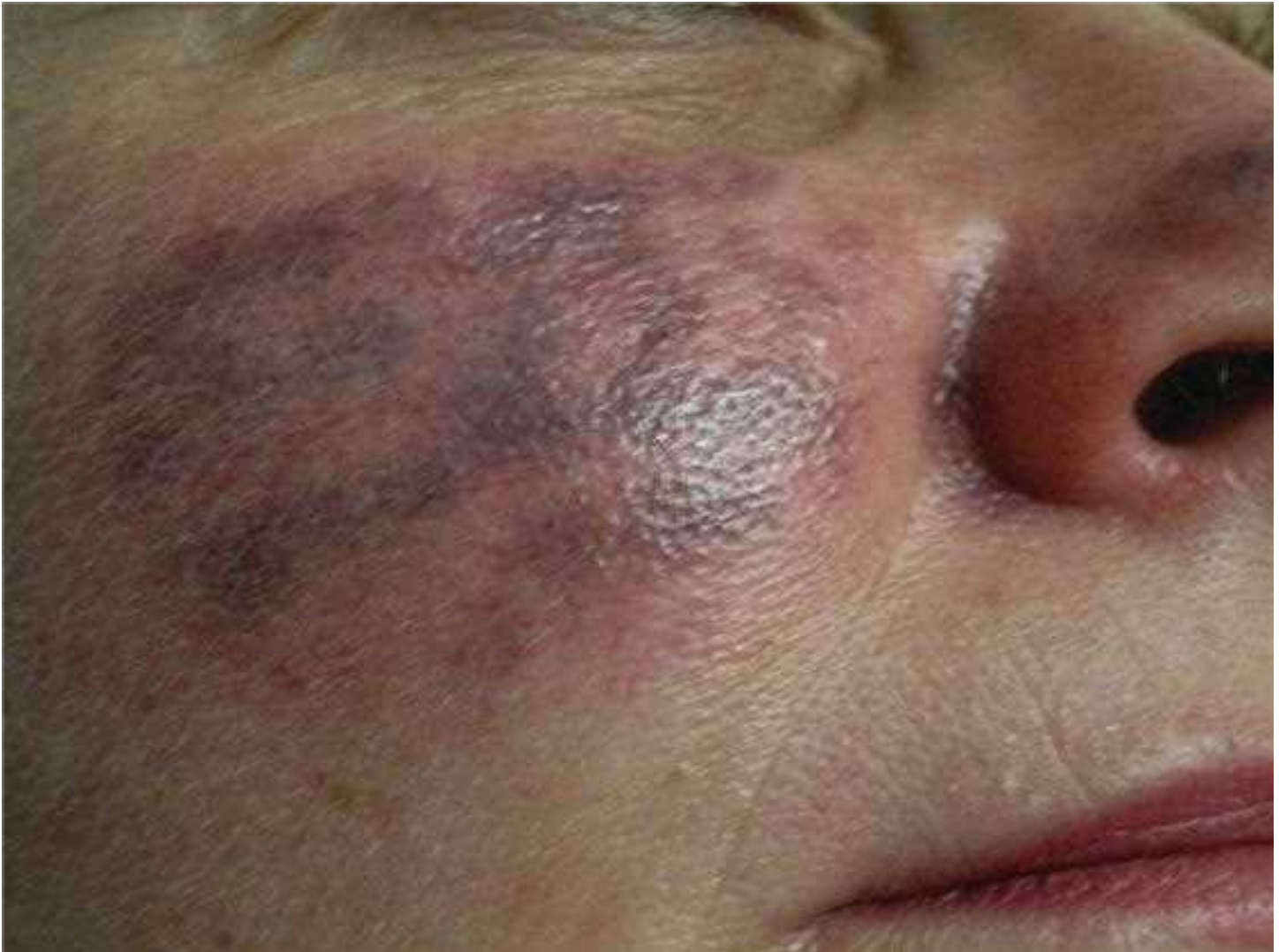

Figure 25.2 Bruising following pulsed dye laser treatment.

Pigmented lesions

A wide variety of pigmented lesions affecting the skin are amenable to laser treatment. The appropriate laser for each lesion can be selected by considering the cause and location of the abnormal pigmentation. It is important to make a specific diagnosis of pigmented lesions, rather than simply treating 'pigmentation' itself, as the responses and adverse effects vary considerably.

The commonest pigmented lesions are the result of an abnormal accumulation of melanin within the skin. The melanin is contained within melanosomes which are around 0.4 μm in size. A laser with a very short pulse duration such as the 532-nm Q-switched Nd-YAG or Q-switched ruby lasers will selectively target melanin within the epidermis. Solar lentigos, café au lait macules ([Figure 25.3](#)) and ephelides (freckles) can all be treated relatively easily in this manner. Between one and three treatments are usually required to achieve patient satisfaction. Lesions that repigment over time can be retreated when necessary.

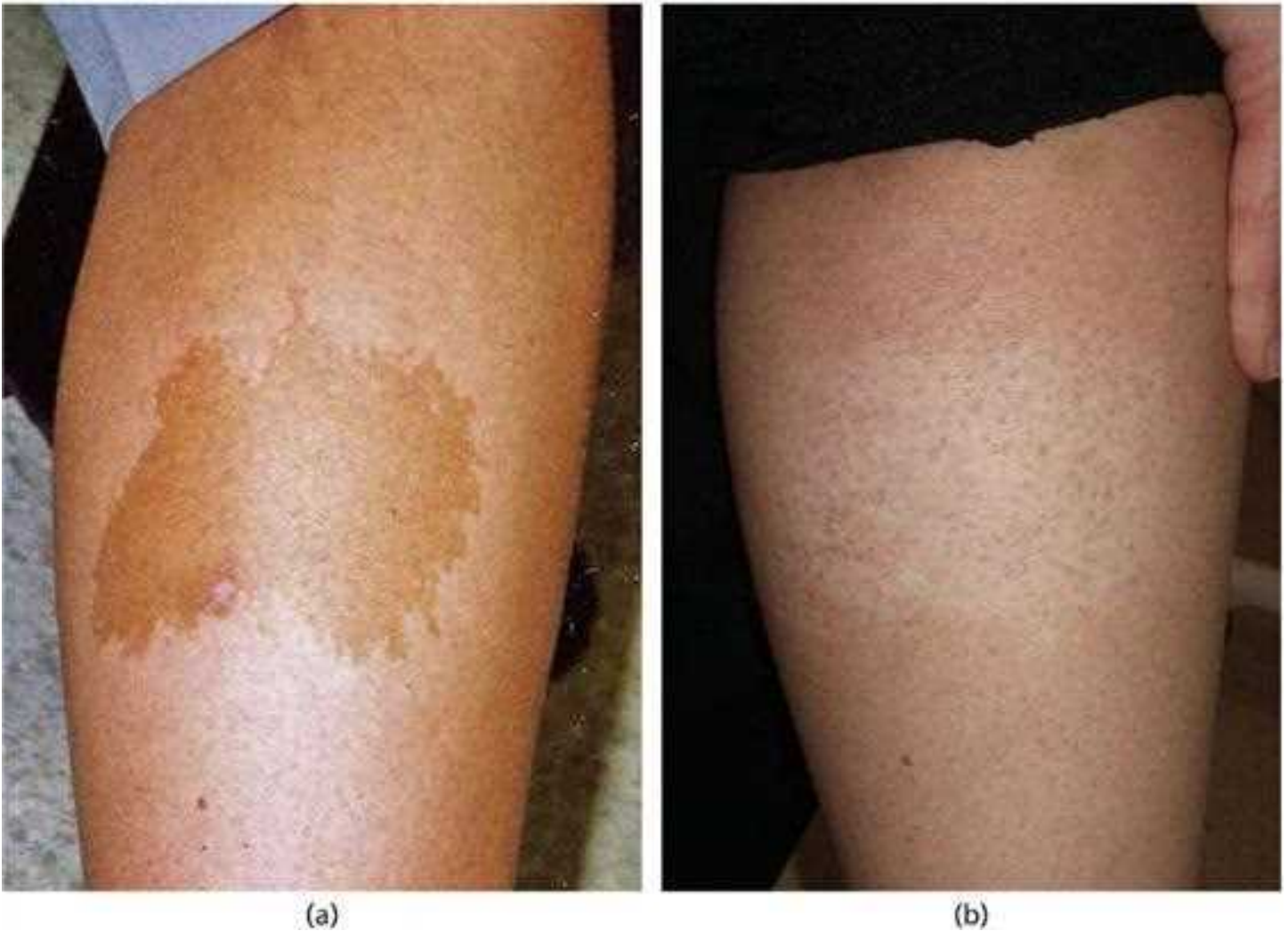

Figure 25.3 Café au lait macule (a) before and (b) after treatment with a Q-switched Nd-YAG laser.

When the melanin is located in the dermis the greater penetration afforded by a longer wavelength light is required to reach the chromophore. A 1064-nm Q-switched Nd-YAG

laser is usually employed in the treatment of congenital naevus of Ota, naevus of Ito and Mongolian blue spots.

Naevi (moles) are the result of a proliferation of melanocytes and often cause cosmetic problems. Their pigment may well be amenable to laser treatment, but this remains controversial as they have a potential for malignant transformation. This potential can range from being extremely small (e.g. junctional naevi) to an appreciable risk requiring regular dermatological review (e.g. giant congenital melanocytic naevi). The effect of laser treatment on the potential for malignant transformation is unknown. Many would suggest that it is negligible but would still be concerned that litigation might arise from any future malignancies in or around the treated lesion.

A second problem is that these malignancies will usually declare themselves through a local pigmentary change which may be masked by a laser that destroys pigment.

Certain types of melanocytic pigmentation are not amenable to laser treatment. Laser treatment of generalised pigmentary disorders such as that associated with Addison's disease should not be attempted, even in exposed sites, as the lack of uniformity of colour after treatment will lead to dissatisfaction. Melasma (chloasma) is the result of an overproduction of melanin in sun-exposed skin. The response to laser treatment is poor and may worsen the condition. Post-inflammatory hyperpigmentation is the result of a temporary overproduction of melanin by melanocytes following inflammation. Laser treatment is likely to cause further inflammation and exacerbate the problem.

Various forms of abnormal pigmentation exist in the skin, which are due to substances other than melanin. Certain drugs cause localised pigmentation of the skin which may be amenable to laser treatment. Amiodarone and minocycline produce pigmentation which may be selectively targeted by the Q-switched Nd-YAG, Ruby, and Alexandrite lasers.

Haemosiderin is an iron-containing pigment that is deposited in the skin following extravasation of red blood cells. This is very common on the lower legs but treatment with laser is not indicated.

Tattoos

The art of inserting exogenous pigments into the dermis of the skin for decorative effect has been practiced for thousands of years. The subsequent granulomatous reaction permanently fixes the pigment in the skin, although this fixation often outlasts the desire to retain the tattoo.

If the colour and consequently the absorption spectrum of the tattoo pigment differs sufficiently from the surrounding skin then it may be amenable to laser treatment. The appropriate wavelength is selected based on the colour of the tattoo ([Table 25.3](#)).

Table 25.3 Laser selection by colour for tattoo removal.

| | |
|------------|--|
| Blue/black | Q-switched Nd-YAG 1064 nm Q-switched Ruby 694 nm Q-switched Alexandrite 755 nm |
| Red | Q-switched Nd-YAG 532 nm |
| Green | Q-switched Ruby 694 nm Q-switched Alexandrite 755 nm |

There is no uniformity in the constituents or the application of tattoo pigment and thus no uniformity in response to treatment. Some tattoos show significant fading after only one treatment whereas others can prove far more resistant. In general, amateur tattoos will fade faster than professional ones which may require 10 or more treatments. Care should be taken in the selection of treatable tattoos and the patient must be given a realistic assessment of what is achievable for their tattoo. Responsible laser operators may deem some large multicoloured tattoos untreatable from the outset.

Laser treatment of tattoos creates microscopic steam bubbles in the skin, sometimes referred to as *laser snow* (Figure 25.4), which disappears in a matter of minutes. Initially, there will be no apparent difference in colour but over the next few months macrophages will phagocytose the newly exposed pigment particles and the tattoo will gradually fade. Treatment is therefore carried out on a 2- to 3-monthly basis.

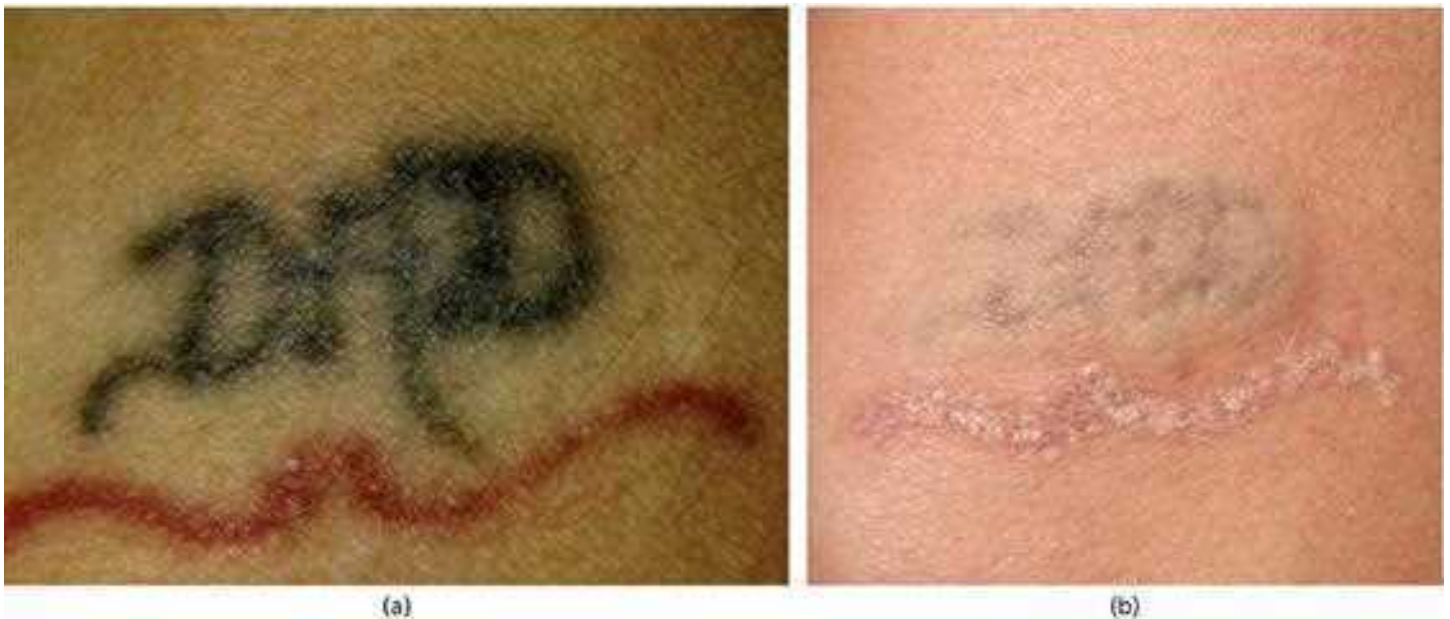

Figure 25.4 Tattoo subjected to laser removal. (a) Before treatment. (b) Fading of tattoo and ‘laser snow’ following Q-switched Nd-YAG laser treatment.

Recently, pico-second wavelength lasers have been introduced to treat tattoos. These have a much shorter duration of laser pulse and therefore do not generate heat within the skin. This results in lower adverse effects and increased efficacy. The pico-second lasers require fewer sessions to remove pigmentation than the Q-switched lasers.

Hair removal

Laser hair removal is carried out using the Alexandrite, Diode, Ruby, or Nd-YAG lasers, the last being more suitable for darker skin types. IPL can also be used, with an appropriate filter for the patient's skin type. The chromophore is melanin in the hair and thermal energy dissipates to and damages the surrounding follicular cells effecting longer term hair removal. Thus white, grey, blonde, or red hair is unresponsive to treatment, and equal care must be taken where the skin is pigmented. Erythema in the treated area can be expected for up to 48 hours. Around six treatments will be required for a satisfactory response.

Laser resurfacing

The carbon dioxide laser (10 600 nm) and the Erbium-YAG laser (2940 nm) have water as their chromophore. All components of the human body contain water and the action of these lasers on the skin cannot truly be described as selective. Rather, they are a destructive entity used to vapourise tissue. They may be applied as a narrow continuous beam to cut tissue which has the advantage of achieving reasonable haemostasis as one proceeds, enabling convenient excision of unwanted tissue, for example, keloids.

Alternatively, 'resurfacing' of the skin is achieved by photothermolysing the epithelial surface of the skin to a reasonably predictable depth in one or more passes with subsequent healing. This method can improve the appearance of superficial lesions, for example, acne scarring, wrinkles, or epidermal naevi.

A satisfactory result will only be achieved by careful patient selection and scrupulous attention to pre- and post-operative wound care. Considerable training is required to operate these lasers successfully and they should only be operated by those with appropriate expertise.

Fractional laser treatment

Fractional laser treatment delivers a series of microscopic laser beams which penetrate into the dermis and are evenly spaced across the treatment area. They do not damage the whole area under treatment, but the resulting columns of ablated tissue encourage the formation of new collagen. It is used to treat scarring, wrinkles, and abnormal pigmentation. Similar columns of epidermal and dermal damage can be induced mechanically by use of a metal roller with small protruding spikes, the so-called 'dermarollers'.

Dermabrasion and chemical peels

Superficial lesions such as wrinkles, scarring, and solar damage can be treated by simple abrasion of the skin surface using a motorised tool in a technique known as *dermabrasion*. Over the following weeks re-epithelialisation from deeper, healthier epidermis around hair follicles and sebaceous glands brings about healing. Local or general anaesthesia is required and despite intensive pre- and post-operative care the procedure may be complicated by

abnormal pigmentation, scarring, or infection. A gentler, but less effective approach is to manually abrade the skin by rubbing it with small crystals (microdermabrasion).

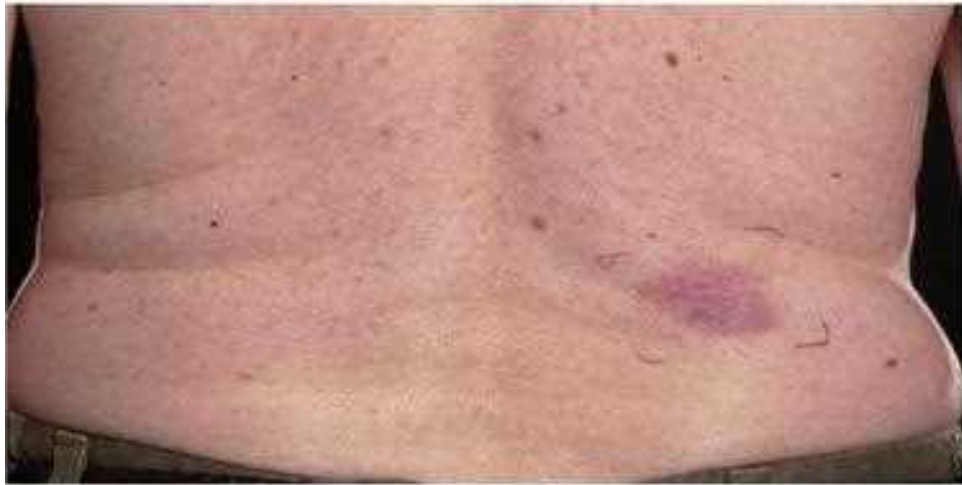A chemical peel typically uses acid solutions to create an inflammatory reaction on the skin, leading to shedding of the skin and new skin formation. Superficial peels will reach the epidermis only, while medium depth peels will remove the epidermis and reach some of the papillary dermis. Deeper peels can reach the deeper dermis. Typical acids used are glycolic acid, trichloroacetic acid and lactic acid, which may be blended with other cosmeceutical agents. Chemical peeling can be used to treat surface changes such as actinic keratosis, seborrhoeic keratosis, and lentigines. Medium depth peels can be used for deeper improvement of acne scars, wrinkles, xanthelasma, and melasma (with caution). Deeper peels are generally superseded by laser. Peels can leave the skin looking lustrous, with removal of fine lines, deeper wrinkles, stimulation of collagen to tighten the skin and make acne scars shallower. However, good results are dependent on correct patient and peel selection: adverse effects include scarring, long-term redness and post-inflammatory hyper/hypo pigmentation.

Intense pulsed light

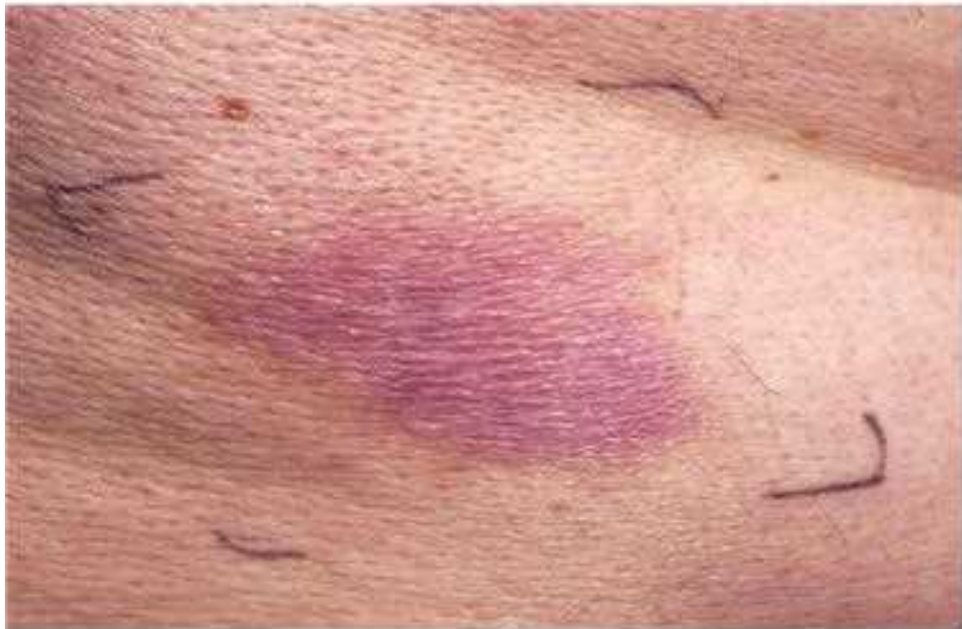Non-laser light sources such as IPL have been advocated as cheaper and less invasive alternatives for the treatment of various skin abnormalities including vascular and pigmentary disorders. They emit light over a range of wavelengths and employ filters to achieve some selectivity. IPL has traditionally been used to treat simple vascular abnormalities such as spider naevi erythema in rosacea and cherry angiomas with relative success. However, they are being increasingly used to treat more complex vascular lesions such as port wine stains. They can be particularly helpful at treating heterogeneous vascular abnormalities where there may be venous and arterial aberrant vessels in the same lesion. IPL, being less chromophore specific, can treat a mixed lesion and can cause thermal heating and subsequent coagulation of deep vessels that may be difficult to target by conventional vascular lasers. There is less blood vessel rupture with IPL when compared to laser treatment and consequently less purpura immediately after IPL. Technology is improving, and IPL is being increasingly used to treat a wider range of skin disorders, but as yet they are considered to be less effective than monochromatic lasers. One of the main advantages of IPL is the ability to treat large areas of skin quickly with relatively little 'downtime' for the patients.

Photodynamic therapy

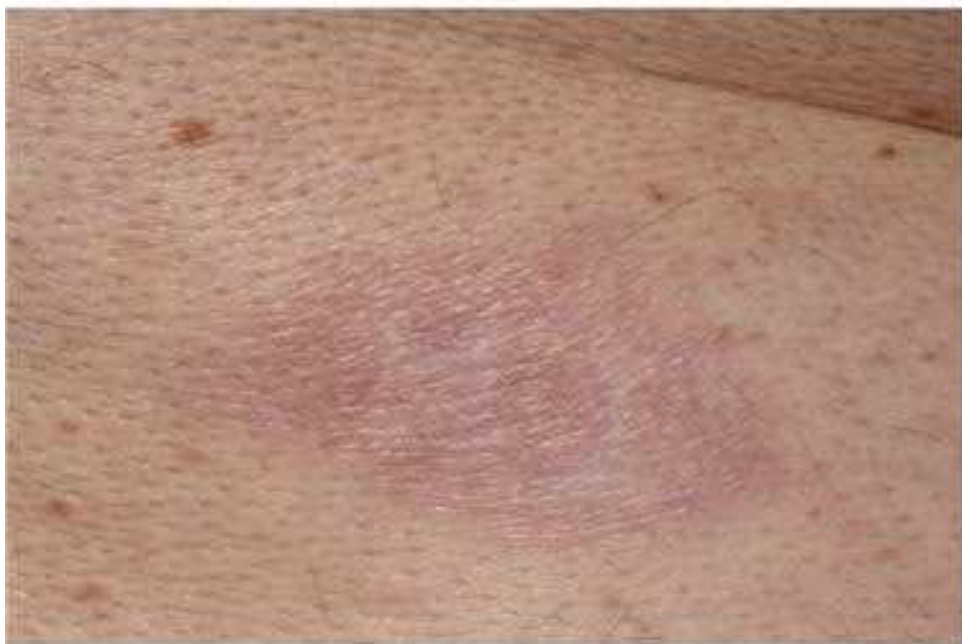Photodynamic therapy (PDT) in dermatology involves the topical application of a photoactivated toxin such as aminolevulinic acid or methyl aminolevulinate to a lesion followed after three hours by exposure to light, usually in the 630-nm range. The effective penetration at this wavelength is 1–3 mm and PDT is used to treat solar keratoses, Bowen's disease and superficial basal cell carcinoma ([Figure 25.5](#)).



(a)



(b)



(c)

Figure 25.5 Superficial basal cell carcinoma on the lower back. (a, b) Before treatment with Metvix photodynamic therapy (PDT). (c) Six months after PDT.

Source: Figures courtesy of Dr Andrew Morris, University Hospital of Wales, Cardiff.

Current protocols allow the option of activating the toxin with either a lamp, a wearable light-emitting patch, or ambient daylight. The lamp-based method will require the patient to come to clinic and can be quite painful for the 8.5 minutes of illumination. In contrast, the light-containing patch can be applied by a nurse and the patient allowed to go home, returning the power source device once used. Actinic keratosis, but not basal cell carcinoma or Bowen's disease can be treated with ambient daylight. The patient is treated with a chemical sunscreen which will filter out UV light but allow ambient light to still activate the drug. This method is much less painful than the lamp method and therefore can be used for wide areas on the face and scalp.

PDT has also been advocated for use in acne and anti-ageing although its role among the other treatment options has yet to be defined.

Summary

Lasers and light-based therapies operate on a principle of targeting specific tissues via a chromophore. This can be naturally occurring such as melanin, or a chromophore added to the skin such as a tattoo, or a light-absorbing molecule as a target, such as gold or aminolevulinic acid.

Further reading

New Zealand Dermatological Society: dermnetnz.org/procedures/lasers.html.

Tanzi, E.L. and Hazra, G.J. (2017). *Lasers and Lights: Procedures in Cosmetic Dermatology*, 4e. Elsevier.

CHAPTER 26

Cosmetic Dermatology

Emma Craythorne

Dermatology Surgery and Laser Unit, St John's Institute of Dermatology, Guy's and St. Thomas' Hospitals, London, UK

The field of cosmetic dermatology has seen an exponential rise in popularity with the advent of less invasive cosmetic procedures and acceptability by the mainstream population. It is important to note that the cosmetic patient visit will differ to that of the medical patient, as in many cases the treatment will be for a normal physiological phenomena – ageing. There are benefits to these cosmetic procedures that extend beyond improvement of the outward appearance due to ageing and numerous studies have shown a positive correlation with increased rate of employment, income, social, and psychological well-being. A word of caution must be made at this point to ensure that these procedures are not being delivered in an attempt to overtreat or change appearance to conform to current fashion ideals and impossibly perfect ‘selfie’ pictures.

Beauty and visible ageing

The concept of beauty as a single ideal standard is difficult to determine and features of beauty vary based on age, culture, race, and gender types. There are some features, however, that are standard throughout – we know that symmetrical and average proportions are crucial factors in determining beauty.

Ageing of the skin, as with all organs, is inevitable and occurs from a combination of extrinsic and intrinsic factors. Intrinsic ageing gives the appearance of fine wrinkled skin on a homogenous background and is determined by our genetic skin type. Extrinsic ageing leads to the hallmark signs of dryness, dyspigmentation, telangiectasia, and wrinkling (fine or coarse) and is caused predominantly by ultraviolet light, tobacco smoke, and other forms of non-ionising radiation. It is not just the skin that gives us an aged appearance, it is the concomitant effect of the underlying structures. Bone ageing, which leads to volume and support loss, hypertrophy and atrophy of facial muscle groups, and reduction and lowering of the facial fat pads all play their part in the ageing of the face ([Figure 26.1](#)).

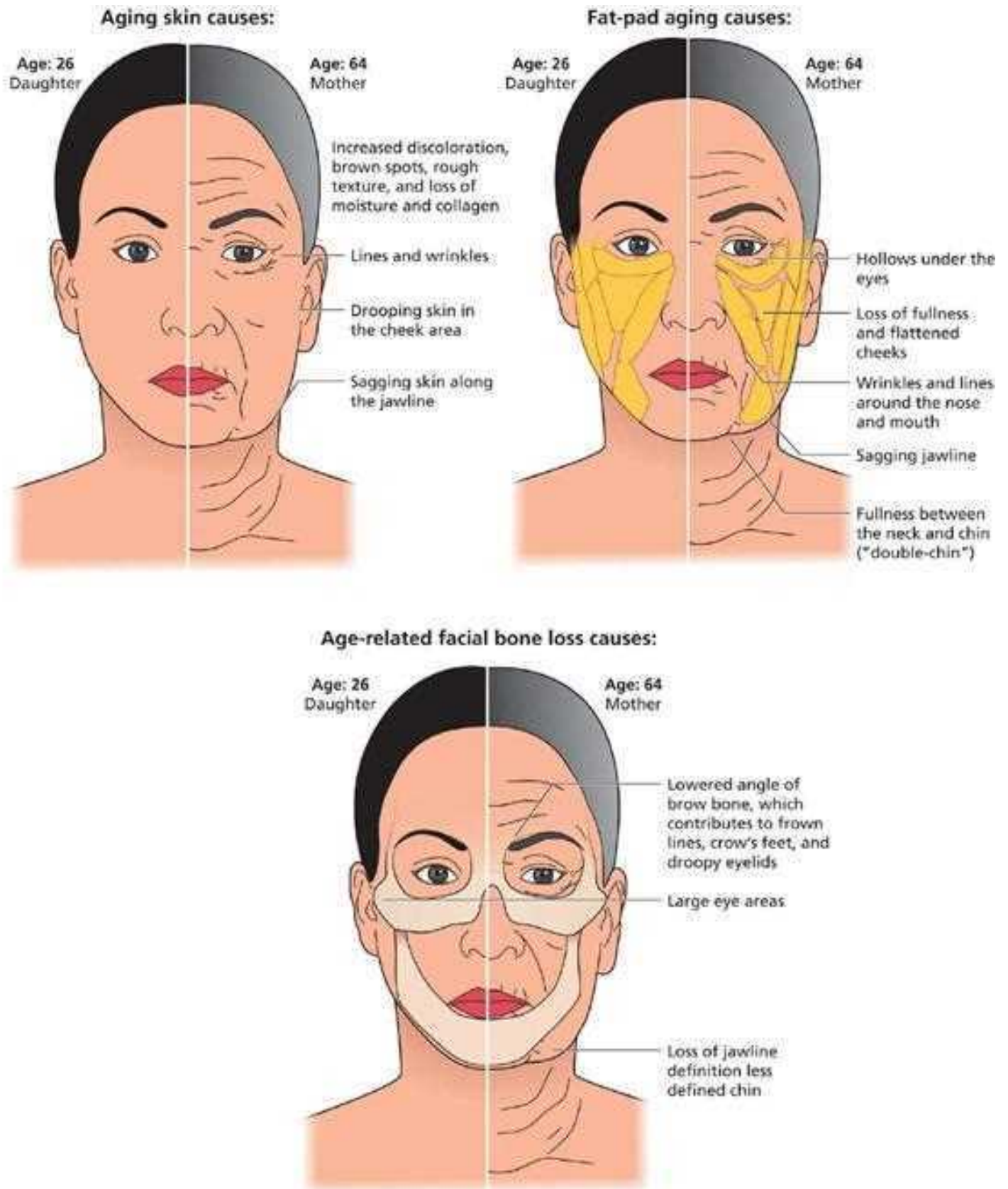


Figure 26.1 Age-related facial changes as a consequence of bone loss, fat pad atrophy, and pigmentary changes on the skin.

The preoperative assessment

History

As with medical patients, this is the key component to the management of the cosmetic patient. At consultation, you develop an understanding of the patient's concerns and expectations for cosmetic improvement and the motivation behind seeking treatment. It is important to obtain a full medical and psychosocial history, a history of previous cosmetic procedures and satisfaction with them. Notes should be made to determine if there is a medical cause for the cosmetic concern, such as hirsutism, or a psychological concern such as body dysmorphism disorder (BDD). It is important to have a record of the concerns from the initial visit.

Physical examination

Evaluation of the face should be done in the upright position and a note should be made of the Fitzpatrick skin type and texture of the skin. Evidence of photo ageing should be recorded using the Glogau classification ([Figure 26.2](#)) and attention should be paid to areas of volume loss, sagging, or atrophy.

| Type | Description | Typical Age | Other features |
|--------|--------------------|-------------|--|
| Type 1 | Early wrinkles | 20 – 30's | Mild pigment change Early photoageing |
| Type 2 | Wrinkles in motion | 30 – 40's | Early photoaging Smile lines Flat seborrhoeic keratosis |
| Type 3 | Wrinkles at rest | 50+ | Advanced photoaging Prominent brown pigmentation Prominent small vessels |
| Type 4 | Only wrinkles | 70+ | Severe photoaging Yellow-gray skin color Advanced photoaging |

Figure 26.2 Glogu classification scale for photodamage.

It is very important to consider the face as an entire unit. Photographic documentation is more accurate for recording treatment outcomes than handwritten notes.

An unexaggerated discussion of potential interventions, with the benefits and risks (common and serious) and alternatives, can be explained. A treatment plan should be given to the patient to outline the procedures considered. It is advisable to allow the patient some time to consider what you have discussed prior to immediate treatment.

Soft tissue augmentation

Injectable fillers are the key agents for the management of facial ageing associated with shrinkage of fat pads and their malalignment, they can also be used to improve skin quality and decrease depth of wrinkles. Early injectable fillers were made of collagen however, due to the risk of infection, hypersensitivity, and poor longevity compared with hyaluronic acid (HA) products, they are no longer used. To reduce the risk of complications it is advisable to use a product that has robust safety and results data from controlled clinical trials. It is important that the correct filler should be used for the relevant indication, placed correctly within the soft tissue ([Figure 26.3](#)), and that the underlying anatomy is well understood e.g. fillers used for volumising should be used deep only and not too superficially to avoid unsightly blue bump (Tyndall effect).

| Product | Viscosity | Elasticity | Spread | Lift |
|---------------------|-----------|------------|----------|-----------|
| Radiesse | 349830 | 1407 | Thickest | Most lift |
| Perlane | 124950 | 541 | | |
| Restylane | 119180 | 513 | | |
| Juvederm Voluma | 62902 | 274 | | |
| Juvederm Ultra plus | 17699 | 75 | | |
| Juvederm Ultra | 73071407 | 28 | Thinner | Less lift |

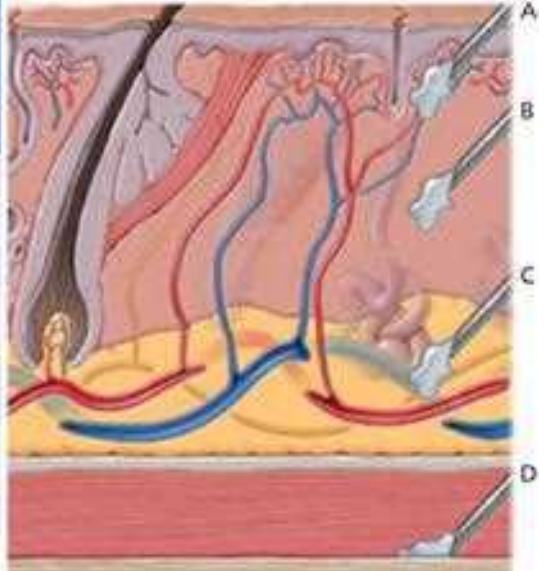


Figure 26.3 Filling agents should be placed within the skin at a site that best suits their purpose (e.g. A – superficial dermis; B – mid dermis; C – subcutaneous fat; D – periosteal placement).

Types of filler

Temporary fillers are those which are biodegradable and further divided into those which may stimulate collagen and those that are clinically inert.

Hyaluronic acid (HA) fillers dominates the market, as they are reversible, long-lasting, and have low allergenic potential and a robust safety profile for many of the branded products. HA is capable of holding 1000 times its weight in water. The products come in various concentrations, particle size, cross linkage, and some contain anaesthetic product. The safety of HA is further enhanced due to its reversible nature using the enzyme capable of degrading it, hyaluronidase. Hyaluronidase can be used in an emergency where there is vessel occlusion with HA and also where there is inappropriate filler placement, overcorrection, or post-treatment inflammatory nodules.

Polyl-L-lactic acid (PLLA) has significant collagen-stimulating ability. Injections are usually given six weeks apart (course of three injections) and there is a delayed effect to onset. Although uncommon nodule formation is the main adverse reaction associated with PLLA, and in rare cases this can be very large.

Calcium hydroxyapatite (CaHa) is made up of calcium phosphate pearls and was initially used for treating lipoatrophy in patients taking antiretrovirals. This product can induce formation of large permanent nodules.

Permanent fillers such as silicones, polyacrylamide, and polyalkylamide are generally not in use and not recommended within current guidelines due to the severity of adverse reactions, both acute and delayed. It should be remembered that the patient's immunological response to a permanent product may change with time and adverse effects such as large granulomatous reactions may occur. Currently there is no antidote to a permanent filler other than surgery.

Polymethylmethacrylate (PMMA) is a permanent filler that is currently available. It is a combination substance of PMMA beads in a bovine collagen that will remain permanently in the skin, and currently it has a licence for treating acne scars.

Technique

There should be thorough understanding of the facial anatomy to reduce the risk of serious complications by inadvertent injection into an artery. Both needles and cannula can be used depending on the specific indication. In some areas only a needle can be used, such as injections to improve skin quality. In other areas the cannula technique can be used, to improve patient safety as there is a reduced risk of penetration into a vessel and resultant embolism. The filler is then injected when it is in the correct plane of tissue in either micro aliquots, or stacked on top of each other or as a fanning technique. The skin should be disinfected and treated as a sterile procedure to avoid infection.

Depending on the desired outcome filler is placed to support the skin on underlying bone, add volume, and fill lines or to used more superficially for improved skin tone and texture. Individual areas can be treated, such as lips ([Figure 26.4](#)). Care should be taken to ensure that individually treated areas remain in proportion to the rest of the face.

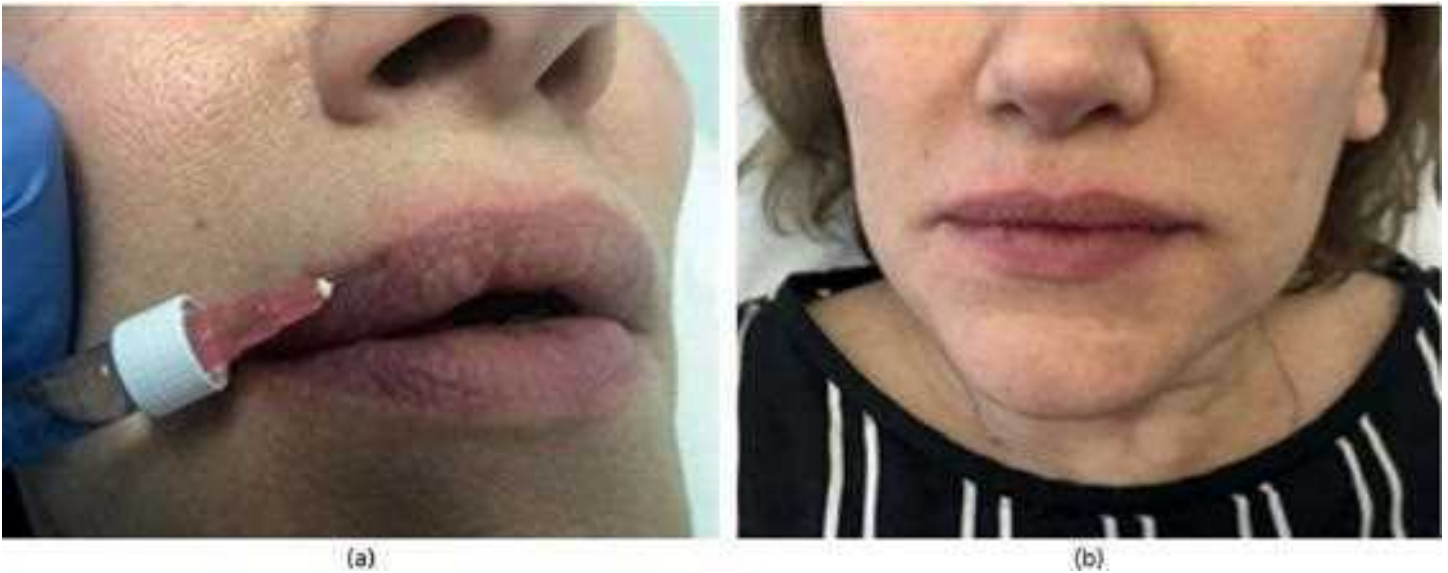

Figure 26.4 (a and b) Placement of hyaluronic acid, with a needle, just below the vermillion border for lip augmentation.

Adverse reactions and their management

The most serious adverse reactions occur as a consequence of intravascular injection and arterial infarction; abscesses, nodular formation, and immunological reactions. Nodules are usually as a consequence of an exaggerated immune response which may be due to a biofilm or immunological reaction to the filler.

Management of arterial occlusion is a medical emergency, the event is accompanied by pain and pallor distal to the occlusion. This occurs most commonly in areas of the mid-face and have included occlusion of the retinal artery causing blindness (risk estimated at 1 in 3 million). If HA has been the filler used then hyaluronidase should be injected immediately in order to prevent the cascade events leading to necrosis. If pustules and erythema are already visible then symptomatic treatment is commenced.

Hyaluronidase

Hyaluronidase is an essential tool for all clinicians administering fillers, and is used in an emergency for inadvertent injection of HA into a vessel, and on a non-urgent basis for removing small amounts of unwanted filler. It is a powder reconstituted with saline to give a solution of 150 IU/ml. The area of injection and the field of discolouration is injected with minimum 200 IU hyaluronidase and repeated at 60 minute intervals. If there has been acute visual loss due to vessel occlusion then a retrobulbar injection of hyaluronidase is required.

The plan for treatment of a nodule depends on the type of filler injected, a biopsy can be taken if there is uncertainty. If an HA filler has been used then hyaluronidase around the nodule should be injected – intralesional steroid injection can then be used in combination with oral antibiotic.

Botulinum toxins

Botulinum toxins (BTXs) are neuromodulators that act by blocking acetylcholine release from axon endings at the neuromuscular junction and is used to treat a variety of conditions caused by muscle hyperactivity. Within the field of aesthetic medicine BTXs are used to reduce the activity of dynamic muscles that contribute to facial lines and to reduce the volume of sweating in hyperhidrosis.

The core molecule in BTX is a 150 kDa protein with three domains and different neurotoxin associated proteins (NAPs) according to the serotype. Its action is at the neuronal endplate and works by blocking release of acetylcholine and inhibiting muscle contraction. BTX-A binds to the SNAP 25 proteins and BTX-B binds to the vesicle associated membrane protein. As new synaptic proteins are synthesised over time, normal function of muscle returns usually around four to six months. The potency of BTX is measured in units of activity; units between different toxin types and different products vary and each product should be considered as a different drug.

Clinical use

Injection site selection follows a common theme; however, as each patient will present with their own particular set of muscular dynamics it is important that placement of the product is individualised. In order to determine this assessment should be made on muscle contraction and at rest, facial asymmetry should be noted and injection site placement and dosage adjusted accordingly. Adjustment should be made to the dosage depending on the bulk of the muscle being treated and attention paid to the desired depth of the injection.

Upper forehead

The glabellar lines are the most commonly treated site and those first studied to gain approval for its cosmetic use. The muscles targeted are the depressors; corrugator and procerus, with a smaller contribution from the superolateral orbicularis oculi muscle. The frontalis muscle is an elevator and responsible for horizontal forehead lines, injection along this muscle must also be targeted to reduce these ([Figure 26.5](#)). A balance must be struck to ensure that there is not overtreatment leading to brow ptosis. It is important to select the correct injection sites depending on the preference for a flat or arched eyebrow.

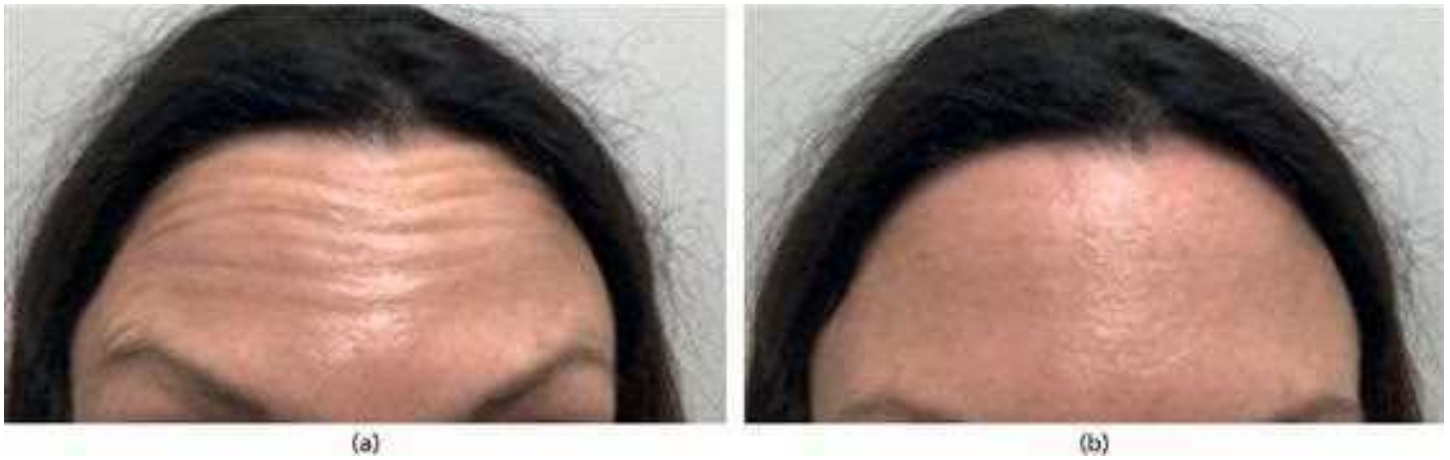

Figure 26.5 (a and b) Botulinum toxin injected into the upper forehead to reduce the horizontal lines.

Lateral canthal lines (crow's feet)

These lines are caused by contraction of the orbicularis oculi, BTX is injected into the lateral aspect 1–2 cm lateral to the ocular bony rim.

Mid face

Common sites treated in the mid face include the lines on the lateral nose treated with a small dose of BTX into the nasalis muscle. Nasal tip ptosis can be improved with injection into the septi nasi muscle. Gummy smile can be corrected with injection into the elevator labii alaeque nasi muscle.

Lower face

The lower face has a higher risk of undesired outcome due to the overlap and interplay of the muscles, particularly around the mouth. Injection to the depressor anguli oris can reduce the downturned appearance to the lateral aspects of the lip. With age the mentalis muscle continues to contract that can lead to puckering of the overlying skin and upward turned chin, adding further to depression of the angles of the mouth. This muscle is injected in its centre.

Injection into the masseter muscle can be exceptional in its benefit for improving bruxism and for slimming the angle of the jaw. The masseter muscle can be isolated by clenching the teeth and palpating the medial and lateral border, the inferior border is the mandible. The muscle is injected at three injection sites deep into the muscle. It is important to ensure that the injections are deep enough to prevent paralysis of only the superficial masseter, resulting in a chipmunk appearance, with bulging of the deep masseter.

Neck

The platysma muscle encircles the neck and with age, vertical bands become more prominent and produces depression of the lower lateral face. Small amounts can be injected along the superior border of the platysma under the angle of the jaw and along the platysma bands, thus

allowing the muscle to relax ([Figure 26.6](#)) and prevent the downward pull of the lower facial muscles and overlying skin.

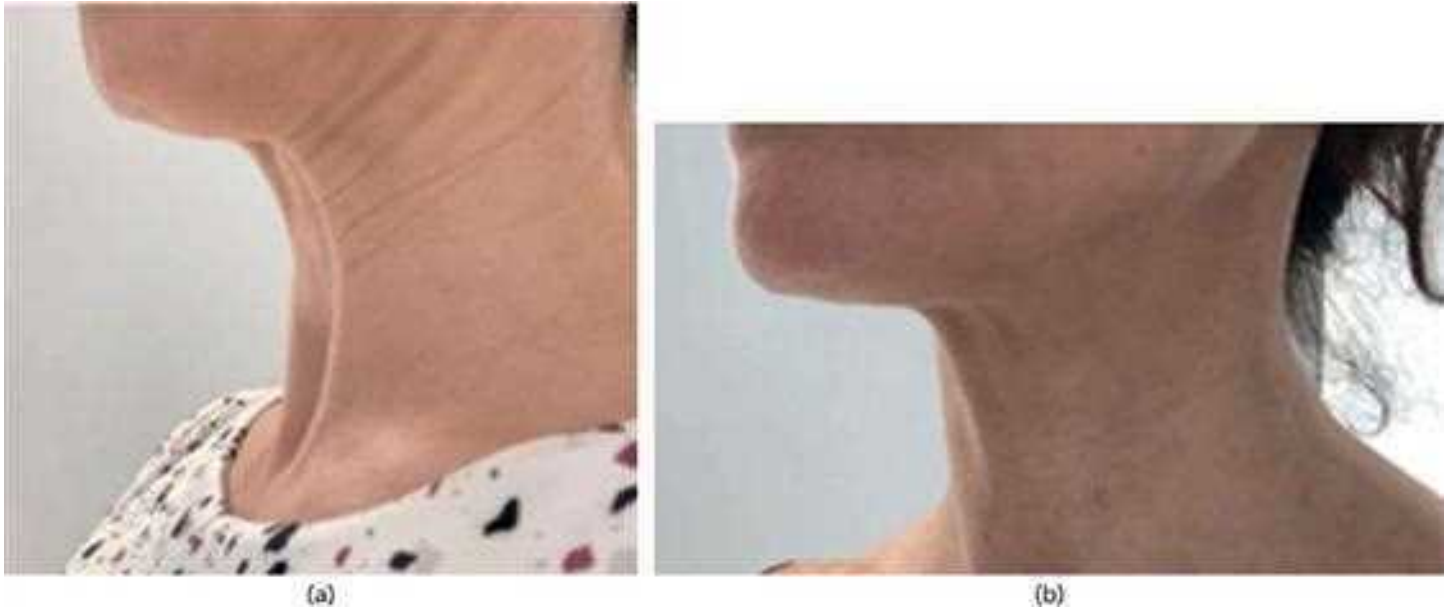

Figure 26.6 (a and b) Botulinum toxin to the platysma muscle and mentalis.

Hyperhidrosis

The use of BTX for hyperhidrosis is well documented and approximately 25 intradermal injections are made in a grid like pattern across the axilla. Effects last approximately six months.

Adverse events

The main serious side effects seen with BTX do not tend to occur in aesthetic dermatology because the doses used are low. The main causes for poor outcome are usually as a consequence of incorrect dose, injection site selection, and poor injection technique. Knowledge of the interplay of all of the facial muscles is essential to reduce the risk of poor outcome. The most frequent side effects include bruising, brow, lip, asymmetry, and ptosis and less frequent side effects include headache, diplopia, dry mouth, and dry eyes.

To reduce the risk of bruising, care should be taken to avoid injection through or into a vessel, if inadvertent injection at a vessel occurs, firm pressure should be applied to the injection site to reduce expansion of the bruise.

BTX injections are contraindicated in patients with myasthenia gravis or similar neuromuscular disorder; and should be avoided in patients who are pregnant or breastfeeding. A careful medication history and examination should be undertaken prior to treatment. BTX can be used in combination with dermal fillers and with resurfacing procedures to improve aesthetic outcome.

Chemical peels

Chemical peels cause controlled skin destruction and are classified according to the depth of the wound they create. They are commonly used to treat scarring, dyschromia, photoageing, and active acne. Treatment benefits and side effects correlate with the depth of tissue involved.

Superficial peels affect the epidermis and dermal-epidermal interface and are useful in the treatment of: mild dyschromias, acne, post-inflammatory pigmentation, and actinic keratosis and can be used to achieve skin radiance and luminosity. They can be used in nearly all skin types and epidermal regeneration occurs within three to five days, there is very little downtime associated. Indications for medium depth peels include wrinkles, photodamage, solar lentigines ([Figure 26.7](#)), and atrophic scars. Deep peels are used rarely now due to advancements in laser technologies, but are useful for marked photoageing, atrophic scarring, and deep wrinkles.

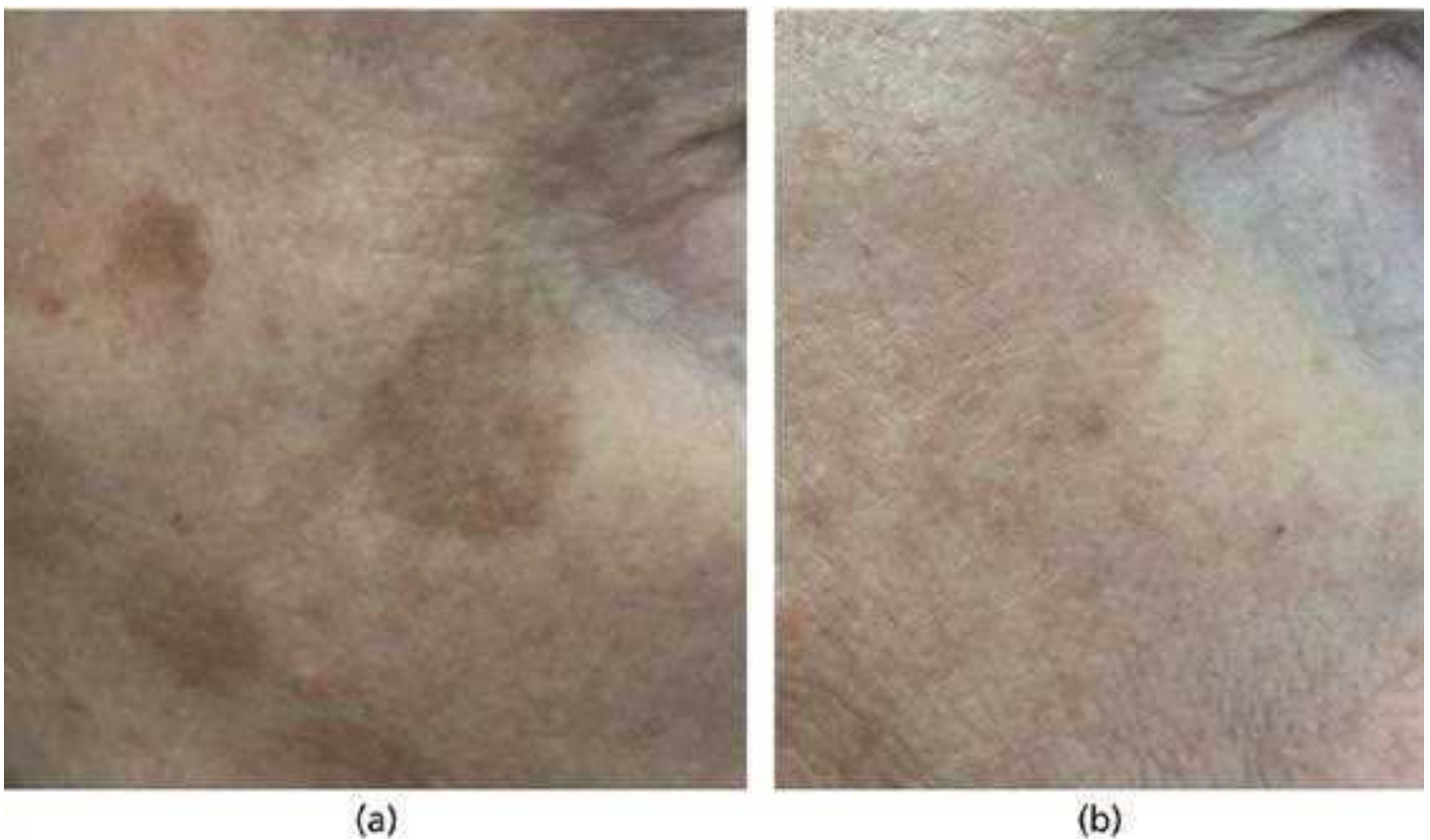


Figure 26.7 Solar lentigines on the cheek after 35% TCA peel.

Agents used in chemical peels

[Figure 26.8](#) shows the depths of penetration of the various agents used.

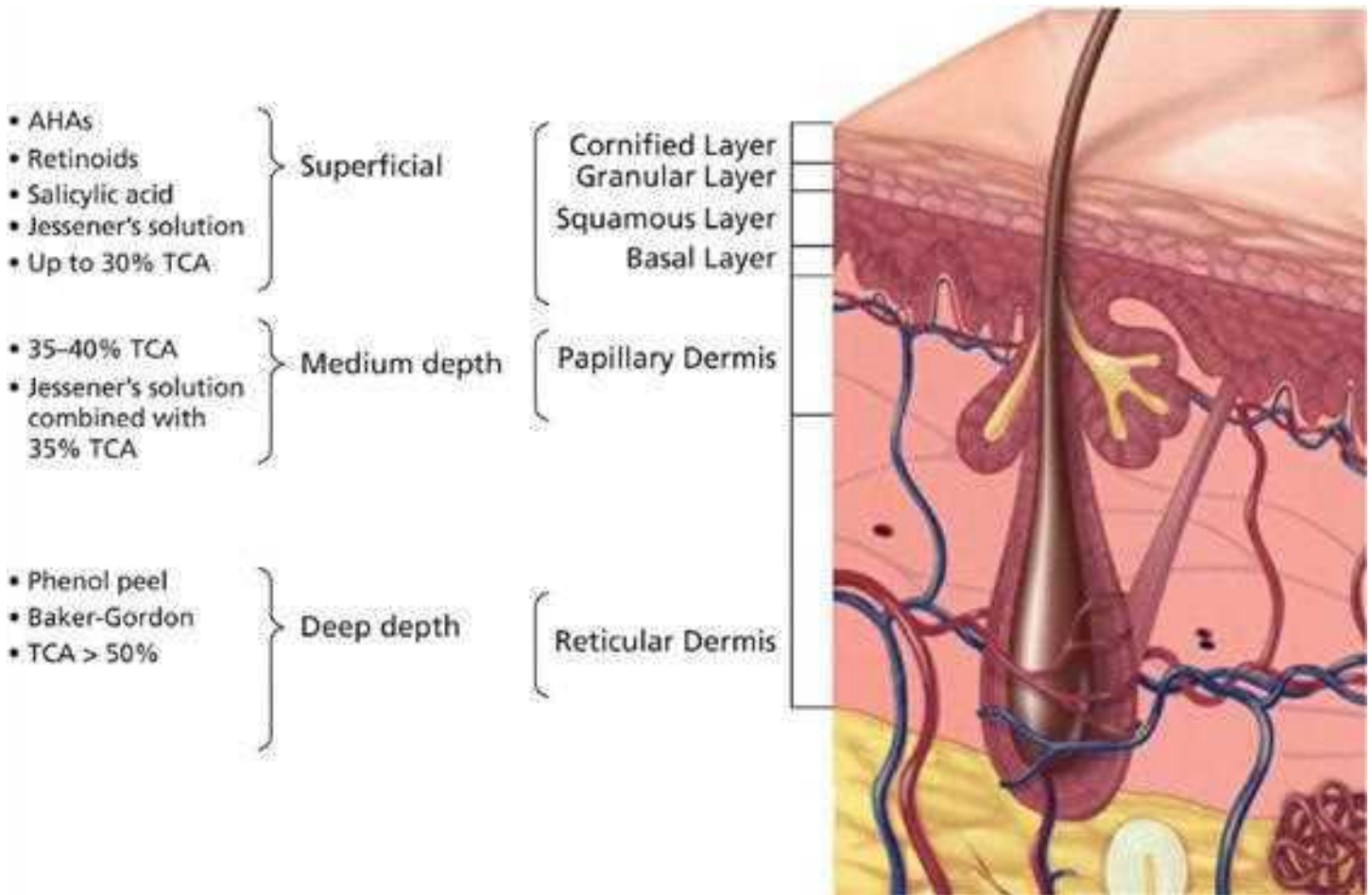


Figure 26.8 Classification of depth of peel penetration and common agents used.

Alpha hydroxyl acid s (AHA) are a group of chemicals that contain a carboxylic acid substituted with a hydroxyl group. They are found naturally occurring or can be synthesised. They act by reducing cell-cell adhesion resulting in desquamation, they also increase dermal collagen. The most commonly used AHAs are glycolic acid and lactic acid, because they are small molecules it allows for greater penetration through the skin. They are generally well tolerated although they can cause burning, pruritus, and hyperpigmentation.

Salicylic acid is a beta hydroxyl acid and is the preferred chemical peel for patients with comedomal acne, as it is lipophilic and concentrates in the pilosebaceous apparatus.

Jessner's Solution – is a blend of resorcinol, salicylic, lactic acid, and alcohol primarily it used as a superficial peel for skin preparation before a trichloroacetic acid (TCA) peel.

Trichloroacetic acid (TCA) is an analogue of acetic acid and acts on the skin by TCA of proteins and a coagulative necrosis this causes a frosting on the skin. The concentration of the TCA used will dictate the depth of the peel.

Phenol is used as an agent to create a deep peel by complete coagulation of epidermal keratin proteins, a side effect, however, is significant bleaching and resultant hypopigmentation.

Baker-Gordon utilises phenol in a formulation that permits deeper penetration into the dermis than full-strength phenol. It is mixed with Septisol (liquid soap), which reduces skin tension,

allowing a more even penetration, and croton oil, which enhances phenol absorption. Patient selection is critical in that there is a significant risk of complications such as scarring and loss of pigment.

Depth of peel

The depth of peel is decided by the molecule used and its concentration, other factors that will have an effect are the additional use of any mixing agents, number of coats applied, degreasing of the skin, pressure used in application, and differences in skin thickness. Patient factors such as concomitant retinoid use or known eczema will also have an effect.

Technique

Pre-peel consultation is important to ascertain the patients concerns and the acceptability of risk and length of downtime. A review of risk for hyperpigmentation and scarring should be undertaken and it should be noted that atrophic skin may be more sensitive to chemical peels. The skin can be primed four weeks before to allow for uniform penetration of the peeling agent. A topical retinoid is used to reduce the thickness of the stratum corneum and the consequent increase in epidermal turnover reduces epidermal melanin.

Procedure

The standard tray would have acetone (for skin degreasing), gauze, cotton-tipped swabs, water spray, bland moisturiser, timer and neutraliser (for AHA), and a syringe of saline (for use if there is accidental spillage of the peeling solution into the eye).

The skin should be washed with soap and water and the skin disinfected with alcohol, the skin is then degreased using acetone and this allows for a more even depth of peel. Vaseline is applied over sensitive areas to protect them. Each agent has its own particular technique to allow for optimal results, but usually starts at the forehead, working in a clockwise motion around the face, with eyelid skin treated last.

AHA peel solution should be applied quickly starting at the forehead. The area is massaged with a gloved hand until the desired contact time has been reached. The concentration of free acid and the contact time will determine the extent of peel. Once the end point is reached then the glycolic acid (GA) is neutralised with sodium bicarbonate. The GA is completely neutralised once the bubbling ceases, after which the face should be washed and mild emollient applied.

TCA is rubbed into the skin with gauze until the end point is reached and the areas are washed with water. The end point for a superficial epidermal peel is erythema, and a medium depth peel is a white frost with visible background erythema ([Figure 26.9](#)).

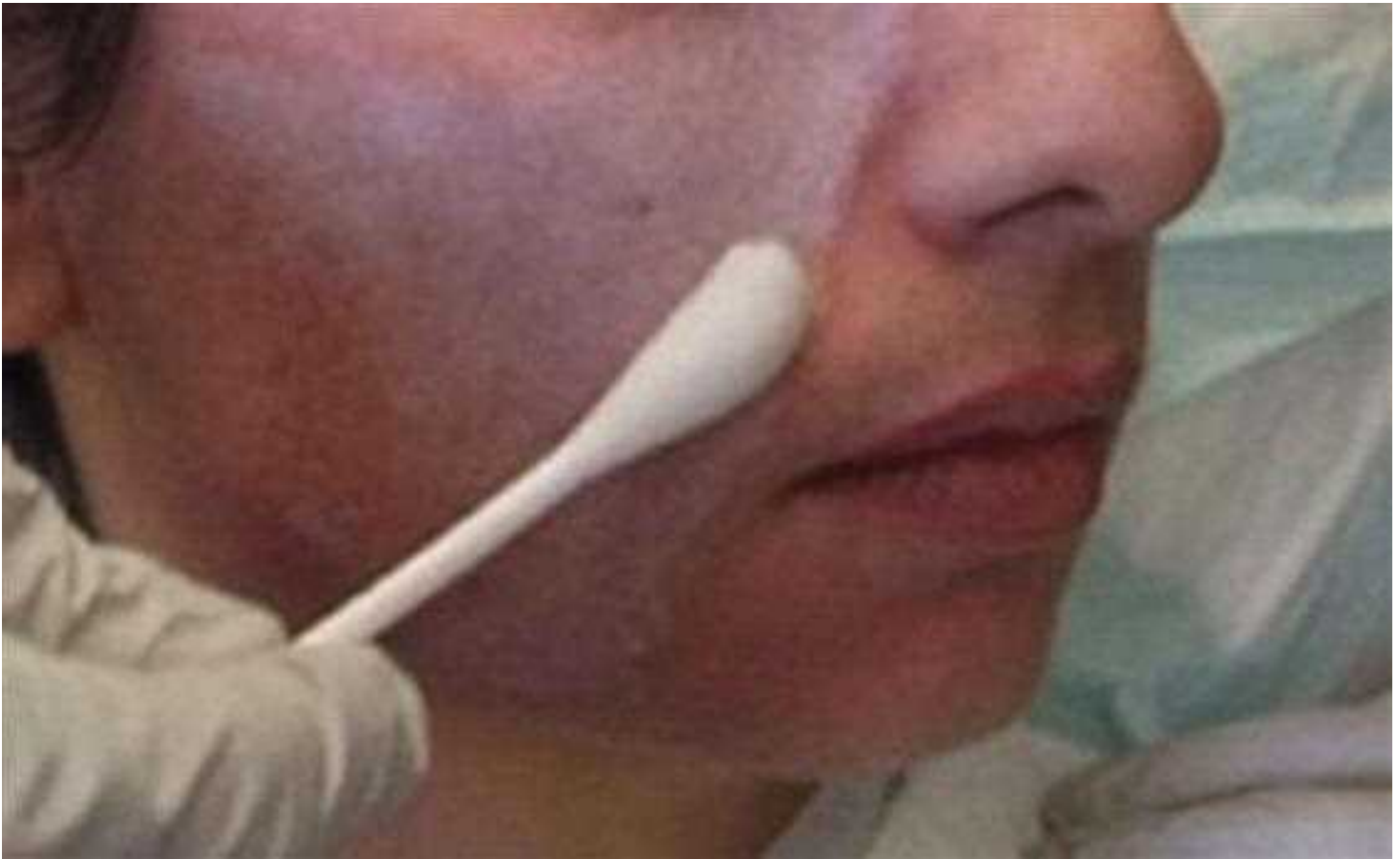

Figure 26.9 Application of trichloroacetic acid on the cheek. Note frosting and background erythema.

Jessner's peel solution is applied to the skin and due to precipitation of the chemical a light whitening occurs (this is not frosting due to tissue coagulation). Up to three layers are applied, allowing each layer five minutes to dry – more layers increase the depth of the peel. There is no need to neutralise.

Salicylic acid 20–30% is applied to the face and a second application on top of acneiform inflammatory papules.

Post peel care

Following a superficial peel a bland emollient can be used 2–4 times a day for two days. Following a medium depth peel a bland emollient is dabbed onto the skin to keep it moist and keep the necrotic area of skin in place. A gentle cleanser can be used and the skin should not be picked at. The skin will take five to seven days to re-epithelialise.

Side effects and complications

Side effects and complications of chemical peels tend to occur more commonly when peels are deeper, agents applied for longer, and in darker skin types. When treating darker skin types agents such as Jessner's, salicylic acid, or glycolic acid should be used as they have a lower risk of post peel complications.

Persistent erythema can occur in some patients and this usually resolves by 60 days; the patient should be observed for scar formation. The risk of infection increases with the depth of peels due to loss of barrier and crust formation leading to bacterial colonisation. Infections should be treated quickly and aggressively with appropriate oral antibiotics and wounds dressed with acetic acid soaks, to prevent scar formation.

Chemical burn of the face ([Figure 26.10](#)) can occur even with superficial peeling agents if they are left on the skin for too long, burns tend to heal with post-inflammatory hyperpigmentation.

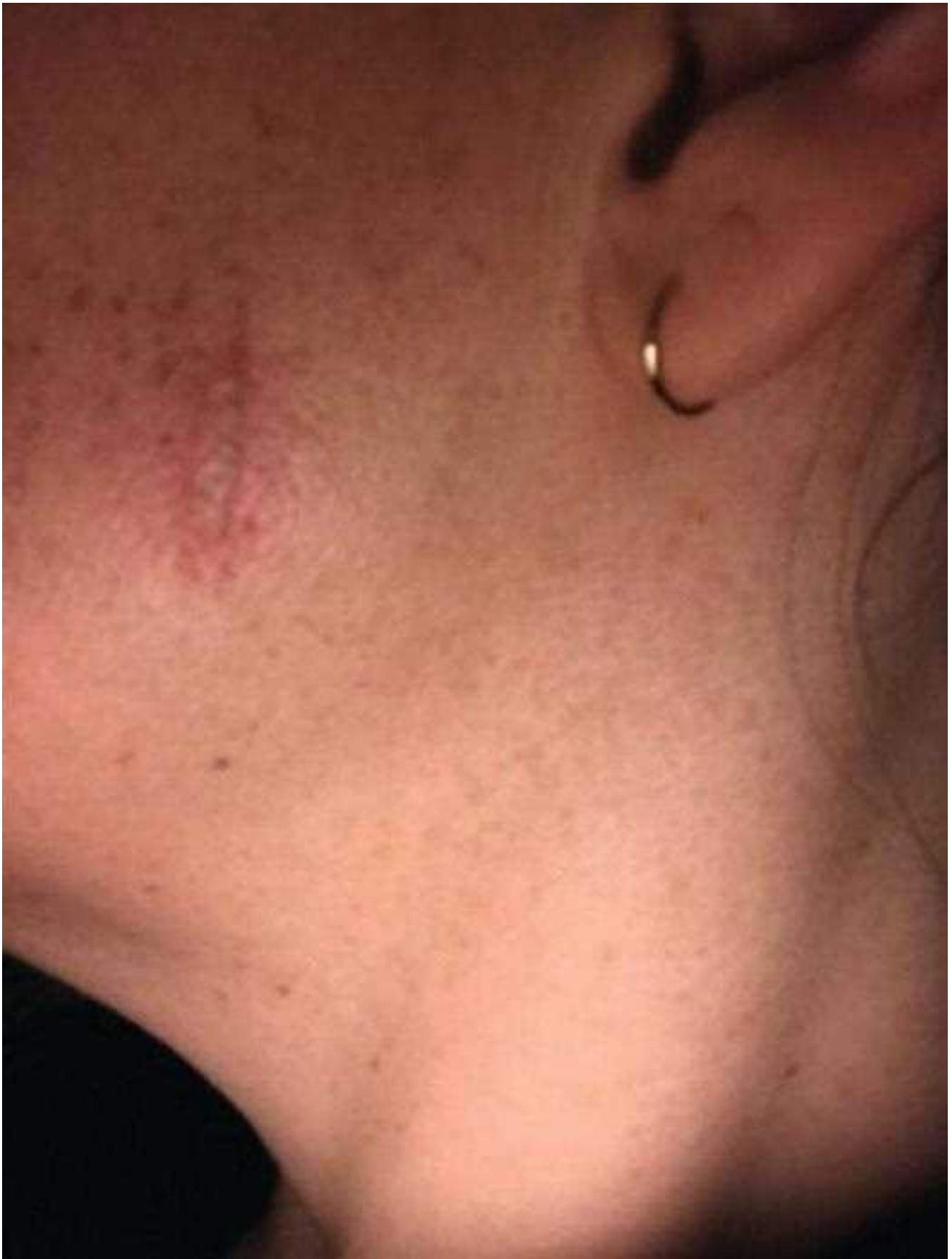

Figure 26.10 Chemical burn as a consequence of accidental spillage of 50% TCA peel.

Milia and acneiform eruptions can occur two to three weeks post peel and are likely as a consequence of the occlusive effects of the thick ointments used post treatment.

Post-inflammatory hyperpigmentation can take months to resolve and treatment is with broad-spectrum sunscreen, topical hydroquinone, vitamin C, and tretinoin.

Hypopigmentation is a complication of deep chemical peels as a consequence of mass melanocyte destruction and may be permanent.

Scarring is rarely seen in superficial peels and are usually as a consequence of infection or reduced wound healing, Hypertrophic scarring can be treated with topical steroids, pulsed dye lasers, and fractionated laser treatment.

Skin tightening devices

Microneedling

Microneedling causes a physical injury to the skin by penetration of microneedles to a specific depth. This induces a wound healing cascade and neocollagenesis. It is effective and safe in the treatment of acne scars, wrinkles, and striae. The microneedles are arranged on a roller drum (192 needles), a pen, or a stamp and are available in different lengths depending on the depth of penetration required. The procedure causes a repair mechanism and neocollagenesis based on the same pathway as that by fractionated laser treatment, with the difference being that it involves a mechanical traumatic micro-injury and not a thermal-induced micro-injury. The procedure is cost-effective and an excellent alternative where lasers are not available or in patients with darker skin type and at risk of hyperpigmentation from thermal injury.

Procedure

The facial skin will have a topical anaesthetic agent applied for a minimum of 45 minutes. The needles are inserted into the skin at exactly 90° and in a multidirectional pattern to ensure maximal coverage. Dragging of the needles should be avoided to ensure that there is not shearing of the skin. For therapeutic benefit and neocollagenesis, pinpoint bleeding will be achieved. The skin will have a 'sunburnt' appearance to it for the next 48 hours and strict sun avoidance must be adhered to. The skin is oedematous for a number of days and the long-lasting benefit of neocollagenesis is only seen at three months post treatment. Treatments are usually multiple and spaced six weeks apart.

The procedure can be used in combination with topical application of platelet-rich plasma (PRP) allowing transdermal delivery. PRP is a concentrate of platelet-rich plasma protein and is derived by collection of autologous whole blood that is double centrifuged. Despite evidence being poor for its role in skin remodelling it is a popular treatment for rejuvenation.

Radiofrequency

Radiofrequency can also be used to tighten tissue by heating the tissue at a selected specific

depth, achieved by adjusting the frequency. Water is the target of the process; local heat injury induces an inflammatory response and neocollagenesis ensues. Radiofrequency is also used for body contouring, when the same technology is applied to the adipose tissue. Devices can be monopolar or bipolar as well as fractional. Erythema and oedema are the common side effects and this resolves within 24 hours, the safety profile especially of the newer devices is excellent, although patients must be set reasonable expectation of effectiveness.

Body contouring

Surgical means of body contouring involves downtime and rare but highly significant risks, therefore the market for non-invasive technologies has grown dramatically.

Cryolipolysis uses controlled cold exposure to selectively damage adipocytes which occurs gradually over three months. The side effects are minimal but include erythema, bruising, and temporary paraesthesia, and care is needed in those patients with cold-induced conditions.

High-intensity focused ultrasound ablates subcutaneous adipose tissue and induces cell necrosis. The areas around the focal zone do not increase in temp to the same degree and therefore are unaffected. Inflammatory response results in metabolism of the disrupted tissue and overall volume loss at the adipose layer. The device is painful and side effects include tenderness and bruising at the site.

Further reading

Cohen, J.L., Ozog, D.M., and Porto, D.A. (2017). *Botulinum Toxins: Cosmetic and Clinical Applications*. Wiley.

Burgess, C. (2005). *Cosmetic Dermatology*. Springer.

CHAPTER 27

Wounds, Dressings, and Bandages

Bernadette Byrne

Tissue Viability, King's College Hospital, London, UK

OVERVIEW

- The physiology of normal wound healing can be optimised by the correct selection and application of appropriate dressings and/or bandage systems.
- Individualised holistic patient assessment including skin and wound is important for selecting the type of dressings required and treat any underlying causes.
- Understanding the properties and functions of different dressing categories is a prerequisite to enable the practitioner to make the most appropriate evidence-based choice for each wound type.
- Correct application of bandages is essential to ensure that they are at the correct tension to prevent slippage or cause damage around bony prominences.
- Patient choice and involvement in wound care leads to improved concordance essential to successful wound healing.
- A multidisciplinary approach is essential between all the healthcare practitioners caring for the patient's wound/skin.
- The patient's quality of life can be significantly improved by optimal wound care.

Introduction

Effective wound management relies heavily upon the selection of an appropriate dressing and an in-depth understanding of the normal physiology of wound healing. Wound dressings have developed in scientific standing over the years and the complexity of their action is reflected in the vast amount of money spent on their development to provide the most optimum evidence-based wound care; however, there are very few large randomised studies to support their use. Without effective wound assessment there is a risk of selecting an inappropriate product which can lead to delayed wound healing. This chapter provides a practical approach to wound management rather than a detailed look at the physiology of the wound healing process.

Wounds

A wound is a cut or break in continuity of any tissue caused by injury or operation, a wound may consist of a tear, incision, cut, erosion, puncture, or ulcer where the top layer of the skin is breached, if this occurs tissues are vulnerable to fluid, blood, and heat loss, allowing potential invasion of micro-organisms or foreign materials into the skin and possible loss of function.

Since the introduction of modern wound dressings such as Granuflex (1982) and Kaltostat Convatec (1986) the science of wound healing has progressed rapidly, and considerable advances have been made in the development of new products to enhance wound healing. This has led to an explosion of wound care products available both in hospital and primary care settings. While a greater choice of dressing products is beneficial to both the patient and the practitioner it can lead to confusion on which dressings to select for each individual wound as different wound dressings often having specific indications for use.

When assessing any wound there are multiple factors that need to be taken into consideration ([Figure 27.1](#)) in addition to the possible underlying aetiology (i.e. vascular disease), decisions on which product to apply are based on a full holistic assessment including short and long-term aims of treatment, patient's diagnosis and prognosis, whether the product is available and the cost.

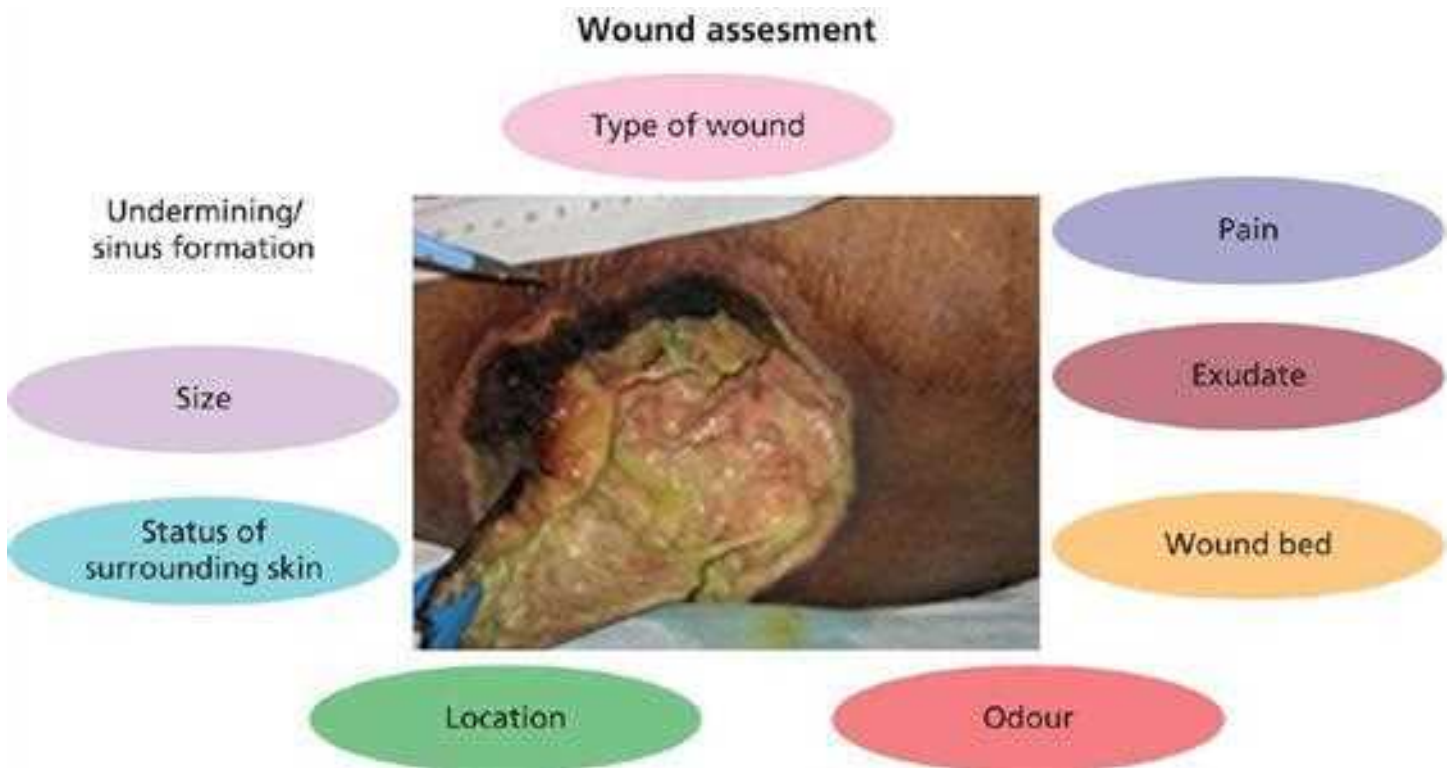


Figure 27.1 Wound assessment.

Principles of local wound management include achieving haemostasis, correct underlying causes, and reduce bioburden, removal of devitalised tissue if present, maintaining moisture balance, and protecting the surrounding skin.

Wound bed preparation

Achieving a healthy wound bed is a prerequisite to the use of many advanced wound care products. The aim of wound bed preparation is to optimise the wound healing environment by removing barriers, i.e. necrotic tissue, slough, exudate, and bioburden. Wound bed preparation in the management of the wound helps accelerate endogenous healing and/or facilitate the effectiveness of other therapeutic measures.

TIME: principles of wound bed preparation

| | |
|---|---|
| T | Tissue, non-viable, or deficient |
| I | Infection or inflammation |
| M | Moisture imbalance |
| E | Edge, epidermal margin, non-advancing, or undermining |

Source: Schultz et al. [2003](#)

Wound types

To manage wounds optimally they are classified into four different types according to the appearance of the wound bed and surrounding tissues. This is illustrated schematically by the wound healing continuum ([Figure 27.2](#)) and clinically in [Table 27.1](#) which characterises each wound type and an approach to their management.

1. *Necrotic wounds*. Dead (ischaemic) tissue is usually black, brown, or dark tan and covered with devitalised epidermis, a black wound indicates the presence of eschar (Bale [1997](#)).
2. *Sloughy wounds*. These are mostly yellow due to the accumulation of cellular debris, fibrin, serous exudate, leucocytes, and bacteria on the wound surface. Yellow fibrous tissue that adheres to the wound bed and cannot be removed by irrigation is known as slough (Tong [1999](#)).
3. *Granulating wounds* are characteristically bright red with a highly vascular nodular, irregular granular appearance. This is a combination of new blood vessel growth, connective tissue, or dermal cells (Grey et al. [2002](#)).
4. *Epithelialising wounds*. Cells migrate from the wound edges to start the process of re-epithelialisation/epidermal regrowth (Grey et al. [2002](#)) which is seen as pink translucent tissue in the wound bed.

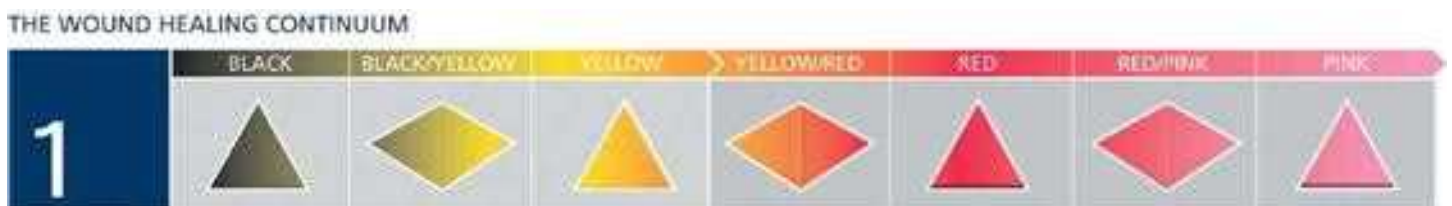







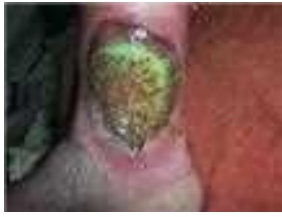Figure 27.2 The wound healing continuum is represented by the colour of the tissues in the wound (Grey et al. [2002](#)).

Table 27.1 Wound types and suitable dressings.

| Wound type | | Characteristics | Examples of suitable dressings |
|-----------------|---|---|---|
| Epithelialising |  | <p>Clean, superficial, low to medium exudate, pink in colour, can have white/translucent margins.</p> <p><i>Aim of dressing:</i></p> <p>Protection to allow further epithelialisation/maturation to occur</p> | <p>Low and non-adherent dressings knitted viscose Paraffin gauze Silicone-based products Film dressings</p> |
| Granulating |  | <p>Clean, low to medium exudate, bright red wound bed with granular, moist, nodular, and uneven appearance.</p> <p><i>Aim of dressing:</i></p> <p>To protect and encourage granulation tissue formation.</p> <p>Promote a moist wound healing environment</p> | <p>Alginates. Hydrofibre Hydrocolloids Foams Alginogels Hydrogels</p> |
| Sloughy |  | <p>Can range from dry to highly exuding.</p> <p>Characterised by fibrous sloughy tissue, yellowish in colour.</p> <p><i>Aims of dressing:</i></p> <p>Remove slough, encourage</p> | <p>Hydrogels Honey Alginates Hydrofibre Hydrocolloids Larvae Packing or ribbon forms of dressing required for</p> |

| | | | |
|-----------------|---|---|---|
| | | and facilitate a clean wound bed for the formation of granulation tissue | cavity wounds |
| Necrotic wounds |  | <p>Black, dry, eschar devitalised tissue, but can present as wet necrosis/gangrene.</p> <p><i>Aims of dressing:</i></p> <ul style="list-style-type: none"> Rehydrate eschar to encourage autolytic debridement if appropriate (not diabetic foot wounds) Manage exudate/actively debride if wet necrosis/infected. Not all wounds are debrided as dry eschar is a natural biological cover. | <p>Hydrogels (non-diabetic)</p> <p>Hydrocolloids (non-diabetic)</p> <p>Honey</p> <p>Sharp debridement by competent practitioner only (TVN or podiatrist)</p> <p>Surgical debridement</p> |
| Infected wounds |  | <p>Painful to touch, malodorous, greenish/yellow in appearance, friable granulation tissue (delicate, easily damaged) often have increased levels of exudates.</p> | <p>Suitable dressings are:</p> <p>Silver-impregnated dressings:</p> <ul style="list-style-type: none"> Silver alginates, hydrofibre, foams Iodine-based dressings Honey PHMBs Larvae |
| | | | |

Exuding wounds



Exuding wounds can appear anywhere on the wound healing continuum. However, increased exudate is often associated with wound infection. They often have per-wound skin that is shiny and white (wet and macerated).

Aims of dressing:

Effective exudate management skin care to encourage healing

Suitable dressings include:
Alginates
Hydrofibre
Foams
Super absorbants
Also require barrier protection of per-wound skin:
Cavilon[®]:
spray/applicators/cream
Sorbaderm[®]:
Spray/applicators/cream
NB: Check for sensitivities prior to application.

Wound-related factors to be considered in selecting an ideal dressing

- The type/aetiology of wound
- The size of the wound
- The location of the wound
- The stage of healing
- The tissue involved
- The amount, colour, and viscosity of exudates
- Wound odour
- The condition of the surrounding skin
- The patient's general health and environment
- Duration of the wound (acute or chronic)
- Long- and short-term aims of treatment

Key factors affecting wound healing

- Overall health and past medical history
- Cardiovascular status/circulatory disorders
- Disease processes e.g. diabetes and cancer
- Extremes of age (very young/very old)
- Psychological factors e.g. stress and anxiety, sleep disturbances
- Malnutrition
- Dehydration
- Smoking
- Drug therapy
- Mobility
- Poor wound management
- Surgical site infections
- Patient's prognosis.

Regardless of type any wound may be additionally infected or colonised by micro-organisms. If organisms proliferate within the wound an infection may develop causing a host reaction, this is characterised by pain, oedema, erythema, odour, increased or purulent exudate, abscess formation, and local heat.

The process of dressing selection is determined and influenced by a variety of clinical factors and what is available. However, we must also include patient-focused issues when making choices. Patients can have preconceived ideas about dressings from either past experiences, friends/family, media, and internet which may affect concordance with treatment.

Principles for selecting an ideal dressing

- To provide a moist environment to promote healing
- To absorb excess wound exudate
- To allow gaseous exchange
- To protect the wound from pathogenic organisms
- To protect the wound from trauma and contamination
- To minimise and contain odour
- To provide a constant wound interface temperature
- To be non-adherent and easily removed

- To be non-toxic, non-allergenic, and non-sensitising
- To reduce pain
- To promote autolytic debridement
- To protect the surrounding skin
- To cause minimum distress and discomfort during dressing change
- To improve the quality of life
- To be cosmetically acceptable to the patient
- Conformability of dressing
- To be cost-effective and available in hospitals and the community

Dressings

Modern dressings are described as either passive or interactive, depending on their composition and structure ([Figure 27.3](#), [Table 27.2](#)). Passive dressings are applied to protect the wound and designed not to stick to the wound bed, these are mostly used for surgical, clean healing and superficial wounds. Interactive dressings actively interact with the wound surface to promote an environment that maximises healing.

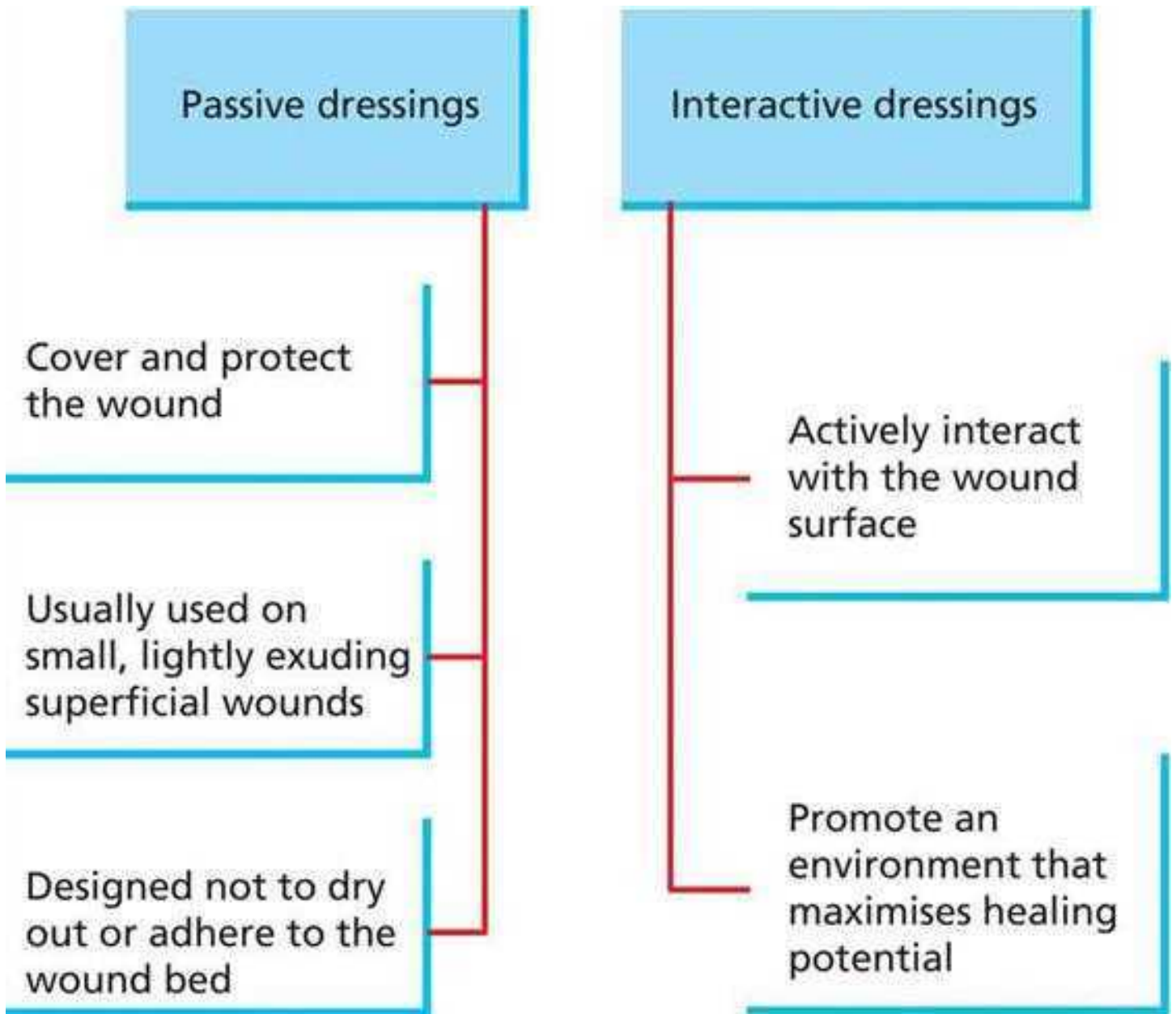


Figure 27.3 Types of wound dressings.

Table 27.2 Wound dressing categories.

| Passive dressings | Interactive dressings |
|--|-------------------------------|
| Non-adherent/non-adherent ultra | Films |
| Melolin [®] | Foams |
| Paraffin gauze | Hydrogels |
| Silicone dressing (Mepilex [®] , Silflex [®] , Adaptic [®] , Touch [®]) | Hydrocolloids/Lipido-colloids |
| Release [®] | Alginates |
| Post-op dressing film/fabric plus pad | Hydrofibres |
| Post-op dressing with silicone border | Odour-controlling |
| Post-op spray dressing (Opsite [®]) | Capillary action |
| | Antimicrobials |

Non- or low-adherent dressings

These are used for superficial, lightly exuding wounds. Their major function is to maintain a moist wound bed and allow exudate to pass through to a secondary dressing and reduce trauma at dressing change. Newer silicone-based dressings are the most effective but tend to be more expensive.

Examples include the following:

- Knitted viscose dressings with an open structure to facilitate the free passage of exudates (e.g. N/A & N/A ultra).
- Perforated film absorbent dressings. The film is perforated to allow the exudate into the absorbent layer (e.g. Melolin, Release).
- Silicone dressings. These are a conformable silicone-covered mesh which gently adheres to wound and surrounding skin but is designed to reduce pain and trauma on removal; the hydrophobic soft silicone layer feels sticky to touch but does not adhere to wound bed. It is nonabsorbent therefore a secondary absorbent dressing is required but self-adhesive with foam backing is also available (e.g. Mepitel[®], Adaptic, Silflex). Uses include donor sites, burns, epidermolysis bullosa patients and under NPWT (Negative pressure wound therapy).
- Paraffin tulle dressings consisting of an open-weave cotton or viscose and cotton-mix dressing impregnated in yellow or white soft paraffin (e.g. Jelonet[®]).

Film dressings

These consist of a thin film of polyurethane, permeable to water vapour and oxygen yet impermeable to water and micro-organisms, allowing gaseous exchange and reducing risk of bacterial contamination. Films are flexible and therefore suitable for difficult anatomical sites

such as across joints. They can be used on superficial wounds, donor sites, post-operative wounds, and as a secondary dressing for other products. These dressings are not recommended for deep, infected, or exuding wounds. Removal of these dressings can be traumatic to the surrounding skin and it is therefore recommended to follow the manufacturers' instructions and remove by the 'horizontal stretch' technique. Examples include Opsite, Tegaderm[®], Bioclusive[®], and C-View[®].

Hydrogel dressings

These consist of insoluble polymers which are hydrophilic and can absorb excess fluid or produce a moist environment at the wound surface. They can be used on dry, sloughy, and necrotic wounds which allow rehydration of devitalised tissue and facilitate autolysis. Hydrogel dressings may be suitable for pressure ulcers, leg ulcers, and surgical wounds; however, they should not be used for wounds producing high levels of exudate, where gangrene is present or on diabetic foot ulcers. Hydrogel dressings also come in a sheet format and usually require a secondary dressing to keep them in place. These dressings need to be changed every one to three days. Examples include Actiform cool (sheet), Intrasite gel[®], Intrasite conformable, Granugel[®], Purilon and Nugel[®].

Hydrocolloid dressings

These consist of a semi-permeable film with sodium carboxymethylcellulose plus gel-forming agents such as pectin and gelatin, which are waterproof, self-adhesive, and reported to reduce pain by keeping exposed nerve endings moist. They form a gel in contact with wound exudate to promote angiogenesis/stimulation of new blood vessels or rehydrate dry slough and necrosis. Hydrocolloids can be left in place for up to seven days, inappropriate use/too frequent dressing changes can lead to irritation and skin stripping. They should not be used to manage heavily exuding wounds, diabetic foot ulcers, and any wound infected with anaerobic organisms. Examples include Comfeel[®], Granuflex/duoderm extra-thin[®], and Tegaserb[®].

Lipido-colloid dressings

Composed of a polyester impregnated mesh with hydrocolloid and petroleum jelly particles, this promotes fibroblast proliferation. The dressing can be used for up to seven days on both flat and cavity wounds, its composition allows a pain-free, atraumatic removal and is available in a silver format. Examples are Urgotulle/Urgotulle SSD.

Hydrofibre dressings

These are composed of sodium carboxymethylcellulose (hydrocolloid fibres) which can absorb and retain significant amounts of exudate by vertical wicking, therefore reducing maceration of the wound margins. The fibres convert into a gel on contact with wound exudate and are suitable for wounds with moderate to heavy exudate, slough, and wet

necrosis. A secondary dressing is required to keep hydrofibre dressings in place. Dressing change should be undertaken every one to seven days depending on any underlying wound infection. Examples are Aquacel extra[®], Aquacel ribbon[®] and Aquacel Ag extra plus[®], Kerracel[®].

Alginate dressings

Dressings that are derived from alginic acid extracted from brown seaweed (Phaeophyceae family), the fibres create a hydrophilic gel in the presence of exudate. All alginates have the capacity to act as a haemostat, used on moderately exuding wound, and can be applied to infected wounds in silver format. Alginates must be applied dry and require a secondary dressing and should not be left in situ longer than seven days. They are also available in rope and ribbon for cavity wounds. Examples of pure calcium alginate include Sorbsan[®] and Algisite M[®]. Kaltostat[®] is a mixture of sodium and calcium salts (licensed haemostat).

Polyurethane foam dressings

These contain hydrophilic, absorbent polyurethane foam which is highly absorbent and are available in a variety of shapes and sizes and can be used as either a primary or secondary dressing. Foams can be used in a variety of wounds ranging from leg ulcers to cavity wounds from light to heavily exuding with the added advantage that they do not shed particles into the wound like traditional gauze. Their main function is to absorb exudate, allow moisture evaporation, maintain a high humidity at the wound interface, allow gaseous exchange, provide thermal insulation, and protect from bacterial contamination. Foam dressings are now available with a self-adhesive or silicone border. Examples include: Mepilex, Biatain[®], Lyofoam[®], Allevyn[®], and Tielle[®].

Antimicrobial dressings

Antimicrobial agents have been applied to wounds for thousands of years. They are defined as any substance that destroys microbes or prevents their growth and multiplication. The careful use of a range of antimicrobial dressings can successfully treat chronic/infected wounds and may omit the need for systemic antibiotics, which may be highly desirable with antibiotic stewardship and increasing levels of antibiotic resistance.

Silver has been used for many years as an antimicrobial agent for the treatment of burns in the form of sulfadiazine cream. New dressings impregnated with silver are available for a variety of wounds that are either colonised or infected. Examples include Actisorb Silver[®], Aquacel Ag extra plus, SilvaSorb[®] and Urgotul SSD[®], Sorbsan silver[®], Contreet[®], Acticoat[®], Kerracontact[®].

Iodine can lower bacterial growth in chronic wounds and is active against Gram-positive and negative organisms. Caution is required for patients with thyroid disease due to possible systemic uptake of iodine. Examples include Inadine[®] and Betadine[®], Cadexomer iodine[®]

(Iodoflex/iodosorb S&N[®]).

Metronidazole gel can be applied to infected wounds, particularly those colonised with anaerobic organisms. The gel helps with odour control and is especially useful in managing fungating malignant wounds.

Odour-controlling dressings

Charcoal dressings filter and absorb malodorous chemicals from wounds, they can be used as a primary or secondary dressing and they are indicated in all malodorous wounds. The activated charcoal loses its ability to absorb odours when it is saturated with exudate and therefore requires regular changing. Honey also has odour control properties. Examples include Actisorb[®], Clinisorb[®], and Kaltocarb[®].

Cavity dressings

Traditionally, cavity wounds were packed with ribbon gauze soaked in a variety of solutions (EUSOL[®], Betadine, proflavine) but these often dry out and cause trauma to wound on removal. Cavities are now therefore commonly dressed with alginate fibre or hydrofibre in the form of rope or ribbon. Cavity dressings fill the whole wound cavity preventing 'dead space' allowing the product to treat the whole wound including undermined areas and sinus's. This assists exudate management and allows the wound to heal by secondary intention, from the wound bed upwards. Examples include Aquacel ribbon, Allevyn Cavity[®], Kaltostat rope[®] and Sorbsan Ribbon[®], Honey ribbon and rope Algivon[®] plus Advancis medical[®] and NPWT; VAC/Renasys[®].

Larvae therapy

Larval therapy is the use of larvae of the greenbottle fly (*Lucillia seriata*) to remove sloughy and necrotic tissue ([Figure 27.4](#)) without damaging healthy granulation tissue. They have three main modes of action: debridement, antimicrobial, and facilitate healing (through secreting enzymes which liquefy the tissue, so it can be ingested). Indication for use include venous ulcers, diabetic foot ulcers, arterial ulcers, pressure ulcers, and wounds awaiting a graft as they can also prevent the wound re-sloughing after debridement. Subsequent applications may be required until granulation tissue has formed

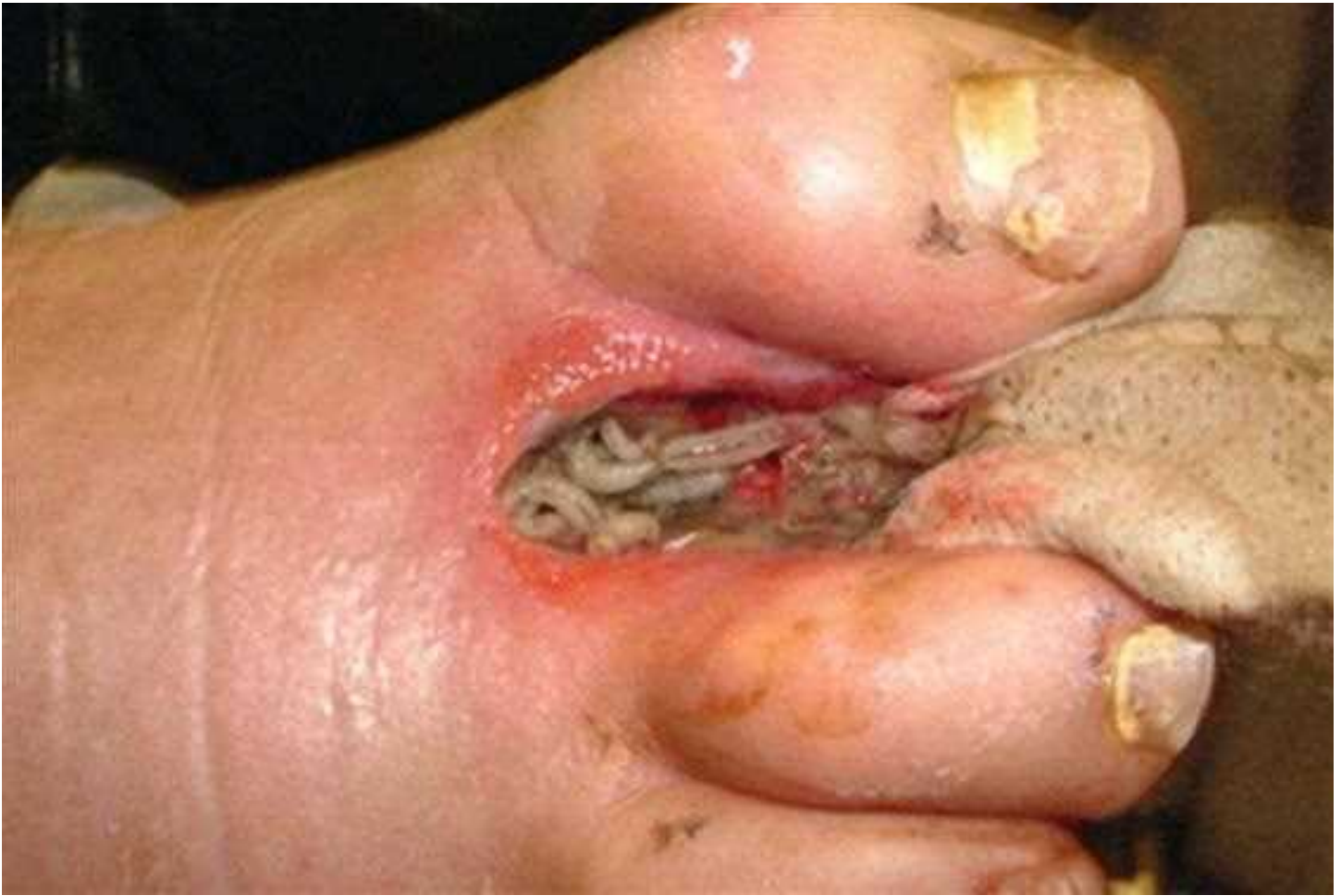

Figure 27.4 Larvae dressing in a second toe amputation site.

Maggots are available in both larvE[®] (free range), which are applied under a net or sleeve and can be left in the wound for three days, or BioFoam[®] (sealed in a net pouch with hydrophilic polyurethane foam pieces), which can be left for up to five days. These are easier to apply and remove as the larvae are contained. In the UK larvae are supplied by BioMonde[®] Bridgend, South Wales where they are bred under sterile conditions and dispatched by a courier. Maggots are contraindicated in patients with dysfunctional blood clotting, wounds that have a tendency to bleed, wounds with exposed major blood vessels or sinus/cavities where the wound bed is not visible.

Honey dressings

Honey is an ancient wound remedy first documented by Hippocrates in 460 BCE. It has a pH of 3.5, which is too acidic for micro-organisms to thrive; however, this can cause pain on application due to its acid mantle – it contains nutrients and herbal properties, amino acids, vitamins, and enzymes. Honey produces hydrogen peroxide enzymatically which is antibacterial. However, this is only 1000th of the concentration of the hydrogen peroxide solution formally used in wound cleansing. Honey has five key modes of action: antimicrobial, anti-inflammatory, provides a moist wound environment, desloughs/debrides devitalised tissue and deodorising/reduces malodour. Examples of honey dressings include

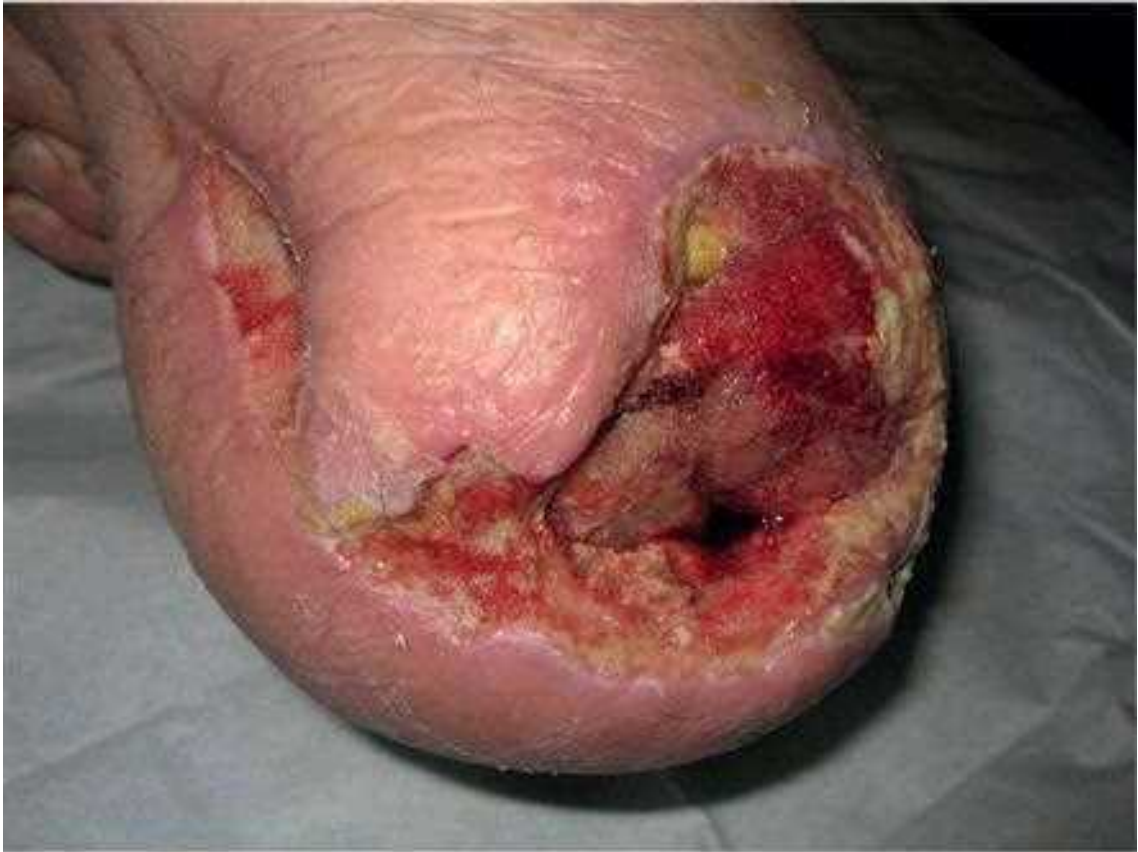Activon Honey Tulle[®] and Advancis[®], Activon tube[®], Algivon ribbon/rope[®], and Honey barrier cream.

Capillary action dressing

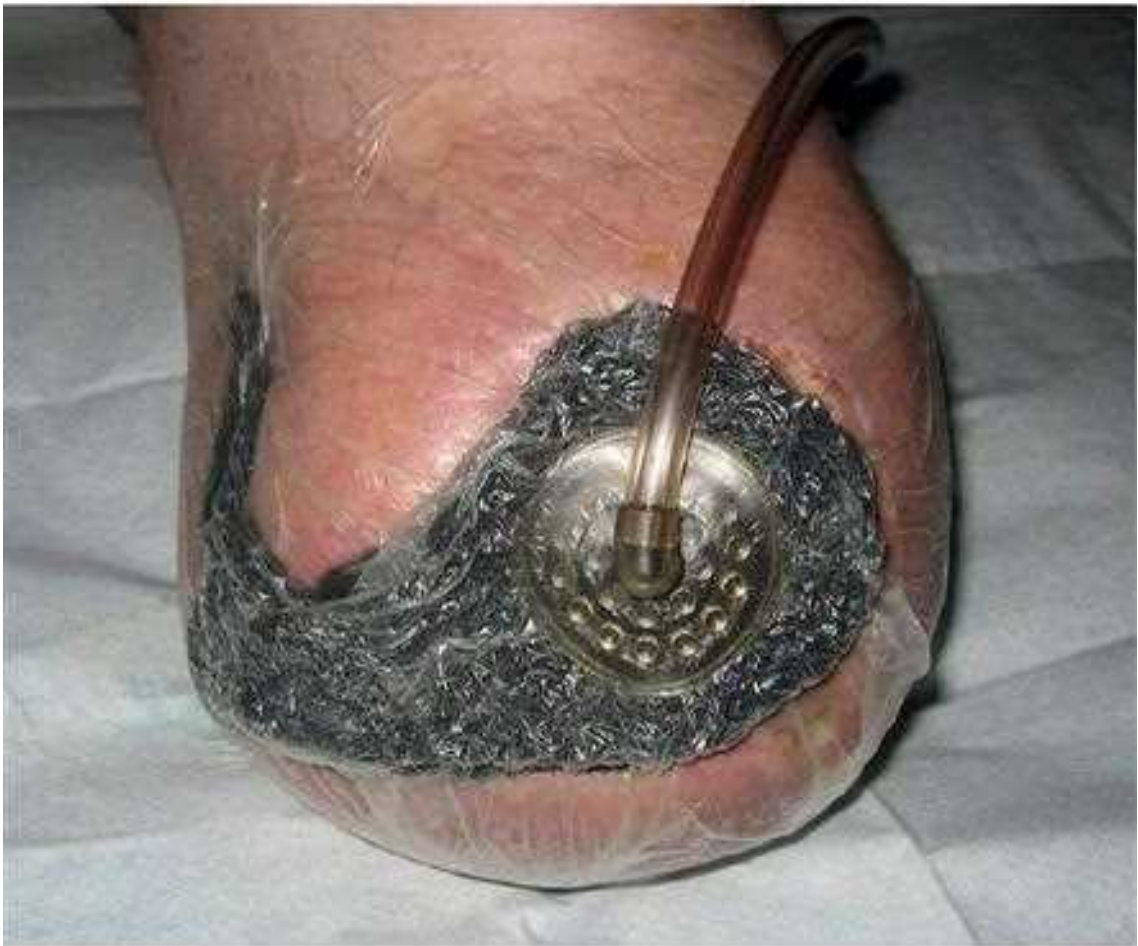An absorbent, low-adherent primary wound contact layer that has a wicking effect, this is made of soft viscose and polyester which are bonded together and backed with a perforated layer on each side (allowing it to be applied either way up). The accelerated capillary action 'pulls' interstitial fluid from the wound bed. Indications for use include acute and chronic wounds, sloughy, or cavity wounds with moderate to heavy exudate, initially dressings may need changing daily but can be left in place up to seven days. Contraindications are bleeding or fungating wounds. Examples include Avadraw[®], Advancis medical[®] is available in sheet or spiral wick form, which can both be cut to size.

Negative pressure wound therapy (NPWT) dressings

The first NPWT wound healing dressing was introduced in 1994 by KCI: the Vacuum-assisted wound closure (VAC). Recently several new devices have been introduced that also deliver NPWT. NPWT is a non-invasive active wound closure device that uses controlled, localised negative pressure to promote wound healing in both acute and chronic wounds ([Figure 27.5](#)). NPWT main modes of action are to: remove interstitial fluid, enhance dermal perfusion, stimulate granulation, help remove infectious material, provide a closed moist wound healing environment, promote flap survival, and improve graft uptake.



(a)



(b)

Figure 27.5 Negative pressure wound therapy (NPWT) dressings applied to a deep stump wound.

Indications for use include pressure ulcers, leg ulcers, diabetic foot ulcers, sinuses, acute/traumatic wounds, dehisced wounds, mesh grafts, and flaps. Contraindications include: malignant fungating wounds, active bleeding, exposed blood vessels/organs, untreated osteomyelitis, unexplored fistula, and necrotic eschar. These dressings must be applied by an experienced practitioner. Types of devices available are VAC[®], VAC Via[®] (single use), KCI; Renasys[®] and Pico[®] (single use) S&N; and Avance[®] Mollycke.

Super-absorbent dressings

These consist of ‘nappy gel’ technology, that absorb exudate away from the wound and retain gel beads inside, reducing the need for frequent dressing changes and maceration of wound margins. Examples include Eclypse/Eclypse adherent[®], Eclypse boot[®], Sorbion satches[®], Dry max extra[®], and Kerramax[®]. These types of dressings cannot be cut to size.

Alginogels

Enzyme alginogels are a new class of dressing which combine the benefits of hydrogels and alginates in an innovative wound care product, incorporating unique broad-spectrum antibacterial enzymes that are effective against a range of clinical isolates, including MRSA. They can either donate fluid to the wound or absorb excess exudate. Indications for use include: debriding, desloughing, and infected wounds but can be used on any wound type. Alginogels are biodegradable creating a soft and soothing wound interface thus reducing pain. Examples are Flaminal[®], Flaminal forte[®], and Crawford healthcare[®].

PHMB

Polyhexamethylene Biguanide (PHMB) is an antiseptic with a long history of use in cosmetics and is commercially used in wet wipes, contact lens solution, and swimming pools. It is thought to be non-irritant and non-toxic but can occasionally cause allergic contact dermatitis. PHMB is a broad-spectrum antimicrobial effective against aerobic and anaerobic bacteria, including MRSA, fungi, moulds, and yeasts. It is available in various formats including cleansing solution, wound gel, biocellulose, and foam dressings. Indications for use include second degree burns, leg ulcers, pressure ulcers, surgical wounds, diabetic foot ulcers, and donor and recipient sites. Examples: Suprasorb X[®] + PHMB available in sheet and rope for use in cavities, Prontosan[®] solution and Wound Gel[®] (B.Braun); AMD foam[®] (Kendal).

MMP

Matrix Metalloproteinase (MMP) plays a major role in cell proliferation and migration, wound contraction, and scar remodelling. However, chronically elevated MMPs can degrade

the extracellular matrix (ECM) proteins and prevent the wound from healing. MMP modulating dressings reduce excessive protease activity by absorbing the wound exudate and retaining the proteases within the dressing. MMP dressings provide a moist wound environment, reduce the bioburden and lower protease and free radical activity. Indications for use are chronic non-healing wounds; but currently there are no means to measure the amount of MMP activity in the wound, although devices are being evaluated at present. Examples include Promogran[®], Promogran Prisma[®] (containing silver) Systagenix[®]; Sorbion[®], H&R; Suprasorb C[®], Activa[®].

Adverse effects of dressings

- Maceration of the surrounding skin
- Irritant contact dermatitis
- Allergic contact dermatitis
- Skin stripping from frequent dressing changes.

Other therapies

Hyperbaric oxygen therapy. The use of O₂ at a level higher than atmospheric pressure, increasing the oxygen transported in plasma. There is no evidence to suggest it provides improved healing rates in chronic wounds than standard treatment.

Leeches. The saliva contains a thrombin inhibitor, they can be used reduce venous congestion following skin graft.

Versa-jet hydro surgical system. High-velocity water jet used for wound debridement.

Biological dressings. Consist of human or animal tissue used a temporary wound covering, often in treatment of burns or large areas of skin loss to prevent infection and fluid loss. i.e. Autograft, Allograft, Xenograft.

New products

Kytocel[®]: (Aspen medical)

Kytocel is an absorbent, gelling fibre dressing composed of natural chitosan fibres. Chitosan is a sugar that is derived from shrimp and crab shell waste which is known for its biodegradable and biocompatible properties. Other properties include: antimicrobial, analgesic, haemostatic, highly absorbent dressing for heavily exuding wounds with easy 'one piece' removal. Now available in sheets and ribbon format and currently being evaluated in clinical practice.

Skin substitutes (Nadine Hachach-Haram, Hawys Lloyd Hughes, and Koval Johal)

Wound healing is a complex process that relies on the dynamic interaction of growth factors, cellular interaction between individual cells and the components of the ECM. ECM consists of hyaluronic acid, proteoglycans, collagen, elastin, and fibronectin providing sound structural support and binding to growth factors which are necessary in wound healing. Recognising this role led to the development of dermal substitutes that could mimic the role of ECMs in damaged tissues, and provide further armamentarium for the reconstructive ladder with regards to wound care management

Skin substitutes and the replacement of skin defects has evolved considerably since the late 1800s when Reverdin first introduced skin grafting, Gamgee first described the use of cotton wool replacement of skin defects and Mangoldt described 'epithelial cell seeding' as a way of treating wounds. Further advancements developed in 1975 when Rheinwald and Green successfully grew human keratinocytes on lethally irradiated murine fibroblasts, paving the way for O'Conner and his group, in 1981, who used cultured autologous epithelium to cover burn defects for the first time. To construct a 'living' alternative, a dermal substitute based on type I collagen gel was now created with mesenchymal cells such as fibroblasts.

Commonly used skin substitutes

Tissue-engineered skin refers to a material made up of cells, ECM, or a combination of both. Skin substitutes can be classified into several types. Commonly used acellular skin substitutes in the management of wounds are described below.

Integra®

Integra is an acellular dermal matrix that can be applied as a dermal substitute in wounds and burns. The template consists of two layers: the upper layer is a silicone sheet that acts to protect the deeper layer that consists of a protein matrix. The thick under-layer is made of pure bovine (cow) collagen and a substance called glycosaminoglycan made from shark cartilage. Following debridement of a wound bed to healthy tissue, the Integra can be applied to the defect ([Figure 27.6](#)) and, providing the area has a good blood supply, is free of bacteria, and immobilised, a new blood supply enters the protein matrix. This allows the migration of cells, called fibroblasts, into the matrix. The fibroblasts will use the matrix as scaffolding to lay down new protein and eventually replace the matrix. The resultant structure is called a 'neodermis'. The protective silicone sheet can then be removed and replaced by a conventional, very thin skin graft. The advantage to applying this Integra two-stage reconstruction technique to a scarred area is that the reconstruction will be elastic and expand.

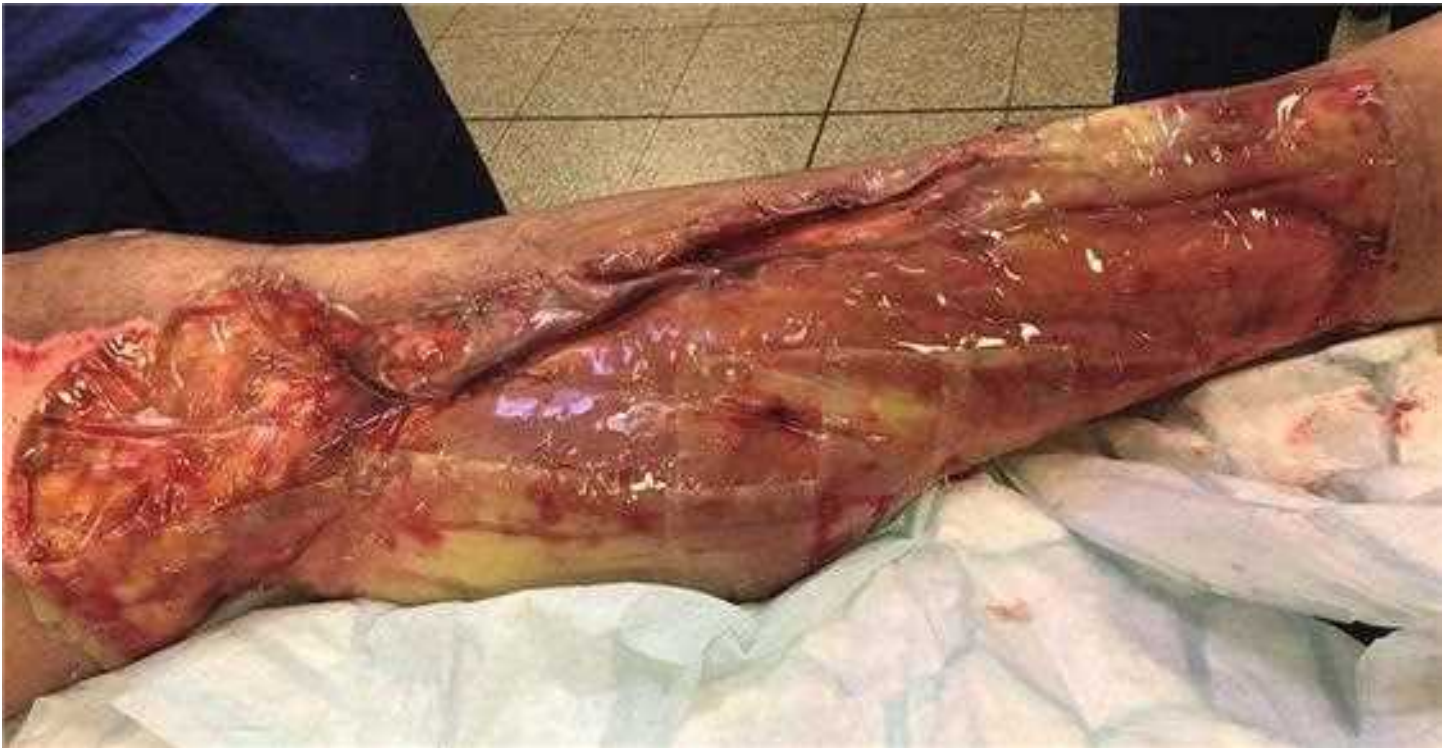

Figure 27.6 Integra skin substitute applied to lower leg wound.

Source: Courtesy of Miss V Rose, Consultant Plastic Surgeon, King's College Hospital.

MatriDerm[®]

MatriDerm is a structurally intact matrix of bovine type I collagen with elastin. Like Integra, it is utilised for dermal regeneration. Its application is indicated for the treatment of all deep dermal defects in combination with a split thickness skin graft (STSG), especially on functional, important anatomical areas like hands, feet, large joints, and face. It is used successfully in burns, trauma, and reconstructive wounds and surgical wounds post excision of skin cancer or congenital defects. One perceived benefit of MatriDerm is that it can be used as a one-step procedure – application and immediate grafting. This is more cost-effective than the two-stage application and can be more convenient for the patient. The wound bed must be clean and well-vascularised, free from infection or necrosis. Dry application of the MatriDerm is recommended. If more than one sheet of MatriDerm is used, the sheets should overlap by approximately 2–3 mm and then trimmed roughly to fit the skin defect. It is important to make sure that the MatriDerm evenly adheres to the wound bed and is rehydrated with a small amount of saline or Ringer's lactate. Iodine and enzymatic agents should be avoided. A STSG of 0.006 in. or 0.2 mm is recommended. Unmeshed graft shows best aesthetic results, but meshed graft can also be used. Direct contact must be achieved between the matrix and the skin graft. When there is poor vascularisation of the wound bed a two-stage procedure can be used, where the MatriDerm is placed initially, then a STSG one week later after the wound bed has been optimised. It is important here to avoid the MatriDerm drying out by maintaining a closed moist wound environment e.g. with a negative pressure wound therapy. Overall, MatriDerm permits a good graft take rate, with satisfying aesthetic and functional results. However, its indications may be limited by its cost and it is

important to recognise that there is a learning curve with its application.

Bandages

Bandages have been used for thousands of years, going back to the time of the ancient Egyptians, who applied woven fabric with considerable skill to mummify their dead. With the discovery of natural rubber in the mid-nineteenth century, the first elasticated bandages were produced for the management of varicose veins. These bandages were made of natural fibres through a weaving process as a simple retention bandage to provide support and protection.

Bandage application is a necessary skill required by most nursing and some medical practitioners during their working life. Therefore, it is essential that training in bandage application is adequate in order that bandages may be applied correctly and safely to patients. Poor bandage technique can lead to pain and discomfort for the patient, pressure damage over bony prominences, misshapen limbs, ridging, and exacerbation of pedal oedema. Bandage usage includes: compression therapy for venous leg ulcers, lymphodema, and chronic lymphodema, to retain dressings considering the location and size of wound, to support joints after a sprain, and to support a limb following soft tissue injury.

Definitions relating to bandaging

- *Extensibility* – the length produced when an extending force is applied.
- *Elasticity* – the ability to return to its original length once the extending force is removed.
- *Compression* – the force applied to produce a desired clinical effect.
- *Support* – the retention and control of tissue without the application of compression.
- *Conformability* – the ability to follow the contours of a limb, largely due to the extensibility and density of the fabric. Knitted bandages are more conformable than woven bandages.

Classification of bandages

Type I

Lightweight conforming bandages used for the retention of light dressings. These bandages should conform to limbs and joints without causing restriction. Examples are Slinky[®], J-fast[®], and Stayform[®].

Type II

Light support bandages are manufactured from cotton, polyamide, viscose, and elastane. They are used for the retention of dressings, mild support in the treatment of strains and sprains,

and to prevent oedema. They are not suitable for compression but can be used in the treatment of venous ulceration with arterial disease. Type II include crepe-type bandages such as Soffcrepe[®], Elastocrepe[®], Leukocrepe, and Comprilan[®].

Type III

Compression bandages are used to apply compression to control oedema and reduce swelling in the treatment of venous or lymphovenous disease of the lower limbs. They are subdivided into four categories (a–d) according to their ability to provide set levels of compression.

Type IIIa

Light compression bandages providing low levels of pressure up to 20 mmHg at the ankle. They are indicated in the management of early, superficial varices but are not suitable for controlling or reducing oedema. Examples include K-Plus[®], Tensolastic[®], and Elset[®].

Type IIIb

Moderate compression bandages may be used to manage varicosities during pregnancy, for the prevention/treatment of ulcers and for control of mild oedema. These exert levels of compression of 30 mmHg at the ankle.

Type IIIc

High-compression bandages may be used for applying 40 mmHg pressure at the ankle. These bandages can be used to manage large varices, leg ulcers, and limb oedema. Examples include Tensopress[®], Setopress[®], and Surepress[®].

Type III d

These extra-high-performance compression bandages apply 50 mmHg pressure at the ankle and therefore can sustain high pressure for extended periods to grossly oedematous limbs. Examples include Varico[®] and Elastic Web[®] bandage.

Tubular bandages

These are cotton bandages used extensively in dermatology in the treatment of atopic eczema and patients with erythroderma. They can be applied to limbs, cut and fashioned into a body suit, and used as dry or wet wraps.

Wet wraps are moist bandages applied to the body over emollients and/or topical steroids to acute active or chronic lichenified eczema. Wet wraps are cooling, reduce itching, prolong emollient effects, enhance topical steroid potency and protect the skin from trauma through scratching. Wet wraps are not indicated for long-term use with a topical steroid and should be avoided if the skin is infected.

Dry wraps are applied in a similar fashion to cover the skin. They enhance the effect of

topical agents and protect the skin and the patient's clothing.

Manufacturers are now producing cotton garments for the same purpose, making it easier for parents and patients to apply the materials and therefore manage skin disease. There is no evidence that silk garments have any additional benefit over cotton.

Medicated paste bandages

These bandages are made from flat open-weave cotton impregnated with appropriate medicaments. They are widely used in a variety of dermatological conditions such as venous ulceration, nodular prurigo, psoriasis, lichen simplex, and chronic lichenified eczema. They should be avoided if the skin is macerated or exudative. Paste bandages are used to soothe, occlude, protect the skin from scratching and enhance the effect of topical applications.

Examples include Calaband[®] (zinc paste with calamine), Tarband[®] (zinc paste with coal tar), Ichthaband[®] (zinc and ichthamol), and Steriband[®] (zinc paste bandage).

Medicated bandages need to be applied skilfully to prevent constriction and to allow for shrinkage and need to be changed when they are drying out. They require a secondary bandage to keep it in place and protect the patient's clothing. Hypersensitivity reactions can develop to the medicaments.

Application of bandages

The correct application of bandages is of paramount importance. Applied too loosely, the bandage will be ineffective and applied too tightly the bandage may cause constriction resulting in tissue damage and necrosis. In extreme cases this can lead to amputation. Research has shown that there is a great variation in the consistency of the tension in the application of bandages between practitioners. To overcome this problem, some bandages have a design printed on the bandage at regular intervals, which changes shape when the correct extension is applied.

Preparation for compression bandaging

1. Limb assessment to identify any deformities, oedema, and alteration of the limb contour which may need consideration when applying the bandage. Measure the ankle circumference to ensure that the correct compression bandages are used.
2. Wound assessment at baseline by measurements or photography to monitor progress.
3. *Dressings.* Appropriate, non-adherent, absorbent dressings to overcome exudate, odour, and pain.
4. *Pain assessment.* Eighty percent of patients with venous ulcers complain of pain which requires appropriate management to enable them to tolerate the compression.
5. *Patient preparation.* Patient understanding and commitment to compression therapy is vital to the success of the treatment and patient concordance.

6. High compression requires an ankle/brachial pressure index (ABPI) of more than 0.8.

The four-layer compression system for ankle circumference 18–25 cm ([Figure 27.7](#))

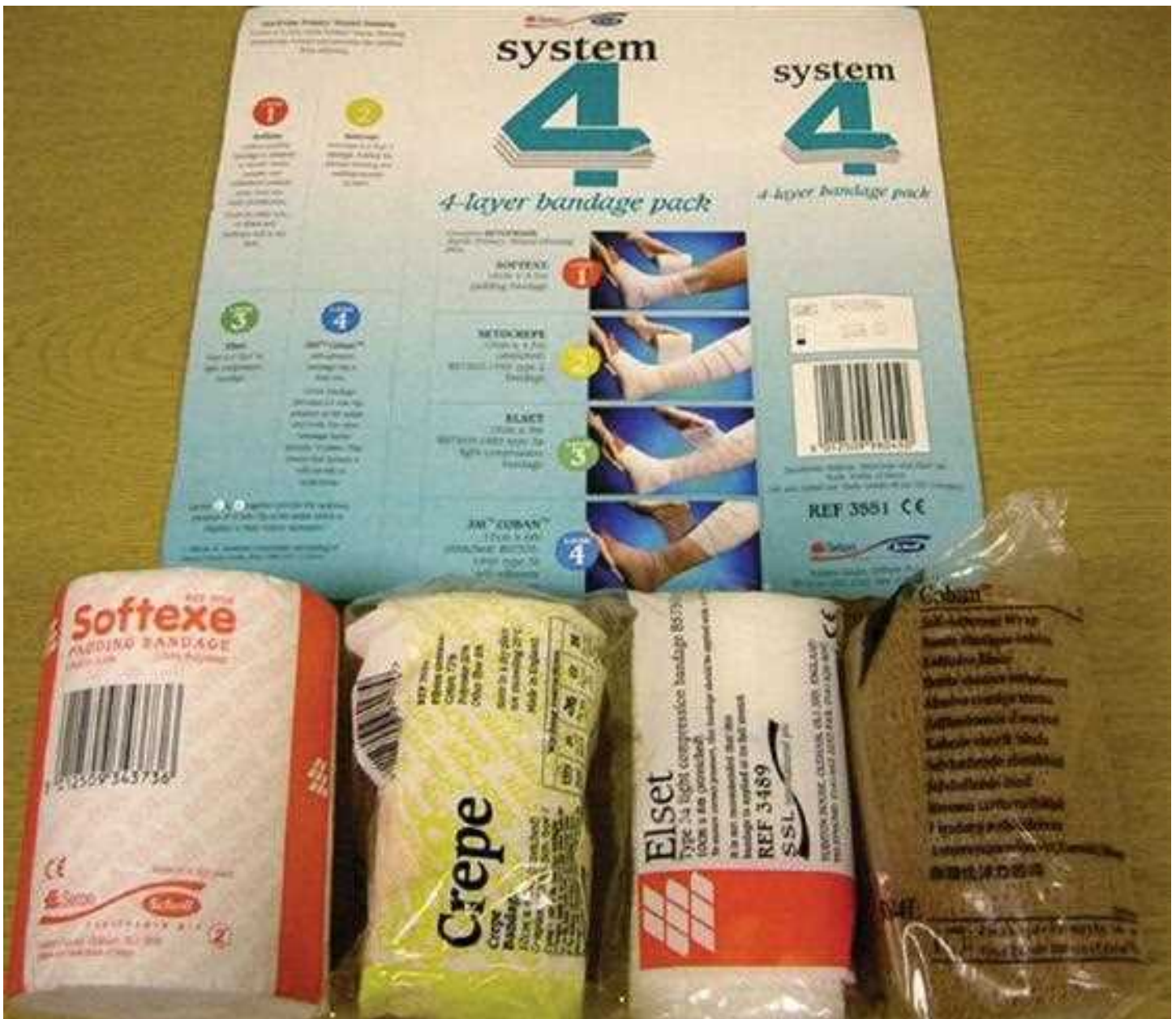

Figure 27.7 Example of a four-layer system.

Orthopaedic wool. The purpose is to absorb exudate, protect bony prominences, and redistribute the pressure around the limb. Apply from the base of the toes to the knee, overlapping 50%. Pad the tender areas on the dorsum of the foot, the Achilles tendon, and the shin.

Cotton crepe. This layer adds absorbency and smoothes the wool layer. Apply from the base of the toes, in even tension with 50% overlap to ensure a smooth surface for the application of the elastic layers.

Elastic, extensible bandage. The first compression layer with sub-bandage pressure of

17 mmHg at the ankle. Anchor the bandage at the base of the toes with two turns and 50% extension, continue with a 'figure of 8' around the ankle and extend up the limb with 50% overlap and 50% extension of the bandage.

Cohesive bandage. This is the second compression bandage of the system and adds the remaining 23 mmHg at the ankle to give 40 mmHg. The cohesiveness assists in the retention of the bandages. The bandage is applied in a spiral technique with 50% stretch and 50% overlap. In patients with 'champagne'-shaped legs, apply with a 'figure of 8' method to prevent slippage of the bandage.

Modifications

In patients with ankle circumference less than 18 cm and greater than 25 cm, the four-layer system can be modified to produce the correct pressure at the ankle as follows:

- where less than 18 cm, apply two or more layers of orthopaedic wool
- where 25–30 cm, use wool, a high-compression bandage, and cohesive bandage
- where more than 30 cm, wool, elastic-conformable, high-compression, and cohesive bandages can be used.

Two-layer compression ([Figure 27.8](#) and [27.9](#))



Figure 27.8 Example of a two-layer system with a foam bandage underneath.



Figure 27.9 Example of a different two-layer compression system with printed pressure indicators.

Two-layer bandage systems give equivalent compression to older four-layer systems

Coban[®]: 3M – Only available in one size

KTwo[®]: Urgo – available in two sizes: 18–25 cm and 25–32 cm.

Both consist of a wadding/inner comfort layer and a cohesive bandage providing 40 mmHg pressure

Application of two-layer

Coban: Foam inner comfort layer, applied with foam layer to skin maintaining enough tension to conform to shape of leg with minimal overlap. Outer cohesive layer is applied at 110% stretch and 50% overlap. Only the outer layer provides the 40 mmHg compression. Pros: More cost-effective than four-layer systems. Cons: The thick foam layer is difficult to conform around champagne bottle shaped legs.

KTwo: Wadding bandage gives up to 32 mmHg compression, short-stretch cohesive bandage gives 8 mmHg compression. Both bandages have a printed pressure indication on bandage to ensure correct bandage tension, it is applied spiral with 50% stretch and 50% overlap. Pros: Easy to apply, conforms to limb shape, better patient concordance, cost-effective and available in two sizes (latex-free option also available).

Two-layer long stretch bandages: class IIIc

Consists of soft ban wool bandage plus either:

Tensopress: Smith & Nephew

Ava-Co[®]: Advancis

Setopress: Molnlycke

Surepress: Convatec

All are applied spiral at 50% stretch and 50% overlap providing 40 mmHg compression

Two-layer short stretch bandages: class IIIc

Virtually inelastic, ridged which also consist of soft ban/wadding and either;

Actico[®]: Advansis

Comprilan[®]: BSn Medical

Rosidal K[®]: Activa, 100% cotton ideal for patients with a latex allergy

All are applied at 100% stretch and 50% overlap providing 40 mmHg compression.

Cons: Patients must be mobile to wear short stretch as it relies on action of calf muscle pump for venous return. Short stretch rapidly reduces oedema therefore bandage slippage is common requiring more frequent dressing changes.

Two-layer reduced bandage system

KTwo reduced compression kit which provides 20 mmHg compression. This also has a pressure indicator incorporated into bandage to ensure correct tension (as per regular KTwo kits).

Pros: Can be used on mixed aetiology leg ulcers depending on ABPI readings (also available as latex-free).

Rubber sensitivity

There is a continuing high incidence of contact sensitivity in patients with venous leg ulcers, which has implications for their management. Contact dermatitis to rubber limits the type of compression bandages that can be used. Cotton short-stretch bandages are recommended for these patients. Apply a tubular cotton gauze bandage directly to the skin. Next apply the wool layer as before and then the short stretch at full extension with a figure of 8 around the ankle and continue with a spiral overlapping 50% at full extension up the leg.

Patient information

Patient agreement is as vital to wound healing as the dressings and bandages themselves. To ensure that the patient complies adequately with their wound management the following should be considered.

- Ensure that the patient understands their treatment regime.
- Devise a treatment plan to suit the patient's lifestyle.
- Provide an information leaflet explaining aftercare.

- Peripheral circulation to the toes should be checked after application of bandages.
- In the event of excessive pain or discomfort caused by the bandages patients should be advised to contact the treatment unit.
- Patients should be advised not to be alarmed by breakthrough exudates.
- Bandages should be kept dry by providing aids to use in the bath/shower.
- Encourage a good balance between rest and exercise.
- Advise patients not to remove bandages themselves.
- Provide the patient with a contact telephone number to ring for advice.

The efficacy of dressings and bandages to heal wounds and treat skin complaints depends on selection of the correct products for the particular situation. Ideally there should be good channels of communication and clinical consistency between primary/secondary care and wound management specialists. Teamwork should ensure the optimum management of the patient's skin, promote rapid healing, provide an excellent local service, reduce the cost of wound care and enhance the patient's quality of life.

References

- Bale, S. (1997). A guide to wound debridement. *Journal of Wound Care* 6: 179–182.
- Grey, D. et al. (2002). The wound healing continuum. *Community Nursing* 7 (supp 4): 15–19.
- Schultz, G.S., Sibbald, R.G., Falanga, V. et al. (2003). Wound bed preparation: a systematic approach to wound management. *Wound Repair and Regeneration* 11: 1–28.
- Tong, A. (1999). The identification and treatment of slough. *Journal of Wound Care* 8 (7): 338–339.

Further reading

- Charles, H. (2004). Does leg ulcer treatment improve patients' quality of life? *Journal of Wound Care* 13 (6): 209–213.
- Flanaga, M. (2013). *Wound Healing and Skin Integrity Principles and Practice*. Wiley-Blackwell.
- Jones, V., Grey, J.E., and Harding, K. (2006). ABC of wound healing: wound dressings. *BMJ* 332: 777–780.
- Moffat, C. (1997). Know how. Four-layer bandaging. *Nursing Times* 93 (16): 82–83.
- Moura, D., Mano, J.F., Paiva, M.C., and Natalia, M. (2016). Chitosan nanocomposites for biomedical applications. *Science and Technology of Advanced Materials* 17 (1): 626.

Myers, B.A. (2004). *Wound Management: Principles and Practice*, 2e. New Jersey: Pearson/Prentice Hall.

Novak, A., Khan, W.S., and Palmer, J. (2014). Evidence-based principles of NPWT in trauma and orthopaedics. *Open Orthopaedic Journal* 8: 168–177.

www.worldwidewounds.com

www.ewma.org (European wound management association)

www.etrso.org (European tissue repair society)

<http://www.wounds-uk.com>

www.tvs.org.uk

www.woundcaresociety.org

CHAPTER 28

Formulary

Karen Watson¹ and Aisling Ryan²

¹ Orpington, Kent, UK

² King's College Hospital, London, UK

OVERVIEW

- Many treatments for the skin are topical, meaning they are applied directly to the skin surface.
- Different formulations of topical treatments are used depending on the site and the type of skin disease.
- Medicated topical treatments should be applied to the diseased skin and emollients are applied all over.
- Systemic therapies are generally used for more severe disease and need careful monitoring.
- Biological therapies have transformed the treatment of some skin diseases, they are delivered intermittently by injection or infusion.

Introduction

Modern dermatology treatment continues to be dominated by the use of traditional topical therapy. However, there is an increased emphasis on injectable biological therapies targeting specific inflammatory pathways.

Topical therapy

The skin has the advantage of being readily amenable to treatment with topical therapy. Relatively high concentrations of medication can be applied to the skin safely, with good efficacy and comparatively few side effects. Several factors govern the choice of topical treatment, such as formulation, frequency of application, site and severity of skin disease and patient preference and ability to apply local therapy. Complications tend to be local irritant or allergic reactions. The choice of topical treatment depends on the disease process, pharmaceutical properties of the drug, site of application and cosmesis.

Emollients

Emollients are important in the treatment of dry, scaly, and inflammatory skin conditions as they help reduce transepidermal water loss from a damaged epidermal barrier. They soften dry skin by filling in the spaces left by desquamating keratinocytes. There is even some evidence pointing towards emollients applied daily to a baby's skin from birth possibly preventing atopic eczema.

The constituents of an emollient or topical base have significant properties. Lipids, for example, cover the stratum corneum to prevent evaporation of water. White and yellow soft paraffin and liquid paraffin are extracted from crude oil. They are stable, inert hydrocarbons, which form the basis of most commercially available ointments and emollients. Emulsifying agents are used to stabilise emulsions, which are immiscible mixtures of aqueous and oily constituents, and penetration enhancers, such as urea and propylene glycol, may be used to increase penetration of an active component through the skin. Humectants are compounds with a high affinity for water, which can draw water into the stratum corneum and have useful emollient properties.

The properties of various formulations of topical therapy are outlined in [Table 28.1](#). Emollients can be applied liberally and regularly to all areas of dry skin.

Table 28.1 Comparison of formulations for topical therapy.

| Formulation | Characteristics | Advantages | Disadvantages |
|--------------------|--|--|--|
| Ointments | Oil-based. Provide occlusive film over skin and help retain water. Aid skin hydration and penetration of topical treatment | Tend not to require preservatives as lack of water in preparation prevents microbial growth | Greasy and cosmetically less appealing to use |
| Creams | Emulsions containing water and oil. May be composed of oil in water or water in oil (oily creams). Aid skin hydration, but generally less effectively than ointments | Cosmetically acceptable | Contain preservatives, which may cause sensitisation |
| Lotions | Watery suspensions, often containing alcohol | Easily spread over a large area. Evaporation of water or alcohol has a drying, cooling effect Cosmetically acceptable Useful for hair-bearing areas, such as the scalp | Contain preservatives and therefore have sensitising potential. Alcohol may cause stinging |
| Gels | Semisolid emulsion in alcohol base. Useful for suspending insoluble drugs Good absorbent properties | Tend to dry on skin Useful for hair-bearing areas. Cosmetically acceptable especially for use on the face | Relatively high irritant and sensitising potential |

Moisturising soap substitutes applied to the skin and washed off are an important part of managing inflammatory skin disease, as regular soaps are irritant detergents that remove intercellular lipids and disrupt the barrier function of the stratum corneum.

Topical immunomodulatory treatments

Topical corticosteroids

Mode of action

Topical corticosteroids have been used to treat a wide range of inflammatory dermatoses since the 1950s. Steroid diffuses through the stratum corneum, cell membrane and into the cytoplasm of keratinocytes where it binds to the glucocorticoid receptor causing activation. The ligand-bound receptor enters the nuclear compartment and interacts with glucocorticoid response elements (GREs), resulting in the modulation of gene transcription. In addition, the ligand-bound receptor may also inhibit other transcription factors. The overall effect is to suppress inflammatory cytokines, inhibit T-cell activation, and reduce cell proliferation.

Classification of topical steroids

Topical corticosteroids are classified according to their potency, which is thought to be related to their glucocorticoid receptor affinity.

Topical steroids are divided into four classes:

Class 1 Super-potent (600 times as potent as hydrocortisone): for example, clobetasone propionate (Dermovate®) and mometasone (Elocon®).

Class 2 Potent (150 times as potent as hydrocortisone): for example, betamethasone valerate (Betnovate®).

Class 3 Moderate (25 times as potent as hydrocortisone): for example, clobetasone butyrate (Eumovate®).

Class 4 Mild – hydrocortisone.

This classification allows determination of the relative strength and therefore the efficacy and potential side effects of therapy. Generally, the weakest steroid to effectively treat the skin condition should be chosen. Milder steroids should be used on the face and flexural sites ([Table 28.2](#) provides a detailed outline of topical steroids and their relative potencies).

Table 28.2 Relative potency of topical corticosteroids.

| Generic name | Proprietary name | Potency |
|---|---------------------------|----------------|
| 1% hydrocortisone | Efcortelan [®] | Mild |
| 1% hydrocortisone acetate and 1% fusidic acid | Fucidin H [®] | Mild |
| 1% hydrocortisone, 1% nystatin 100 000 units/g and 3% oxytetracycline | Timodine [®] | Mild |
| Clobetasone butyrate 0.05% | Eumovate | Moderate |
| Alclometasone dipropionate 0.05% | Modrasone [®] | Moderate |
| Betamethasone valerate 0.1% | Betnovate | Potent |
| Mometasone furoate 0.1% | Elocon | Potent |
| Diflucortolone valerate 0.1% | Nerisone [®] | Potent |
| Betamethasone dipropionate 0.05% and 3% salicylic acid | Diprosalic [®] | Potent |
| Betamethasone valerate 0.1% and fusidic acid 3% | Fucibet [®] | Potent |
| Clobetasol propionate 0.05% | Dermovate | Super-potent |
| Clobetasol propionate 0.05%, neomycin sulfate 0.5% and nystatin 100 000 units/g | Dermovate NN [®] | Super-potent |

Topical corticosteroids should be applied ‘sparingly’. However, this is difficult to define and therefore the finger-tip unit (FTU) system was devised. One FTU (a line of ointment from the tip of the finger to the first skin crease) is enough steroid to treat a hand-sized (palmar and dorsal surface) area of affected skin. This assumes a 5 mm nozzle and equates to 0.5 g of ointment/cream. In medical practice, it is common for patients to use insufficient amounts of topical steroids due to the fear of potential complications.

Side effects of topical steroids

- Skin atrophy ([Figure 28.3](#))
- Telangiectasia
- Striae ([Figure 28.1](#))
- Ecchymosis
- Hirsutism
- Folliculitis
- Perioral and periorbital dermatitis ([Figure 28.2](#))
- Steroid-induced acne/rosacea ([Figure 28.3](#))

- Absorption and suppression of the hypothalamic pituitary axis (HPA)

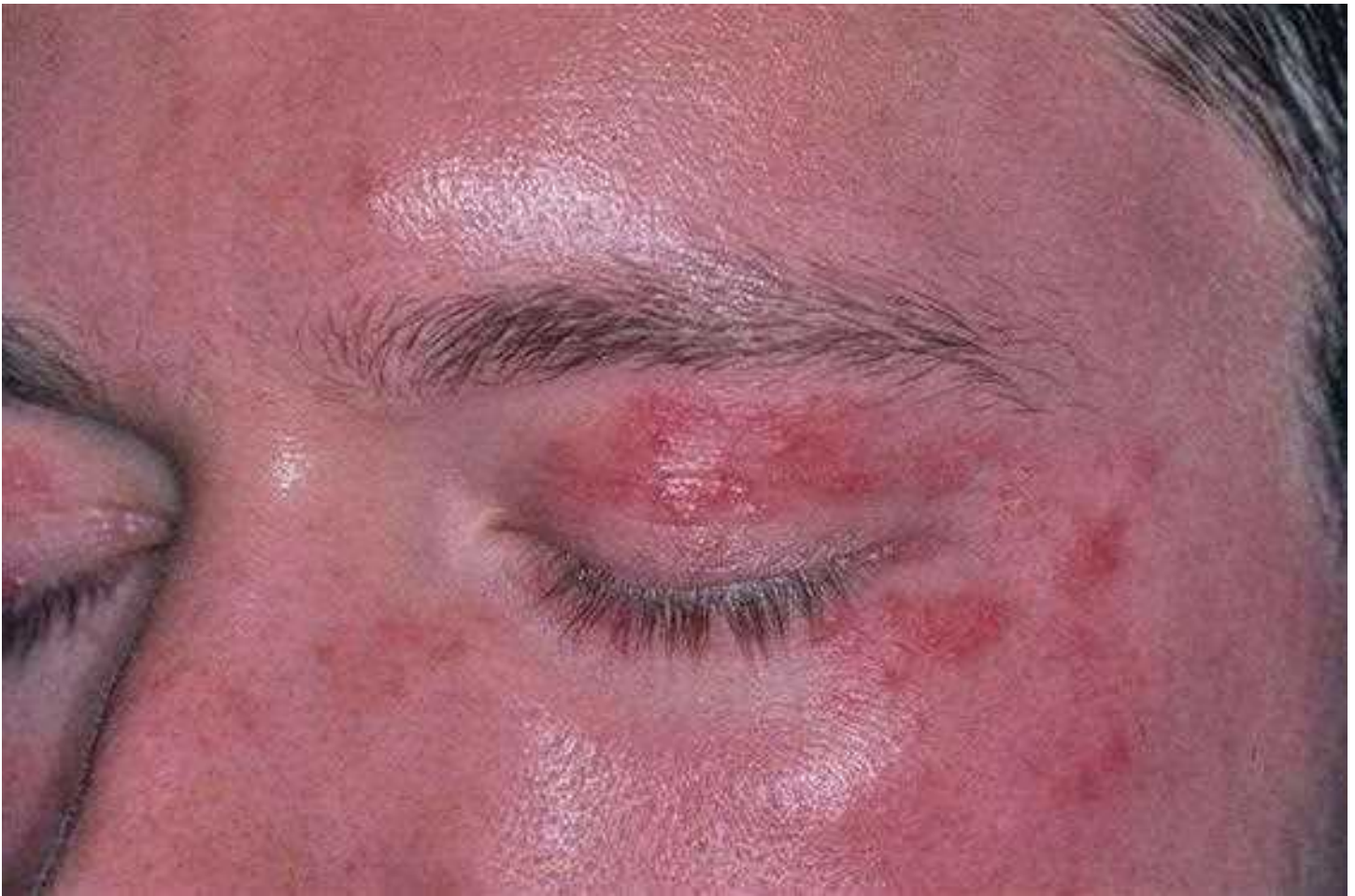

Figure 28.1 Liberal application of a potent topical steroid resulting in striae formation.

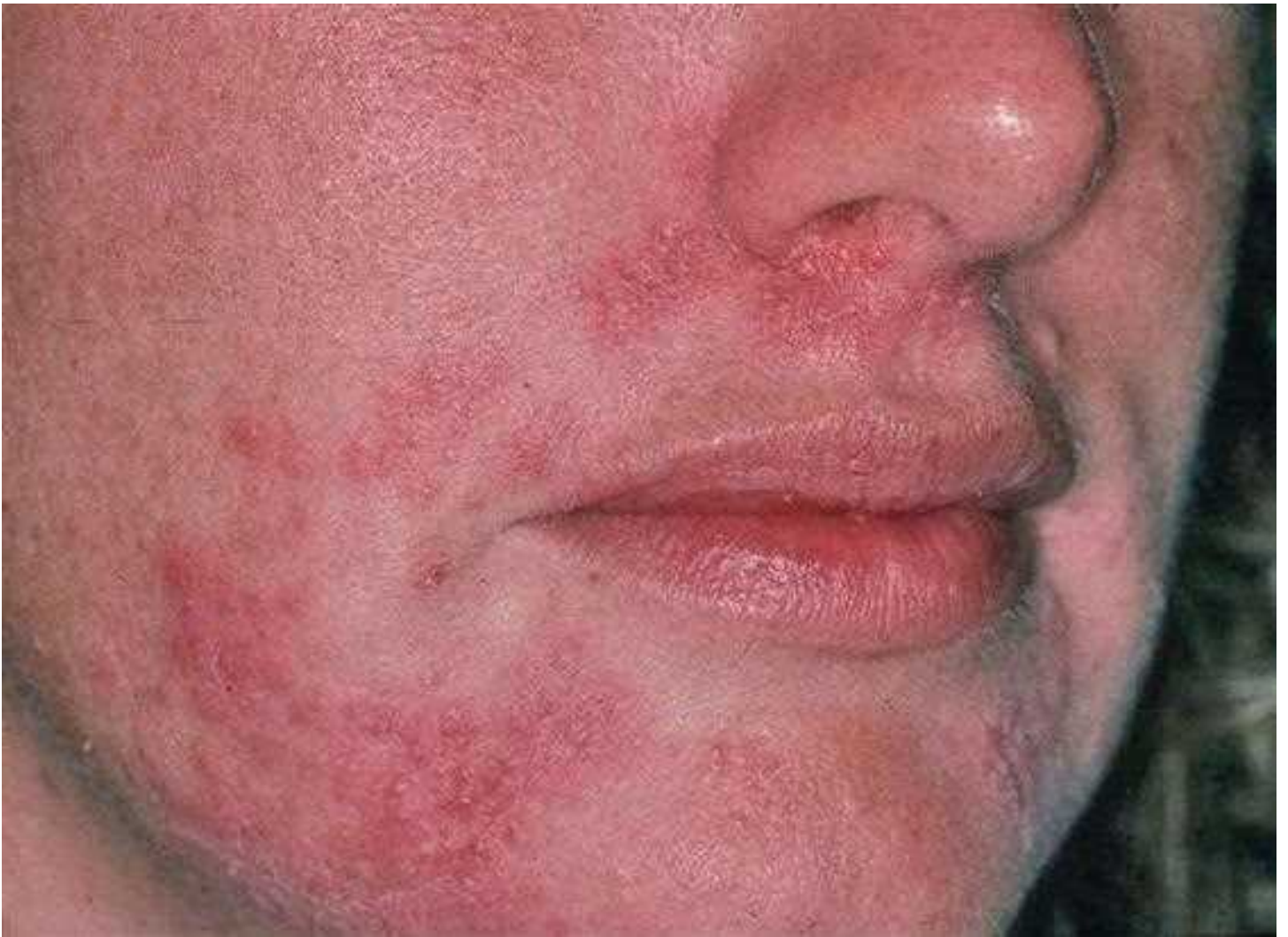

Figure 28.2 Perioral dermatitis caused by local application of topical steroids.

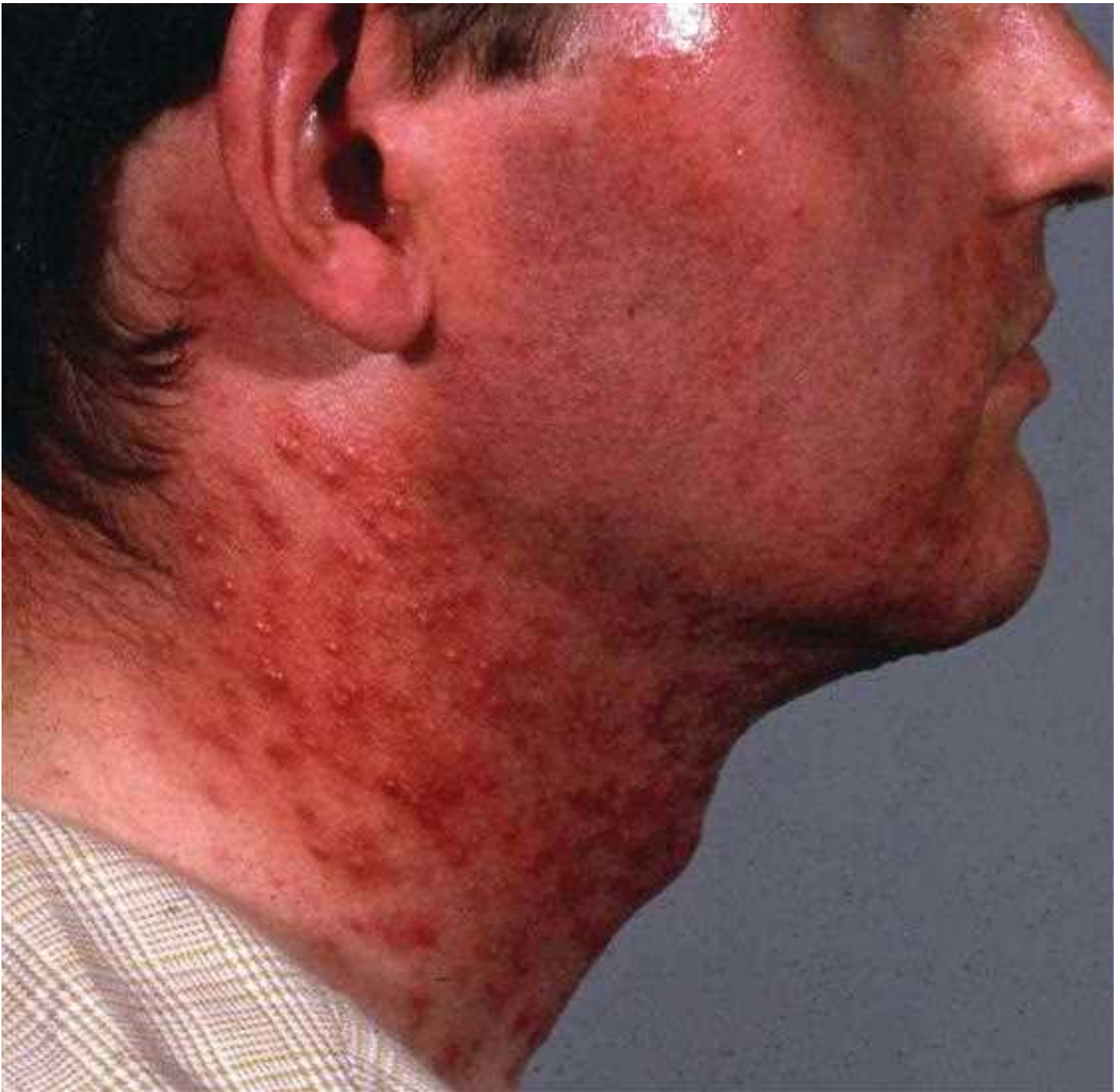

Figure 28.3 Potent topical steroid-induced atrophy and acne.

Calcineurin inhibitors

Topical tacrolimus (ointment) and pimecrolimus (cream) were originally developed for the treatment of eczema (in patients over the age of two years). These agents inhibit calcineurin (a calcium and calmodulin-dependent serine/threonine phosphatase) and suppress T-cell activation. Topical tacrolimus has also been used to treat alopecia areata, oral and genital lichen planus, and vitiligo, with varying degrees of success. Pimecrolimus is less potent than topical tacrolimus and is used predominantly in the treatment of eczema in children as a steroid-sparing agent.

Topical antimicrobials

Several topical antimicrobial preparations are available, some of which are summarised in [Table 28.3](#).

Table 28.3 Topical antimicrobials used in the treatment of superficial infections.

| | Preparation | Indications | Weaknesses |
|---|--|--|---|
| Topical antibiotics | Fusidic acid (Fucidin ointment [®]) Mupirocin (Bactroban ointment [®]) Silver sulfadiazine (Flamazine [®]) | Staphylococcal infections Gram-positive and some gram-negative organisms Treatment of nasal staphylococcal carriage Pseudomonal infection and some prophylaxis against staphylococcal infection | Resistance Resistance Minimal absorption and renal impairment when applied to extensive burns |
| Topical antibiotics used in the treatment of acne | Tetracyclines Erythromycin Clindamycin | Acne May be used in combination with keratolytics such as benzoyl peroxide | Resistance May stain clothing yellow |
| Topical antifungals | Allylamines Terbinafine cream (Lamasil cream [®]) | Fungicidal against dermatophyte infections | Ineffective against dermatophyte infections of the nails and scalp |
| | Imidazoles Clotrimazole (Canesten [®]) Econazole Ketoconazole Miconazole Tioconazole | Fungistatic Active against <i>Candida</i> and <i>Pityrosporum</i> May be used in combination with topical steroids Used in the treatment of intertrigo, pityriasis versicolor, and some dermatophyte infections | Concurrent use of topical steroid may mask infection |
| | Amorolfine (Loceryl lacquer [®]) | Fungistatic Used in the treatment of onychomycosis Some activity against <i>Scytalidium</i> Synergistic activity with systemic antifungals | Poor cure rates in dermatophyte infections affecting the nail matrix when used as sole therapy |
| Topical antivirals | Aciclovir cream | Used to treat labial and genital herpes simplex | Needs to be applied as early as possible in the episode for |

| | | | |
|--------------------------|--|---|---|
| | (Zovirax®) Penciclovir cream (Denavir®) | | maximum benefit |
| Anti-parasitic agents | Permethrin Malathion Ivermectin | 5% cream used in the treatment of scabies and pubic lice. 1% rinse used to treat head lice Used in the treatment of scabies, head lice, and pubic lice 1% cream used to treat rosacea, cutaneous larva migrans | Require two treatments one week apart Alcoholic lotions can irritate skin and can exacerbate eczema |

Miscellaneous topical therapy used in the treatment of psoriasis

These are outlined in [Table 28.4](#).

Table 28.4 Miscellaneous preparations used in the treatment of psoriasis.

| Preparation | Mode of action | Indications | Complications |
|--|--|--|---|
| Crude coal tar and coal tar solution | Unclear | Psoriasis | Messy to use |
| Derived from the distillation of organic matter | Tar has anti-proliferative effects on the epidermis | Used in combination with ultraviolet radiation with additive effects | Potent odour Scrotal squamous cell carcinoma |
| Dithranol | Unclear | Psoriasis | Local reactions and irritation of normal surrounding skin |
| Available in cream formulation or in Lassar's paste in concentrations from 0.1% to 3% | Dithranol has potent anti-proliferative effects | Short contact regimens used in outpatient settings | Skin staining |
| Vitamin D3 analogues: Calcipotriol (Dovonex [®]), and tacalcitol (Silkis [®]) Combination of calcipotriol and betamethasone (Dovobet [®] gel and Enstilar [®] spray) | Regulate cell growth, differentiation, and immune function | Psoriasis | Hypercalcaemia Irritation Prolonged use of betamethasone and calcipotriol may precipitate the formation of pustules on withdrawal |

Topical anti-proliferative agents

Topical 5 fluorouracil

5 fluorouracil (5% cream, 0.5% solution) is an antimetabolite, which blocks DNA synthesis by inhibiting thymidylate synthetase. It is used topically to treat actinic keratoses, Bowen's disease, and superficial basal cell carcinomas (BCCs). Treatment should be applied daily for four to six weeks. Main adverse effects include local erythema and irritation and, with continuous use, marked inflammation and erosions. These adverse effects may be ameliorated by treatment breaks and use of topical steroids.

Topical diclofenac

Diclofenac is a non-steroidal anti-inflammatory drug available in a 3% gel formulation for the treatment of mild actinic keratoses. The mechanism of action is unclear. It is generally

well tolerated, although there may be some localised inflammation.

Topical imiquimod

Topical imiquimod (5% and 3.75% cream) is an immunomodulatory preparation, used to treat genital warts, vulval intra-epithelial neoplasia (VIN), extra-mammary Paget's disease, actinic keratoses, superficial BCCs, and lentigo maligna. It stimulates the innate immune system and promotes the development of antigen-specific cell-mediated responses via Toll-like receptor 7. It causes considerable inflammation with oedema, erosions, and occasional ulceration. It is usually applied three times weekly for up to four months, depending on the indication.

Topical ingenol mebutate

Ingenol mebutate is derived from the plant *Euphorbia peplus*, which is grown in Queensland specifically to produce this gel, used for the treatment of actinic keratoses. The mechanism of action is unclear, but it appears to cause rapid lesion necrosis and neutrophil-mediated antibody-dependent cellular cytotoxicity. It is applied for two to three days depending on the site and may cause discomfort and irritation.

Miscellaneous agents

Keratolytics

Keratolytic agents are topical preparations used in the treatment of hyperkeratosis and acne. They help soften the skin and aid the removal of scale. They may also have anti-comedogenic activity, although they can cause local irritation with erythema and dryness. Examples include salicylic acid and vitamin A derivatives such as tretinoin and adapalene.

Sunscreens

The aim of sunscreens is to block both ultraviolet A (UVA) and ultraviolet B (UVB) penetration of the skin and thereby inhibit the ageing and carcinogenic effects of ultraviolet (UV) radiation. Compounds used to achieve sun protection may either reflect and scatter UV light or absorb it. Examples of physical agents blocking UV include zinc oxide, titanium dioxide, and ferrous oxide. They tend to be used in combination with light absorbers such as *para*-aminobenzoic acid (PABA) and benzophenones. The sun protection factor (SPF) of a sunscreen is an indication of the level of protection from UVB. An SPF over 15 is considered to confer good UVB protection when the sunscreen is applied adequately; however, evidence suggests most people apply insufficient amounts. UVA protection is measured on a 1–5-star basis although there is little standardisation. Therefore, high factor sunscreen with UVA and UVB protection should be applied to exposed skin before going out in the sun, and this should be reapplied regularly to maintain protection.

Cosmetic camouflage

Cosmetic camouflage plays an important role in the treatment of patients with disfiguring conditions such as scarring, dyspigmentation, and port wine stains. Proprietary preparations are readily available (e.g. VitiColor®, Dermablend®) and the charity Changing Faces provides a volunteer-led skin camouflage service for patients in the United Kingdom (www.changingfaces.org.uk).

Phototherapy

Phototherapy (see [Chapter 3](#)) is the treatment of skin disease with UV radiation alone and photochemotherapy is UV irradiation in combination with psoralen ultraviolet A (PUVA). Both are used extensively in dermatological practice to treat a wide range of skin disorders. Phototherapy involves the use of artificial UVB irradiation delivered by fluorescent lamps. UVB consists of electromagnetic energy of wavelength 290–320 nm and represents that part of the spectrum that is largely responsible for sunburn. UVA consists of energy of wavelength 315–400 nm. Both PUVA and narrow-band UVB phototherapy are now widely used for the treatment of psoriasis, atopic eczema, polymorphic light eruption, mycosis fungoides, and vitiligo, among others.

Systemic therapy

Drugs used for infectious disorders

Antibacterial drugs

Antibiotics are used widely in dermatology for a range of conditions from acne to impetigo and cellulitis. They may be required for prolonged courses over a period of weeks to months. Host factors, drug properties, and causative pathogens should all be considered when choosing a suitable antibiotic. Host factors include underlying disease, age, previous adverse reactions, and pregnancy. Drug parameters include interaction with concomitant therapy, side effect profile, dosage, route of administration, and cost. Causative pathogens and their sensitivity/resistance patterns should ideally be identified through swabs taken for microbiology. [Table 28.5](#) illustrates some of the antibiotics most commonly used in dermatology (mode of action, indications, and complications).

Table 28.5 Antibiotics used in dermatology, their method of action, indications, and complications.

| Antibiotic group | Method of action | Antibiotic | Indications | Considerations |
|------------------|--|------------|---|---|
| Penicillin's | Inhibition of bacterial cell wall synthesis Activation of autolytic bacterial enzymes | Penicillin | Gram-positive infections, e.g. <i>Streptococcus</i> Cellulitis | Hypersensitivity reactions which may be severe Dose reduction in |

| | | | | |
|---------------|---|--|--|---|
| | Bactericidal β lactamase resistant penicillin | | Erysipelas | renal impairment |
| | | Flucloxacillin | β lactamase producing organisms, e.g. <i>Staphylococcus aureus</i> Cellulitis Impetigo | Hypersensitivity reactions |
| Macrolides | Penetration of bacterial cell wall and inhibition of RNA-dependent protein synthesis by reversible binding to ribosomes | Erythromycin | Gram-positive infections Penicillin allergy Cellulitis Erysipelas Impetigo Acne Erythrasm | Nausea, diarrhoea |
| | | Clarithromycin | Gram-positive and gram-negative cover Erysipelas | Fewer gastrointestinal side effects |
| | | Azithromycin | Short courses, long acting | |
| Tetracyclines | Inhibition of protein synthesis by ribosomal binding | Oxytetracycline Minocycline Doxycycline Lymecycline | Gram-positive and gram-negative organisms Mycobacteria Acne Rosacea Perioral dermatitis Bullous pemphigoid Lyme disease Fish tank granuloma | Nausea, vomiting. Brown discolouration of teeth and delayed bone growth in children. Contraindicated in children under 12 years Hypersensitivity reactions Blue-black pigmentation of nails and skin Photosensitivity |

Antifungal drugs

Most cutaneous fungal infections can be effectively treated with topical therapy. However,

systemic treatment is required for fungal infections of the nails and hair. Terbinafine is a fungicidal allylamine, which binds to plasma proteins and is found in high concentrations in the hair, nails, and stratum corneum. In the treatment of tinea capitis oral terbinafine is more effective against endothrix organisms (*Trichophyton tonsurans*) than ectothrix infections (*Microsporum canis*). Terbinafine is licensed for use in children in several countries. Multiple studies have shown terbinafine to be safe and effective (severe liver injury is recognised but unusual). Treatment dosage is calculated according to the patient's weight (62.5 mg up to 20 kg; 125 mg up to 40 kg; 250 mg over 40 kg) and given daily for one month. Prolonged courses of three months or more are required in the treatment of onychomycosis involving the nail matrix.

Griseofulvin has fungistatic activity and has been used for many years to treat tinea capitis in children (weight < 50 kg; 10–20 mg/kg) given daily for six to eight weeks. However, terbinafine and itraconazole are often used in preference to griseofulvin as they are better tolerated and have a broader spectrum of activity. Griseofulvin is ineffective against pityriasis versicolor or yeast infections such as *Candida albicans*.

Itraconazole is a triazole used in pulsed therapy (one week per month) or continuously for the treatment of onychomycosis, tinea capitis, particularly in young infants (available as an oral solution) and pityriasis versicolor resistant to topical therapy.

Antiviral drugs

Systemic antivirals are available for the treatment of human herpes virus (HHV) infections such as herpes simplex virus (HSV) type 1 and type 2 (causing herpes labialis and genital lesions respectively) and varicella zoster virus (VZV) causing chickenpox and herpes zoster (shingles).

Aciclovir is a well-established antiviral drug used in the treatment of HHV. It inhibits viral DNA polymerase and irreversibly inhibits viral DNA synthesis. The underlying diagnosis determines the dose and treatment duration. Primary genital herpes simplex requires 200 mg three times daily for five days while herpes zoster and chickenpox in adults require 800 mg three times a day for seven days.

Aciclovir tends to be most effective if therapy is started within 72 hours of disease onset. Secondary prophylaxis for recurrent and frequent attacks of HSV may be given at a dose of 200–400 mg twice daily. Intravenous administration is preferable in severely ill patients at risk of disseminated HSV (immunocompromised, eczema herpeticum). A topical preparation of acyclovir/penciclovir is also available for the treatment of mild herpes labialis.

Alternative oral antivirals include valaciclovir and famciclovir, which are licensed for the treatment of herpes zoster and primary and recurrent genital herpes. Their advantage is that they are better absorbed through the gut and are useful in the treatment of acyclovir-resistant HHV infections (most common in patients with HIV or post bone marrow transplantation), though they are more expensive.

Antiparasite drugs

Scabies and pediculosis are usually adequately treated with topical therapy. Most studies show that 5% permethrin cream applied to the skin, left on overnight and repeated after seven days, is highly effective in treating scabies. However, Norwegian/resistant scabies and pediculoses refractory to conventional topical preparations may be amenable to treatment with oral ivermectin (200 µg/kg). Ivermectin causes paralysis and death of parasites and a single dose is usually sufficient. Ivermectin is available on a named-patient basis only in the UK. Topical 1% ivermectin cream has also been shown to be effective in the treatment of rosacea, scabies, and cutaneous larva migrans.

Larva migrans (hookworm) and larva currens (strongyloides) are effectively treated with oral albendazole (400 mg once daily for three days) or ivermectin 200 mcg/kg two doses (see [Chapter 17](#)).

Systemic immunomodulatory drugs

Corticosteroids

Systemic corticosteroids are used in the treatment of a wide range of inflammatory dermatoses. They are effective and often life-saving immunosuppressant and anti-inflammatory agents but need to be used with caution as they may have adverse effects. These include hyperglycaemia, hyperlipidaemia, hypertension, sodium and fluid retention, atherosclerosis, suppression of the HPA, growth retardation, osteoporosis, avascular necrosis of bone, alteration of fat distribution, myopathy, increased incidence of infection, reactivation of tuberculosis, peptic ulceration, glaucoma, cataracts, striae and psychiatric disorders. The indications, risks, benefits, potential adjuvant steroid-sparing therapy, and gastro and bone protection should therefore be carefully considered. However, systemic corticosteroids are particularly useful in controlling vasculitis, connective tissue disorders, sarcoidosis, erythroderma, lichen planus, and neutrophilic dermatoses among others. They are relatively contraindicated in psoriasis as withdrawal of the steroid may precipitate an exacerbation or generalised pustular psoriasis.

Patients treated with corticosteroids should be monitored closely for adverse effects, and they should be weaned off therapy slowly. A reducing course over six weeks is often used to treat severe exacerbations of atopic dermatitis. Patient education is important for those on long-term treatment. They should be provided with a steroid treatment card, which outlines important information for patients and carers.

Methotrexate

Methotrexate is an antimetabolite and is a potent inhibitor of the enzyme dihydrofolate reductase. It competitively and irreversibly binds to dihydrofolate reductase with a much greater affinity than its natural substrate folic acid, thereby preventing the conversion of dihydrofolate to tetrahydrofolate. This is an important step in the synthesis of thymidylate and purine nucleotides needed for DNA and RNA synthesis, and results in inhibition of cell division.

Methotrexate is very useful in the treatment of psoriasis and atopic dermatitis. It is thought to act as an immunomodulator by inhibiting DNA synthesis in lymphocytes rather than having an antiproliferative effect. It is also used in sarcoidosis, connective tissue disease, bullous pemphigoid, vasculitis, and morphea.

Methotrexate is taken once a week, the dose being carefully titrated by 2.5 mg increments. It has several side effects including bone marrow suppression, hepatotoxicity, nausea and vomiting, pulmonary fibrosis and teratogenicity, and patients need careful monitoring. Liver biopsy and procollagen III measurements have been surpassed by the use of ultrasound FibroScan technology as an indirect measure of liver fibrosis. Folic acid 5 mg once/week or several times per week is taken in addition to prevent folate deficiency, reduce nausea and hepatotoxicity. Acute methotrexate overdose or toxicity may be treated with folinic acid, which bypasses the metabolic effects of methotrexate. Methotrexate also has several potentially serious drug interactions including non-steroidal anti-inflammatory drugs, antibiotics, corticosteroids, and omeprazole.

Azathioprine

Azathioprine is an antimetabolite, which inhibits DNA and RNA synthesis, and the differentiation and proliferation of lymphocytes. It is an immunosuppressant and is often used in conjunction with corticosteroids as it has steroid-sparing effects. Azathioprine is an effective treatment in a wide range of dermatological conditions, such as severe atopic eczema, chronic actinic dermatitis, immunobullous disorders, systemic lupus erythematosus, and dermatomyositis. Although it is usually well tolerated, it has several side effects including bone marrow suppression, nausea and vomiting, hypersensitivity reactions, hepatotoxicity, macrocytosis, pancreatitis, and diffuse hair loss. Bone marrow suppression may be predicted in susceptible patients who have low levels of the enzyme thiopurine methyl transferase (TPMT), and who are therefore unable to metabolise the drug efficiently. Unfortunately, the other side effects of azathioprine cannot be predicted by the TPMT activity.

Ciclosporin

Ciclosporin is an immunosuppressant drug derived from the fungus *Tolypocladium inflatum*. It suppresses the induction and proliferation of T-lymphocytes and inhibits the production of inflammatory cytokines. It is effective in the treatment of severe psoriasis (including erythrodermic psoriasis and palmo-plantar pustulosis), atopic eczema, and possibly in severe drug eruptions such as toxic epidermolytic necrolysis (TEN). Its advantages include rapid onset of action (one to two weeks) and lack of bone marrow suppression. However, it has several side effects, such as renal toxicity, hypertension, hypertrichosis, tremor, and gingival hyperplasia. There is also an increased risk of malignancy. Ciclosporin therefore tends to be used for short periods to treat severe flares of disease, or as part of a rotational regimen. It is metabolised by cytochrome P450 and interacts with several other drugs. Ciclosporin is usually given between 3 and 5 mg/kg/day in two divided doses.

Mycophenolate mofetil

Mycophenolate mofetil (MMF) is an immunosuppressant agent, which acts by selectively and irreversibly inhibiting inosine monophosphate dehydrogenase, resulting in the depletion of intracellular guanine nucleotides. It seems to have a selective effect on activated T-lymphocytes. In dermatology, it is mainly used for the treatment of immunobullous disorders and pyoderma gangrenosum. Side effects are predominantly gastrointestinal, with nausea, vomiting, and diarrhoea. The elderly generally more susceptible to the adverse effects of MMF, which also include bone marrow suppression, infection, fatigue, headaches, and weakness. Treatment doses in dermatology usually range from 250 mg to 1 g twice daily.

Dimethyl fumarate

Self-experimentation by the German Chemist Schweckendiek led to the discovery that fumaric acid esters were useful in the treatment of psoriasis. Dimethyl fumarate (DMF) is approved for use in patients with severe psoriasis unresponsive to or ineligible for standard systemic therapies. The mode of action of DMF and its metabolite monomethyl fumarate is not fully understood but is thought to be intracellular, resulting in a shift in T-helper cells from the Th1 and Th17 profile to a Th2 phenotype. DMF is less effective than biologic therapy and associated with significant symptomatic adverse events. Gastrointestinal upset occurs in two-thirds of patients and typically includes diarrhoea, abdominal pain, nausea, and flatulence. Flushing occurs in up to 20% of patients. Lymphopenia occurs in 10% of patients and necessitates regular monitoring of full blood count. A lymphocyte count below $0.7 \times 10^9/l$ is an indication for dose reduction.

Apremilast

Apremilast is approved for severe chronic plaque psoriasis in adults unresponsive to or ineligible for standard systemic therapies. Apremilast is an oral small molecule which inhibits the enzyme phosphodiesterase-4 (PDE4) which plays a key role in intracellular T-cell signalling. Inhibition of PDE4 down-regulates the expression of key cytokines in psoriasis including tumour necrosis factor alpha (TNF- α) and IL-23.

Apremilast is significantly less effective than biologic therapy. It is associated with several adverse events early in treatment. Gastrointestinal upset is the most commonly reported adverse event (about 15%) and typically involves mild to moderate nausea and diarrhoea. It is usually self-limiting and resolves within four weeks. Less commonly reported adverse events include upper respiratory tract infections and headache. Clinical trials and post-marketing surveys suggested an increased risk of serious psychiatric symptoms, including depression, suicidal thoughts, and suicidal behaviours in patients taking apremilast. As such these symptoms are known to be more common in patients with psoriasis, the true significance of the reports therefore is unclear. Nonetheless, caution is indicated.

Systemic retinoids

Retinoids are derived from vitamin A and include acitretin, isotretinoin, alitretinoin, and

bexarotene. They activate nuclear receptors and regulate gene transcription. They have anti-inflammatory, anti-keratinising, anti-sebum, anti-tumour, and anti-proliferative effects. Acitretin is used in the treatment of psoriasis, Darier's disease, pityriasis rubra pilaris, ichthyosis, keratodermas, and in transplant recipients who are at high risk of developing cutaneous malignancies. Isotretinoin is the drug of choice for treating severe nodulocystic acne and timely initiation of treatment is aimed at preventing significant scarring. It may also be used in hidradenitis suppurativa, dissecting cellulitis of the scalp and severe recalcitrant papulopustular rosacea. Alitretinoin is used for the treatment of severe chronic hand eczema, which is refractory to treatment with topical corticosteroids. Bexarotene is reserved for the treatment of cutaneous T-cell lymphoma.

Systemic retinoids have several side effects, the most important of which is teratogenicity. Women of child-bearing age must use a robust form of contraception for at least a month prior to and during treatment. Isotretinoin, alitretinoin, and bexarotene have a relatively short elimination half-life and contraception needs to be continued for at least a month after discontinuation of therapy. Acitretin has a much longer half-life and pregnancy needs to be avoided for at least three years after treatment has stopped. The side effect profile of systemic retinoids is summarised in [Table 28.6](#). Acitretin is usually prescribed at doses ranging from 10 to 50 mg daily. Isotretinoin dosage is based on weight between 0.5 and 1 mg/kg/day with a treatment course for severe acne usually being given as a total target dose of 120–150 mg/kg. The dose of alitretinoin is 30 mg daily, reducing to 10 mg daily in patients with side effects on the higher dose.

Table 28.6 Side effects of systemic retinoids.

| |
|-------------------------------|
| Teratogenicity |
| Depression |
| Cheilitis |
| Hypercholesterolaemia |
| Hypertriglyceridaemia |
| Elevation of transaminases |
| Hepatitis |
| Pancreatitis |
| Myopathy |
| Reduced night vision |
| Dry eyes |
| Epistaxis |
| Facial erythema |
| Photosensitivity |
| Hair loss |
| DISH |
| Premature epiphyseal closure |
| Leucopenia ^a |
| Agranulocytosis ^a |
| Hypothyroidism ^{a,b} |

DISH, diffuse interstitial skeletal hyperostosis.

^a Predominantly a risk with bexarotene.

^b Predominantly a risk with alitretinoin.

Antihistamines

Histamine has numerous effects on the skin, causing itching, vasodilatation, and increased vascular permeability predominantly through its action on H1 receptors. Antihistamines reversibly block H1 receptors. First-generation antihistamines tend to be sedating and include chlorpheniramine, hydroxyzine, and promethazine. Second-generation antihistamines tend to be non-sedating, have a slower onset and longer duration of action. They include cetirizine, loratidine, fexofenadine, levocetirizine, and desloratidine. They play a central role in the treatment of urticaria, angioedema, type 1 hypersensitivity reactions, anaphylaxis, pruritus, cutaneous mastocytosis, and acute insect bite reactions. They tend to be well tolerated although side effects include drowsiness, anticholinergic activity, and arrhythmias. Topical

antihistamines should be avoided because of the risk of developing allergic contact dermatitis.

Miscellaneous drugs

Dapsone

Dapsone is a sulfonamide, traditionally used in the treatment of leprosy. Its mode of action is unclear, but it is particularly useful in the treatment of disorders where neutrophils or IgA immune complexes play a role, for example, dermatitis herpetiformis, bullous pemphigoid, mucous membrane pemphigoid, linear IgA disease, and pyoderma gangrenosum. Side effects include dose-related haemolysis and haemolytic anaemia, which are more common in those individuals with glucose-6-phosphate dehydrogenase (G6PD) deficiency. G6PD should therefore be measured prior to starting treatment. Other adverse effects include agranulocytosis, methaemoglobinaemia, hypersensitivity syndrome, and peripheral neuropathy.

Antimalarials

Hydroxychloroquine, mepacrine, and chloroquine are used to treat systemic lupus erythematosus, discoid lupus erythematosus, subacute cutaneous lupus erythematosus, sarcoidosis, polymorphic light eruption, and porphyria cutanea tarda. Their mode of action is thought to involve interruption of antigen processing and inhibition of inflammatory cytokines. Chloroquine can cause irreversible retinopathy, and mepacrine is unlicensed in the United Kingdom. Hydroxychloroquine therefore tends to be the antimalarial of choice in the treatment of dermatological disorders. It is well tolerated at doses of 200 mg once or twice daily (lower doses should be used in low body weight patients) although retinal toxicity can rarely occur. Visual acuity should be monitored by an optician for those patients on long-term therapy.

Biological therapies

Biologics are drugs whose active substance is made by a living organism. Small-molecule medicines (SMOLs) are conventional drugs made by chemical synthesis. Biologics are large, complex molecules; most are proteins or polypeptides. In contrast, SMOLs have a low molecular weight. Being large protein molecules, biologics are intrinsically unstable; they are poorly absorbed from the gastrointestinal tract and easily degraded by gastric acids and enzymes. They are usually administered parenterally.

Biologics used in psoriasis

Psoriasis is a complex immunologic disease which occurs in genetically susceptible individuals exposed to appropriate environmental stimuli. Our understanding of psoriasis has evolved significantly in the last decade. It is now recognised that the key cytokine in psoriasis is interleukin-17 (IL-17), which is produced by T-helper 17 (Th17) cells in

response to differentiation, which is induced by interleukin-23 (IL-23). TNF- α is also over-expressed in psoriasis. Its effects are mediated via the IL-23/Th17 pathway, with which it interacts at two points. Upstream, TNF- α stimulates myeloid dendritic cells to produce IL-23. Downstream, TNF- α and IL-17 interact synergistically in keratinocytes to increase transcription of many psoriasis-related genes. As the importance of TNF- α in psoriasis was recognised long before that of IL-17, biologics targeting TNF- α were among the first developed for psoriasis.

There are currently three tumour necrosis factor inhibitors (TNFi) approved for use in psoriasis in the UK: infliximab, adalimumab, and etanercept. A fourth, certolizumab, is currently being assessed by NICE (the National Institute for Health and Care Excellence) and approval is expected in April 2019. There are a few key structural differences between these TNFi. Etanercept is a soluble receptor; infliximab and adalimumab are monoclonal antibodies. Infliximab is chimeric (it has a murine variable region and a human constant region). Adalimumab is fully human. Certolizumab is an antibody fragment, which is pegylated (conjugated with polyethylene glycol). Because certolizumab lacks an Fc portion, it is not transported across the placenta in pregnancy and will be useful in women of child-bearing age.

TNFi are effective and are well tolerated. Like other biologic agents, the TNFi lack traditional end-organ toxicity (hepatotoxicity, nephrotoxicity) and require less frequent monitoring of laboratory parameters. Important but uncommon adverse events include tuberculosis (reactivation and de novo disease), reactivation of hepatitis B, demyelination, and exacerbation of heart failure.

IL-12/23 inhibitors were developed after TNFi. Ustekinumab is a monoclonal antibody to the p40 subunit of IL-12 and IL-23. It prevents these cytokines binding to their T-cell receptors and stimulating differentiation into T-helper 1 (Th1) and Th17 cells, respectively. The efficacy of ustekinumab is similar to adalimumab. It is dosed less frequently and has shown better drug survival than the TNFi. Its side effect profile is similar.

IL-17 inhibitors followed IL-12/23 inhibitors. These target IL-17 specifically, downstream of IL-23. There are currently three IL-17 inhibitors approved for psoriasis in the UK: secukinumab and ixekizumab are monoclonal antibodies to IL-17A, brodalumab blocks its receptor. Where head-to-head trials have been undertaken, IL-17 inhibitors have shown superior efficacy to TNFi and ustekinumab. They have thrown up some unique adverse events, however: such as candidiasis and induction or exacerbation of inflammatory bowel disease (IBD). This is not entirely surprising as IL-17 is known to play a key role in defence against extracellular pathogens and maintaining gut mucosal integrity.

The latest class of biologics target IL-23, upstream of IL-17. Unlike ustekinumab, which targets the p40 subunit common to IL-12 and IL-23, IL-23 inhibitors target the p19 subunit only, which is unique to IL-23. Although early indications are that their efficacy is broadly similar to the IL-17 inhibitors, they may be better tolerated. Candidiasis and induction or exacerbation of IBD were not seen in clinical trials. This may be due to the preservation of IL17 produced by macrophages, monocytes, and neutrophils, which are not dependent on IL-

23. Just one IL-23 inhibitor is currently approved for use in psoriasis in the UK (guselkumab). Approval for others is expected soon.

Biologics used in atopic dermatitis

Atopic dermatitis is a T-helper 2 (Th2) cell mediated disease in which the cytokines IL-13 and IL-4 play a key role. Dupilumab is a monoclonal antibody that binds competitively to the α -subunit common to the type I and type II IL-4 receptors, blocking IL-4 and IL-13 binding and signalling. Dupilumab was recently approved for use in moderate to severe atopic eczema in the UK. It is effective and generally well tolerated. Common adverse events reported in phase III trials were non-serious, and included nasopharyngitis, upper respiratory tract infections, injection site reactions, skin infections (particularly HSV), and conjunctivitis. Following a long period with little drug development in atopic eczema, there are now many drugs in the pipeline, including topical, oral, and biological therapies.

Biologics used in chronic spontaneous urticaria

Chronic spontaneous urticaria (CSU) is characterised by recurrent wheals for at least six weeks. The immunopathogenesis of urticaria is not fully understood but immunoglobulin E (IgE)-mediated histamine release from mast cells and basophils plays a key role. Omalizumab is a monoclonal antibody which binds to free IgE and prevents it from binding to its receptor on mast cells and basophils. Omalizumab is recommended as an add-on therapy for patients with severe CSU which has not responded to standard treatment with H1-antihistamines and leukotriene receptor antagonists (montelukast). Omalizumab is generally well tolerated: commonly reported adverse reactions include headache, upper respiratory tract infections, sinusitis, arthralgia, and injection site reactions.

Miscellaneous

Rituximab is an anti-CD20 humanised monoclonal antibody originally developed for the treatment of non-Hodgkin's lymphoma (NHL), which leads to transitory B-cell depletion. It has been used in the treatment of cutaneous graft-versus-host disease, primary cutaneous large B-cell NHL, paraneoplastic pemphigus, pemphigus vulgaris, pemphigus foliaceus, bullous pemphigoid, and epidermolysis bullosa acquisita.

Further reading

Smith, C.H., Jabbar-Lopez, Z.K., Yiu, Z.Z. et al. (2017). British Association of Dermatologists guidelines for biologic therapy for psoriasis 2017. *British Journal of Dermatology* **177**: 628.

Wakelin, S.H. (2014). *Handbook of Systemic Drug Treatment in Dermatology*. London: Manson.

Wolverton, S.E. (2001). *Comprehensive Dermatologic Drug Therapy*. Toronto: WB Saunders.

Index

Page locators in **bold** indicate tables. Page locators in *italics* indicate figures. This index uses letter-by-letter alphabetization.

- ABCDE of malignant pigmented lesions, [199](#)
- Abscesses, [107](#), [107](#)
- Acanthosis nigricans (AN), [77–78](#), [78](#), [179](#)
- Acitretin, [23–24](#)
- Acne, [95–101](#)
 - acne conglobata/fulminans, [98–99](#), [99](#)
 - acne excoriée, [98](#), [98](#)
 - acne keloidalis, [97](#), [97](#), [108](#), [108](#)
 - acne vulgaris, [97–98](#), [97–98](#)
 - clinical presentation, [95–96](#), [95–96](#)
 - diet, [97](#)
 - drug rashes, [54](#)
 - infantile acne, [98](#)
 - introduction, [95](#)
 - treatment, [99–101](#), [99](#)
 - types of acne, [97–99](#)
 - underlying causes, [96–97](#)
- Acquired immune deficiency syndrome *see* [HIV/AIDS](#)
- Acquired melanocytic naevi, [186–187](#), [186–187](#)
- Acral melanoma, [201–202](#), [202](#)
- Acrodermatitis enteropathica, [79](#), [80](#), [179](#)
- Acropustulosis, [14](#)
- Actinic keratoses (AK), [195–196](#), [195](#), [208](#), [220–221](#)
- Acute generalised exanthematous pustulosis (AGEP), [57–58](#), [57](#)
- Acute leishmaniasis, [149](#), [150](#)

AD *see* [atopic dermatitis](#)

Adalimumab, [26](#)

AGEP *see* [acute generalised exanthematous pustulosis](#)

AHA *see* [alpha hydroxyl acids](#)

AIDS *see* [HIV/AIDS](#)

AK *see* [actinic keratoses](#)

Alagille syndrome, [81](#), [81](#)

Albinism, [82](#)

Alfalmelanotide, [45](#)

Alginate dressings, [236](#)

Alginogels, [237](#)

Allergic contact dermatitis, [31–32](#), [33–34](#), [35](#), [176](#), [176](#)

Allergic reactions, [140–141](#)

Alopecia

alopecia areata, [159–160](#), [159–160](#), [170](#), [170](#)

drug rashes, [54](#)

female pattern hair loss, [159](#), [159](#)

fungal infections, [132](#), [132–133](#)

lymphocytic disorders, [161–162](#), [162](#)

male pattern hair loss, [158–159](#), [158](#)

neutrophilic disorders, [162–163](#), [162](#)

non-scarring alopecias, [158–161](#)

scarring alopecias, [161–163](#), [163](#)

telogen effluvium, [160–161](#), [161](#)

tinea capitis/kerion, [161](#), [161](#)

Alpha hydroxyl acids (AHA), [228–229](#)

Amelanotic melanoma, [202](#), [202](#)

AN *see* [acanthosis nigricans](#)

Androgenetic alopecia, [158–159](#), [158](#)

Angiokeratoma, [175](#), [175](#)

Angiomata, [188](#)–189, [189](#)

Angio-oedema *see* [urticaria and angio-oedema](#)

Annular lesions

anatomy and physiology, [4](#), [7](#)

psoriasis, [13](#), [14](#)

systemic disease, [77](#)

urticaria and angio-oedema, [41](#)

Antibiotics

acne, rosacea, and hidradenitis suppurativa, [100](#), [102](#)–103

bacterial infections, [107](#)

eczema (dermatitis), [37](#)

systemic treatment, [249](#)–250, [249](#)

topical treatment, [247](#), [248](#)

wound management, [234](#), [236](#)

Antihistamines, [252](#)

Antimalarials, [252](#)

Antiseptic washes, [107](#)

Aphthous ulcers, [179](#)

Apocrine hidrocystoma, [190](#), [191](#)

Apparent leukonychia, [168](#), [168](#)

Apremilast, [26](#), [37](#), [251](#)

Arterial leg ulcers, [91](#), [91](#)

Asteatotic eczema, [29](#), [30](#)

Athlete's foot, [134](#), [134](#)

Atopic dermatitis (AD)

- anatomy and physiology, [6](#)
- biological treatment, [37](#), [253](#)
- clinical features, [27](#), [27](#)
- endogenous eczema, [28–30](#), [28–29](#)
- food allergy, [29–30](#), [29–30](#)
- pathophysiology, [27](#)

Atrophie blanche, [89](#), [89](#)

Atrophy, [4](#), [5](#)

Azathioprine, [250](#)

Azelaic acid, [99](#)

Azothioprine, [23](#)

Bacillary angiomatosis, [111](#), [111](#)

Bacterial folliculitis, [108](#), [108](#)

Bacterial infections, [105–112](#)

- clinical presentation, [105](#)
- common patterns of bacterial infection in the skin, [106](#)
- deeper infections, [108–110](#), [109–110](#)
- general management approach, [107](#)
- HIV/AIDS, [126](#), [126–127](#)
- introduction, [105](#)
- investigations, [105–106](#)
- mycobacterial disease, [110–111](#), [110–111](#)
- nails, [171](#), [171](#)
- other infections, [111–112](#), [111–112](#)
- superficial infections, [107–108](#), [107–108](#)
- tropical dermatology, [147–150](#), [148](#), [150](#)

Baker-Gordon, [229](#)

Balanitis, [176](#)

Balano-posthitis, [176](#)

Bandages, [239](#)–243, [241](#)–242

Basal cell carcinoma (BCC), [196](#)–198, [197](#)–198
treatment, [208](#), [210](#)–211, [214](#), [220](#)–221, [221](#)

Bazin’s disease, [110](#), [111](#)

BCC *see* [basal cell carcinoma](#)

B-cell lymphoma, [83](#), [83](#)

Beau’s lines, [12](#), [167](#), [172](#)

Beauty, [223](#)

Becker’s naevi, [186](#)–187, [187](#)

Bed bugs, [139](#), [139](#)

Bee stings, [142](#)

Behçet’s disease, [179](#)

Benign skin tumours, [183](#)–193
dermatofibroma, [187](#), [187](#)
differential diagnosis, [183](#)
introduction, [183](#)
melanocytic naevi, [185](#)–187, [185](#)–187
nodules, [191](#)–192, [191](#)–192
papules, [189](#)–190, [190](#)–191
pigmented benign tumours, [184](#)–185, [184](#)–185
plaques, [192](#), [192](#)–193
vascular benign tumours, [188](#)–189, [188](#)–190

Benzoyl peroxide, [99](#)

Biological treatment
atopic dermatitis, [37](#), [253](#)
psoriasis, [23](#), [25](#)–26, [25](#), [252](#)–253

Blashko’s lines, [85](#)–86, [85](#)–86

Blastomycosis, [152](#)–153, [152](#)

Blepharitis, [101](#), [102](#)

Blisters *see* [immunobullous/blistering disorders](#)

Blue naevi, [186](#), [187](#)

Body contouring, [230](#)

Body lice, [144](#)–145

Borderline leprosy, [148](#)

Botulinum toxin (BTX), [226](#)–228, [227](#)

Bowen's disease, [196](#), [196](#), [208](#), [220](#)–221

Bruising, [218](#)

BTX *see* [botulinum toxin](#)

Bullae *see* [immunobullous/blistering disorders](#)

Bullous impetigo, [110](#)

Bullous lichen planus, [71](#), [71](#)

Bullous pemphigoid

- clinical features, [61](#), [61](#)–62
- genital dermatoses, [179](#)
- management, [65](#)
- morphology, [9](#)
- pathophysiology, [59](#)

Bullous vasculitis with necrosis, [68](#)

Buruli ulcer, [93](#), [93](#)

Cacinosi cutis, [70](#), [70](#)

CAD *see* [chronic actinic dermatitis](#)

Café au lait macule, [218](#)

Calcineurin inhibitors, [247](#)

Calcipotriol, [20](#)–21

Calcium hydroxyapatite, [225](#)

Campbell de Morgan spots, [189](#), [189](#)

Candida albicans, [135](#)–137, [137](#)

Candidiasis, [180](#)

Capillary action dressings, [237](#)

Cardiovascular disease (CVD), [17](#)

Cat-scratch disease, [111](#)

Cavity dressings, [236–237](#)

CCCA *see* [central centrifugal cicatricial alopecia](#)

Cellulitis, [9](#), [109](#), [109](#)

Central centrifugal cicatricial alopecia (CCCA), [162](#)

Chemical burn, [230](#), [230](#)

Chemical peels, [220](#), [228–230](#), [228–230](#)

Chemotherapy, [203](#)

Chickenpox, [115](#), [115](#)

Chilblains, [69](#), [69](#)

Cholinergic urticaria, [41](#)

Chromoblastomycosis, [152](#), [152](#)

Chronic actinic dermatitis (CAD)
 diagnosis, [7](#), [8](#)
 photodermatitis, [33–34](#), [34](#)
 photosensitivity, [47–48](#), [48](#)

Chronic atopic dermatitis, [27](#), [27](#)

Chronic eczema, [4](#)

Chronic leishmaniasis, [149](#), [150](#)

Chronic paronychia, [136](#)

Chronic plaque psoriasis, [1](#), [1](#)

Chronic spontaneous urticaria (CSU), [253](#)

Cicatricial pemphigoid *see* [mucous membrane pemphigoid](#)

Ciclosporin, [23–24](#), [250–251](#)

Cleansers
 acne, [99](#)
 antiseptic washes, [107](#)
 eczema (dermatitis), [36](#)

Clubbing, [168](#), [168](#), [172](#)

Coal tar, [20](#)

Cockayne syndrome, [45](#)

Cold-induced urticaria, [40](#)

Cold sores, [114](#), [114](#)

Compound naevi, [186](#), [186](#)

Compression bandages, [90](#), [90](#), [240](#)–242, [241](#)–242

Congenital bowel disorders, [80](#)

Congenital melanocytic naevi, [185](#)–186, [185](#)

Connective tissue disease (CTD), [67](#), [74](#)

Contact dermatitis

- allergic contact dermatitis, [31](#)–32, [33](#)–34, [35](#)
- anatomy and physiology, [5](#)
- clinical features, [31](#)
- exogenous eczema, [31](#)–35, [32](#)–35
- investigations of contact dermatitis, [35](#)–36, [36](#)
- irritant contact dermatitis, [32](#)–33, [35](#)
- occupational dermatitis, [34](#)–35, [35](#)
- photodermatitis, [33](#)–34, [34](#)
- symmetry, [6](#), [8](#)
- wound management, [242](#)

Contact urticaria, [35](#)

Corticosteroids

- acne, [97](#)
- alopecia, [160](#)
- dermatomyositis, [74](#)
- eczema (dermatitis), [36–37](#)
- immunobullous/blistering disorders, [65](#)
- lupus erythematosus, [72–73](#)
- psoriasis, [21](#)
- systemic treatment, [250](#)
- topical treatment, [245–246](#), [246–247](#), [246](#)
- vasculitis, [69](#)

Cosmetic camouflage, [248](#)

Cosmetic dermatology, [223–230](#)

- beauty and visible ageing, [223](#), [224](#)
- botulinum toxin, [226–228](#), [227](#)
- chemical peels, [228–230](#), [228–230](#)
- introduction, [223](#)
- preoperative assessment, [223](#), [225](#)
- skin tightening devices, [230](#)
- soft tissue augmentation, [223–226](#), [225–226](#)

Cosmetic hair growth, [164](#)

Cosmetic nails, [174](#)

Cosmoceuticals, [2](#)

CREST syndrome, [70–71](#), [70](#)

Crohn's disease, [80](#), [179](#)

Crusts

- anatomy and physiology, [4](#), [6](#)
- bacterial infections, [107](#), [107](#)
- crusted scabies, [129](#), [142](#), [143](#)

Cryotherapy, [118](#), [207–208](#), [208](#)

CSU *see* [chronic spontaneous urticaria](#)

CTD *see* [connective tissue disease](#)

Curettage, [209–210](#), [209](#)

Cutaneous larva migrans, [145](#), [145](#)

Cutaneous leishmaniasis, [149–150](#), [150](#)

Cutaneous lymphoma, [7](#), [204–205](#), [204](#)

CVD *see* [cardiovascular disease](#)

Cyanosis, [172](#)

Dapsone, [252](#)

Darier's disease, [167](#), [167](#), [170](#)

DDTU *see* [dermatology day treatment units](#)

Deep fungal infections, [137](#), [137](#)

Delusions of parasitosis (DoP), [140](#), [140](#)

Dermabrasion, [220](#)

Dermatitis *see* [eczema \(dermatitis\)](#); *individual subtypes*

Dermatitis artefacta, [93](#), [93](#)

Dermatitis herpetiformis (DH)

- clinical features, [63–64](#), [64](#)
- management, [66](#)
- pathophysiology, [60](#)
- systemic disease, [80](#), [80](#)

Dermatofibroma, [187](#), [187](#)

Dermatographism, [41](#), [42](#)

Dermatology day treatment units (DDTU), [19–20](#)

Dermatology Life Quality Index (DLQI), [2](#), [19–20](#)

Dermatomyositis, [73–74](#), [73–74](#)

Dermatosis papulosa nigra (DPN), [184](#), [184](#)

Desmoplastic melanoma, [202](#), [202](#)

Desquamation, [4](#), [6](#)

DH *see* [dermatitis herpetiformis](#)

Diabetes mellitus (DM), [78](#), [92](#), [92](#)
Diathermy loop cautery, [118](#)
Diclofenac, [247](#)
Diffuse cutaneous leishmaniasis, [149](#), [150](#)
Dimethyl fumarate, [251](#)
Diphencyprone, [119](#)
Discoid eczema, [5](#), [29](#), [30](#)
Discoid lesions, [4](#), [5](#)
Discoid lupus erythematosus (DLE), [72–73](#), [73](#), [161](#), [162](#)
Dissecting folliculitis, [162](#)
Dithranol, [20](#), [21](#)
DLE *see* [discoid lupus erythematosus](#)
DLQI *see* [Dermatology Life Quality Index](#)
DM *see* [diabetes mellitus](#)
DoP *see* [delusions of parasitosis](#)
DPN *see* [dermatosis papulosa nigra](#)
Dracunculiasis, [155](#)
DRESS *see* [drug reaction with eosinophilia and systemic symptoms](#)
Dressings, [233–235](#), [235–239](#), [235](#), [237–239](#)

Drug rashes, [51–58](#)

anatomy and physiology, [6](#)

classification of drug reactions in the skin, [52–54](#)

common drug-induced rashes, [54–56](#), [54–56](#)

exacerbation of pre-existing dermatoses, [54](#)

examination, [51](#)

genital dermatoses, [179](#)

hair and nails, [53–54](#)

history, [51](#)

HIV/AIDS, [129](#), [129](#)

introduction, [51](#)

investigation of a suspected drug reaction, [52](#)

photosensitivity, [52–53](#), [52](#), [53](#)

pigmentation, [53](#), [53](#)

severe drug reactions in the skin, [56–58](#), [56–57](#), [56](#)

Drug reaction with eosinophilia and systemic symptoms (DRESS), [57](#), [57](#)

Dupilumab, [37](#)

Dysplastic naevi, [199](#), [200](#)

EAC *see* [erythema annulare centrifugum](#)

Ecchymosis, [177](#), [177](#)

Ecthyma, [110](#), [110](#)

Eczema (dermatitis), [27–38](#)
anatomy and physiology, [4](#), [5](#)
biological treatment, [37](#)
classification of eczema, [31](#)
clinical features, [27](#), [27](#)
drug rashes, [54](#)
endogenous eczema, [28–30](#)
exogenous eczema, [31–35](#), [32–35](#)
food allergy in atopic dermatitis, [29–30](#), [29–30](#)
general management, [36–37](#)
genital dermatoses, [176](#), [176](#)
introduction, [27](#)
investigations of contact dermatitis, [35–36](#), [36](#)
investigations of eczema, [30–31](#)
leg ulcers, [89](#)
morphology, [8](#)
nails, [166–167](#), [170](#), [170](#)
occupational dermatitis, [34–35](#), [35](#)
pathology, [27–28](#), [28](#)
pathophysiology, [27](#)
photodermatitis, [33–34](#), [34](#)
pruritis, [37–38](#)
symmetry, [7](#)
see also individual subtypes

Eczema herpeticum, [29](#), [29](#), [114](#)

EF *see* [eosinophilic folliculitis](#)

Electrosurgery, [209](#), [209](#)

EM *see* [erythema multiforme](#)

Emollients

eczema (dermatitis), [36](#)

formulary, [245](#)

psoriasis, [20](#)

EMP *see* [extra-mammary Paget's disease](#)

EN *see* [erythema nodosum](#)

Eosinophilic folliculitis (EF), [125](#), [125](#)

Epidermal naevi, [192](#), [193](#)

Epidermoid cysts, [191](#), [192](#)

Epithelialising wounds, [232](#), [233](#)

EPP *see* [erythropoietic protoporphyria](#)

Epstein–Barr virus (EBV), [127](#), [127](#)

Erosions

anatomy and physiology, [4](#), [6](#)

bacterial infections, [107](#), [107](#)

genital dermatoses, [178](#)

Erysipelas, [108](#)–[109](#), [109](#)

Erythema

anatomy and physiology, [3](#), [3](#)

genital dermatoses, [176](#), [176](#)

morphology, [9](#)

psoriasis, [13](#)

Erythema annulare centrifugum (EAC), [76](#), [77](#)

Erythema chronicum migrans, [77](#), [141](#)

Erythema induratum, [110](#), [111](#)

Erythema infectiosum, [120](#), [120](#)

Erythema multiforme (EM), [8](#), [8](#), [76](#), [76](#)

Erythema nodosum (EN)
 clinical features, [1](#), [2](#)
 drug rashes, [56](#)
 systemic disease, [76](#), [77](#)

Erythrasma, [108](#), [109](#)

Erythroderma, [83](#), [83](#)

Erythrodermic psoriasis, [16](#), [16](#)

Erythropoietic protoporphyria (EPP), [45](#), [45](#)

Etanercept, [25](#)

Exanthems, [54](#), [54](#)

Exclamation mark hairs, [159](#), [160](#)

Excoriation, [4](#), [6](#)

Extra-mammary Paget's disease (EMP), [181](#)

Exuding wounds, [234](#)

Eyes, [63](#), [63](#)

Favus, [151](#)

Female pattern hair loss, [159](#), [159](#)

Filariasis, [153](#)–155, [154](#)–155

Filiform warts, [118](#)

Fillers, [223](#)–226, [225](#)–226

Film dressings, [235](#)

Finasteride, [158](#)

Finger-tip units (FTU), [21](#)

Fissures, [4](#), [6](#)

Fitzpatrick skin type, [43](#)–44

Fixed drug eruption, [56](#), [56](#)

Flexural psoriasis, [14](#), [16](#)

Fluid retention, [96](#)

5 Fluoruracil, [247](#)

Folliculitis decalvans, [162](#)–163, [162](#)

Food allergy, [29–30](#), [29–30](#)

Fordyce spots, [175–176](#)

Fractional laser treatment, [220](#)

FTU *see* [finger-tip units](#)

Fungal infections, [131–138](#)

- deep fungal infections, [137](#), [137](#), [151–153](#), [152–153](#)
- feet/dominant hand, [134](#), [134](#)
- general features on fungi in the skin, [132–136](#), [132–136](#)
- HIV/AIDS, [125–126](#), [126](#)
- introduction, [131](#)
- investigations, [131](#)
- nails, [135–136](#), [135–136](#), [171](#), [171](#)
- scalp and face, [132–134](#), [132–134](#)
- systemic antifungal drugs, [138](#)
- tropical dermatology, [150–153](#), [151–153](#), [151](#)
- trunk, [134–135](#), [134–135](#)
- yeast infections, [135–137](#), [137](#)

Gastrointestinal disorders, [78–81](#), [80](#)

GCS *see* [Gianotti–Crosti syndrome](#)

Generalised pustular psoriasis (GPP), [14](#), [16](#)

Genetics, [84–86](#), [85–86](#), [85](#)

Genital dermatoses, [175](#)–181

- balanitis and balano-posthitis, [176](#)
- eczema (dermatitis), [176](#), [176](#)
- extra-mammary Paget’s disease, [181](#)
- history and examination, [175](#)–176
- infections and infestations, [180](#)
- inflammatory dermatoses, [179](#)
- intra-epithelial neoplasia, [180](#)–181, [180](#)–181
- introduction, [175](#)
- lichen planus, [178](#), [178](#)
- lichen sclerosus, [177](#)–178, [177](#)–178
- lichen simplex, [176](#), [176](#)
- pigmentation, [179](#), [180](#)
- psoriasis, [176](#), [177](#)
- ulcers, [179](#), [179](#)
- vulval and penile pain, [181](#)

Gianotti–Crosti syndrome (GCS), [76](#), [120](#), [120](#)

Glogau classification scale, [225](#)

Glomus tumours, [173](#)

Gluten-free diet, [66](#)

GPP see [generalised pustular psoriasis](#)

Granulating wounds, [232](#), [233](#)

Granuloma annulare, [78](#), [79](#)

Guttate psoriasis, [14](#), [15](#)

HA see [hyaluronic acid](#)

Haemangioma, [3](#)

Haemochromatosis, [82](#), [82](#)

Hair follicles/hair cycle, [157](#), [158](#)

Hair loss see [alopecia](#)

Hair removal, [219](#)–220

Halo naevi, [186](#), [187](#)

Hand, foot, and mouth disease (HFMD), [120–121](#), [120–121](#)

Hart's line, [176](#)

Head lice, [144](#), [144](#)

Henoch–Schönlein purpura, [69](#)

Hepatic porphyrias, [81](#)

Herald patch, [116](#), [116](#)

Herpes simplex virus (HSV), [113–115](#), [114](#)

- eczema (dermatitis), [29](#), [29](#)
- genital dermatoses, [180](#)
- HIV/AIDS, [126–127](#), [127](#)
- morphology, [9](#)

Herpes zoster ophthalmicus (HZO), [115](#)

HFMD *see* [hand, foot, and mouth disease](#)

Hidradenitis suppurativa (HS), [102–103](#), [102](#)

Hirsutism, [53](#), [163](#), [163](#), [163](#)

Histoplasmosis, [153](#), [153](#)

HIV/AIDS, [123–129](#)

- bacterial infections, [126](#), [126–127](#)
- drug rashes, [129](#), [129](#)
- fungus infections, [125–126](#), [126](#)
- introduction, [123–124](#)
- parasitic infestations, [128–129](#), [129](#)
- skin disorders in HIV, [124–125](#), [124–125](#)
- stages of HIV, [124](#), [124](#)
- viral infections, [126–128](#), [127–128](#)

Honey dressings, [237](#)

Hormonal imbalances, [77–78](#), [78](#), [96](#)

Hormone therapies, [100](#)

HPV *see* [human papillomaviruses](#)

HS *see* [hidradenitis suppurativa](#)

HSV *see* [herpes simplex virus](#)

Human immunodeficiency virus *see* [HIV/AIDS](#)

Human papillomaviruses (HPV)

- genital dermatoses, [180–181](#), [180–181](#)
- malignant skin lesions, [198](#)
- warts, [117–119](#), [118](#), [128](#), [128](#), [172](#), [208](#)

Hyaluronic acid (HA), [223–225](#), [226](#)

Hydrocolloid dressings, [236](#)

Hydrofibre dressings, [236](#)

Hydrogel dressings, [235–236](#)

Hyperhydrosis, [227](#)

Hyperkeratosis

- malignant skin lesions, [199](#)
- nails, [165–166](#), [166](#)
- psoriasis, [13](#), [15](#)

Hyperkeratotic papules, [128–129](#)

Hyperkeratotic periungual warts, [118](#)

Hyperpigmentation

- cosmetic dermatology, [229](#)
- lichen planus, [71](#), [71](#)
- systemic disease, [77](#), [78](#), [82–83](#), [82](#)

Hypertension, [91](#), [91](#)

Hypertrichosis, [53](#), [163–164](#), [164](#), [164](#)

Hypertrophic lichen planus, [3](#), [3](#)

Hypopigmentation

- anatomy and physiology, [7](#)
- cosmetic dermatology, [229](#)
- eczema (dermatitis), [29](#), [29](#)
- fungal infections, [135](#)
- systemic disease, [77](#), [82](#), [82](#)
- tropical dermatology, [148](#)

HZO *see* [herpes zoster ophthalmicus](#)

Ichthammol, [20](#)

Ichthyosis vulgaris (IV), [85](#), [85](#)

Id reaction, [133](#), [133](#)

IH *see* [infantile haemangioma](#)

ILVEN *see* [inflammatory linear verrucous epidermal naevus](#)

IMF *see* [immunofluorescence](#)

Imiquimod, [119](#), [247](#)

Immune-mediated rashes, [52](#)

Immune reconstitution inflammatory syndrome (IRIS), [114–115](#), [127](#), [127](#)

Immunobullous/blistering disorders, [59–66](#)

- anatomy and physiology, [3](#), [4](#)
- bacterial infections, [107](#), [107](#)
- clinical features, [61–64](#), [61–64](#), [61](#)
- differential diagnosis, [60](#), [60](#)
- insect bites and stings, [139](#), [140](#)
- introduction, [59](#)
- investigation, [64](#), [64](#), [65](#)
- management, [65–66](#)
- morphology, [8](#), [8–9](#)
- pathophysiology, [59–60](#)
- viral infections, [120–121](#), [120](#)

Immunofluorescence (IMF), [64](#), [65](#), [68](#)

Immunotherapy, [119](#)

Impetigo, [107](#), [107](#)

Incisional biopsy, [211](#), [211](#)

Induration, [9](#)

Infantile acne, [98](#)

Infantile haemangioma (IH), [188](#), [189](#)

Infection

eczema (dermatitis), [30–31](#), [30](#)

genital dermatoses, [180](#)

leg ulcers, [90–93](#), [93](#)

systemic disease, [75–77](#), [76–77](#)

systemic treatment, [249–250](#), [249](#)

topical treatment, [247](#), [248](#)

wound management, [234](#), [236](#)

see also [bacterial infections](#); [fungal infections](#); [HIV/AIDS](#); [parasitic infestations](#); [viral infections](#)

Inflammation

eczema (dermatitis), [27](#)

genital dermatoses, [179](#)

leg ulcers, [92](#), [92](#)

morphology, [8–9](#)

psoriasis, [16–17](#), [17](#)

systemic disease, [79](#)

Inflammatory linear verrucous epidermal naevus (ILVEN), [192](#), [193](#)

Inflammatory polymorphs, [11–12](#)

Infliximab, [25–26](#)

Ingenol mebutate, [247](#)

Injectable fillers, [223–226](#), [225–226](#)

Inoculation herpes, [114](#)

Insect bites and stings, [139](#)–[142](#)
 allergic reaction to bites, [140](#)–[141](#)
 delusions of parasitosis, [140](#), [140](#)
 management of bite reactions, [141](#)
 morphology, [9](#)
 parasite transmission, [141](#), [141](#), [141](#)
 prevention of bites, [141](#)
 spider bites, [141](#)–[142](#), [142](#)
 treatment, [142](#)
 wasp and bee stings, [142](#)

Intense pulsed light (IPL), [215](#), [220](#)

Intradermal naevi, [186](#), [186](#)

Intradermal testing, [52](#)

Intra-epithelial neoplasia, [180](#)–[181](#), [180](#)–[181](#)

In vitro testing, [52](#)

IPL *see* [intense pulsed light](#)

IRIS *see* [immune reconstitution inflammatory syndrome](#)

Irritant contact dermatitis, [32](#)–[33](#), [35](#)

Irritant dermatitis, [166](#)–[167](#)

Irritant eczema, [7](#), [176](#)

Isotretinoin, [100](#)–[102](#), [100](#)–[101](#)

Itching and scratching, [37](#)–[38](#)

IV *see* [ichthyosis vulgaris](#)

Ixekizumab, [26](#)

JAK inhibitors, [37](#), [160](#)

Jessner's solution, [229](#)

Junctional naevi, [186](#), [186](#)

Kaposi's sarcoma (KS), [127](#)–[128](#), [128](#)

Keloid scars, [192](#), [192](#)

Keratoacanthoma, [198](#)–[199](#), [199](#)

Keratolytics, [247](#)

Kerion, [132](#), [133](#), [161](#), [161](#)

Koebner's phenomenon, [13](#), [15](#)

Koilonychia, [168](#)

Koplick's spots, [119](#), [119](#)

KS see [Kaposi's sarcoma](#)

Kytocel, [238](#)

Lamellar nail splitting, [167](#)

Larvae dressings, [237](#), [237](#)

Laser dermatology, [215](#)–[220](#)

- fractional laser treatment, [220](#)
- hair removal, [219](#)–[220](#)
- indications and laser selection, [216](#), [216](#)
- intense pulsed light, [215](#), [220](#)
- introduction, [215](#)
- laser–tissue interaction, [215](#)–[216](#)
- perioperative anaesthesia, [217](#)
- pigmented lesions, [218](#)–[219](#), [218](#)
- postoperative care, [217](#)
- preoperative assessment/complications, [216](#), [216](#)
- resurfacing skin, [220](#)
- safety issues, [217](#)
- tattoos, [219](#), [219](#), [219](#)
- vascular lesions, [217](#)–[218](#), [217](#)–[218](#)

LE see [lupus erythematosus](#)

Leg ulcers, [87–93](#)

arterial leg ulcers, [91](#), [91](#)

clinical features, [88–89](#)

diabetic/neuropathic ulcers, [92](#), [92](#)

infection, [90–93](#), [93](#)

introduction, [87](#)

local/topical treatment, [90–91](#), [90](#)

malignancy, [89](#), [93](#), [93](#)

pathology, [88](#), [88](#)

risk factors, [88](#), [89](#)

trauma, [93](#), [93](#)

venous leg ulcers, [87–91](#), [87–90](#)

Leiomyoma, [191](#), [191](#)

Lentigines (freckles), [184–185](#), [185](#), [228](#)

Lentigo maligna melanoma, [200–201](#), [201](#)

Lepromatous leprosy, [148](#)

Leprosy, [147–149](#), [148](#)

Lice, [144–145](#), [144–145](#), [180](#)

Lichenification

anatomy and physiology, [4](#), [4](#)

eczema (dermatitis), [28](#)

genital dermatoses, [176](#), [176](#)

Lichenoid drug eruptions, [55–56](#), [55](#)

Lichen planopilaris, [161](#), [162](#)

Lichen planus (LP), [71](#), [71](#)

anatomy and physiology, [3](#), [3](#)

genital dermatoses, [178](#), [178](#)

nails, [170](#), [170](#)

Lichen sclerosus (LS), [5](#), [177–178](#), [177–178](#)

Lichen simplex, [29](#), [30](#), [176](#), [176](#)

Linear immunoglobulin A disease, [64](#), [64](#), [179](#)

Lipido-colloid dressings, [236](#)

Lipodermatosclerosis, [89](#), [89](#)

Lipoma, [191](#), [191](#)

Lipschutz ulcer, [179](#)

Liver disease, [81](#), [81](#)

Loiasis, [154](#), [155](#)

Longitudinal nail splitting, [167](#), [167](#)

Low-adherent dressings, [235](#)

LP see [lichen planus](#)

LS see [lichen sclerosus](#)

Lupus erythematosus (LE), [71](#)–73, [72](#)–73

- clinical variants, [71](#)–72
- drug rashes, [55](#), [55](#)
- management, [72](#)–73
- nails, [170](#), [170](#)

Lupus vulgaris, [110](#), [110](#)

Lyme disease, [141](#), [141](#)

Lymphatic filariasis, [154](#)

Lymphoedema, [89](#), [89](#), [154](#)

Macule, [3](#), [3](#)

Maculopapular exanthems, [54](#)

Madura foot, [151](#), [152](#)

Malabsorption deficiencies, [79](#)

Male pattern hair loss, [158](#)–159, [158](#)

Malignant skin lesions, [195–205](#)
basal cell carcinoma, [196–198](#), [197–198](#)
cutaneous lymphoma, [7](#), [204–205](#), [204](#)
dysplastic naevi, [199](#), [200](#)
introduction, [195](#)
laser dermatology, [218](#)
leg ulcers, [89](#), [93](#), [93](#)
metastatic disease, [205](#)
naevi, [199](#)
Paget’s disease of the nipple, [205](#), [205](#)
pre-malignant skin tumours, [195–196](#), [195–196](#)
significance of skin disease, [2](#)
systemic disease, [83–84](#), [83–84](#)
see also [melanoma](#); [squamous cell carcinoma](#)

Martorell ulcer, [91](#), [91](#)

Matrix metalloproteinase (MMP), [238](#)

MCTD *see* [mixed connective tissue disease](#)

Measles, [119](#), [119](#)

Medicated paste bandages, [240](#)

Melanocytic naevi, [185–187](#), [185–187](#)

Melanoma, [200–204](#)
incidence, [200](#)
nails, [172–173](#), [173](#)
pre-existing moles, [200](#)
prognosis, [202](#), [203](#)
significance of skin disease, [2](#), [2](#)
sun exposure, [200](#)
treatment, [202–204](#)
types, [200–202](#), [200–202](#)

Melanonychia, [169](#), [169](#)

Melanosis, [179](#), [180](#)
Melasma, [77](#), [78](#)
Metastatic disease, [2](#), [205](#)
Methotrexate, [23–24](#), [250](#)
Microneedling, [230](#)
Milia, [190](#), [191](#)
Minoxidil, [158](#)
Mixed connective tissue disease (MCTD), [74](#)
MMF *see* [mycophenolate mofetil](#)
MMP *see* [matrix metalloproteinase](#)
Mohs' micrographic surgery, [214](#)
Moles *see* [naevi](#)
Molluscum contagiosum, [117](#), [117](#), [128](#), [128](#)
Mongolian blue spot, [186](#), [186](#)
Morbilliform rash, [75–76](#), [76](#)
Morphoea, [70](#), [70](#)
Morphoeic basal cell carcinoma, [197](#), [198](#)
Mosaicism, [85–86](#), [85–86](#)
Mucous membrane pemphigoid, [62–63](#), [62–63](#), [65](#)
Multidermatomal shingles, [4](#)
Multiple spider nevi, [81](#)
Multiple telangiectasia, [70–71](#), [70](#)
Mycetoma, [151](#), [152](#)
Mycobacterial disease, [110–111](#), [110–111](#)
Mycophenolate mofetil (MMF), [23–24](#), [251](#)
Mycosis fungoides, [83](#), [83](#), [204](#), [204](#)
Myxoid pseudocysts, [172](#), [172](#)

Naevi

- benign skin tumours, [185–188](#), [185–187](#), [189](#), [192](#), [192–193](#)
- genital dermatoses, [179](#)
- laser dermatology, [218](#)
- malignant skin lesions, [199–200](#), [200](#)
- nails, [172](#)

Naevus flammeus neonatorum, [188](#), [188](#)

Naevus sebaceous, [192](#), [192](#)

Nails, [165–174](#)

- bed changes, [168](#), [168](#)
- common dermatoses of the nail unit, [169–170](#), [169–170](#)
- drug rashes, [54](#)
- fungal infections, [135–136](#), [135–136](#)
- general diseases affecting the nails, [172–173](#), [172–173](#)
- infection, [171](#), [171](#)
- introduction, [165](#)
- plate changes, [166](#), [166](#), [168–169](#), [169](#)
- psoriasis, [12–14](#), [13](#), [15](#)
- section through finger, [165](#)
- shape, surface, and attachment changes, [160](#), [165–168](#), [166–169](#)
- trauma, [171–172](#), [172](#)
- treatment of nail conditions, [173–174](#)

Napkin psoriasis, [16](#), [16](#)

Necrobiosis lipoidica, [78](#), [78](#)

Necrosis, [68](#), [232](#), [234](#)

see also [pyoderma gangrenosum](#)

Necrotising fasciitis, [109](#)

Nemolizumab, [37](#)

Neonatal lupus erythematosus (NLE), [7](#), [72](#), [73](#)

Neuropathic ulcers, [92](#)

NFALD see [non-alcoholic fatty liver disease](#)

Nickel allergy, [4](#)

NLE see [neonatal lupus erythematosus](#)

Nodular basal cell carcinoma, [196–197](#), [197](#)

Nodular melanoma, [201](#), [201](#)

Nodular prurigo, [125](#), [125](#)

Nodules

anatomy and physiology, [3](#), [3](#)

benign skin tumours, [191–192](#), [191–192](#)

Kaposi's sarcoma, [128](#)

Non-adherent dressings, [235](#)

Non-alcoholic fatty liver disease (NFALD), [18](#)

Non-immune-mediated rashes, [52](#)

Occlusion, [37](#)

Occupational dermatitis, [34–35](#), [35](#)

Oculocutaneous albinism, [44](#)

Odour-controlling dressings, [236](#)

OHL see [oral hairy leukoplakia](#)

Oily spot, [166](#)

Onchocerciasis, [154–155](#), [155](#)

Onycholysis, [166](#), [166](#), [169](#)

drug rashes, [54](#)

psoriasis, [12–14](#), [13](#), [15](#)

Onychomadesis, [121](#), [121](#), [167](#)

Onychomycosis, [135–136](#), [135–136](#)

Oral hairy leukoplakia (OHL), [127](#), [127](#)

Oral prednisolone, [37](#)

Ordinary urticaria, [39–40](#), [40–41](#)

Orf, [117](#), [117](#)

Paediatric dermatology, [142](#), [143](#)

Paget's disease

eczema (dermatitis), [31](#), [31](#)

extra-mammary Paget's disease, [181](#)

of the nipple, [205](#), [205](#)

Palmo-plantar pustular psoriasis (PPPP), [14](#), [16](#)

PAN see [polyarteritis nodosa](#)

Papilloma, [208](#)

Papules

anatomy and physiology, [3](#), [3](#)

benign skin tumours, [189](#)–190, [190](#)–191

genital dermatoses, [176](#)

Papulovesicular acrodermatitis of childhood, [76](#)

Paraneoplastic bullous pemphigoid, [6](#)

Paraneoplastic pemphigus (PNP), [66](#)

Parapsoriasis, [83](#)–84

Parasitic infestations, [142](#)–145, [143](#)–145

genital dermatoses, [180](#)

HIV/AIDS, [128](#)–129, [129](#)

insect bites and stings, [141](#), [141](#), [141](#)

tropical dermatology, [153](#)–155, [153](#)–155

Paronychia, [171](#)

PASI see [psoriasis area severity index](#)

Patch testing, [35](#)–36, [36](#), [52](#)

Patient information/compliance, [242](#)–243

PCOS see [polycystic ovarian syndrome](#)

PCT see [porphyria cutanea tarda](#)

PDI see [psoriasis disability index](#)

PDT see [photodynamic therapy](#)

Pearly penile papules, [176](#)

Pemphigoid gestationis (PG)

clinical features, [61](#)–[62](#), [62](#)

management, [65](#)

systemic disease, [84](#), [84](#)

Pemphigus foliaceus (PF), [60](#)

Pemphigus vulgaris

anatomy and physiology, [6](#)

clinical features, [63](#), [63](#)

genital dermatoses, [179](#)

management, [65](#)–[66](#)

pathophysiology, [59](#)–[60](#)

Penile pain, [181](#)

PEP see [polymorphous eruption of pregnancy](#)

Perioral dermatitis, [97](#), [97](#)

Periungual fibrokeratomas, [173](#)

Periungual tissues, [167](#)–[168](#), [171](#), [171](#)

Perniosis, [69](#), [69](#), [92](#), [92](#)

Peutz–Jehgers syndrome, [80](#)–[81](#)

PF see [pemphigus foliaceus](#)

PG see [pemphigoid gestationis](#)

Phenol, [229](#)

PHMB see [polyhexamethylene biguanide](#)

Photodermatitis, [33](#)–[34](#), [34](#)

Photodynamic therapy (PDT), [220](#)–[221](#), [221](#)

Photosensitivity, [43–49](#)
dermatomyositis, [73](#)
drug rashes, [52–53](#), [52](#), [53](#)
history and clinical examination, [44](#)
medications causing photosensitivity, [46](#), [46](#), [46](#)
oculocutaneous albinism, [44](#)
photodermatoses, [44](#), [47–48](#), [47–48](#)
phytophotodermatitis, [46–47](#), [47](#)
pigmentation and Fitzpatrick skin type, [43–44](#)
porphyrias, [45](#)
sun protection behaviour and sunscreens, [48](#)
ultraviolet radiation, [43](#), [43](#)
vitamin D levels and sun protection, [48](#)
xeroderma pigmentosum, [44–45](#)

Phototherapy/photochemotherapy

acne, [97](#), [100](#)
alopecia, [160](#)
eczema (dermatitis), [37](#)
formulary, [249](#)
porphyrias, [45](#)
psoriasis, [21–23](#), [22–23](#)

Phytophotodermatitis, [46–47](#), [47](#)

Piebaldism, [82](#), [82](#)

Piedra, [151](#)

Pigmentation and pigmented lesions

benign skin tumours, [184–185](#), [184–185](#)

drug rashes, [53](#), [53](#)

genital dermatoses, [179](#), [180](#)

laser dermatology, [218–219](#), [218](#)

malignant skin lesions, [197](#), [197](#), [199](#)

nails, [168–169](#), [169](#), [172–173](#), [173](#)

photosensitivity, [43–44](#)

see also [hyperpigmentation](#); [hypopigmentation](#)

Pilar cysts, [191](#)

Pilomatrixoma, [191–192](#)

Pitting, [12–14](#), [13](#), [15](#), [160](#), [165](#), [166](#), [169](#)

Pityriasis alba, [29](#), [29](#)

Pityriasis amiantacea, [164](#)

Pityriasis rosea (PR), [116–117](#), [116](#)

Pityriasis versicolor, [135](#), [135](#)

Plantar dermatitis, [29](#), [29](#)

Plaques

anatomy and physiology, [3](#), [4](#)

benign skin tumours, [192](#), [192–193](#)

genital dermatoses, [176](#), [177](#), [180](#)

immunobullous/blistering disorders, [62](#)

psoriasis, [11–13](#), [13–14](#), [22](#)

PLLA *see* [poly-L-lactic acid](#)

PMLE *see* [polymorphous light eruption](#)

PMMA *see* [polymethylmethacrylate](#)

PNP *see* [paraneoplastic pemphigus](#)

Podoconiosis, [154](#)

Podophyllin, [118–119](#)

Poikiloderma, [84](#), [84](#)

Polyarteritis nodosa (PAN), [69](#), [69](#)

Polycystic ovarian syndrome (PCOS), [96](#)

Polyhexamethylene biguanide (PHMB), [238](#)

Poly-L-lactic acid (PLLA), [225](#)

Polymethylmethacrylate (PMMA), [225](#)

Polymorphous eruption of pregnancy (PEP), [84](#), [84](#)

Polymorphous light eruption (PMLE), [47](#), [47](#)

Polyurethane foam dressings, [236](#)

Pompholyx eczema, [29](#), [30](#)

Poroma, [192](#), [192](#)

Porphyria cutanea tarda (PCT), [45](#), [45](#), [81](#), [81](#)

Port wine stain, [188](#), [188](#), [217–218](#), [217–218](#)

Poxviruses, [117](#), [117](#), [128](#), [128](#)

PPPP *see* [palmo-plantar pustular psoriasis](#)

PR *see* [pityriasis rosea](#)

Prednisolone, [37](#)

Pregnancy, [84](#), [84](#)

Premalignant skin tumours, [195–196](#), [195–196](#)

Pressure urticaria, [41](#)

Pretibial myxoedema, [78](#), [79](#)

Pruritis, [37–38](#)

- management, [38](#)
- pruritis ani/vulvae, [38](#)
- with normal skin, [38](#)
- with skin changes, [37–38](#)

Pseudofolliculitis, [108](#), [108](#)

Pseudopelade of Brocq, [162](#), [162](#)

Psoralen with ultraviolet A (PUVA) therapy, [21–23](#), [22–23](#), [160](#)

Psoriasis, [11](#)–[18](#)

assessment of the patient, [9](#)–[10](#), [9](#)

biological treatment, [23](#), [25](#)–[26](#), [25](#), [252](#)–[253](#)

cardiovascular disease, [17](#)

cellular abnormalities, [12](#), [13](#)

clinical appearance, [12](#)–[13](#), [13](#)

clinical features, [1](#), [1](#)

clinical presentation, [13](#)–[16](#), [14](#)–[16](#)

dermatology day treatment units, [19](#)–[20](#)

drug rashes, [54](#)

epidemiology, [11](#)

genital dermatoses, [176](#), [177](#)

HIV/AIDS, [125](#)

introduction, [11](#)–[12](#)

management, [19](#)–[26](#)

nails, [160](#), [166](#), [166](#), [169](#)

non-alcoholic fatty liver disease, [18](#)

pathogenesis and pathophysiology, [11](#), [12](#)

phototherapy/photochemotherapy, [21](#)–[23](#), [22](#)–[23](#)

psoriatic arthritis, [16](#)–[17](#)

scalp psoriasis, [21](#), [21](#), [164](#), [164](#)

systemic treatment, [23](#)–[24](#), [24](#)

topical treatment, [20](#)–[21](#), [21](#), [247](#), [248](#)

treatment options and considerations, [19](#), [20](#)

typical patient, [13](#)

Psoriasis area severity index (PASI), [19](#)

Psoriasis disability index (PDI), [19](#)

Psoriatic arthritis (PA), [16](#)–[17](#), [17](#)

Pterygium, [170](#)

Pubic lice, [145](#), [145](#), [180](#)

Punch biopsy, [210](#), [210–211](#)

Pustules

anatomy and physiology, [4](#), [5](#)

drug rashes, [57–58](#), [57](#)

nails, [167–168](#)

psoriasis, [13–14](#), [16](#)

PUVA *see* [psoralen with ultraviolet A](#)

Pyoderma gangrenosum

anatomy and physiology, [5](#)

leg ulcers, [92](#), [92](#)

systemic disease, [79](#), [80](#)

Pyogenic granuloma, [189](#), [190](#)

Radiofrequency, [230](#)

Rashes

assessment of the patient, [9–10](#)

clinical approach to diagnosis, [5–6](#)

clinical features, [1](#)

diagnosis, [6–7](#)

distribution, [7–8](#)

drug rashes, [51–58](#)

insect bites and stings, [141](#)

morphology, [8–9](#)

symmetry, [6](#)

systemic disease, [75–77](#)

viral infections, [119–121](#), [119–121](#)

Raynaud's phenomenon, [70](#)

Reiter's syndrome, [179](#)

Resurfacing skin, [220](#)

Reticulate lesions, [4](#), [7](#)

Retinoids, [100–102](#), [100–101](#), [251–252](#), [251](#)

Rhinophyma, [101](#), [101](#)

Ringworm, [132](#)

Rituximab, [65–66](#), [253](#)

Rocky mountain spotted fever (RMSF), [111–112](#), [112](#)

Rosacea, [101–102](#), [101–102](#)

Roseola infantum, [120](#)

Rubber sensitivity, [242](#)

Rubella, [119–120](#), [120](#)

Salicylic acid, [99](#), [118](#), [229](#)

Sarcoidosis, [77](#), [77](#)

Scabies, [128–129](#), [129](#), [142–144](#), [143](#), [180](#)

Scaling, [13–14](#), [134–135](#), [134–135](#)

Scalp

- fungal infections, [132–134](#), [132–134](#)
- psoriasis, [13](#), [15](#), [21](#), [21](#), [164](#), [164](#)
- seborrhoeic dermatitis, [164](#), [164](#)

SCAR *see* [severe cutaneous adverse reaction](#)

Scarring, [97–98](#), [98](#), [230](#)

SCC *see* [squamous cell carcinoma](#)

SCLE *see* [subacute cutaneous lupus erythematosus](#)

Sclerotic plaques, [177](#)

SD *see* [seborrhoeic dermatitis](#)

Sebaceous gland hyperplasia, [190](#), [191](#)

Seborrhoeic dermatitis (SD)

- fungal infections, [133–134](#), [134](#)
- genital dermatoses, [176](#)
- HIV/AIDS, [124](#), [124](#)
- skin disease involving the scalp, [164](#), [164](#)

Seborrhoeic keratoses, [184](#), [184](#), [208](#)

Secondary syphilis, [112](#), [112](#)

Secukinumab, [26](#)

Sentinel lymph node biopsy (SLNB), [203](#)

Severe cutaneous adverse reaction (SCAR) syndromes, [51–52](#)

Sézary syndrome, [83](#), [83](#)

Shave biopsy, [210](#)

Shiitake mushroom flagellate dermatosis, [79](#), [80](#)

Shingles, [115](#), [115](#)

Single gene disorders, [85–86](#), [85–86](#)

SJS *see* [Stevens–Johnson syndrome](#)

Skin grafts, [91](#)

Skin substitutes, [238–239](#), [239](#)

Skin tags, [184](#), [185](#), [208](#)

Skin tightening devices, [230](#)

Skin wrinkle lines, [212](#)

SLE *see* [systemic lupus erythematosus](#)

SLNB *see* [sentinel lymph node biopsy](#)

Sloughy wounds, [232](#), [233](#)

Soft tissue augmentation, [223–226](#), [225–226](#)

Solar urticaria, [41](#), [47](#)

Spider bites, [141–142](#), [142](#)

Spider telangiectasia, [188–189](#), [189](#)

Spitz naevi, [186](#), [187](#)

Splinter haemorrhages, [12](#), [172](#)

Sporotricoid spread, [111](#), [111](#)

Squamous cell carcinoma (SCC), [198](#)–199
clinical presentation and investigations, [198](#), [198](#)–199
genital dermatoses, [178](#)
keratoacanthoma, [198](#)–199, [199](#)
leg ulcers, [89](#), [93](#), [93](#)
management, [199](#)
nails, [173](#)
pre-malignant skin lesions, [195](#)–196

SSc *see* [systemic sclerosis](#)

Staphylococcus scalded skin syndrome (SSSS), [109](#)–110, [110](#)

Stevens–Johnson syndrome (SJS), [56](#)–57, [56](#), [56](#)

Stomatitis, [136](#)

Strawberry naevi, [188](#), [189](#)

Stress, [96](#)–97

Sturge–Weber syndrome, [188](#), [188](#)

Subacute cutaneous lupus erythematosus (SCLE), [55](#), [55](#), [72](#), [72](#)

Subcutaneous myiasis, [153](#), [154](#)

Subungual exostosis, [173](#), [173](#)

Subungual hyperkeratosis, [12](#), [13](#), [165](#)

Sun protection/sunscreens, [48](#), [247](#)–248

Super-absorbent dressings, [237](#)–238

Superficial basal cell carcinoma, [197](#), [197](#), [220](#)–221, [221](#)

Superficial spreading melanoma, [200](#), [200](#)–201

Surgical excision, [211](#)–214
skin wrinkle lines, [212](#)
suturing, [213](#), [213](#)
technique, [212](#)–213, [212](#)

Swimming pool granuloma, [111](#), [111](#)

Syphilis, [112](#), [112](#), [126](#), [127](#)

Syringoma, [189](#), [190](#)

Systemic disease, [75–86](#)

gastrointestinal disorders, [78–81](#), [80](#)

genetics, [84–86](#), [85–86](#), [85](#)

hormonal imbalances, [77–78](#), [78](#)

infections, [75–77](#), [76–77](#)

introduction, [75](#)

leg ulcers, [92–93](#)

liver disease, [81](#), [81](#)

malignancy, [83–84](#), [83–84](#)

pigmentation, [77](#), [78](#), [82–83](#), [82](#)

pregnancy and the skin, [84](#), [84](#)

thyroid disease, [78](#), [79](#), [79](#)

Systemic lupus erythematosus (SLE), [71–73](#), [72](#)

Systemic sclerosis (SSc), [70–71](#), [70](#)

Systemic treatment

acne, [100–101](#), [100–101](#)

alopecia, [160](#)

bacterial infections, [107](#)

eczema (dermatitis), [37](#)

formulary, [249–252](#), [249](#), [251](#)

fungal infections, [135–138](#)

infection, [249–250](#), [249](#)

malignant skin lesions, [203](#)

nails, [173](#)

psoriasis, [23–24](#), [24](#)

viral infections, [114–116](#)

Tacalcitol, [20–21](#)

Tattoos, [219](#), [219](#), [219](#)

TCA see [trichloroacetic acid](#)

Telangiectasia, [101–102](#)

Telogen effluvium, [160](#)–[161](#), [161](#)

TEN *see* [toxic epidermal necrolysis](#)

Thickened nail, [169](#)

Thyroid disease, [78](#), [79](#), [79](#)

Tick bites, [141](#), [141](#)

Tinea capitis, [132](#), [132](#)–[133](#), [161](#), [161](#)

Tinea corporis, [134](#)–[135](#), [134](#)

Tinea cruris, [134](#)–[135](#), [135](#)

Tinea imbricata, [151](#), [151](#)

Tinea incognito, [133](#), [133](#)

Tinea pedis, [134](#), [134](#)

Topical negative pressure (TNP) dressings, [237](#), [238](#)

Topical treatment

- acne, [99](#)–[100](#)
- alopecia, [160](#)
- bacterial infections, [107](#), [248](#)
- eczema (dermatitis), [36](#)–[37](#), [38](#)
- formulary, [245](#)–[248](#), [246](#)–[247](#), [246](#)
- fungal infections, [134](#)–[137](#), [248](#)
- leg ulcers, [90](#)–[91](#), [90](#)
- psoriasis, [20](#)–[21](#), [21](#), [247](#), [248](#)
- viral infections, [114](#), [248](#)

Toxic epidermal necrolysis (TEN)

- drug rashes, [52](#), [56](#)–[57](#), [56](#), [56](#)
- HIV/AIDS, [129](#), [129](#)

Toxic erythema, [75](#)–[76](#), [76](#)

Transverse nail splitting, [167](#)

Transverse ridges, [166](#)

Trauma

leg ulcers, [93](#), [93](#)

nails, [171](#)–172, [172](#)

Trichloroacetic acid (TCA), [229](#)

Trichoepithelioma, [190](#), [190](#)

Trichothiodystrophy, [45](#)

Tropical dermatology, [147](#)–155

bacterial infections, [147](#)–150, [148](#), [150](#)

deep fungal infections, [151](#)–153, [152](#)–153

fungal infections, [137](#), [137](#)

introduction, [147](#)

parasitic infestations, [153](#)–155, [153](#)–155

superficial fungal infections, [150](#)–153, [151](#)–153, [151](#)

True leukonychia, [169](#)

Tuberculoid leprosy, [148](#)

Tubular bandages, [240](#)

Tungiasis, [153](#), [153](#)

Ulceration

anatomy and physiology, [4](#), [5](#)

genital dermatoses, [179](#), [179](#)

leg ulcers, [87](#)–93

Urticaria and angio-oedema, [39–42](#)
 cholinergic urticaria, [41](#)
 classification of urticaria, [39–40](#)
 clinical history, [39](#), [40](#)
 clinical presentation of angio-oedema, [41](#), [42](#)
 drug rashes, [54–55](#), [54](#)
 general investigations, [42](#)
 general management, [42](#)
 introduction, [39](#)
 ordinary urticaria, [39–40](#), [40–41](#)
 pathophysiology, [39](#)
 pressure urticaria, [41](#)
 solar urticaria, [41](#), [47](#)

Urticarial vasculitis, [39](#), [40](#)

Ustekinumab, [26](#)

Vaccination, [115–117](#), [203–204](#)

Variant xeroderma pigmentosum, [45](#)

Varicella zoster virus (VSV), [115–117](#), [115–116](#)

Varicose veins, [88](#), [88](#)

Vasculitis

- anatomy and physiology, [7](#)
- clinical presentation, [67](#), [68](#)
- drug rashes, [55](#), [55](#)
- Henoch–Schönlein purpura, [69](#)
- investigation, [68](#)
- leg ulcers, [92](#), [92](#)
- management, [69](#)
- pathophysiology, [68](#)
- polyarteritis nodosa, [69](#), [69](#)

Venous leg ulcers, [87–91](#), [87–90](#)

Venous (stasis) eczema, [29–30](#), [30](#), [88–89](#), [89](#)

Verrucas, [118](#)

Vesicles, [3](#), [4](#), [8](#), [8–9](#)

Vestibular papillae, [175](#)

Viral infections, [113–121](#)

- herpes simplex virus, [113–115](#), [114](#)
- HIV/AIDS, [126–128](#), [127–128](#)
- introduction, [113](#)
- poxviruses (molluscum contagiosum), [117](#), [117](#), [128](#), [128](#)
- rashes, [119–121](#), [119–121](#)
- varicella zoster virus, [115–117](#), [115–116](#)
- wart viruses (HPV), [117–119](#), [118](#), [128](#), [128](#), [172](#), [208](#)

Visible ageing, [223](#), [224](#)

Vitamin C deficiency, [79](#)

Vitamin D deficiency, [48](#)

Vitiligo, [82](#), [82](#)

VSV *see* [varicella zoster virus](#)

Vulval pain, [181](#)

Wart viruses, [117–119](#), [118](#), [128](#), [128](#), [172](#), [208](#)

Wasp stings, [142](#)

Wound management, [231–243](#)

- assessment, [231](#), [232](#)
- bandages, [239–243](#), [241–242](#)
- clinical classification, [233–234](#)
- dressings, [233–235](#), [235–239](#), [235](#), [237–239](#)
- healing continuum, [232](#), [232](#)
- introduction, [231](#)
- patient information/compliance, [242–243](#)
- types of wound, [232–235](#)
- wound bed preparation, [231–232](#)

Xanthomas, [81](#), [81](#)

Xeroderma pigmentosum (XP), [44](#)–45

Yeast infections, [135](#)–137, [137](#)

Yellow nail syndrome, [168](#)–169, [169](#)

Zinc deficiency, [79](#), [80](#)

Zoophilic fungi, [132](#), [132](#)

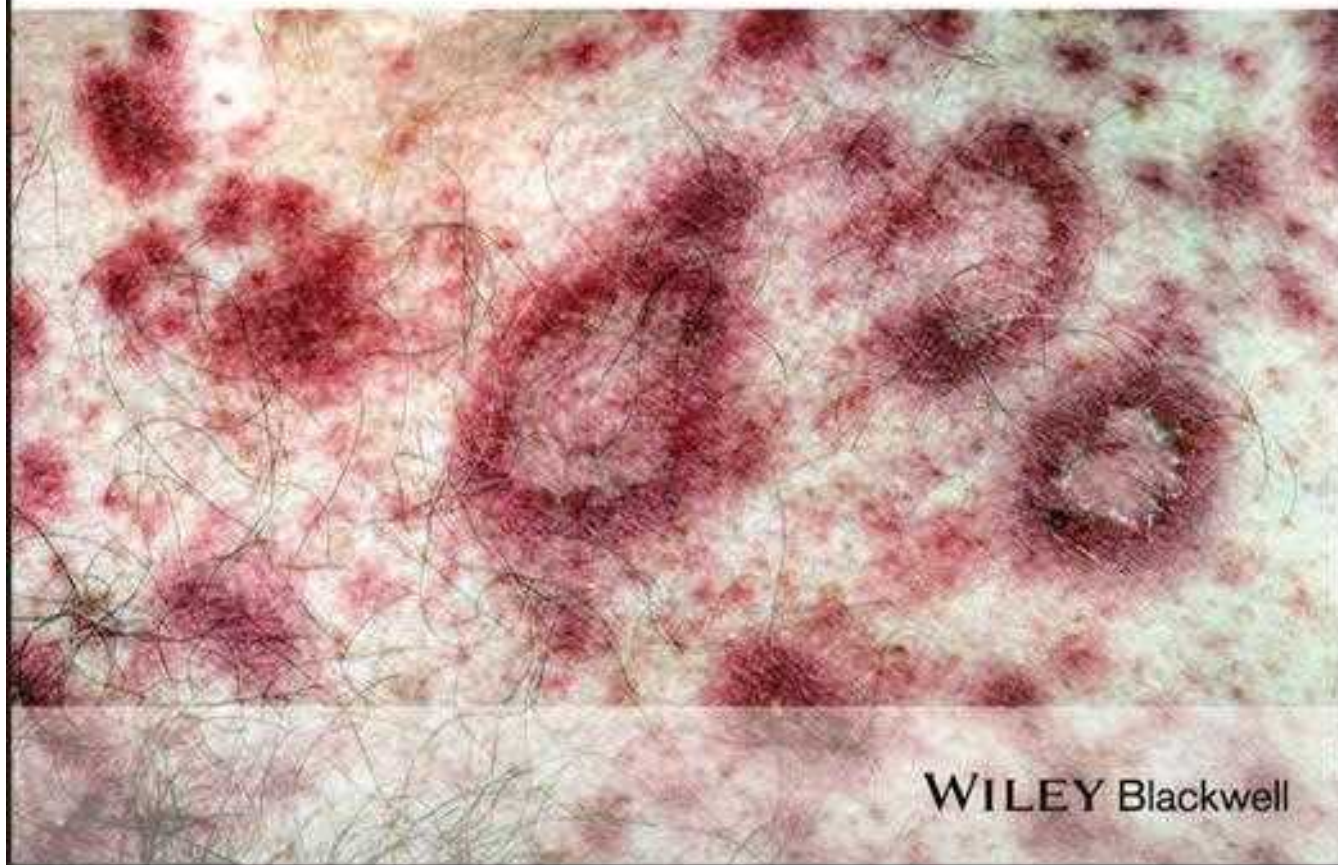WILEY END USER LICENSE AGREEMENT

Go to www.wiley.com/go/eula to access Wiley's ebook EULA.

ABC of Dermatology

SEVENTH EDITION

Edited by Rachael Morris-Jones



WILEY Blackwell