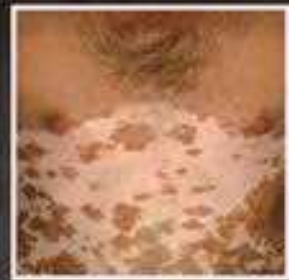
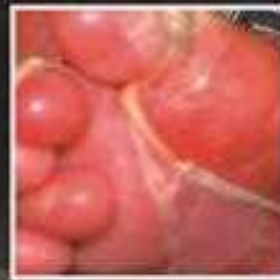
Illustrated Synopsis of
Dermatology
and Sexually
Transmitted Diseases

FOURTH EDITION



Neena Khanna

Illustrated Synopsis of
Dermatology
and
Sexually Transmitted Diseases

"This page intentionally left blank"

Illustrated Synopsis of
Dermatology
and
Sexually Transmitted Diseases
Fourth Edition

Neena Khanna, MD

Professor

Department of Dermatology and Venereology

All India Institute of Medical Sciences

New Delhi, India



ELSEVIER

A division of

Reed Elsevier India Private Limited

Illustrated Synopsis of Dermatology and Sexually Transmitted Diseases, 4/e

Neena Khanna

ELSEVIER

A division of

Reed Elsevier India Private Limited

Mosby, Saunders, Churchill Livingstone, Butterworth-Heinemann and Hanley & Belfus are the Health Science imprints of Elsevier.

© 2011 Elsevier

First Edition 2005

Second Edition 2008

Third Edition 2009

Fourth Edition 2011

All rights are reserved. No part of this publication may be reproduced, stored in a retrieval system, or transmitted in any form or by any means, electronic, mechanical, photocopying, recording, or otherwise without the prior permission of the publisher.

ISBN: 978-81-312-2802-9

Medical knowledge is constantly changing. As new information becomes available, changes in treatment, procedures, equipment and the use of drugs become necessary. The author, editors, contributors and the publisher have, as far as it is possible, taken care to ensure that the information given in this text is accurate and up-to-date. However, readers are strongly advised to confirm that the information, especially with regard to drug dose/usage, complies with current legislation and standards of practice. *Please consult full prescribing information before issuing prescriptions for any product mentioned in this publication.*

Published by Elsevier, a division of Reed Elsevier India Private Limited.

Registered Office: 622, Indraprakash Building, 21 Barakhamba Road, New Delhi-110 001.

Corporate Office: 14th Floor, Building No. 10B, DLF Cyber City, Phase II, Gurgaon-122 002, Haryana, India.

Managing Editor (Development): Shabina Nasim

Development Editor: Shravan Kumar

Copy Editor: Shrayosee Dutta

Manager Publishing Operations: Sunil Kumar

Manager Production: NC Pant

Production Executive: Arvind Booni

Typeset by Chitra Computers, Delhi

Printed and bound at Thomson Press, Delhi.

Dedicated to

*the three people
I miss immensely*

My Dad,

who had the tenacity to survive all handicaps,

My Teacher,

Prof. LK Bhutani

who academically honed many of us

and

My Sister,

Sunita

who was an epitome of life and verve.

"This page intentionally left blank"

Preface to the Fourth Edition

About the book ...

The importance of Dermatology cannot ever be overemphasized. A quarter of a general practitioner's patients are 'dermatological', and it is necessary for the physician to be well-versed with the presentations of common skin diseases. It is equally important to remember that the skin manifestation may be a clue to the patient's internal disease.

The book is nothing but a simplified and brief journey through skin diseases, peppered with numerous clinical pictures, illustrations, and tables—the basic aim being to familiarize medical students and general practitioners with the plethora of common skin conditions they are likely to encounter and to help them in handling these correctly and not to succumb to the morbid temptation of prescribing steroids—often thought to be 'panacea of all skin ills'.

About this edition ...

"A picture is worth a thousand words" is an apt description for Dermatology, because it is a visual specialty. So it is necessary for any dermatology textbook to be more of an atlas rather than just full of text. And that is the reason that about 100 new pictures have been added in this new edition.

Neena Khanna

"This page intentionally left blank"

Acknowledgements

There are some people whom I cannot thank enough

My Teachers

- ❖ Professor (Late) LK Bhutani, who honed our clinical skills during our training and in his charming way admonished us to ‘click’ the lesion.
- ❖ Professor RK Pandhi, who was a friend and mentor during our training and afterwards too!
- ❖ Professor JS Pasricha, who insisted we write what we see.

This book, in a sense, is a tribute to them all. I owe so-so much to them!

My Family

- ❖ My father, who overcame several handicaps with his discipline and perfection and who was to a large measure responsible for what I am doing today.
- ❖ My mother, who believed that education is the only true wealth and one is never too old to learn.
- ❖ Anil, my better half (!) who has always been a mountain (literally!) of support.
- ❖ My mother-in-law, who believes (wrongly though!) that I am a perfectionist.
- ❖ My sister Sunita, for always believing in my ability.
- ❖ My bacchas, Chandni and Abhishek who have accepted the book as another sib, and are now showing signs of intense sibling rivalry!!
- ❖ And my pug Cuddles, for quietly sitting at my ‘charan’ like an obedient son and giving me constant company while I worked on the manuscript (and thankfully not showing any sibling rivalry!).

For this edition

Several people helped with this edition:

My Colleagues

- ❖ Dr. Seema, Divya, Ishita and Neetu for nit picking the lous(e)y initial manuscript and giving suggestions that culminated in the present shape of the book.
- ❖ The feedback of undergraduate students has always helped in more ways than one.

Office Staff

- ❖ Meenu who has worked endlessly on all editions.
- ❖ Tanu who worked on this edition.
- ❖ Munni for keeping the papers sorted.

My Publisher

Several people from Elsevier helped the new edition see the light of day—

- ❖ Rohit and Vidhu for their constructive optimism.
- ❖ Shabina, Shukti, Shrayosee and Shravan for their editorial expertise (and gentle pressurising!!) and ability to put up with an intrusive author!
- ❖ Swaroop and Thakur saab for typesetting.
- ❖ Sunil and Arvind for overseeing the production.

Neena Khanna

"This page intentionally left blank"

Contents

<i>Preface</i>	<i>vii</i>
<i>Acknowledgement</i>	<i>ix</i>
1. Introduction.....	1
2. Diagnosis of Skin Diseases.....	3
3. Genodermatology and Genodermatoses.....	19
4. Papulosquamous Disorders.....	39
5. Bullous Disorders.....	67
6. Eczematous Dermatitis.....	85
7. Disorders of Skin Appendages.....	109
8. Disorders of Pigmentation.....	145
9. Diseases of Cutaneous Vasculature.....	161
10. Abnormal Vascular Responses.....	173
11. Cutaneous Response to Physical Stimuli.....	191
12. Adverse Drug Reactions.....	205
13. Autoimmune Connective Tissue Diseases.....	217
14. Infections.....	241
15. Sexually Transmitted Infections and HIV Infection.....	299
16. Skin Diseases Caused by Arthropods, Worms, and Protozoa.....	335
17. Nevi and Skin Tumors.....	349
18. Cutaneous Manifestations of Internal Diseases.....	381
19. Treatment of Skin Diseases.....	397
<i>Index</i>	421

"This page intentionally left blank"

Chapter Outline

About this Book

A patient with a skin problem usually presents first to her family physician. As a matter of fact, a quarter of family physician's practice is "dermatological." More often than not, the physician is foxed with the rash, sometimes diagnoses it as allergy and almost always treats it with steroids—often topical, sometimes systemic, and occasionally both. This ignorance is primarily because the medical students often focus on the more rewarding (marks wise) undergraduate subjects and give Dermatology a step motherly treatment. Students would rather prefer to study the nuances of electroencephalogram (something, they may never again see in their career) than learn about mundane (though ubiquitous) skin diseases like scabies. The "Dermatology" posting is taken as one of those "extra, not to be regularly attended" postings. And of course everyone believes that steroids are panacea for all "skin ills".

However, of late, greater awareness of one's appearance and the "skin obsession" have made dermatology an important discipline to be pursued seriously. It is necessary for both the physician and the medical student to be well-versed with skin diseases.

This book is an endeavor to cover the common conditions of dermatology that students are likely to encounter and will need to be updated upon.

About this Book

The Fourth edition is a little different from the Third—though the book continues to focus on common dermatoses, treatment of many has been updated.

The dermatoses have been discussed in such a way to simplify understanding as well as to facilitate learning by:

- ❖ Encapsulating a synopsis; this gives the gist of what is to follow.
- ❖ By breaking the discussion on diseases into:
 - Etiology: Usually illustrated with tables.

- Epidemiology.
 - Clinical features:
 - Morphology, illustrated with clinical pictures.
 - Sites of predilection, illustrated with body diagram.
 - Variants.
 - Complications.
 - Course.
 - Investigations: Often, skin biopsy is illustrated with line diagrams and histopathology.
 - Diagnosis: The salient diagnostic features are re-emphasized. The differential diagnosis is discussed in a tabular form.
 - Treatment is generally discussed as:
 - General measures.
 - Topical measures.
 - Systemic measures.
- “Rare Skin Disorders” have been discussed on the companion Website <http://www.manthan.info/>, and some cutaneous manifestations relevant to the internist have been included.

Chapter Outline

History Taking[•]

Presenting complaints

Past history

Family history

Other history

Examination[•]

Environment for examination

Basic morphology of lesions

Secondary changes

Further description of lesions

Sites of predilection

Investigations[•]

Simple but necessary tools

Some important investigations

The diagnosis of skin diseases depends on the accurate use of the lexicon of dermatology, on the ability to identify the primary and secondary skin lesions, and to recognize various patterns formed by them. The challenge lies in being able to discern normal from the abnormal, in the ability to differentiate one lesion from another and to distinguish one pattern of distribution from another. In an era when clinical diagnosis has been relegated to the back seat by the availability of a plethora of lab tests, in dermatology a good history and a detailed physical examination retain unquestionable importance.

History Taking

A good history is an important tool in our armamentarium and should include questions of special significance in relation to the skin disease as well as a succinct enquiry concerning major systemic symptoms.

Presenting Complaints

Patients present to the dermatologist with a variety of complaints, which can be grouped as:

- ❖ **Subjective symptoms:** Which cannot be seen by physician and include symptoms like itching, pain, and paresthesia (Table 2.1).
- ❖ **Objective symptoms:** Which can be seen by a doctor and include symptoms like rash, ulcers, hair fall (or growth), changes in nails, etc. (Table 2.2).

For each symptom, the following questions should be asked:

- ❖ **Duration:** Is the problem acute or chronic? If chronic, about relapses and remissions.
- ❖ **Site of first involvement:** And spread.
- ❖ **Evolution:** Of lesions.
- ❖ **Diurnal variation:** In most dermatoses, itching is generally more severe at night because the patient's mind is not diverted. But in sun-induced dermatosis, the itching is logically worse during the day.

[•]Should know

Table 2.1. Detailed history of subjective symptoms

Symptoms	Itching	Pain	Paresthesia
Diurnal variation			
❖ Nocturnal ↑ ❖ Daytime ↑	Scabies Photo-dermatoses ¹		
Seasonal variation			
❖ Summer ↑ ❖ Winter ↑	Miliaria Fungal infections Insect bites Ichthyosis Psoriasis Scabies Chilblains	Systemic sclerosis	
Precipitated by			
❖ Exercise ❖ Cold	Cholinergic urticaria Cold urticaria	Intermittent claudication Raynaud's phenomenon	
Associated features			
❖ Rash ❖ Wheals ❖ Cyanosis ❖ Hypopigmented lesions	Drug rash Urticaria	Herpes zoster Raynaud's phenomenon	Leprosy

Table 2.2. Detailed history of objective symptoms

Type of skin lesions	Macules, papules, plaques, vesicles, pustules
Associated symptoms	
❖ Itching ❖ Pain	Drug rash Herpes zoster
Seasonal aggravation	
❖ Winter ❖ Summer/rainy season	Ichthyosis, psoriasis, seborrheic dermatitis Fungal infections, bacterial infections, insect bites
Sites of involvement	
❖ Face, back ❖ Extensors, pressure points ❖ Scalp, nasolabial folds, flexors ❖ Photo exposed parts	Acne Psoriasis Seborrheic dermatitis Photosensitive eruption

❖ **Precipitating factors:**

- Exercise precipitates cholinergic itching and cholinergic urticaria.
- Many dry, scaly and ichthyotic disorders are worse in winter and so is the associated itching.

- Sun exposure aggravates photodermatoses.
- Drugs may precipitate a rash, *e.g.*, fixed drug eruption.

❖ **Relieving factors:**

- Response to withdrawal of antigens (drugs, chemicals) points to an “allergic” reaction.
- ❖ **Associated features:** Ask for history of rash, wheals, cyanosis, gangrene, hypopigmented lesions, neuritis and sensory impairment. Also for nail changes, hair loss, and involvement of palms, soles, scalp, and mucosae (all!).

Past History

- ❖ Any medication received recently should be noted, including regular or intermittent self-medication.
- ❖ Any past illness (medical, surgical) and therapy, thereof, are important in drug eruptions.
- ❖ History of medical disorders like diabetes, hypertension, tuberculosis, seizures is relevant. The dermatosis could be a manifestation of the disease or could be an adverse effect of the drug used to treat the disease.
- ❖ Past exposure to *Mycobacterium tuberculosis* is important, when cutaneous tuberculosis is suspected.

Family History

Family history is important in patients with:

- ❖ Genetic disorders like ichthyosis, neurofibromatosis and epidermolysis bullosa.
- ❖ Infections and infestations, *e.g.*, scabies, pediculosis.
- ❖ Families who are exposed to similar environmental influences may also develop same problems, *e.g.*, arsenical keratoses.

Other History

Social, occupational, travel and recreational history may help the physician in reaching a diagnosis.

Examination

Before you begin, it is important to make the patient comfortable. Always examine in a room which is well-lit.

Skin lesions have to be described in three terms:

- ❖ Morphology (Table 2.3).
- ❖ Distribution.

1. **Photodermatoses:** increase in day time because of sun exposure.

Table 2.3. Terminology of skin lesions

Morphology	Small (<0.5 cm)	Large (>0.5 cm)
Flat lesions		
❖ Normal texture	Macule	Patch
❖ Indurated	Plaque	Plaque
Elevated lesions		
❖ Solid	Papule	Nodule
❖ Fluid filled	Vesicle	Bulla
❖ Pus filled	Pustule	Pustule
Indurated lesions (diameter>depth)	Plaque	Plaque
Lesions due to extravasation of blood	Petechiae	Ecchymosis

- ❖ Configuration.

Also always remember to examine nails, hair (and scalp) and mucosae (oral, genital and nasal).

Environment for Examination

- ❖ Examine patients in natural lighting. Oblique lighting may be necessary to detect subtle elevation of lesions, while subdued lighting enhances subtle changes in pigmentation.
- ❖ Expose the area affected and do not hesitate to ask the patient to undress if need be (in the presence of an attendant, if required). Do not let stubbornness, shyness or the sex of the patient put you off!
- ❖ Remove make-up if necessary.
- ❖ Magnification: An ordinary magnifying glass (5×, 10×) can provide much needed information.

Morphology of Lesions

Morphology of skin lesions is more important for reaching a diagnosis than their distribution. The initial (or characteristic) lesions of a disease are called **primary lesions**; these lesions are often modified by the scratch marks, ulcers and other events (**secondary changes**). The rule is to find out a primary lesion and study it closely and then note the secondary changes (Table 2.3).

Macules

- ❖ Macule is a circumscribed, flat lesion of skin, which is visible because of a change in skin

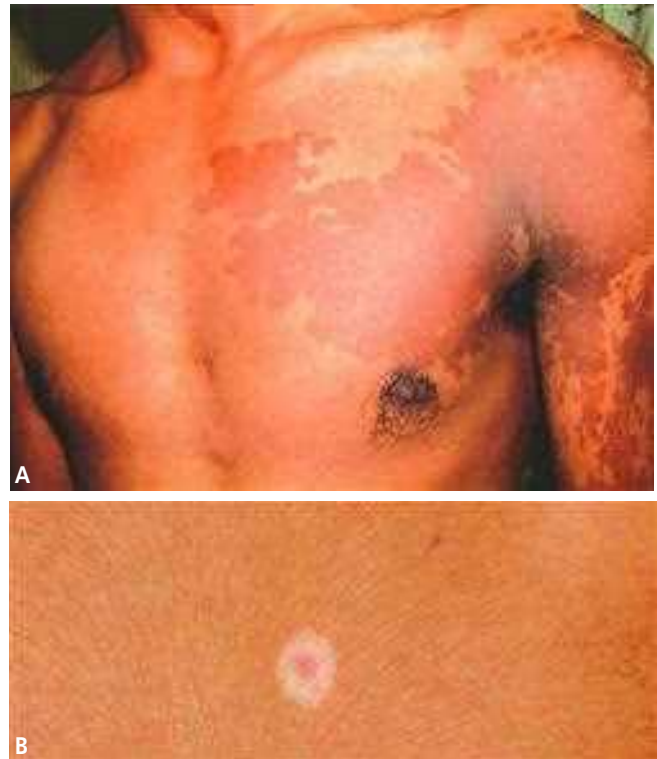


Fig. 2.1. Macule: circumscribed, flat lesion. A: hyperpigmented macule. B: depigmented macule.

color (Fig. 2.1). Not felt, as no change in skin texture.

- ❖ Macules may be well-defined or ill-defined and may be of any size.²
- ❖ A macule may be:
 - *Hyperpigmented*: e.g., fixed drug eruption, café au lait macule (Fig. 2.1A). Hyperpigmented macules may be:
 - Brown, if the melanin pigment is present in the epidermis, e.g., café au lait macule.
 - Slate gray or violaceous, if melanin is present in dermis (**Tyndall effect**)³ e.g., Mongolian spot.
 - Brownish grey, if melanin is present both in the epidermis and dermis, e.g., nevus of Ota (some patients).
 - *Hypopigmented*: when the lesion is less pigmented than the surrounding skin, e.g., leprosy. If the lesion is completely devoid of pigment it is labelled as depigmented, e.g., vitiligo (Fig. 2.1B), piebaldism.

2. **Macules**: a large macule is often referred to as **patch**.

3. **Tyndall effect**: scattering of different wavelengths of light to different degrees. Melanin present in dermis appears violaceous because of greater scattering of light of longer wavelengths (red), while violet is remitted back.

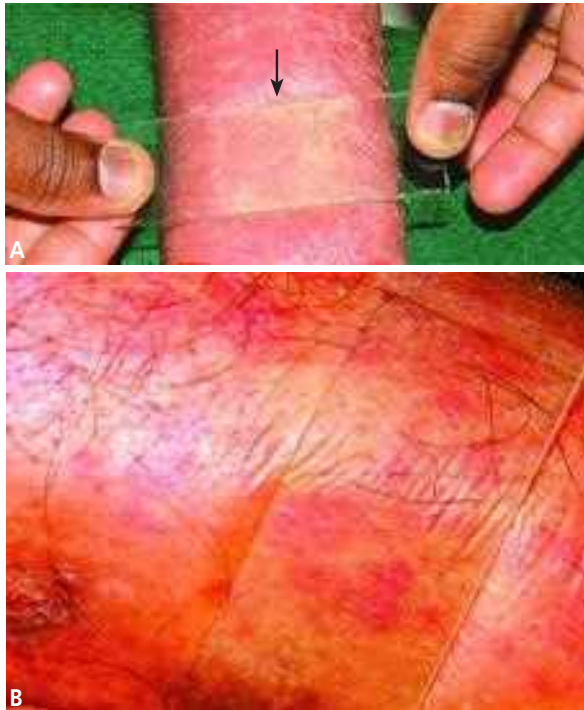

Fig. 2.2. Diascopy: helps to differentiate erythema due to vascular dilatation from that due to extravasation of RBCs. A: If redness disappears on applying pressure (arrow shows blanching) using a glass slide, it is due to vascular dilatation. B: If the redness stays, it is due to extravasation of RBCs (purpura).

- *Erythematous*: erythematous lesions can be due to vascular dilatation or extravasation of RBCs (purpura) and the two can be differentiated by **diascopy**⁴ (Fig. 2.2).

Papules

- ❖ Small, solid, elevated lesion, <0.5 cm in diameter (Fig. 2.3). A major portion of the papule projects above the skin.
- ❖ Papules can be due to:
 - Hyperplasia of cellular components of epidermis or dermis.
 - Metabolic deposits in dermis.
 - Cellular infiltrate in dermis.
- ❖ Papules may be surmounted by scales or crusts and may evolve into vesicles and pustules.

Nodules

- ❖ Solid lesions, >0.5 cm in diameter (Fig. 2.4).

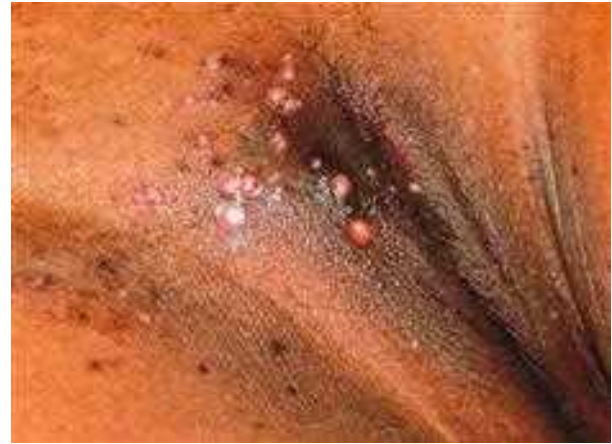

Fig. 2.3. Papule: solid, elevated lesion <0.5 cm in diameter.

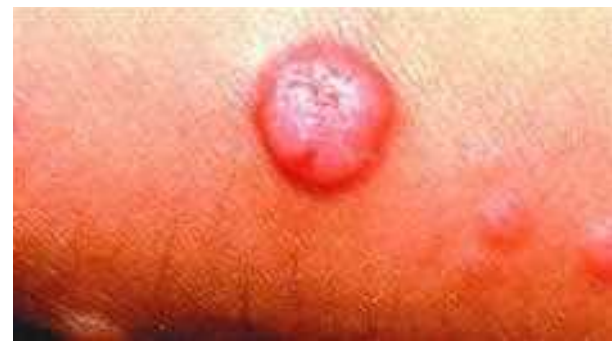

Fig. 2.4. Nodule: solid lesion, >0.5 cm in diameter.

- ❖ Have a deeper component and some nodules are better felt than seen.

Plaques

- ❖ An area of altered consistency of skin which is usually elevated, but can be depressed or flushed with surrounding skin.
- ❖ Are formed either by enlargement of individual papules or their confluence.
- ❖ Plaques (Fig. 2.5) may be discoid (uniformly thickened) or annular (ring shaped). Annular plaques can form either when center of a discoid plaque clears or due to confluence of papules.

Tumors

- ❖ Tumor implies enlargement of tissues, by normal or pathological material or cells, to form a mass (Fig. 2.6).

4. **Diascopy**: in erythematous macules, when firm pressure is applied using a glass slide, if the redness disappears, it is due to vascular dilatation and if it does not, it is due to extravasation of RBCs (purpura).

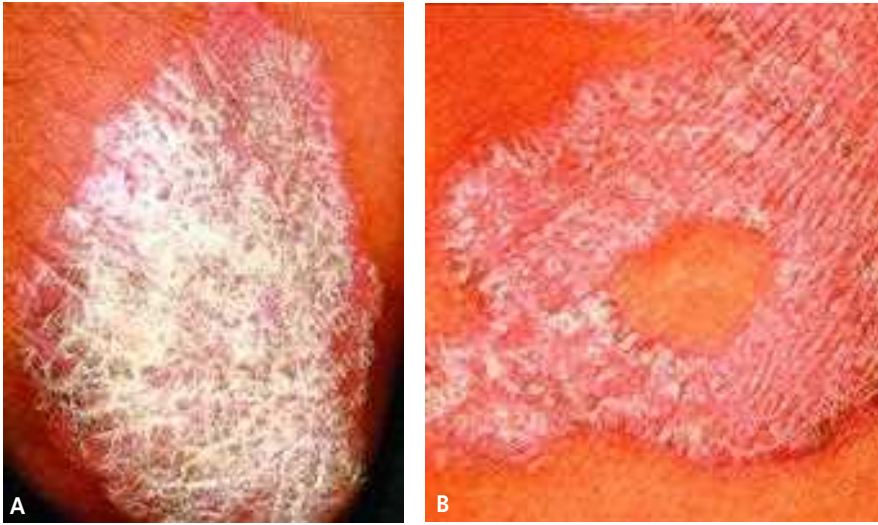


Fig. 2.5. Plaque: an area of altered consistency of the skin which could be elevated, depressed or flat. A: discoid plaque of psoriasis. B: annular plaque of psoriasis.

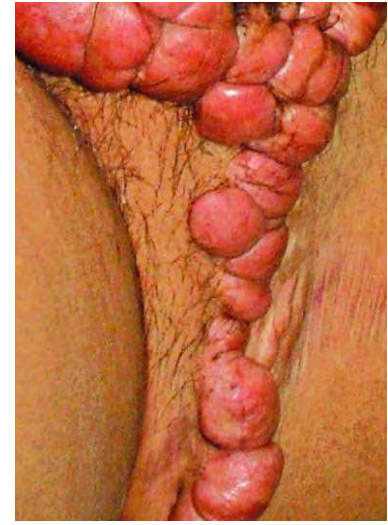

Fig. 2.6. Tumors: large nodules.

- ❖ Since this term may alarm the patient, it is better to use the term “large nodule” instead of tumor.

Blisters

- ❖ Blisters (**vesicles** and **bullae**) are fluid filled, circumscribed, elevated lesions, which form due to a split in the skin.
- ❖ If <0.5 cm in diameter, they are called **vesicles** (Fig. 2.7A) and if >0.5 cm in diameter, they are called **bullae** (Fig. 2.7B).

The characteristics of a bulla depend on the level of split (Table 2.4):

- ❖ **Subcorneal vesicle.**
- ❖ **Intraepidermal vesicle.**
- ❖ **Dermoepidermal vesicle.**

Pus-Filled Lesions

- ❖ **Pustule:** Is a pus-filled vesicle (Fig. 2.8). Pustules can be follicular (when they are conical) or extrafollicular. Sometimes, level of pus can be made out in a pustule.
- ❖ **Abscess:** Is pus-filled nodule, having a thick wall (Fig. 2.9). An abscess is usually deep seated with only a part of it visible on the surface.

Lesions Due to Dermal and Subcutaneous Edema

- ❖ **Wheal:** Is an evanescent (lasting 48–72 h) elevated lesion produced by dermal edema (Fig. 2.10A). This is usually white, surrounded by a red flare and subsides without any skin

Table 2.4. Characteristics of different bullae

	<i>Subcorneal</i>	<i>Intraepidermal</i>	<i>Dermoepidermal</i>
Level of split	Just below stratum corneum	In granular layer, spinous layer or suprabasal	At dermoepidermal junction
Characteristics			
❖ Ease of rupture	Very thin roof, so rupture very easily	Thin roof; rupture less readily	Thick roof; rupture least readily so persistent
❖ Flaccidity	Very flaccid	Usually flaccid	Usually tense
❖ Contents	Scanty fluid	Serous/turbid fluid	Serous/turbid often hemorrhagic fluid
❖ On rupturing	Form areas of scale crust. No erosions	Form erosions covered with crusts	Form erosions/ulcers covered with crusts, often hemorrhagic
❖ On healing	Normal skin	Hyperpigmentation	Milia and scarring
Examples	Pemphigus foliaceus Bullous impetigo	Pemphigus vulgaris	Bullous pemphigoid

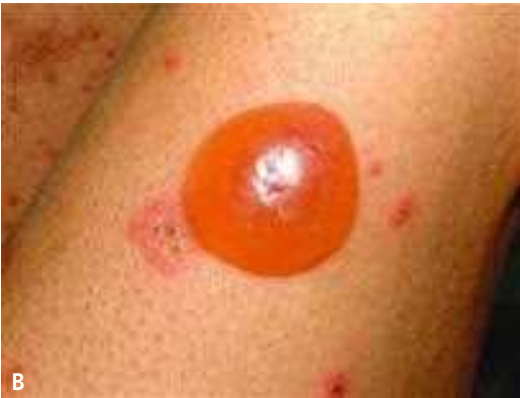
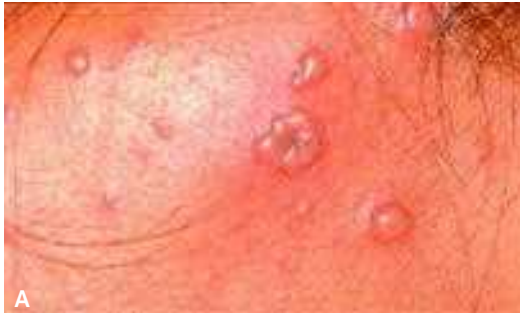
Fig. 2.7. Vesicles and bullae: circumscribed fluid-filled lesions. A: vesicles are <0.5 cm. B: bullae are >0.5 cm.

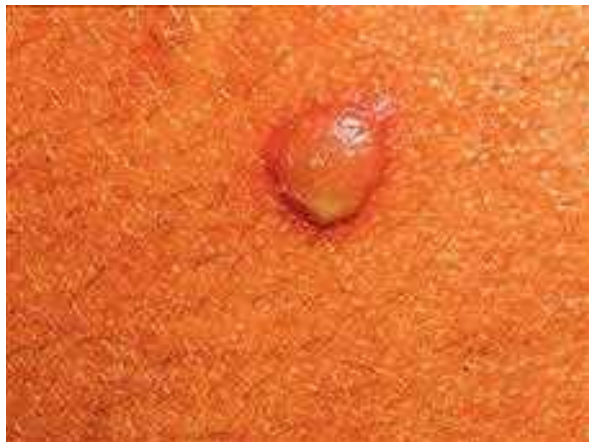

Fig. 2.8. Pustule: pus-filled hollow lesion. This one shows a distinct level of pus.

changes. When linear, called **dermographic urticaria** (Fig. 2.10B).

- ❖ **Angioedema:** Is a wheal which extends into the subcutaneous tissue and lasts >48 h. Most frequently occurs at the mucocutaneous junctions.

Lesions Due to Extravasation of Blood

- ❖ **Purpura:** Erythematous macule due to extravasation of RBCs into dermis. Lesion is not blanchable—meaning that if a glass slide

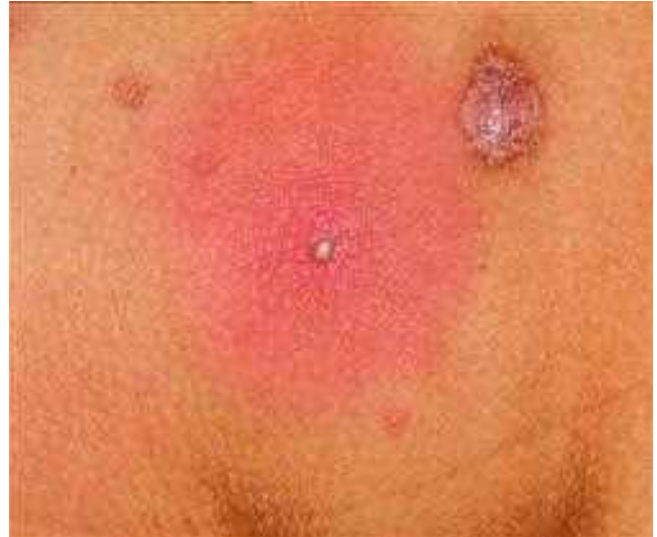

Fig. 2.9. Abscess: thick-walled collection of pus usually deep seated, with only a part of it visible on the surface.

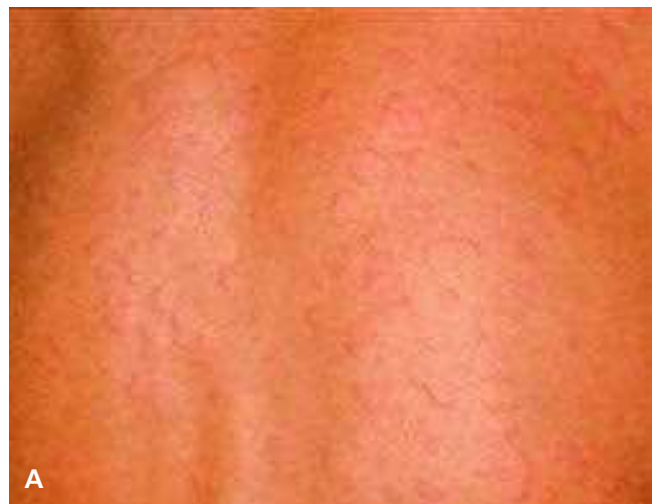

Fig. 2.10. Urticaria: evanescent elevated lesion lasting 48–72 hours. A: edematous evanescent lesions. B: linear wheals called dermographic urticaria.

is pressed on the lesion (**diascopy**), the erythema persists. Lesions <0.5 cm are called **petechiae** and >0.5 cm are called **ecchymosis** (Fig. 2.11).

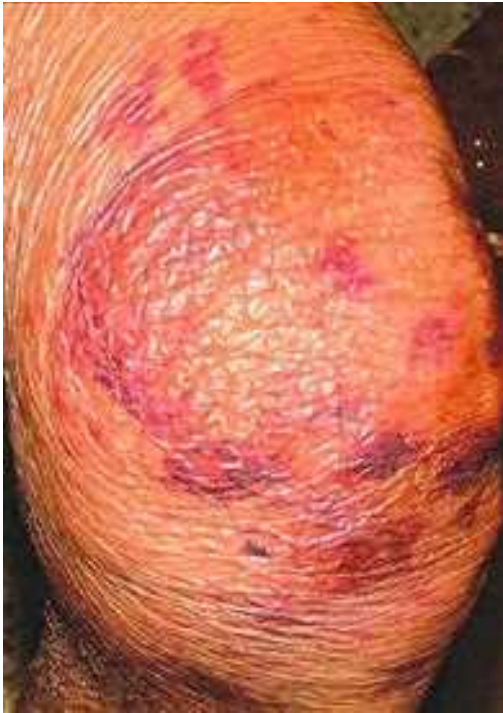

Fig. 2.11. Purpura: erythematous macules which do not blanch on diascopy.

- ❖ **Hematoma:** Is a swelling caused by extravasation of blood.

Lesions Due to Dilatation of Vessels

- ❖ **Telangiectasia:** Visible dilatation of small blood vessels of skin (Fig. 2.12). Characteristically seen on the face of a person chronically exposed to sun, in lupus erythematosus, in dermatomyositis (in periungual area), systemic sclerosis (mat-like telangiectasia on face) and rosacea.
- ❖ **Poikiloderma:** Triad of atrophy of skin, reticulate hyperpigmentation and telangiectasia (Fig. 2.13), seen in dermatomyositis and mycosis fungoides.

Specific Lesions

- ❖ **Burrow:** Is pathognomonic lesion of scabies. Appears as a serpentine, thread-like, grayish (or darker) curvilinear lesion, varying in length from a few millimeters to a centimeter (Fig. 2.14). The open end is marked by a papule. The burrow may be difficult to discern in dark-skinned individuals.
- ❖ **Comedones:** Comedones are inspissated plugs of keratin and sebum wedged in dilated pilosebaceous orifices. Comedones are typically

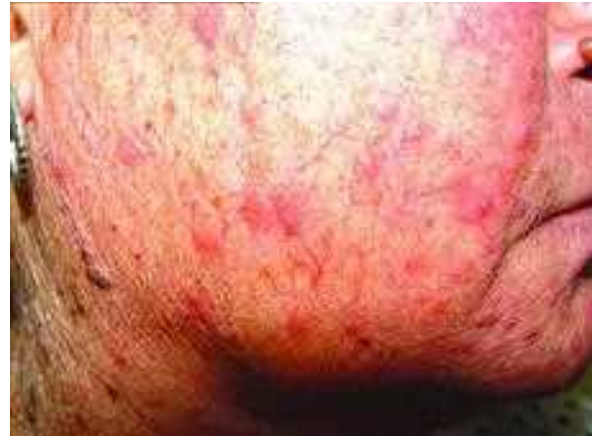

Fig. 2.12. Telangiectasia: dilated capillaries. Seen in rosacea and collagen vascular disorders.

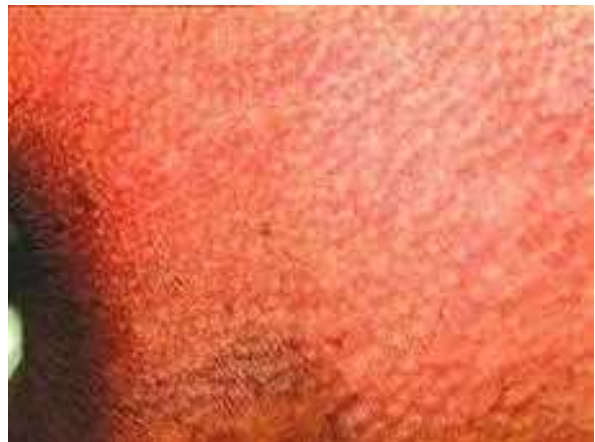

Fig. 2.13. Poikiloderma: triad of telangiectasia, atrophy of skin and reticulate pigmentation.

present in acne vulgaris, in nevus comedonicus and in senile comedones. There are two types of comedones:

- **Open comedone:** black head, in which the keratinous plug is black (Fig. 2.15A).
- **Closed comedone:** white head, in which the plug is covered by skin, so the lesion appears as a white shiny papule (Fig. 2.15B).

Secondary Changes

Secondary changes modify the primary lesions.

Due to Collection of Cells/Exudate

- ❖ **Scale:** Is a flake formed by collection of cells of horny layer of the skin (Fig. 2.16). Removal of scales reveals a dry surface. Scales may be characteristic in some diseases (Table 2.5).

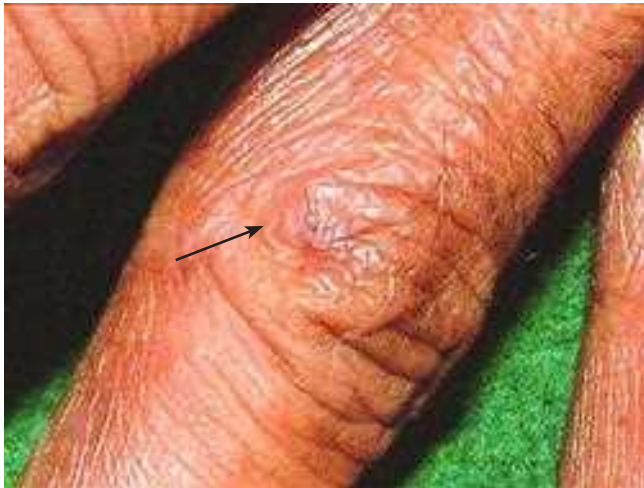

Fig. 2.14. Burrow: curvilinear lesion lodging the adult female mite.

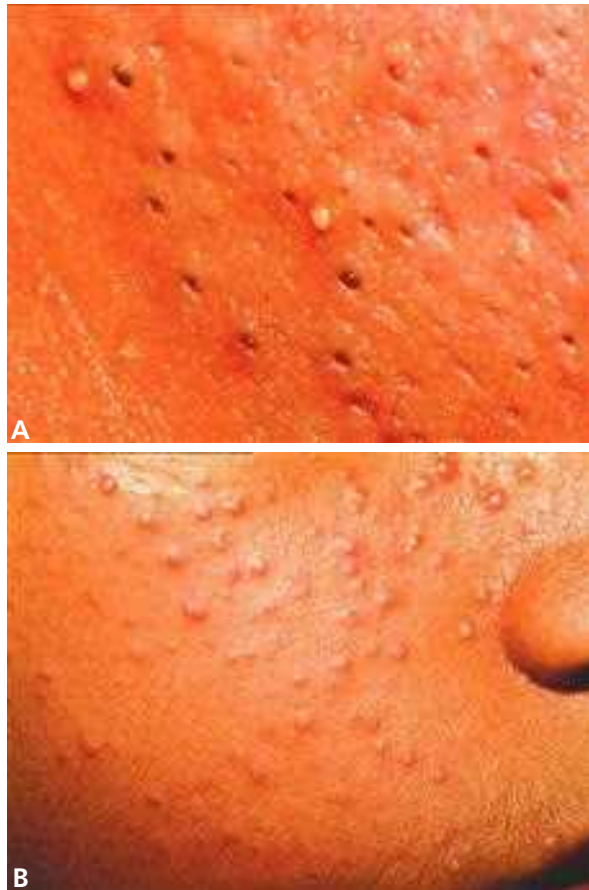


Fig. 2.15. Comedone is an inspissated plug of keratin and sebum wedged in a dilated pilosebaceous orifice. A: open comedones have black keratinous plugs. B: closed comedones appear as white, shiny papules.

❖ **Crust:** Is a collection of dead epidermal cells, dried serum and sometimes dried blood. It is yellow to

Table 2.5. Diagnostic significance of character of scale

Disease	Type of scale
Psoriasis	Silvery, easily removable
Pityriasis versicolor	Branny (fine)
Pityriasis rosea	Collarette
Ichthyosis	Fish-like
Pityriasis lichenoides chronica	Mica like, adherent

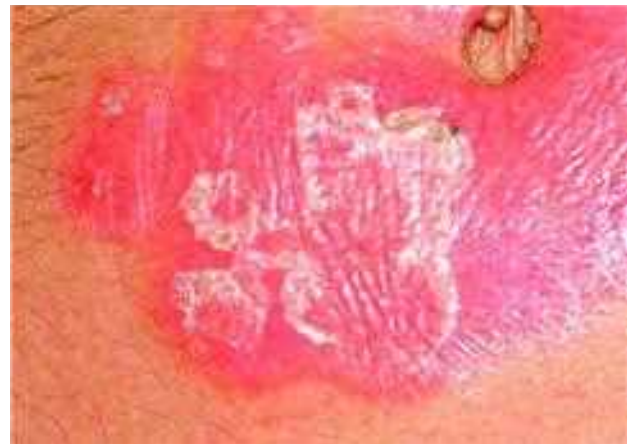

Fig. 2.16. Scales: flakes formed by collection of horny layer; loosely attached silver scales are typical of psoriasis.

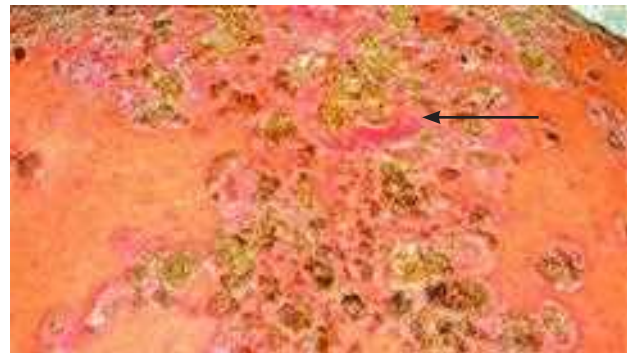


Fig. 2.17. Crust: yellow brown collection of keratin and serum. Note erosions from where crusts have been removed.

brown (sometimes hemorrhagic) in color. Removal of crust reveals a moist surface (Fig. 2.17).

Due to Loss of Continuity of Skin

❖ **Erosion:** Due to complete or partial loss of viable epidermis (Fig. 2.18) with no (or minimal) loss of the dermis (*cf.*, ulcer).

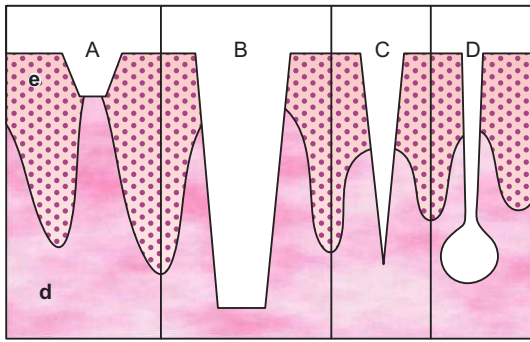


Fig. 2.18. Diagrammatic representation of erosion (A), ulcer (B), fissure (C) and sinus (D). **e**, epidermis; **d**, dermis.

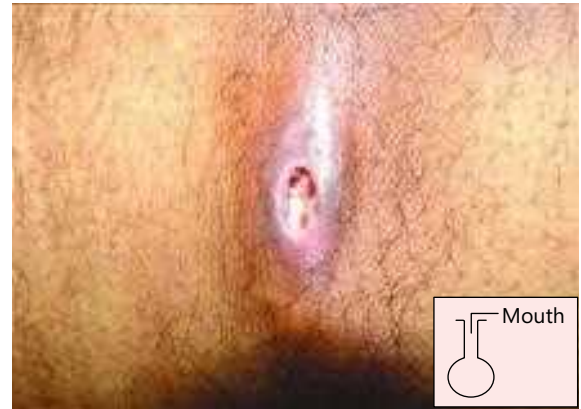

Fig. 2.20. Sinus: the mouth of this sinus is undermined indicating a tubercular etiology.

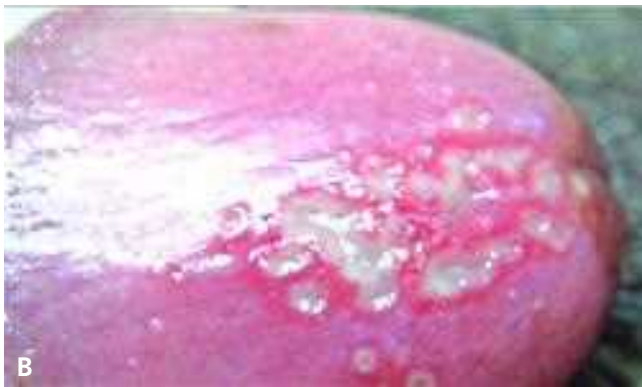
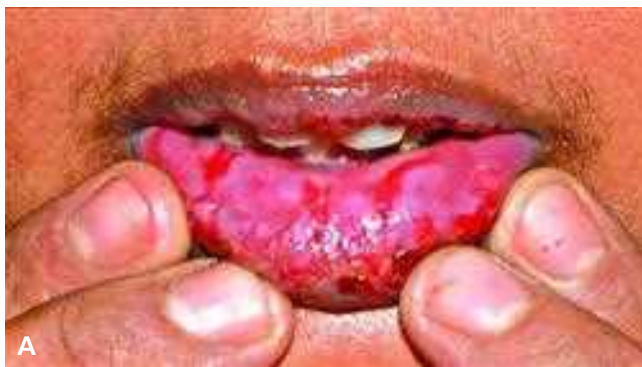
Fig. 2.19. A: Erosion: due to complete or partial loss of viable epidermis with no loss of the dermis. B: Ulcer: destruction of the epidermis and at least the upper (papillary) dermis.

- ❖ **Ulcer (Fig. 2.19):** Loss of epidermis and at least upper (papillary) dermis, though sometimes ulcer may extend into the deeper tissues. A complete description of ulcer should include its **site**, **shape**, **size**, **surface** (floor) and **surrounding** skin (the five **s**'s) and the two **b**'s, **base** and **border** (edge).
- ❖ **Fissure** : Is a slit in the epidermis.
- ❖ **Excoriation**: Is linear erosion or an ulcer, formed when skin is scratched.

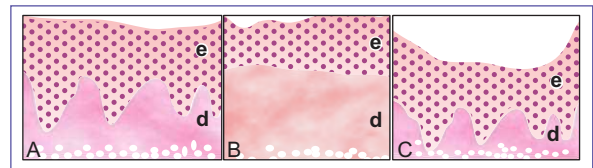


Fig. 2.21. A: normal skin. B: epidermal atrophy. C: dermal atrophy. **e**, epidermis; **d**, dermis.

- ❖ **Sinus**: Is a blind track in skin; opening of the sinus (mouth) should be examined as it may give a clue to diagnosis, *e.g.*, mouth of tubercular sinus is undermined and hyperpigmented (Fig. 2.20). Always look for the attachment of sinus to the underlying tissues.

Miscellaneous Changes

- ❖ **Atrophy (Fig. 2.21):** Thinning of skin and could be due to atrophy of the epidermis, dermis or subcutaneous tissue.
 - **Epidermal atrophy**: it manifests as thin, shiny skin, which may crinkle like cigarette paper and may show loss of surface markings, *e.g.*, in leprosy. In pure epidermal atrophy, the skin is not depressed because the mass of epidermis is small as compared to that of dermis (Fig. 2.21B).
 - **Dermal atrophy**: clinically manifests as an area of depressed skin and it may be possible to invaginate a finger in the depressed skin (Fig. 2.21C).
- ❖ **Lichenification**: Lichenification is the response of the skin to repeated scratching and is typically seen in lichen simplex chronicus and atopic dermatitis. It manifests as (Fig. 2.22):
 - Thickening of the skin.

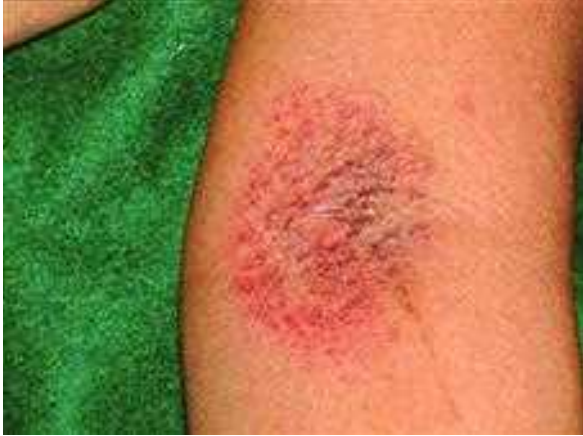

Fig. 2.22. Lichenification: thickening and hyperpigmentation of skin with increased skin marking.

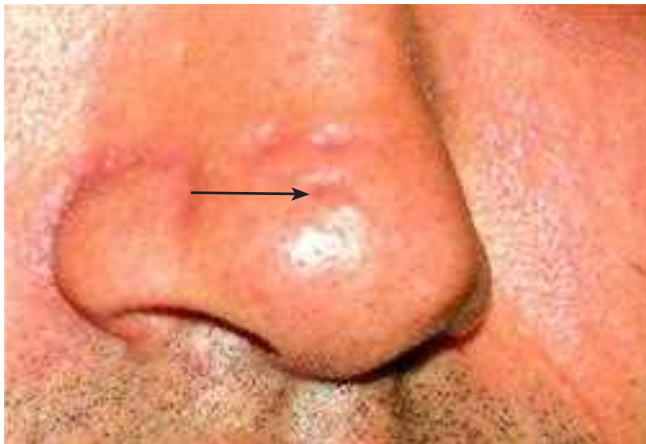

Fig. 2.23. Scars: depressed scar after pyoderma on the nose.

- Hyperpigmentation.
- Increased skin markings.
- ❖ **Scar:** In scar, normal structures of skin are replaced by fibrous tissue, which is not laid in an organized fashion. The normal skin markings are hence lost in a scar (Fig. 2.23). Scars are of two types:
 - *Atrophic scars:* characterized by loss of tissue.
 - *Hypertrophic scars:* characterized by increase in fibrous tissue.
- ❖ **Sclerosis:** Is diffuse or circumscribed induration of dermis/subcutaneous tissue, e.g., lichen sclerosus *et* atrophicus.
- ❖ **Changes in skin color:** Skin color can be darker (hyperpigmentation) or lighter (hypopigmenta-

Table 2.6. Differences between epidermal pigmentation and dermal pigmentation

Epidermal	Dermal
Brown	Slate gray
Enhanced by Wood's lamp ⁵	Not enhanced
Due to an increased number of melanocytes or increased melanin synthesis in epidermis	Due to the presence of melanocytes or increased melanin in dermis

tion/depigmentation). Increased pigmentation could be epidermal or dermal (Figs. 2.24A and B, Table 2.6).

Further Description of Lesions

Sharpness of Lesions

- ❖ Are the macules and plaques well-defined or ill-defined?
- ❖ Are the nodules well-defined? Deep-seated nodules (papules) appear ill-defined while superficial ones appear well-defined.

Shape/Configuration of Lesions

- ❖ **Papules and nodules:** Can have a variety of shapes (Table 2.7) and this may help in the diagnosis.
- ❖ **Plaques:** Can have different configuration (Table 2.8) and this may help in diagnosis.

Arrangement of Lesions

An important clue to the diagnosis of skin diseases is the arrangement of lesions (Table 2.9).

Sites of Predilection

- ❖ Distribution of lesions is an important clue to diagnosis (Table 2.10, Fig. 2.25). Remember, it is not only the areas of involvement but also the areas, which are spared that indicate diagnosis.
- ❖ The distribution of skin lesions depends on several factors:
 - *Exposure to triggers:* in contact dermatitis, the “rash” is limited to the sites of contact and in photodermatoses to photoexposed sites.
 - *Regional variations:* acne is predominantly localized to areas rich in sebaceous glands,

5. **Wood's lamp:** device which emits ultraviolet rays of wavelength 360 nm.

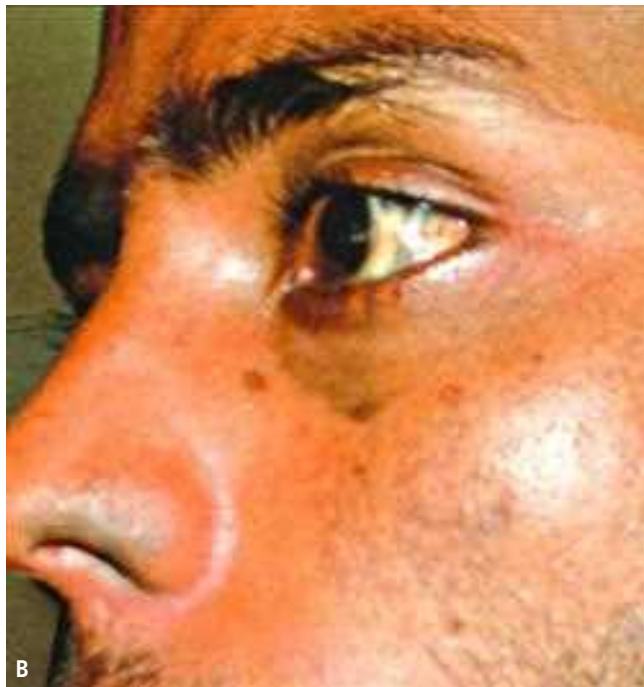
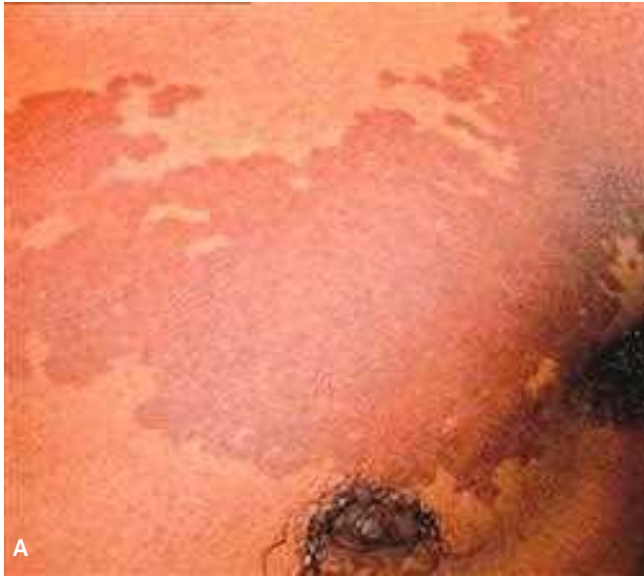
Fig. 2.24. Pigmentation: A: epidermal pigmentation is brown. B: dermal pigmentation is slate gray.

while diseases of apocrine glands are localized to axillae and pubic region.

- *Variations in blood supply:* e.g., vasculitic lesions on legs, stasis dermatitis on legs.
- *Variations in thickness of horny layer:* thin skin of eyelids is more susceptible to developing contact dermatitis than palms and soles because horny layer is thin on the lids.

Table 2.7. Vertical profile of skin lesions







Shape	Example
Dome shaped	 Trichoepithelioma
Flat topped	 Plane warts
Umbilicated	 Molluscum contagiosum
Acuminate	 Condyloma acuminata
Verrucous	 Verruca vulgaris
Pedunculated	 Skin tags

Table 2.8. Horizontal profile of skin lesions






Configuration	Example
Nummular (discoïd)	 Nummular dermatitis Psoriasis
Annular	 Tinea corporis Borderline leprosy Psoriasis
Circinate/polycyclic	 Herpes simplex
Arcuate (arciform)	 Granuloma annulare
Retiform (reticulate)	 Lichen amyloidosis

Table 2.9. Arrangement of skin lesions

Arrangement	Example
Grouped	Herpes simplex
Linear	Verrucous epidermal nevus
Dermatomal	Herpes zoster
Arcuate	Granuloma annulare

Investigations

Simple but Necessary Tools

Magnifying Lens

A magnifying lens amplifies subtle changes in the skin. A 5× or 10× convex lens produces optimum magnification.

Glass Slides

Glass slides are used for diascopy (pressing the lesion with a glass slide to blanch the lesion). Diascopy is useful in the following situations:

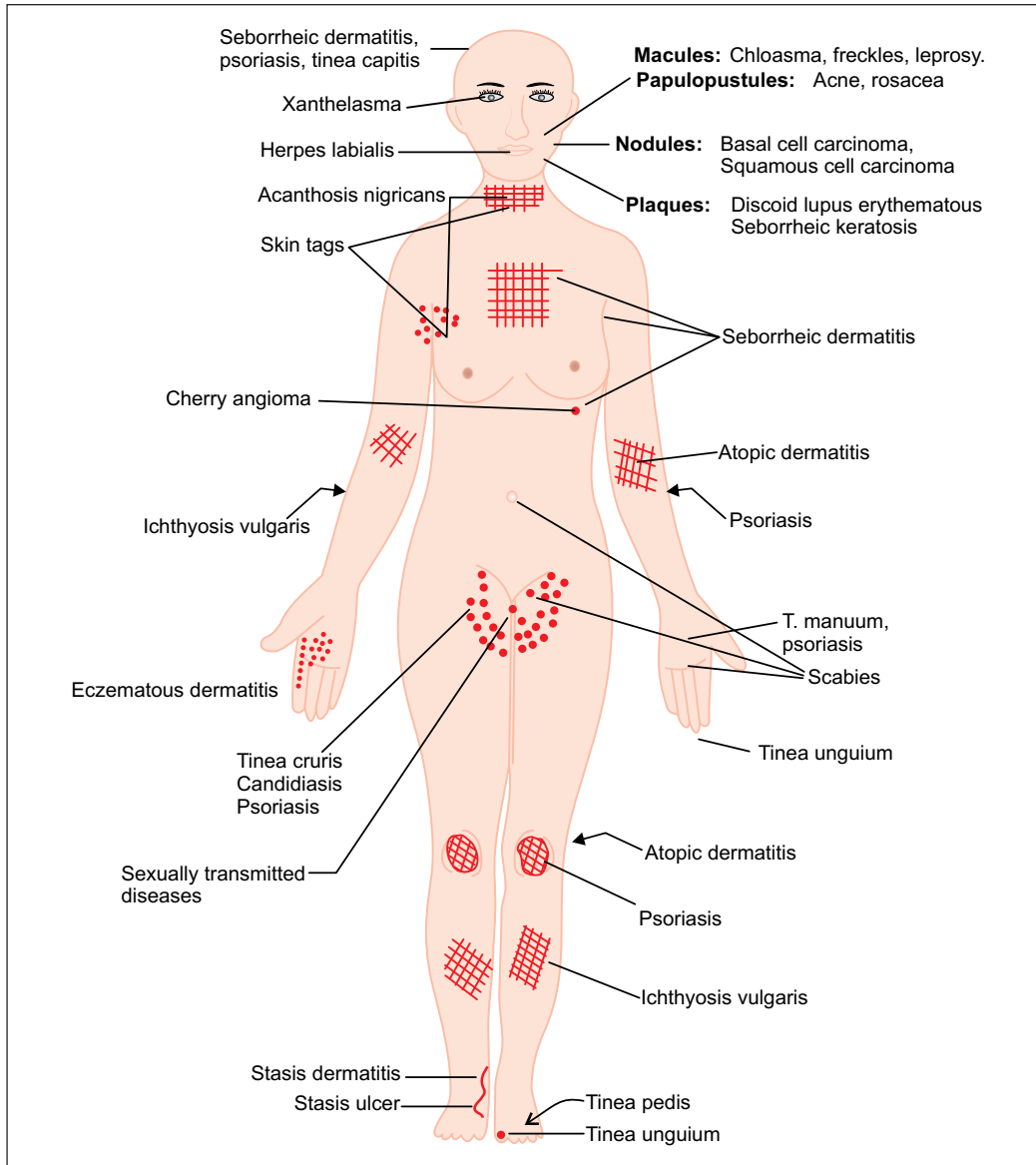


Fig. 2.25. Sites of predilection of common skin diseases.

Table 2.10. Distribution of skin lesions

Diseases	Distribution
Acne	Face, upper trunk, deltoid region
Photodermatitis	Face, V of neck, dorsolateral aspect of forearms; sparing of covered parts
Seborrheic dermatitis	Scalp, nasolabial folds, front of the chest, axillae, groins
Airborne contact dermatitis	Face, especially eye lids, retroauricular region, cubital fossae
Scabies	Webs of fingers, ulnar aspect of forearm, lower trunk, genitalia; sparing of face in adults

- ❖ To differentiate purpuric lesions (due to extravasation of blood) from erythema (due to vasodilatation). Erythema blanches on diascopy while purpura does not.
- ❖ In granulomatous lesions to appreciate the true color of the lesion, *e.g.*, in lupus vulgaris, blanching reveals apple jelly nodules.

Wood's Lamp

Wood's lamp is a device which emits ultraviolet rays (wavelength, 360 nm).

Uses

- ❖ **Disorders of pigmentation:** Wood's lamp enhances epidermal pigmentation but not dermal pigmentation and so can be used to:
 - Differentiate epidermal from dermal pigmentation.
 - Enhance subtle hypopigmented lesions, *e.g.*, ash leaf macule of tuberous sclerosis.
- ❖ **Infections:** Fluorescence of different colors is emitted on exposure to Wood's lamp.
 - Tinea capitis : green
 - Pityriasis versicolor : yellow
 - Erythrasma : coral pink

Dermoscopy

- ❖ Uses a hand lens (magnification 10× or 30×) with in-built light. Surface reflection is eliminated by covering lesion with mineral oil or water.
- ❖ Helps in noninvasive inspection of dermoepidermal junction.
- ❖ Useful in differentiating benign from malignant lesions.

Some Important Investigations

Certain tests are easy to perform and aid substantially in the diagnosis of a dermatologic disease.

Potassium Hydroxide Mount

This simple bedside test should always be done, if a fungal infection is suspected.

Specimens to be taken (Table 2.11)

Method

- ❖ Skin sample is put on a glass slide and an aqueous solution of 20% potassium hydroxide⁶ is added before applying the cover slip.
- ❖ After 20–30 min (60–90 min in case of nail clippings), mount is examined under microscope with condenser lens lowered to enhance contrast.
- ❖ Fungal hyphae/pseudohyphae/spores are looked for (Fig. 2.26).

Scrapings for Scabies Mite

Though presence of a burrow is diagnostic of scabies, burrows may not be visible in many patients.

Table 2.11. Specimens for potassium hydroxide preparation

Disease suspected	Specimen
Tinea corporis	Scales/roof of vesicles
Tinea cruris	Scales/roof of vesicles
Tinea capitis	Plucked hair, scales
Onychomycosis	Nail clippings, subungual debris
Pityriasis versicolor	Scales
Candidiasis	Contents of pustule, vaginal discharge

Method

- ❖ If the burrow is identified, the mite appears as a black (gray) dot at the end of the burrow under a magnifying lens. If the burrow is not visible, doubtful papules are used to collect the sample.
- ❖ The dot/papule is vigorously scraped with a sterile scalpel blade on which a drop of mineral oil has been applied till the whole dot/papule has been picked up and tiny flecks of blood appear in the oil. The oil is transferred on to a glass slide and examined under a microscope for mite, eggs and feces.
- ❖ Mites have four pairs of legs.

Tzanck Smear

- ❖ Is cytological examination of skin blisters.
- ❖ After rupturing roof of the blister, the floor is scraped with a surgical blade and material transferred on to a microscopic slide and fixed.

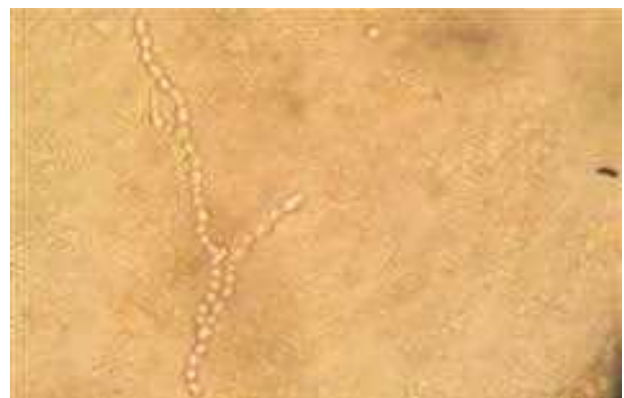

Fig. 2.26. Potassium hydroxide mount for fungal hyphae: hyphae appear as septate tube-like structures while pseudohyphae are elongated sausage shaped.

6. **Potassium hydroxide:** used to remove keratin.

- ❖ The slides are stained with Giemsa stain, Wright's stain or toluidine blue and examined under the microscope (Table 2.12, Fig. 2.27).

Patch Test

Patch test detects antigens (allergens) responsible for type IV allergy, as in allergic contact dermatitis.

Antigens

- ❖ Suspected antigens as well as antigens, which are likely to be used as substitutes are tested.

Table 2.12. Role of Tzanck smear in the diagnosis of blistering diseases

Microscopic finding	Diagnosis
Acantholytic cells ⁷	Pemphigus
Multinucleated giant cells ⁸	Herpes simplex, herpes zoster, varicella

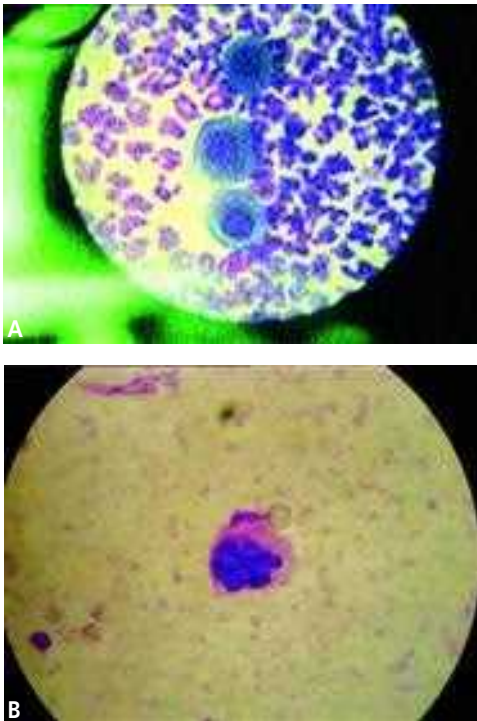


Fig. 2.27. Tzanck smear. A: showing acantholytic cells. B: showing multinucleated giant cells.

- ❖ If these are not known, a standard battery⁹ of antigens can be used.

Method

- ❖ Antigens are used in standardized dilutions and are applied to the back under occlusion.¹⁰
- ❖ The patches are removed after 48 h and the site on which the antigens had been applied is marked (Fig. 2.28).
- ❖ Areas are inspected after ½–1 h and then at 96 h (to detect delayed reactions), if necessary.

Reading

Reaction in the form of erythema, edema, papulation and vesiculation is noted. (Fig. 2.28). Depending on the degree of inflammation, the reaction is graded from 0 to 3+ (Table 2.13).

Table 2.13. Interpretation of patch tests

	Clinical findings	Grading
No reaction	Normal skin	0
Doubtful reaction	Minimal macular erythema	?
Weak reaction	Erythema and edema	1+
Strong reaction	Erythema, papules, edema, vesicles	2+
Extreme reaction	Erythema, papules, and bullae	3+
Irritant reaction	Cauterization	IR




Fig. 2.28. Patch testing: confirms the cause of allergic dermatitis.

7. **Acantholytic cells:** rounded keratinocytes with a perinuclear halo.

8. **Multinucleated giant cells:** large epithelial cells with 10–12 nuclei.

9. **Standard battery:** this contains common antigens to which a patient is likely to be exposed and different batteries are used in different geographic areas.

10. **Occlusion:** encourages penetration of allergens.

It is not necessary that the antigen which has been tested positive in patch test is the cause of current episode of dermatitis, so results of patch test should be interpreted keeping the clinical picture in mind.

Photopatch Test

Photopatch test is done to find cause of photoallergic contact dermatitis.

Method

Antigens are applied (as in routine patch testing) but in duplicate. At 24 h, one set of patches is irradiated with UVA and covered again. Both sets are then read at 48 h.

Interpretation

Photoallergic contact dermatitis, if present, manifests at 48 h. The negative control patch which has not been irradiated rules out allergic contact dermatitis (Table 2.14).

Skin Biopsy

Skin biopsy is a very useful diagnostic tool in dermatology.

Technique of taking biopsy

- ❖ Depending on the size of tissue needed, there are two common techniques of taking skin biopsy:
 - *Punch biopsy*: used for the superficial lesions.
 - *Scalpel biopsy*: used for deeper lesions, e.g., those involving subcutaneous tissue.
- ❖ Both techniques generally require local anesthesia.

Table 2.14. Interpretation of photopatch test

Reading at unexposed site	Reading at site exposed to UVA	Interpretation
–	–	No allergy
–	++	Photocontact allergy
++	++	Contact allergy
+	+++	Contact allergy with photoaggravation

Processing of skin biopsy

Skin biopsy can be sent for:

- ❖ Routine hematoxylin and eosin (H and E) staining.
- ❖ Special stains (Table 2.15) for various tissues (collagen and elastic fibers) to identify different organisms (mycobacteria, fungi), and deposits.
- ❖ Special procedures like immunofluorescence and electron microscopy.
- ❖ Culture, if an infectious etiology is suspected.

Precautions while taking a skin biopsy

- ❖ Biopsy a “new” lesion and the active edge of a progressing lesion.
- ❖ Avoid legs (slow healing), upper trunk (tendency to keloid formation), exposed parts (cosmetic objections), and bony prominences (infection).
- ❖ Do not crush the tissue.
- ❖ Place in proper fixative: formalin (for light microscopy), glutaraldehyde (for electron microscopy) or immunofluorescence fluid (for immunofluorescence) and if the sample is being sent for culture, send in normal saline.
- ❖ Label samples correctly (patient’s name, age, sex, hospital record number). Fill in the relevant details in the biopsy form.

Table 2.15. Stains used in dermatology

	Stain	Color
Skin components		
❖ <i>Collagen</i>	Masson’s trichrome Verhoeff–van Gieson	Green Red
❖ <i>Elastic fibers</i>	Verhoeff–van Gieson	Black
❖ <i>Mast cell granules</i>	Toluidine blue	Purple
Organisms		
❖ <i>Mycobacteria</i>	Fite stain	Pink
❖ <i>Fungi</i>	PAS ¹¹	Red
Deposits		
❖ <i>Glycogen</i>	PAS	Red
❖ <i>Acid mucopolysaccharides</i>	Toluidine blue Alcian blue	Blue
❖ <i>Amyloid</i>	Congo red	Orange pink ¹²

11. **PAS**: periodic acid schiff.

12. **Amyloid**: gives orange pink color with congo red with apple green birefringence.

Intradermal Tests

The following tests are useful in dermatological settings:

- ❖ Tuberculin test.
- ❖ Lepromin test.

Serological Tests

The following serological tests are frequently done:

- ❖ Serological tests for syphilis.
- ❖ Serological tests for HIV infection.
- ❖ Serological tests for collagen vascular disorders, *e.g.*, antinuclear antibody.
- ❖ Serological tests in bullous disorders, *e.g.*, desmoglein levels in pemphigus.

Chapter Outline

Basics of Genetic Inheritance

- Definitions•
- Principles of Mendelian genetics•
- Principles of non-Mendelian genetics◦
- Prenatal diagnosis•

Ichthyoses

- Ichthyosis vulgaris•
- X-linked ichthyosis•
- Lamellar ichthyosis•
- Nonbullous ichthyosiform erythroderma•
- Epidermolytic hyperkeratosis•
- Collodion baby◦
- Acquired ichthyosis◦

Keratodermas

- Palmoplantar keratodermas•

Epidermolysis Bullosa

- Etiology•
- Clinical features•
- Investigations•
- Treatment•

Neurocutaneous Disorders

- Tuberous sclerosis•
- Neurofibromatosis•
- Incontinentia pigmenti◦

Miscellaneous

Genodermatoses

- Xeroderma pigmentosum◦
- Acanthosis nigricans•
- Darier's disease◦

•Should know
◦Good to know

Genodermatology is the branch of dermatology that deals with inherited single¹ gene disorders that manifest themselves wholly or in part in skin, mucous membranes, hair, and nails. Though the clinical manifestations and mode of inheritance for many of these dermatoses are well-delineated, the exact gene(s) involved and biochemical defects of only a handful of them has been established.

Characters are transmitted from one generation to the next by pairs of chromosomes, each pair having a definite number of genes arranged in a regular order (**Mendelian genetics**). However, several inherited (and congenital dermatoses) cannot be explained on the basis of Mendelian principles and such aberrant defects are explained on the basis of **non-Mendelian genetics**.

Basics of Genetic Inheritance

Definitions

- ❖ **Genotype:** Genetic constitution of an individual.
- ❖ **Phenotype:** Physical manifestations of the genotype.
- ❖ **Penetrance:** Ability to detect any (even a single) manifestation of an abnormal genotype².
- ❖ **Expressivity:** Number and severity of various manifestations of an abnormal genotype.

Principles of Mendelian Genetics

Three main pedigree patterns of Mendelian inheritance are recognized:

- ❖ **Autosomal dominant inheritance (ADI).**
- ❖ **Autosomal recessive inheritance (ARI).**

1. Single (or few).
2. The effects of a gene on the phenotype are not constant because the clinical presence of the character depends on the penetrance and expressivity of the gene.

❖ *X-linked recessive inheritance* (XLRI).

The characteristics of these three patterns of inheritance are shown in Tables 3.1–3.3.

Table 3.1. Characteristics of autosomal dominant inheritance

❖ Every index patient has an affected parent (except for new mutations). So disease is transmitted from generation to generation.
❖ Half of the children of an affected parent are affected, with both sexes being equally affected.
❖ Distribution of affected individuals in a pedigree chart is vertical.
❖ Only one abnormal gene is needed to produce the disease. Homozygous individuals (a rare phenomenon) are not necessarily more severely affected.
❖ ADI disorders are generally less severe than ARI disorders.
❖ Examples: Epidermolysis bullosa (EB) simplex, EB dystrophica (some variants), ichthyosis vulgaris, bullous ichthyosiform erythroderma, Darier's disease, albinism (some variants), tuberous sclerosis, neurofibromatosis.

Table 3.2. Characteristics of autosomal recessive inheritance

❖ Parents are unaffected in most patients. Consanguinity is an important historical marker of ARI.
❖ Quarter of children of unaffected (heterozygous) parents are affected. However, if one parent is affected, the number of children having disease increases to half.
❖ Distribution of affected individuals in a pedigree chart is horizontal.
❖ Recessive abnormalities appear only in homozygous state because the normal allelomorphous gene is dominant.
❖ ARI disorders are generally more severe than ADI.
❖ Examples: EB dystrophica (some variants), junctional EB, non-bullous ichthyosiform erythroderma, lamellar ichthyosis, albinism (some variants).

Table 3.3 Characteristics of X-linked recessive inheritance

❖ Index patient may have an affected maternal uncle.
❖ Only males are affected (rarely females).
❖ Never transmitted from affected father to sons, but all daughters are carriers. Half of daughter's, sons affected, while half of daughters' daughters are carriers.
❖ If sibship is ascertained by an affected male, on an average more than half are affected.
❖ Abnormal gene always transmitted with sex chromosomes.
❖ Examples: X-linked ichthyosis.

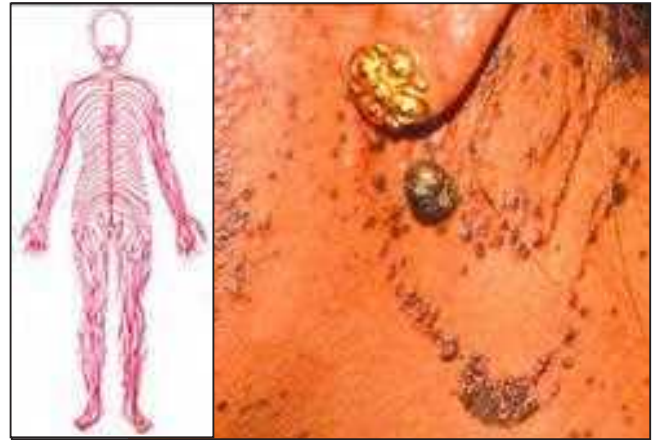

Fig. 3.1. Lines of Blaschko: lines and whorls often with a bizarre pattern.

Principles of Non-Mendelian Genetics

Several congenital manifestations that may have a genetic basis cannot be explained on the basis of Mendelian principles. These aberrant manifestations are explained on the basis of non-Mendelian genetics.

Mosaicism

Sometimes, mutation occurs in a single cell in the fetus. This abnormal cell generates a clone of mutated cells, which adopt patterns of lines and whorls following Blaschko's lines (Fig. 3.1), *e.g.*, as seen in the nevoid conditions like linear verrucous epidermal nevus.

Genomic Imprinting

Sometimes, either paternal or maternal gene has a dominant influence on the progeny, *e.g.*, paternal genes are more influential in psoriasis, while maternal genes are more dominant in atopy.

Contiguous Gene Deletions

Phenotypes with complex features (or multiple genodermatoses) may be inherited when adjacent genes are inherited together.

Uniparental Disomy

Sometimes, both pairs of a gene in an individual are inherited from one parent and the child lacks the gene from the other parent. When this happens, the disorder that is normally inherited as a recessive trait can manifest even though only one parent is affected, provided the child has inherited both the genes from the affected parent.

Prenatal Diagnosis

Prenatal diagnosis is a technique of detecting hereditary diseases and congenital defects in the fetus. This gives parents the option to have an elective abortion of a child affected with a severe genodermatosis for which effective treatment is not available. The various techniques used in prenatal diagnosis are:

- ❖ **Visualization of skin:**
 - Through fetoscopy and biopsy of fetal skin.
 - Allows diagnosis in three groups of disorders: albinism, ichthyosis and epidermolysis bullosa.
- ❖ **Karyotyping of fetal cells:**
 - Obtained by chorionic villous biopsy or amniocentesis.
 - Allows diagnosis of X-linked disorders by determining sex of the child.
- ❖ **Fetal DNA haplotyping:**
 - Will become the predominant method of disease detection in future.
 - DNA obtained from amniotic fluid/chorionic villi (at 12 weeks). Recent advance includes preimplantation testing.

Ichthyoses

- ❖ Ichthyoses are a heterogeneous group of dermatoses characterized by the presence of fish-like scales.
- ❖ Scaling is generally worse in winter.
- ❖ Ichthyotic disorders are usually inherited but may be acquired (Table 3.4).

Table 3.4. Ichthyoses: causes and types

Congenital	Acquired
Ichthyosis vulgaris	Infections: leprosy
X-linked ichthyosis	Drugs: clofazimine
Lamellar ichthyosis	Malignancies: lymphomas
Nonbullous ichthyosiform erythroderma	Endocrine disorders: hypothyroidism
Epidermolytic hyperkeratosis	Systemic diseases: sarcoidosis
	Nutritional deficiencies

Ichthyosis Vulgaris (IV)

Synopsis

Epidemiology: Common.

Etiology: ADI. Filaggrin absent or reduced.

Character of scales: Asymptomatic (or mildly itchy) fine scaling. Scales larger and conspicuous on shins.

Distribution: Extensors of limbs, lower back. Flexures spared.

Associated features: Keratosis pilaris, hyperlinear palms and soles, atopic diathesis.

Treatment: Hydration (by immersing in water) and immediate lubrication (petrolatum; urea+glycerine+water) of skin. Use keratolytic agents (hydroxy acids, propylene glycol, and salicylic acid) when severe.

Etiology

- ❖ **Inheritance:** ADI.
- ❖ **Molecular defect:** Reduced or absent filaggrin³.

Epidemiology

- ❖ **Prevalence:** Common disorder (incidence of 4/1000).
- ❖ **Age of onset:** 3–12 months.
- ❖ **Gender predilection:** Males = Females.

Clinical Features

Symptoms

Dryness is mild, so patients are asymptomatic. Or have mild itching, especially on the legs, most frequently in winters.

Character of scales

- ❖ **On most parts of body:** Fine, white scales.
- ❖ **On extensors of lower extremities** (most severely affected parts): Large scales (Fig. 3.2), attached (pasted) at center and turned up at the edge, making skin rough. Superficial fissuring may develop on shins in winter.

Sites of predilection

- ❖ Prominent involvement of extensors of limbs (shins most severely, forearms, thighs and arms less severely) and lower back (Fig. 3.3).

3. **Filaggrin:** responsible for formation of keratin filaments.

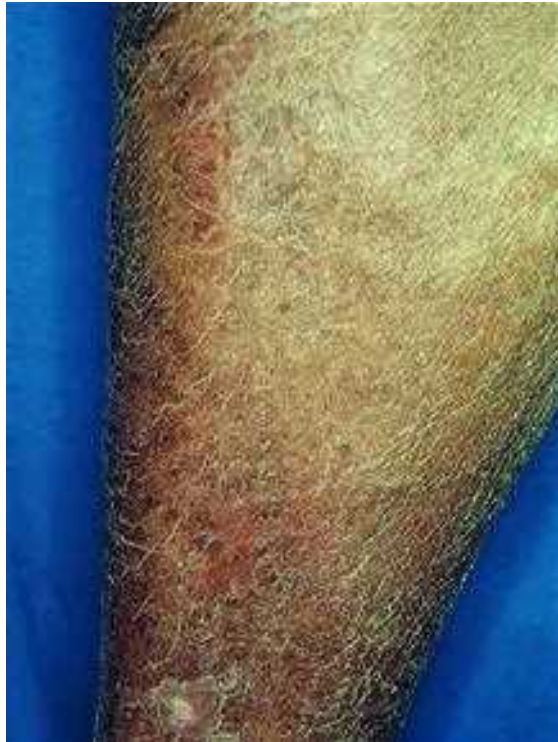

Fig. 3.2. Ichthyosis vulgaris: large scales on shins that are attached at the center and turned up at edge.



Fig. 3.4. Hyperlinear palms: accentuated skin creases on the palms.

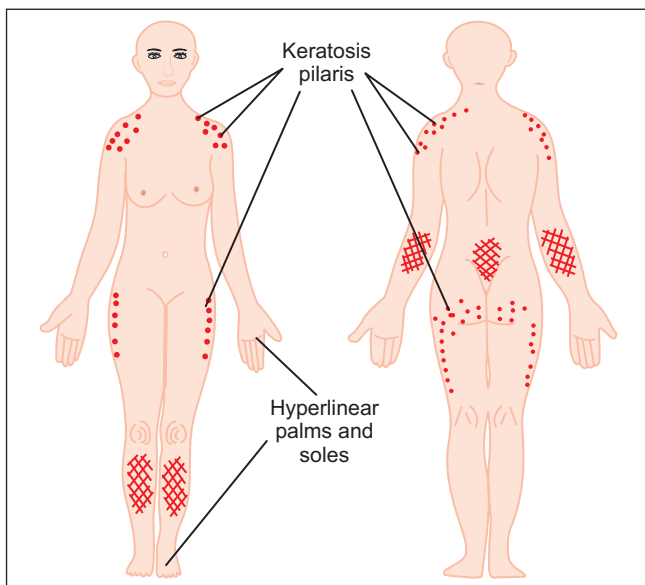


Fig. 3.3. Ichthyosis vulgaris: sites of predilection. Note scaling is conspicuous on the extensors with sparing of major flexures.

- ❖ Major flexures (popliteal and cubital fossae, axillae and groins) always spared.
- ❖ Face usually spared, though cheeks and forehead may occasionally be involved.

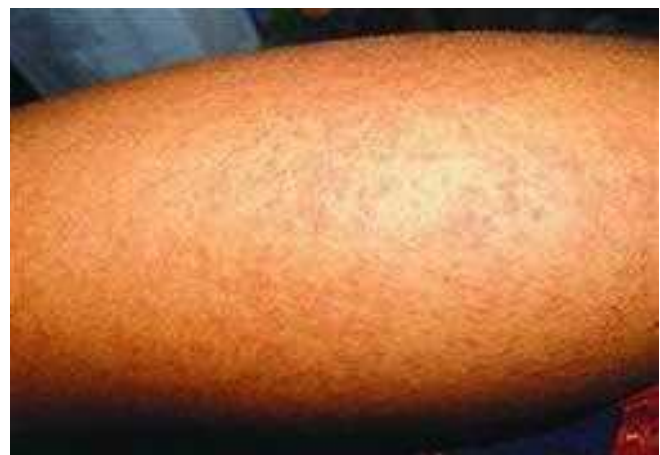

Fig. 3.5. Keratosis pilaris: keratotic (spiny) follicular papules on the lateral aspect of the proximal parts of the upper limb. Also present on thighs.

Associated features

- ❖ **Hyperlinear palms** (Fig. 3.4): And occasionally, keratoderma of palms and soles.
- ❖ **Keratosis pilaris** (Fig. 3.5): Keratotic (spiny) follicular papules on deltoid region and lateral aspect of thighs.
- ❖ **Atopic diathesis:** Hay fever, eczema, and asthma.

Complications

- ❖ Fissuring of dry skin in winter. Intolerance to degreasing agents (soaps, detergents).
- ❖ Eczematization of dry skin, especially in presence of atopic diathesis.

Course

- ❖ Appears during 1st few years of life.
- ❖ May improve during adolescence, especially during summer and if the patient relocates to a warm humid climate.

Investigations

- ❖ None needed.

Diagnosis

Points for diagnosis

Diagnosis of IV is based on the presence of:

- ❖ Scales, which are generally fine (white) but are larger and pasted on the shins.
- ❖ Characteristic distribution on extensors with conspicuous sparing of major flexures.
- ❖ **Associations:** Hyperlinear palms, keratosis pilaris and atopic diathesis.

Differential diagnosis

IV should be differentiated from:

(a) *X-linked ichthyosis (XLI)* (P. 24).

Treatment

Some patients require treatment, particularly in winter. Treatment includes:

- ❖ Restricted use of degreasing agents.
- ❖ **Hydration of skin:** Best accomplished by soaking in a tub of water and gently wiping the skin followed by application of a lubricant, while the skin is still wet and soft.
- ❖ **Lubrication:** Helps to retain moisture. Can be achieved by:
 - *Petrolatum:* helps to retain moisture by occlusion.
 - *Urea containing creams and lotions:* help to retain moisture by binding water in stratum corneum.
- ❖ **Keratolytic agents:**
 - Help to remove scales by dehiscence of keratin.
 - Used in severe cases, especially on shins. And in winters.
 - Include:
 - Urea (10–20%), dispensed in water + glycerine.
 - α -hydroxy acids (lactic acid, glycolic acid, 5–10%).

- Propylene glycol (40–60%).
- Salicylic acid (1–5%).

Treatment of complications:

- *Eczematized skin:* short course of topical corticosteroid–antibiotic combination.

X-linked Ichthyosis (XLI)

Synopsis

Epidemiology: Rare. Affects only males.

Etiology: XLRI; deficiency of steroid sulfatase.

Character of scale: Large, adherent, dark brown–black scales.

Distribution: Generalized involvement. Encroaches flexures.

Treatment: As for ichthyosis vulgaris.

Etiology

- ❖ **Inheritance:** XLRI (Fig. 3.6).
- ❖ **Molecular defect:** Deficiency of enzyme, steroid sulfatase.

Epidemiology

- ❖ **Prevalence** 1: 5000 males.
- ❖ **Age of onset:** At birth.
- ❖ **Gender predilection:** Affects only males (Fig. 3.6), though some female carriers may show mild scaling.

Clinical Features

Character of scales

Large, adherent (Fig. 3.7) and brown (sometimes almost black, particularly in darker individuals, hence the name **ichthyosis nigra**).

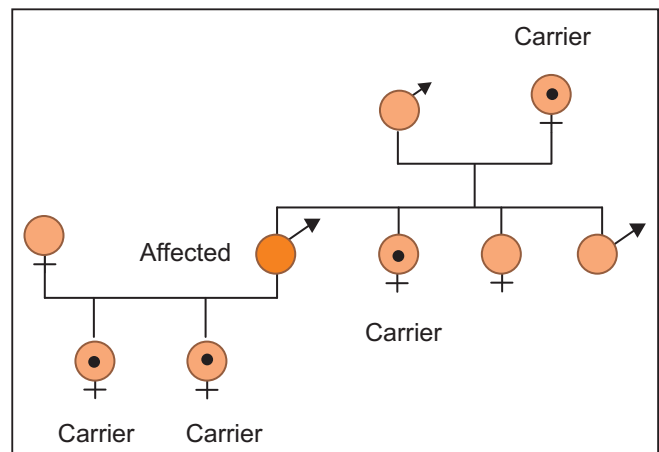


Fig. 3.6. Inheritance of X-linked ichthyosis.



Fig. 3.7. X-linked ichthyosis: dark scales on abdomen. Scales larger on shins.

Sites of predilection

- ❖ Generalized involvement with no (only minimal) sparing of the body flexures.
- ❖ Scales most pronounced on the posterior aspect of neck, extensors of arms and legs encroaching cubital and popliteal fossa (Fig. 3.8).
- ❖ Palms and soles spared.

Associated features

- ❖ No keratosis pilaris, hyperlinear palms and soles or atopic diathesis.
- ❖ Comma-shaped corneal opacities (do not interfere with vision)⁴.
- ❖ Cryptorchidism⁵.

Investigations

- ❖ Skin biopsy (if done) shows:
 - Hyperkeratosis.
 - Hypergranulosis (*cf.*, IV, where granular layer is absent or thin).
- ❖ Elevated serum cholesterol sulfate.
- ❖ Lowered steroid sulfatase in fibroblasts cultured from a skin biopsy (done for research purposes).

Diagnosis

Points for diagnosis

The diagnosis of XLI is based on:

- ❖ Patient being male.
- ❖ Presence of large, dark, adherent scales.
- ❖ Involvement of extensors with encroachment of flexures.

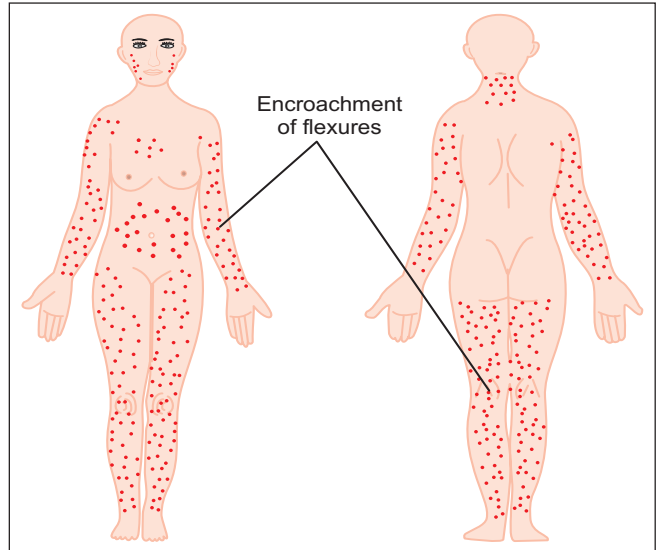


Fig. 3.8. X-linked ichthyosis: distribution of lesions; note scales encroach the major flexures.

Differential diagnosis

Differentiate XLI from:

a. Ichthyosis vulgaris (IV)

IV	XLI
<i>Inheritance:</i> ADI	XLRI. Maternal uncle affected, but parents not affected
<i>Gender:</i> both males and females	Only males
<i>Onset:</i> 1st few years	At birth
<i>Course:</i> may improve in adolescence	Persists for life
<i>Scales:</i> small and branny except on shins where large and pasted	Large and dark (very!!)
<i>Sites:</i> extensors. Flexures spared.	Generalized. Flexures encroached
<i>Associated features:</i> <ul style="list-style-type: none"> ❖ Hyperlinear palms and soles ❖ Keratosis pilaris ❖ Atopic diathesis 	<ul style="list-style-type: none"> ❖ Corneal opacities ❖ Cryptorchidism

Treatment

- ❖ Measures as for IV usually suffice, though need to be used more aggressively (P. 23).
- ❖ Oral retinoids⁶ best avoided due to their side effects and due to benign nature of disease.

4. **Corneal opacities:** in 50% of patients.

5. **Cryptorchidism:** in 20% of patients.

6. **Oral retinoids:** frequently used oral retinoids include **acitretin** (used in disorders of keratinisation) and **isotretinoin** (used in acne).

Lamellar Ichthyosis (LI)

Synopsis

Epidemiology: Rare.

Etiology: ARI.

Onset: At birth, as collodion baby.

Character of scale: Large thick, brown, pasted scales.

Distribution: Generalized, including flexures

Treatment: *Mild cases:* Manage with hydration, lubrication and keratolytics. *Severe cases:* Acitretin.

Etiology

- ❖ **Inheritance:** ARI.
- ❖ **Molecular defect:** Abnormality of gene encoding for transglutaminase.

Epidemiology

- ❖ **Prevalence:** Rare.
- ❖ **Age of onset:** At birth. Newborn presents as a collodion (lacquered) baby, ensheathed in a membrane; when the membrane sheds, typical scales become apparent.
- ❖ **Gender predilection:** Equal in both sexes.

Clinical Features

Morphology

- ❖ Newborn usually presents as a collodion baby, ensheathed in a membrane (Fig. 3.9).
- ❖ Over a period of weeks, the membrane is shed and the child develops diffuse large, thick, brown pasted (plate-like) scales, which persist for life (Fig. 3.10A).
- ❖ Flexures may show continuous linear rippling (Fig. 3.10B).

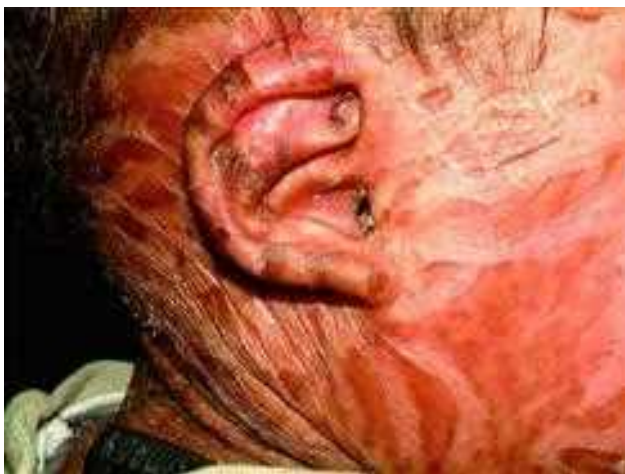

Fig. 3.9. Collodion baby: newborn is ensheathed in a shiny lacquer-like membrane.

- ❖ Erythema is minimal or absent; but when present, it is maximum on face (Fig. 3.10C).

Sites of predilection

Generalized lesions, accentuated on lower extremities and flexural areas.

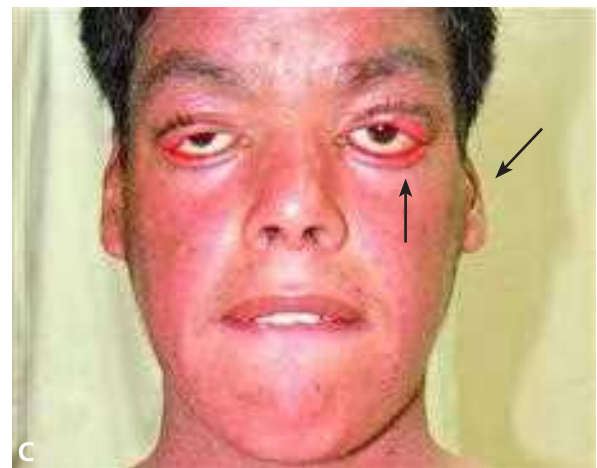
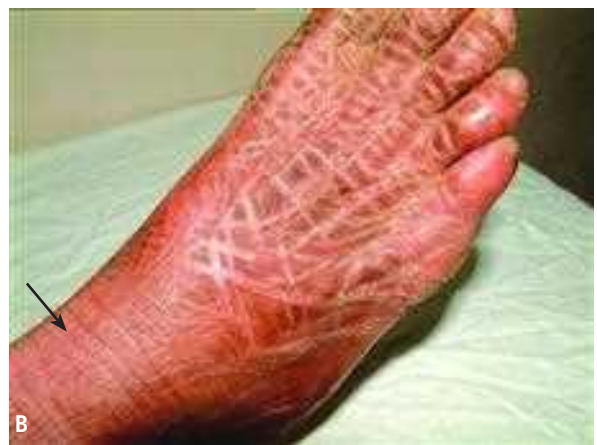
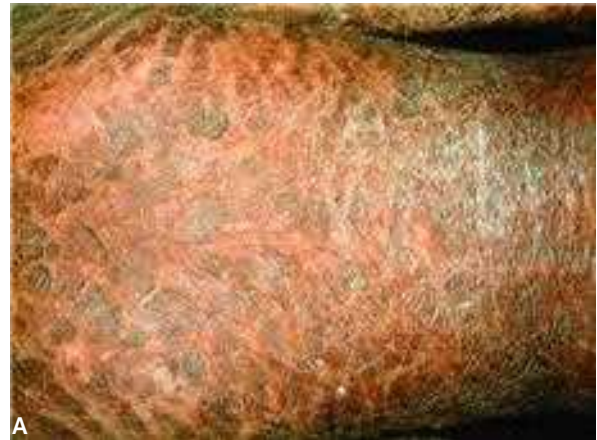Fig. 3.10. Lamellar ichthyosis: A: large pasted scales. B: note continuous rippling around ankle. C: some patients have erythema of face. Note the ectropion and crumpled ears.

Associated features

- ❖ Ectropion (Fig. 3.10B) and eclabium.
- ❖ Rippled hyperkeratosis around joints.
- ❖ Palmar and plantar keratoderma frequent.
- ❖ Crumpled ears (Fig. 3.10B).

Diagnosis

Point for diagnosis

Diagnosis of LI is based on:

- ❖ History of collodion membrane at birth.
- ❖ Characteristic thick, large, brown, pasted scales, especially on the shins.
- ❖ Continuous rippling around joints.
- ❖ Minimal erythema (except on face).

Differential diagnosis

LI needs to be differentiated from:

(a) *Nonbullous ichthyosiform erythroderma (vide infra)*.

Treatment

- ❖ **Mild cases:** Managed as patients with IV (P. 23).
- ❖ **Severe cases:** Acitretin, under careful supervision.

Nonbullous Ichthyosiform Erythroderma (NBIE)

Synopsis

Etiology: ARI.

Onset: At birth, as collodion membrane.

Character of scales: On shedding of collodion membrane, there is fine diffuse scaling on background of erythema.

Distribution: Generalized.

Treatment: As for LI.

Etiology

- ❖ **Inheritance:** ARI.

Epidemiology

- ❖ **Prevalence:** Rare.
- ❖ **Gender predilection:** Equal in both sexes.
- ❖ **Age of onset:** At birth, child usually presents as a collodion (lacquered) baby, ensheathed in a membrane (Fig. 3.9). When the membrane sheds, typical scales become obvious.

Clinical Features

Newborn is encased in a collodion membrane,

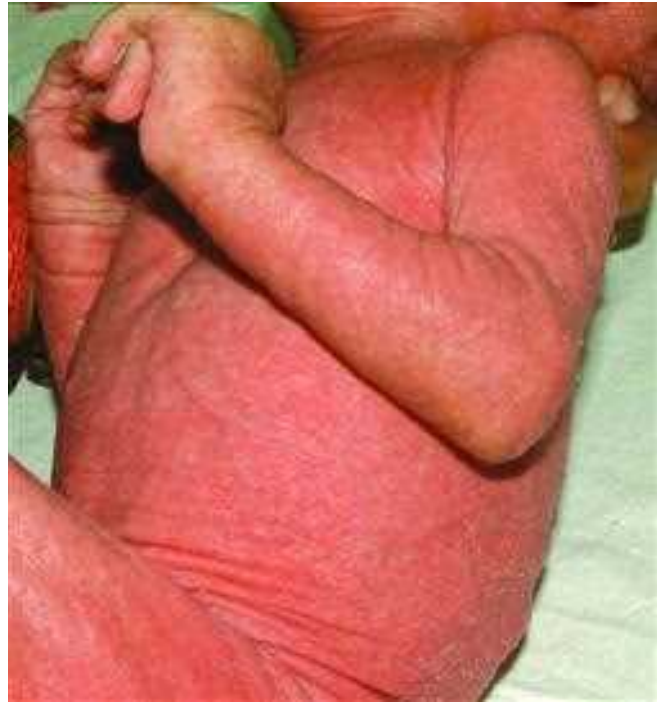

Fig. 3.11. NBIE: generalized erythema with branny scales.

which is shed in a couple of weeks to reveal generalized erythema and fine branny scales, which persist throughout life (Fig. 3.11).

Diagnosis

Points for diagnosis

Diagnosis of NBIE is based on:

- ❖ Presence of collodion membrane at birth.
- ❖ Presence of small branny scales on a background of diffuse erythema.
- ❖ Generalized involvement.

Differential diagnosis

NBIE should be differentiated from:

a. Lamellar ichthyosis (LI)

LI	NBIE
Prevalence: very rare	Rare
Erythema: minimal or absent	Marked
Scales: large, brown, adherent, scales especially on the shins	Branny scales
Palmoplantar keratoderma: frequent	Less frequent

Treatment

As for LI (vide supra).

Epidermolytic Hyperkeratosis (EHK)

Synopsis

Etiology: ADI.

Onset: Self-limiting blistering stage.

Character of scales: Brown hyperkeratotic (warty) waxy scales forming broad linear lesions with skip areas.

Distribution: Generalized with accentuation in flexures.

Associations: Palmoplantar keratoderma.

Treatment: Emollients. *Mild disease:* Topical retinoic acid (care in flexures!). *Extensive disease:* Systemic retinoids.

Etiology

- ❖ **Inheritance:** ADI.
- ❖ **Molecular defect:** Defect in keratin synthesis or degradation.

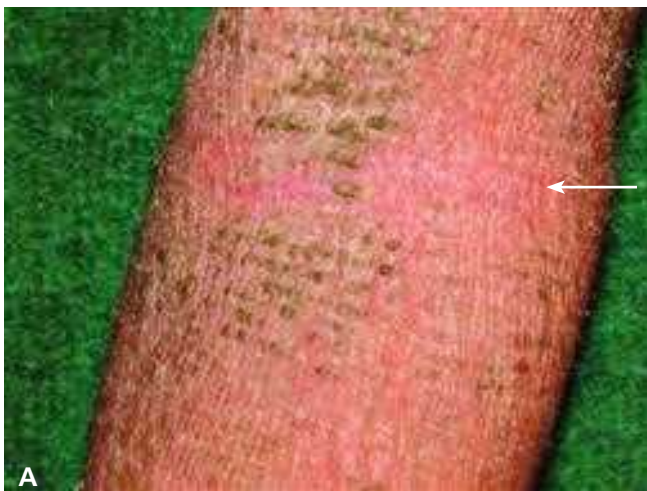

Fig. 3.12. Epidermolytic hyperkeratosis: A: hyperkeratotic (warty) lesions. Note the scales peel off in small areas leaving bald patches (skip areas). B: extreme case, lesions resembling a range of mountains.

Epidemiology

- ❖ **Prevalence:** Rare.
- ❖ **Gender predilection:** None.
- ❖ **Age of onset:** At birth.

Clinical Features

Morphology

- ❖ **Neonatal phase:** Onset at birth or soon thereafter. Skin develops generalized erythema interspersed with numerous blisters.
- ❖ **Childhood phase:**
 - As the child grows, the erythema and tendency to blister reduces.
 - Child gradually develops brownish, warty (hyperkeratotic), waxy, predominantly broad linear lesions.
 - Warty scales may fall off in small areas (Fig. 3.12A), leaving bald patches (skip areas).
 - In extreme cases, there is massive hyperkeratosis, which resembles a **range of mountains** (Fig. 3.12B).

Sites of predilection (Fig. 3.13)

Lesions are generalized, with accentuation at the joint flexures, resulting in linear spiny lesions (**hystrix lesions**, Fig. 3.12B).

Associations

- ❖ Palmoplantar keratoderma in 60% of patients.

Variants

- ❖ Unilateral linear lesions, clinically resembling linear verrucous epidermal nevus, but with typical histology.

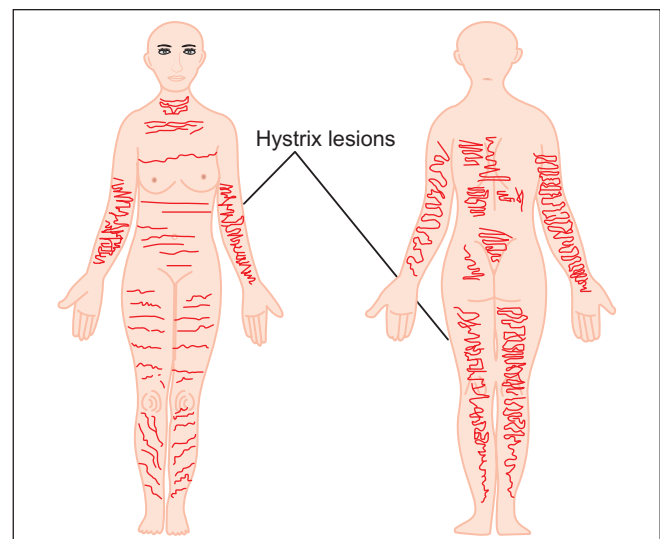


Fig. 3.13. Epidermolytic hyperkeratosis: sites of predilection.

Diagnosis

Points for diagnosis

The diagnosis of EHK is based on:

- ❖ History of blistering in infancy.
- ❖ Warty scales, most prominent in the flexures; may fall off, leaving small bald areas (skip areas).
- ❖ Palmoplantar keratoderma in 60%.
- ❖ Typical histology of vacuolar degeneration of keratinocytes.

Differential diagnosis

EHK should be differentiated from:

a. Lamellar ichthyosis (LI).

LI	EHK
Onset: at birth as collodion baby	At birth with erythema with blistering
Scales: large brown and pasted	Warty hyperpigmented scales. May peel off leaving bald patches (skip areas)
Flexures: continuous rippling in flexures	Discontinuous rippling in flexures

Treatment

Blistering stage

- ❖ Local hygiene.
- ❖ Topical/systemic antibiotics may be necessary.
- ❖ Systemic steroids (in severe cases).

Hyperkeratotic stage

- ❖ Topical retinoic acid (0.05–0.1%) results in flattening of lesions but should be avoided in depth of flexures.
- ❖ Acitretin in severe cases. May result in blistering initially.

Collodion Baby

Etiology

A morphological diagnosis. Most frequently associated with:

- ❖ An underlying ichthyotic disorder:
 - Nonbullous ichthyosiform erythroderma.
 - Lamellar ichthyosis.
 - X-linked ichthyosis (less often).
- ❖ Rarely, on shedding reveals normal skin.

Clinical Features

Morphology

- ❖ Neonate is born with a smooth and shiny skin

(lacquered appearance), as if covered with cellophane or collodion (Fig. 3.9).

- ❖ Tightness of the skin causes ectropion and eclabium.
- ❖ Outer cover (which is present all over the body) is eventually shed to reveal the underlying ichthyosis. Rarely, skin is normal.

Complications

- ❖ Temperature dysregulation.
- ❖ Feeding difficulties due to eclabium.
- ❖ Water and electrolyte imbalance.

Variants

- ❖ **Harlequin fetus:** Where the skin is covered with thick fissured skin resembling an armor. Often fatal.

Treatment

- ❖ High-humidity incubator nursing necessary to maintain body temperature and to restrict water loss.
- ❖ Regular application of emollients to make skin supple.
- ❖ Short course of acitretin (oral retinoid) hastens shedding.

Acquired Ichthyosis

- ❖ If ichthyosis appears in adult life, suspect an underlying cause.
- ❖ Commonest cause in India is leprosy, especially if the patient is receiving clofazimine. Other causes include internal malignancies (e.g., Hodgkin's lymphoma), endocrine disorders (e.g., hypothyroidism), sarcoidosis and nutritional deficiencies (Table 3.4).
- ❖ Clinical features resemble IV (Fig. 3.14). In clofazimine-induced ichthyosis, skin is in addition pigmented.
- ❖ Symptomatic treatment with topical emollients after hydration. Treatment of underlying problem often reverses the ichthyosis.

Palmoplantar Keratodermas (PPKD)

Synopsis

Etiology: Heterogeneous group: genetic (ADI or ARI) and acquired. Commonest acquired cause, psoriasis.

Clinical features: Diffuse, punctate, striate and mutilating patterns.

Treatment: Response less than satisfactory. Topical keratolytics. Acitretin in debilitating cases.

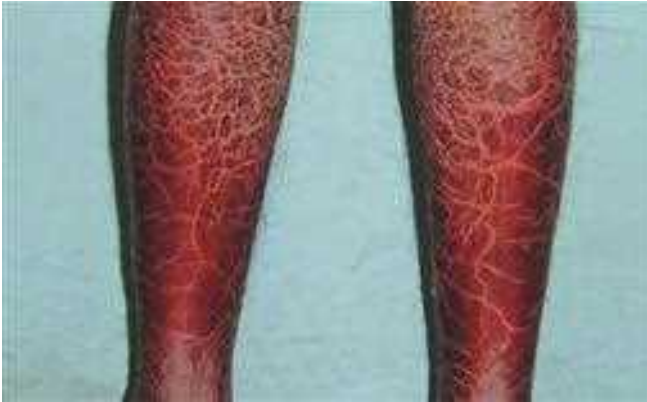

Fig. 3.14. Acquired ichthyosis: large scales on shins that are centrally attached, similar to ichthyosis vulgaris.

Keratodermas are a heterogeneous group of disorders characterized by thickening of skin, a prototype of which is keratoderma of palms and soles (so **palmoplantar keratoderma**, PPKD).

Palmoplantar Keratodermas

Etiology

PPKD can be inherited or acquired. Inherited PPKD can either be part of a syndrome or can be inherited as an isolated anomaly (Table 3.5).

Manifestations

Inherited PPKD

Palmoplantar keratoderma can be diffuse (called **tylosis** Fig. 3.15A), punctate, striate (Fig. 3.15B) or mutilating (Fig. 3.15C). Sometimes, the keratoderma spills onto dorsum of hands and feet (**transgradiens**).

Table 3.5. Classification of palmoplantar keratoderma (PPKD)

Inherited PPKD	Inheritance
Diffuse	Autosomal dominant
Punctate	Autosomal dominant
Striate	Autosomal dominant
Mutilating	Autosomal recessive
Transgradiens	Autosomal recessive
Acquired PPKD	
Psoriasis	
Pityriasis rubra pilaris	

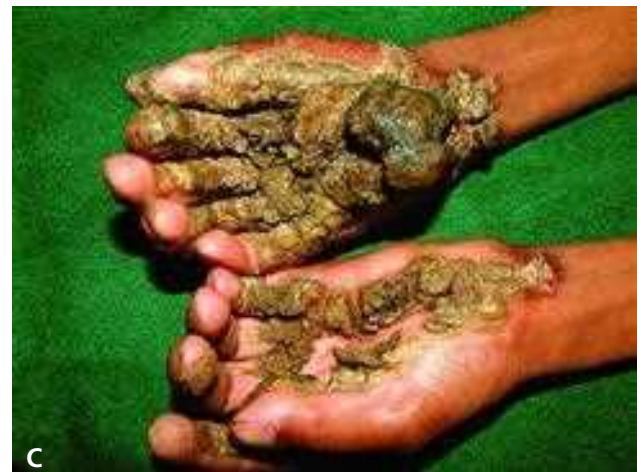
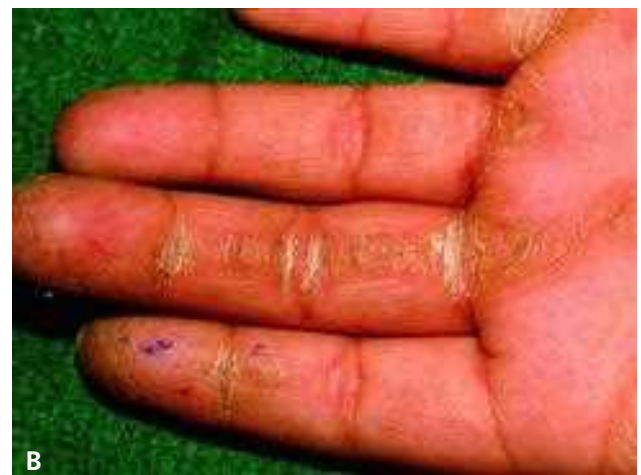
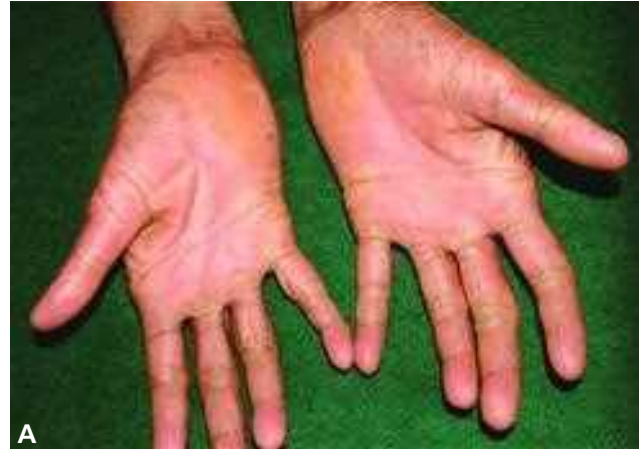Fig. 3.15. Palmoplantar keratoderma: A: diffuse symmetrical thickening of palms and soles, called tylosis. B: striate palmar keratoderma. C: an extreme case with massive thickening and mutilation.

Acquired PPKD

- ❖ Many normal people have a few inconspicuous punctate keratoses on palms and soles.
- ❖ Keratoderma of palms and soles can also be a

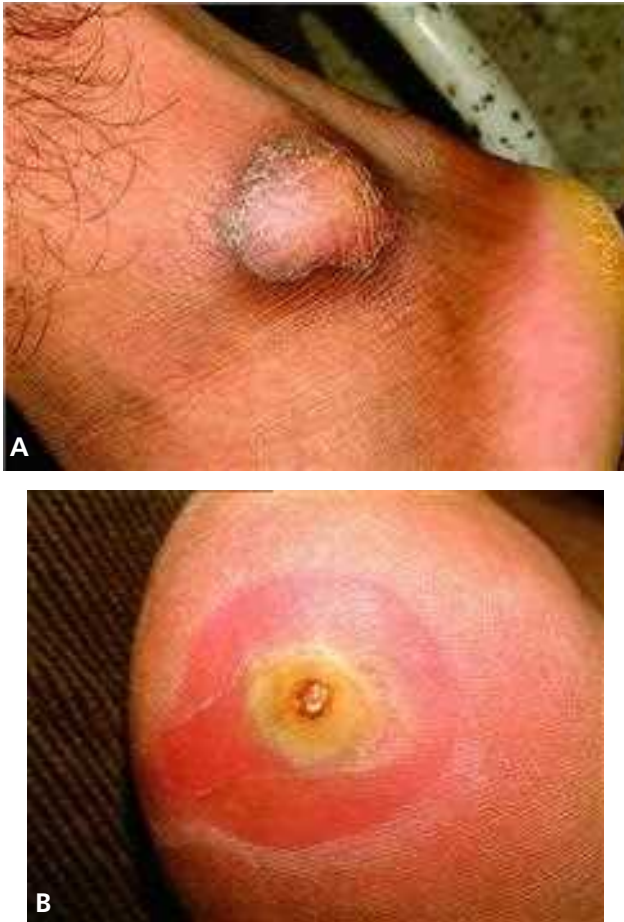


Fig. 3.16. Acquired keratoderma: A: callosities: ill-defined thickening at site of constant friction. B: corns: defined area of hyperkeratosis, which on paring reveals a central core.

part of dermatoses like psoriasis and pityriasis rubra pilaris.

❖ **Callosities (Fig. 3.16A):**

- **Etiology:** develops at site of constant/repeated pressure/friction. Commonly seen due to:
 - Occupation, on palms, *e.g.*, of manual laborer.
 - Ill-fitting footwear, on soles.
 - Prosthesis, on stumps of amputees.
 - Recreation: golf club on palms.
- **Clinical features:** ill-defined area of yellowish thickening of palms/soles (Fig. 3.16A). Usually asymptomatic.

❖ **Corns**

- **Causes:** intense localized pressure due to:
 - Ill fitting shoes.
 - Architectural defect of foot.
 - **Clinical features:**
 - Painful.
 - Well-defined area of hyperkeratosis, which is tender on horizontal pressure. Paring reveals central core.
 - On soles, under the heads of metatarsal bones.
 - **Differential diagnosis:** plantar warts.
- ❖ Infrequently, PPKD may be associated with internal malignancies⁷.

Treatment

Less than satisfactory.

- ❖ Keratolytics⁸, such as salicylic acid (12%) or urea (30–40%), best applied after soaking in water; often used under occlusion.
- ❖ Acitretin in mutilating variants.
- ❖ **Corns and callosities**
 - Remove trigger.
 - Keratolytics, paring (to remove core).

Epidermolysis Bullosa (EB)

Synopsis

Etiology: Heterogeneous group of rare disorders. Commonly genetic (keratin and collagen VII gene defect), infrequently acquired (immune mediated).

Classification: Inherited (EB simplex, EB dominant dystrophic, EB junctional, EB recessive dystrophic)⁹.

Clinical features: Bullae at sites of trauma (mechano-bullous disorders). Severity depends on type of EB: mild in simplex, severe in recessive dystrophic, in between in dominant dystrophic. Mucosal and nail involvement in dystrophic (less in dominant and more severe in recessive) variants. Severe deformities in recessive dystrophic.

Treatment: Unsatisfactory. Prevention of trauma (by careful handling) paramount to prevent blistering. Surgical treatment of deformities.

EB is a heterogeneous group of disorders, characterized by a tendency to develop blisters even after trivial trauma.

7. **Internal malignancies:** carcinoma of esophagus.

8. **Keratolytics:** take care. Avoid contact with other areas.

9. **Lamina lucida:** middle layer of basement membrane zone. Below this layer is lamina densa and above is the membrane of the basal layers and hemidesmosomes.

Classification (Table 3.6)

Based on pathogenesis (whether gene defect or immunological) and level of split (Fig. 3.17). EB is classified into:

❖ **Inherited:**

- **Dominant:**
 - Simplex: split in basal layer due to cytolysis of cells.
 - Dominant dystrophic: split in lamina lucida.
- **Recessive:**
 - Junctional: split in lamina lucida.
 - Recessive dystrophic: split in sublamina densa.

❖ **Acquired:** immunobullous.

Etiology

Etiology of different variants of EB is:

❖ **Inherited:**

- *EB simplex*: most variants due to defective

keratin gene.

- *EB dystrophica*: many variants due to defective collagen VII gene.

❖ **Acquired:** Immune mediated due to circulating immunoglobulins.

Clinical Features

EB Simplex

- ❖ ADI.
- ❖ Bullae (nonhemorrhagic) on normal skin develop in early childhood. Aggravated by sweating, so worse in the summer. Heal without scarring.
- ❖ Sites of repeated trauma (hands and feet). One variant, restricted to palms and soles (Fig. 3.18A).
- ❖ Nails and mucosae spared.

Autosomal Dominant Dystrophic EB

- ❖ ADI.
- ❖ Bullae (on normal skin) appear at birth or in

Table 3.6. Classification and inheritance of epidermolysis bullosa (EB)

Inherited	
❖ Autosomal dominant	EB simplex Dominant dystrophic EB
❖ Autosomal recessive	Junctional EB Recessive dystrophic EB
Acquired	
	EB acquisita

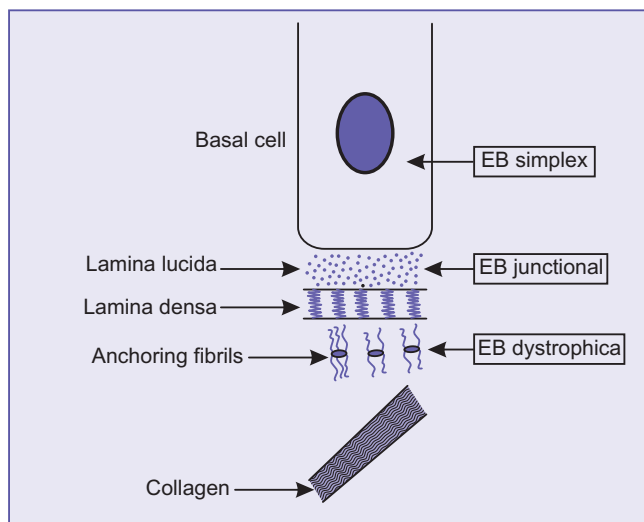


Fig. 3.17. Diagram showing level of split in epidermolysis bullosa.

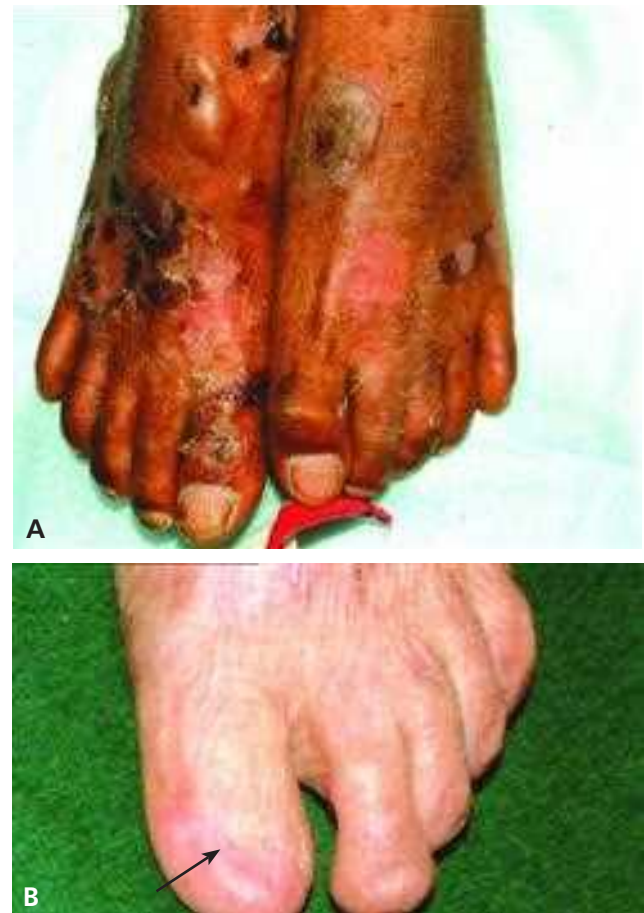

Fig. 3.18. Epidermolysis bullosa: A: EB simplex: bullae on hand and feet. B: EB recessive dystrophic: bullae heal with scarring. Note loss of nails.

early infancy. Blisters hemorrhagic, which heal with scarring and milia¹⁰ formation.

- ❖ Most frequent at sites of friction (knees, elbows, and fingers).
- ❖ Nail involvement frequent, mucosal involvement minimal.

Junctional Epidermolysis Bullosa

- ❖ ARI. Rare.
- ❖ Onset at birth. Large flaccid bullae on the normal skin. Rupture to leave raw areas, which heal slowly.
- ❖ Perioral and perianal areas.
- ❖ Nail and mucosal involvement.
- ❖ One variant, lethal.

Autosomal Recessive Dystrophic EB

- ❖ ARI.
- ❖ Onset at birth. Hemorrhagic blisters (on normal appearing skin). Heal with severe scarring (hallmark of disease). Results in webbing of digits (**mitten hands**).
- ❖ Lesions are present at trauma-prone sites.
- ❖ Nail involvement (Fig. 3.18B) and mucosal involvement (even esophageal) severe. Esophageal strictures may be seen.

Epidermolysis Bullosa Acquisita (EBA)

- ❖ Not inherited. An autoimmune mechanobullous disease. Due to linear deposit of IgG at dermoepidermal junction.
- ❖ Seen in adults.
- ❖ Bullae, often hemorrhagic. Develop usually on normal, sometimes on inflamed skin¹¹.
- ❖ At sites of trauma. Heal with milia formation.

Investigations

Biopsy

- ❖ Light microscopy indicative not confirmatory.
- ❖ Electron microscopy confirms level of bulla:
 - *EB simplex*: in basal layer.
 - *EB dominant dystrophic*: in lamina lucida.
 - *EB recessive dystrophic*: in sublamina densa.

Treatment

Treatment is disappointing. No specific therapy available.

General Measures

- ❖ Blistering can be minimized by:
 - Avoiding trauma.
 - Wearing soft, well-fitting shoes.
 - Keeping feet dry.
- ❖ When formed, blisters should be pricked without removing the roof. Topical antibiotic dressing prevents secondary infection.

Specific Measures

- ❖ Phenytoin has been tried in dystrophic recessive EB but is of doubtful value.
- ❖ Vitamin E has been used empirically.
- ❖ **Gene therapy**: By adding the absent gene to epidermal cells and layering on the eroded skin.

Surgical Intervention

Surgery is necessary for:

- ❖ Deformities, *e.g.*, mitten hands.
- ❖ Esophageal strictures.

Neurocutaneous Disorders

Several genetic diseases involve skin and nervous system and so are called neurocutaneous disorders or neuroectodermatoses (earlier called **phakomatoses**), *e.g.*, tuberous sclerosis complex and neurofibromatosis.

Tuberous Sclerosis Complex (TSC)

Synopsis

Inheritance: ADI.

Skin lesions: Pathognomonic skin lesions: angiofibromas (on face), ash leaf macules and shagreen patch (on trunk), Koenen's tumors (periungual fibromas).

Systemic manifestations: Seizures, mental retardation and eye tumors.

Treatment: Cosmetic; symptomatic treatment for seizures.

Etiology

- ❖ **Inheritance:** ADI trait with variable expressivity even in the same family. As fertility is reduced, transmission through more than two generations is rare.
- ❖ **Genetic defect:** Gene located to chromosome 9q and 16q.

10. **Milia:** small white papules. Appear when subepidermal bullae heal.

11. **EBA:** bullae may appear on inflamed skin. *Cf.*, inherited EB where bullae invariably on nonerythematous (bland) skin.

Clinical Features

Classical triad of epilepsy, mental deficiency and adenoma sebaceum (angiofibromas), hence the acronym **epiloia** (**epi** = epilepsy, **loi** = low intelligence, **a** = adenoma sebaceum).

Cutaneous manifestations

❖ **Angiofibromas** (previously called adenoma sebaceum):

- Most frequent manifestation, seen in almost 90% of patients.
- Appear in childhood and enlarge at puberty (hence the misnomer “sebaceum”).
- Reddish brown, smooth, dome-shaped papules with telangiectasia (Fig. 3.19).
- Symmetrically, on nose, nasolabial folds, cheeks.

❖ **Ash leaf macules:**

- Seen in 80% of patients.

- Are the earliest manifestations, being present at birth.
- Dull, hypopigmented macules, rounded at one end and pointed at the other (Fig. 3.20).
- Single or numerous.
- Frequently on the trunk.

❖ **Shagreen patch (connective tissue nevus):**

- Seen in 40% of patients.
- Leathery cobble stoned, yellow–brown plaque resembling pig skin (Fig. 3.21).
- Lumbosacral area; less frequently on the face.

❖ **Periungual fibromas (Koenen’s tumors):**

- Present in 20% of patients.
- Develop in adult life.
- Small, pink, sausage-shaped growths arising from under the nail folds; may distort the nail plate (Fig. 3.22).

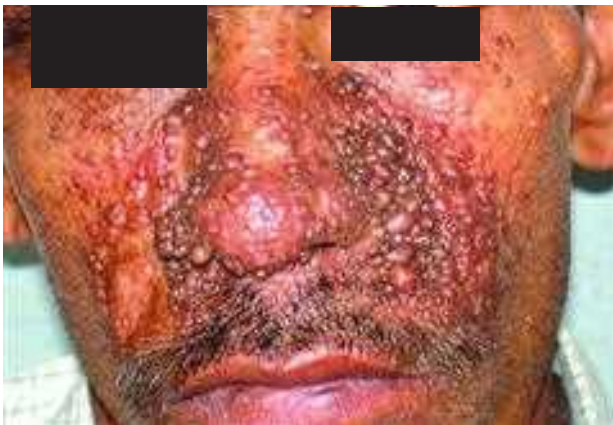

Fig. 3.19. Angiofibromas: dome-shaped papules with telangiectasia in the nasolabial folds and cheeks.

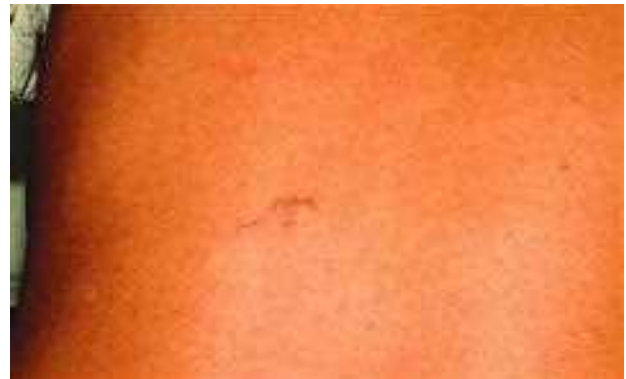

Fig. 3.21. Shagreen patch: leathery cobble stoned, yellow–brown plaque resembling pig skin in lumbosacral region.

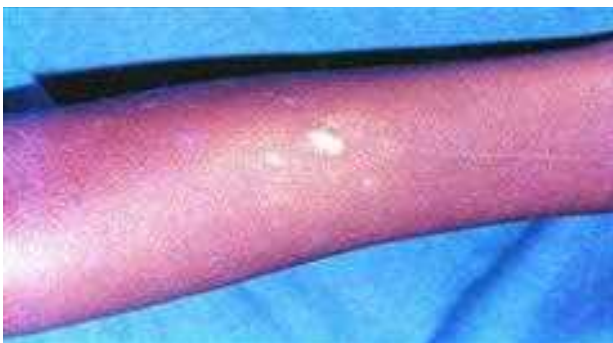

Fig. 3.20. Ash leaf macules: dull hypopigmented macules rounded at one end and pointed at the other.

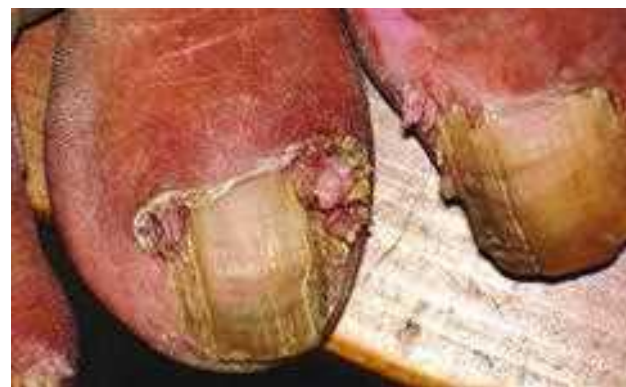

Fig. 3.22. Koenen’s tumors: small, pink, sausage-shaped growths arising from under the nail folds. May distort the nail plate.

Systemic manifestations

Neurological findings

- ❖ Seizures¹² (75% of patients).
- ❖ Mental retardation (50% of patients).

Ophthalmological findings

- ❖ Retinal and optic nerve hamartomas (50% patients).
- ❖ Pigmentary abnormalities (less frequent).

Renal and cardiac findings

- ❖ Tumors of heart (rhabdomyomas).
- ❖ Tumors in kidneys (angiomyolipomas).

Bone involvement

- ❖ Asymptomatic localized areas of sclerosis.
- ❖ Skull, spine, and pelvis.

Diagnosis

Criteria for diagnosis of TSC are shown in Table 3.7.

Treatment

- ❖ Genetic counselling.
- ❖ Prenatal diagnosis.
- ❖ No specific treatment:
 - *Facial lesions*: require cosmetic intervention with either diathermy or dermabrasion or laser therapy.
 - *Convulsions*: anticonvulsants.
- ❖ **Newer modalities**: Oral rapamycin for cerebral tumors.

Table 3.7. Criteria for diagnosis of TSC

Major features	Minor features
Facial angiofibroma/forehead plaque	Confetti multiple dental pits
Ungual fibroma	Gingival fibromas
Ash leaf macules (≥3)	Rectal polyps
Shagreen patch	Bone cysts
Multiple retinal tumors	
Cerebral tumors	
Renal angiomyolipoma	
Cardiac rhabdomyoma	

Definite TSC: + of either 2 major OR 1 major and 2 minor criteria.

Probable TSC: + of 1 major + 1 minor criteria.

Possible TSC: + of 1 major OR 2 minor criteria.

Neurofibromatosis

Synopsis

Inheritance: ADI; eight types, of which two are common: NF1, NF2.

NF1: Cutaneous features: More than six CALMs*. Dermal neurofibromas (molluscum fibrosum, plexiform neurofibromas). **Associated features**: Lisch nodules in iris (on slit lamp), central nervous system (CNS) features, low IQ, skeletal defects.

NF2: Acoustic neuromas but no cutaneous lesions.

Investigations: All patients should be evaluated by slit lamp (for Lisch nodules), assessment of IQ and an X-ray of skull/spine.

Treatment: Genetic counseling. Removal of symptomatic tumors (not as a routine).

*Cafe-au-lait macules

Etiology

- ❖ **Inheritance**: ADI, with 100% penetrance.

Clinical Features

Eight variants of neurofibromatosis (NF) recognized.

NF1

NF1 is characterized by:

- ❖ **Cutaneous neurofibromas**:
 - May not appear till puberty.
 - Manifest as:
 - Molluscum fibrosum (Fig. 3.23): Small, superficial, soft, skin-colored (sometimes darker), dome-shaped nodules, which can be pushed through a defect in the skin (**button hole sign**).
 - Plexiform neurofibromas: Diffuse plaques that feel knotty or wormy on palpation (Fig. 3.23).
- ❖ **Café-au-lait macules (CALMs)**:
 - Usually present at birth, but increase in number and size.
 - Light brown, oval macules with smooth border (Fig. 3.24).
 - Presence of six or more CALMs is diagnostic of NF1, even in the absence of cutaneous neurofibromas.
- ❖ **Axillary and inguinal (intertriginous) freckling**:
 - Present in 2/3 of affected individuals.

12. **Seizures**: due to cerebral tumors.

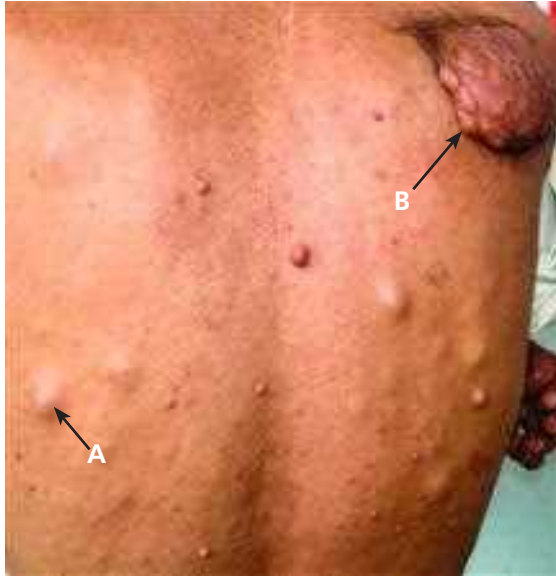

Fig. 3.23. Neurofibromatosis: molluscum fibrosum (A): small, superficial, soft, skin-colored (sometimes darker), dome-shaped nodules, which can be pushed through a defect in the skin (button hole sign). Note patient also has a plexiform neurofibroma (B).

- Appears in second decade.
- Pathognomonic of NFI.

❖ **Lisch nodules:**

- Present in almost all patients.
- On iris (on slit lamp examination).

❖ **Central nervous system:**

- Mental retardation (30%).
- Cerebral and spinal tumors (10%).

❖ **Associated features and complications:**

- Osseous lesions (sphenoidal dysplasia, thinning of cortex of long bones, pseudoarthrosis).
- Pheochromocytoma.
- Malignant transformation of neurofibromas.
- Optic pathway tumors.

NF2

NF2 is characterized by:

- ❖ Bilateral acoustic neuromas.
- ❖ Minimal cutaneous manifestations.
- ❖ Absence of Lisch nodules.

Other types of NF

- ❖ **Type 3 (mixed):** Combination of cutaneous and CNS involvement.
- ❖ **Type 4:** Variants.
- ❖ **Type 5:** Segmental lesions.

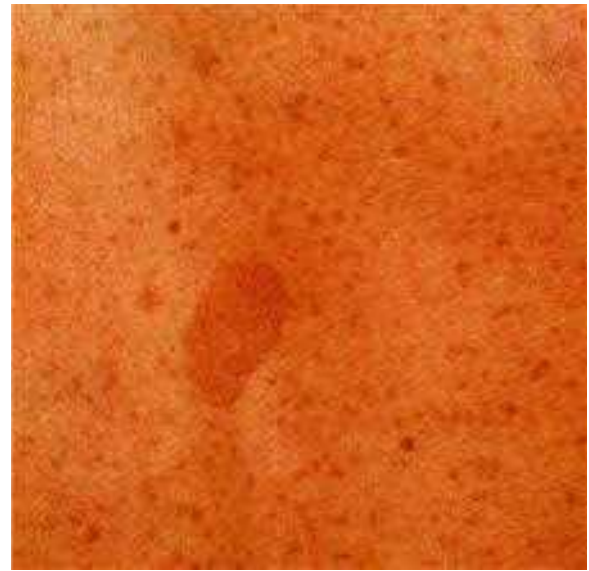

Fig. 3.24. CALM: uniformly light brown oval macule with smooth margin.

- ❖ **Type 6:** Only CALMs.
- ❖ **Type 7:** Late onset.
- ❖ **Type 8:** Unclassifiable.

Investigations

The following investigations should be done in all patients:

- ❖ Evaluation of intelligence quotient.
- ❖ Ophthalmological examination of eyes for Lisch nodules (by slit lamp), optic pathway tumors (visual acuity), color vision, perimetry and funduscopy.
- ❖ X-ray of skull/spine.

Other tests should be done based on the history, e.g., electroencephalogram if patient has seizures.

Diagnosis

Diagnosis of NF1 is based on the presence of two of the following:

1. Presence of at least six CALMs (>5 mm in prepubertal or >15 mm in postpubertal individuals).
2. Two or more neurofibromas of any type or one plexiform neurofibroma.
3. Multiple freckle-like lesions in axillae and groins.
4. First degree relative with NF1.
5. Optic glioma.
6. Lisch nodules (two or more).

7. Definite bone lesions (sphenoid dysplasia and/or thinning of cortex of long bones \pm pseudoarthrosis)

Treatment

Genetic counseling

- ❖ Patient's offspring have a 50% risk of developing neurofibromatosis, so genetic counseling is important.
- ❖ Prenatal diagnosis is still not possible but there may be a possibility in the near future.

Speech therapy

Surgery

Surgery is indicated if:

- ❖ Neurofibroma is cosmetically ugly, painful or there is a suspicion of malignant transformation.
- ❖ There is a surgically correctable skeletal defect.
- ❖ Phaeochromocytoma present.

Incontinentia Pigmenti

- ❖ Rare X-linked dominant disorder, seen only in females.

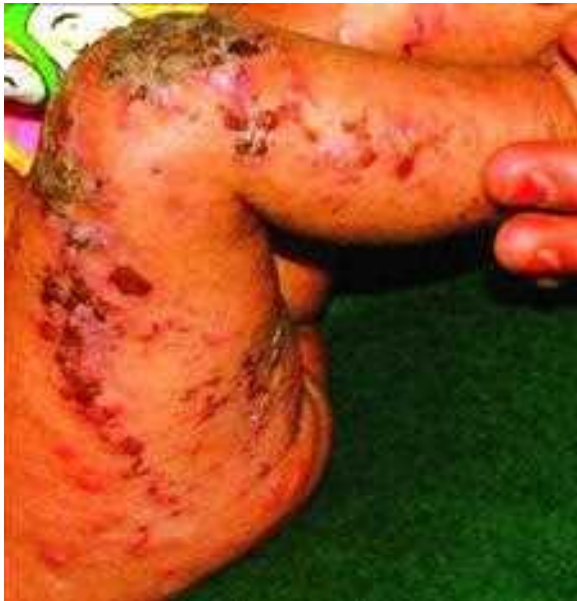

Fig. 3.25. Incontinentia pigmenti: broad linear bands of lesions consisting of hyperkeratotic papules and nodules. In this patient, some vesicular lesions are present—this is unusual, as the stage is *in utero*. Later the girl child developed whorled pigmentation.

- ❖ **Stages of skin lesions:** 3 stages seen:
 - *Vesicular:* initial stage, usually occurs *in utero*.
 - *Warty papules:* broad linear bands of hyperkeratotic warty papules seen after healing of the vesicular stage (Fig. 3.25).
 - *Pigmentation:* typical whorls of brown to slate-gray pigmentation replace the verrucous papules.
- ❖ **Associated abnormalities:**
 - Mental retardation, seizures, microcephaly.
 - Skeletal abnormalities.
 - Delayed and abnormal dentition.
 - Ocular defects in a third of patients.
- ❖ **Treatment:** Symptomatic.

Miscellaneous Genodermatoses

Xeroderma Pigmentosum (XP)

Etiology

- ❖ **Inheritance:** ARI. Heterogeneous group.
- ❖ **Molecular defect:** Normally, exposure to ultraviolet rays damages DNA¹³, which is repaired by excision and repair but in XP the repair of UV-damaged DNA is defective.

Clinical Features

- ❖ Photosensitivity, hallmark of disease.
- ❖ Child normal at birth. Soon develops multiple freckles and hypopigmented macules (Fig. 3.26)

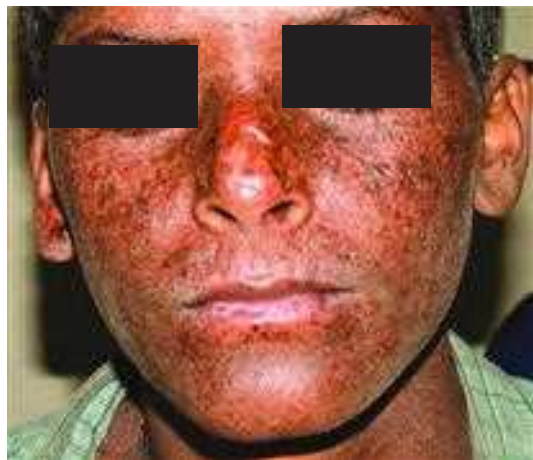

Fig. 3.26. Xeroderma pigmentosum: multiple freckles and hypopigmented macules on the face on a background of dryness.

13. **Damage to DNA:** due to the production of covalent linkages between adjacent pyrimidines.

on a background of dry, rough skin (hence xeroderma—dry skin).

- ❖ On photo-exposed parts.
- ❖ Patients eventually develop actinic keratosis, keratoacanthoma, basal cell carcinoma, squamous cell carcinoma and malignant melanoma.
- ❖ Many patients die before age of 20 years.

Treatment

- ❖ Photoprotection is most important:
 - Strictly avoid sunlight.
 - Use protective clothing.
 - Regular continuous use of sunscreens.
- ❖ Tumor surveillance and removal of overt neoplasia is essential.
- ❖ Topical retinoic acid and systemic retinoids to prevent neoplasia.

Acanthosis Nigricans (AN)

Synopsis

Classification: Several types: Hereditary, HAIR-AN syndrome, benign acquired, drug-induced, malignant.

Morphology: Thick velvety skin. Surface rugose and mammillated. Skin tags in benign acquired AN.

Sites: Neck, axillae and groins frequently. Other flexures less frequently.

Associations: Depend on type.

Treatment: Retinoic acid

Classification

- ❖ **Hereditary AN:** ADI
- ❖ **HAIR-AN syndrome:** Several endocrine disorders associated. **H**yperAndrogenism, **I**nsulin Resistance and **A**canthosis Nigricans.
- ❖ **Benign acquired AN:** Obesity¹⁴ associated. Earlier called pseudo AN.
- ❖ **Drug-induced AN:** Nicotinic acid, stilbestrol, corticosteroids, oral contraceptives.
- ❖ **Malignant AN:** Adenocarcinoma of stomach and genitourinary tract.

Clinical Features

Morphology

- ❖ Begins as hyperpigmentation and area appears dirty.
- ❖ Gradually, skin thickens and becomes velvety.

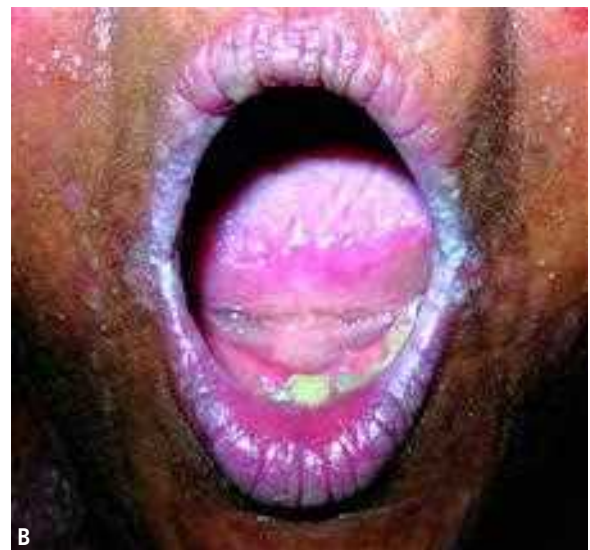
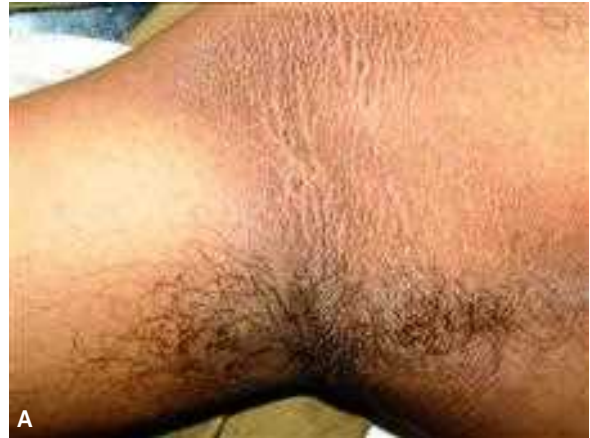
Fig. 3.27. Acanthosis nigricans. A: skin is thick and velvety, the surface of skin appearing rugose and mammillated. The edges of lesions are feathered. B: Mucosal involvement in malignant AN.

Surface of skin appears rugose and mammillated. The edge of lesion feathered (Fig. 3.27).

Sites of predilection

Neck, axillae, and groins frequently. Other flexures (antecubital and popliteal fossae, face sometimes; submammary folds, wrists less frequently; Fig. 3.28).

Associations

Depends on type of AN:

- ❖ **HAIR-AN syndrome:** Several endocrine disorders associated. Insulin-resistant diabetes mellitus, hyperandrogenic states, Cushing's syndrome.

14. **Obesity:** produces insulin resistance.

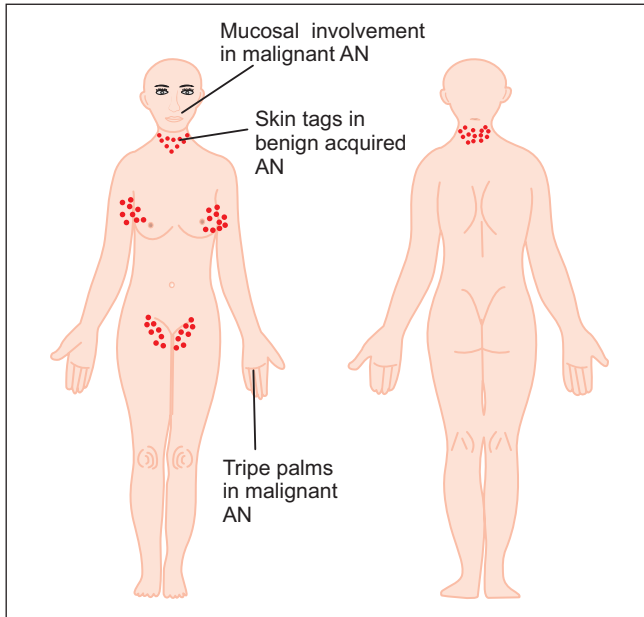


Fig. 3.28. Acanthosis nigricans: sites of predilection.

- ❖ **Benign-acquired AN:** Skin tags in the major flexures.
- ❖ **Malignant AN:** Several associations:
 - Tripe palms.
 - Mucosal involvement (Fig. 3.27B).
 - Severe itching.

Investigations

Rule out:

- ❖ Underlying endocrinopathies.
- ❖ Underlying malignancies.

Treatment

- ❖ Retinoic acid (0.025%) topically, response often unsatisfactory.

Darier's Disease

Synopsis

Etiology: ADI

Morphology: Multiple follicular (many) and nonfollicular (few) discrete, crusted papules. Confluence and hypertrophic lesions in flexures.

Sites of predilection: Seborrheic distribution.

Nails: V-shaped nicks.

Oral mucosa: Cobblestone lesions.

Treatment: Topical and systemic retinoids.

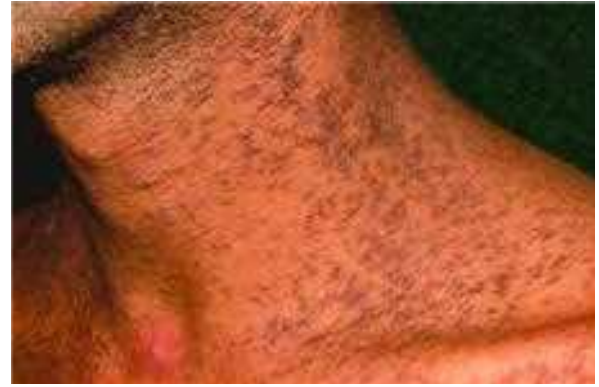

Fig. 3.29. Darier's disease: multiple discrete, crusted follicular and few nonfollicular papules.

Etiology

- ❖ **Inheritance:** ADI
- ❖ **Precipitating factors:** Summers, ultraviolet radiation, friction.

Clinical Features

- ❖ **Morphology:** Multiple, discrete, crusted follicular (sometimes nonfollicular) papules (Fig. 3.29). Become confluent, warty and foul smelling in flexures. Reveal a fissure/crater when the crust falls.
- ❖ **Sites of predilection:** Seborrheic distribution: scalp, forehead, nasolabial fold, retroauricular region, chest and middle of back, axillae and groins.
- ❖ **Nails:** V-shaped nicks.
- ❖ **Oral mucosa:** Cobblestone lesions on palate.

Diagnosis

- ❖ **Histopathology:** Diagnostic. Shows **corps ronds**¹⁵, **grains**¹⁶ and **acantholytic clefts**¹⁷.

Treatment

- ❖ **General measures:** Avoid precipitating factors.
- ❖ **Specific measures:**
 - *Limited lesions:* topical retinoids.
 - *Extensive lesions:* systemic retinoids.
- ❖ **Treatment of complications:** Like secondary infection in groins.

15. **Corps ronds:** eosinophilic dyskeratotic cells in the spinous layer.

16. **Grains:** eosinophilic dyskeratotic cells in the horny layer.

17. **Acantholytic clefts:** in suprabasal layer.

Papulosquamous Disorders

4

Chapter Outline

Psoriasis[•]

Definition

Etiology

Histogenesis

Epidemiology

Clinical features

Investigations

Diagnosis

Treatment

Self-Limiting Papulosquamous Dermatoses

Pityriasis rosea[•]

Lichen planus[•]

Chronic Papulosquamous Dermatoses

Pityriasis lichenoides[◦]

Pityriasis rubra pilaris[◦]

Parapsoriasis[◦]

Erythroderma[•]

Introduction

Papule¹ is a solid elevated lesion of the skin, <0.5 cm in diameter. When larger or deeper, lesion is called **nodule**. It may be produced by:

- ❖ Proliferation of cells of epidermis or dermis.
- ❖ Infiltration with inflammatory cells.
- ❖ Deposits in dermis.

Scale is flake-like exfoliation and represents visible shedding of the skin. Histologically, scaly lesions show **hyperkeratosis**² and **parakeratosis**³.

Papulosquamous disorders manifest as papules surmounted by scales. Many papules evolve into plaques either due to enlargement of individual papules or due to confluence of several adjoining papules. A plaque may be **discoid**⁴ or **annular**⁵. Annular plaques form when the center of a discoid plaque clears. Sometimes, papules in the periphery of a plaque are arranged in incomplete rings giving rise to gyrate lesions.

Papulosquamous lesions are characteristically present in psoriasis, lichen planus and seborrheic dermatitis, as also in disorders suffixed with the term **pityriasis**⁶, e.g., pityriasis rosea, pityriasis rubra pilaris and pityriasis lichenoides chronica (Table 4.1).

Both the morphology of the papule and character of the scale give clues to making a diagnosis (Tables 4.2 and 4.3).

1. **Papule**: sometimes taken as <1 cm.
2. **Hyperkeratosis**: means thickening of stratum corneum; could be **orthokeratosis**, i.e., cells of stratum corneum are not nucleated or due to **parakeratosis**.
3. **Parakeratosis**: means retention of nuclei in stratum corneum—normally, the stratum corneum does not contain nuclei.
4. **Discoid**: uniformly thickened.
5. **Annular**: centre normal/less thick, while periphery thicker and more prominent.
6. **Pityriasis**: means scaling.

[•]Should know
[◦]Good to know

Table 4.1. Diseases characterized by presence of papulosquamous lesions

Common ones	Less common ones
Psoriasis	Secondary syphilis
Lichen planus	Pityriasis rubra pilaris
Drug rash	Pityriasis lichenoides chronica
Seborrheic dermatitis	Pityriasis lichenoides <i>et</i> varioliformis acuta
Pityriasis rosea	Mycosis fungoides

Table 4.2. Morphology of papules/plaques in papulosquamous disorders

Psoriasis	Erythematous papules and plaques
Lichen planus	Violaceous papules with Wickham's striae
Pityriasis rosea	Annular plaques
Seborrheic dermatitis	Yellowish, follicular papules
Pityriasis rubra pilaris	Erythematous follicular papules
Secondary syphilis	Dusky erythematous papules
Pityriasis lichenoides et varioliformis acuta	Erythematous edematous papules surmounted with vesicles/crust
Pityriasis lichenoides chronica	Erythematous papules surmounted with mica-like scales

Psoriasis

Synopsis

Epidemiology: Prevalence 1%. Bimodal age distribution. No gender predilection. Winter aggravation frequent.

Morphology: Well-defined erythematous plaques with characteristic silvery, large, loose scales, accentuated by grating lesions. Auspitz sign positive. **Isomorphic phenomenon** seen. Variants include rupioid lesions.

Distribution: Scalp, pressure points and extensors. Sometimes generalized.

Patterns seen: Chronic plaque psoriasis (psoriasis vulgaris), guttate psoriasis. Lesions modified by site (scalp, flexures, penis, palms and soles).

Associations: Nail changes, arthritis.

Complications: Erythroderma, pustular psoriasis.

Treatment: *Localized lesions:* topical therapy with coaltar, dithranol, calcipotriol and PUVA sol. Topical steroids in special situations. *Generalized lesions:* narrow band UVB, PUVA sol, methotrexate, cyclosporine, acitretin. *Pustular psoriasis:* methotrexate, acitretin.

Definition

Psoriasis is a chronic dermatosis characterized by

Table 4.3. Characteristics of scales in papulosquamous disorders

Psoriasis	Silvery scales
Pityriasis rosea	Collarette of scales on leading edge
Seborrheic dermatitis	Greasy scales
Pityriasis lichenoides chronica	Mica-like, adherent scales

an unpredictable course of remissions and relapses and presence at typical sites of well-defined erythematous papules and plaques, which are surmounted with large, silvery loose scales. There is frequent nail and joint involvement.

Etiology

Unknown, but many factors have been incriminated (Table 4.4).

Histogenesis

Epidermal Changes

Two important changes are seen:

- ❖ **Increased epidermal cell proliferation:** Due to—
 - *Increased growth fraction*⁷: from normal of 30–100% in psoriasis.
 - *Shortened epidermal turnover time:* from normal of 60–10 days in psoriasis.
- ❖ **Parakeratosis:** Retention of nuclei in stratum corneum.

Dermal Changes

Two important changes are seen:

- ❖ Dilated and tortuous capillary loops.
- ❖ Proliferation of fibroblasts.

Epidemiology

- ❖ **Prevalence:** Roughly 1% of population is affected, but less than half require aggressive treatment.
- ❖ **Age:** Though can occur at any age, two peaks are seen:
 - *Early onset*, with peak incidence at 22.5 years; indicates more severe disease and such patients usually have positive family history.
 - *Late onset*, with peak incidence at 45.5 years.

7. **Growth fraction:** percentage of basal cells that are dividing.

Table 4.4. Pathogenesis of psoriasis

Genetic
<ul style="list-style-type: none"> ❖ May be autosomal dominant (with incomplete penetrance). Or polygenic. ❖ Genetic basis supported by: <ul style="list-style-type: none"> ➢ Increased familial cases. ➢ Greater concordance in monozygotic twins (70%) than in dizygotic twins (30%). ➢ Increased association of HLA-CW 6 (20 times increased risk) with early onset psoriasis. ➢ Identification of psoriasis genes⁸
Triggers
<ul style="list-style-type: none"> ❖ Physical trauma <ul style="list-style-type: none"> ➢ Scratches, surgical incisions and injuries (isomorphic or Koebner's phenomenon)⁹. ❖ Infections <ul style="list-style-type: none"> ➢ β-hemolytic streptococcal infection: precipitates guttate lesions. ➢ HIV infection: precipitates explosive psoriasis. ❖ Drugs <ul style="list-style-type: none"> ➢ Antimalarials, lithium, β-adrenergic blockers, NSAIDs. ➢ Corticosteroid withdrawal may aggravate psoriasis or may precipitate pustular lesions.
Biochemical changes
Cyclic nucleotides : \uparrow levels of cGMP or \downarrow levels of cAMP Arachidonic acid : \uparrow levels of arachidonic acid and its metabolites Polyamines : \uparrow levels Proteinases : \uparrow plasminogen activator and their inhibitors Calmodulin : \uparrow levels
Immunological factors
Psoriasis develops due to interplay of: <ul style="list-style-type: none"> ❖ Cells in the skin: <ul style="list-style-type: none"> ➢ <i>T-cells</i>: which play a key role, with the epidermal T cells being CD8⁺ and dermal cells being a mixture of CD4⁺ and CD8⁺ cells. Majority of these cells are memory T cells (expressing CLA, the skin homing receptor and chemokine receptor CCR4) but natural killer (NK) T cells may be important. ➢ <i>Keratinocytes</i>: express the transcription factor STAT-3, which may be pathogenic. ➢ <i>Langerhans cells</i>: secrete cytokines, which are mitogenic and chemotactic. ❖ Signaling molecules: involves interaction of cytokines, chemokines and growth factors and their receptors. Psoriasis is a type 1 helper T cell (Th1) disease with increased Th1 cytokines (IFN-γ and IL-2) and reduction of anti-inflammatory cytokine IL-10. Other molecules which may be important include IL-12, IL-23 and IL-15.

- ❖ **Sex:** Both sexes equally affected.
- ❖ **Season:** Most patients worse in winters.

Clinical Features

Evolution of Disease

- ❖ Usually chronic, indolent lesions, which persist for months.
- ❖ Less frequently, acute onset; two forms of acute presentations recognized:
 - Acute guttate psoriasis.
 - Generalized pustular psoriasis.

Morphology

Psoriasis vulgaris¹⁰ (chronic plaque psoriasis) is the commonest form of psoriasis. The primary lesion in psoriasis is a mildly itchy plaque or papule (Figs. 4.1 and 4.2) which is:

- ❖ **Well-demarcated:** An important feature for diagnosis in flexures and on glans, where other features like scaling may be absent.
- ❖ **Indurated.**
- ❖ **Erythematous:** Deep pink to red but may be modified by skin color; the plaque is often surrounded by a hypopigmented halo (**ring of Woronoff**).
- ❖ **Scaly:** Lesions are surmounted with silvery, white (due to presence of air trapped between scales), loose, lamellar scales (Fig. 4.1B); scaling is accentuated by grating with a glass slide (Fig. 4.3). Scaling is absent in flexures and on glans in uncircumcised patients. Scaling is also minimal in early lesions and in guttate lesions and is profuse in elephantine and rupioid psoriasis.
- ❖ **Discoid:** Initial lesions are discoid but may merge to form gyrate, polycyclic and geographic plaques. Central clearing results in annular lesions. When lesions develop at sites of trauma (**Koebner's or isomorphic phenomenon**), they may be linear (surgical incisions, scratch marks), or irregular (conforming to shape of injury).
- ❖ Size and number of lesions are variable.

8. **Psoriasis genes:** PSORS 1–8 genes, which are eight genes located on different chromosomes.

9. **Isomorphic phenomenon** (*iso*: similar, *morph*: form) or **Koebner's phenomenon**: new lesions of the original disease develop at sites of trauma (scratches, surgical incisions and injury). This phenomenon is seen in psoriasis, lichen planus, and vitiligo and indicates active disease. **Pseudo-isomorphic phenomenon**: is due to auto-inoculation and is seen in infections (like plane warts, molluscum contagiosum) and eczema.

10. **Vulgaris:** derived from the Latin word "vulgar", which during the Victorian era meant "common" (indicating the masses). Several dermatoses are suffixed with term vulgaris; lupus vulgaris (to differentiate it from less common lupus erythematous), acne vulgaris (*cf.*, acne rosacea), and pemphigus vulgaris (*vis-à-vis* pemphigus foliaceus); so vulgaris indicates the more frequent variant of the disease.

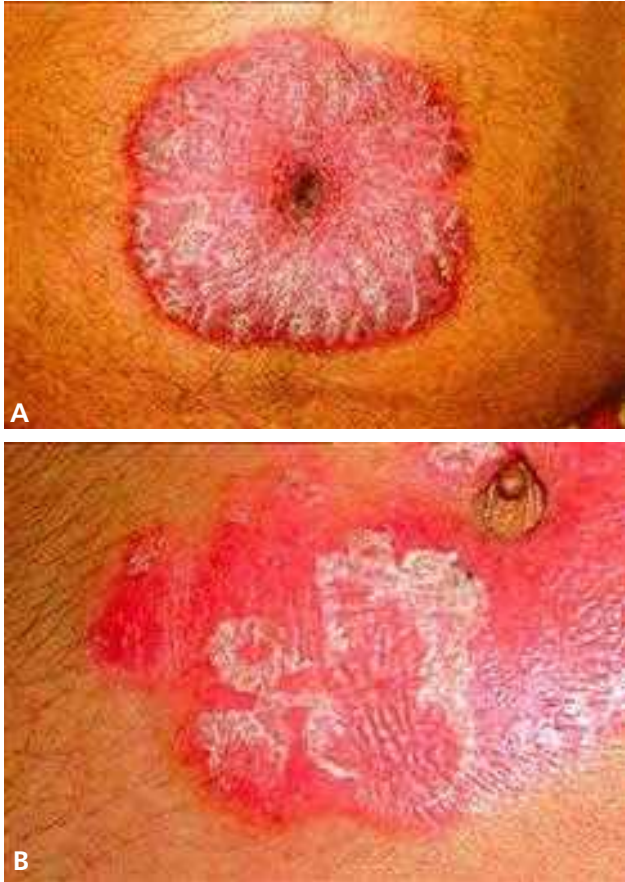


Fig. 4.1. Psoriasis vulgaris: A: typical plaque which is well-defined, discoid, erythematous, indurated and surmounted with loose silvery scales. B: easily removable lamellar, silvery scales.

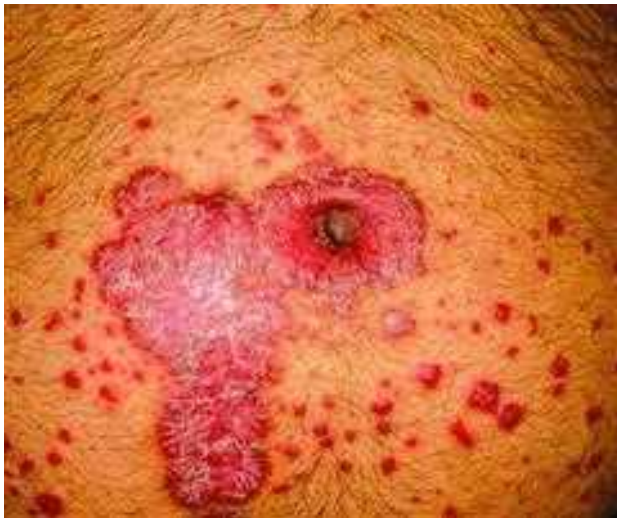

Fig. 4.2. Psoriasis vulgaris: discoid lesions become confluent to give rise to gyrate and polycyclic lesions.

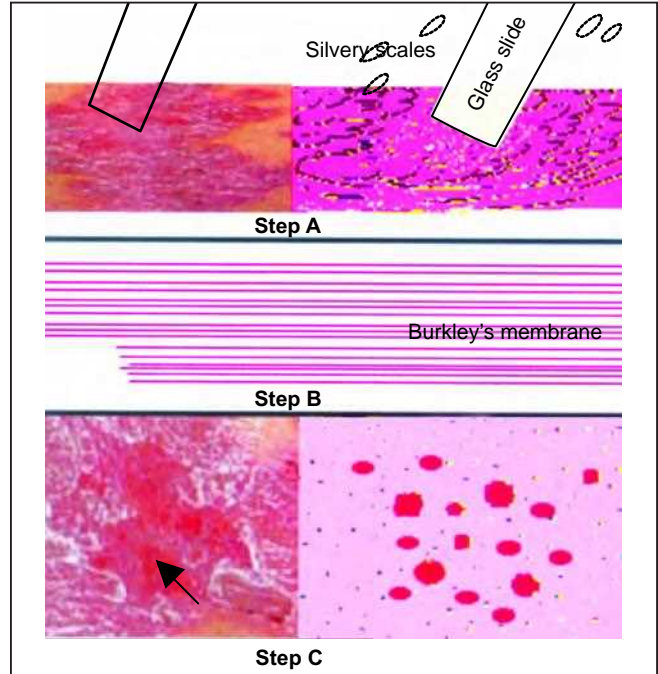


Fig. 4.3. Grattage test and Auspitz sign: accentuation of scales in a psoriatic plaque by grating with a glass slide (Step A) and finally appearance of bleeding points (Step C).

Bedside Tests

Two bedside tests may be done to confirm clinical diagnosis of psoriasis.

Grattage test

Scales in a psoriatic plaque can be accentuated by grating with a glass slide (Fig. 4.3, step A).

Auspitz sign¹¹ (Fig. 4.3)

There are three steps to this test:

- ❖ **Step A:** Gently scrape lesion with a glass slide. This accentuates the silvery scales (**Grattage test positive**). Scrape off all the scales.
- ❖ **Step B:** As you continue to scrape the lesion, a glistening white adherent membrane (**Burkley's membrane**) appears (Fig. 4.3, step B).
- ❖ **Step C:** On removing the membrane, punctate bleeding points become visible (Fig. 4.3, step C); this is **positive Auspitz sign**.

Sites of Predilection

- ❖ Bilateral, often symmetrical (Fig. 4.4).
- ❖ Favors pressure points (elbows and knees), scalp (from where it may spill on to forehead

11. **Auspitz sign:** now generally not performed and considered a test of historical significance.

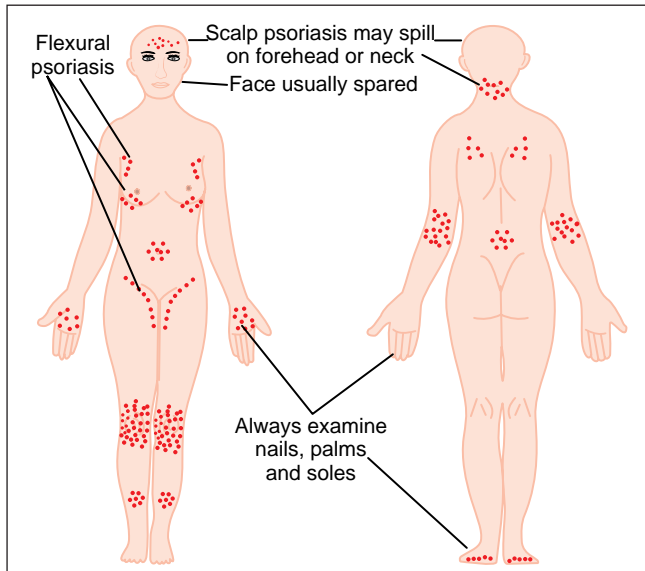


Fig. 4.4. Psoriasis: sites of predilection.

and nape of neck) and extensors (more than flexors). On trunk, lumbosacral region, back and periumbilical area are common sites of involvement.

- ❖ Infrequent involvement of photo exposed parts. Involvement of face uncommon and indicates refractory psoriasis.
- ❖ Intertriginous involvement in flexural psoriasis.
- ❖ Sites of trauma (as Koebner's phenomenon).

Variants

Morphological variants

Guttate psoriasis

- ❖ Occurs in children and adolescents.
- ❖ May be precipitated by streptococcal tonsillitis.
- ❖ Lesions appear in several crops (as a shower) of small erythematous papules (Fig. 4.5). Clear within a few weeks. Or evolve into plaque psoriasis.
- ❖ Predominant site: trunk.

Rupoid psoriasis

- ❖ Heaped up scales (Fig. 4.6A), so the lesions appear conical. Scales are firmly adherent to the underlying skin (**limpet-like**)¹².
- ❖ Such lesions are classically present in **Reiter's syndrome**¹³, which is characteristically associated with:

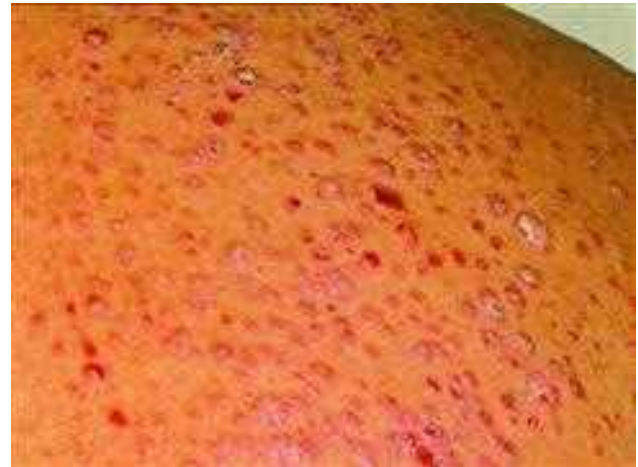


Fig. 4.5. Guttate psoriasis: in a 14-year-old boy, small erythematous scaly papules appeared in crops over the trunk, after an episode of sore throat.

- HLA B27.
- *Preceding infection*¹⁴: chlamydial genital tract infection or infectious dysentery (*Salmonella/Shigella*).
- Acute, asymmetric, additive, *ascending inflammatory arthritis* including severe sacroiliitis.
- *Keratoderma blennorrhagicum* (Fig. 4.6B): crusted exudative plaques on palms and soles.
- *Circinate balanitis* (Fig. 4.6C): moist, well-demarcated erosions with a slightly raised micropustular circinate border on glans.
- *Iridocyclitis*.

Modification by site

Flexural psoriasis

- ❖ Elderly females. Less frequently males.
- ❖ Though scaling is minimal because lesions are present in moist friction-prone areas, two characteristic features of psoriasis are retained:
 - *Definition*: lesions are well-defined (Fig. 4.7).
 - *Erythema*: lesions are salmon pink.
- ❖ Groins, axillae, inframammary folds, vulva, gluteal cleft.
- ❖ Depth of the fold may show fissuring.
- ❖ Needs to be differentiated from candidal intertrigo.

12. **Limpet**: is a small conical shellfish, which sticks to rocks.

13. **Reiter's syndrome**: is a reactive arthritis.

14. **Preceding infection**: usually symptomatic enteric infection or asymptomatic venereal infection.

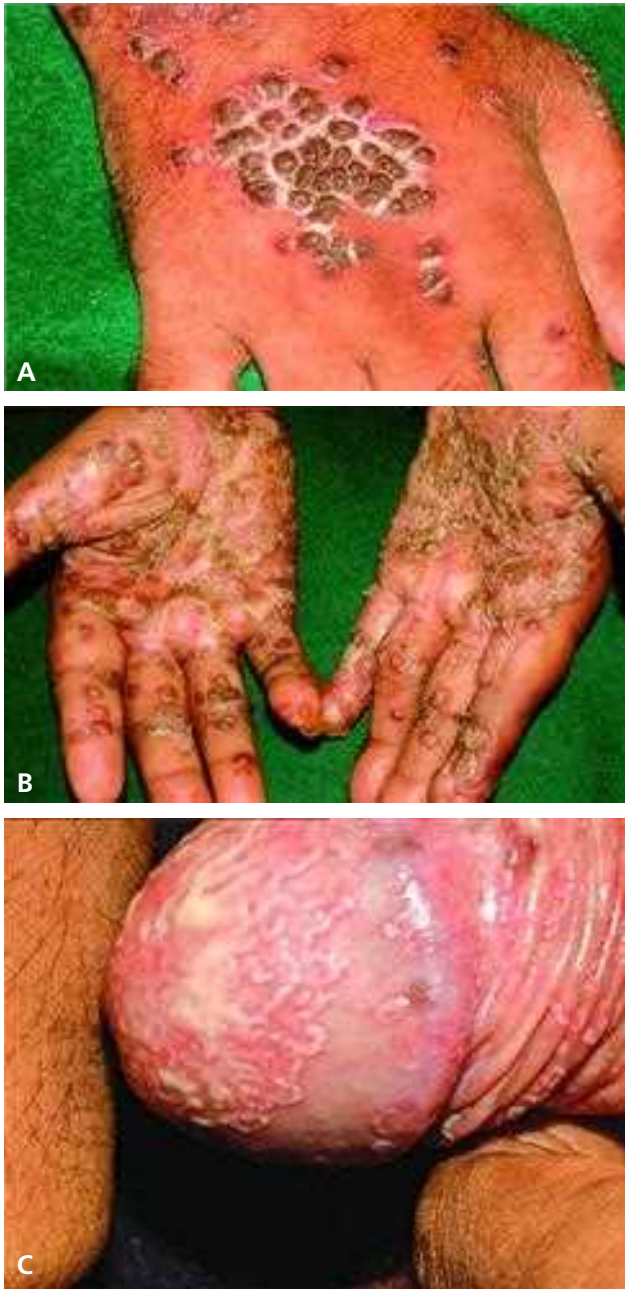

Fig. 4.6. Reiter's syndrome. A: rupoid psoriasis: heaped up, adherent, scaly lesions in patient with mutilating polyarthritis. B: keratoderma blennorrhagicum: crusted, exudative plaques on palms (and soles). C: circinate balanitis: moist, well-demarcated erosions with a slightly raised micropustular circinate border on glans.

Scalp psoriasis

- ❖ Sharply defined indurated scaly plaques (Fig. 4.8A).

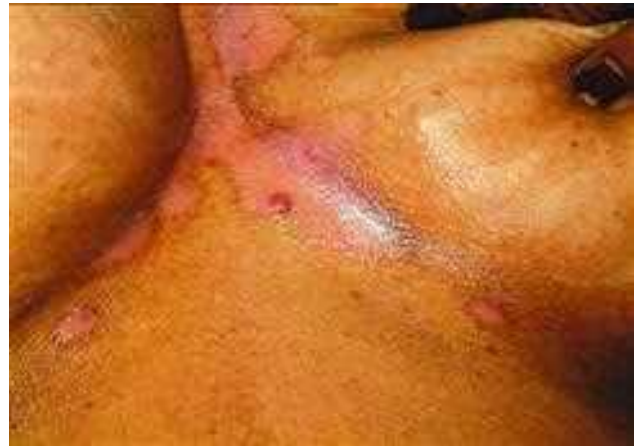

Fig. 4.7. Flexural psoriasis: well-demarcated, erythematous plaques in the inframammary area with minimal scaling in the depth of flexures.

- ❖ Scaling may be massive, especially on the occiput. Sometimes, the scaling is asbestos-like, being firmly adherent to the scalp (**pityriasis amiantacea**¹⁵; Fig. 4.8B).
- ❖ May spill onto forehead (Fig. 4.8A) and nape of neck.
- ❖ Involvement may be diffuse, in which case it should be differentiated from **seborrheic dermatitis**¹⁶.

Penile psoriasis

- ❖ In uncircumcised males, scaling is absent on glans but lesions continue to be erythematous and well-defined (Fig. 4.9).
- ❖ In circumcised patients, the lesions on the glans are similar to psoriatic lesions elsewhere.

Psoriasis of palms and soles

- ❖ Bilateral involvement (*cf.*, tinea manuum/pedis is unilateral).
- ❖ Symmetrical, well-defined, erythematous thickened plaques (Fig. 4.10). Silvery scales may be profuse or minimal. Scales may be adherent on palms and soles unlike loose scales on other parts.
- ❖ Erythema less obvious because of the thickness of stratum corneum.

Associations

In a patient with psoriasis always check for nail and joint involvement.

15. **Amiantacea:** asbestos-like. Pityriasis amiantacea is seen in psoriasis and seborrheic dermatitis.

16. **Seborrheic dermatitis of scalp:** lesions do not spill onto forehead and nape of neck, while psoriasis may.

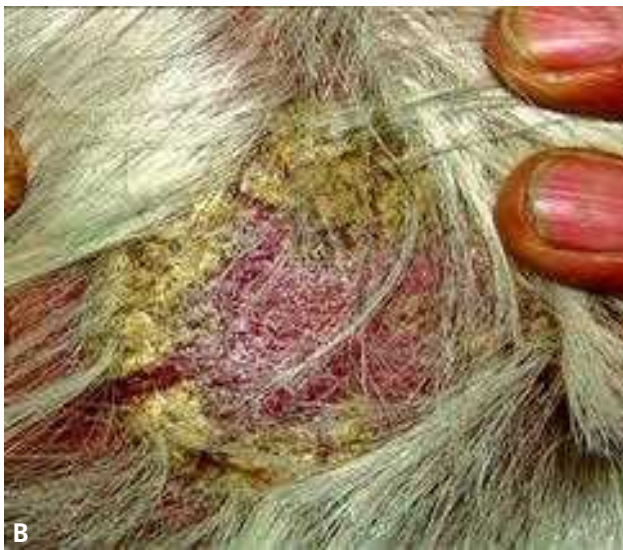
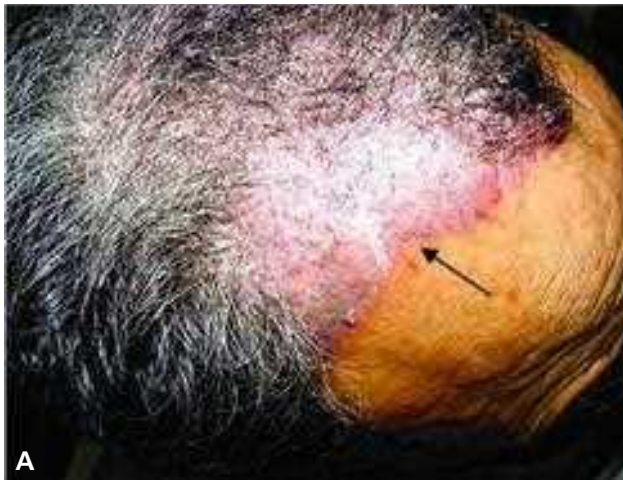
Fig. 4.8. Scalp psoriasis: A: sharply defined, localized, indurated scaly plaques. Note plaques on scalp spill onto forehead and nape of neck. B: pityriasis amiantacea: scaling is asbestos-like, being firmly adherent to scalp

Nails

- ❖ 10–50% of patients with psoriasis have nail involvement.
- ❖ Following changes are characteristic (Fig. 4.11A):
 - *Pitting*: small, regularly placed pits, like seen on a thimble (Fig. 4.11B).
 - *Nail plate thickening*¹⁷: which is not friable.
 - *Subungual hyperkeratosis*¹⁸: accumulation under nail plate of keratinous material, which does not crumble.

17. **Nail plate thickening**: also seen in onychomycosis (fungal infection of nails), but in this, the nail plate is tunneled.

18. **Subungual hyperkeratosis**: also seen in onychomycosis but in this, the subungual debris is friable.

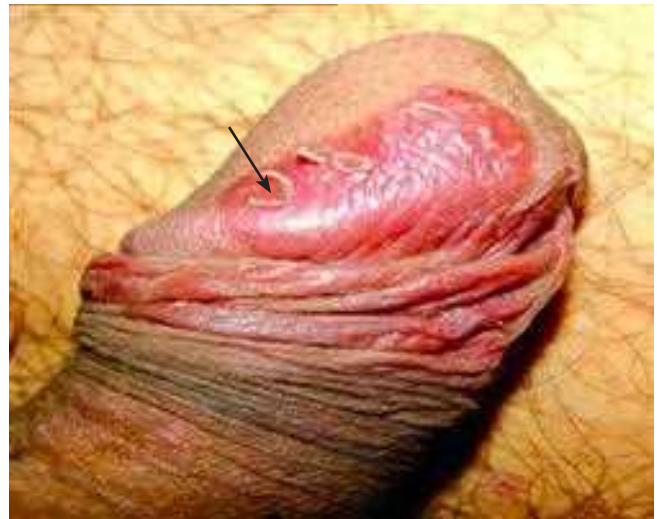

Fig. 4.9. Penile psoriasis: this uncircumcised patient had a well-defined erythematous plaque on the glans; lesion was only minimally scaly.

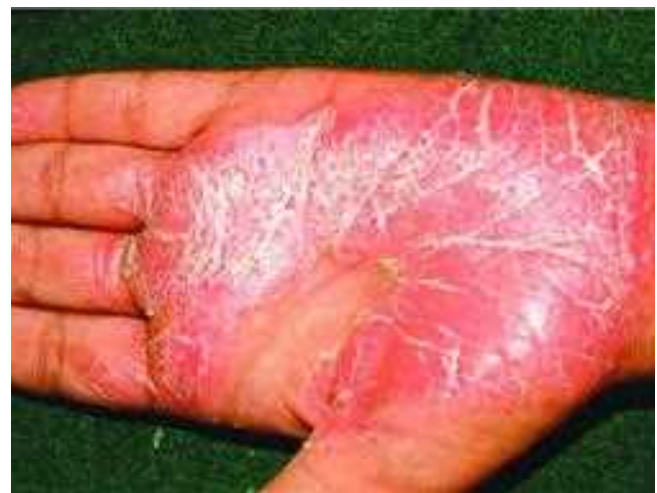

Fig. 4.10. Psoriasis of palms: well-defined, erythematous thickened plaques with silvery scales. Note the well-defined edge. On the palms and soles, the scales may be adherent.

- *Discoloration and dystrophy of nail plate*: nail plate becomes yellow or brown and dystrophic.
- *Onycholysis*: separation of nail plate from the nail bed.
- *Oil spots*: due to nail bed psoriasis and is specific for psoriasis.

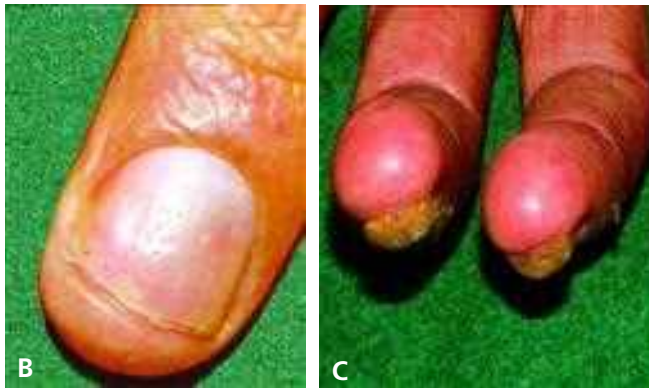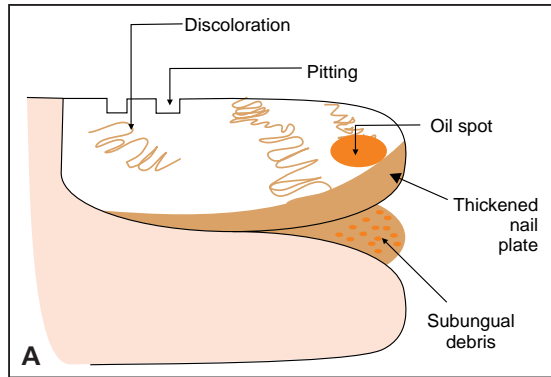


Fig. 4.11. Psoriasis of nail. A: nail changes include pitting, nail plate thickening, subungual hyperkeratosis, onycholysis and discoloration of nail plate. B: small regularly placed pits and onycholysis. C: thickening of nail plate.

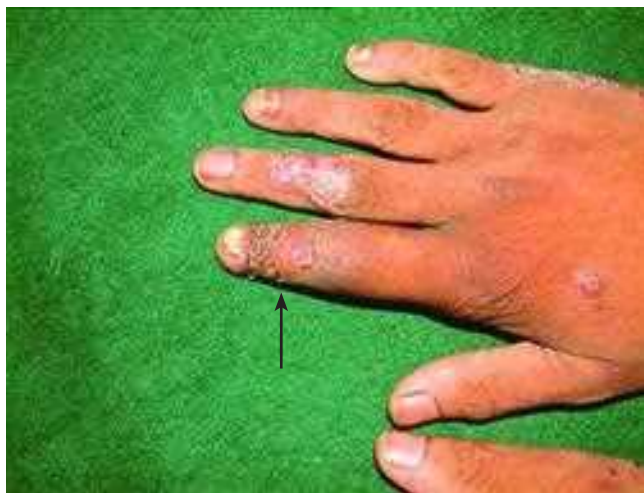

Fig. 4.12. Psoriatic arthritis: distal interphalangeal joints involved (dactylitis) with prominent nail changes.

Joints

- ❖ **Prevalence:** 10% of patients with psoriasis have joint involvement (Fig. 4.12).
- ❖ **Patterns:** Four patterns recognized:
 - *Asymmetrical oligoarticular arthritis:* commonest; involves usually joints of hands and feet leading to dactylitis¹⁹ due to joint involvement and flexor sheath inflammation.
 - *Distal interphalangeal (DIP) arthritis:* involves DIP²⁰ and there are marked nail changes.
 - *Rheumatoid arthritis-like:* predominantly symmetrical, seronegative and less severe.
 - *Arthritis mutilans:* uncommon; severely deforming arthritis of fingers and toes.
 - *Axial arthritis:* spondylitis, sacroiliitis with or without peripheral joint involvement; strongly associated with HLA B27.
- ❖ **Radiological changes:** Simultaneous presence of ankylosis, periosteal new bone formation, erosions and osteolysis are strongly suggestive of psoriatic arthritis.

Complications

Erythrodermic psoriasis

- ❖ Common complication.
- ❖ **Precipitating factors:** Precipitated by
 - Irritant effect of topical therapy.
 - Withdrawal of topical/systemic steroids used for treating psoriasis.
- ❖ **Clinical features:**
 - Psoriatic plaques lose their definition and merge. Skin becomes uniformly red with marked scaling. Involvement is generalized (Fig. 4.13).
 - **Complications:** like hypothermia, hyperthermia, water and electrolyte imbalance and hypoproteinemia may develop, especially in elderly.

Pustular psoriasis

- ❖ **Precipitating factors:** Pustulation precipitated by:
 - Irritant effect of topical therapy
 - Withdrawal of topical or systemic steroids.

19. **Dactylitis:** leading to sausage-shaped digits.

20. **DIP:** cf., in rheumatoid arthritis proximal interphalangeal joints are involved.

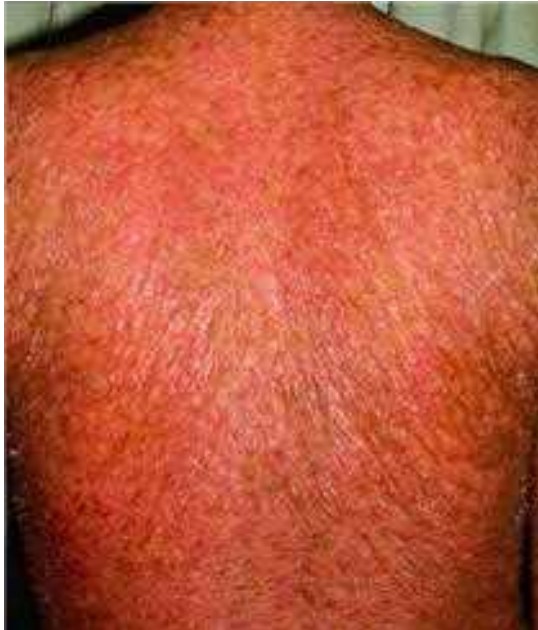

Fig. 4.13. Erythrodermic psoriasis: generalized involvement with loss of definition of the plaques.

❖ **Clinical features:** Pustulation can be:

- **Localized:** as seen in palmoplantar psoriasis (Fig. 4.14).
- **Generalized:** as seen in **von Zumbusch's pustular psoriasis** which is:
 - A serious condition accompanied by constitutional symptoms (high fever, chills, tachypnea).
 - Characterized by generalized fiery red erythema followed by appearance of tiny waves of superficial pustules (often can be easily wiped off!), which become confluent to form circinate lesions and lakes of pus (Fig. 4.15).
 - Appearance of new pustules as the old ones are crusting.

Investigations

Biopsy

Skin biopsy shows the following (Fig. 4.16):

- ❖ **Parakeratosis**²¹
- ❖ **Regular acanthosis**²²
- ❖ **Suprapapillary thinning**²³

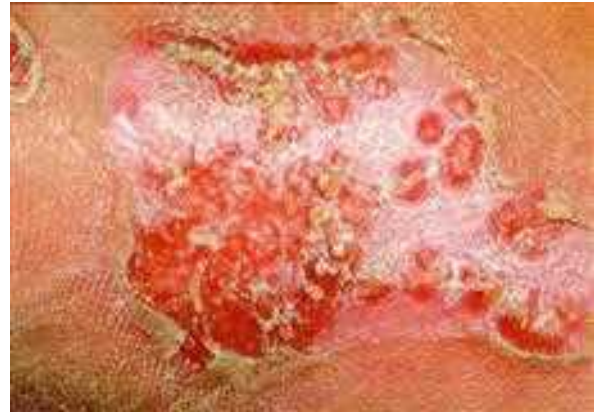

Fig. 4.14. Pustules in plantar psoriasis: typical plaque of psoriasis surmounted by pustules.

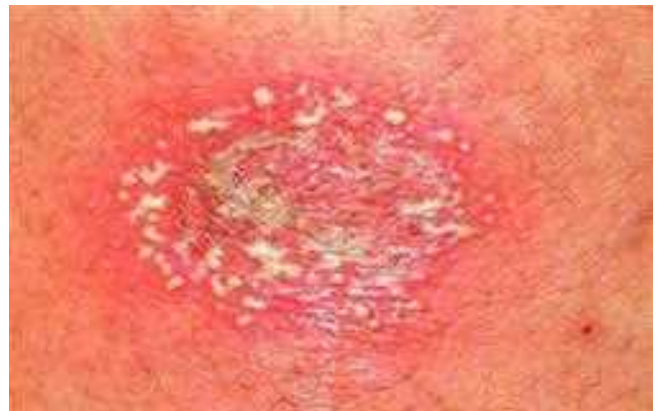

Fig. 4.15. Generalized pustular psoriasis: lakes of pus on a fiery red background; pustules appear in waves and can be easily wiped off.

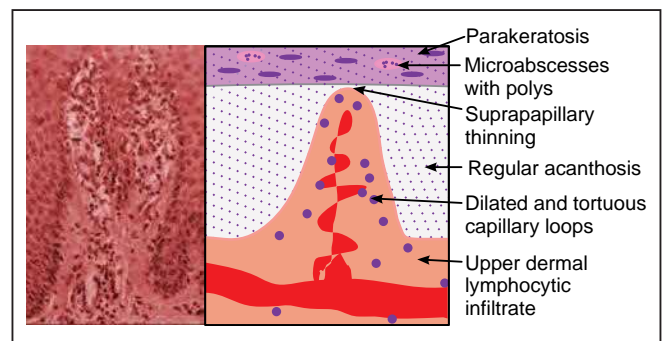


Fig. 4.16. Histopathology of psoriasis: parakeratosis, acanthosis, suprapapillary thinning, collection of polymorphs in epidermis, tortuosity of capillary loops in dermal papillae and lymphocytic infiltrate in dermis.

21. **Parakeratosis:** nuclei retained in horny layer.

22. **Acanthosis:** thickening of viable epidermis.

23. **Suprapapillary thinning:** the histological marker of Barkley's membrane in Auspitz sign with the tortuous capillaries being responsible for pin-point bleeding.

- ❖ Collection of polymorphs in the epidermis forming micro-abscesses (**Munro's micro-abscesses**).
- ❖ Dilatation and tortuosity of capillary loops in the dermal papillae.
- ❖ Lymphocytic infiltrate in the upper dermis.

Biochemical Changes

- ❖ Hypocalcemia, especially in pustular psoriasis.
- ❖ Anemia and hypoproteinemia, in erythrodermic psoriasis.

Radiological Changes

Simultaneous presence of ankylosis, periosteal new bone formation, erosions and osteolysis strongly suggestive of psoriatic arthritis.

Diagnosis

Points for Diagnosis

Diagnosis of psoriasis is based on:

- ❖ Winter aggravation.
- ❖ Morphology of lesions:
 - Well-defined plaques.
 - Deep red color.
 - Loosely attached, silvery scales, accentuated by grattage
- ❖ Positive grattage test and Auspitz sign.
- ❖ Distribution (pressure points, scalp and extensors of trunk and extremities; relative sparing of face).
- ❖ Associated nail involvement (50%) and joint involvement (10%).

Differential Diagnosis

Psoriasis (Ps) should be differentiated from:

a. Discoid eczema

Discoid eczema	Ps
Itching: severe	Variable itching
Morphology: crusted, exudative plaques	Scaly (silvery), dry plaques
Definition: not very well-defined	Very well-defined
Nail changes: only if lesions on nail fold	In 50% of patients

b. Seborrheic dermatitis (SD)

SD	Ps
Scalp	
Diffuse	Well-defined
Less indurated	Indurated
Spillage: on neck, forehead	Present
Scales: greasy, perifollicular	Silvery
Flexural	
Itching severe	Moderate
Less well-defined	Well-defined
Less erythematous	Very erythematous
Associated features	
	Nail changes (50%)
	Joint involvement (10%)

c. Hyperkeratotic hand eczema (HHE)

HHE	Ps of hands
More itchy	Less itchy
Less well-defined	Very well-defined; hyperkeratosis on knuckles
Less erythematous	More erythematous
Vesicles frequently present	Pustules occasionally present

d. Pityriasis rosea (PR)

PR	Ps
Self-limiting	Chronic course of remissions & relapses
Larger patch heralds eruption in 80%	Variable onset
Oval lesions; most lesions annular, unless papular variant	Discoid/gyrate lesions; healing lesions may be annular
Collarette of scales on active edge	Silvery scales present uniformly on lesion
Trunk; lesions tend to run along rib lines	Pressure points, scalp, extensor of extremities and trunk, especially lower back.

e. Candidal intertrigo

Candidal intertrigo	Flexural psoriasis
Less well-defined; frayed edges	Well-defined
Less erythematous	Deeply erythematous
Satellite pustules	Not seen

f. Secondary syphilis

Secondary syphilis	Guttate Ps
History of preceding high-risk sexual contact	History of upper respiratory tract infection
Papulosquamous lesions	Papules surmounted with silvery scales
Associated features	
Mucosal lesions Coppery scaly papules on palms and soles Condyloma lata Lymphadenopathy	

Treatment

The treatment of psoriasis should be individualized and depends on patient and disease factors (Table 4.5).

Table 4.5. Factors influencing treatment

Patient factors	Disease factors
Age	Type of psoriasis
Sex	Severity of psoriasis ²⁴
Quality of life index ²⁵	Comorbidities

General Measures

- ❖ Counseling of patients very important. Reassurance and emotional support are invaluable.
- ❖ Inform the patient:
 - That psoriasis is not contagious and is benign.
 - That disease is associated with relapses and remissions.
 - That treatments available are suppressive and not curative!
 - That several treatment options are available.
- ❖ Physical activity and mental rest may enhance effect of specific therapy.

Treatment Options

Depending on the type of psoriasis, various therapeutic options are available:

- ❖ Topical agents (Table 4.6).
- ❖ Systemic agents (Table 4.7).
- ❖ Photochemotherapy and phototherapy (Table 4.8).
- ❖ Steroids, but only topical! (Table 4.9).
- ❖ Biologicals.

Steroids

Steroids (only the topical ones!!) once a taboo are now used frequently especially in combination.

❖ Topical Steroids

- Judicious and monitored use of topical steroids is a good therapeutic option in managing limited stable plaque psoriasis (Table 4.10)
- *Advantages:*
 - ⊕ Efficacy and ease of application and removal
 - ⊕ Lack of irritation
 - ⊕ Absence of staining of skin or linen.
 - ⊕ Can be combined with coal tar, calcipotriol and tazarotene with benefit.
- *Disadvantages:*
 - ⊕ Long-term use causes dermal atrophy, tachyphylaxis and rarely (when used in extensive lesions) adrenal suppression (due to systemic absorption but this has questionable clinical relevance).
 - ⊕ Early relapses.
 - ⊕ Precipitation of unstable psoriasis (occasionally).

❖ Systemic steroids

- Rapid response but withdrawal associated with precipitation of generalized pustular psoriasis and erythroderma.
- Only indication is generalized pustular

24. **Severity of psoriasis:** two measures of severity are used—body surface area (BSA) and psoriasis area severity index (PASI). BSA is a good measure of extent of psoriasis, but PASI is better because apart from surface area, it quantifies erythema, scaling and induration.

25. **Quality of life (QOL) indices:** these measure the disability a particular disease is causing in an individual, e.g., psoriasis of the same extent and severity causes different alterations in QOL in two different patients, depending on several individual and socio-cultural factors.

Table 4.6. Topical agents to treat psoriasis

Agent	Mode of application	Indications	Disadvantages	Comments
Coal tar (CT) ²⁶ 3–6% Formulated in petrolatum often with salicylic acid	Daily application of CT (even as a bath) followed by exposure to UVL	<ul style="list-style-type: none"> ❖ CPP* with BSA <10% ❖ Adjunct to systemic therapy 	<ul style="list-style-type: none"> ❖ Chemical folliculitis²⁷ common ❖ Irritant and allergic contact dermatitis (uncommon) ❖ Skin malignancies (extremely rare) 	<ul style="list-style-type: none"> ❖ Very safe ❖ 80% patients with limited CPP* achieve remission in 6–8 weeks. ❖ Improved response when combined with salicylic acid.
Dithranol ²⁸ 0.05%, 0.25–2% Formulated with salicylic acid	<ul style="list-style-type: none"> ❖ Method: 1. Conventional: lower concentration (0.05%) applied for 18–22 h daily. 2. Short contact: higher concentration (0.25–2%) applied for 10–30 minutes ❖ Protect surrounding skin with bland paste (like zinc oxide. Or petrolatum. ❖ Avoid on face, flexures and genitals. 	<ul style="list-style-type: none"> ❖ CPP*, when few large plaques are present 	<ul style="list-style-type: none"> ❖ Irritation: reduced by: <ul style="list-style-type: none"> ➢ applying carefully, ➢ starting with lower concentration and shorter duration ➢ avoiding on sensitive areas. ❖ Discoloration of normal skin: fortunately, peels off in a few days! ❖ Discoloration of clothes 	<ul style="list-style-type: none"> ❖ Short contact therapy as effective as conventional therapy but less cumbersome. ❖ CPP* clears in 3–6 weeks (in experienced hands!) ❖ No systemic absorption, so safe
Calcipotriol ²⁹ 0.005% Can be combined with topical steroids.	<ul style="list-style-type: none"> ❖ Twice daily application. ❖ Do not exceed 100 g/week. 	<ul style="list-style-type: none"> ❖ Localized CPP* in a(n) (affluent!) patient who finds CT and dithranol unacceptable 	<ul style="list-style-type: none"> ❖ Avoid in extensive psoriasis (systemic absorption) 	<ul style="list-style-type: none"> ❖ Cost prohibitive ❖ Odorless, colorless (does not stain skin or clothes) ❖ Easy to apply and remove ❖ No irritation
Tazarotene ³⁰ 0.05–0.1% Can be combined with CT and topical steroids	<ul style="list-style-type: none"> ❖ Once daily application ❖ Protect surrounding skin with petrolatum ❖ If irritation, reduce duration of contact 	<ul style="list-style-type: none"> ❖ Localized CPP* 	<ul style="list-style-type: none"> ❖ Irritation ❖ Reduces scaling and plaque thickness but not erythema 	<ul style="list-style-type: none"> ❖ Newer topical retinoid

*CPP: chronic plaque psoriasis

26. **Coal tar:** CT along with UVB is antimitotic and inhibits chemotaxis.

27. **Chemical folliculitis:** appearance of sterile follicular pustules.

28. **Dithranol:** inhibits DNA synthesis.

29. **Calcipotriol:** probably reduces epidermal proliferation.

30. **Tazarotene:** keratoplastic agent.

Table 4.7. Systemic agents to treat psoriasis

Drug/dosage	Indications	Side effects	Monitoring
Methotrexate (Mtx)³¹ ❖ Test dose: (often skipped) of 2.5–5 mg ↓ Hemogram, LFT** ❖ Regular dose: 7.5–25 mg weekly (for an adult), orally > As a single dose. > Or in three divided doses at 12 hourly intervals ❖ Always add folic acid, 5 mg weekly to reduce side effects	❖ Generalized pustular psoriasis ❖ Erythrodermic psoriasis ❖ CPP* unresponsive to conventional therapy ❖ Palmoplantar psoriasis (in small doses) ❖ Debilitating psoriatic arthritis Comments Commonest systemic therapy used in psoriasis (efficacy, ease of use and low cost)	❖ Nausea, fatigue, alopecia ❖ Hepatotoxicity: (leading to fibrosis) very important, (especially in those who consume alcohol or have diabetes, obesity) ❖ Bone marrow suppression: manifests as leucopenia and thrombocytopenia. Treated by 25 mg of leucovorin intramuscularly (folinic acid rescue) preferably within first 4 h. ❖ Teratogenicity and mutagenicity: so use contraception: for 1 month in females and 3 months in males.	❖ Baseline: hemogram, LFT**, RFT***, chest X-ray ❖ Follow up: > Hemogram, LFT** weekly × 4 weeks; then 4–8 weekly. > RFT***: yearly unless suspicion of kidney dysfunction. Titrate dose, if RFTs*** impaired (as excreted through kidneys). > Liver biopsy: only when Mtx dose reaches 3.5 g. Earlier in patients with risk of hepatic dysfunction. ❖ Avoid concurrent use of aspirin, sulfonamides, tetracyclines, frusemide. Or reduce dose of Mtx.
Acitretin³² 25–50 mg daily, preferably after meals Comments Expensive	❖ Pustular psoriasis ❖ Psoriasis erythroderma ❖ Less effective in CPP Comments Expensive	❖ Minor side effects: universal and reversible—so do not stop drug. Cheilitis, dryness of mouth, vagina, and eyes (so avoid contact lenses). Peeling of skin and pruritus (so use emollients). ❖ Teratogenicity: Avoid in women of child-bearing age. If at all prescribed, contraception (by two different methods) mandatory for minimum of <u>3 years</u> after treatment is stopped (because of long half-life of the drug and metabolites). ❖ Elevation of triglycerides (more frequent) and cholesterol. ❖ Liver toxicity. ❖ Ossification of paraspinal ligaments (DISH) ❖ Do not donate blood for 3 years after stopping Rx	❖ Lipid profile and LFT**: Baseline, at 4 weeks, and then 3 monthly. Stop acitretin if SL raised or add a lipid-lowering agent. ❖ Yearly X-ray of spine for ossification of paraspinal ligaments. ❖ Pregnancy test: Monthly during treatment; 3 monthly thereafter for 3 years.
Cyclosporine³³ Initial daily dose of 3–5 mg/kg reduce dose with improvement	❖ Pustular psoriasis ❖ Psoriatic erythroderma Comments Expensive; used in presence of liver damage.	Use with great caution, because of several adverse effects: ❖ Hypertension: mild–moderate in 50% of patients. Treat with calcium-channel blockers (amlodipine) or ACE inhibitors. Avoid diuretics (worsen renal function) and beta blockers (worsen psoriasis) ❖ Nephrotoxicity. ❖ Drug interactions: erythromycin, NSAIDs, several others.	❖ BP: (Daily initially and then weekly). ❖ Serum creatinine: Baseline. Then weekly and later monthly. > Dose reduction by 25–50%, if serum creatinine level rises to 30% > baseline. > Drug withdrawn if creatinine level persistently elevated, despite dose reduction.

* CPP: chronic plaque psoriasis

**LFT: liver function tests

***RFT: renal function tests

31. **Mtx:** folic acid antagonist, which inhibits DNA synthesis in 'S' phase. Potent antiinflammatory action (suppresses lymphocytes).
32. **Acitretin:** regulates growth and terminal differentiation of keratinocytes, (so normalizes hyperproliferation). Also antiinflammatory effect.
33. **Cyclosporine:** inhibits cell-mediated immunity due to inhibition of lymphocyte mitosis and release of lymphokines. Also direct antiproliferative effect on keratinocytes.

Table 4.8. Photochemotherapy and phototherapy to treat psoriasis

Drug/Method of therapy	Indications	Advantages	Adverse effects
<p>Photochemotherapy³⁴</p> <ul style="list-style-type: none"> ❖ Drugs used: 8-methoxypsoralen, 0.6–0.8 mg/kg. Less frequently, trimethyl psoralen (1.2 mg/kg) ❖ Taken after breakfast on alternate days. <div style="text-align: center;"> <pre> graph TD A[Application of petrolatum³⁵] --> B[1-2 h later] B --> C[Exposure to UVA (supplied by special chambers):] </pre> </div> <ul style="list-style-type: none"> ❖ Exposure to UVA (supplied by special chambers): <ul style="list-style-type: none"> ➢ Initial exposure based on either: <ul style="list-style-type: none"> • skin type: fair skinned, 0.5 J/cm²; dark skinned, 2.0 J/cm². Or • on MPD³⁶. ➢ UVA dose gradually increased depending on erythema produced and therapeutic response. 	<ul style="list-style-type: none"> ❖ Extensive CPP* (especially those resistant to topical treatment). ❖ Psoriatic erythroderma. 	<p>Lesions usually clear in 5–10 weeks. Patients may need to be maintained on treatment once in 1–2 weeks.</p>	<ul style="list-style-type: none"> ❖ Phototoxicity (intense erythema) due to excessive exposure to UVR. Minimized by careful dosimetry. ❖ Nausea and giddiness common. Minimized by splitting dose of psoralens. ❖ Premature aging of skin, pigmentation, wrinkling and atrophy. ❖ Development of cutaneous malignancies controversial. ❖ Cataract. Prevented by using UVA blocking sun glasses for 12 h, after psoralen ingestion.
<p>Variations of PUVA:</p> <ul style="list-style-type: none"> ❖ PUVA sol: Uses solar energy as source of UVA. ❖ Topical PUVA/PUVA sol: UV exposure, ½ hour after application of topical psoralens. ❖ Bath PUVA: Soaking in bath water containing trimethyl psoralen and immediately exposing to UVA. 	<p>PUVA sol: As for PUVA.</p> <p>Topical PUVA and PUVA sol: Palmoplantar psoriasis.</p> <p>Bath PUVA: As for PUVA.</p>	<p>PUVA sol: Reduces cost.</p> <p>Topical PUVA and bath PUVA</p> <ul style="list-style-type: none"> ❖ Lack of systemic effects (especially nausea). ❖ Lower UVA dose. ❖ No eye protection needed. 	
<p>Phototherapy³⁷</p> <ul style="list-style-type: none"> ❖ UVB therapy (now obsolete). ❖ Narrow band UVB (311 nm). 	<ul style="list-style-type: none"> ❖ Treatment of choice in CPP with BSA >10% especially in <ul style="list-style-type: none"> ➢ Pregnant females. ➢ Patients with renal/hepatic dysfunction. ➢ Patients who are immunocompromised. 	<ul style="list-style-type: none"> ❖ No side effects of drugs, so safe in pregnancy, liver/renal disease. 	

*CPP: Chronic plaque psoriasis

34. **Photochemotherapy:** acts by inhibiting DNA synthesis and epidermal cell turnover by forming photoadducts (in presence of UVA) with DNA bases.

35. **Topical application of petrolatum:** to reduce scattering of light.

36. **MPD:** minimal phototoxic dose. Needs to be determined for each patient by exposing the back of patient to geometrically increasing doses of UVA, 2 h after ingestion of psoralen and finding the minimum dose of UVA, which caused erythema at 72 h.

37. **Phototherapy:** acts by direct inhibition of cell proliferation and apoptosis of T cells.

Table 4.9. Role of topical corticosteroids in psoriasis

In whom to use?	Which corticosteroid
Lesions on face	Low–medium-potency steroid (cream base)
Lesions on genitals and flexures	Low–medium-potency steroid combined with antifungal (cream base)
Few lesions on trunk/ extremities in patient not tolerating tar/dithranol	Medium-potency steroids (cream base in thin lesions and ointment base in thick lesions)
Lesions on scalp	High-potency steroid (lotion base). Combine with salicylic acid if thick lesions
Lesions on palms and soles	High-potency steroid (ointment base), preferably after soaking area. If lesions very thick, combine with salicylic acid, use very high- or ultra high-potency steroids and/or use under occlusion

lar psoriasis in pregnancy (**impetigo herpetiformis**)³⁸.

Biological response modifiers

- ❖ The biological response modifiers found effective in psoriasis include:
 - Etanercept
 - Alefacept
 - Infliximab
 - Efalizumab
- ❖ In psoriatic arthritis, etanercept has been found effective.

Treatment Strategies

Usually combination therapy is used in psoriasis (Table 4.10). Newer strategies for combining various treatment modalities include rotational and sequential therapy.

Rotational and sequential therapy

- ❖ Used in patients with chronic, extensive disease, which relapses shortly after stopping therapy.

- ❖ Involves rotating from one therapeutic modality to another to:
 - Reduce toxicity/adverse effects.
 - Improve response due to additive and synergistic effects.
- ❖ Therapy may be changed at predetermined intervals or when the disease has reached a certain level of control.

Self-Limiting Papulosquamous Dermatoses

Pityriasis Rosea (PR)

Synopsis

Etiology: Unknown. Self-limiting condition (2–10 weeks).

Morphology: Herald patch, followed by secondary eruption. Typical lesion oval, annular, erythematous, plaque with collarette of scales.

Sites: Trunk, in a fir tree arrangement along lines of cleavage

Differential diagnosis: Guttate psoriasis, secondary syphilis and drug rash.

Treatment: No specific treatment. Symptomatic treatment usually sufficient.

Etiology

Unknown. A virus (HHV-7³⁹ more frequently, HHV-6 less frequently) has often been incriminated, but PR is not contagious.

Epidemiology

- ❖ **Age:** Usually between ages of 10–35 years.
- ❖ **Sex:** No gender predilection.
- ❖ **Season:** Incidence lowest in summer.

Clinical Features

Symptoms

Itching, usually mild.

38. **Impetigo herpetiformis:** term best discarded. Generalized pustular lesions; recur in subsequent pregnancies; typically associated with hypocalcemia. Apart from corticosteroids, cyclosporine may be used in pustular psoriasis in pregnancy.

39. **HHV:** Human Herpes Virus.

Table 4.10. Treatment strategies in psoriasis

	Treatment of choice	Alternatives in resistant cases
Psoriasis vulgaris		
❖ Localized (<10% BSA*)	Topical coal tar + salicylic acid Topical dithranol (short contact)	Topical steroids + salicylic acid
❖ Moderately extensive (10–30% BSA)	NB UVB** PUVA/PUVA sol***	Methotrexate
❖ Extensive (>30% BSA)	Methotrexate	NB UVB** PUVA/PUVA sol*** Cyclosporine A
❖ Facial lesions	Topical low–mid potency steroids	
❖ Palmoplantar psoriasis ⁴⁰	Topical high (even ultra high in resistant cases) potency steroid combined with salicylic acid, even under occlusion.	Methotrexate (small dose) in debilitating cases
Erythrodermic psoriasis	Methotrexate Acitretin + Emollients ⁴¹	Cyclosporine
Guttate psoriasis	Antibiotics + Emollients ⁴¹ PUVA**/PUVA sol***	Coal tar Tacrolimus Mild topical steroids
Flexural psoriasis	Topical low–medium potency steroids combined with antifungal agents	
Pustular psoriasis⁴⁰		
❖ Hands and feet	Topical high-potency steroids + Salicylic acid Topical PUVA/PUVA sol***	Methotrexate (small dose)
❖ Generalized	Methotrexate + Emollients	Acitretin Cyclosporine Oral steroids <u>but only</u> in pregnant women

* BSA: Body Surface Area

**NB UVB: Narrow band UVB

***PUVA/PUVA sol: Psoralens + UVA/Psoralens + sunlight

Evolution (Fig. 4.17)

Morphology

Herald patch (Fig. 4.18A)

- ❖ Is the first lesion of PR and is seen in about 80% of patients.
- ❖ Oval lesions with wrinkled, salmon pink centre and **collarette of scales** at the periphery. Scales are attached just within leading edge and free towards the center (Fig. 4.18A).

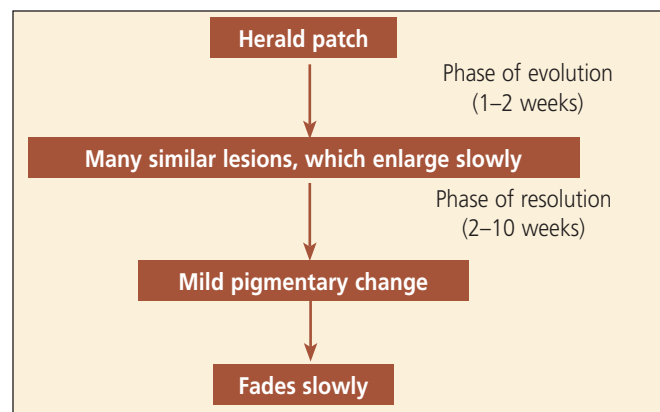


Fig. 4.17. Pityriasis rosea: a self-limiting disease.

40. **Palmoplantar psoriasis:** because of high impact on patients' quality of life, methotrexate frequently used in this localized disease.

41. **Emollients:** Always a good idea to add emollients like petrolatum (Vaseline®) in psoriasis.

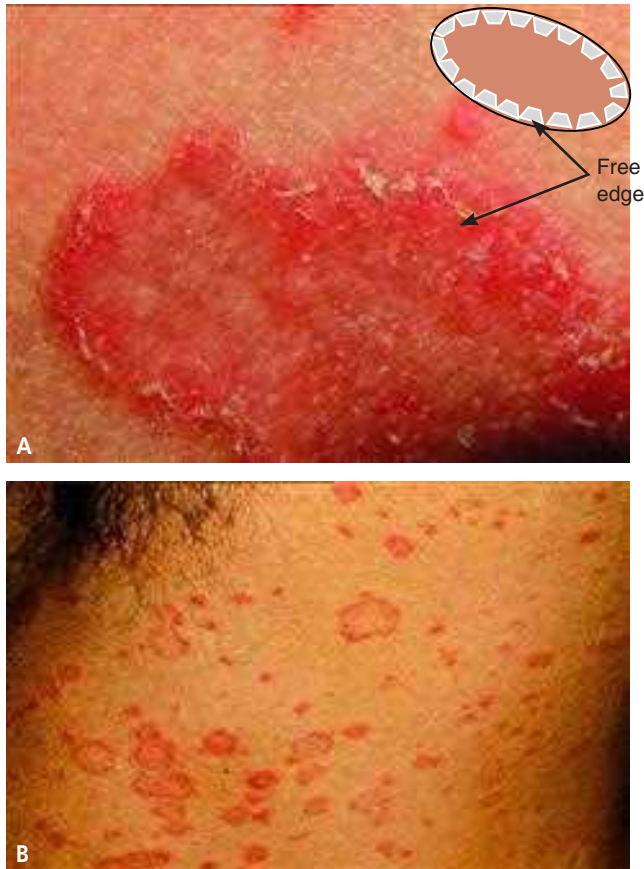

Fig. 4.18. Pityriasis rosea: A: Herald patch. Inset: attachment of scales. B: annular erythematous plaques with collarette of scales, on the neck and trunk.

Secondary lesions (Fig. 4.18B)

- ❖ Begin as scaly papules, which enlarge to form oval annular plaques similar to herald patch
- ❖ Are smaller, less scaly and less erythematous than herald patch.
- ❖ Are arranged characteristically: the long axis of patches runs downwards and outwards from the spine, along the lines of the ribs (**fir tree** or **Christmas tree appearance**, Fig. 4.19).

Sites of predilection

- ❖ Trunk, along lines of cleavage.
- ❖ Sometimes (in 20% of patients) lesions occur predominantly on extremities and neck (**inverse pattern**).

Variants

- ❖ **Inverse PR:** When secondary eruption is predominantly present on the extremities and neck.
- ❖ **Papular PR:** When secondary eruption is predominantly papular.
- ❖ **Bullous PR:** When secondary eruption is predominantly vesicular.

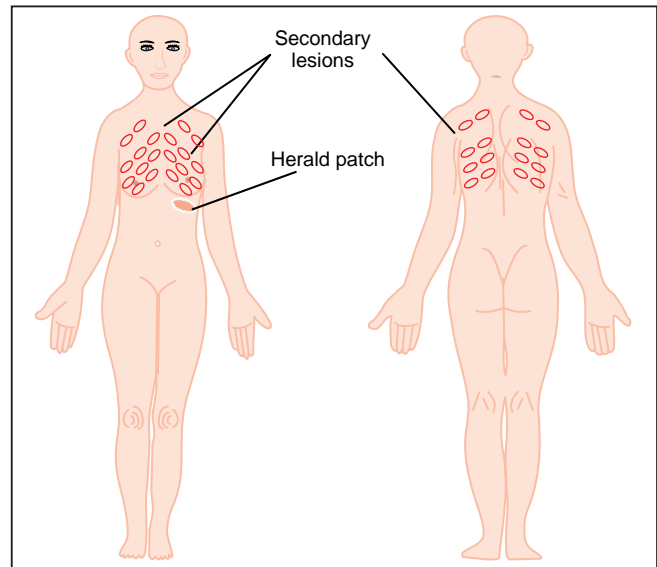


Fig. 4.19. Pityriasis rosea: distribution of lesions on the trunk in a typical fir tree appearance.

Investigations

- ❖ Serological testing to rule out syphilis is advisable in patients diagnosed as PR, as secondary syphilis can closely resemble PR.

Diagnosis

Points for diagnosis

PR is characterized by:

- ❖ Presence of herald patch (in 80% of patients).
- ❖ Eruption consisting of erythematous, oval annular plaques with a peripheral collarette of scales.
- ❖ Typical distribution on the trunk (fir tree appearance).

Differential diagnosis

Herald patch (when alone) should be differentiated from:

a. *Tinea corporis*

<i>Tinea corporis</i>	<i>Herald patch</i>
<i>Itching:</i> severe	Asymptomatic or mildly itchy
<i>Morphology:</i> annular, polycyclic lesion with papulovesicles and scales at edge	Annular, oval lesion with collarette of scales attached just within edge
<i>Location:</i> anywhere on trunk, extremities, flexures	Christmas tree distribution of secondary eruption on trunk
<i>KOH preparation:</i> shows fungal hyphae	Fungal hyphae absent

Fully evolved PR needs to be differentiated from:

b. Secondary syphilis

Secondary syphilis	PR
History of: genital ulcer	Herald patch
Morphology: maculopapular and papulosquamous lesions	Annular lesions with collarette of scales
Associated features: Oral lesions, condyloma lata, palmoplantar lesions, and lymphadenopathy	Oral lesions absent (rare!) Lymphadenopathy infrequent
Serology for syphilis and dark ground microscopy: positive	Negative

c. Guttate psoriasis

Guttate psoriasis	PR
Morphology: papules with silvery scales present uniformly on papules	Annular oval lesions with collarette of scales at periphery.
Course: appear in crops, sometimes after streptococcal sore throat	Herald patch appears first followed by secondary lesions, which appear in crops

d. Pityriasis lichenoides chronica (PLC)

PLC	PR
Morphology: erythematous papules	Erythematous oval, annular lesions. Herald patch seen
Scales: mica like	Collarette of scales
Subsides: with hypopigmentation	Without pigmentation, sometimes hyperpigmentation, or hypopigmentation
Course: chronic, of remissions and relapses	Self-limiting

e. Drug eruptions

Gold, captopril, barbiturates and penicillamine can cause a PR-like rash.

Treatment

The disease is self-limiting, so only symptomatic treatment is required (Table 4.11).

Table 4.11. Treatment options in PR

Symptoms/signs	Treatment
Itchy lesions	Antihistamines + calamine lotion Low–medium potency topical steroid
Very scaly/ erythematous lesions	Coal tar in petrolatum ⁴² Low–medium potency topical steroid
Recalcitrant lesions	Sunlight PUVA/PUVA sol Narrow band UVB

42. **Petrolatum:** available as Vaseline®.

Lichen Planus (LP)

Synopsis

Etiology: Common dermatosis of unknown etiology.

Morphology: Pruritic, **P**olygonal, **P**urple (but violaceous is the term to use!), **P**lane (flat topped), **P**apules (five Ps) with Wickham’s striae on surface.

Sites: Wrists, legs.

Associations: Always look in the mouth (lacey pattern) and examine the scalp (follicular lesions and scarring alopecia) and the nails (thinning of nails, pterygium).

Variants: Number of variants. Common ones being follicular, hypertrophic and linear.

Treatment: Depending on extent and site. *Localized lesions:* Topical steroids and antihistamines. *Extensive lesions:* Dapsone, PUVA, acitretin and systemic steroids. *Erosive oral LP:* Acitretin.

Epidemiology

- ❖ **Age:** 10–40 years.
- ❖ **Sex:** Females > males.

Etiology

- ❖ Unknown: May be a reaction pattern.
- ❖ **Lichenoid eruption:** Closely resembles LP and can be triggered by several agents (Table 4.12).

Table 4.12. Causes of lichenoid eruption

Drugs	Chloroquine Phenothiazines Gold salts
Contact sensitizers	Color photograph developers
Infections	Hepatitis C infection
Graft vs host reaction	

Clinical Features

Onset

Acute or insidious.

Symptoms

- ❖ **Skin lesions:** Very itchy lesions.
- ❖ **Oral lesions:** Oral lesions may be asymptomatic. Or patient may complain of burning sensation especially on eating spicy foods.

Morphology

- ❖ Violaceous, shiny flat topped, polygonal papules of variable size (Fig. 4.20).

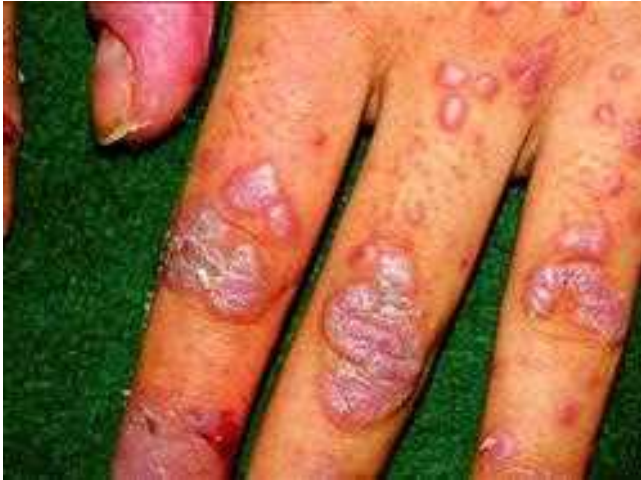

Fig. 4.20. Lichen planus: flat topped, polygonal, violaceous papules, characteristically on flexors of wrist and on shins.

- ❖ When viewed under a magnifying lens, surface of the lesions has white streaks (**Wickham's striae**); these can be enhanced by putting a drop of mineral oil on the lesions.

Variants

Several variants of LP are described (Table 4.13, Figs. 4.21A–E).

Sites (Fig. 4.22)

- ❖ Lesions are most frequently seen on extremities (flexors of wrists and shins) and lower back.
- ❖ Lesions may appear at the sites of trauma (**Koebner's or isomorphic phenomenon**).

Associations

LP may be associated with mucosal (oral and genital) lesions, and nail and scalp involvement.

Mucosal lesions

❖ Oral mucosa:

- Involved in 50% of patients with cutaneous LP and may be sole manifestation of LP in 10% of patients.
- May be asymptomatic. Or patient may complain of intolerance to spicy food.
- Different patterns recognized:
 - White, reticulate lacey pattern (pathognomonic) on the buccal mucosa, (Fig. 4.23) tongue and gingiva.
 - White plaques in the buccal mucosa.
 - Erosive lesions on tongue and buccal mucosa; also erosive gingivitis (Fig. 4.23B).

❖ Genital mucosa

- Involved in 25% of patients.
- Annular lesions on the glans penis (Fig. 4.23B), characteristic.

Table 4.13. Lichen planus: variants and their morphology

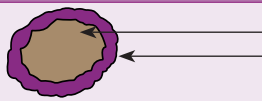
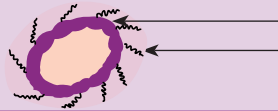




Variant	Change	Morphology	Sites of predilection
Annular (Fig. 4.21A)		Hyperpigmented flat center Violaceous elevated periphery	Face, glans penis
Actinic (Fig. 4.21B)		Annular lesions with thready edge Perilesional hypopigmented halo	Face, dorsal/dorsolateral aspect of upper extremities.
Linear (Fig. 4.21C)		Papules arranged linearly	Extremities
Follicular (Fig. 4.21D)		Perifollicular violaceous papules leading to cicatricial alopecia	Scalp, trunk, medial aspect of extremities
Hypertrophic (Fig. 4.21E)		Central depigmentation Verrucous hyperkeratotic papules and nodules	Shins
Bullous (Rare)		Lesion of LP Bulla	Extremities

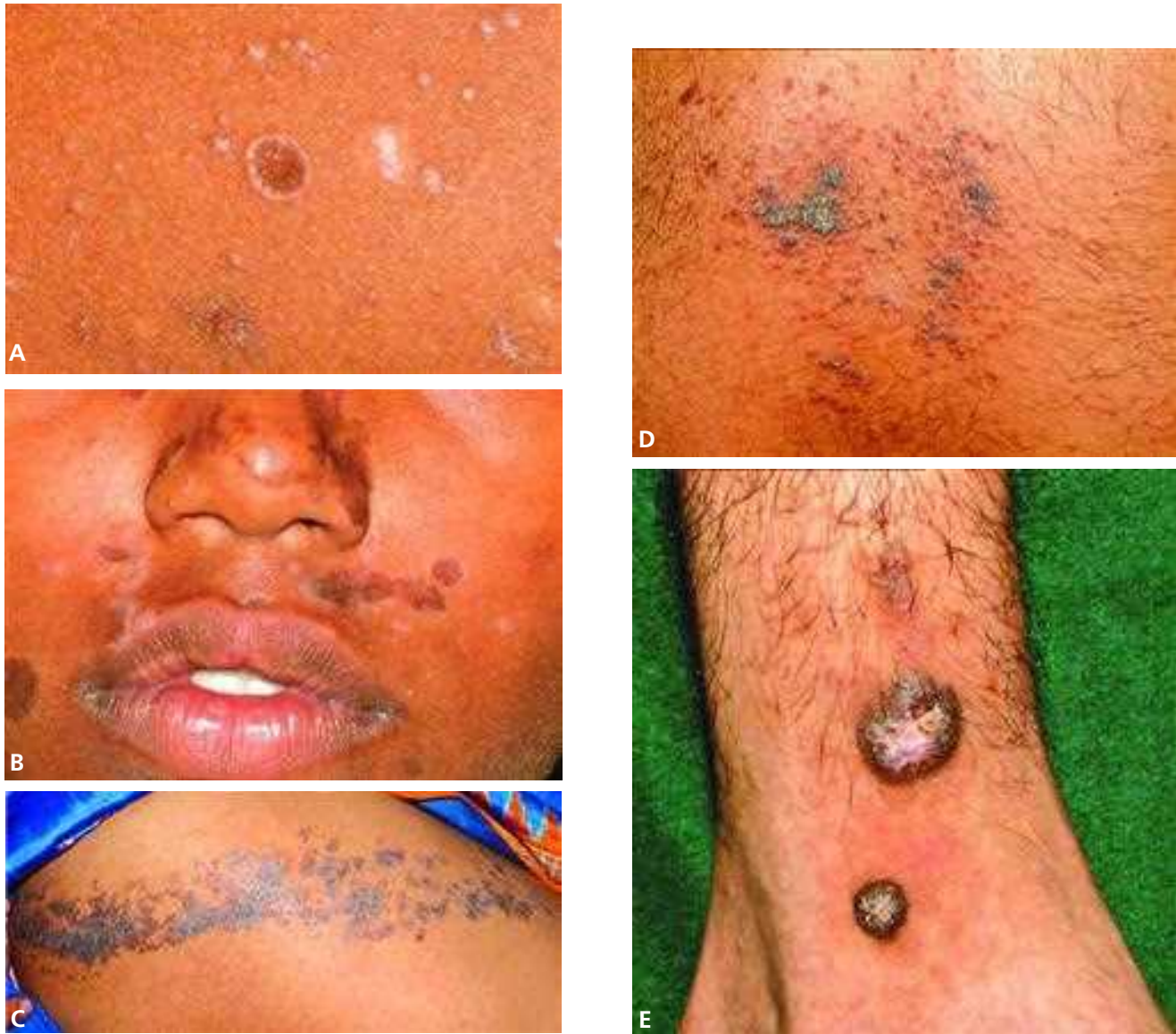

Fig. 4.21. Variants of lichen planus: A: annular lichen planus. B: actinic lichen planus. C: linear lichen planus. D: follicular lichen planus (lichen planopilaris), E: hypertrophic lichen planus.

Nail changes

- ❖ Seen in 15% of patients (less frequently in children).
- ❖ Nail changes (like mucosal lesions), often help to establish diagnosis of LP.
- ❖ Common manifestations of LP of nails are:
 - Thinning and distal splitting of nail plates.
 - Longitudinal ridging.
 - Tenting of nail plate (**pup tent sign**).
 - *Trachyonychia*⁴³: characterized by nail roughness due to excessive longitudinal ridging (sand paper nails).
 - *Pterygium*⁴⁴: **pterygium** formation is diagnostic. The proximal nail fold is prolonged on to the nail bed, splitting and destroying the nail plate (Fig. 4.24).

43. **Trachyonychia**: causes are LP, psoriasis and alopecia areata.

44. **Pterygium**: wing shaped, broad at one end, tapered at the other.

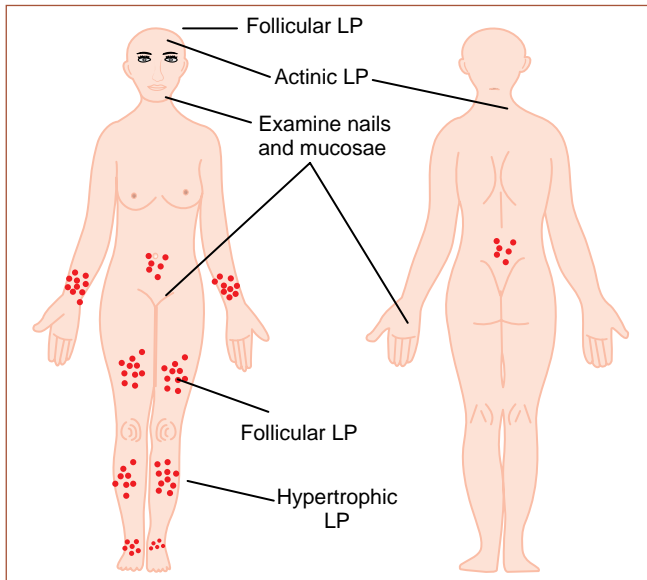


Fig. 4.22. Lichen planus: sites of predilection.

Scalp lesions

Follicular lesions of LP on the scalp subside with scarring and result in cicatricial (scarring) alopecia (Fig. 4.25).

Complications

- ❖ Nail and hair loss in LP is irreversible.
- ❖ Chronic ulcerative LP of oral mucosa can undergo malignant change (but this is decidedly rare!).

Course

- ❖ LP is a chronic self-limiting disease, which may last many months to a couple of years. Over period of time, papules flatten, become darker and leave behind discrete grayish areas of hyperpigmentation. Lesions sometimes recur.
- ❖ Hypertrophic LP is very persistent.

Diagnosis

Points for diagnosis

LP is characterized by:

- ❖ Itchy violaceous, polygonal flat topped papules with characteristic Wickham's striae on the surface (the five p's—**p**ruritic, **p**urple, **p**olygonal, **p**lane topped **p**apules).
- ❖ Typical sites (wrists, ankles, shins, lower back) of involvement.
- ❖ Oral lesions: Lacey reticulate lesions.
- ❖ Nail changes: Thinning of nail plate and pterygium corroborate diagnosis.

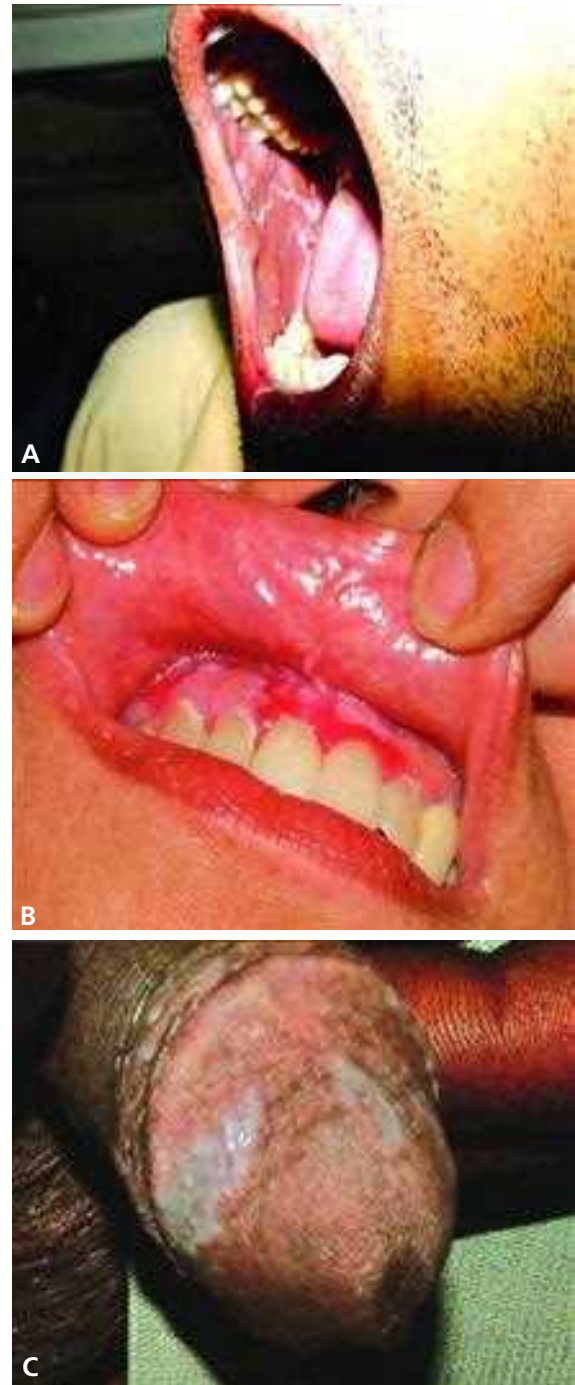


Fig. 4.23. Lichen planus, mucosal lesions: A: lacey pattern on the buccal mucosa. B: erosive gingivitis. C: annular lesions on glans.

- ❖ Diagnosis confirmed histopathologically (Fig. 4.26).

Differential diagnosis

LP needs to be differentiated from:

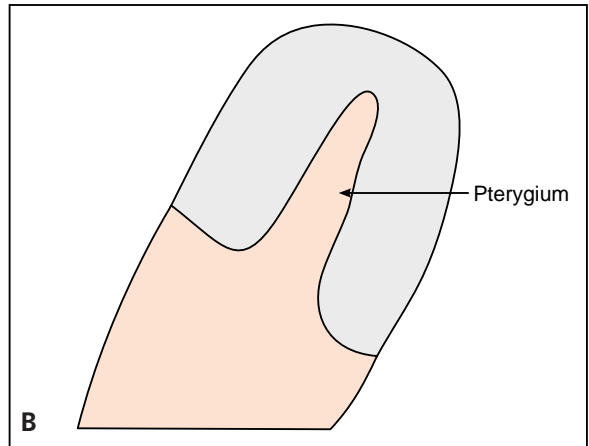
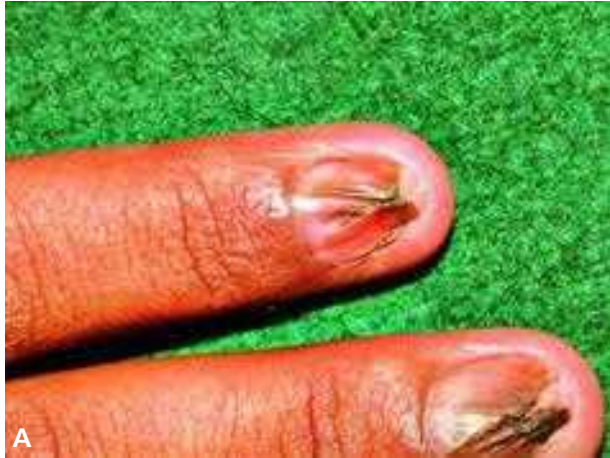

Fig. 4.24. Lichen planus: A: nails show thinning, distal splitting, tenting of nail plate and pterygium formation, B: pterygium forms due to wing-shaped prolongation of proximal nail fold onto the nail bed, splitting and eventually destroying nail plate.

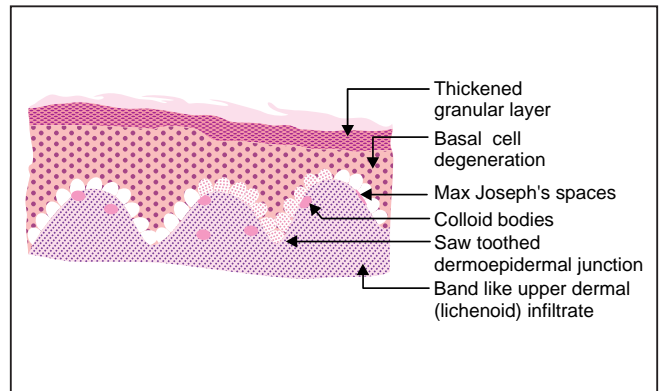
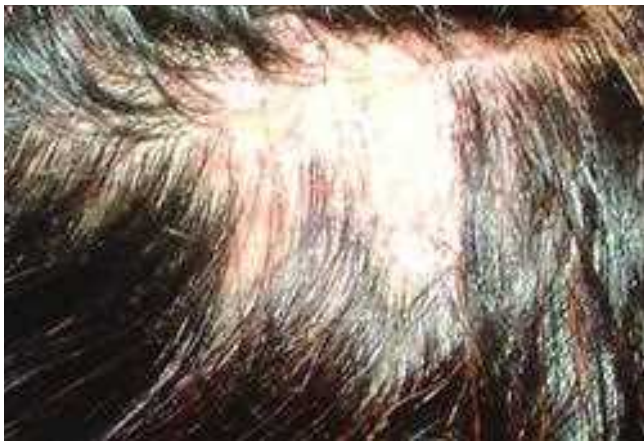

Fig. 4.26. Lichen planus: histopathology.

Fig. 4.25. Lichen planus, scalp lesions: violaceous follicular papules leading to cicatricial alopecia.

a. Lichenoid eruption

Lichenoid eruption	LP
Size: lesions larger	Lesions smaller
Surface: scaling prominent but Wickham's striae absent	Scaling minimal but Wickham's striae present
Sequelae: residual hyperpigmentation common	Residual hyperpigmentation less common
Location: sun-exposed areas, trunk	Flexures and extremities
Mucosae: mucous membrane involvement less common	Common
Alopecia: common	Uncommon

b. Lichen nitidus (LN)

LN (Fig. 4.27)	LP
Symptoms: asymptomatic	Itchy
Morphology: very tiny, multiple, rounded/flat topped, skin-colored shiny papules	Larger, flat topped, polygonal, violaceous papules
Wickham's striae: absent	Present
Grouping: prominent	Not typical
Site: trunk, flexures of upper extremities, dorsal aspects of hands and genitalia	Flexures and extremities
Mucous membrane involvement: uncommon	Common
Pathology: typical, with rete ridges hugging inflammatory infiltrate, which may be granulomatous.	Typical lichenoid band of infiltrate of lymphocytes

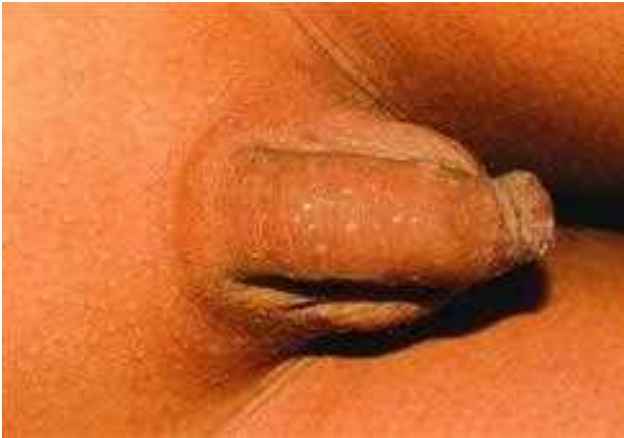

Fig 4.27. Lichen nitidus: very tiny multiple, round, skin-colored shiny papules. Shaft of penis is a characteristic site of involvement.

c. Discoid lupus erythematosus (DLE)

DLE	LP
<i>Symptoms:</i> photosensitivity present	Intensely itchy
<i>Morphology:</i> annular lesions with central scarring and an erythematous halo	Polygonal, violaceous papules
<i>Scaling:</i> adherent and prominent	Minimal
<i>Typical feature:</i> follicular plugging	Wickham's striae
<i>Site:</i> face, ears; scalp, lip	Wrists, shins; examine mucosae, scalp, nails

Treatment

LP is a self-limiting dermatosis but which often disturbs the patient. The treatment depends on extent of involvement and the site and morphology of lesions (Table 4.14).

Chronic Papulosquamous Dermatoses

Pityriasis Lichenoides

Etiology

Unknown, though it may be hypersensitivity to infectious agents.

Clinical Manifestations

Two clinical patterns recognized:

Table 4.14. Treatment guidelines for LP

	Treatment	Comments
Localized LP	Topical steroids (medium potency) + Oral antihistamines	Flattens lesions Reduces itching
Extensive LP	PUVA Oral steroids Acitretin	Try weekly steroids (called oral mini pulse-OMP) in resistant cases
Hypertrophic LP	Potent topical steroids + salicylic acid Antihistamines	Response better, if used underocclusion*. Intralesional steroids
LP of nails, scalp	Oral steroids (can use OMP)	Watch for side effects of steroids!
Erosive mucosal LP	Dapsone + oral steroids (can use OMP) Acitretin	Very effective, especially if lesions ulcerated but requires careful monitoring

* **Occlusion:** Apply topical steroid, place a piece of polythene (cutting a piece of a polythene carry bag to size of lesion) and bandage lesion. Occlusive dressings increase the penetration of the active ingredient due to hydration and maceration.

❖ *Pityriasis lichenoides et varioliformis acuta (PLEVA)*

- Constitutional symptoms like fever and arthralgia frequent.
- Polymorphic eruption⁴⁵ of multiple, erythematous, edematous papules, often surmounted by vesicles. Pustules/hemorrhagic necrosis may develop (Fig. 4.28A).
- Lesions heal with hyperpigmented varioliform⁴⁶ scars.
- Trunk and flexures of extremities.

❖ *Pityriasis lichenoides chronica (PLC)*

- Polymorphic eruption of successive crops of asymptomatic red-brown papules, which are surmounted by a central, adherent mica-like scale (Fig. 4.28B).
- Lesions heal with hypopigmentation.
- Trunk and proximal part of extremities.

Treatment

❖ **PLEVA:**

- Oral steroids/methotrexate in severe cases.
- Oral antibiotics, *e.g.*, doxycycline, tetracycline.
- Phototherapy and photochemotherapy.

45. **Polymorphic eruption:** lesions of different stages present at the same time.

46. **Varioliform:** small pox-like.

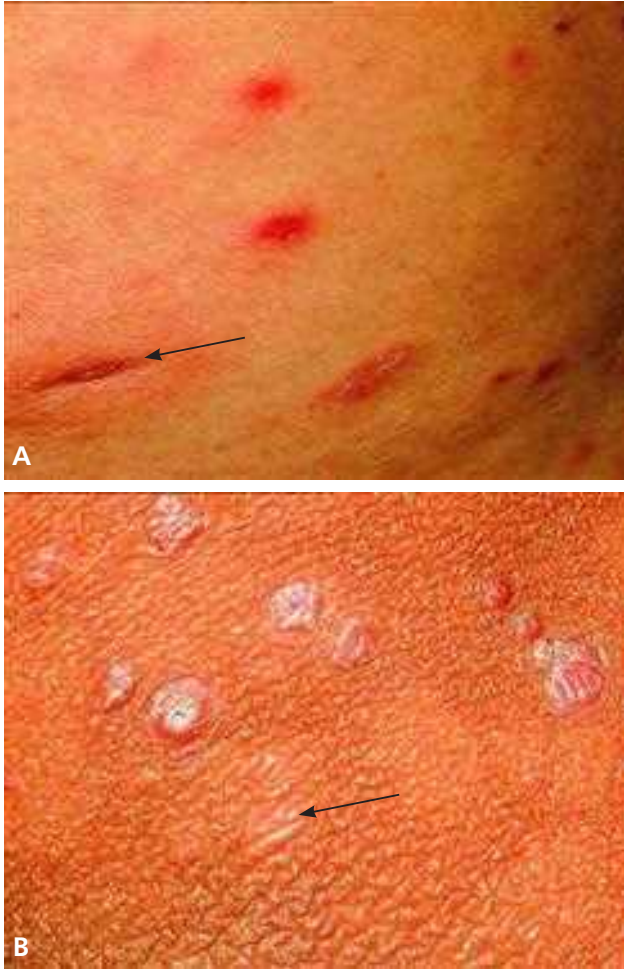


Fig. 4.28. Pityriasis lichenoides. A: pityriasis lichenoides et varioliformis edematous papules surmounted with hemorrhagic crust. Note scarring. B: pityriasis lichenoides chronica: red brown papules surmounted by mica-like scales. Note hypopigmentation.

❖ **PLC:**

- Oral antibiotics.
- Phototherapy and photochemotherapy.

Pityriasis Rubra Pilaris (PRP)

Synopsis

Etiology: Inherited and acquired variants.

Morphology: Scaly, erythematous, follicular papules (so the name, *pityriasis rubra pilaris*); erythroderma can occur, characterized by generalized erythema and scaling with islands of normal skin.

Site: Trunk. Follicular papules on dorsa of digits typical.

Treatment: Acitretin (oral retinoids) in extensive disease useful; can try methotrexate.

Etiology

- ❖ Unknown in most patients.
- ❖ Familial in a few patients.

Epidemiology

- ❖ **Prevalence:** Rare
- ❖ **Age:** two peaks seen:
 - *Juvenile variant:* 5–10 years.
 - *Adult variant:* 40–60 years.

Clinical Features

Classification

- ❖ Classical adult type.
- ❖ Atypical adult type.
- ❖ Classical juvenile type.
- ❖ Circumscribed juvenile type.
- ❖ Atypical juvenile type.
- ❖ HIV associated.

Morphology

- ❖ As the name PRP suggests, characteristic lesions are orange to pink (**rubra**) follicular (**pilaris**) scaly (**pityriasis**) papules (Fig. 4.29A).
- ❖ Papules frequently coalesce to form large plaques. A characteristic feature of plaques is presence of distinct islands of normal skin within them. These islands of normal skin, however may be studded with erythematous follicular scaly papules (Fig. 4.29A).

Sites of predilection

- ❖ **Trunk:** Lesions on the trunk evolve in a cephalo-caudal direction.
- ❖ **Digits:** Typically, follicular lesions are seen on dorsal aspects of digits (feel of **nutmeg grater**).

Associated features

- ❖ Diffuse erythema and scaling of face.
- ❖ Orangish thickening of palms (Fig. 4.29B) and soles (**keratodermic sandals**).
- ❖ **Nail changes:** Distal yellow–brown discoloration and nail plate thickening.

Course

- ❖ **Juvenile type:** Familial, less common. Skin lesions develop during childhood and resolve in 1–2 years.
- ❖ **Adult type:** Commoner. Lesions develop during adulthood and resolve in a couple of years.

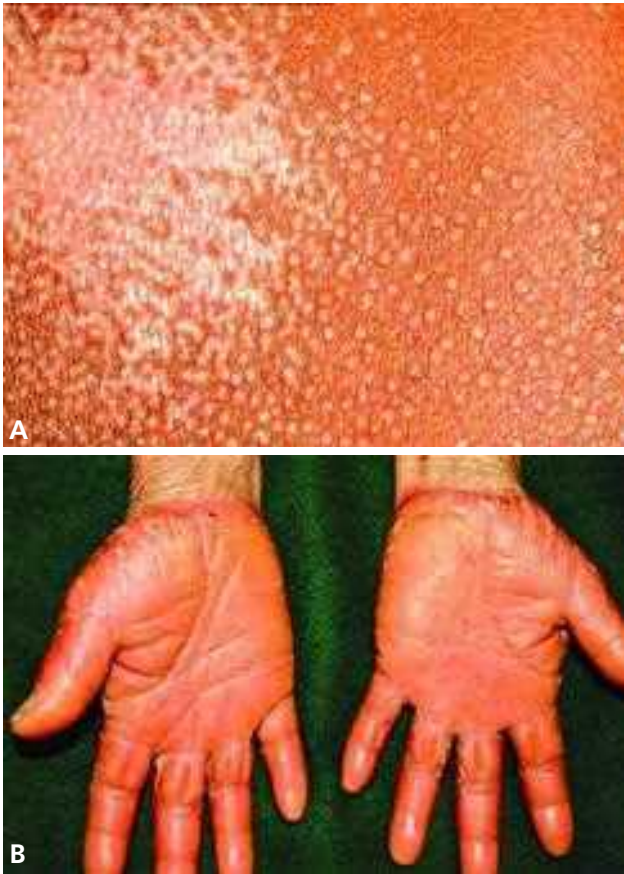

Fig 4.29. A: Pityriasis rubra pilaris: grouped erythematous scaly papules coalescing to form plaques. B: palmo-plantar keratoderma, characteristically orange in color. Plantar involvement called keratodermic sandals.

Complications

Erythroderma (generalized erythema and scaling) can develop. However, small islands of normal skin characteristically remain. These islands of normal skin may have erythematous, plugged, follicular papules.

Diagnosis

Points for diagnosis

PRP is characterized by:

- ❖ Grouped erythematous, scaly, follicular papules; often coalesce to form large plaques.
- ❖ Truncal lesions. And characteristic follicular lesions on dorsal aspect of digits.
- ❖ Orangish palmo-plantar keratoderma.
- ❖ Erythema and scaling of face.

- ❖ Erythroderma common, with islands of normal skin (a clue to diagnosis).

Differential diagnosis

PRP should be differentiated from:

a. Psoriasis

Psoriasis	PRP
Worse in winter	No seasonal variation
<i>Morphology:</i> erythematous scaly plaques; follicular lesions absent except in follicular psoriasis	Follicular scaly papules; may coalesce; follicular keratotic papules on dorsal aspects of digits
<i>Sites:</i> trunk, dorsal aspect of digits. Face relatively spared.	Pressure points, lower back, scalp. Face involved
<i>Palms and soles:</i> typical lesions	Keratoderma orange red
<i>Nails:</i> pitting, thickening discoloration, onycholysis of nails	Nails discolored and thickened

Treatment

Localized lesions

Topical corticosteroids + keratolytics (salicylic acid, urea).

Erythroderma

- ❖ Acitretin (effective, but expensive).
- ❖ Intermittent doses of oral vitamin A (less effective, but inexpensive).
- ❖ Oral methotrexate (small, weekly doses).

Parapsoriasis

Synopsis

A controversial term

Etiology: Heterogeneous group, some benign dermatoses, others premalignant.

Clinical features: Two types recognized. *Small plaque* (which is benign) and *large-plaque* (which is premalignant); both look similar except for size. Asymmetrical, scaly erythematous plaques on covered parts. Suspect premalignant variant, if induration and poikiloderma-tous change.

Treatment: Treat *large plaque* variant aggressively.

Parapsoriasis is a controversial term used for a heterogeneous group of dermatoses. Though some specialists have stopped using this term, others use it as:

- ❖ **Small plaque parapsoriasis:** Which is benign.
- ❖ **Large plaque parapsoriasis:** Which is premalignant⁴⁷.

47. **Premalignant:** also called premycotic as it develops into mycosis fungoides.

Etiology

Unknown.

Epidemiology

- ❖ **Prevalence:** Uncommon.
- ❖ **Age:** Fifth decade.
- ❖ **Gender:** Male preponderance.

Clinical Features

Morphology

Small plaque parapsoriasis

- ❖ Asymmetrical, yellow-erythematous, scaly plaques, which are small (<5 cm) and have digitating margins.
- ❖ Predominantly on covered parts of body (abdomen, buttocks, breasts and flexures).
- ❖ Runs a chronic course, usually responding to treatment and relapsing when treatment is stopped.

Large plaque parapsoriasis

- ❖ Initially asymmetrical, erythematous, scaly plaques (Fig. 4.30), quite similar to lesions of small plaque parapsoriasis except being larger (>5 cm) and more erythematous.
- ❖ Presence of **poikiloderma**⁴⁸ and induration in lesions suggestive of malignant transformation.
- ❖ Predominantly on covered parts of body.

Course

Both variants run a chronic course; over period of time, large plaque variant may develop poikiloderma and induration indicating a malignant change.

Diagnosis

Important to distinguish benign variant from the premalignant variety by:

- ❖ **Repeated biopsies:** Appearance of atypical mononuclear cells in dermal infiltrate and in epidermis is suggestive of a malignant change.
- ❖ **Newer investigative techniques:** Including electron microscopic examination (to detect atypical cells) and DNA probes (to determine monoclonality of T cells) may be helpful.

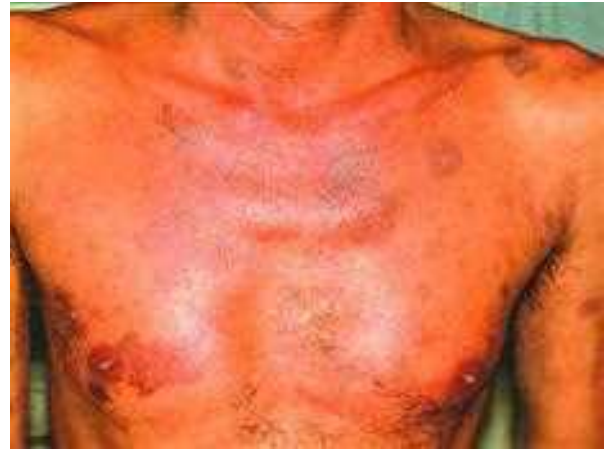

Fig. 4.30. Large plaque parapsoriasis: erythematous, scaly, indurated plaques on the covered parts of body.

Treatment

Small plaque parapsoriasis

Since course not aggressive, treat with:

- ❖ Moderately potent corticosteroids.
- ❖ Phototherapy (narrow band UVB).

Premalignant parapsoriasis

Since course may be aggressive, treat with:

- ❖ Topical nitrogen mustard (an antimitotic drug).
- ❖ Electron beam therapy.

Erythroderma (Exfoliative Dermatitis)

Synopsis

Etiology: *Secondary:* to psoriasis, dermatitis (contact, atopic, seborrheic), drugs, reticuloendothelial neoplasms. *Idiopathic:* in 25%.

Morphology: Extremely itchy. Generalized erythema and scaling.

Associations: Nail changes, lymphadenopathy. Look for signs of underlying disease.

Complications: Thermodysregulation; sepsis; nutritional, fluid and electrolyte imbalance.

Treatment: Treat underlying disease. Prevent complications. Bland applications and antihistamines.

Definition

Erythroderma is a morphological diagnosis characterized by generalized erythema and scaling.

Epidemiology

- ❖ **Prevalence:** Uncommon

48. **Poikiloderma:** triad of atrophy, pigmentation and telangiectasia.

- ❖ **Age:** Most frequently seen in the age group 40–60 years. Ichthyosiform variant seen in children.
- ❖ **Gender:** Male:female ratio of 2:1.

Etiology

Erythroderma occurs as a late stage in the natural history of several cutaneous and systemic disorders (Table 4.15):

- ❖ **Underlying skin diseases:** Erythroderma can be a late manifestation in the clinical course of several skin disease (Table 4.15).
- ❖ **Idiopathic:** In 25% of patients, no underlying cause can be determined.

Clinical Features

- ❖ Extremely itchy.
- ❖ In erythroderma secondary to other skin diseases (*e.g.*, psoriasis), there may be evidence of primary disease historically and on clinical examination.
- ❖ Intense erythema and scaling (Fig. 4.31). The scales may be small or large and their color may vary from white to yellow.
- ❖ Involvement is generalized or almost generalized (>90%).

Table 4.15. Etiology of erythroderma

Common	Less common
❖ Psoriasis (20%)	❖ Pityriasis rubra pilaris
❖ Dermatitis: <i>e.g.</i> , contact dermatitis, airborne contact dermatitis, atopic dermatitis, seborrheic dermatitis (15%)	❖ Cutaneous T cell lymphomas <i>e.g.</i> , Sezary syndrome
❖ Drugs, <i>e.g.</i> , antiepileptics (carbamazepine, lamotrigine) calcium channel blockers, antibiotics (penicillin group) antimalarials, captopril, dapsone (15%),	❖ Ichthyosis <i>e.g.</i> , non bullous ichthyosiform erythroderma, lamellar ichthyosis
❖ Pemphigus foliaceus	
❖ Undetermined* (25%)	

* Patients in whom the cause of erythroderma cannot be identified form the largest group

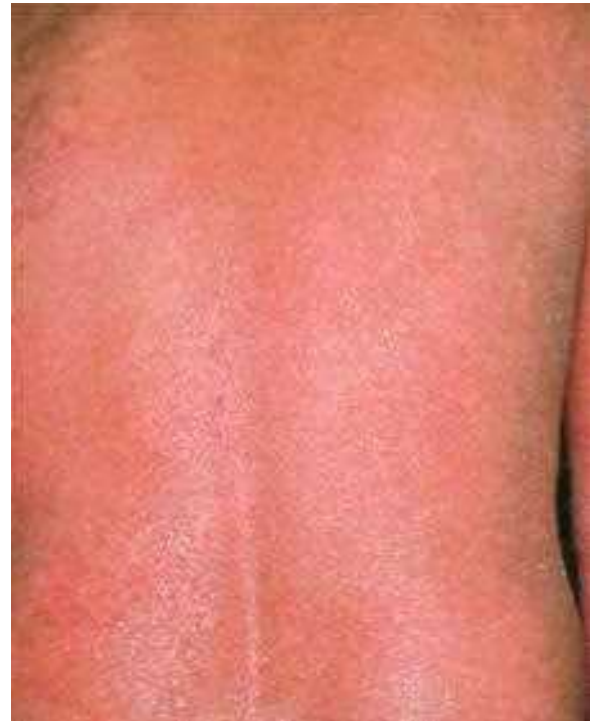

Fig. 4.31. Erythroderma: diffuse scaling and erythema. Note in this patient the erythroderma is secondary to psoriasis.

Associated features

- ❖ Alopecia.
- ❖ Shiny and beveled nails initially⁴⁹. Dystrophic nails and shedding of nails.
- ❖ Palmoplantar involvement with massive hyperkeratosis.
- ❖ Lymphadenopathy⁵⁰ (in 50% of patients). Hepatomegaly and splenomegaly (occasionally).
- ❖ Lesions of underlying disease.

Complications

- ❖ Sepsis.
- ❖ Fluid and electrolyte imbalance.
- ❖ Nutritional imbalance: anemia, hypoproteinaemia (protein is lost as scales).
- ❖ Abnormal temperature control.
- ❖ Hypervolemia (manifesting as pedal edema), high output cardiac failure.

Course

Course and prognosis depends on the underlying disease.

49. **Shiny and bevelled nails:** Due to scratching.

50. **Lymphadenopathy:** can be dermatopathic (meaning benign, secondary to skin condition) or due to a reticuloendothelial malignancies.

Investigations

- ❖ **Skin biopsy:** Is necessary for two reasons:
 - To establish the underlying cause *e.g.*, psoriasis, pityriasis rubra pilaris.
 - To rule out a cutaneous lymphoma, *e.g.*, Sezary syndrome.
- ❖ **Screening for associated complications**
- ❖ **Screening for an underlying neoplasm:** especially in elderly, in those with recalcitrant disease and in those with lymphadenopathy and hepatosplenomegaly.

Treatment

- ❖ **Treat underlying cause.**

- ❖ **Supportive treatment:**

- Prevention of secondary infection.
 - Management of fluid and electrolyte imbalance.
 - Treatment of hypoproteinemia and anemia.
 - Temperature control.
 - Management of other complications.
- ❖ **Symptomatic treatment:** Bland applications and antihistamines for symptomatic relief.
 - ❖ **Corticosteroids:** In patients in whom the underlying cause cannot be determined, a short course of systemic steroid can be tried, provided there are no contraindications.

Bullous Disorders

5

Chapter Outline

Diagnosis of Bullous Disorders[•]

Clinical features

Investigations

Subcorneal Bullous Disorders

Staphylococcal scalded skin syndrome

Subcorneal pustular dermatosis[◦]

Intraepidermal Bullous Disorders

Pemphigus[•]

Hailey Hailey disease[◦]

Dermoepidermal Bullous Disorders

Bullous pemphigoid[•]

Chronic bullous disease of childhood[•]

Dermatitis herpetiformis[•]

Herpes gestationis[◦]

Stevens-Johnson syndrome—
toxic epidermal necrolysis complex[•]

[•]Should know

[◦]Good to know

Introduction

Bullae in skin are formed due to collection of fluid at sites where cohesion of skin is weak (Fig. 5.1). They can be:

❖ *Subcorneal:*

- Bulla is just below the stratum corneum.
- Is seen in bullous impetigo, staphylococcal scalded skin syndrome, miliaria crystallina and subcorneal pustular dermatosis.

❖ *Intraepidermal:*

- Bulla is within epidermis.
- Is seen in eczemas, viral infections, pemphigus group of diseases and epidermolysis bullosa (EB) (some types).

❖ *Dermoepidermal:*

- Bulla is below epidermis.
- Is seen in pemphigoid, chronic bullous disease of childhood, dermatitis herpetiformis, bullous erythema multiforme, toxic epidermal necrolysis and EB (some types).

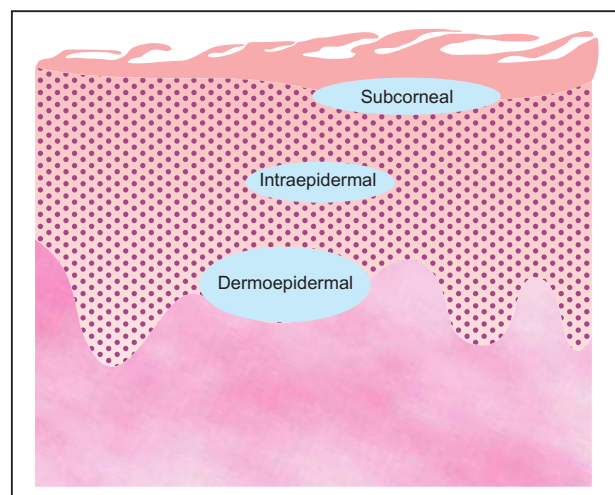


Fig. 5.1. Level of split in skin in cutaneous bullae.

Bullae occur in the skin due to a variety of causes (Table 5.1).

Table 5.1. Classification of bullous disorders based on etiology

Genetic	Epidermolysis bullosa Bullous ichthyosiform erythroderma
Infections	Varicella-zoster Herpes simplex virus
<i>Viral infections</i>	
<i>Bacterial infections</i>	Bullous impetigo
Metabolic	Porphyrias
Immunobullous	Pemphigus Pemphigoid Chronic bullous disease of childhood Dermatitis herpetiformis Epidermolysis bullosa acquisita
Hypersensitivity	Epidermal necrolysis (SJS–TEN complex)

Diagnosis of Bullous Disorders

The diagnosis of bullous disorders is based on:

- ❖ Clinical features (less important).
- ❖ Investigations (more important).

Clinical Features

History

❖ **Duration:**

- *Short duration:* is a clue to diagnosis of bullae due to infections (bullous impetigo, chicken pox, herpes zoster, herpes simplex infection) and hypersensitivity disorders like Stevens–Johnson syndrome–toxic epidermal necrolysis (SJS–TEN) complex.
- *Long duration:* chronicity is a feature of mechanobullous¹ and immunobullous disorders.

❖ **Onset at birth or during infancy:** Is a feature of bullous ichthyosiform erythroderma and EB.

❖ **Triggers:**

- *Trauma:* triggers bullae in EB.
- *Drugs:* triggers bullae in bullous fixed drug eruption and SJS–TEN complex.
- *Contactants:* trigger bullae in allergic contact dermatitis and irritant contact dermatitis.

➤ **Infections:**

- Herpes simplex virus: triggers bullous erythema multiforme.
- Staphylococcal focus of infection: triggers staphylococcal scalded skin syndrome.

Morphology of Lesions

The first step in establishing a diagnosis in a blistering disorder is to determine the level of its split, with the morphology of the bulla being a reasonable clue to this (Table 5.2).

Table 5.2. Characteristics of bullae based on level of split

<i>Subcorneal bulla</i>	<i>Intraepidermal bulla</i>	<i>Dermoepidermal bulla</i>
Located below stratum corneum	In prickle cell layer	At dermoepidermal junction
Flaccid bulla	Flaccid bulla	Tense bulla
Bulla fragile, ruptures easily, so hardly ever seen.	Takes time to rupture	Persistent bulla; often does not rupture but collapses with roof intact.
Contains scanty clear fluid/pus	Clear fluid/pus	Hemorrhagic fluid
Scale crust on rupturing; no erosion	Crusted erosions on rupturing	Hemorrhagic crusts and ulcers on rupturing
Heals with no residue	Heals with pigmentary change	Heals with milia formation and scarring

Distribution of Lesions

The distribution of lesions may give a clue to diagnosis (Table 5.3).

Table 5.3. Distribution of blisters

<i>Disease</i>	<i>Distribution</i>
Epidermolysis bullosa	Sites of trauma
Pemphigus vulgaris	Scalp, face, flexures, trunk
Pemphigus foliaceus²	Seborrheic distribution
Bullous pemphigoid	Trunk, limb, flexures
Chronic bullous disease of childhood	Around body orifices
Dermatitis herpetiformis	Symmetrical over extensors of trunk including buttocks, elbows, knees.

1. **Mechanobullous disorders:** characterized by development of bullae at sites of trivial trauma.
2. **Pemphigus foliaceus:** bullae infrequent; usually scale crusts.

Configuration

- ❖ **Grouping:** Of blisters seen in herpes simplex infection and dermatitis herpetiformis.
- ❖ **Segmental distribution:** Is a constant feature of herpes zoster.

Associated Features

- ❖ **Mucosal lesions:** Seen in some variants of EB, universally in pemphigus vulgaris (PV) and in severe SJS–TEN complex.
- ❖ **Nail changes:** Frequent in some variants of EB.

Investigations

Several investigations are necessary to confirm the etiology of a bullous disorder.

Tzanck Smear

- ❖ Is a quick bedside test.
- ❖ A fresh blister is ruptured, the roof detached and the floor scraped using a scalpel blade. If blister not present, then taken from erosion, after removing the crust. The material so obtained is spread on a glass slide and stained with Giemsa stain.
- ❖ Findings in various bullous diseases are shown in Table 5.4.

Table 5.4. Tzanck smear findings in bullous disorders

Disorders	Findings
Pemphigus	Acantholytic cells
Bullous pemphigoid	Predominantly eosinophils
Chronic bullous disease of childhood	Predominantly neutrophils
Varicella-zoster infection	Multinucleated giant cells
Herpes simplex infection	Multinucleated giant cells
Toxic epidermal necrolysis	Necrotic cells

Biopsy

- ❖ Biopsy of a fresh blister should be taken and ideally should include perilesional skin.
- ❖ Biopsy should be send for:
 - Histopathology.
 - Immunofluorescence.

- Other tests (done in research settings):
 - Electron microscopy: especially useful to type EB.
 - Immunoelectron microscopy.
- ❖ In histopathology, following points need to be noted:
 - Level of split³.
 - Presence and type of infiltrate.
 - Presence of specific cells, *e.g.*, acantholytic cells (in pemphigus) and multinucleated giant cells (in viral bullae).

Immunofluorescence Tests

- ❖ Are very important in diagnosis of bullous disorders (Table 5.5).
- ❖ Two types of immunofluorescence tests are available:

Table 5.5. Immunofluorescence findings in common bullous disorders

	Direct immunofluorescence*	Indirect immunofluorescence**
Pemphigus	<ul style="list-style-type: none"> ❖ IgG ❖ Intercellular deposit in epidermis ❖ Fishnet pattern 	<ul style="list-style-type: none"> ❖ In 100% of patients ❖ IgG, to cell surface of epidermal cells of substrate tissue ❖ Titer correlates with disease activity
Bullous pemphigoid	<ul style="list-style-type: none"> ❖ C3 and IgG ❖ Dermoepidermal junction ❖ Linear 	<ul style="list-style-type: none"> ❖ In 70% of patients ❖ IgG, at basement membrane of substrate tissue ❖ Titer does not correlate with disease activity
Chronic bullous disease of childhood	<ul style="list-style-type: none"> ❖ IgA ❖ Dermoepidermal junction ❖ Linear 	Low titer of IgA
Dermatitis herpetiformis	<ul style="list-style-type: none"> ❖ IgA ❖ Dermal papillary tips ❖ Granular 	Immune complexes in less than 50%
Epidermolysis bullosa acquisita	<ul style="list-style-type: none"> ❖ IgG and C3 ❖ Dermoepidermal junction ❖ Linear 	IgG in 50% patients

* Direct immunofluorescence detects antibodies deposited in skin.

** Indirect immunofluorescence detects circulating antibodies.

3. **Level of split:** a healing dermoepidermal bullae may appear intraepidermal, so need of biopsying a fresh lesion.

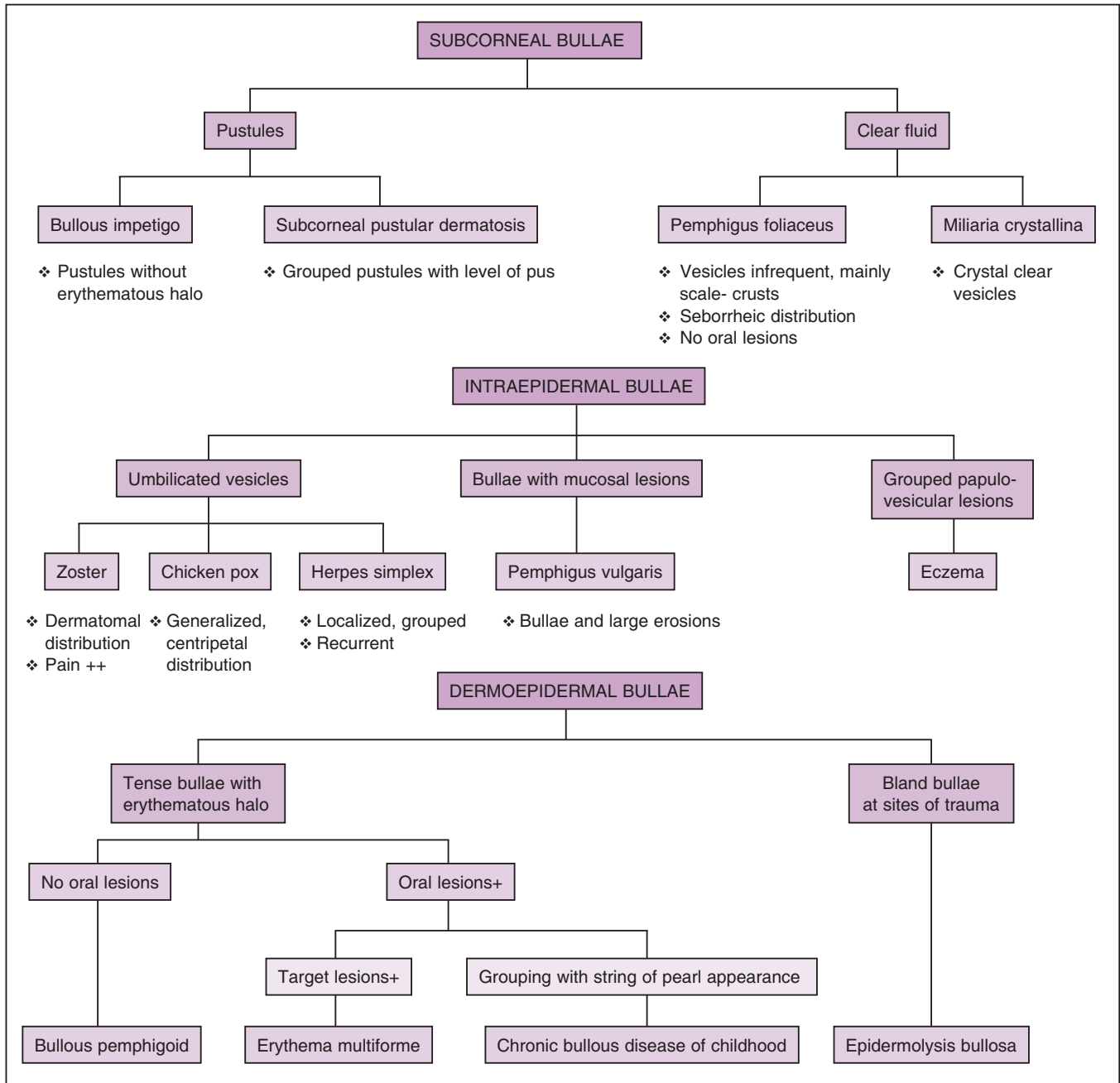


Fig. 5.2. Principles of diagnosing bullous disorders.

- *Direct immunofluorescence (DIF)*: done on the skin of patient to detect antibodies deposited in skin.
- *Indirect immunofluorescence (IIF)*: done on serum of patient to detect circulating antibodies using:
 - Tissue substrates.
 - ELISA.
- ❖ The following points need to be noted:
 - *Type of immunoreactants deposited*: whether IgG, IgM, IgA, C3, etc.
 - *Location of deposit*: whether intraepidermal or at dermoepidermal junction.
 - *Pattern of deposit*: whether linear, granular, in a fishnet pattern, etc.

Subcorneal Bullous Disorders (Fig. 5.2)

Staphylococcal Scalded Skin Syndrome

- ❖ *Staph. aureus*, present in either a distant cutaneous focus (infected wound, furuncle) or in an extracutaneous focus (ear, throat, conjunctiva), releases an exfoliative toxin that results in peeling of skin.
- ❖ Seen in infants.
- ❖ Begins as diffuse, painful erythema, with a wrinkled appearance. Followed by peeling of skin in sheets (Fig. 5.3).

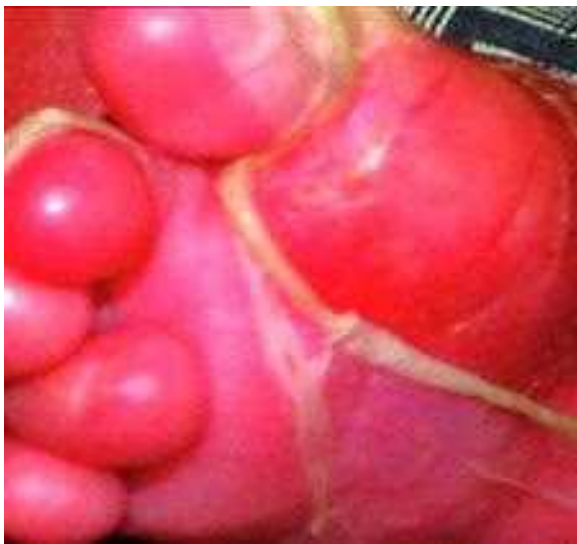

Fig. 5.3. Staphylococcal scalded skin syndrome: peeling of skin in sheets leaving an erythematous surface.

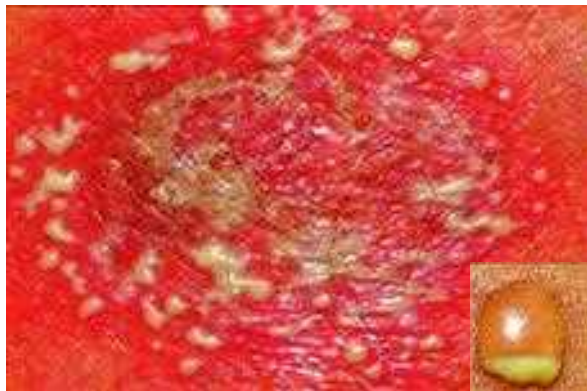

Fig. 5.4. Subcorneal pustular dermatosis: pustules present in groups and may coalesce to form annular lesions. Inset: level of pus in a pustule.

- ❖ Generalized involvement, wrinkling accentuated in flexures.
- ❖ Treat aggressively with antistaphylococcal antibiotics (initially parenteral).

Subcorneal Pustular Dermatitis

- ❖ Unknown cause.
- ❖ Pustules appear in crops; each shows a level of pus (Fig. 5.4). Present in groups that coalesce to form annular/serpiginous lesions.
- ❖ Major flexures.
- ❖ Dapsone treatment of choice.

Intraepidermal Bullous Disorders

Pemphigus

Synopsis

Etiology: Autoimmune disease, characterized by acantholysis, induced by deposition of IgG autoantibodies in an intercellular area of epidermis.

Clinical features: Several variants; commonest is *pemphigus vulgaris*: Flaccid bullae that rapidly rupture to form painful erosions that heal slowly. Oral erosions universally present. Less common, *P. foliaceus*: Bullae superficial, rupture rapidly, so only scale crust seen; in seborrheic distribution. No oral lesions.

Others: *P. erythematosus*, *P. vegetans*.

Investigations: Diagnosis based on Tzanck smear (acantholytic cells), histopathology (intraepidermal bulla with acantholytic cells), immunopathology (intercellular fishnet pattern IgG deposit in epidermis on DIF; circulating IgG antibodies on IIF).

Differential diagnosis: Differentiate variants. And pemphigus vulgaris from bullous pemphigoid.

Treatment: Aggressive treatment. Supportive care is very important. Steroids systemically (daily doses or as monthly bolus) along with immunosuppressive adjuvants (azathioprine, methotrexate, or cyclophosphamide).

Pemphigus is an intraepidermal bullous disorder, which is associated with substantial mortality and morbidity and characterized clinically by presence of cutaneous and mucosal blisters and histologically by **acantholysis**⁴, which occurs due to the deposition of intercellular autoantibodies.

Etiology

- ❖ **Idiopathic autoimmune phenomenon:** Pemphigus is an autoimmune disorder

4. **Acantholysis:** separation of viable epidermal cells from each other.

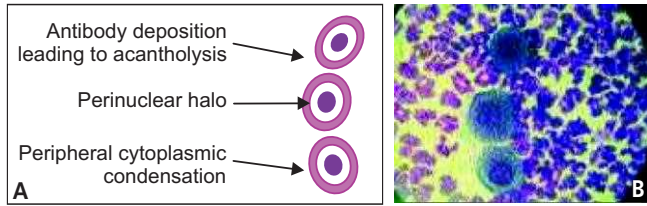


Fig. 5.5. Acantholytic cells: A: acantholytic cells (rounded cells with perinuclear halo) formed by deposition of antibodies to desmogleins. B: acantholytic cells in Tzanck smear.

characterized by the presence of IgG autoantibodies against **desmogleins (Dsg)**⁵ (present in desmosomes), which are involved in keratinocyte–keratinocyte adhesion. Antibodies are deposited in the intercellular area resulting in separation of keratinocytes from each other (Figs. 5.5A and B).

- ❖ **Neoplasia-induced autoimmune phenomenon:** Thymoma and lymphoma.
- ❖ **Drug-induced autoimmune phenomenon:** Penicillamine, rifampicin and captopril⁶.

Classification

Pemphigus is classified (based on level of split, clinical features and serological profile) into:

- ❖ **Pemphigus vulgaris:** Where split is suprabasal.
- ❖ **Pemphigus vegetans:** Where split is suprabasal.
- ❖ **Pemphigus foliaceus:** Where split is either in granular layer or just below the horny layer.
- ❖ **Pemphigus erythematosus:** Where split is either in granular layer or just below the stratum corneum.

Epidemiology

- ❖ **Prevalence:** Rare in the West, but commonest cause of autoimmune blistering in India.
- ❖ **Age:** Disease of middle age, but may occur in children.
- ❖ **Sex:** No gender predilection.

Clinical Features

Pemphigus vulgaris

Characterized by cutaneous and mucosal blisters.

Skin lesions

- ❖ Flaccid bullae develop on normal skin (Fig. 5.6A) and rupture to form painful erosions,

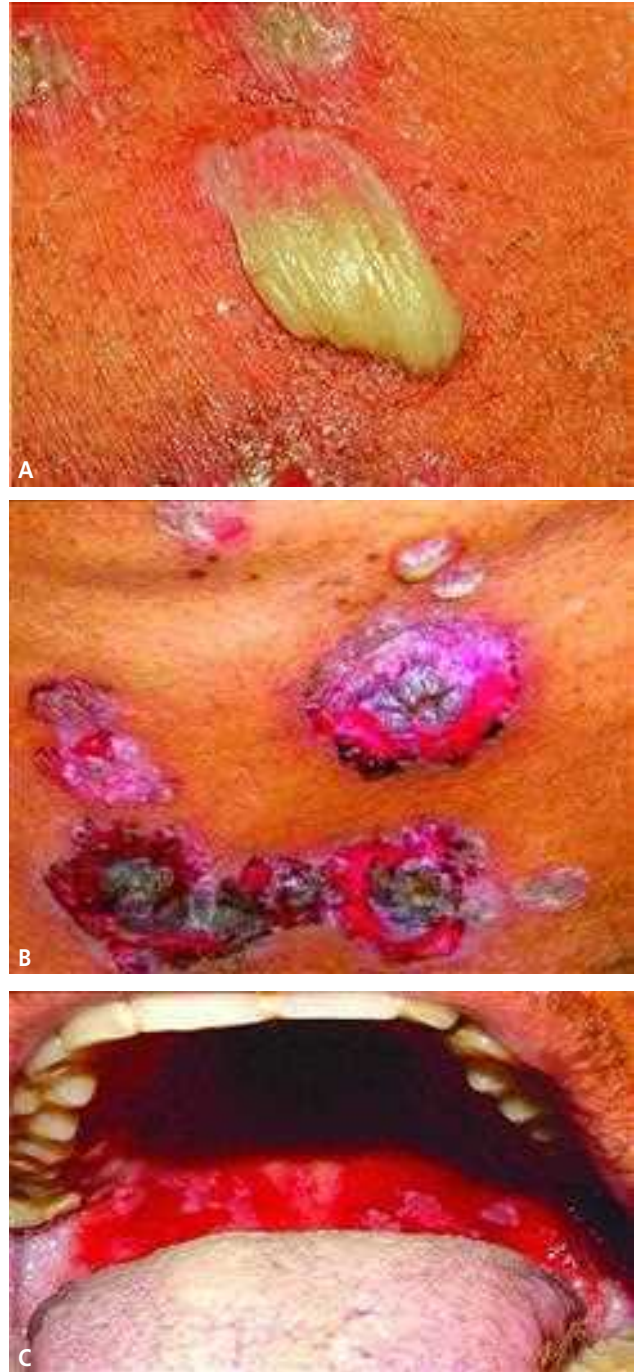

Fig. 5.6. Pemphigus vulgaris A: flaccid blisters on normal skin. B: superficial blisters and erosions which take long to heal. C: painful oral erosions with ragged edge.

5. **Desmogleins:** there are two desmogleins important in pemphigus. Antibodies to Dsg 3 and 1 are pathogenic in pemphigus vulgaris while antibodies to Dsg 1 are pathogenic in pemphigus foliaceus.

6. **Captopril:** an antihypertensive.

which have a tendency to spread and take very long to re-epithelialize (Fig. 5.6B).

- ❖ Application of tangential pressure on normal skin (usually in pretibial area) results in formation of new bulla (**Nikolsky sign**). Or if applied to pre-existing bulla results in the spread of bulla (**bullae spread sign**).
- ❖ Lesions predominantly present on scalp, face, flexures (axillae, groins) and trunk (Fig. 5.7). Periungual lesions frequent.

Mucosal lesions

- ❖ In 50% of patients, disease begins in oral mucosa. Eventual mucosal involvement universal.
- ❖ Oral mucosa most frequently involved (Fig. 5.6C).
- ❖ **Manifestations:** Painful erosions which extend peripherally with shedding of mucosa, giving a ragged appearance.

Complications

- ❖ **Secondary infection:** Erosions frequently secondarily infected (with bacteria in skin and candida in mucosa). Sepsis frequent due to large areas of denudation and the immune suppression due to treatment.

❖ **Water and electrolyte imbalance:** Extensive lesions associated with water and electrolyte imbalance.

❖ **Complications of treatment:** Of steroid therapy and immunosuppressive drugs.

Pemphigus foliaceus

- ❖ Transient superficial bullae⁷, which rupture rapidly to form extensive areas of scaling and crusting (Fig. 5.8).
- ❖ Removal of scale-crust does not reveal an erosion but only a minimally moist skin.
- ❖ Initial seborrheic distribution (face, trunk), later becomes generalized to resemble erythroderma.
- ❖ Mucosal lesions infrequent (rare!).

Pemphigus vegetans

- ❖ Variant of PV (so bulla is suprabasal).
- ❖ Characterized by presence of heaped up, (Fig. 5.9) vegetating lesions which extend centrifugally.
- ❖ Groins, axillae, angles of mouth.
- ❖ Mucosal lesions may be present.

Pemphigus erythematosus

- ❖ Less severe variant of pemphigus foliaceus.

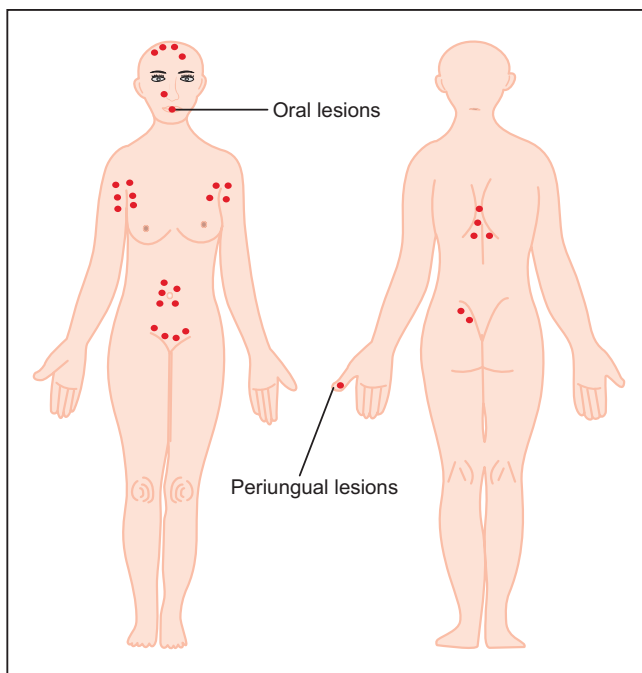


Fig. 5.7. Pemphigus vulgaris: sites of predilection.

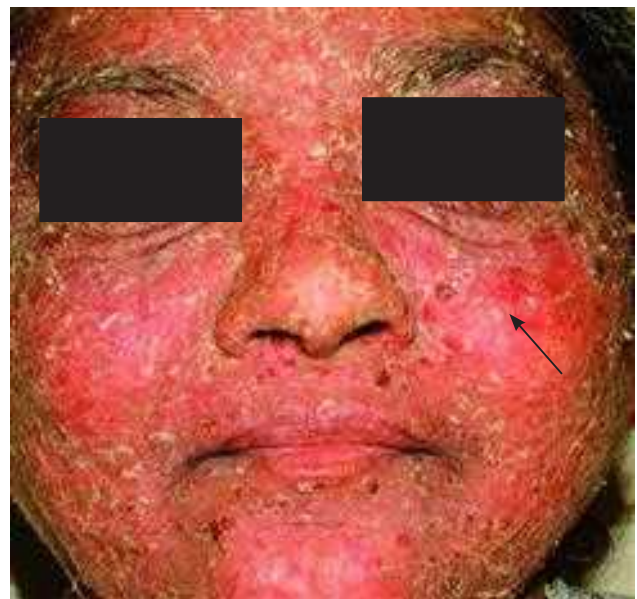

Fig. 5.8. Pemphigus foliaceus: extensive areas of scaling and crusting and no blisters. Note removal of scale-crust reveals a minimally moist area.

7. **Bullae:** usually not seen.

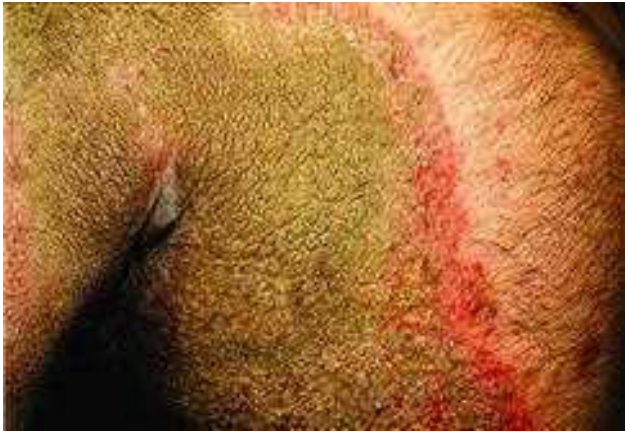

Fig. 5.9. Pemphigus vegetans: heaped up vegetating plaques in flexures.

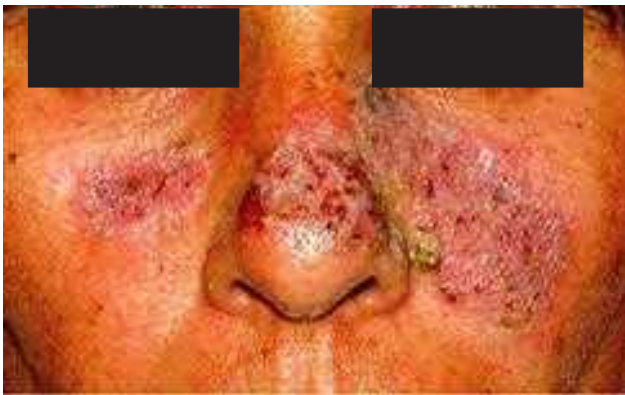

Fig. 5.10. Pemphigus erythematosus: dry hyperkeratotic scaly plaques on the malar region.

- ❖ Characterized by dry, hyperkeratotic, scaly lesions.
- ❖ Face, especially malar region (Fig. 5.10).

Pemphigus variants

Paraneoplastic pemphigus

- ❖ Associated internal malignancies, *e.g.*, thymoma, lymphoma.
- ❖ Polymorphic skin lesions—polycyclic lesions, erythema multiforme-like (Fig. 5.11) or lichen planus-like lesions.
- ❖ Painful indolent mucosal (especially oral) lesions.
- ❖ Improvement on removal of tumor.

Drug-induced pemphigus

- ❖ Penicillamine, rifampicin and captopril.
- ❖ PF or PV like picture.
- ❖ Improvement on withdrawal of incriminating drug.

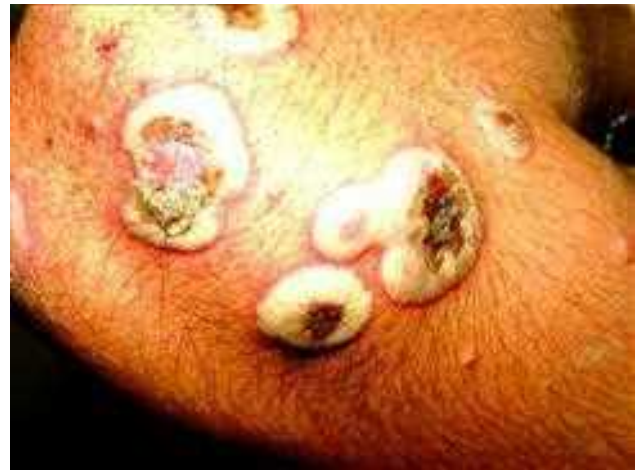

Fig. 5.11. Paraneoplastic pemphigus: polycyclic lesions. Patient also had recalcitrant oral lesions.

Brazilian pemphigus

- ❖ Also called fogo selvagem.
- ❖ Speculated that caused by an infectious agent.
- ❖ Variant of PF (clinically, histologically and immunologically).

Investigations

A clinical diagnosis of pemphigus needs to be confirmed by laboratory tests.

Tzanck smear

- ❖ A bedside test.
- ❖ Made either from floor of bulla (after deroofing). Or erosion (after removing crust). Or mucosal (usually oral) erosion.
- ❖ Shows acantholytic cells (Fig. 5.5, P. 72).

Biopsy

Biopsy for histopathology is taken from the edge of the bulla while for immunopathology is taken from perilesional skin.

- ❖ **Histopathology:** The bulla in pemphigus has the following characteristics:

- Is *intraepidermal*, the split being suprabasal in PV and in the granular layer or below stratum corneum (subcorneal) in pemphigus foliaceus.
- Presence of *acantholytic cells* (Figs. 5.12A). These cells (which are present both in the blister cavity and at the edge of the blister) are rounded keratinocytes with the cytoplasm condensed in the periphery, resulting in a perinuclear halo.

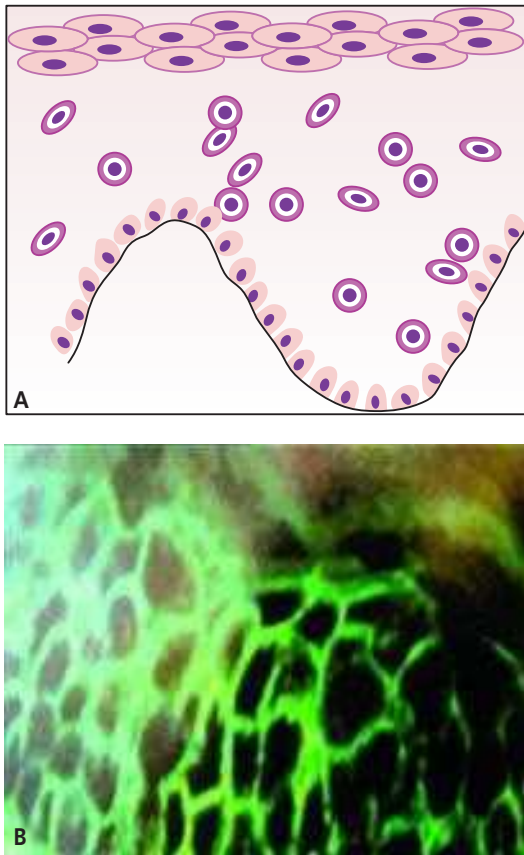


Fig. 5.12. Pemphigus: A: histopathology showing an intraepidermal bulla with acantholysis. B: immunofluorescence in intercellular spaces of the epidermis giving a fishnet appearance.

- ❖ **Direct immunofluorescence (DIF):** Shows intercellular deposits of IgG, giving a fishnet appearance (Fig. 5.12B), usually throughout epidermis, in all variants of pemphigus.

Serodiagnosis

- ❖ Circulating IgG antibodies present in all patients.
- ❖ Titers correlate with disease activity.
- ❖ Two methods of detecting circulating antibodies:
 - **IIF:** in which antibodies in patient's serum attach to intercellular spaces of substrate.
 - **ELISA:** in which antibodies to Dsg 3 and 1 are detected in PV and to only Dsg 1 in PF.

Diagnosis

Points for diagnosis

Diagnosis of pemphigus is based on:

- ❖ It being a chronic vesiculobullous disease.
- ❖ Presence of flaccid bullae which rupture to form nonhealing erosions; bullae may be transient or absent in PF.
- ❖ Positive Nikolsky's and bulla spread sign.
- ❖ Painful oral erosions (in PV).
- ❖ Tzanck smear, histological and immunopathological confirmation.

Differential diagnosis

PV needs to be distinguished from:

a. Bullous pemphigoid (BP)

BP	PV
Age: older age	Younger age
Morphology: tense bullae with hemorrhagic contents; rupture less readily, but roof just settles down when bulla collapses.	Flaccid bullae with clear fluid; rupture readily to leave painful erosions which continue to spread
Surrounding skin: bullae develop on erythematous, edematous (urticarial) skin. Or normal skin	On normal skin
Oral lesions: less frequent; as bullae or erosions	Universal; usually erosions
Histopathology: dermoepidermal bulla	Intra-epidermal bulla with acantholytic cells
DIF: linear band of IgG and C3 at dermoepidermal junction	IgG deposit in intercellular space in epidermis in a fishnet pattern
IIF: circulating IgG against basement membrane in 70% of patients;	Circulating IgG against intercellular substance; titers correlate with disease activity

b. Pemphigus foliaceus (PF)

PF	PV
Morphology: blisters may not be visible; extensive lesions with scale-crusts	Flaccid bullae which rupture to form superficial erosions
Distribution: initially seborrheic distribution; becomes generalized	Lesions on scalp, face, axillae; can be extensive
Oral lesions: infrequent	Universal
Course: less morbidity and mortality	Greater morbidity and mortality
Histopath: subcorneal or granular layer split with acantholysis	Suprabasal split with acantholysis
DIF: IgG deposit in the intercellular spaces of epidermis	Similar
Treatment: low-dose steroids; often recalcitrant	Treatment with high-dose steroids and adjuvants

Treatment

Patients of pemphigus (especially extensive PV) are seriously ill and need not only specific treatment but supportive care also.

Supportive treatment

- ❖ Barrier nursing, if required.
- ❖ Local hygiene of mucosal and skin lesions. Prophylactic as well as therapeutic use of antibiotics (for cutaneous infection and septicemia) and anticandidal agents both topical and systemic (for mucosal lesions).
- ❖ Maintenance of water and electrolyte balance.
- ❖ Maintenance of body temperature.

Specific treatment

Specific treatment consists of judicious and monitored use of steroids and immunosuppressive drugs since pemphigus is an autoimmune disorder.

Corticosteroids

Two regimens are commonly used:

- ❖ **Daily dose:**
 - Of 1–2 mg/kg body weight of prednisolone equivalent is used to suppress disease activity. Steroids are tapered when the disease is controlled.
 - Is probably associated with several adverse events.
- ❖ **Monthly steroid therapy:**
 - Of 1–2 mg/kg of oral betamethasone or intravenous dexamethasone is given, usually for three consecutive days every month.
 - May induce remissions, with less side effects.

Immunosuppressive therapy

- ❖ **Indications:** Are usually used:
 - As steroid-sparing agents, especially in patients who have severe adverse effects of steroid therapy.
 - In patients with recalcitrant disease.
- ❖ **Drug regimens:**
 - *Azathioprine:* initially 2–3 mg/kg of body weight till clearing of disease; maintain on 1 mg/kg.

- *Methotrexate:* as 15–25 mg weekly.
- *Cyclophosphamide:* as daily oral dose (50–200 mg). Or as monthly intravenous bolus dose (500–1,000 mg). Or as both.

Other modalities of therapy

- ❖ Mycophenolate mofetil.
- ❖ Biologic response modifier.
- ❖ High-dose intravenous IgG.
- ❖ Plasmapheresis.
- ❖ Extracorporeal photochemotherapy.

Familial Benign Pemphigus

- ❖ **Synonym:** Hailey Hailey disease.
- ❖ **Etiology:** Autosomal dominant inheritance.
- ❖ **Age:** Presents in third–fourth decade.
- ❖ **Morphology:** Presents as flaccid vesicles, crusted erosions and circinate plaques on erythematous base (Fig. 5.13). May become hypertrophic and malodorous.
- ❖ **Distribution:** Major flexures (groins, perineum, axillae and sides of neck).
- ❖ **Treatment:** Includes:
 - Reduction of friction; keeping area dry.
 - Combination of potent steroids with antibiotics, mainstay of treatment.

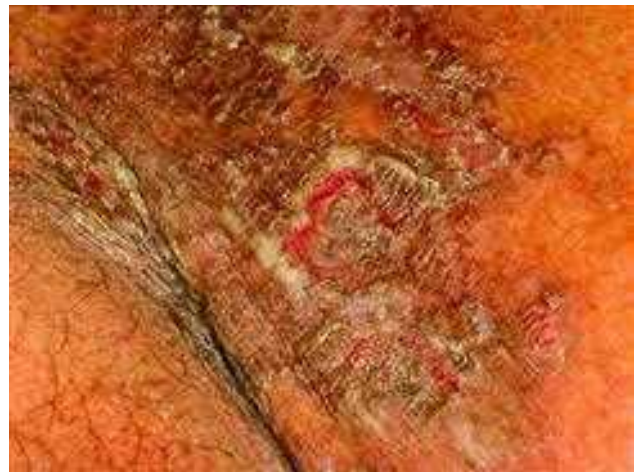

Fig. 5.13. Familial benign pemphigus: crusted erosions and circinate plaques on erythematous base, usually in main flexures.

Dermoepidermal Bullous Disorders

Bullous Pemphigoid (BP)

Synopsis

Etiology: Autoimmune disorder, characterized by deposition of IgG and C3 at dermoepidermal junction.

Clinical features: Elderly. Itchy, tense hemorrhagic blisters on normal or erythematous or urticarial skin.

Mucosal lesions: Infrequent.

Investigations: Diagnosis based on histopathology (dermoepidermal bulla), DIF (deposition of IgG and C3 at dermoepidermal junction) and IIF (circulating IgG in 70%).

Treatment: *Localized disease:* topical steroids, dapsone. Or combination of tetracyclines and niacinamide. *Generalized disease:* systemic steroids and immunosuppressive adjuvants like azathioprine.

Etiology

- ❖ Pathogenic IgG antibodies and C3 attach to BP antigens⁸, which are components of hemidesmosomes at the dermoepidermal junction.
- ❖ This initiates an inflammatory cascade causing bullae.

Epidemiology

- ❖ **Age:** 60–80 years.
- ❖ **Gender:** Equal incidence in males and females.

Clinical Features

Morphology

- ❖ Itchy (sometimes severely so!).
- ❖ Large tense bullae arise either on normal skin or on large urticarial plaques (Figs. 5.14A and B). The bullae may be hemorrhagic (because they are dermoepidermal).
- ❖ Rupture less readily than bullae of PV—often instead of rupturing, the roof of bulla just settles down on the floor as contents are reabsorbed (Fig. 5.14C).
- ❖ Bulla spread sign and Nikolsky's sign are usually negative.
- ❖ Lesions heal with **milia**⁹ formation.

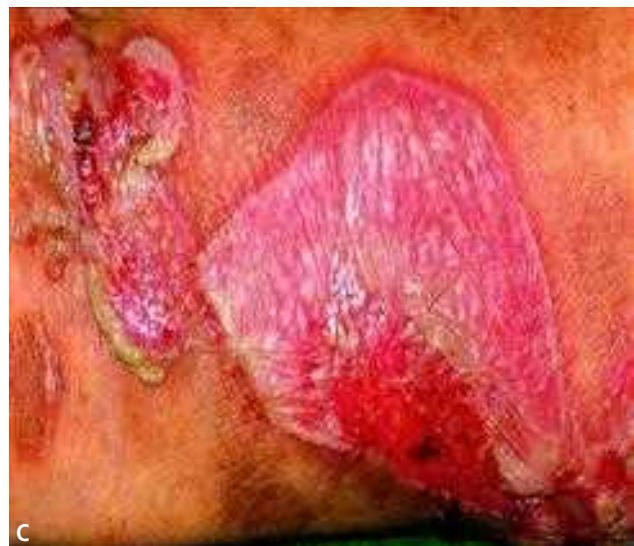
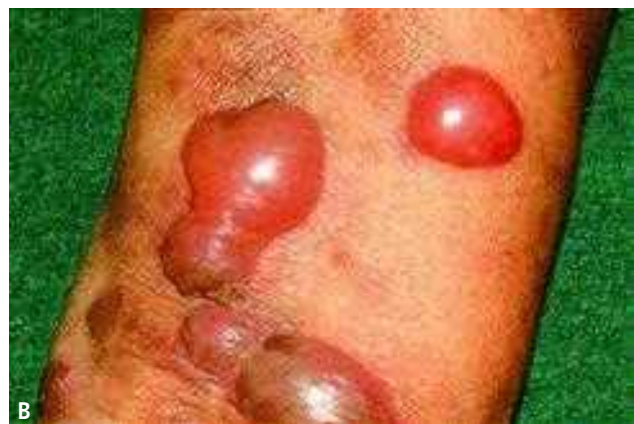
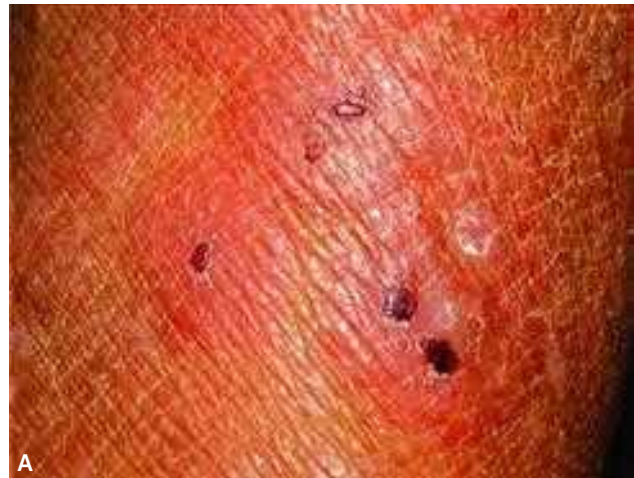Fig. 5.14. Bullous pemphigoid: A: urticarial lesions. B: large hemorrhagic blisters some on normal skin. C: roof of bulla settling without rupturing.

8. **BP antigens:** Two BP antigens identified—BP 180 and 230.

9. **Milia:** intraepidermal cysts, appearing as small pearly papules. Milia commonly develop when dermoepidermal bullae heal.

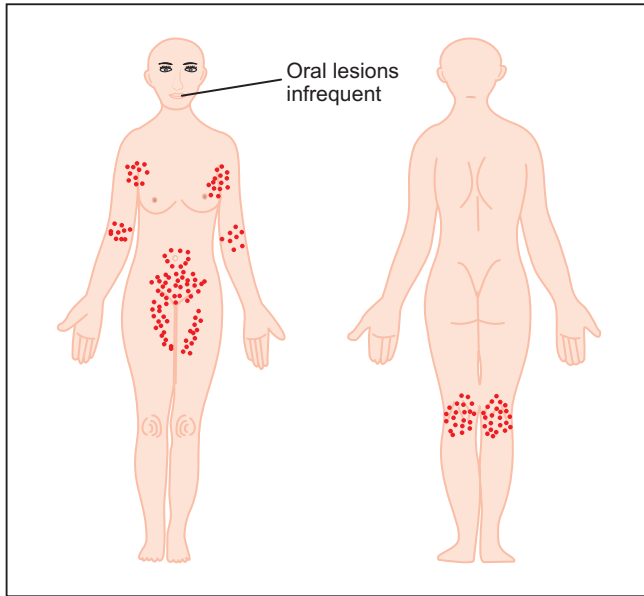


Fig. 5.15. Bullous pemphigoid: sites of predilection.

Mucosal lesions

- ❖ Infrequent.
- ❖ If present, seen as intact bullae or as erosions.

Sites of predilection (Fig. 5.15)

Lower abdomen, inner thighs, groins, flexures and intertriginous areas. Sometimes generalized involvement.

Complications

Secondary infection, especially because lesions are itchy.

Associations

- ❖ Co-existing malignancies should be ruled out as BP is a disease of elderly.
- ❖ Malignancies associated include those of stomach, breast and lungs.

Course

A self-limiting condition causing morbidity but very little mortality.

Investigations

Biopsy

- ❖ **Histopathology:** A dermoepidermal bulla (Fig. 5.16A), with neutrophils and eosinophils both in the bulla and dermis.

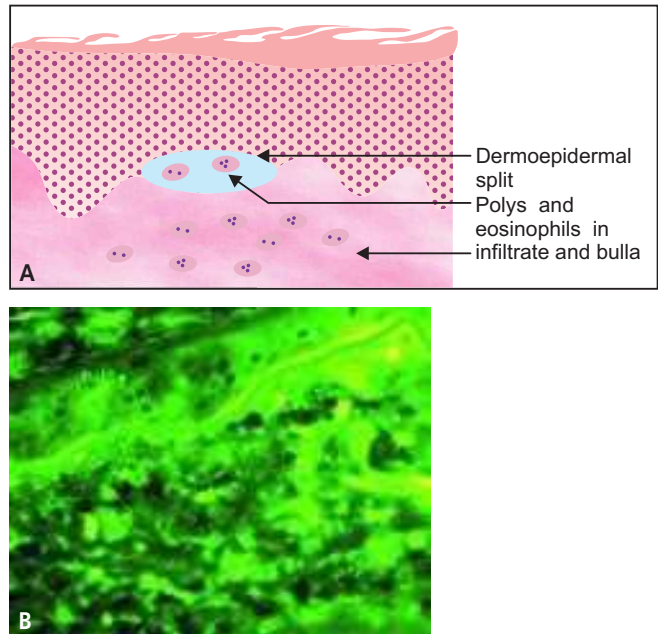


Fig. 5.16. Bullous pemphigoid: A: histopathology shows a dermoepidermal split. B: DIF shows linear deposit of C3 and IgG at dermoepidermal junction.

- ❖ **DIF:** Linear deposit of C3 and IgG (sometimes only C3 in absence of IgG) along the dermoepidermal junction (Fig. 5.16B).

Serodiagnosis

- ❖ Demonstrated by IIF, where circulating IgG attaches to the basement membrane zone of substrate tissues.
- ❖ Seen in 70% of patients. Titers do not correlate with disease activity.

Diagnosis

Points for diagnosis

BP is characterized by:

- ❖ Itchy, tense, persistent, large hemorrhagic bullae; on normal skin or on erythematous urticarial lesions. Bullae often do not rupture, but roof just settles down heal with milia formation.
- ❖ Infrequent oral lesions.
- ❖ Dermoepidermal split on histology. Linear deposition of IgG and C3 at the dermoepidermal junction on DIF of skin biopsy. Circulating antibodies on IIF in 70% of patients.

Differential diagnosis

BP needs to be differentiated from other bullous disorders:

a. *Pemphigus vulgaris (PV)* (P. 75).

b. *Bullous erythema multiforme (EM)*

Bullous EM	BP
Onset: acute eruption	Chronic eruption
Typical lesions: target lesions typical	Hemorrhagic bullae on urticarial plaques
Oral lesions: hemorrhagic crusting of lips is common	Oral lesions are infrequent
Sites: acral parts, then generalized	Lower abdomen, inner thighs, flexures and then generalized
Associations: antecedent history of drug intake/herpes simplex infection	Associated malignancies
DIF: not specific	Shows linear band of IgG and C3 at dermoepidermal junction

c. *Other diseases*

Dermatitis herpetiformis (P. 81), herpes gestationis¹⁰ (P. 82) and linear IgA bullous dermatosis (P. 80) may sometimes be confused with BP.

Treatment

BP is chronic disease which does not cause death and so the treatment need not (and should not) be aggressive.

Localized disease

- ❖ Topical steroids
- ❖ Dapsone (100–200 mg daily in adults).
- ❖ Combination of tetracycline (2 g daily) or doxycycline (200 mg daily) with niacinamide (1.5 g daily).

Generalized disease

- ❖ Systemic steroids (prednisolone 40–60 mg daily equivalent) mainstay of treatment.
- ❖ Immunosuppressive agents (azathioprine) may be added, if steroids alone fail to control the disease, or are contraindicated.

Chronic Bullous Disease of Childhood (CBDC)

Synopsis

Etiology: Immune-mediated blistering disorder.

Epidemiology: Seen in children 5–12 years of age. Variant seen in adults.

Morphology: Tense blisters; new bullae develop around healing bulla (string of pearl appearance).

Sites: Grouped, around body orifices.

Variants: Linear IgA dermatosis of adults.

Investigations: Dermoepidermal split (histopathology). Linear deposit of IgA (DIF).

Treatment: Dapsone/erythromycin ± low-dose steroids.

Etiology

- ❖ Autoimmune blistering disorder.
- ❖ Characterized by homogeneous deposition of IgA deposits linearly along dermoepidermal junction.

Epidemiology

- ❖ **Age:** Children usually starting below 5 years of age.
- ❖ **Gender:** Slight female preponderance.

Clinical Features

Morphology

- ❖ Itchy, tense bullae sometimes on an erythematous base.
- ❖ New lesions appear around previous lesions (**string of pearl appearance**) (Fig. 5.17).
- ❖ Oral lesions often present.

Sites of predilection

- ❖ Lesions are usually grouped (**cluster of jewels**).
- ❖ Occur around the orifices (perioral/perinasal/perigenital/perianal). Also frequently seen on lower abdomen, buttocks, knees, and elbows (Fig. 5.18).

10. **Herpes gestationis:** a bullous eruption which occurs in pregnancy.

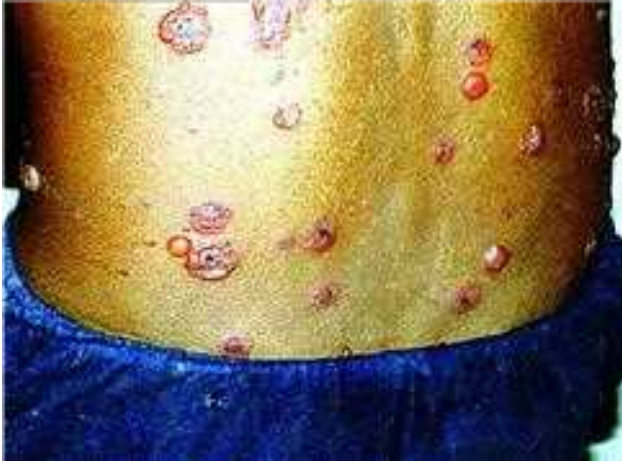

Fig. 5.17. Chronic bullous disease of childhood: string of pearl appearance is typical.

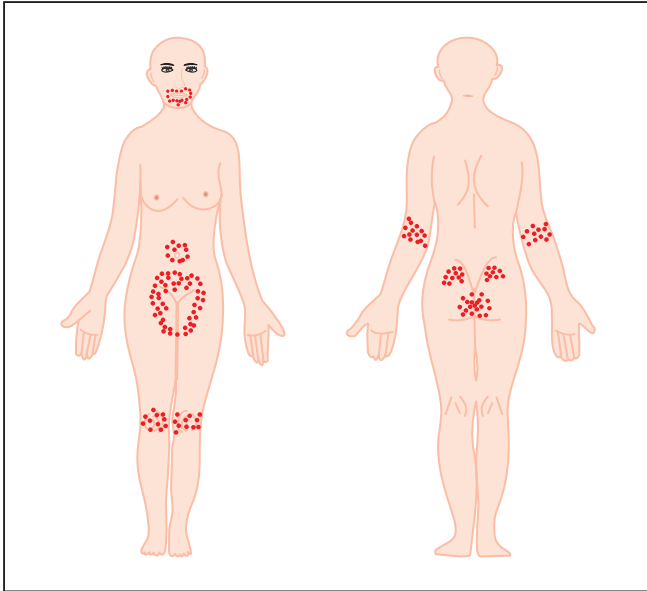


Fig. 5.18. Chronic bullous disease of childhood: sites of predilection

Complications

Secondary infection.

Variants

Linear IgA dermatosis of adults

- ❖ Itchy lesions in adults.
- ❖ Annular or grouped papules, vesicles and bullae.
- ❖ Extensor surfaces of elbows, knees, and buttocks.

Course

Usually self-limiting disease.

Investigations

- ❖ **Histopathology:** Dermoepidermal bulla with collections of **neutrophils** in the dermal papilla.
- ❖ **Immunopathology:** Linear deposit of IgA at dermoepidermal junction.

Treatment

Mild–moderate disease

Treatment options available include:

- ❖ Dapsone (1–2 mg/kg) is effective.
- ❖ Sulfapyridine and erythromycin have also been tried.

Severe disease

Add oral corticosteroids to above options.

Dermatitis Herpetiformis (DH)

Synopsis

Etiology: Gluten-sensitive enteropathy is always associated and probably responsible for skin lesions.

Morphology: Grouped erythematous papules (less frequent), vesicles (more frequent) and excoriated lesions (most frequent).

Site: Extensors and pressure points.

Associations: Gluten-sensitive enteropathy is almost always present, though rarely symptomatic.

Investigations: Dermoepidermal split with microabscesses or polyps in tips of dermal papillae (histopathology) and granular IgA deposits in tips of dermal papillae (DIF).

Treatment: Dapsone works dramatically. A gluten-free diet only slowly. So combine the two and then reduce dose of dapsone.

Etiology

- ❖ A gluten-sensitive enteropathy (GSE), though frequently asymptomatic, is almost always present.
- ❖ Absorption of gluten (and other dietary antigens) induces formation of circulating immune complexes which deposit in the dermal papillae, causing inflammation and a dermoepidermal split.

Epidemiology

- ❖ **Prevalence:** Rare.
- ❖ **Age:** 20–60 years, most frequent at 30–40 years.
- ❖ **Sex:** Male:female ratio is 2:1.

Clinical Features

Morphology

- ❖ Extremely itchy, grouped (so herpetiformis) papules (less commonly) and small vesicles (more frequently) develop on normal or erythematous skin. Are rapidly scratched (because of intense itching) and so usually only grouped excoriations seen (Fig. 5.19).
- ❖ Repeated scratching may cause eczematous changes and secondary infection.

Sites of predilection

Most frequently extensors (elbows, knees, buttocks, shoulders and sacral area).

Mucosal involvement

Asymptomatic oral mucosal involvement frequent.

Associated features and complications

- ❖ GSE (mild and patchy) is present in almost 100% of patients. Usually asymptomatic, though few patients may be symptomatic with abdominal pain, diarrhea and malabsorption.
- ❖ Rarely, small intestinal lymphomas may complicate enteropathy.

Investigations

Biopsy

- ❖ **Histopathology:** Of an early erythematous papule shows a dermoepidermal split with collection of polymorphs (microabscesses) at the tips of dermal papillae.

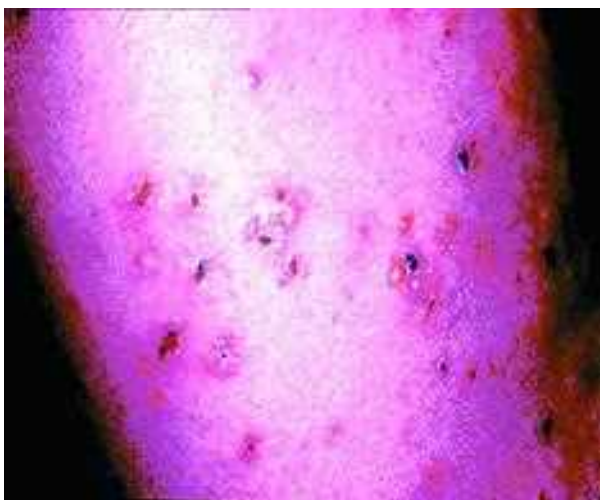

Fig. 5.19. Dermatitis herpetiformis: grouped vesicles develop either on normal or erythematous skin. Since the lesions are extremely itchy, they are rapidly excoriated.

- ❖ **DIF:** Granular deposit of IgA in tips of dermal papillae.

Serology

- ❖ Immune complexes in 20–40%.
- ❖ Antiendomysial and antireticulin antibodies present in most patients.

Diagnosis

Points for diagnosis

DH is characterized by:

- ❖ Itchy grouped, erythematous, papulovesicular lesions, frequently manifesting as grouped excoriations.
- ❖ Extensors of trunk and extremities.
- ❖ Characteristic histology (dermoepidermal split, papillary tip neutrophilic abscesses) and DIF findings (granular IgA deposit at dermal papillary tips).
- ❖ Dramatic response to dapsone.

Differential diagnosis

DH has to be distinguished from:

a. Scabies:

Scabies	DH
<i>Morphology:</i> papules, vesicles and pathognomonic burrows.	Grouped excoriations (frequent) and vesicles (infrequent)
<i>Distribution:</i> webs spaces, wrists, ulnar aspect of forearms, genitals, lower abdomen.	Extensors of extremities and trunk
<i>Associations:</i> family history present	Gluten-sensitive enteropathy
<i>Response:</i> to antiscabietic therapy	Dramatic response to dapsone

b. Nummular dermatitis:

Nummular dermatitis	DH
<i>History:</i> of atopic diathesis	Suggestive of gluten-sensitive enteropathy
<i>Morphology:</i> discoid plaques	Grouped papules (less frequent), vesicles (more frequent) and excoriations (most frequent)
<i>Site:</i> acral parts	Extensors of extremities and trunk

c. Insect bite hypersensitivity (IBH)

IBH	DH
<i>History:</i> of insect bite may not be forthcoming	Suggestive of gluten-sensitive enteropathy
<i>Morphology:</i> discoid plaques	Grouped papules (less frequent), vesicles (more frequent) and excoriations (most frequent)
<i>Site:</i> exposed parts	Extensors of extremities and trunk

Treatment

A two-pronged approach brings about quick and lasting response.

- ❖ **Gluten-free diet**¹¹: Slow to act on the skin lesions (several months) though the bowel changes revert to normal quickly. However, a gluten-free diet may be difficult to follow.
- ❖ **Drugs**: Dapsone (100–200 mg daily for adults) and sulfapyridine (1–1.5 g daily) work dramatically. Response (within 48–72 h) to dapsone, often used as a therapeutic test for diagnosis of DH.

Herpes Gestationis

- ❖ Rare dermatosis of pregnancy beginning in second and third trimester. Problem tends to recur in subsequent pregnancies.
- ❖ Pruritic, polymorphic eruption (papules, vesicles, bullae) and erythema multiforme-like targetoid lesions (Fig. 5.20).
- ❖ Abdomen. Other areas involved are chest and back. Mucosae spared.
- ❖ May be associated with fetal morbidity and death.
- ❖ Systemic steroids mainstay of therapy.

Epidermal Necrolysis

Synopsis

Etiology: Drug induced: anticonvulsants, sulfonamides, penicillin, butazones, oxicams, allopurinol, nevirapine.

Morphology: Deeply erythematous (purpuric) coalescing irregular lesions which either develop bullae. Or peel-off in sheets leaving large areas of denuded skin; heals with hyperpigmentation.

Mucous membranes: Mouth and eyes frequently, other mucosae less frequently affected. Manifest as hemorrhagic crusts and white pseudomembrane of lips.

Distribution: Symmetrically on face, trunk, proximal extremities.

Complications: High mortality. Infections, fluid and electrolyte imbalance, pulmonary involvement, renal failure. Late ophthalmic sequelae frequent.

Treatment: Supportive treatment paramount. Role of steroids controversial. Intravenous immunoglobulin, cyclosporine encouraging.

Also known as Stevens-Johnson syndrome–toxic epidermal necrolysis (SJS–TEN) complex.

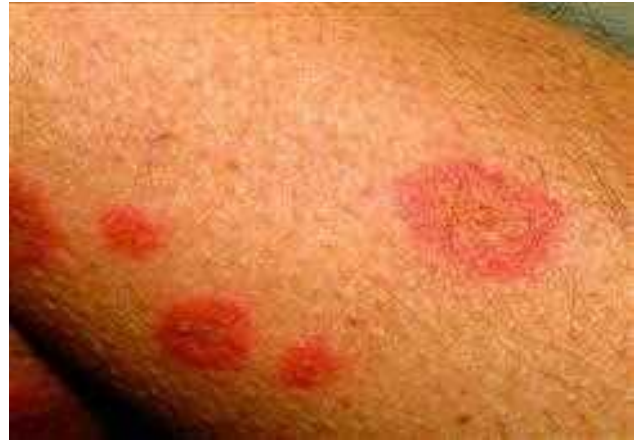

Fig. 5.20. Herpes gestationis: polymorphic eruption and erythema multiforme-like targetoid lesions.

Etiology

Epidermal necrolysis (EN) is almost always due to drugs (Table 5.5).

Table 5.5. Etiology of epidermal necrolysis

Drugs	<i>Anticonvulsants:</i> carbamazepine, phenytoin, barbiturates, lamotrigine <i>Chemotherapeutic agents:</i> sulfonamides, penicillin <i>NSAIDs:</i> butazones, oxicams <i>Others:</i> allopurinol, nevirapine
Miscellaneous	Systemic lupus erythematosus, graft vs host reaction, lymphoreticular malignancies, infections (<i>Mycoplasma pneumoniae</i> , herpes virus infection)
Idiopathic	5% of patients

Clinical Features

Morphology

- ❖ Consists of deeply erythematous (often purpuric) irregular lesions that rapidly coalesce.
- ❖ Either develop bullae (Fig. 5.21A). Or peel-off in sheets (similar to scalds) either spontaneously or when pressure is applied (positive **Nikolsky's sign**). On peeling, leave large areas of denuded skin (Fig. 5.21B) that heal with hyperpigmentation.
- ❖ Based on total body surface area (BSA) of skin detached, EN classified into:
 - SJS: <10% BSA.

11. **Gluten-free diet:** avoid wheat, but intake of oats is controversial.

- SJS/TEN¹¹ overlap: 10–30% BSA.
- TEN: > 30% BSA.

Sites

Symmetrical involvement of face, trunk and proximal part of extremities. Spares distal part of extremities.

Mucous membranes

Mucous membranes (mouth and eyes frequently, other mucosae less frequently) affected. Manifest as hemorrhagic crusts (Fig. 5.21C) and white pseudomembrane of the lips.

Constitutional symptoms

Common and includes high fever, pain and weakness.

Complications

EN is an emergency, associated with high mortality due to:

- ❖ **Infections:** Including sepsis.
- ❖ **Fluid and electrolyte imbalance.**
- ❖ **Pulmonary involvement:** Interstitial syndrome.
- ❖ **Renal failure:** A direct nephrotoxic effect of the drug. Or due to hypotension.
- ❖ **Ophthalmic complications:** Acute complications and late sequelae like dry eyes, symblepharon.

Course

- ❖ If offending drug withdrawn, early supportive care instituted and no complications supervene, the denuded areas re-epithelialize over a few days.
- ❖ Otherwise high mortality.

Investigations

- ❖ **Biopsy:** Shows a subepidermal split with necrotic epidermis.
- ❖ **Provocation:** Causative drug can be identified by provocation test, but this is controversial¹².

Diagnosis

Points for diagnosis

EN is characterized by:

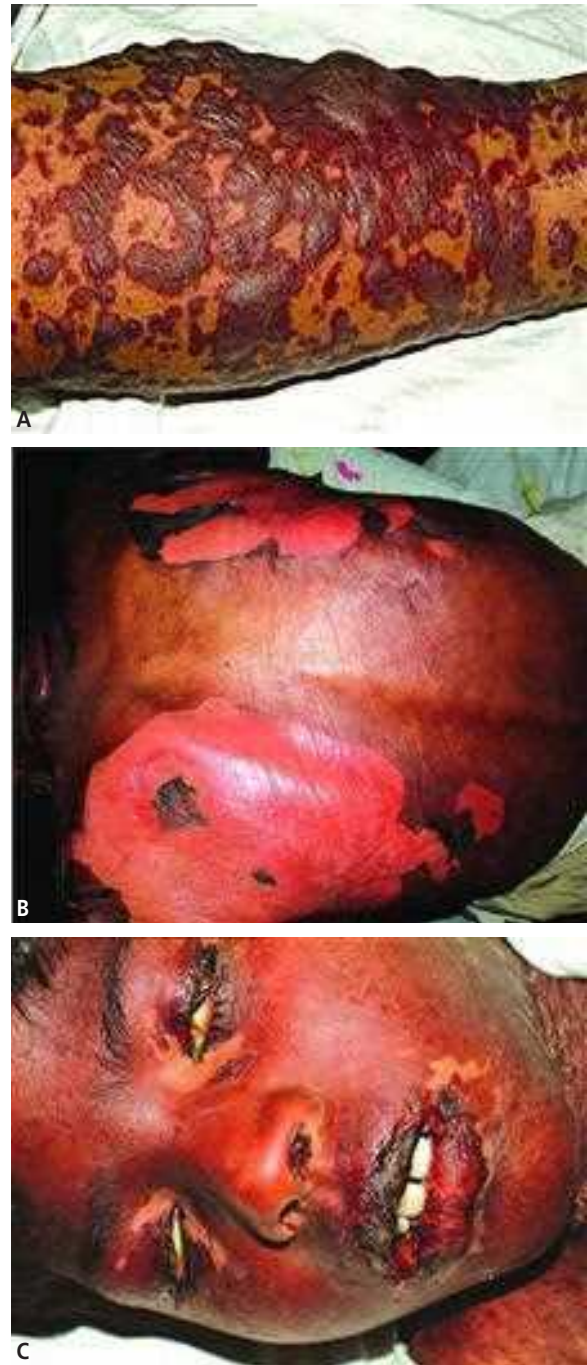


Fig. 5.21. Toxic epidermal necrolysis: A: bullae on dusky erythema. Bullae rupture to leave large areas of denuded skin healing with hyperpigmentation. B: large areas of denudation. C: hemorrhagic crusts on lips and eye involvement frequent.

11. **SJS-TEN:** Stevens–Johnson syndrome–toxic epidermal necrolysis.

12. **Provocation test:** doing the test is ethically controversial. If the patient has been taking several drugs before the onset of TEN, the causative drug may be identified after subsidence of the reaction, by giving one drug at a time, at 24–48 h intervals and waiting for the eruption to develop under close supervision. If reaction develops, it is rapidly controlled by giving systemic steroids. Provocation also provides information regarding the alternative drugs which can be safely given, in case of polypharmacy of seizures and tuberculosis.

- ❖ Acute onset, usually in adults; history of antecedent drug intake.
- ❖ Generalized tender, erythematous (purpuric) skin; may develop bullae or may peel off in sheets, leaving large denuded areas; positive Nikolsky's sign.
- ❖ Mucosal involvement.

Differential diagnosis

EN should be distinguished from:

a. Erythema multiforme major (EMM)

EMM	EN
<i>Etiology:</i> drugs, infection, idiopathic	Drugs
<i>Constitutional symptoms:</i> present	Conspicuous
<i>Skin lesions:</i> target lesions, extensive	Deeply erythematous (purpuric) irregular lesions which either develop bullae or peel-off in sheets
<i>Mucosal involvement:</i> present	Severe

b. Staphylococcal scalded skin syndrome (SSSS)

SSSS	EN
<i>Etiology:</i> <i>S. aureus</i> infection at distant focus	Drugs
<i>Age:</i> in infancy	At any age
<i>Constitutional symptoms:</i> absent	Conspicuous
<i>Skin lesions:</i> superficial peeling	Deep peeling
<i>Mucosal involvement:</i> absent	Severe
<i>Treatment:</i> antistaphylococcal antibiotics	Remove trigger. Supportive care. Steroids may help

Treatment

General measures

EN is a dermatological emergency and needs to be treated aggressively.

- ❖ Withdrawal of suspect drug.
- ❖ Intensive barrier nursing and medical support, including use of parenteral alimentation.
- ❖ Suspension beds for patients with extensive lesions.
- ❖ Antibiotics, therapeutic and prophylactic use, but only if necessary.
- ❖ Thermoregulation.
- ❖ Eye and mouth care.

Specific therapy

- ❖ Use of steroids is controversial. A short course of systemic steroids often resorted to in acute phase.
- ❖ Intravenous immunoglobulin and cyclosporine are promising (new) modalities.

Eczematous Dermatitis

6

Chapter Outline

Basics of Eczema[•]

Definition

Classification of eczema

Clinical features

Complications of eczema

Diagnosis

Investigations to find cause of eczema

Treatment

Common Patterns of Eczema

Atopic dermatitis[•]

Seborrheic dermatitis[•]

Contact dermatitis[•]

Miscellaneous eczemas[•]

Basics of Eczema

The term eczema means **to boil out**¹, because it seems that the skin is “boiling out” or “oozing out” in eczema.

Definition

Eczema is a reaction pattern that has two components:

❖ **Clinical component**

❖ **Histological component**

Clinical Component

Eczema, clinically manifests as pruritus, erythema, edema, papules, vesicles, scaling, and **lichenification**². The feature that predominates depends on the stage—acute eczema is exudative (Fig. 6.1), while chronic eczema is dry, scaly, and often lichenified (Fig. 6.2).

Histological Component

Histologically, the hallmark of eczema is **spongiosis**³ but the exact histological appearance depends on the stage of the disease, *i.e.*, on the clinical appearance. In the chronic stage, the lesion shows **hyperkeratosis**⁴ and **acanthosis**⁵.

Difference between Eczema and Dermatitis⁶

The terms eczema and dermatitis are used with different connotations by different people:

1. **Boil out:** *ec* = out; *zema* = boil.
2. **Lichenification:** skin change due to scratching. Manifests as thickening and hyperpigmentation of skin with increased skin markings.
3. **Spongiosis:** sponge-like; this occurs due to intercellular (in between cells) edema, which gives epidermis a sponge-like appearance.
4. **Hyperkeratosis:** thickening of stratum corneum.
5. **Acanthosis:** thickening of viable epidermis.
6. **Dermatitis:** inflammation of skin; *cf.* dermatosis which is a broader term and includes dermatitis and several other skin conditions.

[•]Should know

[◦]Good to know

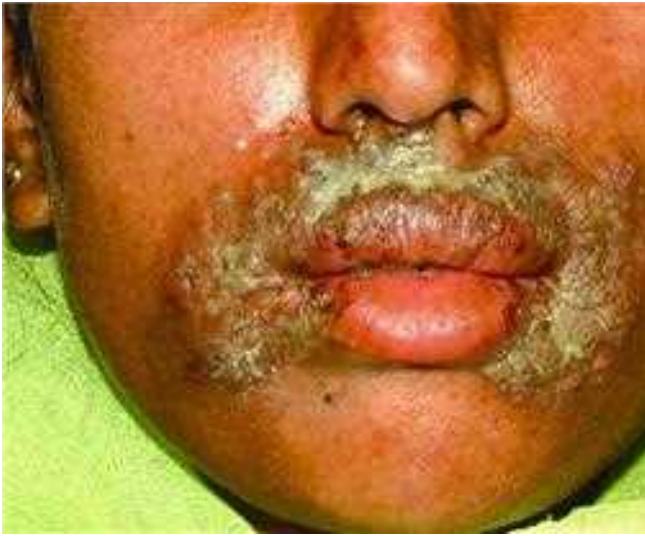

Fig. 6.1. Acute eczema: erythematous, edematous, exudative crusted plaques with papulovesiculation.

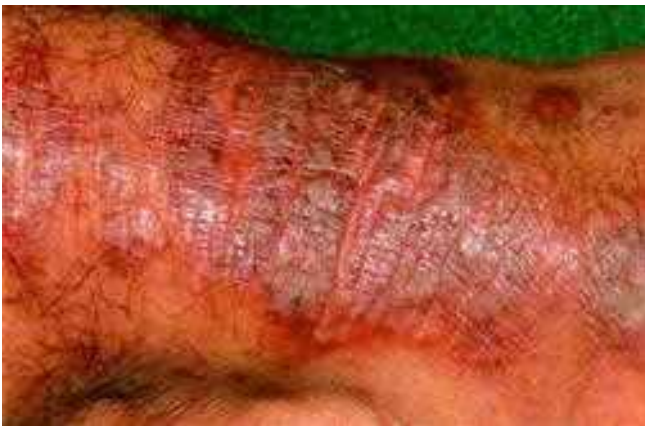

Fig. 6.2. Chronic eczema: lichenified plaque characterized by thickening, hyperpigmentation and increased skin markings.

- ❖ Patients usually use the term eczema to denote any skin disease which is chronic. They sometimes also use the term “allergy”.
- ❖ Some dermatologists use the term dermatitis to include any cutaneous inflammation, eczema being just one type of dermatitis, implying dermatitis is a broader term.
- ❖ Some use both terms interchangeably.

Classification of Eczema

Several classifications of eczemas are available, none being all encompassing (Table 6.1).

Table 6.1. Classification of eczema

Etiology	Pattern/morphology	Chronicity
Endogenous	Discoid	Acute
Exogenous	Hyperkeratotic	Chronic
Combined	Lichenified	
	Seborrheic	

The most practical way to classify eczema, according to etiology is:

- ❖ **Endogenous eczema:** Where constitutional factors predispose the patient to developing an eczema.
- ❖ **Exogenous eczema:** Where external stimuli trigger development of eczema, e.g., irritant dermatitis.
- ❖ **Combined eczema:** When a combination of constitutional factors and extrinsic triggers are responsible for the development of eczema e.g., atopic dermatitis (Table 6.2).

Table 6.2. Eczema: Etiological classification

Endogenous	Exogenous	Combined
Seborrheic dermatitis	Irritant dermatitis	Atopic dermatitis
Nummular dermatitis (discoid)	Allergic dermatitis	Pompholyx
Lichen simplex chronicus	Photodermatitis	
Pityriasis alba	Radiation dermatitis	
Stasis dermatitis	Infective dermatitis	

Clinical Features

The clinical features of eczema depend on the stage of the disease:

- ❖ Acute
- ❖ Chronic.

Acute Eczema

Acute eczema is characterized by an erythematous and edematous plaque, which is ill-defined and is surmounted by papules, vesicles, pustules and exudate that dries to form crusts (Fig. 6.1). A subsiding eczematous plaque may be covered with scales.

Chronic Eczema

Chronic eczema is characterized by **lichenification** (Fig. 6.2), which is a triad of hyperpigmentation, thickening of skin and increased skin

markings. The lesions are less exudative and more scaly. Flexural lesions may develop fissures.

Complications of Eczema (Table 6.3)

Dermatological Complications (Table 6.3)

Table 6.3. Complications of eczema

Dermatological complications
Infection
Ide eruption
Contact dermatitis
Erythroderma
Psychosocial complications
Anxiety
Depression
Social complications
Wage loss
Debility
Social ostracism

Infections

- ❖ Presence of exudate encourages development of secondary infection, *e.g.*, in atopic dermatitis, seborrheic dermatitis.
- ❖ Bacteria, by virtue of their antigenicity, may sustain the eczematous process.

Ide eruption (dissemination)

Severely exudative lesions of eczema in one part of the body may be associated with appearance of a shower of papulovesicular lesions on other parts (especially trunk and palms and soles) due to hypersensitivity (Figs. 6.3A and B).

Contact dermatitis

Liberal (and often unwarranted) use of several topical agents (antibiotics, antifungals, and steroids) to treat lesions of eczema encourages development of contact allergic dermatitis. This may sustain the eczematous process.

Erythroderma⁷

Extensive eczema, especially when chronic, may generalize to involve whole body.

Diagnosis (Fig. 6.4)

Is It Eczema?

Points for diagnosis

The diagnosis of eczema is based on following features:

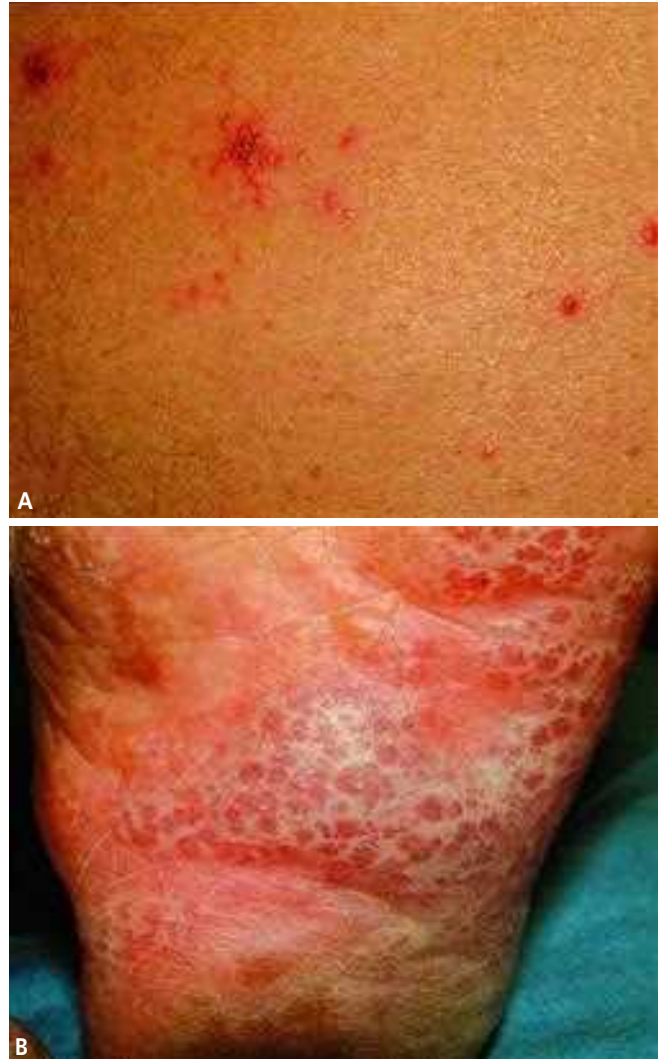

Fig. 6.3. Ide eruption. A: in a patient with acute eczema at another site, papulovesicular lesions develop symmetrically on the trunk. B: they may also develop on soles (and palms).

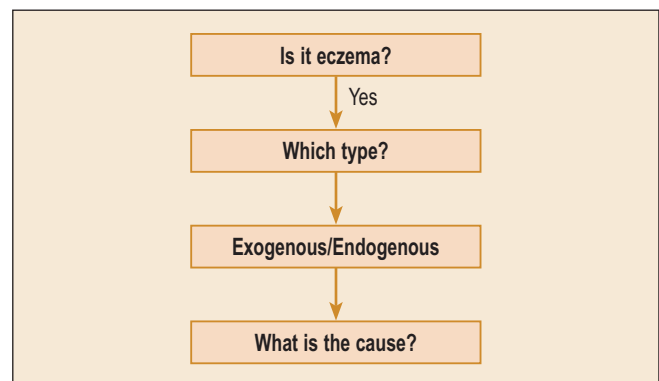


Fig. 6.4. Algorithm for diagnosis of eczema.

7. **Erythroderma:** involvement of the whole body with erythema and scaling.

- ❖ **Acute eczema:** Itchy exudative plaques, surmounted by papulovesicles.
- ❖ **Chronic eczema:** Lichenified scaly plaques.

Differential diagnosis

Eczema should be differentiated from:

a. Psoriasis

Psoriasis	Eczema
<i>Itching:</i> moderately itchy. Scratching results in bleeding	Very itchy. Scratching results in oozing
<i>Morphology:</i> well-defined indurated plaques	Not so well-defined and not indurated
<i>Surmounted with:</i> silvery scales	Scale-crust
<i>Auspitz sign:</i> positive	Negative
<i>Nail changes:</i> typical	Variable

b. Scabies in infants

Scabies in infants	Infantile eczema
<i>Morphology:</i> burrows	Papulovesicles
<i>Distribution:</i> characteristic; on palms and soles, genitalia	Spare palms and soles
<i>Family history:</i> positive	Positive for atopic diathesis

c. Dermatophytic infections

Dermatophytic infections	Eczema
<i>Morphology:</i> annular lesions (center relatively clear)	Discoid lesions
<i>Exudation:</i> minimal exudation/crusting	Exudation/crusting/lichenification
<i>Potassium hydroxide mount:</i> positive for fungus	Negative

Which Type of Eczema: Endogenous or Exogenous?

It is important to differentiate between endogenous and exogenous eczema.

Endogenous eczema

Clinical features that suggest an **endogenous eczema** are:

- ❖ Symmetrical distribution.
- ❖ Well-set patterns like atopic dermatitis or seborrheic dermatitis.

Exogenous eczema

Clinical features which suggest an **exogenous eczema** are:

- ❖ Asymmetrical distribution; sometimes linear or rectilinear configuration.

- ❖ Known contact with irritants and allergens.
- ❖ Well-set pattern like airborne contact dermatitis.
- ❖ Temporal improvement on change of environment and removal of trigger.

Investigations to Find Cause of Eczema

Some eczemas need to be investigated extensively while others can be treated without investigations. The rule of the thumb is to treat acute eczemas without investigations while chronic and recurrent eczema should be investigated.

Patch Tests

Patch tests are very useful in finding the cause of allergic but not irritant dermatitis, *i.e.*, they detect allergens responsible for type IV allergy.

Antigens

The following antigens are tested:

- ❖ Suspected antigens and those chemicals which are likely to be used as substitutes.
- ❖ Battery of antigens (which includes the common culprits). There are different antigen series for different geographic areas, for different occupations, *etc.*

Technique

- ❖ Antigens, in standardised dilutions, are applied to the back and occluded⁸ (Fig. 6.5A).
- ❖ Patches are removed after 48 h and read after ½ h (Fig. 6.5B). Another reading done at 96 h detects delayed reactions (Fig. 6.5C).

Interpretation

Depending on the degree of inflammation, the reaction is graded from 0 to 3+ (Table 6.4).

Table 6.4. Interpretation of patch tests

	Clinical findings	Grading
No reaction	Normal skin	0
Doubtful reaction	Faint erythema	?
Weak reaction	Palpable erythema, infiltration	1+
Strong reaction	Erythema, infiltration, papules, and vesicles	2+
Extreme reaction	Intense erythema, infiltration, coalescing vesicles	3+
Irritant reaction	Cauterization	IR

8. **Occluded:** to encourage penetration of allergens.




Fig. 6.5. Patch testing: A: patches are occluded after application of antigens. B: readings at 48 and 96 h. C: patch testing—schematic representation.

Results of patch test should be interpreted keeping the clinical picture in mind as it is not necessary that the antigen positive in the patch test is the one causing the current episode of dermatitis.

Photopatch Tests

Photopatch tests are done to establish cause of **photoallergic contact dermatitis**⁹.

Technique (Fig. 6.6)

- ❖ Antigens applied as in routine patch testing, **but in duplicate**.
- ❖ At 24 h, one set of patches is removed and irradiated with UVA and reoccluded.
- ❖ The reaction to both set of patches is read at 48 h.

Interpretation

Photoallergic contact dermatitis, if present, manifests at 48 h. The negative control patch which has not been irradiated rules out allergic contact dermatitis (Table 6.5).

Table 6.5. Interpretation of photopatch test

Reading at unexposed sites	Reading at sites exposed to UVA	Interpretation
–	–	No allergy
–	++	Photocontact allergy
++	++	Contact allergy
+	+++	Contact allergy with Photoaggravation

9. **Photoallergic contact dermatitis:** in this, patient develops a reaction if exposed to antigen and ultraviolet rays (usually UVA), and not when exposed to either.

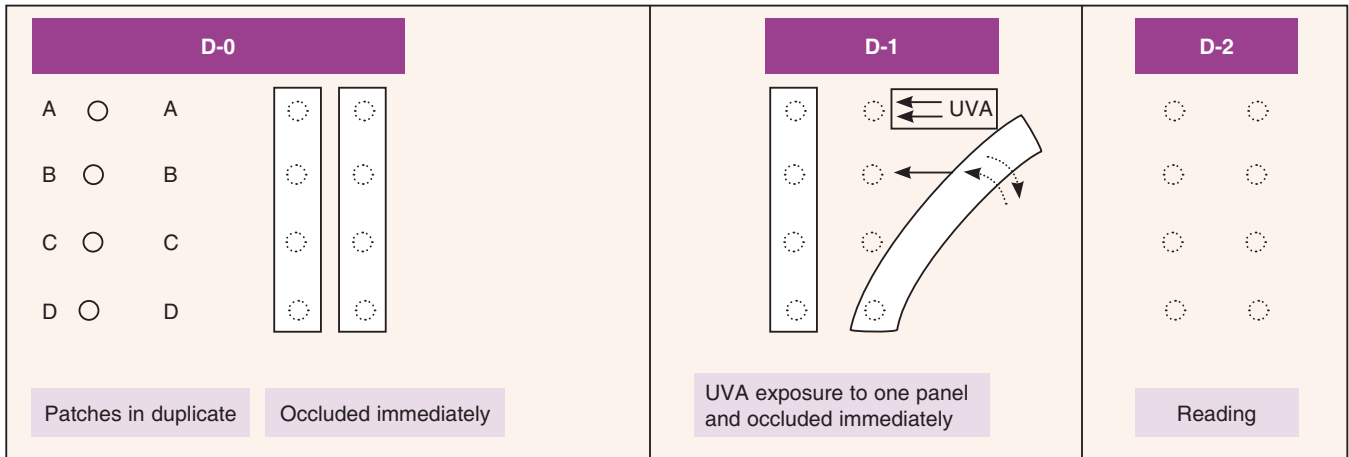


Fig. 6.6. Photopatch test: schematic representation.

Prick Tests

- ❖ Type I hypersensitivity is detected by prick tests.
- ❖ Relevance of positive prick tests in determining the cause of eczema (atopic dermatitis) and urticaria, however, is debatable.

Serological Tests

- ❖ Total serum IgE levels and IgE antibodies specific to certain antigens (measured using radioallergosorbent test or RAST) may be useful in diagnosis in atopic states and this test has replaced the prick test completely.
- ❖ RAST may some times help to identify specific (dietary and environmental) allergens which may be perpetuating dermatitis in an atopic patient. Most dermatologists, however, doubt the relevance of this test.

Treatment

Synopsis

- ❖ **Remove trigger**
- ❖ **Hydration**
- ❖ **Acute localized lesions:** Soaks followed by topical of steroids.
- ❖ **Acute extensive lesions:** Short course of systemic steroids.
- ❖ **Infected lesions:** Topical or systemic antibiotics and topical steroids.
- ❖ **Chronic lesions:** Topical steroids, often with keratolytic agents like urea and salicylic acid, in ointment base.

General Measures

Remove triggers

- ❖ Contact allergens/irritants in contact dermatitis.
- ❖ Aggravating factors in atopic dermatitis.

Hydration and use of emollients

- ❖ Several eczematous conditions, *e.g.*, atopic dermatitis and asteatotic eczema associated with dryness with dry skin being more susceptible to irritants.
- ❖ So one basic principle of treatment of eczema is hydration of skin, followed by application of emollients to trap the moisture.

Acute Phase

Topical treatment

The best treatment for acute weeping phase of eczema is liquid applications.

- ❖ **Acute eczema of hands and feet:** Soaks of potassium permanganate (0.01%) or aluminium acetate (0.65%) solution, followed by application of steroid lotion or cream is best.
- ❖ **Larger areas:** Compresses followed by application of soothing agents like calamine lotion as also topical steroids and topical **immunomodulators**¹⁰ are helpful.

Systemic treatment

- ❖ **Systemic steroids:** A short course of systemic steroids is often necessary in extensive lesions and when an 'ide' eruption develops.
- ❖ **Immunosuppressives:** Like azathioprine used for recurrent episodes.

10. **Immunomodulators:** like tacrolimus ointment or pimecrolimus cream.

- ❖ **Antibiotics:** Used for infected lesions.
- ❖ **Antihistamines:** As itching is frequently troublesome.

Chronic Phase

- ❖ Though chronic eczema responds well to nonsteroidal applications like ichthammol, these are no longer popular.
- ❖ **Steroids:**
 - *Topical steroids:* for localized lesions, topical steroids in an ointment base, treatment of choice. The strength of the steroid is important. Nothing stronger than a low–medium potency steroid should be used on the face, flexures and in infants. Even in adults, one should not prescribe more than 200 g of a medium potency steroid, 50 g of a medium–high potency steroid or 25 g of a high-potency steroid in a week. For lichenified lesions, topical steroids may be combined with keratolytic agents like salicylic acid or urea.
 - *Systemic steroids:* for extensive lesions like in airborne contact dermatitis.
- ❖ **Antibiotics:** Bacterial infection would need topical or systemic antibiotics.
- ❖ **Topical immunomodulators:** For their steroid sparing action.

Common Patterns of Eczema

Atopic Dermatitis (AD)

Synopsis

Etiology: A strong genetic predisposition. Raised IgE level is most consistent immunological finding.

Clinical features: Picture varies with age of patient. *Infantile phase:* Begins at about 3 months, severely itchy, exudative lesions on face and other parts, sparing diaper area. Clears in 40%, by age of 18 months. *Childhood phase:* Itchy, leathery flexural lesions. *Adult phase:* Lichenified flexural lesions; sometimes a discoid pattern.

Associated features: Ichthyosis vulgaris, lick cheilitis, nipple eczema, hand dermatitis, and asthma.

Complications: Bacterial and viral infections.

Treatment: Multipronged approach. Avoid triggers like woollens and excessive degreasing. Rehydration followed by topical moisturizers forms the mainstay of therapy. Topical therapy like steroids (with oral antihistaminics) during flares. Tacrolimus and pimecrolimus to prevent flares. *Extensive lesions:* oral steroids, cyclosporine and azathioprine. Antihistamines regularly used, though role debated.

The word “**atopy**”¹¹ was first used for a group of hereditary disorders in people who had a tendency to develop an urticarial response to foods and inhaled substances.

Definition

AD is an endogenous eczema triggered by exogenous agents and characterized by:

- ❖ Extremely pruritic, recurrent, symmetric eczematous lesions.
- ❖ Site of involvement characteristic, but variable depending on age of patient.
- ❖ Personal or family history of atopic diathesis.
- ❖ Increased ability to form IgE (reagin) to common environmental allergens.

Etiology and Pathogenesis (Fig. 6.6)

Genetic

- ❖ Genetic predisposition very important, but precise mode of inheritance uncertain, though may be autosomal dominant.
- ❖ Atopic diseases run true to type within each family—in some families, members predominantly have eczema, while in other families respiratory symptoms predominate. This is probably because dermatitis and asthma are inherited through separate though closely related genetic pathways.
- ❖ HLA typing, however, does not support genetic inheritance.

Immunological changes

IgE levels

- ❖ **Abnormalities of IgE:** Include:
 - Elevated IgE levels (more than 80% of patients with AD have levels of >200 IU/ml of IgE).
 - Increased specific IgE to multiple allergens (foods, aeroallergens, microbes, and their toxins).
 - Increased expression of IgE receptors on B cells.
- ❖ **Cause of elevated levels of IgE:** The exact cause is not known but may be due to:
 - Defective control of IgE production by T-lymphocytes.
 - IgE overproduction to a variety of antigenic challenges.
- ❖ **Role of IgE:** Antigens attach to IgE on surface of mast cells leading to their degranulation

11. **Atopy:** A = without; *topical* = local place or position; atopy means “without local position” referring to lack of niche for this disorder in the early times.

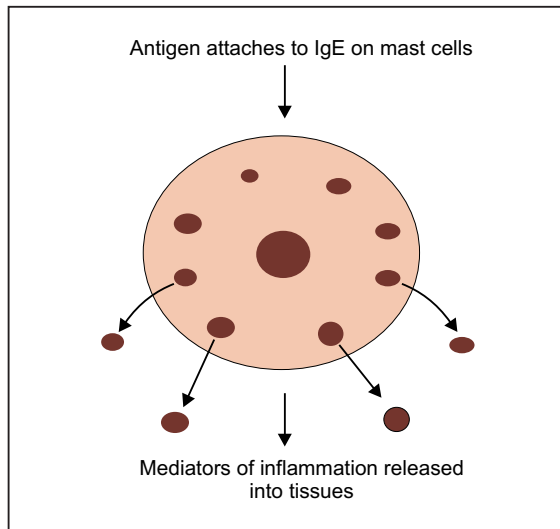


Fig. 6.7. Pathogenesis of atopic dermatitis.

resulting in release of mediators of inflammation (Fig. 6.7).

Abnormalities of lymphocytes

Abnormalities of lymphocytes detected include:

- ❖ Reduced delayed hypersensitivity.
- ❖ Decreased number of circulating T-lymphocytes, especially suppressor T-cells resulting in decrease in T-cell activity.
- ❖ Increased proportion of B-lymphocytes with surface-bound IgE.

Epidemiology

- ❖ Seen in 3% of all infants.
- ❖ Begins between 3 and 6 months of age.
- ❖ Increasing worldwide incidence because of:
 - Increased exposure to pollutants.
 - Increased exposure to indoor allergens (especially house dust mite).
 - Decline in breast feeding.

Clinical Features

Three distinct patterns of AD have been recognized, depending on the age of the patient.

Infantile phase¹²

- ❖ Begins after the age of 3 months¹³.
- ❖ Intensely itchy papules and vesicles, which soon become exudative.

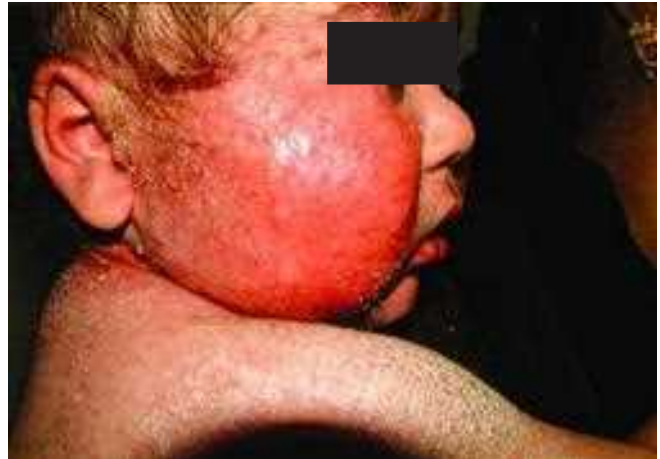

Fig. 6.8. Infantile phase of atopic dermatitis: papulovesicular lesions on face.

- ❖ Begins on the face (Fig. 6.8) but can involve rest of the body, but sparing the diaper area.
- ❖ Secondary infection common.
- ❖ Runs a chronic course:
 - In 40% of infants, lesions clear by the age of 18 months.
 - In 60%, pattern changes into childhood pattern.

Childhood phase (Fig. 6.9)

- ❖ Dry, leathery and extremely itchy plaques.
- ❖ Mainly on the elbow and knee flexors. Often a reversed (extensor) pattern seen.

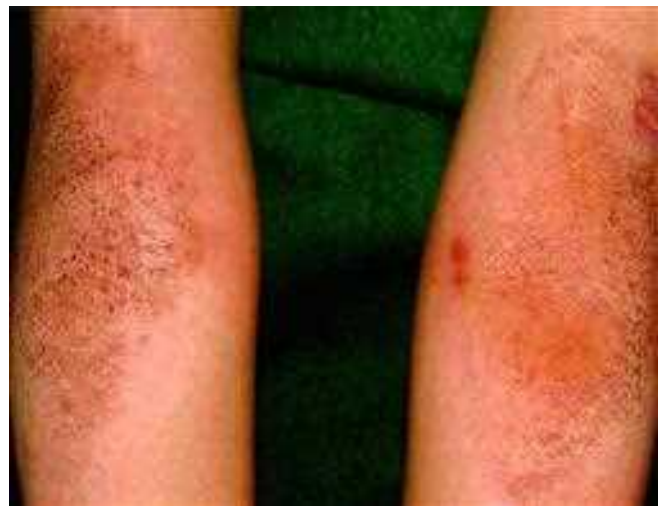

Fig. 6.9. Atopic dermatitis in childhood: note dry plaques in the flexors.

12. **Infantile phase:** often referred to as infantile eczema.

13. **3 months:** coordinated scratching response develops after age of 3 months, so the onset of AD usually after 3 months of age.

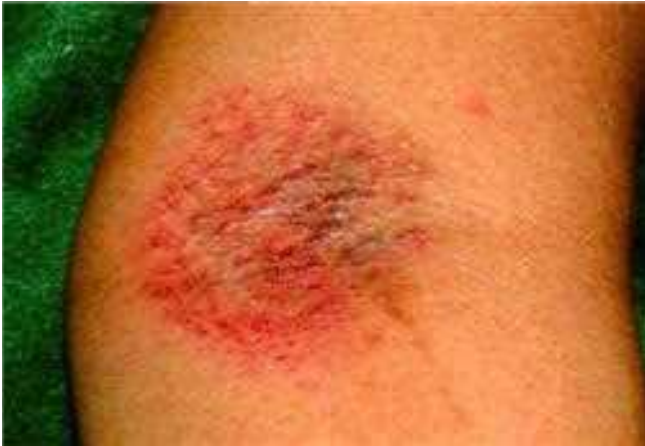

Fig. 6.10. Atopic dermatitis in adults: lichenified plaques in the flexures.

Adult phase

- ❖ Intensely itchy, lichenified plaques (Fig. 6.10).
- ❖ Cubital and popliteal fossae and sometimes the neck.
- ❖ A low-grade involvement may be seen on the rest of the body, *e.g.*, lick cheilitis, (Fig. 6.11A), nipple eczema, hand dermatitis, and nummular dermatitis (Fig. 6.11).

Associated features (Table 6.6)

- ❖ **Other atopic manifestations:** About 50% of patients with AD have allergic rhinitis and about 30% have asthma. In patients with both asthma and dermatitis, there may be an inverse relationship between the two.
- ❖ **Urticaria:** Atopics also develop food allergies and urticaria more frequently.

Complications

Infections

- ❖ **Bacterial infections:** Impetigo is common.
- ❖ **Viral infections:** Atopics have a greater susceptibility to viral infections like herpes simplex, molluscum contagiosum and human papilloma virus infection due to impairment of cell-mediated immunity. In the presence of active eczema, herpes simplex infection may become generalized (**eczema herpeticum or Kaposi's varicelliform eruption**), manifesting as generalized grouped vesicles which rapidly evolve into polycyclic erosions (Fig. 6.12).
- ❖ **Fungal infections.**

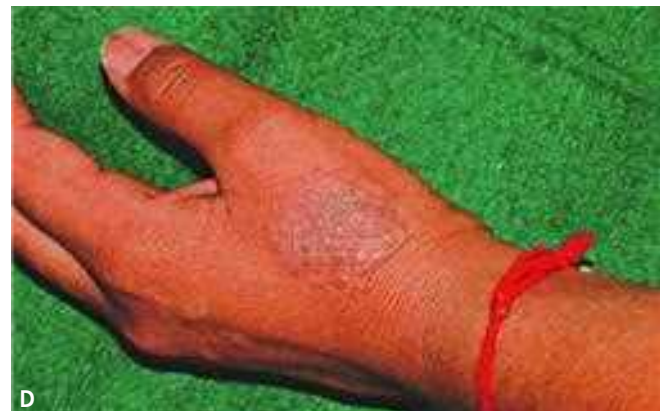
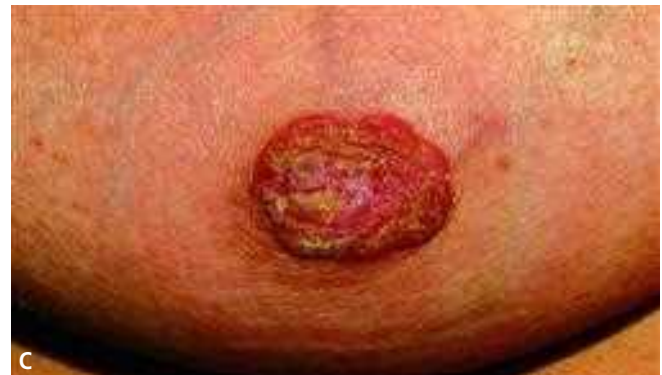
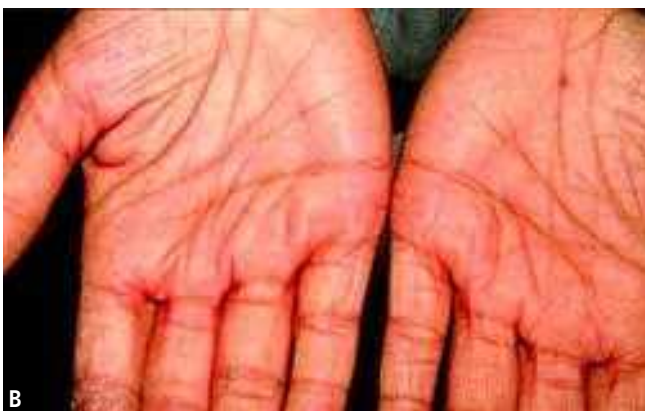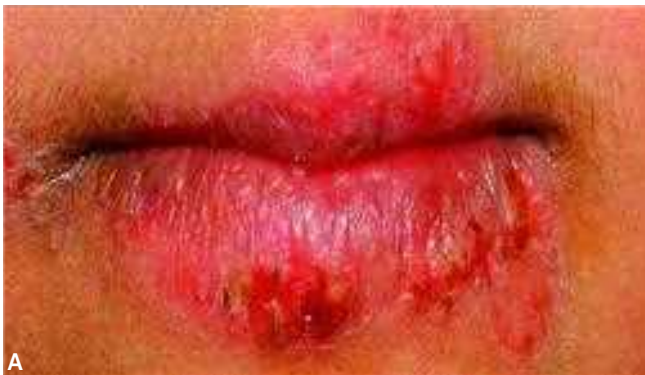Fig. 6.11. Atopic dermatitis: A: cheilitis due to licking. B: hyperlinear palms with irritant dermatitis. C: nipple dermatitis: usually appears bilaterally as itchy and crusted plaques. D: nummular lesions on acral parts.

Table 6.6. Hanifin and Rajka's criteria for diagnosis of atopic dermatitis

Major features (must have 3 or more):
Pruritus
Typical morphology and distribution:
• Facial and extensor involvement in infants and children
• Flexural lichenification in adults
Dermatitis, chronic or chronically relapsing
Personal or family history of atopy (asthma, allergic rhinitis or atopic dermatitis)
Minor features* (must have 3 or more):
Cataracts (anterior subcapsular)
Cheilitis (Fig. 6.11A)
Conjunctivitis, recurrent
Facial pallor/erythema
Food intolerance
Hand dermatitis: nonallergic, irritant (Fig. 6.11B)
Ichthyosis
Elevated levels of IgE
Immediate (type I) skin test reactivity
Infections
Itching, when sweating
Keratoconus
Keratosis pilaris
Nipple dermatitis (Fig. 6.11C)
Orbital darkening
Palmar hyperlinearity (Fig. 6.11B)
Perifollicular accentuation
Pityriasis alba
White dermographism
Wool intolerance
Xerosis

* Arranged alphabetically

Miscellaneous complications

- ❖ **Growth:** Due to itching, these children sleep poorly. Growth hormone levels generally rise during deep sleep and this may not happen in patients with AD due to disturbed sleep. Consequently, these children grow poorly.
- ❖ **Side effects of steroids:** Prolonged use of topical steroids can result in local and systemic side effects.
- ❖ **Social and psychosocial disturbances.**

Course (Fig. 6.13)

Investigations

The diagnosis of AD is mainly clinical with very few laboratory tests available for confirmation.

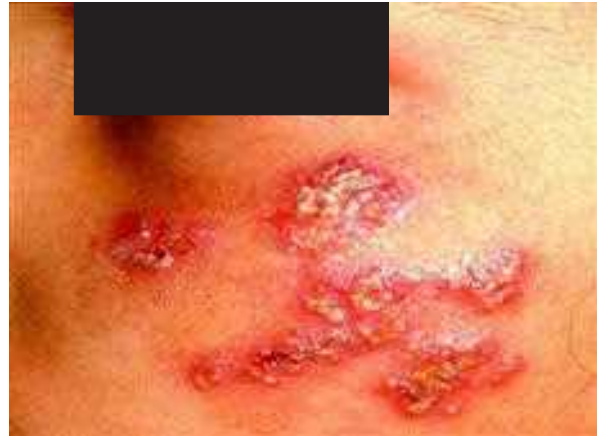

Fig. 6.12. Eczema herpeticum: generalized grouped vesicles which rapidly evolve into polycyclic erosions.

Prick test

- ❖ Value of prick test in diagnosis of AD debatable.
- ❖ Has been replaced by RAST to measure antigen specific IgE and this also has a doubtful value.

IgE levels

- ❖ Elevated total serum IgE (normal: <200 IU/ml)¹⁴ and IgE antibodies specific to antigens may be useful in diagnosing atopic state.
- ❖ May help in advising patient on role of dietary and environmental allergens in perpetuating dermatitis.

Diagnosis

Points for diagnosis¹⁵

- ❖ For routine clinical work, diagnosis of AD is based on:
 - Presence of an itchy skin condition (or parental report of scratching or rubbing in a child).
 - Plus 3 or > of the following:
 - Onset <2 years of age (not used if child is under 4 years).
 - History of skin crease involvement (including cheeks) in children under 10 years.
 - History of a generally dry skin.
 - Personal history of other atopic disease. Or history of any atopic disease in a first degree relative in children under 4 years.
 - Visible flexural dermatitis (or dermatitis of cheeks/forehead and outer limbs in children under 4 years).

14. **IgE levels:** 80% of AD patients have elevated IgE and 15% of normal individuals may have elevated IgE.

15. **Diagnostic criteria:** UK refinement of Hanifin and Rajka's diagnostic criteria for atopic dermatitis.

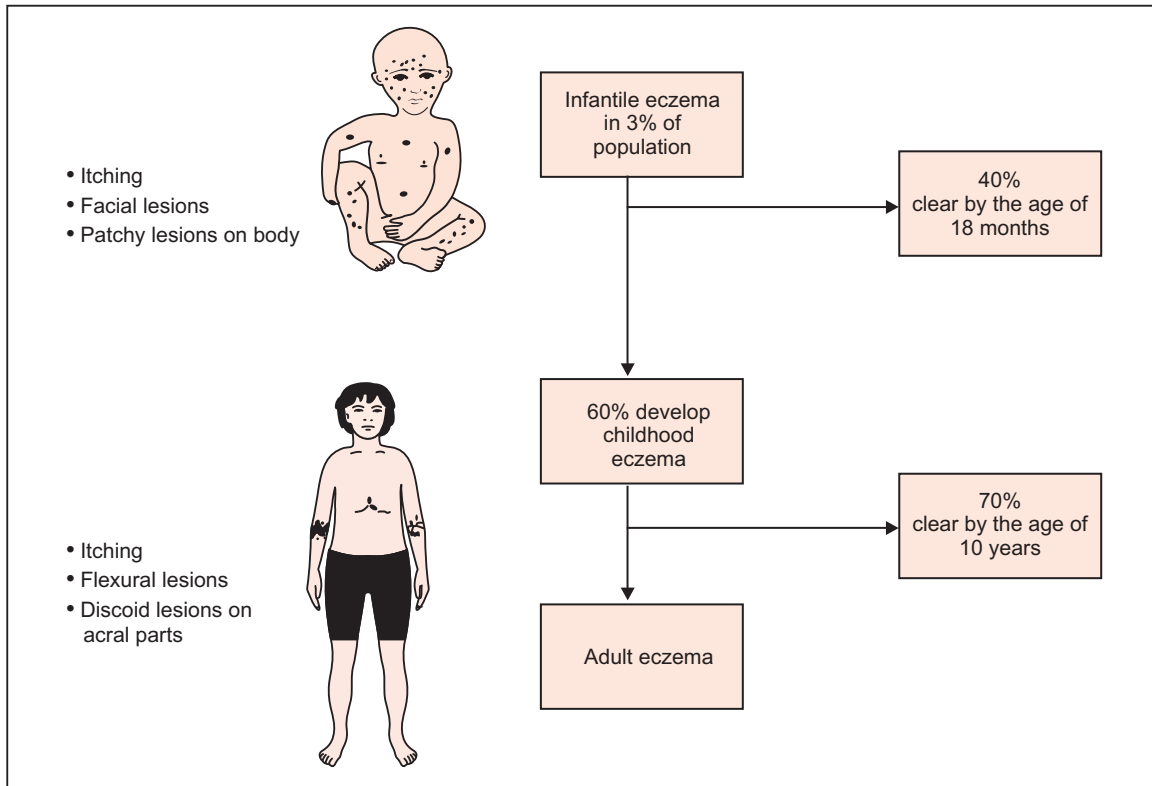


Fig. 6.13. Course of atopic dermatitis.

❖ For research purposes, diagnosis of AD is based on Hanifin and Rajka's criteria (Table 6.6).

Differential diagnosis

Depending on the age of patient, AD should be differentiated from several disorders:

a. Infantile seborrheic dermatitis

Infantile seborrheic dermatitis	Infantile AD
Onset: infants <3 months	Infants > 3 months
Symptoms: asymptomatic	Extremely itchy
Distribution: scalp, major flexures (axillae, groins)	Face, other parts of the body; may begin like seborrheic dermatitis
Associations:	Family or personal history of atopy

b. Scabies

Scabies in infants	Infantile AD
Morphology: papulovesicular lesions and burrows	Papulovesicular lesions
Distribution: characteristic: palms, soles, genitalia, face	Spare palms and soles
Associations: typical lesions in family members	Atopic diathesis in family

c. Airborne contact dermatitis (ABCD)

ABCD	AD in adults
Morphology: lichenified plaques	Lichenified plaques
Distribution: face (prominent involvement) and flexures	Flexures; face relatively spared
Associations:	Family history of atopy; dry skin; nipple eczema.

Treatment

General measures

- ❖ Explain the disease, its chronicity and course.
- ❖ Reassuring parents (who usually need more!!) and child.

What should be avoided?

- ❖ **Avoid scratching:** Itching may be reduced by giving antihistamines (*vide infra*)
- ❖ **Avoid triggers:** which precipitate itching:
 - **Irritants:** Like woolen and synthetic clothes. And chemicals (occupational, recreational). Avoid environments which trigger sweating.
 - **Excessive degreasing of skin:** By using mild soaps or cleansers.
 - **House dust mite avoidance:** Often measures

to reduce contact with house dust mites¹⁶ may help patients.

❖ **Dietary restrictions:**

- Role of avoiding dietary items like milk and eggs in controlling itching in AD is controversial.
- Some evidence to support hypothesis that breast feeding of children at risk of developing atopy may decrease chance of these children developing AD.
- Conflicting evidence to support hypothesis that pregnant mothers should avoid milk, eggs and other allergens to reduce incidence of atopic disorders in a child.

❖ **Vaccinations:**

- *Routine vaccinations:* Can be given during the quiescent phase of the disease.
- *Children suspected of allergy:* Should not be inoculated against measles, influenza and yellow fever.

❖ **Cosmetics:**

- Moisturizers used should not contain fragrances which are potent sensitizers.
- Avoid alcohol based cosmetics *e.g.*, astringents.

Topical therapy

The aim of the topical therapy is:

- ❖ Hydration of skin.
- ❖ Reduction of itching (and so scratching).
- ❖ Protection from environmental factors.
- ❖ Suppression of inflammation.
- ❖ Reduction/prevention of secondary infection.

Moisturizers

- ❖ Emollients form cornerstone of therapy **but only after hydration of skin.**
- ❖ Emollients alleviate itching and in mild cases may suffice without any additional therapy.
- ❖ There are two methods of using emollients:
 - Can be applied directly to skin after soaking baths (for at least 20 minutes). Occlusive or hydrophilic emollients so applied retain moisture and give symptomatic relief.
 - Or can be added to bath.

Topical steroids

- ❖ Used sometimes in combination with antibiotics for localized exudative lesions (flares). In extensive cases, it is best to dilute topical steroid with an emollient.
- ❖ Start with a lower potency steroid and increase the potency if there is failure to respond.
- ❖ Potent fluorinated steroids should be avoided on the face, genitalia and intertriginous areas.
- ❖ In lichenified lesions, steroids combined with keratolytic agents, like salicylic acid with benefit. In infected lesions, steroids combined with topical antibiotics¹⁷.

Topical calcineurin inhibitors (TCI)

Topical immunomodulators like pimecrolimus (1% cream) and tacrolimus (0.03% and 0.1% ointment) modify the cytokine response of cells and are useful in mild–moderate AD because of:

- ❖ Their steroid sparing action.
- ❖ Minimal local side effects¹⁸ (no atrophy and telangiectasia *cf.*, steroids)
- ❖ Rapid reduction in itching.

Systemic therapy

Systemic therapy is used in patients with extensive AD **but should always be combined with topical therapy.**

Systemic antibiotics

Systemic antibiotics are used in patients with:

- ❖ Extensive infected lesions.
- ❖ Even without frank secondary infection, proliferation of bacterial pathogens may exacerbate eczema. So the empirical use of systemic antibiotics in some cases with extensive dermatitis.

Systemic steroids

With availability of potent topical steroids and TCIs, the use of systemic corticosteroids has reduced substantially.

Antihistaminics

- ❖ Especially the sedating ones are used regularly to overcome the itching and are of great value in those in whom the sleep is interrupted.

16. **Reduction of contact with house dust mites:** by using barriers on mattresses, thorough and regular vacuuming of rooms, avoiding use of carpets, use of antimite sprays.

17. **Topical antibiotics:** topical steroids frequently empirically combined with antibiotics even in absence of frank infection, as it is believed that presence of bacterial antigens may be sustaining the eczema.

18. **Side effects of TCIs:** both tacrolimus and pimecrolimus are safe with the only important side effect being mild local burning.

- ❖ However, of late, role of antihistaminics in AD is being debated but only very few dermatologists would be radical enough not to use them.

Newer therapies

- ❖ **Phototherapy:** In stubborn extensive disease, narrow band UVB or PUVA¹⁹ is useful.
- ❖ **Immunosuppressives:** In recalcitrant extensive disease, immunosuppressive therapy given for disease control and steroid sparing effect:
 - Cyclosporine.
 - Azathioprine.
 - Mycophenolate mofetil.

Seborrheic Dermatitis

Synopsis

Etiology: Overgrowth of yeast, *Malassezia furfur* may play an important role.

Age: Adults; infrequently seen in infants, but not in children.

Morphology: Follicular papules with greasy scales. Several other variants—eczematous, petaloid, flexural pattern.

Sites: Scalp, eyebrows/eyelashes (squamous blepharitis), nasolabial folds, retroauricular region, presternal and interscapular regions and flexures. Sites involved in isolation or in combination.

Treatment: Topical and systemic antifungal agents along with topical antibiotics/corticosteroids.

Etiology

- ❖ **Microbial etiology:** Overgrowth of yeast, *Malassezia furfur* may play a part in the development of seborrheic dermatitis.
- ❖ **Genetic predisposition:** Is suggested because the disease runs in families.
- ❖ **Immunodeficiency:** Because of its manifestation in HIV positive patients.

Epidemiology

- ❖ **Prevalence:** Fairly common, if all patients with mild dandruff (**pityriasis capitis**) are included (10–20% of general population). Incidence of seborrheic dermatitis in HIV-positive patients is much higher.
- ❖ **Age:** Most common in adults. Infrequently seen in infants.
- ❖ **Gender:** More common in males.

Clinical Features

Patterns

Infantile seborrheic dermatitis

- ❖ Asymptomatic.
- ❖ Begins as cradle cap, usually at birth (Fig. 6.14A).
- ❖ May involve other seborrheic area (Fig. 6.14B).
- ❖ Self-limiting.

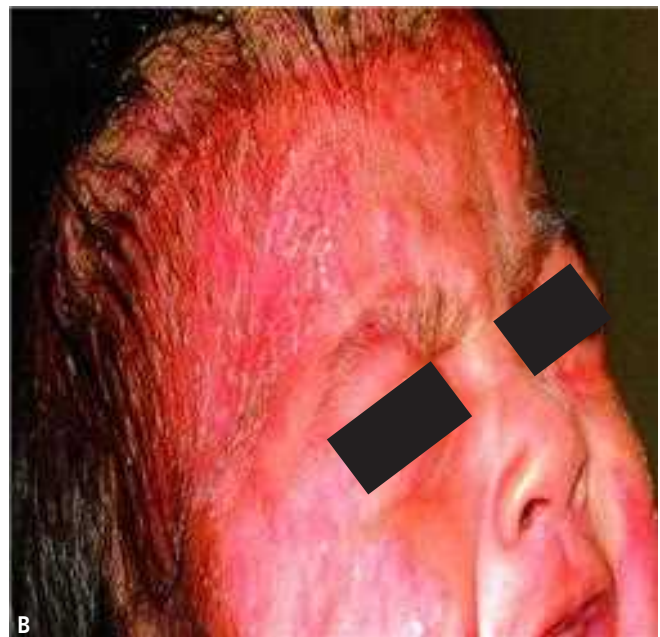

Fig. 6.14. Infantile seborrheic dermatitis: A: begins as cradle cap, usually at birth. B: may involve other seborrheic area.

19. **PUVA:** not to be used in children.

Scalp (Fig. 6.15A)

- ❖ Dandruff usually earliest and only manifestation of seborrheic dermatitis in most.
- ❖ Some patients develop perifollicular redness and scaling initially localized, then diffuse.
- ❖ Associated retroauricular erythema and scaling; sometimes crusted fissures develop (Fig. 6.15B).

Face

- ❖ **Morphology:** Erythema and scaling, occur, usually in association with involvement of the scalp. May be triggered by stress and photoexposure.

❖ **Distribution:** Characteristically involves medial part of eyebrows, glabella and nasolabial folds (Fig. 6.15C).

❖ **Associations:** Usually associated with scalp involvement. **Squamous blepharitis** common. Manifests as erythema, scaling and yellow crusts on lid margin. Also associated with **otitis externa**.

Trunk

Several patterns of seborrheic dermatitis seen on trunk:

❖ **Petaloid pattern:**

- Commoner variant.

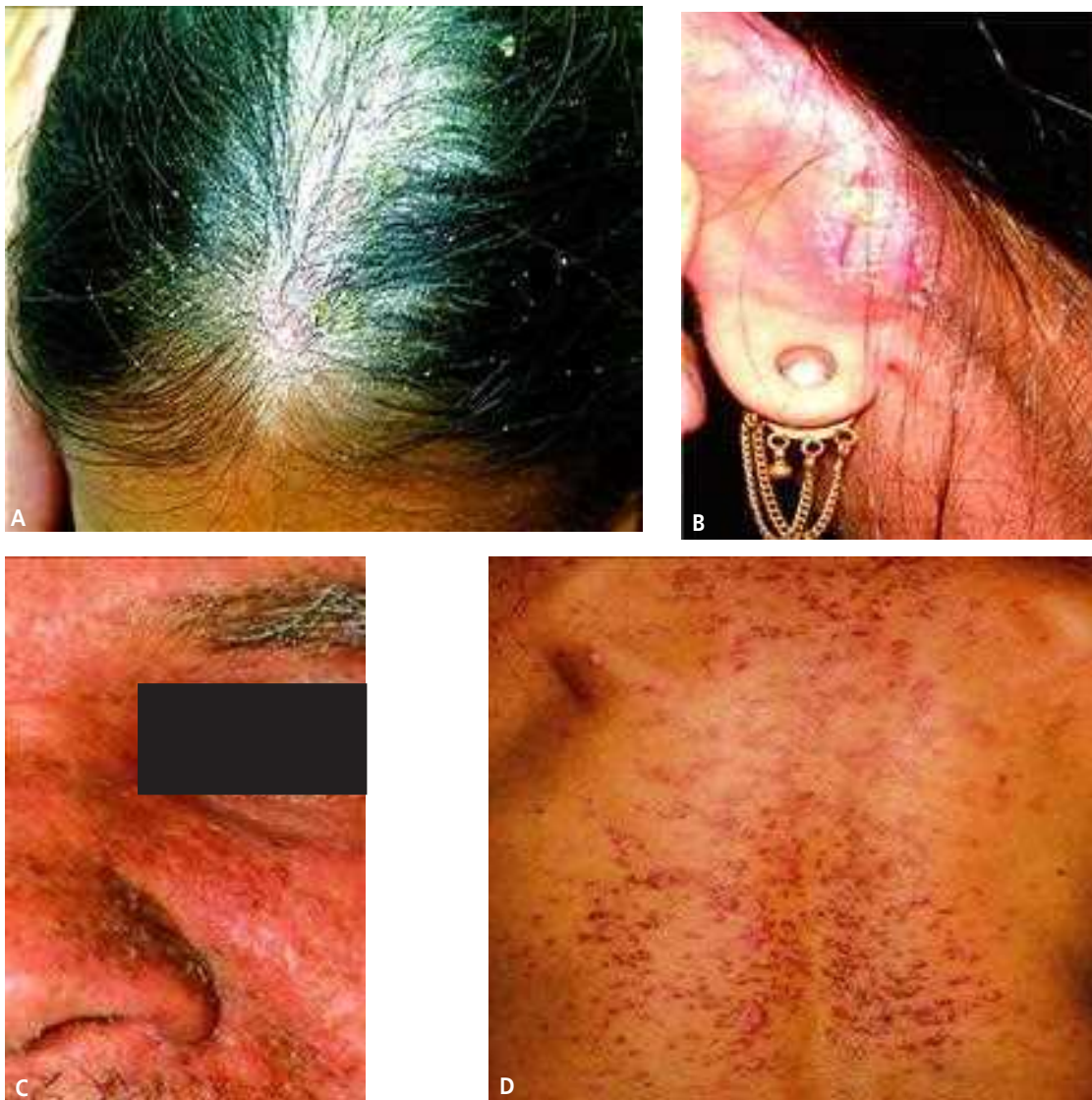

Fig. 6.15. Seborrheic dermatitis: A: scalp shows greasy scales not spilling on to forehead. B: retroauricular erythema and scaling with crusted fissures. C: nasolabial and eyebrow scaling. D: petaloid variant: erythematous annular plaques in interscapular region.

- **Morphology:** Nonexudative, scaly annular and circinate lesions with follicular papules surmounted with greasy scales (Fig. 6.15D).
- **Distribution:** In presternal and interscapular region.

❖ **Pityriasisform pattern:**

- Rarer.
- **Morphology:** Extensive erythematous eruption.
- **Distribution:** Trunk and neck up to the hair margin.

❖ **Seborrheic folliculitis:**

- **Morphology:** Extensive erythematous follicular papules surmounted with pustules.
- **Distribution:** Trunk.

❖ **Flexures:**

- **Morphology:** Intertrigo with diffuse, sharply marginated erythema and greasy scaling. Crusted fissures develop in the folds. Secondary infection and frank eczematization common.
- **Distribution:** Axillae, groins, submammary area, umbilicus, genitals and natal cleft.

AIDS and seborrheic dermatitis

- ❖ Severe seborrheic dermatitis occurs in patients with AIDS.
- ❖ Recurrent, severe and often recalcitrant to treat.

Sites of predilection

- ❖ Scalp, face (nasolabial folds, eyebrows and eyelashes), retroauricular area, presternal and interscapular regions and the major flexures (axillae, groins, inframammary region, umbilicus and natal cleft). This distribution of seborrheic dermatitis is very characteristic (Fig. 6.16) and is called **seborrheic distribution**²⁰.
- ❖ Lesions restricted to one to two sites depending on pattern. Or may be generalized.

Complications

- ❖ Superadded bacterial infection (in the scalp).
- ❖ Candidal infections (in the flexures).

Course

The disease runs a chronic course with relapses and remissions.

Investigations

- ❖ Usually, no investigations are needed.

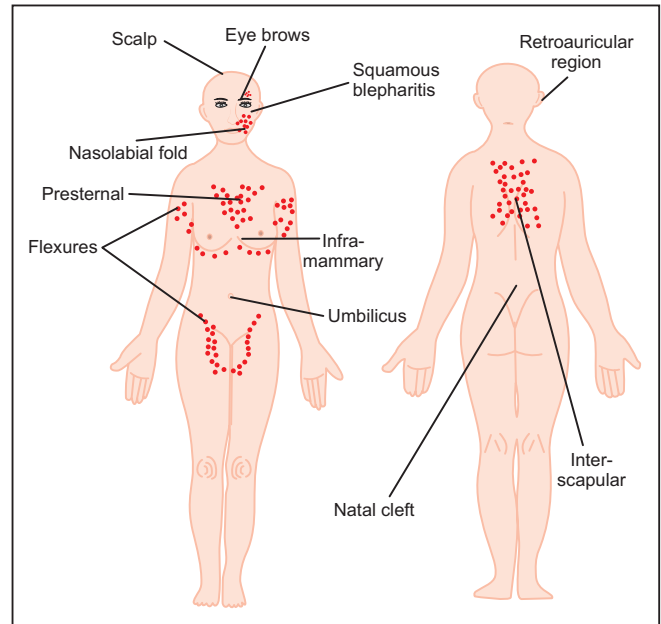


Fig. 6.16. Distribution of lesions of seborrheic dermatitis: lesions predominantly in hairy areas.

- ❖ Rule out HIV infection in patients with seborrheic dermatitis which is extensive, severe, recurrent and recalcitrant to treatment.

Diagnosis

Points for diagnosis

Diagnosis is based on:

- ❖ **Morphology:** Folliculocentric papules surmounted with typical yellow, greasy scales.
- ❖ **Typical distribution:** Seborrheic distribution²⁰.

Differential diagnosis

The diagnosis is easy in typical cases, but seborrheic dermatitis needs to be differentiated from:

a. Psoriasis

Psoriasis	SD
Definition: well-defined	Less defined
Induration: indurated plaques	Not indurated
Erythema: marked	Less
Scales: silvery	Greasy, yellow
Distribution: scalp (may spill onto forehead) elbows, knees, and lower back. Facial lesions less common	Scalp (does not spill), facial involvement (common; nasolabial folds, retroauricular region), presternal and interscapular region, axillae, and groins.

20. **Seborrheic distribution:** seen in seborrheic dermatitis, pemphigus foliaceus and less common skin diseases like Darier's disease and Langerhan's cell histiocytosis.

b. Candidal intertrigo

This needs to be differentiated from flexural variant of seborrheic dermatitis.

Treatment

Therapy suppresses disease activity and recurrences are generally the rule, once the treatment is stopped. Treatment depends on:

- ❖ Site of disease.
- ❖ Extent of disease.
- ❖ Severity.

Topical therapy

Topical treatment is the first line of therapy in localized lesions.

Topical antifungals

- ❖ **Basis of use:** Thought to be caused by *M. furfur*.
- ❖ **Agents used:** Topical ketoconazole, selenium sulfide, and ciclopirox.
- ❖ **Formulations used:** For scalp, as a lotion or incorporated into a shampoo. For flexures and for exudative lesions, combined with mild topical steroids, in cream formulation.

Topical steroids

- ❖ **Indications:**
 - Combined with antifungal agents in flexural lesions and exudative lesions.
 - Combined with salicylic acid in recalcitrant lesions of scalp.
- ❖ **Formulations used:** For scalp, as a lotion. For other areas, in cream formulation.

Others

- ❖ **Topical immunomodulators:** Like tacrolimus and pimecrolimus.
- ❖ Topical metronidazole, 2% sulfur, 2% salicylic acid, and lithium have been used.

Systemic therapy

- ❖ **Indications:** In extensive lesions and in HIV-positive patients.
- ❖ **Agents used:** Antibiotics, antifungal agents (fluconazole or itraconazole). Also low-dose oral retinoids.

Contact Dermatitis (CD)

Contact dermatitis is reaction of skin to **contactants** and is of two types:

- ❖ Irritant CD
- ❖ Allergic CD

Irritant Contact Dermatitis**Synopsis**

Etiology: Occupational/recreational exposure.

Morphology: Acute (with strong irritants) or chronic (with weak irritants) dermatitis.

Sites: Hands/forearms

Treatment: Absolute or relative withdrawal of exposure to irritant. Topical corticosteroids for acute stage. To prevent and minimize exposure.

Etiology**Agents**

Irritant dermatitis is most frequently caused by occupational exposure, either as an industrial contact or as a household contact (Table 6.7).

Table 6.7. Agents causing irritant dermatitis

Water
Detergents
Solvents
Abrasive dusts
Alkalis
Cutting oils

Predisposing factors**❖ Patient factors:**

- **Dry skin:** is more susceptible to irritant dermatitis.
- **Atopic individuals:** are more susceptible.
- **Site:** skin of face, scrotum and back of the hands is more susceptible while skin of palms and soles is resistant.

❖ Environmental factors:

- **Occupations:** people working in certain occupations (e.g., hair dressers) are more likely to develop to irritant dermatitis.
- **Protective measures:** measures like using gloves reduces contact irritant dermatitis.

Pathogenesis

- ❖ Chemical directly injures skin without involving the immunologic pathway.
- ❖ Therefore, develops in all patients who are exposed to sufficient concentration of the chemical and can develop with the first exposure itself.

Clinical features

Irritant contact dermatitis has a spectrum of clinical features, ranging from a little dryness,

redness or chapping to various types of eczematous dermatitis to an acute caustic burn. As a rule, depending on the strength of irritant, patients presents with:

- ❖ **Acute exudative lesions:** If the exposure is to a strong irritant (Fig. 6.17).
- ❖ **Dry dermatitic lesions:** If there is chronic repeated exposure to a weak irritant. A prototype of this type of dermatitis is **house wives dermatitis** or **cumulative insult dermatitis** (Fig. 6.18).

Diagnosis

It is important to differentiate irritant contact dermatitis from allergic contact dermatitis. Though this may occasionally be possible clinically, the confirmation comes by patch testing.

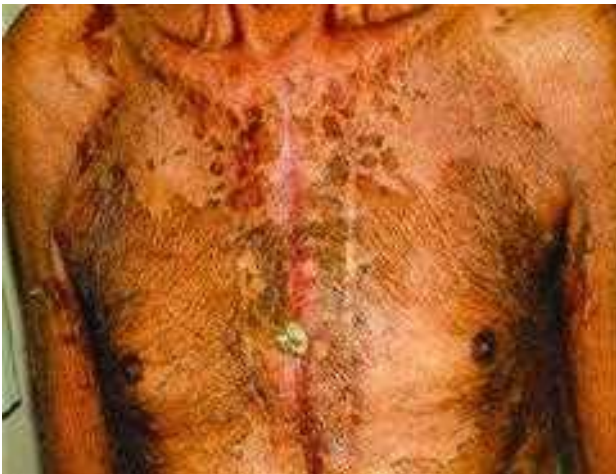

Fig. 6.17. Irritant contact dermatitis: due to overzealous postoperative care.

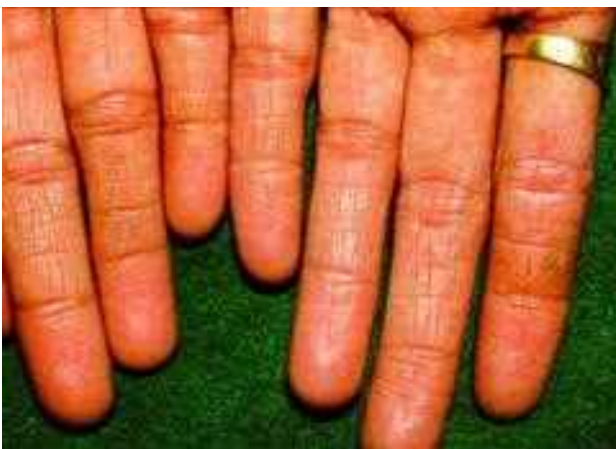

Fig. 6.18. Cumulative insult injury: chronic irritant dermatitis seen in housewives due to repeated exposure to harsh chemicals.

Management

- ❖ **Prophylaxis:** Avoid/reduce contact:
 - *Complete avoidance:* ideal, e.g., changing occupation.
 - *Relative avoidance:* if absolute avoidance is not possible, reduce exposure by using protective gloves and clothing. Barrier creams, however, are of little help.
- ❖ **Treatment**
 - *Acute dermatitis:* moderately potent steroids hasten recovery.
 - *Chronic dermatitis:*
 - Topical steroid ointments.
 - Emollients.

Allergic Contact Dermatitis (ACD)

Synopsis

Etiology: Common allergens are plants (parthenium), metals (nickel), cosmetics (hair dyes and fragrances), medicines and rubber.

Clinical features: Could manifest either as acute or chronic dermatitis. Distribution characteristic, depending on the antigen.

Investigations: Patch test confirmatory.

Treatment: Removal of antigen essential to prevent recurrences. *Localized disease:* treat symptomatically with topical steroids. *Widespread disease:* systemic steroids; other immunosuppressive drugs.

Etiology

Several antigens can cause ACD (Table 6.8).

Pathogenesis

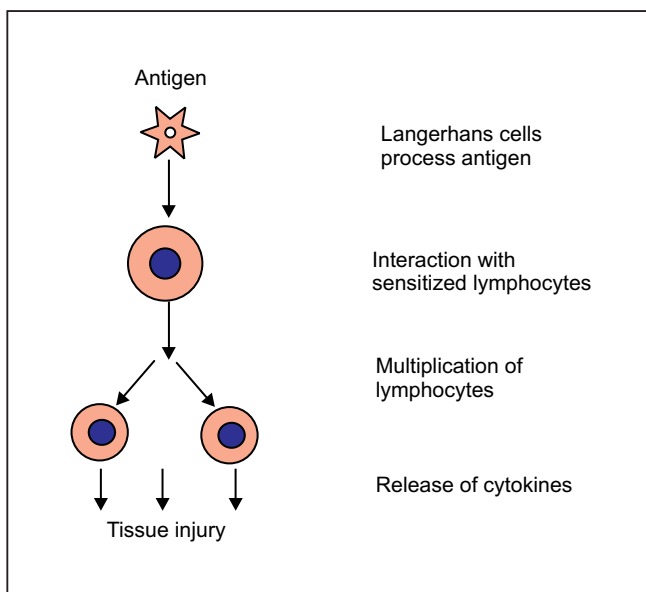
- ❖ Develops due to involvement of immunological pathway, being a type IV (delayed hypersensitivity) reaction to exogenous contact antigens (Fig. 6.19). Therefore, it develops only in a small proportion of patients exposed to the antigen.
- ❖ It does not develop on the first exposure (unless there is cross reaction with a closely related chemical) because the patient's immunological pathway has not been sensitized. Sensitization occurs
 - When antigen is presented to the skin, it is processed by antigen presenting cells (Langerhans cells).
 - Processed antigen then interacts with sensitized lymphocytes which are stimulated to multiply and to secrete cytokines.
 - Cytokines then cause skin injury.

Table 6.8. Agents causing contact dermatitis

	Agent	Source	Distribution
Plants	Parthenium (Fig. 6.20A)	Airborne exposure	Face (supraorbital crease, retroauricular area) neck, cubital and popliteal fossa (Fig. 6.20B).
Metals	Nickel Chromates	Costume jewellery, clips Chromium plating Cement Leather	Ear lobes, wrists, (Fig. 6.20C), interscapular area Patchy; on face, forearms Feet
Cosmetics	Paraphenylenediamine Fragrances Formaldehyde Parabens	Hair dyes Cosmetics, perfumes, shampoos Preservatives in cosmetics Preservatives in cosmetics	Face and ears (more) and scalp (less) Face and neck; also sites of application Sites of application Sites of application
Medicines	Neomycin Benzocaine	Topical antibiotics Local anesthetics	Sites of application Sites of application
Rubber	Mercapto mix (additives) Thiuram mix (additives)	Shoe soles and uppers Rubber gloves	Feet (Fig. 6.20D) Hands

Factors influencing development of ACD

- ❖ Sensitivity is specific to a chemical. However, patients may cross react with closely related chemicals.
- ❖ Repeated contact increases chance of developing hypersensitivity, though ACD may begin after the first contact.
- ❖ All sites are “allergic” though lesions manifest only in areas of direct contact (basis of doing patch tests on the back).
- ❖ Allergy is permanent and desensitization is not consistently possible.

**Fig. 6.19.** Pathogenesis of allergic contact dermatitis.**Clinical features****Morphology**

Patient presents either with acute or chronic eczema (Fig. 6.20):

❖ **Acute eczema:**

- Progresses from erythema to edema to papulo-vesiculation.
- However, in some area like eyelids and genitalia, it may manifest as edema.

❖ **Chronic eczema:** Manifests as itchy lichenified plaques.**Location of lesions (Table 6.8, Figs. 6.20 and 6.21)**

Depends on the allergen causing the eczema.

Investigations

- ❖ In-depth questioning to evaluate domestic, occupational, and recreational contact.
- ❖ Distribution of the skin lesions often gives a clue to (nature of) allergen (Figs. 6.20 and 6.21).
- ❖ **Patch testing (Fig. 6.22):** Patch testing confirms cause of allergic dermatitis.

Treatment**Prevention**

- ❖ Contact with the antigen should be completely avoided (*cf.*, irritant dermatitis in which even a decreased exposure to the irritant helps). Sometimes difficult as some common and potent allergens like nickel are ubiquitous.
- ❖ Best also to avoid antigens which are likely to cross react.

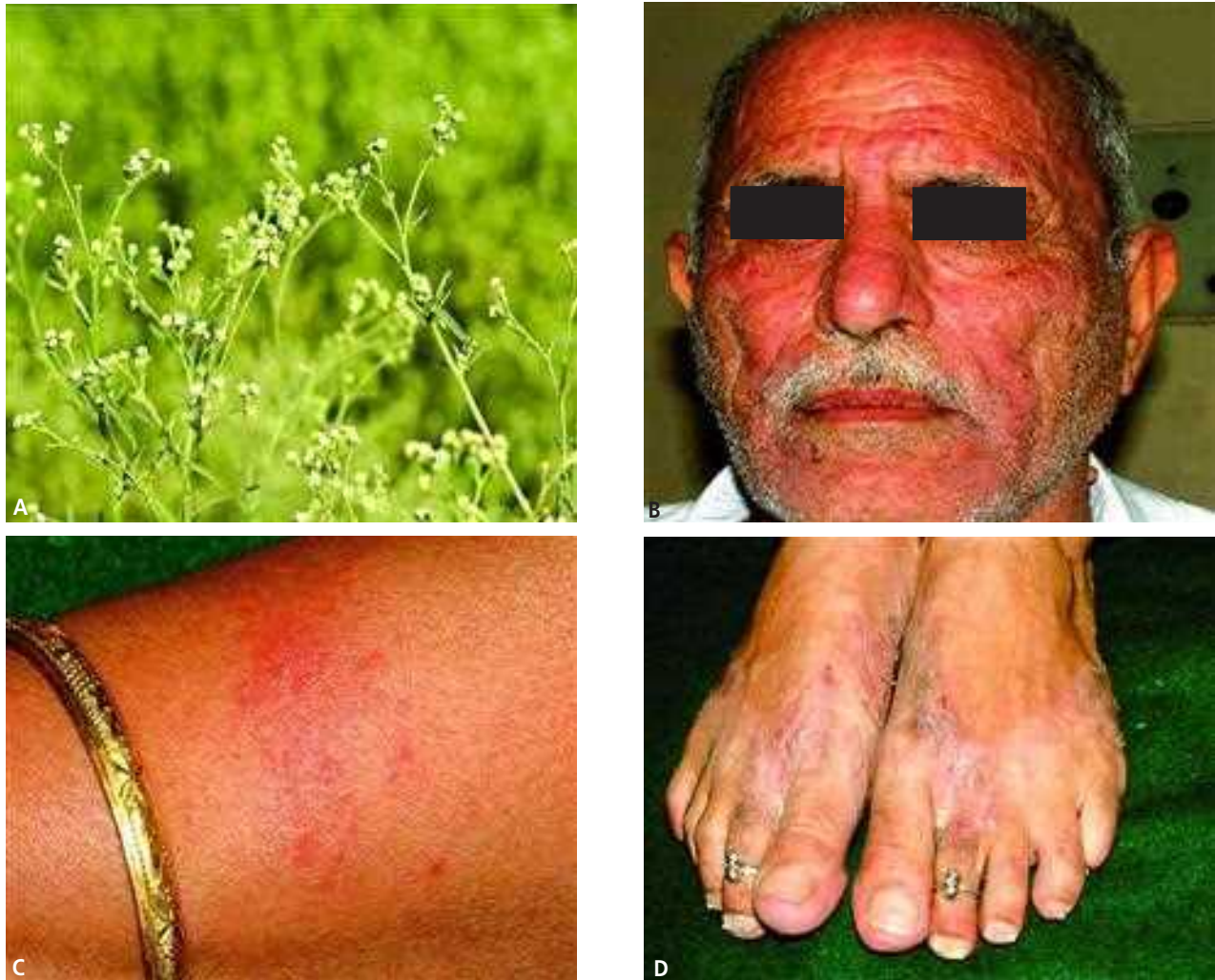


Fig. 6.20. Allergic contact dermatitis: A: *Parthenium hysterophorus*, common cause of airborne contact dermatitis. B: airborne contact dermatitis to parthenium, which manifests as dermatitis on face including supraorbital crease, nasolabial folds, retroauricular area and cubital fossae. C: to metals manifesting as dermatitis to costume jewellery. D: to rubber, manifesting as dermatitis to footwear.

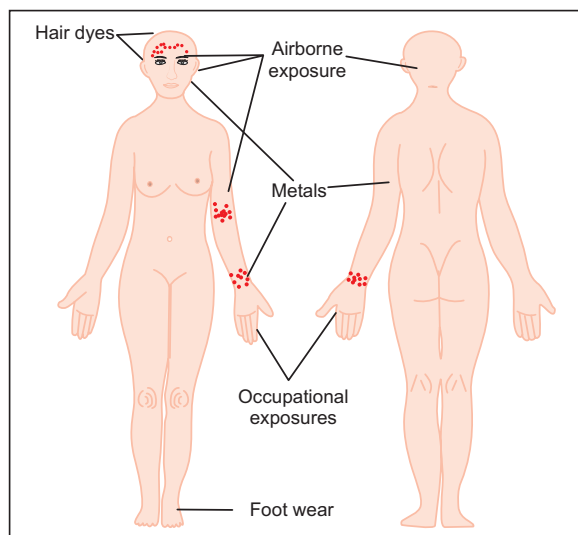


Fig. 6.21. Distribution of lesions of contact dermatitis.



Fig. 6.22. Patch testing: confirms the cause of the allergic dermatitis. Patches 11, 13, 14, 16, 17 and 19 are positive.

Therapy

- ❖ **Localized lesions:** Topical steroids in cream base effective in most cases. Use ointments (sometimes with salicylic acid) in lichenified lesions.
- ❖ **Extensive lesions:**
 - May require treatment with a short course of oral steroids.
 - In airborne contact dermatitis, azathioprine (50–100 mg, daily adult dose) may be effective.
- ❖ Always combine with antihistamines.

Miscellaneous Eczemas**Nummular Eczema**

Synonym: Discoid eczema.

Synopsis

Etiology: Unknown. Rule out atopic dermatitis.

Age/gender: Middle aged men.

Morphology: Multiple, itchy, coin-shaped exudative plaques.

Sites: Usually acral areas.

Treatment: Combine topical steroids with antibiotics. For extensive lesions, PUVA sol can be tried.

Etiology

- ❖ Unknown in most cases.
- ❖ Frequent association with atopy.
- ❖ Reaction to bacterial antigens has been suspected:
 - Because of positive yield of *Staphylococcus* on culture.
 - Better response of lesions to steroid–antibiotic combination than to either used alone.

Clinical features**Age/Gender**

Middle-aged males, most frequently affected.

Morphology

Extremely itchy, multiple, sharply demarcated coin-shaped vesicular or crusted plaques (Fig. 6.23). The lesions run a chronic course.

Sites of predilection

Extremities, specially distal parts

Treatment

- ❖ **Symptomatic:** Antihistamines.

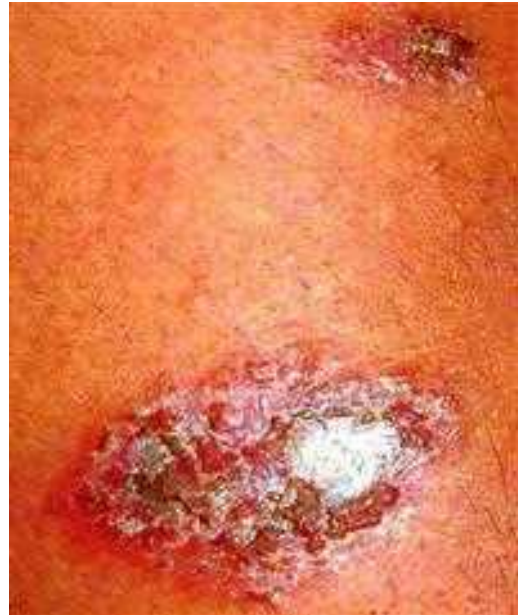

Fig. 6.23. Discoid eczema: coin shaped, vesicular, crusted plaques.

- ❖ **Localized lesions:** Combination of topical steroid antibiotics gives best response.
- ❖ **Extensive lesions:** PUVA sol/narrow band UVB.

Pompholyx**Synopsis**

Etiology: Unknown.

Clinical features: Recurrent episodes of deep-seated, bland vesicles on palms and soles.

Treatment: Soothing soaks followed by topical steroids.

Etiology

- ❖ Unknown
- ❖ Some patients with pompholyx develop a vesicular palmoplantar eruption on ingestion of minute amounts of nickel.

Clinical features

- ❖ Summer aggravation.
- ❖ Recurrent episodes of deep seated, bland looking (without inflammation) vesicles (sometimes blisters).
- ❖ Each episode of disease is self-limiting, but fresh crops of vesicles develop successively, leaving patient symptomatic for long periods.
- ❖ Lesions occasionally get secondarily infected.
- ❖ Fingers (Fig. 6.24) and palms and sometimes soles.

Diagnosis

Points for diagnosis

The diagnosis of pompholyx is based on:

- ❖ Recurrent episodes.
- ❖ Presence of bland vesicles.
- ❖ Presence on fingers, palms, soles.

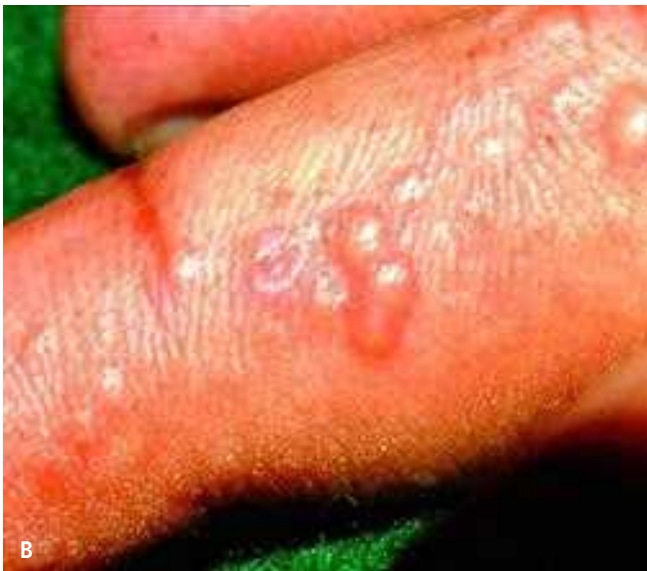
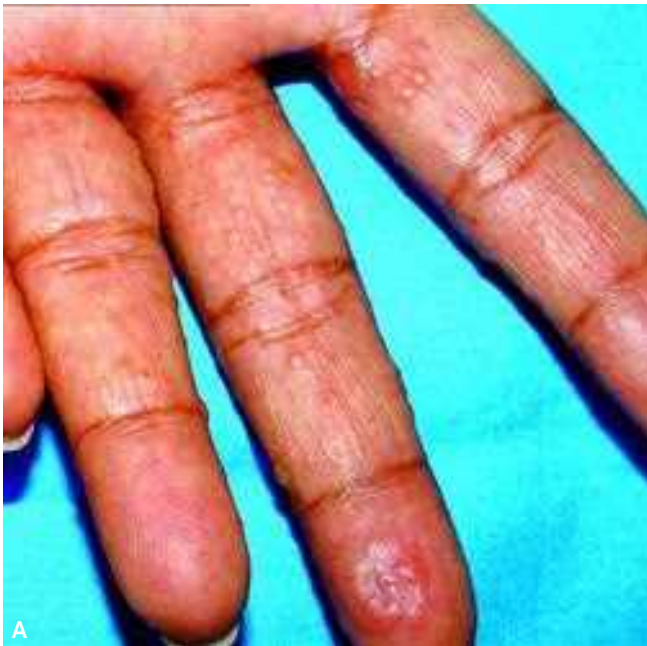
Fig. 6.24. Pompholyx: deep-seated bland vesicles on the ventral and lateral aspects of fingers.

Differential diagnosis

Pompholyx should be distinguished from:

a. *Ide eruption:*

Vesicular eruption of palms (and soles), which is triggered by an intensely inflammatory dermatoses:

- ❖ Inflammatory tinea capitis or tinea pedis²¹.
- ❖ Infectious eczematoid dermatitis.
- ❖ Acute contact dermatitis.

Treatment

- ❖ Saline soaks followed by topical steroids.
- ❖ Appropriate antibiotics, if bacterial infection present.

Lichen Simplex Chronicus

Synonym: Neurodermatitis.

Synopsis

Etiology: Due to excessive scratching; may be associated with atopy.

Morphology: Single (occasionally several), itchy, lichenified plaque(s).

Sites: Nape of neck, legs and anogenital region.

Treatment: Topical steroid combined with keratolytics used under occlusion.

Etiology

- ❖ Scratching, in predisposed individuals.
- ❖ Rule out atopy, as these patients prone to developing lichenification.

Clinical features (Fig. 6.25)

- ❖ **Symptoms:** Extremely itchy.
- ❖ **Morphology:** Single (sometimes multiple) lichenified plaque(s). Lesion may reappear after treatment is stopped.
- ❖ **Associations:** Many patients have an atopic diathesis.
- ❖ **Distribution:** Nape of neck in women, legs in men and anogenital area in both.

Treatment

- ❖ The itch-scratch cycle needs to be broken and this is achieved by use of topical steroid and keratolytic agents, often **under occlusion**²².
- ❖ Antihistamines may help.

21. **Tinea pedis:** fungal infection of feet.

22. **Occlusion:** apply topical steroid, place a piece of polythene (cutting a piece of a polythene carry bag to size of lesion) and bandage lesion. Occlusive dressings increase the penetration of the active ingredient due to hydration and maceration.

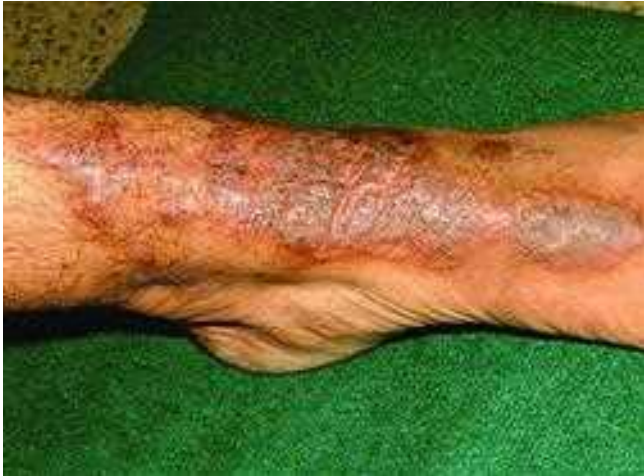

Fig. 6.25. Lichen simplex chronicus: thickened, hyperpigmented plaques with increased skin markings.

Stasis Eczema

Synonym: Gravitational eczema.

Synopsis

Etiology: Varicose veins associated with venous hypertension.

Morphology: Eczema with stippled and confluent hyperpigmentation.

Associations: Pedal edema, varicosities and sclerosis.

Site: Lower third of leg especially around medial malleolus.

Treatment: Foot end elevation. Mild topical steroid. Combine with antibiotics, if infection present. Surgery for varicose veins.

Etiology

Secondary to venous hypertension, may be a late sequel of previous deep vein thrombosis.

Clinical features

Morphology

- ❖ Begins usually with pedal edema (initially pitting, later nonpitting) especially around the ankles.
- ❖ Over period of time, brownish pigmentation (due to hemosiderin from the breakdown of extravasated red cells) appears; the pigmentation is punctate initially, but later becomes confluent.
- ❖ Long-standing disease presents with ivory white sclerotic plaques with dilated capillary loops (combination of findings is called **lipodermatosclerosis**).
- ❖ Minor trauma results in ulcers which are painless, slow to heal and extend peripherally often

attaining a large size. Floor has red granulation tissue and the depth of the ulcer is variable. With rest and proper management, the ulcer heals by epithelialization from the edge as also by appearance of scattered, small gray islands of skin over floor.

Site

- ❖ Stasis dermatitis occurs over the lower third of leg (Fig. 6.26).
- ❖ Venous ulceration occurs typically over medial malleolus.

Complications

- ❖ **Ulceration.**
- ❖ **Bacterial infection:** Resulting in cellulitis, lymphangitis, and septicemia.
- ❖ **Allergic contact dermatitis:** To topical agents (*e.g.*, lanolin, neomycin and parabens) should be suspected, if there is an acute exacerbation of the dermatitis after application of topical medications.
- ❖ **Deformity:** Prolonged disease with recurrent ulceration may give one leg a look of an “inverted champagne bottle”.
- ❖ **Malignant change:** Though rare, should be ruled out if the edge is rolled or the base hyperplastic.

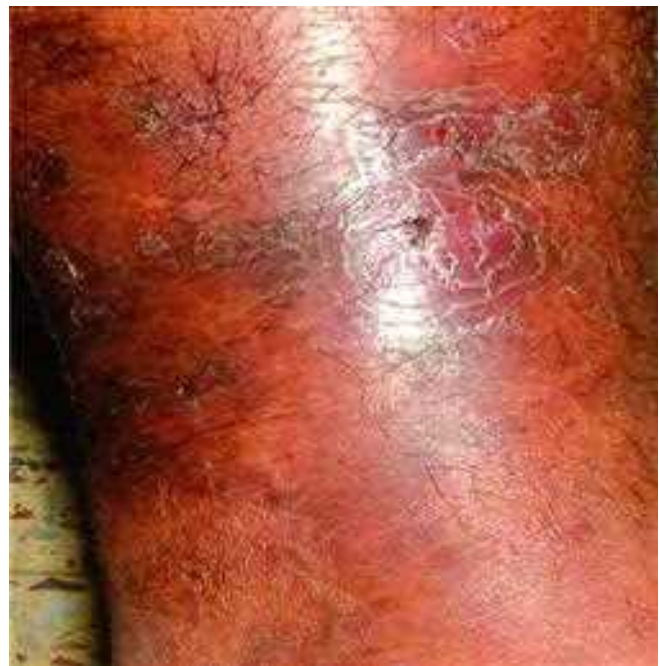

Fig. 6.26. Stasis dermatitis: hyperpigmented skin with sclerosis and dermatitis.

Treatment

- ❖ **Reduce edema:** By elevation of the foot-end of bed and use of pressure bandage.
- ❖ **Treatment of varicose veins:** Surgically, though stasis eczema is likely to persist despite surgery.
- ❖ **Topical steroids:** Use low-potency topical steroids to relieve irritation but avoid potent steroids.
- ❖ **Treatment of complications:**
 - *Secondary infection:* antibiotics
 - *Contact sensitivity:* confirm with patch test. Withdrawal of culprit.

Asteatotic Eczema

Etiology

Associated with:

- ❖ Old age.
- ❖ Dry skin.
- ❖ Low humidity, as seen in winters.
- ❖ Hypothyroidism.
- ❖ Underlying malignancy.

Clinical features

- ❖ Extremely itchy.
- ❖ Skin is generally dry, with fine reticulate red, superficial fissures, an appearance similar to crazy pavement (Fig. 6.27).
- ❖ Shins, lower back.

Treatment

Acute phase

Mild steroid in an ointment base topically.

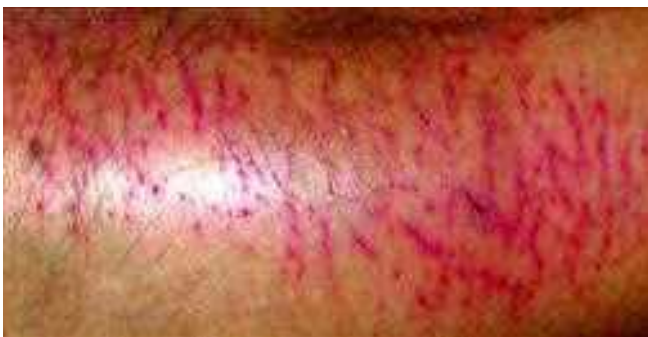

Fig. 6.27. Asteatotic eczema: dry skin with fine reticulate red superficial fissures.

Prevention

- ❖ Regular use of an emollient preferably after a soaking bath.
- ❖ Substituting an aqueous cream for soap usually prevents recurrences.

Diaper Dermatitis

Etiology

- ❖ Irritant dermatitis due to prolonged contact with feces and urine²³.
- ❖ Aggravated by use of water-proof plastic diapers.

Clinical features

- ❖ Moist, glazed erythema which affects area of skin in contact with diapers. The depth of skin folds typically spared (Fig. 6.28).
- ❖ Superadded infection with candida is frequent.

Treatment

Prevention

- ❖ Keep area clean and dry.
- ❖ Use of superabsorbent napkins reduces incidence of diaper dermatitis, provided they are changed appropriately. If ordinary cotton diapers are used, they should not be occluded with plastic covers and should be properly washed.
- ❖ Protective creams used to prevent recurrences.

Acute phase

- ❖ Mild dermatitis responds to moisturizers.
- ❖ Mild steroid (never stronger) with an antifungal agent is useful.

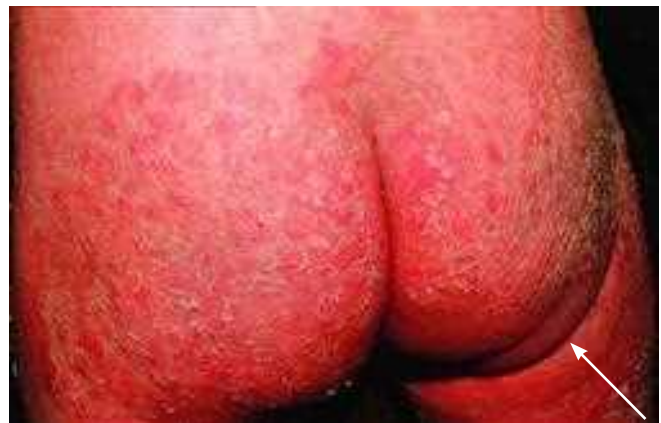

Fig. 6.28. Diaper dermatitis: moist glazed erythema of area in contact with diapers. Note sparing of depth of flexures.

23. **Urine:** ammonia is produced by action of urea splitting microbes on urine.

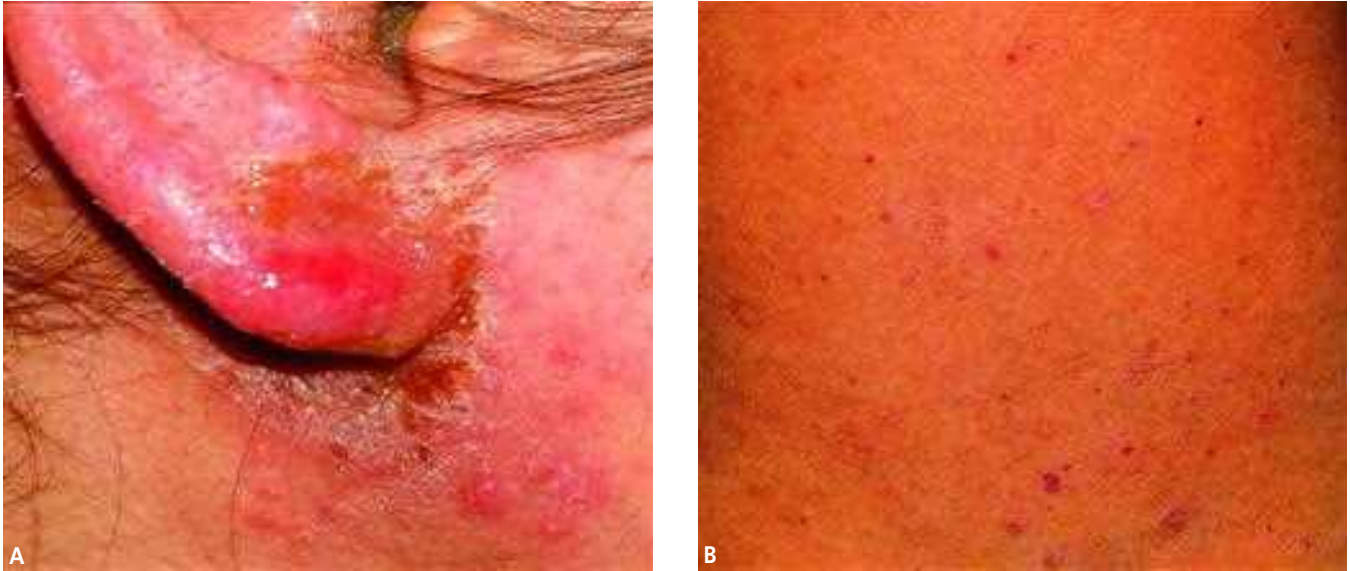

Fig. 6.29. Infectious eczematoid dermatitis: A: exudative lesion around a focus of infection. B: this patient also had an ide eruption.

Infectious Eczematoid Dermatitis (IED)

A controversial entity.

Etiology

Bacterial or viral infection is the primary event and eczema is the secondary event *e.g.*, eczematization around a lesion of pyoderma, infected wound or molluscum contagiosum.

Clinical features

- ❖ Seen predominantly around discharging wounds and ulcers.
- ❖ Presents as an area of advancing erythema

sometimes with microvesicles at the edge, around an infected lesion (Fig. 6.29).

- ❖ May be complicated by an **ide eruption**.

Treatment

Localized lesions

Topical steroid-antibiotic combination.

Severe infection or in presence of ide eruption

- ❖ Oral antibiotics with topical steroid-antibiotic combination.
- ❖ Short course of oral steroids, if severe ide eruption.

Chapter Outline

Disorders of Sebaceous Glands

Structure and function[○]

Acne vulgaris[•]

Rosacea[•]

Disorders of Eccrine Sweat Glands

Structure and function[○]

Hyperhidrosis[○]

Hypohidrosis and anhidrosis[○]

Miliaria[•]

Disorders of Apocrine Glands

Structure and function[○]

Hidradenitis suppurativa[○]

Disorders of Hair

Structure and function[○]

Definitions[•]

Alopecia areata[•]

Androgenetic alopecia[•]

Miscellaneous causes of alopecia[○]

Hirsutism[•]

Hypertrichosis

Disorders of Nails

Structure[○]

Disorders of nails[•]

Skin contains several appendages:

- ❖ Sebaceous glands.
- ❖ Sweat glands.
 - Eccrine glands.
 - Apocrine glands.
- ❖ Hair.
- ❖ Nails.

Disorders of Sebaceous Glands

Structure and Function

Anatomy

- ❖ Sebaceous glands are closely associated with hair follicles, lying at an obtuse angle between the follicle and epidermis.
- ❖ It consists of:
 - *Multilobed gland*: made up of lipid containing cells, which secrete sebum as a holocrine¹ secretion.
 - *Duct*: that opens into pilary canal.
- ❖ Sebum is discharged into the upper part of hair follicle (Fig. 7.1).
- ❖ Sebum is made up of a complex mixture of triglycerides, fatty wax esters, squalene, and cholesterol.

Activity

- ❖ Though sebaceous gland activity is controlled by androgens, it is not the level of circulating androgens which is important, but an enhanced end organ sensitivity.
- ❖ The glands contain an enzyme called **5 α -reductase**, which converts less potent testosterone into more potent

1. **Holocrine**: when whole cell is secreted into the lumen; this is in contrast to **apocrine** (when the cell decapitates) and **eccrine** (when no part of cell is lost) secretions.

[•]Should know

[○]Good to know

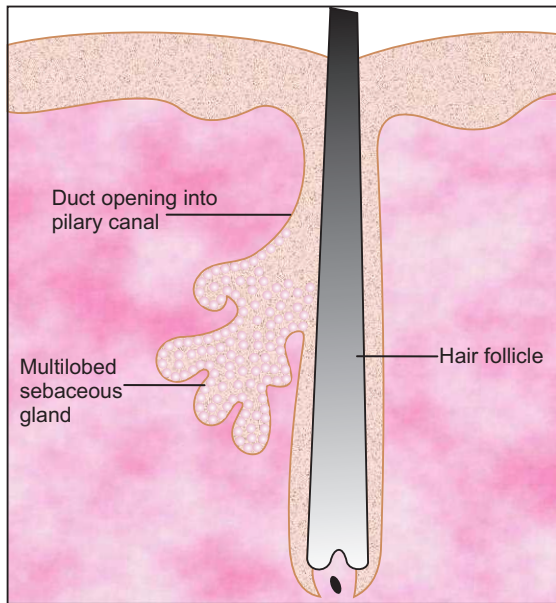


Fig. 7.1. Structure of sebaceous glands.

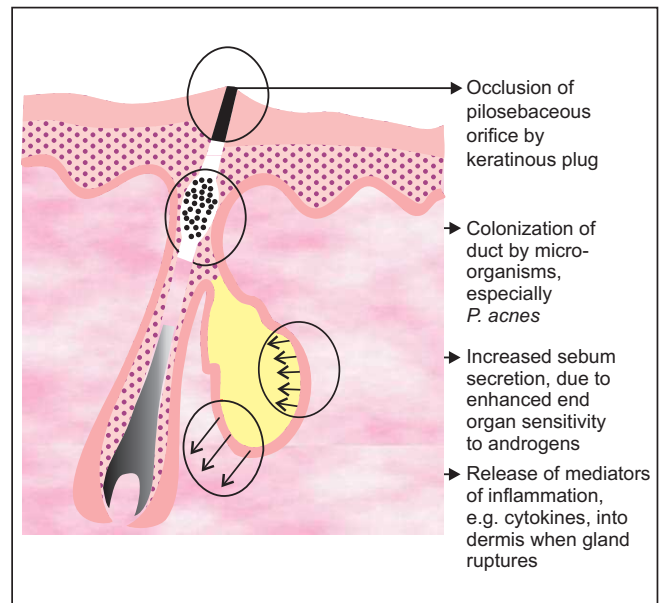


Fig. 7.2. Etiology of acne vulgaris.

dihydrotestosterone, which is directly responsible for sebaceous gland activity.

Acne Vulgaris

Synopsis

Etiology: Several factors incriminated. Increased sebum secretion (due to increased end organ sensitivity to androgens), follicular duct hypercornification, and increased colonization with *Propionibacterium acnes* and inflammation.

Onset: 12–14 years of age.

Morphology: Polymorphic eruption consisting of papules, pustules, nodules, cysts, and pathognomonic open and closed comedones on a background of oiliness. Heal with ice pick, box car, or hypertrophic scars.

Sites: Face, upper trunk, and deltoid region.

Variants: Acne conglobata, occupational acne, drug-induced acne, and acne after massage.

Treatment: Depends on type of predominant lesion and severity. In predominantly comedonic acne, comedolytic agents like retinoic acid (0.025–0.1%), adapalene (0.1%), and benzoyl peroxide (2.5–10%) are used while in more severe acne, systemic antibiotics like doxycycline and macrolides and in acne conglobata, isotretinoin is used.

Acne **vulgaris**² is a disorder of pilosebaceous complex which predominantly affects the peripubertal

population and clinically manifests as comedones (open/closed), papules, nodules, pustules, and cysts and heals with scars.

Pathogenesis

Although the basic cause of acne is unknown, several pathogenic mechanisms are incriminated (Fig. 7.2).

Occlusion of pilosebaceous orifice

- ❖ Pilosebaceous orifice in acne is occluded by a keratinous plug induced by:
 - Chemicals (present as ingredients of cosmetics).
 - Reduced levels of linoleic acid in sebum of acne patients.
- ❖ Results in retention of sebum, encouraging growth of microbes, triggering a vicious cycle.
- ❖ Distended follicle ruptures, releasing proinflammatory chemicals into the dermis, stimulating intense inflammation.
- ❖ Ductal epithelium also produces cytokines and an inflammatory cascade is triggered.

Increased sebum secretion

- ❖ Sebaceous gland activity is controlled by androgens.

2. **Vulgaris:** means common. The term is suffixed to many skin diseases, e.g., pemphigus vulgaris (the commonest type of pemphigus) to differentiate it from pemphigus foliaceus; lupus vulgaris (a type of tuberculosis) to differentiate it from lupus erythematosus and acne vulgaris to differentiate it from acne rosacea (now referred to as rosacea).

- ❖ Most patients with acne have normal levels of circulating androgens, but their sebaceous glands are unusually sensitive to androgens due to an **enhanced end organ sensitivity**.
- ❖ This is due to increased activity in sebaceous glands of an enzyme **5 α -reductase**, which converts testosterone to more potent 5 α -dihydrotestosterone, which binds to specific receptors in the sebaceous glands increasing sebum secretion.

Microbial colonization

- ❖ **Organisms implicated:**
 - *Propionibacterium spp.* especially *P. acnes*.
 - *Malassezia furfur*.
 - *Staph epidermidis*.
- ❖ **Role in pathogenesis:** These organisms:
 - Trigger a type IV inflammatory response.
 - Produce extracellular enzymes, which attract inflammatory cells.

Release of inflammatory mediators

- ❖ Distended follicle ruptures, releasing inflammatory chemicals into dermis, stimulating intense inflammation.
- ❖ Ductal epithelium also produces cytokines, triggering an inflammatory cascade.
- ❖ Microbes also produce extracellular enzymes, which attract inflammatory cells.

Factors Modifying Acne

Genetic predisposition

Acne vulgaris is familial, but the mode of inheritance has not been clearly elucidated:

- ❖ Patients with severe cystic acne often have a positive family history of acne of similar severity.
- ❖ Identical twins have greater concordance of severity of acne.

Diet

- ❖ Though for decades dermatologists believed that diet plays very little, if any role, in pathogenesis and aggravation of acne, some recent studies have incriminated a high glycemic diet.
- ❖ However, till further evidence is available, there is no need to restrict items of diet³ like nuts, oily foods, chocolates, and aerated drinks in patients with acne.

Cosmetics

- ❖ Acne is frequently seen in women who use oil-based cosmetics for long periods of time.
- ❖ Acne often follows **facial massage**⁴.

Menstrual cycle

About 70% of the female patients complain of premenstrual aggravation of acne, probably related to premenstrual edema of the pilosebaceous duct.

Psychological factors

Severe acne is related to increased anger and anxiety.

Epidemiology

- ❖ **Prevalence:** An extremely common disorder, it is believed at least mild acne affects almost all adolescents.
- ❖ **Age:** Age of onset of acne is 12–14 years, being earlier in females. In about 70% of subjects, the lesions subside in the third decade.
- ❖ **Gender:** Acne affects both sexes equally, but nodulocystic acne is almost 10 times more frequent in males.

Clinical Features

Morphology (Figs. 7.3–7.5)

- ❖ Most patients with severe acne have a greasy skin with patulous follicular openings (pores).
- ❖ Eruption is **polymorphic**, characterized by comedones, papules, pustules, nodules, and cysts, all seen in the same patient at the same time (Figs. 7.3A and B).
- ❖ **Comedones:**
 - Are pathognomonic lesions of acne vulgaris (Figs. 7.4 and 7.5).
 - Two main types of comedones recognized:
 - **Open comedones (black heads):** are due to plugging of the pilosebaceous orifice by keratin and sebum on the skin surface (Fig. 7.4A).
 - **Closed comedones (white heads):** are due to keratin and sebum accretions plugging the pilosebaceous ducts below the skin surface (Fig. 7.4B). Some closed comedones are deep seated (**submarine comedones**) and are best seen by stretching the skin.

3. **Diet:** some of these food stuffs may themselves not be healthy for other reasons.

4. **Facial massage:** a form of facial beauty treatment.

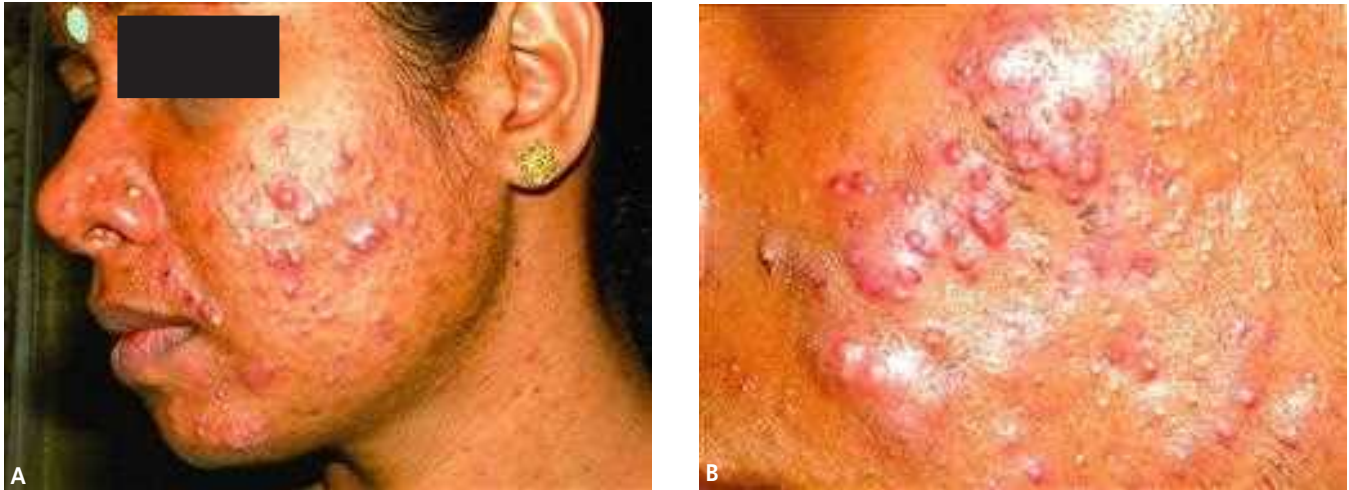

Fig. 7.3. Acne vulgaris: A: polymorphic eruption of comedones, papules, pustules, nodules, and cysts. B: close up.

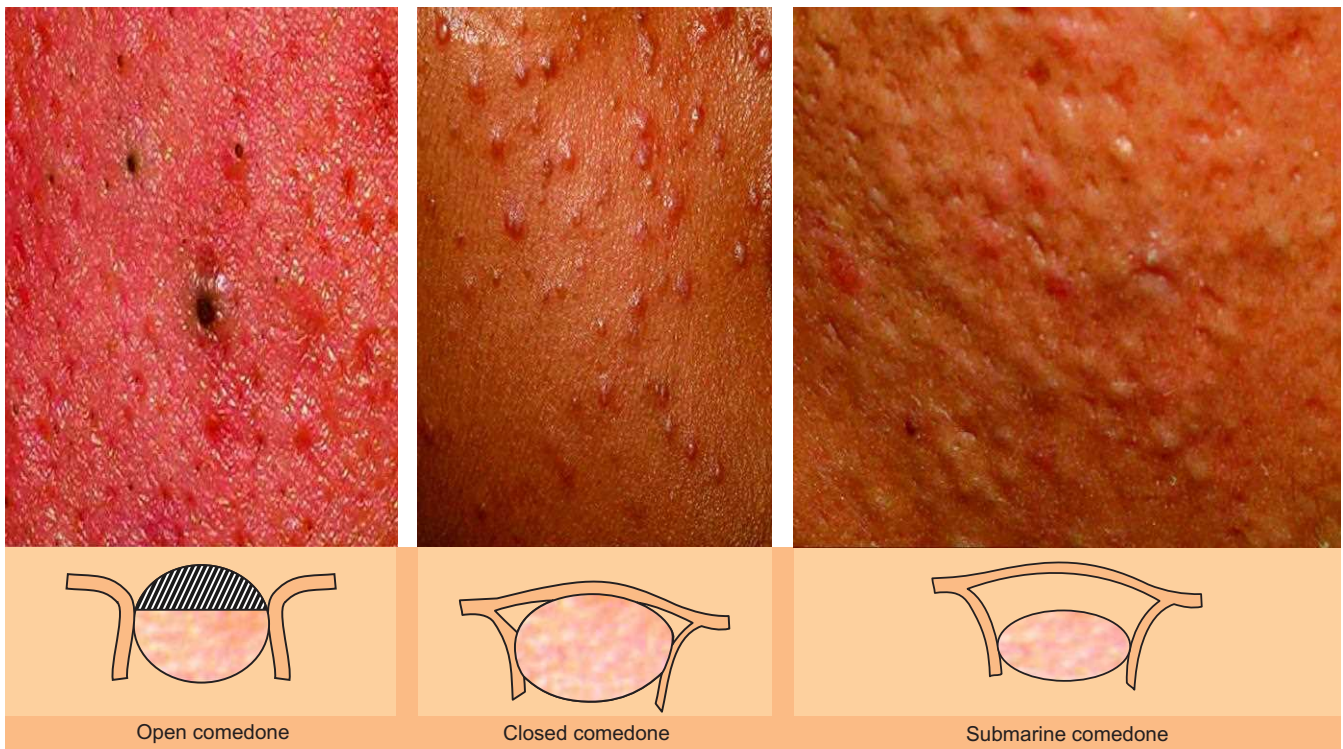


Fig. 7.4. Acne vulgaris: comedones. A: open comedones. B: closed comedones. C: submarine comedones.

(Fig. 7.4C). Submarine comedones respond poorly to medical treatment.

❖ **Scars:** Lesions of acne usually heal with scarring. Acne scars can be:

➤ **Depressed scars:**

- **Ice pick scars:** which are deep pits (Fig. 7.6A).
- **Box car scars:** which can be superficial or deep.

■ **Rolling scars.**

➤ **Hypertrophic and keloidal scars** (Fig. 7.6B).

Sites of predilection (Fig. 7.7)

- ❖ Lesions of acne vulgaris are seen predominantly on the face (forehead, cheeks, and chin), shoulders, upper chest, and back (Fig. 7.8).
- ❖ If acne-like lesions occur at unusual sites, suspect an acneiform eruption due to drugs. Or occupational acne.

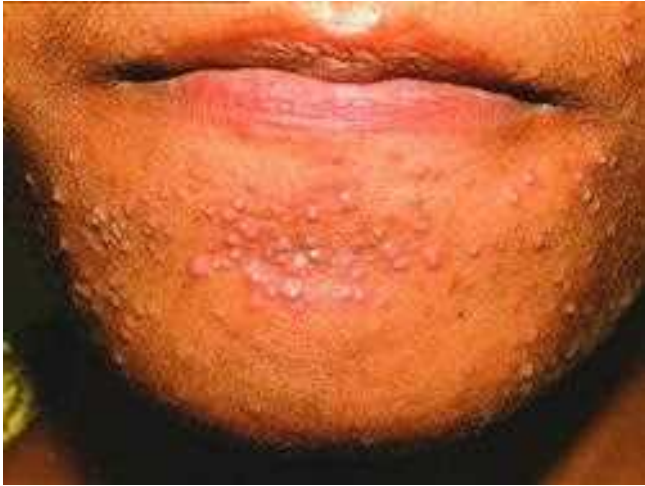


Fig. 7.5. Acne vulgaris: polymorphic eruption of comedones, papules, and pustules.

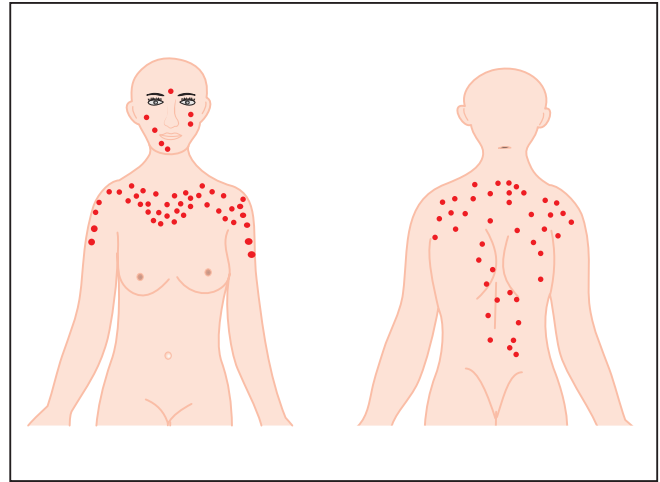


Fig. 7.7. Acne vulgaris: sites of predilection

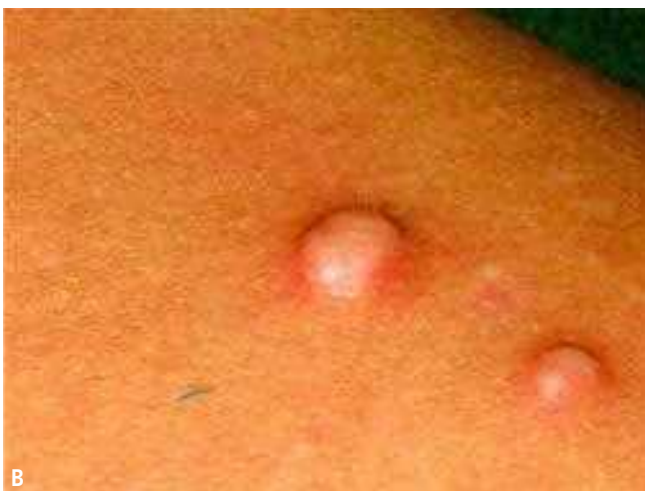
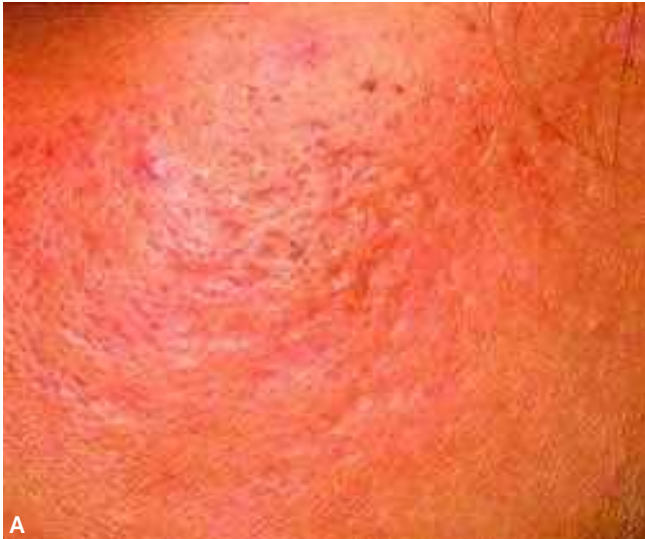
Fig. 7.6. Acne vulgaris: A: lesions heal with depressed scars. B: or with hypertrophic scars.

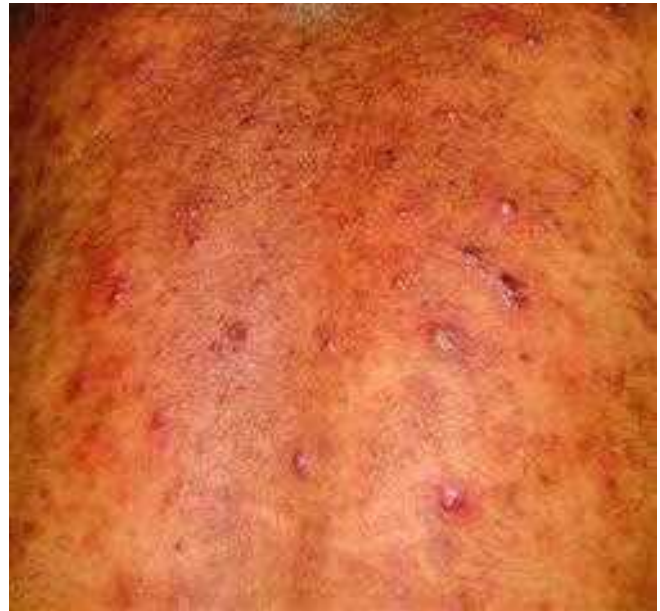

Fig. 7.8. Acne vulgaris on trunk: patient has both comedones and inflammatory lesions.

Associations

- ❖ **Seborrhea:** Greasiness of face and patulous follicular openings.
- ❖ **Features of hyperandrogenism:**
 - Like hirsutism, virilism, irregular periods, and weight gain may be present in some women.
 - Such patients need to be investigated for androgen secreting pathology like polycystic ovary syndrome.

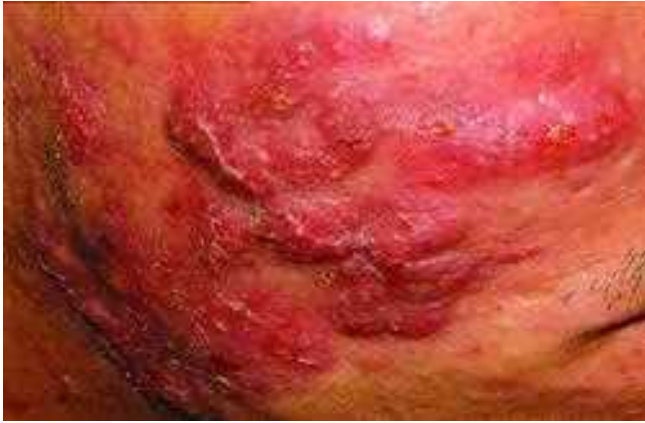

Fig. 7.9. Acne conglobata: interconnecting abscesses, cysts and sinuses. Note irregular bridges.

Variants

*Acne conglobata*⁵

- ❖ A severe form of acne, characterized by intercommunicating abscesses, cysts, and sinuses loaded with serosanguinous fluid or pus (Fig. 7.9).
- ❖ Comedones are typically **multiporous**⁶.
- ❖ Lesions take months to heal and on healing leave behind deep pitted or hypertrophic (sometimes keloidal) scars, joined by keloidal bridges.
- ❖ Lesions are not only severe but also more extensive and may be associated with **follicular occlusion syndrome**⁷.

Occupational acne

- ❖ Caused by exposure to industrial chemicals like tar, chlorinated hydrocarbons (when it is called **chloracne**), and cutting oils.
- ❖ Lesions are predominantly comedones (Fig. 7.10), though sometimes inflammatory cystic lesions may be present.
- ❖ Suspect occupational acne if:
 - Unusual sites of involvement, *e.g.*, forearms, legs, and retroauricular region.
 - Unusual age, *e.g.*, middle aged males.

Cosmetic acne

- ❖ Eruption frequently seen in women using cosmetics, especially oil-based ones.
- ❖ Almost always comedones.
- ❖ Lesions frequently on the chin.

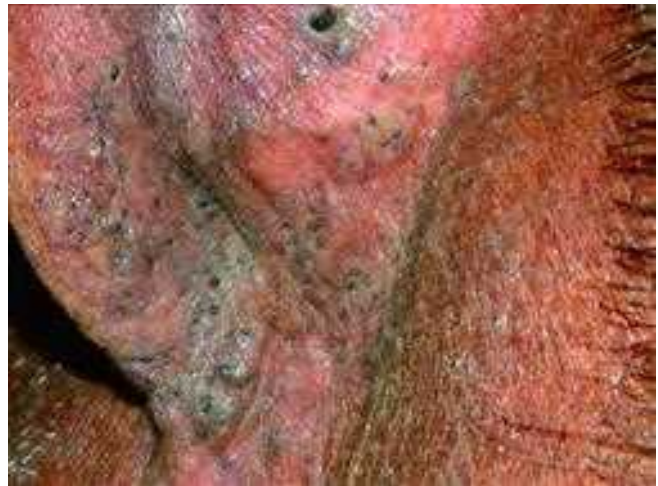

Fig. 7.10. Chloracne: predominantly comedones at unusual sites (retroauricular, in this patient) in a middle aged male (unusual age).

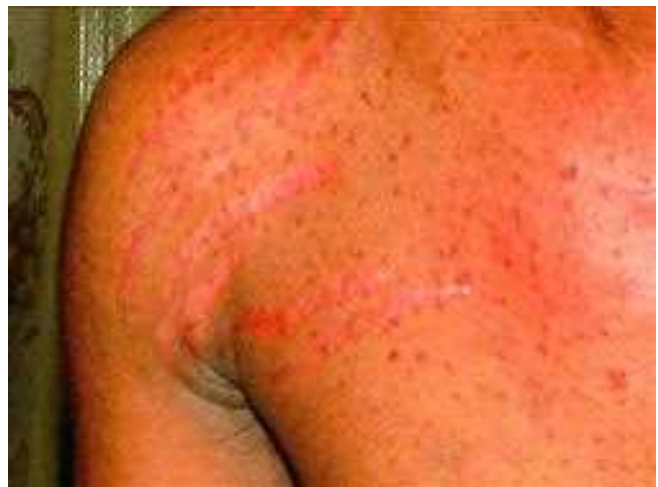

Fig. 7.11. Steroid acne: monomorphic lesions consisting of papules. Patient also has steroid-induced striae.

Drug-induced acne

- ❖ Steroids, androgens, anabolic steroids, oral contraceptives, antitubercular drugs, iodides, bromides, and anticonvulsants can cause an acneiform eruption.
- ❖ Lesions are monomorphic (Fig. 7.11), consisting of papules and sometimes pustules. Comedones and scarring are unusual, especially when induced by steroids.
- ❖ Trunk especially back; face may be involved.

5. **Conglobate:** means a "collection of balls".

6. **Multiporous:** having several openings.

7. **Follicular occlusion syndrome:** combination of acne conglobata, hidradenitis suppuritiva, dissecting folliculitis, and pilonidal sinus.

Infantile acne

- ❖ Due to presence of maternal hormones in the child.
- ❖ More common in males.
- ❖ May present at birth and may last for up to three years.
- ❖ Lesions similar to those of adolescent acne.

Late onset acne

- ❖ Acne with onset after 25 years of age.
- ❖ Predominantly women.
- ❖ Presents as deep seated, persistent lesions on lower half of face.
- ❖ Exclude underlying androgen secreting pathology, especially polycystic ovarian syndrome.

Acne excoriee

- ❖ Seen in young girls, who obsessively pick their otherwise mild acne.
- ❖ Results in discrete excoriations on the face, while comedones and papules (primary lesions of acne) are few and far in between (Fig. 7.12).

Acne fulminans

- ❖ Acute onset.
- ❖ Presents as crusted, ulcerated lesions (Fig. 7.13).
- ❖ Associated with fever, myalgia, and arthralgia.

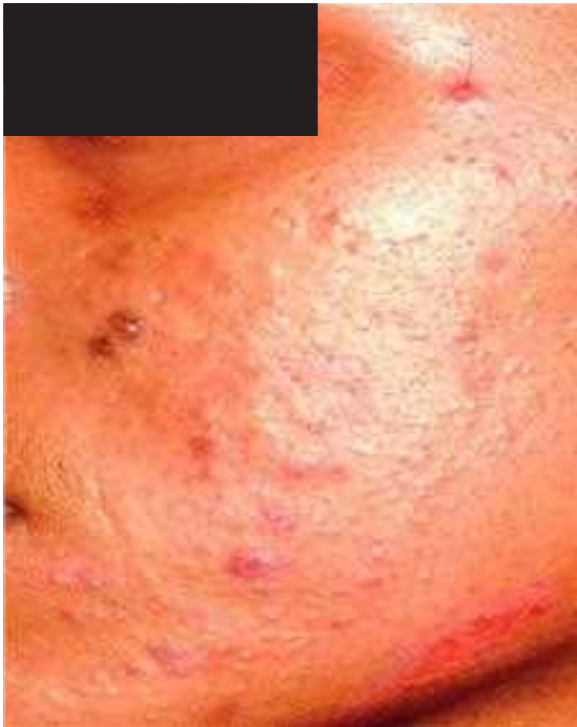

Fig. 7.12. Acne excoriee: mainly excoriated lesions in a young girl. Note disproportionately few acne lesions.

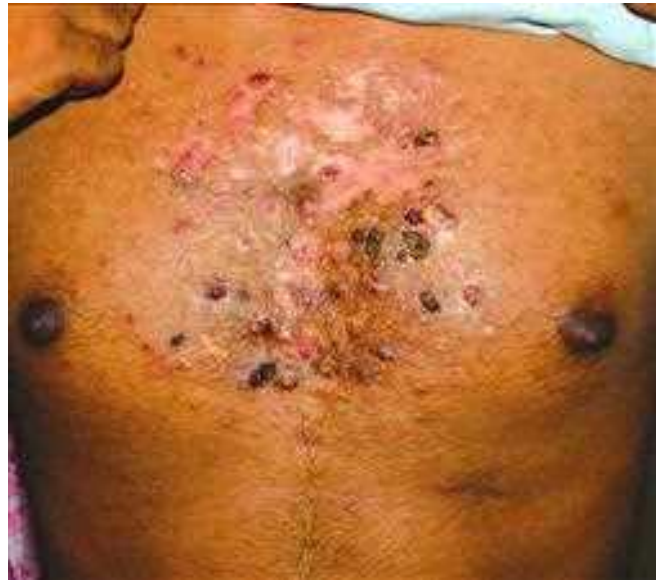

Fig. 7.13. Acne fulminans: crusted lesions in presternal area. Patient also had fever and myalgia.

Acne after facial massage

- ❖ Facial massage may be followed (3–6 weeks later) by an acneiform eruption in about 30% of patients.
- ❖ Indolent deep seated nodules with very few (or no) comedones (Fig. 7.14). Heal with hyperpigmentation after several weeks.
- ❖ Predominantly on cheeks, along the mandible. Less on chin.

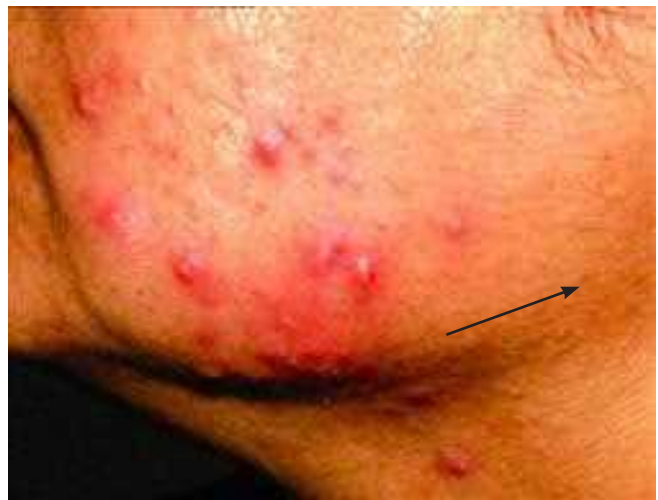

Fig. 7.14. Acneiform eruption after facial massage consists mainly of inflammatory lesions on cheeks along mandible. Note, location of lesions is along direction of massage movements.

Course

Seventy percent of patients are clear of their acne by the third decade (*i.e.*, in 30% of patients, the lesions persist into the fourth decade). Persistence of lesions into middle age is more common in females.

Investigations

- ❖ No investigations are required for routine management of acne vulgaris.
- ❖ In women, who have late-onset acne associated with hirsutism, virilization, and menstrual irregularities, investigations to exclude an androgen secreting pathology (*e.g.*, polycystic ovaries) need to be done.

Diagnosis

Points for diagnosis

Diagnosis of acne vulgaris is based on:

- ❖ Adolescent patient.
- ❖ Background skin of face is greasy with prominent follicular openings.
- ❖ Polymorphic eruption of papules, pustules, nodules, and cysts; lesions heal with typical scarring.
- ❖ Presence of comedones (essential for diagnosis).
- ❖ Typical distribution: face, shoulders, upper part of trunk and chest.

Differential diagnosis

Acne vulgaris needs to be differentiated from:

a. Rosacea

Rosacea	Acne vulgaris
Age: older (middle aged) women	Adolescent patients
Distribution: lesions on convexities of face (cheeks, nose, and forehead)	Face, upper trunk, and deltoid region
Morphology: comedones absent. Papules, nodules, and pustules present	Comedones typical. So also papules, nodules, pustules, cysts, and scars
Associations: background erythema and telangiectasia prominent	Background skin greasy with patulous follicular openings

b. Folliculitis

Folliculitis	Acne vulgaris
Morphology: pustules, papules or nodules	Polymorphic eruption; lesions not related to terminal hair
Comedones: absent	Present
Distribution: perifollicular, around terminal hair	Not related to terminal hair

Treatment (Fig. 7.15)

Factors which influence treatment

Treatment depends on several factors:

- ❖ **Severity of lesions:** Severity of acne is the most important guide to therapy. However, some patients with mild acne may be psychologi-

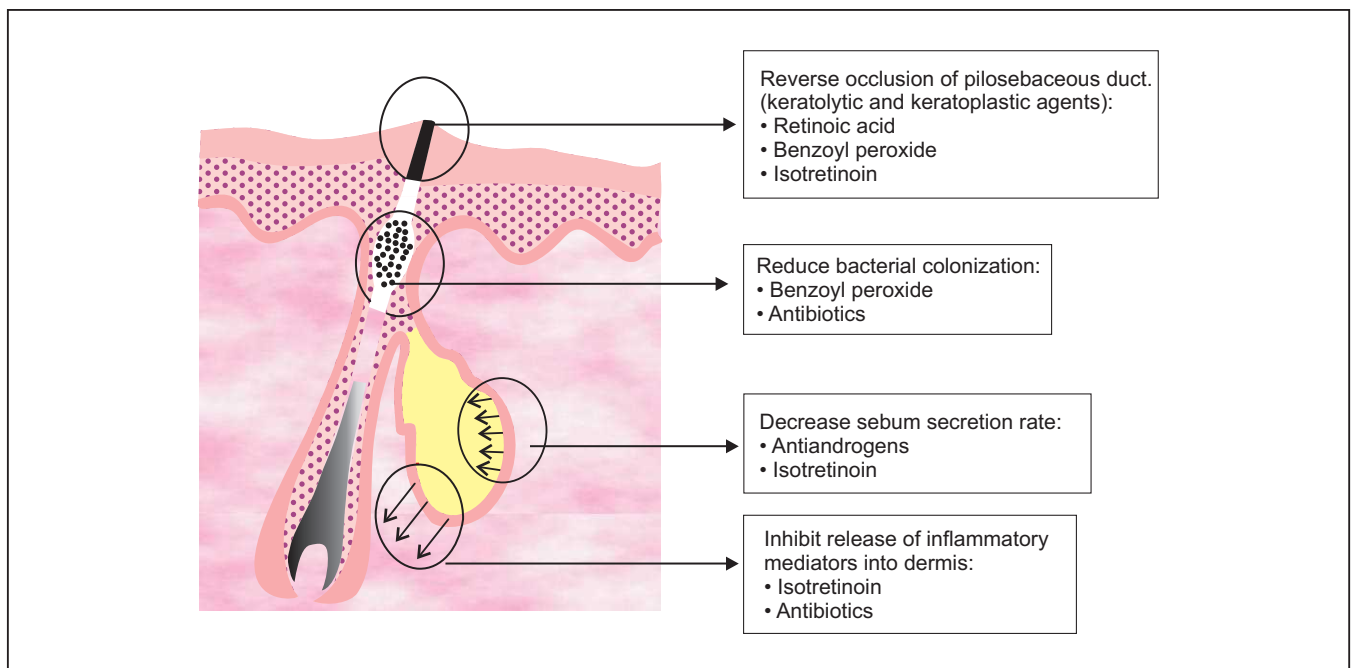


Fig. 7.15. Acne vulgaris treatment is multipronged, attacking the four mechanisms which lead to acne.

cally more disturbed than patients with severe acne and this may impact their **quality of life (QOL)**⁸, warranting aggressive therapy.

- ❖ **Aggravating factors:** Aggravating factors (drugs and facial massage) should be eliminated.
- ❖ **Age of patient:** Lesions in older patients are more resistant to treatment and such patients would warrant more aggressive treatment.
- ❖ **Underlying hormonal disturbance:** In female patients who have an underlying hormonal disturbance, or in those with late onset acne, antiandrogens are frequently used.

Treatment modalities available include:

- ❖ General measures.
- ❖ Topical therapy.
- ❖ Systemic therapy.
- ❖ Physical therapy.

General measures

Local hygiene

- ❖ Regular gentle cleansing (not overzealous) with soap and water should be encouraged.
- ❖ Application of oil-based cosmetics should be avoided as they may aggravate acne, but **water-based cosmetics**⁹ can be used.

Diet

Since diet plays only a doubtful role in the pathogenesis of acne, it is not necessary to restrict intake of fatty (oily) foods, nuts, aerated drinks, and chocolates. Some dermatologists have begun to restrict high glycemic diets.

Stress

- ❖ Acne induces stress and this needs to be handled. Some patients with mild acne may be more distressed than those with severe acne.
- ❖ Stress itself may induce acne.

Topical therapy

Retinoids

❖ **Preparations available:**

- **Drugs:** retinoic acid (RA), adapalene, isotretinoin, and tazarotene.
- **Available as:**
 - RA, 0.025%, 0.05%, 0.1%, cream and gel formulations. Newer formulations include

microsphere or polymer formulations which are less irritating. Also available in combination with topical clindamycin.

- Adapalene 0.1% cream is less irritating¹⁰.
- Other retinoids available include isotretinoin gel, 0.05% and tazarotene gel, 0.05% and 0.1%.

❖ **Indications:**

- *In active disease:* effective against both comedones and inflammatory acne. So, used as a stand-alone treatment in mild acne and as a combination in moderate and severe acne.
- *For maintenance:* reduces formation of **microcomedo**¹¹.

❖ **Mode of action:**

- Specially effective against comedones (both to prevent and treat) because it normalizes follicular keratinization by:
 - Increasing epidermal cell turnover.
 - Increasing dehiscence of stratum corneum.
- Also effective against inflammatory lesions, especially adapalene.

❖ **Clinical use:** Retinoids are one of the most frequently used topical agents in acne. Remember:

- Start with lowest concentration; gradually introducing higher concentrations over period of weeks.
- Use only at night, it can cause photosensitivity. Adapalene may be used during day.
- Should be applied to all acne-prone areas.
- Excessive dryness is to be avoided to ensure compliance.
- Can be combined with topical antibiotics. RA should not be combined with benzoyl peroxide, because it gets inactivated.

❖ **Side effects:** Retinoids can cause:

- *Irritation:* more common with higher concentrations, being more with tazarotene > retinoic acid > adapalene. Is more around eyes, nose, and mouth (so avoid around these areas).
- *Photosensitivity:* frequent with RA, so RA should be used only at night.

8. **QOL:** measures impact of disease on patient's life.

9. **Water-based cosmetics:** cosmetics can be water based or oil-based. Most cosmetic manufacturers mention this on the label.

10. **Less irritating:** because RA has affinity for all retinoid receptors while adapalene binds only to RAR α and RAR β .

11. **Microcomedo:** precursor of all acne lesions; histological term referring to a plugged follicle not visible to the naked eye.

Benzoyl peroxide (BP)❖ **Mode of action:**

- Is a powerful antimicrobial, decreasing population of *P. acnes*.
- Also has anti-inflammatory effect.

❖ **Available:** In concentrations of 2.5%, 4%, 5%, and 10%, either alone or in combination with sulfur.

❖ **Indications:**

- Mild acne, as stand-alone therapy, especially if few inflammatory lesions also present.
- Always to antibiotic therapy, to reduce resistance.
- Moderate–severe acne as topical adjunct to systemic therapy.

❖ **Clinical use:**

- Used in both inflammatory and non-inflammatory acne.
- Initially used in lower concentration for short duration (1–2 h); increased over period of time to higher concentration and longer periods of time (overnight).

❖ **Side effects:**

- Irritation is frequent, so treatment is started with lower concentration.
- Bleaching of hair.

Topical antibiotics

❖ Most frequently used topical antibiotics are clindamycin (1–2%) and erythromycin¹² (2–4%).

❖ **Mode of action:** Suppress *P. acnes* and its mediators of inflammation and so are more effective against inflammatory acne.

❖ **Clinical use:** Useful in inflammatory acne but must always be combined with topical retinoic acid or benzoyl peroxide¹³.

❖ **Side effects:** Resistance of microorganisms to antibiotics is a major problem, so should be combined with topical retinoids¹⁴ or benzoyl peroxide.

Other agents

Other topical agents which have been used with benefit:

- ❖ **α-hydroxy acids:** e.g., glycolic acid, 6–12%.
- ❖ **Azelaic acid (10–20%):** Also reduces postacne

hyperpigmentation, a common sequelae of acne.

Systemic treatment**Antibiotics**

❖ **Drugs used:** Doxycycline and minocycline are most commonly used. Less frequently, erythromycin and azithromycin.

❖ **Mode of action:**

- Inhibit growth of *P. acnes* and its metabolism.
- Direct anti-inflammatory effect.

❖ **Indications:**

- Moderately severe acne (being the most frequently used systemic therapy).
- Mild acne, if acne is affecting patient's quality of life.
- Severe acne, if oral retinoids cannot be used.

❖ **Regimens:**

- Tetracycline (1 g), doxycycline (100 mg), minocycline (100 mg), erythromycin (1 g) daily. Or azithromycin (250 mg), 3–4 times a week. May need to be given for long periods of time (up to 3–6 months).
- Tetracycline and doxycycline should be taken on empty stomach (absorption decreased by milk, antacids, and metal salts). Absorption of minocycline, not affected by food.
- Oral antibiotics should always be combined with topical agents, so as to facilitate withdrawal of antibiotics when acne is controlled. The patient can then be maintained on topical therapy.
- Minocycline concentrates in sebaceous glands (lipophilic drug) and is bacteriologically more effective than tetracyclines; it is also effective in tetracycline-resistant acne.

❖ **Adverse events:** Even with long courses, serious side effects are uncommon.

- **Gastrointestinal side effects:** frequent and include nausea.
- **Cutaneous side effects:** long-term administration of minocycline may cause grayish pigmentation of skin, mucosae, and nails.

12. **Erythromycin:** topical, not available in India.

13. **Benzoyl peroxide:** *P. acnes* not reported to develop resistance to benzoyl peroxide.

14. **Combination topical therapy:** combining topical antibiotics with topical retinoids or benzoyl peroxide reduces the development of resistance to antibiotics. Also improves efficacy of the antibiotics. The anti-inflammatory effect of antibiotics reduces irritation due to retinoids and benzoyl peroxide.

- **Teratogenicity:** tetracyclines should be avoided in pregnant women and in children under 8 years of age¹⁵.
- **Infections:** vaginal candidiasis.
- **Resistance of *P. acnes* to antibiotics:** more frequent with macrolides, so their use should be limited.

Hormones

- ❖ **Mode of action:** Antiandrogens act by decreasing sebum secretion rate.
- ❖ **Indications:** Only in females.
 - Late onset acne.
 - Women with menstrual irregularities.
- ❖ **Treatment schedules:** Need to be used for long periods of time (6–24 months)
 - **Cyproterone acetate:**
 - Is available as combination, of 2 mg cyproterone acetate and 35 µg ethinyl estradiol.
 - Used cyclically.
 - **Spironolactone:** 50–100 mg daily.

Isotretinoin

- ❖ Isotretinoin (13-cis-retinoic acid), a retinoid, has revolutionized management of severe intractable acne (Fig. 7.16).
- ❖ **Mode of action:** Isotretinoin acts in acne at several levels by:
 - Inhibiting sebum secretion.
 - Decreasing *P. acnes* counts (by reducing sebum secretion).
 - Reducing inflammation.
- ❖ **Indications:** Recommended in the following situations:
 - Severe acne, acne conglobata.
 - Moderately severe acne not responding to conventional therapy.
 - Moderate acne which repeatedly relapses after conventional therapy.
 - Any grade of acne which is causing distress.
- ❖ **Treatment schedule:** Used in a dose of 0.5–1 mg/kg body weight daily. Higher dose required for truncal acne. Is given for a period of 12–16 weeks. Response to treatment is usually long lasting and only few patients need a second course.
- ❖ **Side effects:**
 - Some reversible side effects occur in all patients and do not warrant withdrawal of

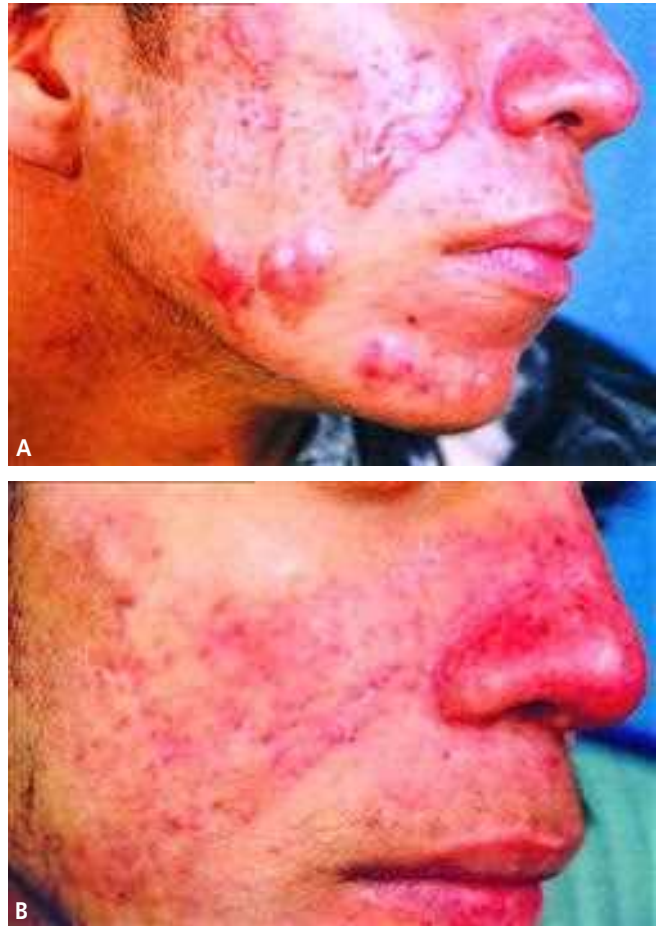


Fig. 7.16. Acne conglobata: A: pretreatment. B: 12 weeks post-treatment with oral isotretinoin.

treatment. Include dry skin, cheilitis, hair loss, dryness of eyes (intolerance to contact lenses), and nose bleeds.

- Few patients show an initial aggravation of inflammatory lesions but this aggravation is short lived.
- Should **NOT** be used in women who are pregnant or likely to get pregnant because of teratogenicity. If used at all, contraception (using two different methods) should be ensured throughout treatment and for 1 month thereafter, because of long half life of isotretinoin.
- Other side effects include myalgias, vertebral hyperostosis (on prolonged use), and altered night vision.
- Patients advised not to donate blood during treatment and for 1 month thereafter.

15. **Tetracyclines in pregnancy and in children:** is deposited in growing bones and developing teeth, causing staining of teeth and dental hypoplasia.

Table 7.1. Principles of treating acne

	Mild		Moderate		Severe
	Comedonal	Papulopustular	Papulopustular	Nodular	Nodular/Conglobata
Drug of choice	Topical R	Topical R + Topical Ab/BP	Oral Ab + Topical R + BP	Oral Ab + Topical R+ BP	Oral R
Alternatives	Alternative topical R/Ab/AzA	Alternative topical R/Ab/AzA	Alternative oral Ab + Topical Ab + BP	Oral R	Oral Ab + Topical R + BP
Maintenance	Topical R	Topical R	Topical R	Topical R	Topical R
Females	–	–	–	Oral AA+ topical R Oral R under supervision	Oral AA + topical R Oral R under supervision

R: retinoids; Ab: antibiotics; BP: benzoyl peroxide; AzA: azelaic acid; AA: antiandrogens.

- Pseudotumor cerebri (so should not be combined with tetracyclines).
- Careful monitoring is very important:
 - Liver function tests (causes elevation of transaminases) and fasting lipid levels (causes hypertriglyceridemia) should be done at baseline and every 4–6 weeks thereafter.
 - Pregnancy test: Before starting treatment and every 4 weeks.

Principles of treating acne (Table 7.1)

Physical modalities of treatment

Intralesional corticosteroids

- ❖ **Active disease:** Injection of long-acting steroid (triamcinolone acetonide 10 mg/ml, diluted further) into nodules results in dramatic resolution of lesions. Over zealous treatment, however, may result in atrophy.
- ❖ **Hypertrophic scars:** Injections of long-acting steroid (triamcinolone acetonide 10 mg/ml) into recalcitrant hypertrophic scars/keloids results in slow resolution of lesions.

Cryotherapy

- ❖ Freezing with liquid nitrogen hastens resolution of recalcitrant nodulocystic lesions.
- ❖ Scars also respond to cryotherapy.

Laser therapy

- ❖ Laser skin resurfacing has been used to treat acne scars.
- ❖ Laser used is carbon dioxide laser.

Photodynamic treatment

- ❖ **Uses:** Red light and a photosensitizer like aminolevulinic acid (ALA).
- ❖ **Response:** Moderate response

Dermabrasion

- ❖ Superficial dermabrasion helps in reducing scars but should be used only in absence of active lesions.
- ❖ Occasionally leaves behind unsightly hyperpigmentation and may cause photosensitivity.

Fillers

Injections of fillers to augment tissue defects are of limited benefit because treatment is expensive and needs to be repeated every 6 months.

Rosacea¹⁶

Synopsis

Etiology: Unknown.

Morphology: Characterized by erythema and telangiectasia, and acute episodes of papules and pustules.

Sites: Cheeks, forehead, chin, and nose (convexities of face).

Treatment: Tetracyclines and topical metronidazole are the mainstay of therapy. *Do not use* steroids (topical or systemic). Isotretinoin used in recalcitrant rosacea.

Definition

Rosacea is a chronic skin disorder characterized by erythema and telangiectasia and punctuated by acute episodes of papules, pustules, and swelling.

16. **Rosacea:** is primarily not a disorder of sebaceous glands though in later stages, there may be hyperplasia of sebaceous glands. It is being discussed here because it frequently enters the differential diagnosis of acne vulgaris.

Etiology

The exact cause of rosacea is not known.

- ❖ **Vascular abnormalities:** May be associated with an abnormal vascular reactivity (exaggerated flushing response to heat, spicy food, alcohol and stress) but no pharmacological defect has been found.
- ❖ **Pathogenic organisms:** A pathogenic role for the follicular mite *Demodex folliculorum* and the microaerophilic Gram-negative bacterium *Helicobacter pylori* is suspected.

Epidemiology

- ❖ **Age:** Peak incidence in fourth and fifth decade.
- ❖ **Gender:** More frequent in females.

Clinical Features

Triggers

Factors which trigger flushing include emotional stress, hot drinks, spicy foods, alcohol, and withdrawal of steroids.

Morphology (Fig. 7.17)

The morphological features in order of importance are:

- ❖ **Erythema and telangiectasia:** Intermittent flushing is followed by more permanent erythema and telangiectasia.
- ❖ **Papules and pustules:** Discrete erythematous dome-shaped papules, papulopustules, and rarely nodules develop on this background. There are no comedones. Typically, patients of rosacea, if on steroids, develop a rebound when the steroid is withdrawn.

Sites of predilection

Rosacea is a centrofacial disease, especially seen on the convexities of the face (cheeks, chin, forehead, and nose). Periorbital and perioral areas are spared (Fig. 7.18).

Course

- ❖ **Early disease:** Episodic flushing and edema, mild telangiectasia.
- ❖ **Progressive disease:** Papules, pustules, sustained edema, extensive telangiectasia.
- ❖ **Late disease:** Induration, rhinophyma.

Complications

- ❖ **Ophthalmologic complications:** Blepharitis, conjunctivitis, and keratitis.

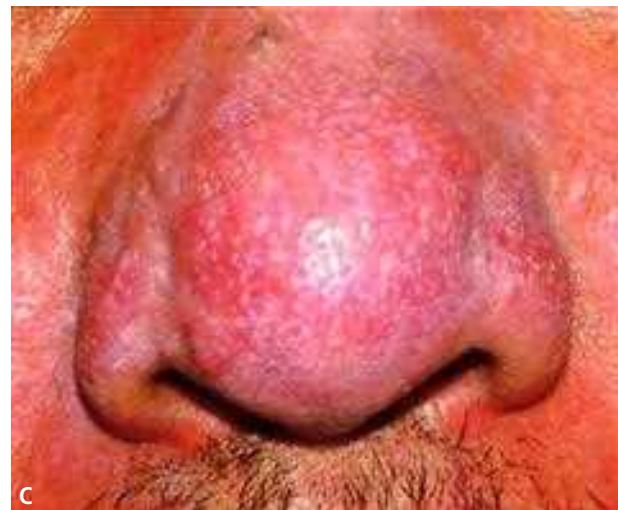
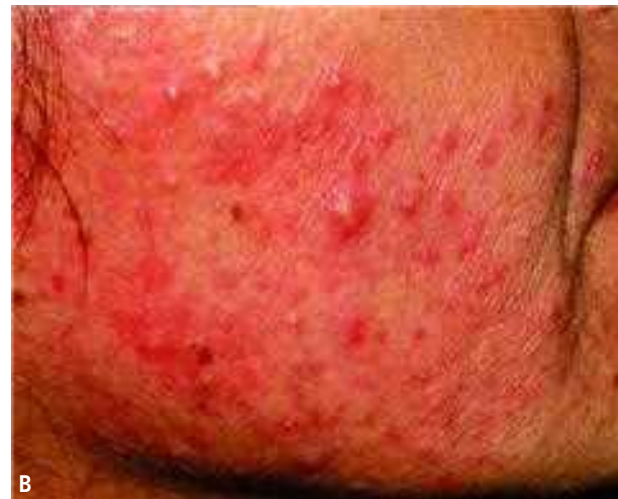
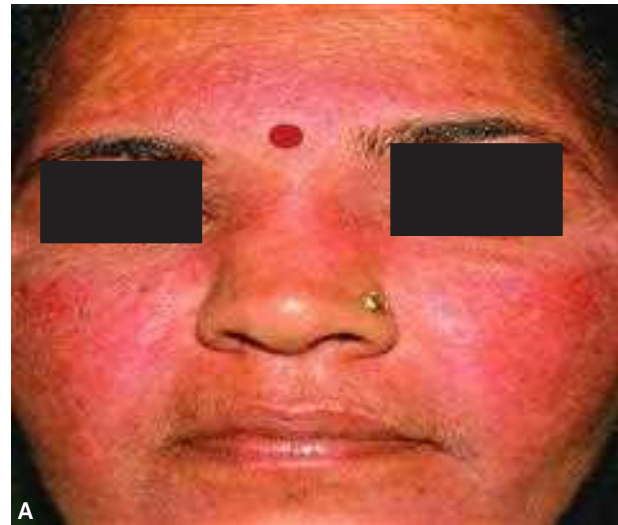Fig. 7.17. Rosacea: A: showing typical distribution of lesions on convexities of face and sparing of periorificial areas. B: papulopustules on background of erythema and telangiectasia. C: rhinophyma: bulbous nose with patulous follicular openings.

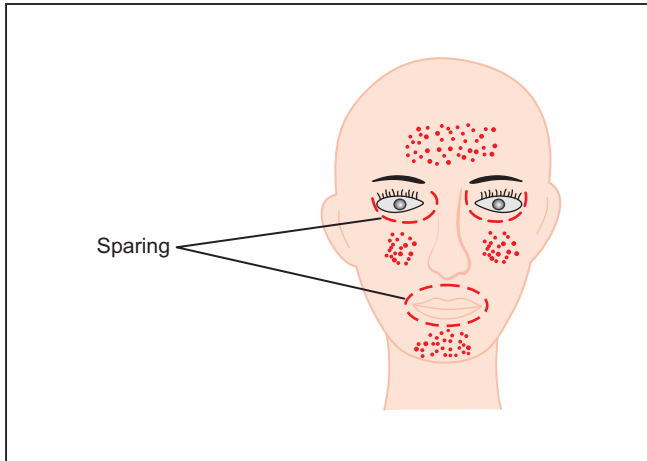


Fig. 7.18. Rosacea: sites of predilection.

- ❖ **Rhinophyma:** More frequent in males. Characterized by bulbous nose with patulous follicular openings, due to hyperplasia of sebaceous glands and connective tissue of the nose (Fig. 7.17C).
- ❖ **Lymphedema:** Infraorbital and forehead.

Diagnosis

Points for diagnosis

The diagnosis of rosacea is based on:

- ❖ Middle aged women.
- ❖ Episodes of flushing and intolerance to heat and spicy foods.
- ❖ Background erythema and telangiectasia with episodes of papules and pustules.
- ❖ Absence of comedones.
- ❖ Convexities of the face involved—forehead, nose, cheeks, and chin. Characteristic sparing of periorbital and perioral area.

Differential diagnosis

Rosacea should be differentiated from:

a. Acne vulgaris

<i>Acne vulgaris</i>	<i>Rosacea</i>
Age: adolescents	Middle aged
Gender: no gender predilection, though more severe in males	Women
Background: oiliness	Background erythema and telangiectasia
Morphology: polymorphic eruption; comedones prominent	Papules, pustules, telangiectasia; comedones absent
Distribution: face, deltoid region trunk	Convexities of face. Spares periorificial area

b. Seborrheic dermatitis

<i>Seborrheic dermatitis</i>	<i>Rosacea</i>
Morphology: follicular papules with greasy, loose scales	Erythematous papules, pustules and telangiectasia
Background: greasiness	Erythema and telangiectasia
Distribution: eyebrows, eyelashes, nasolabial folds, retroauricular region, scalp	Forehead, cheeks, nose, chin

c. Systemic lupus erythematosus (SLE)

<i>SLE</i>	<i>Rosacea</i>
Morphology: erythema and edema. Papules and pustules infrequent	Erythema and telangiectasia. Episodes of papules and pustules frequent
Distribution: butterfly area	Forehead, nose, cheek and chin
Associations: systemic symptoms frequent	Intolerance to heat and spices; eye complications

d. Perioral dermatitis (Fig. 7.19)

Treatment

Mild cases managed with topical therapy, while acute exacerbations and severe rosacea need to be treated with systemic therapy.

Topical agents

Sunscreens

Useful in those patients in whom photosensitivity is severe.

Topical metronidazole (0.75%)

- ❖ Very effective in mild to moderate rosacea.
- ❖ Papulopustular lesions respond well, but erythema and telangiectasia do not.

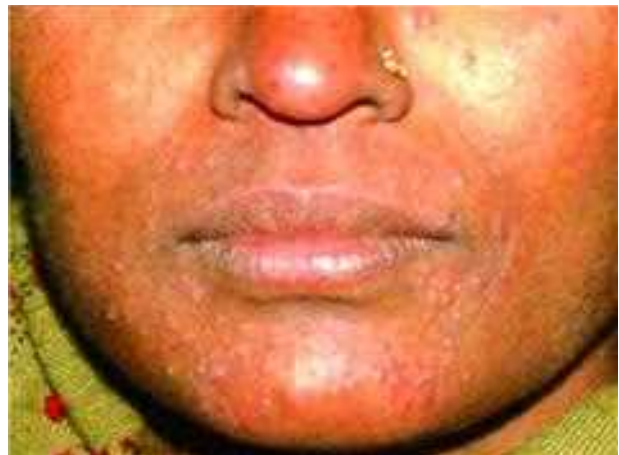

Fig. 7.19. Perioral dermatitis: papules and pustules in the perioral area. Note sparing of rim around the lips.

Retinoic acid (0.025%)

- ❖ Effective in mild to moderate rosacea.
- ❖ Papules and pustules respond, while erythema and telangiectasia do not.

Topic immunomodulators

- ❖ Pimecrolimus 1% cream and tacrolimus 0.03% and 0.1% ointment.
- ❖ Effective to wean patients off topical steroids.

Steroids

Should be absolutely avoided.

Systemic therapy**Antibiotics**

- ❖ **Doxycycline:** Forms the mainstay of therapy.
 - Suppress papules and pustules but not erythema and telangiectasia.
 - Start with 100 mg a day; reduce to 100 mg alternate days as lesions respond. Given for 2–3 months.
- ❖ **Erythromycin:** Is the drug of second choice.
- ❖ **Metronidazole:** Has also been tried orally.

Isotretinoin

- ❖ Effective against all severities of rosacea. And in rosacea-resistant to conventional therapy.
- ❖ Reduces inflammatory lesions as well as erythema and telangiectasia. Interestingly, also reduces size of rhinophyma.
- ❖ 0.5–1 mg/kg body weight daily for 3–6 months.

Fordyce's Spots¹⁷

- ❖ Very common
- ❖ Ectopic sebaceous glands.
- ❖ Appear as symmetric, multiple, yellow, flat topped papules (Fig. 7.20).
- ❖ Lips, buccal mucosa and penile shaft.
- ❖ Reassure patient.

Disorders of Eccrine Sweat Glands**Structure and Function****Anatomy**

- ❖ Present all over body, especially on palms, soles, and in axillae.

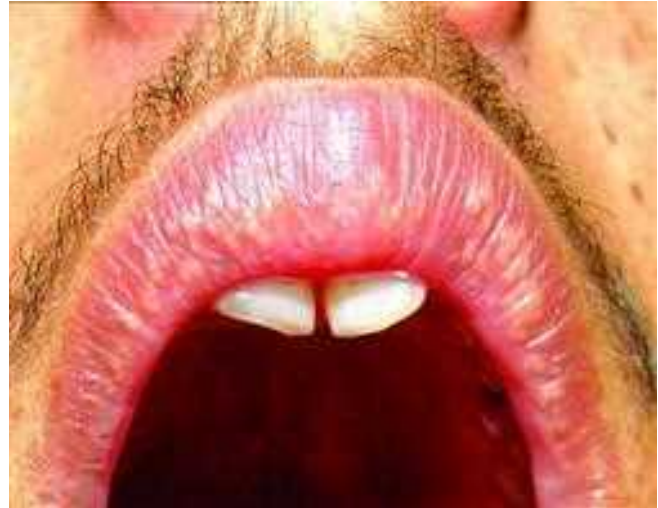

Fig. 7.20. Fordyce's spots: multiple, symmetric, flat topped, yellow papules.

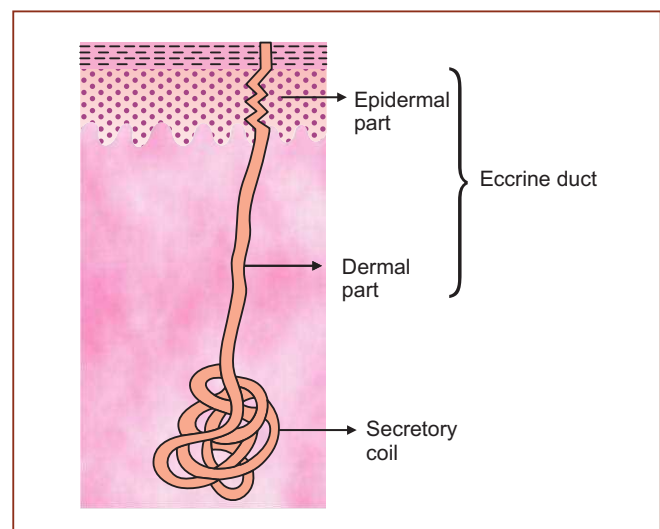


Fig. 7.21. Eccrine sweat glands: the gland is made up of a secretory coil and a duct.

- ❖ Consists of two parts:
 - **Coil:** a tightly packed coil which lies deep in the dermis.
 - **Duct:** which connects the coil to skin surface. (Fig. 7.21). Duct has two parts:
 - Lower straight part, which lies in the dermis.
 - Upper intraepidermal part, which penetrates epidermis in a corkscrew fashion (Fig. 7.21).

17. **Fordyce's spots:** not to be confused with Fox Fordyce's disease, which is a disease of apocrine glands.

Control

- ❖ **Central control:** Central control of sweating resides in preoptic hypothalamic sweat center.
- ❖ **Innervation:**
 - Are innervated by cholinergic fibers of sympathetic system.
 - Sweating induced by cholinergic drugs and blocked by anticholinergic drugs.
- ❖ **Hormonal control:** Aldosterone and antidiuretic hormone are responsible for making sweat hypotonic.

Physiology

- ❖ **In the secretory coil:** Sweat formed by active secretion through the sodium pump is isotonic.
- ❖ **In the duct:** Sweat becomes hypotonic, under influence of aldosterone and antidiuretic hormone.

Factors Controlling Sweating

Several factors control rate of sweating:

- ❖ **Thermal control:** Sweat glands play an important role in temperature control. Increased ambient temperature increases sweat secretion to up to 10 L. Thermal sweating occurs all over the body especially on the chest, back, scalp, and axillae.
- ❖ **Hormonal control:** Aldosterone and antidiuretic hormone influence reabsorption of electrolytes in duct, making sweat hypotonic.
- ❖ **Emotional control :** Emotional sweating, provoked by fear, anxiety, and worry is seen mainly on palms, soles, and axillae.
- ❖ **Gustatory control:** Sweating in response to ingestion of hot, spicy foods affects the face especially nose, lips, and chin and is usually profuse.

Hyperhidrosis

Hyperhidrosis is excessive sweating and can either be:

- ❖ Generalized
- ❖ Localized

Generalized Hyperhidrosis

Thermal hyperhidrosis

Etiology

Body temperature is controlled by hypothalamus and sweating occurs:

- ❖ **Physiologically:** When there is rise in body temperature due to:
 - Fever.
 - Exercise.
 - High environmental temperature.
- ❖ **In disease states:** Diseases which alter the “thermostat” in the hypothalamus:
 - Infections.
 - Hodgkin’s disease.

Clinical features

Sweating is generalized and may be associated with increased body temperature.

Sympathetic hyperhidrosis

Etiology

Sympathetic stimuli¹⁸ induce hyperhidrosis by direct or reflex stimulation of the sympathetic system at hypothalamic or higher centers.

Clinical features

- ❖ A generalized sympathetic discharge causes sweating.
- ❖ Is accompanied by generalized vasoconstriction manifesting as pale, cold skin.

Endocrine diseases

Etiology

Thyrotoxicosis, diabetes mellitus, Cushing’s syndrome, menopausal flushes, pheochromocytoma, and carcinoid syndrome.

Pathogenesis

Unclear.

Clinical features

- ❖ Generalized sweating.
- ❖ Features of underlying endocrine disorder.

Neurological diseases

Disorders of central nervous system may cause generalized sweating by interfering directly with the hypothalamic center.

18. **Sympathetic stimuli:** emotional stimuli, hypoglycemia, opiate withdrawal, and shock.

Localized Hyperhidrosis

Causes

- ❖ Usually idiopathic.
- ❖ Often associated with anxiety states.
- ❖ Occasionally associated with thyrotoxicosis, acromegaly, tuberculosis, and Hodgkin's disease.

Clinical features

- ❖ Frequently seen in young adults.
- ❖ Profuse sweating of palms, soles, and axillae.
- ❖ Psychological problems due to body odor.
- ❖ Physical disability due to excessive sweating of palms (writing, doing fine work) and soles (walking).

Treatment

Topical therapy

- ❖ **Aluminium chloride hexahydrate** (20% in alcohol base):
 - Frequently used topical therapy.
 - *Use:* for both palmoplantar as well as axillary hyperhidrosis.
 - *Regimen:* initially, daily applications. As hyperhidrosis improves, applications reduced to weekly and then even fortnightly.
 - Irritation occurs, if applied to wet skin (so apply only on dry skin) and to recently shaved axillae. Also causes thickening of skin.

❖ **Iontophoresis:**

- Frequently used.
- *Use:* mainly palmoplantar hyperhidrosis.
- *Regimen:* a low-voltage direct current is passed across skin using tap water (or with anticholinergic drugs). Initially alternate days. Frequency reduced as patient responds.

- ❖ **Botulinum toxin:** To be injected in affected area by trained personnel. Needs repetition every 6–9 months.

Systemic therapy

Anticholinergic drugs are not used because of systemic side effects.

Surgical therapy

- ❖ Since topical therapy and iontophoresis are successful in managing localized hyperhidrosis, surgical measures are usually not needed.
- ❖ However, in recalcitrant axillary hyperhidrosis, removal of the vault of axilla (where most of the sweat glands lie) or cervical sympathectomy (as a last resort) can be tried.

Hypohidrosis and Anhidrosis

Etiology

Hypohidrosis and anhidrosis are caused either by anatomical or physiological defects of sweat glands or by defective delivery of sweat. Skin diseases and disorders of nervous system, including infections (leprosy) which result in destruction of nerves can manifest as hypohidrosis (Table 7.2).

Table 7.2. Causes of hypohidrosis and anhidrosis

Defects of sweat glands	
❖ <i>Anatomical defects</i>	Hypohidrotic ectodermal dysplasia
❖ <i>Physiological dysfunction</i>	Premature birth Heat stroke
Defective delivery of sweat	Miliaria
Nervous system diseases	Multiple sclerosis Cerebral tumors Leprosy
Skin diseases	Sjogren's syndrome Ichthyosis Psoriasis

Clinical Features

Hypohidrosis (or anhidrosis) can be localized or generalized.

Generalized hypohidrosis

- ❖ Patients present with intolerance to heat, increased body temperature (especially in summers) and dry skin.
- ❖ Acute generalized hypohidrosis, as seen in heat stroke, is a medical emergency because it is associated with hypotension and biochemical abnormalities.
- ❖ Chronic generalized hypohidrosis is seen in **hypohidrotic ectodermal dysplasia** (Fig. 7.22), an X-linked genodermatosis.

Localized hypohidrosis

Patients with localized hypohidrosis do not develop hyperthermia, because of compensatory hyperhidrosis in adjoining skin. So the body temperature does not rise.

Treatment

Acute generalized hypohidrosis (heat stroke)

- ❖ Is a medical emergency.
- ❖ Patient should be cooled down immediately with cold water.

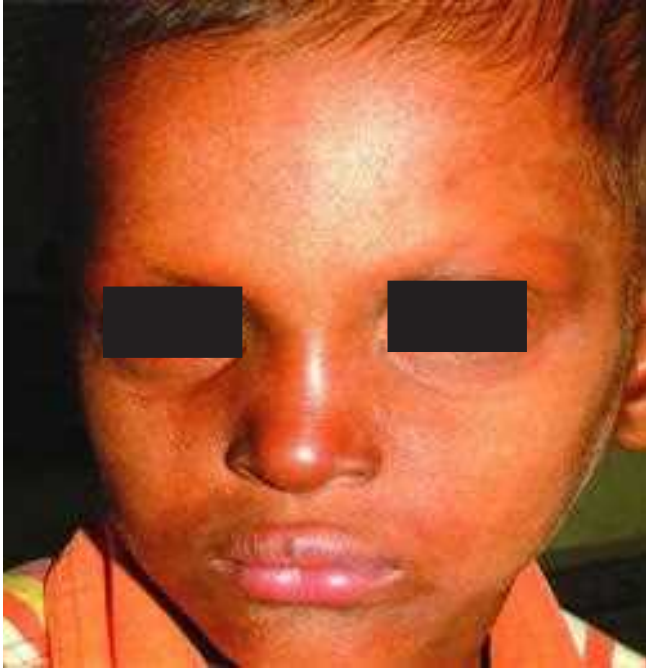

Fig. 7.22. Hypohidrotic ectodermal dysplasia: apart from absence of sweating, patients have sparse hair, abnormal dentition and a characteristic facies.

- ❖ Body fluids must be replaced.
- ❖ Biochemical abnormalities should be corrected.

Chronic generalized hypohidrosis

- ❖ These patients are intolerant to heat and are best managed in an air-conditioned or cooler environment.
- ❖ If that is not possible, frequent baths and hydration may help.

Miliaria

Synonym: Prickly heat

Synopsis

Etiology: Spillage of sweat into dermis due to obstruction of sweat duct. Occurs in hot humid climate.

Clinical features: Several variants. Miliaria crystallina, rubra, and profunda. Miliaria rubra (commonest) presents as small, erythematous papules, surmounted by vesicles.

Treatment: Avoid hot humid environment; Soothing agents (lotion calamine) give relief.

Etiology

- ❖ Miliaria is caused by obstruction and rupture of eccrine sweat ducts resulting in spillage of sweat into adjoining tissues.

- ❖ Depending on the level of the rupture, miliaria is classified into three morphological variants:
 - *Miliaria crystallina*: when duct ruptures just below the stratum corneum.
 - *Miliaria rubra*: when duct ruptures in the epidermis.
 - *Miliaria profunda*: when duct ruptures at the dermoepidermal junction.

Clinical Features

Miliaria can occur at any age. Morphology of lesions depends on level of rupture.

Miliaria crystallina

- ❖ Tiny, clear, noninflamed (crystalline) vesicles (Fig. 7.23A).
- ❖ Usually occurs during episodes of lysis of fever.

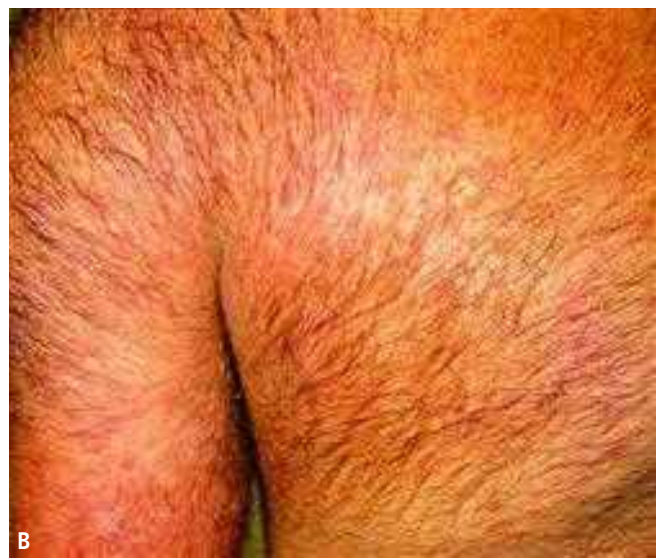
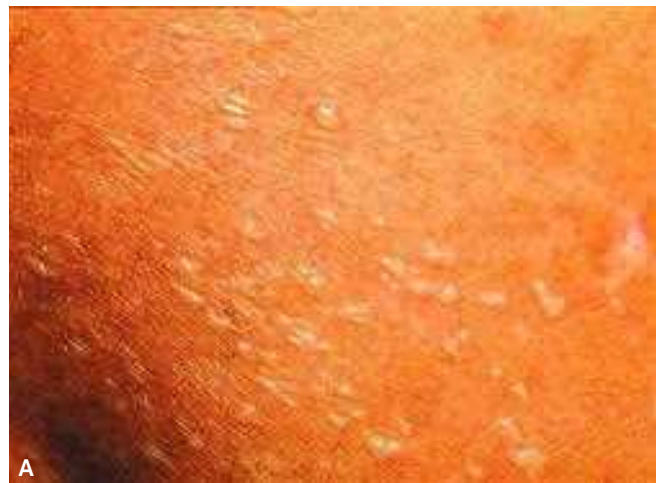
Fig. 7.23. Miliaria: A: miliaria crystallina, tiny clear superficial vesicles on a bland background. B: miliaria rubra, small erythematous papules surmounted by vesicles.

Miliaria rubra

- ❖ Patients usually complain of **pricking**¹⁹ or burning, more than itching.
- ❖ Small, erythematous papules (Fig. 7.23B), often surmounted by vesicles. The vesicles can be easily ruptured by “flicking the lesion”.
- ❖ Trunk, forehead, and extremities.
- ❖ Triggered by hot humid weather.

Miliaria profunda

Larger erythematous papules.

Treatment**General measures**

- ❖ Avoid hot humid environment. Air-conditioned environment ideal.
- ❖ Avoid wearing synthetic garments; cottons are best because they absorb sweat. Remember not only the undergarments but even top wear should be cotton.

Specific treatment

- ❖ Calamine lotion is soothing.
- ❖ For severely symptomatic patients, application of low-mid potency topical steroid for a few days gives symptomatic relief.

Disorders of Apocrine Glands**Structure and Function****Anatomy**

- ❖ Present in the axillae, nipples, periumbilical area, perineum, and genitalia. Modified apocrine glands present in the external ear canal (**ceruminous glands**) and eyelids (**Moll’s glands**). Breast is also a modified apocrine gland.
- ❖ Consists of two parts (Fig. 7.24):
 - *Coil*: coil of the apocrine gland lies at junction of dermis and subcutaneous tissue and its cells discharge secretion into the lumen by decapitation, resulting in loss of their supra-nuclear part (Fig. 7.24 Inset).
 - *Duct*: connects coil to mid-portion of hair follicle, just above entrance of the sebaceous duct.

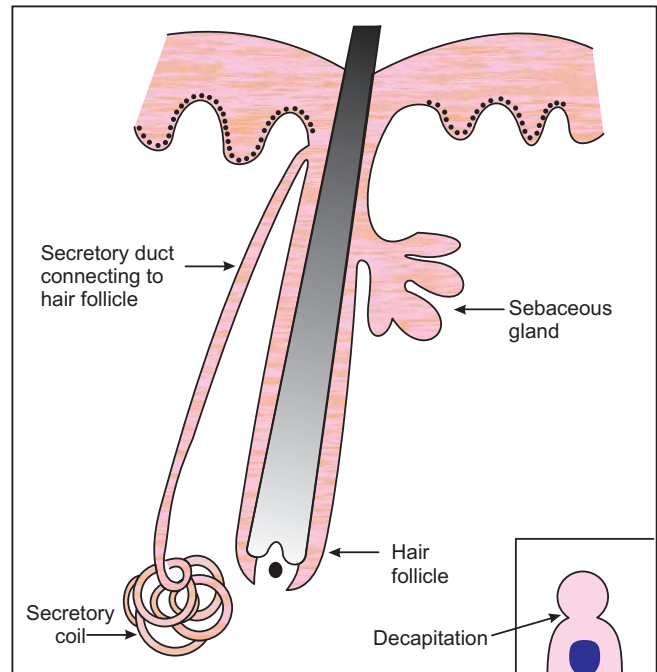


Fig. 7.24. Apocrine sweat gland: duct opening into the hair follicle. Inset: decapitation secretion of apocrine gland.

Activity

- ❖ Innervated by adrenergic fibers of sympathetic nervous system.
- ❖ Become functional only just before puberty.

Hidradenitis Suppurativa (Apocrine Acne)**Etiology**

- ❖ Cause not known.
- ❖ May be a part of follicular occlusion syndrome, but levels of circulating androgens are normal.
- ❖ Microorganisms like *Staph aureus*, anaerobic streptococci (like *Streptococcus milleri*), and bacteroides often found in the lesions but their role in pathogenesis of hidradenitis is doubtful.

Clinical Features**Morphology**

- ❖ Nodules, pustules, cysts, and sinuses with inter-connecting bridges (Fig. 7.25).

19. **Pricking**: so aptly called ‘prickly heat’.

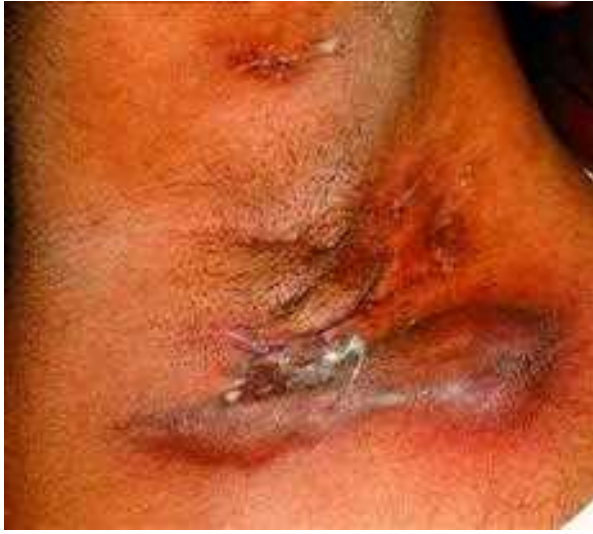

Fig. 7.25. Hidradenitis suppurativa: papules, nodules, pustules, cysts, sinuses, and interconnecting bridges in axillae. Note comedones.

- ❖ Comedones, mainly polyporous, frequently seen.

Site of predilection

Axillae, groins, and perianal region.

Associations

May occur as a part of **follicular occlusion syndrome**, when it is associated with acne conglobata, dissecting folliculitis of scalp and pilonidal sinus.

Treatment

Medical treatment

Treatment is unsatisfactory and needs to be given for several months (years!):

- ❖ Systemic antibiotics (like tetracyclines and erythromycin).
- ❖ Systemic antiandrogens and isotretinoin may be useful.
- ❖ Intralesional injections of triamcinolone 10 mg/ml (given diluted) may prevent/reduce scarring and formation of sinuses especially if given early.

Surgical treatment

- ❖ **Incision and drainage:** Of abscesses and cysts.
- ❖ **Excisional surgery:**
 - In recalcitrant and severe disease.
 - Large area of vault of axilla is excised to remove apocrine glands to prevent recurrences.

Disorders of Hair

Structure and Function

Anatomy

- ❖ **Longitudinal section of hair:** Is made up of three parts:
 - *Hair shaft:* the part of hair which is visible above skin.
 - *Hair follicle:* the part of hair embedded in skin.
 - *Hair bulb:* is the distended deepest part of follicle.
- ❖ **Cross section of hair shaft and follicle:** Is made up of:
 - *Medulla:* which is central core, present in terminal hair but not in vellus hair.
 - *Cortex:* which surrounds the medulla in terminal hair and forms bulk of vellus hair.
 - *Cover:*
 - follicle is ensheathed by **inner root sheath** and **outer root sheath** (Fig. 7.26).
 - hair shaft is ensheathed by **cuticular scales**.

Types of Hair

Hairs are classified into three main types:

- ❖ **Lanugo hair:** Fine, soft hair of the fetus which

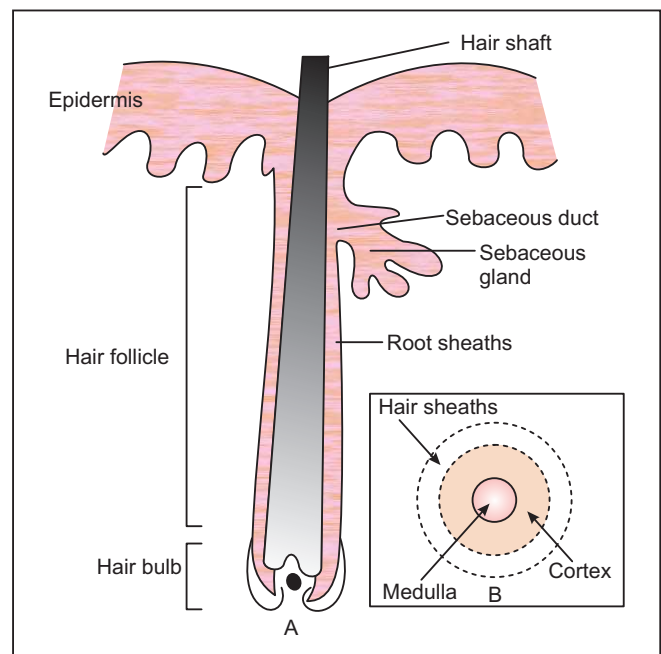


Fig. 7.26. Section of hair. A: Longitudinal section. B: Cross section.

are shed *in utero* but may rarely be retained, *e.g.*, in **congenital hypertrichosis lanuginosa**.

- ❖ **Vellus hair:** Fine, short and nonmedullated hair, present on most parts of the body.
- ❖ **Terminal hair:** Long, coarse, and medullated hair present on scalp and some other parts of the body, (*e.g.*, axillae, pubis, beard, and mustache area) depending on age and sex of individual.

Hair Cycle and Growth (Fig. 7.27)

- ❖ Hair passes through three stages of growth and shedding. Cycle of one hair is independent of the cycle of the neighboring follicles, *i.e.*, neighboring follicles are not synchronized in growth.
- ❖ The stages of hair cycle are:
 - *Anagen:* phase of activity and growth. Hair shows pigmented malleable bulb.
 - *Catagen:* phase of involution.
 - *Telogen:* phase of resting. Hair shows club-shaped depigmented bulb.
- ❖ Proportion of hair in each phase is estimated by a **trichogram**²⁰, which sometimes helps in making a diagnosis of cause of hair fall.
- ❖ Duration of each phase varies in different parts of the body.

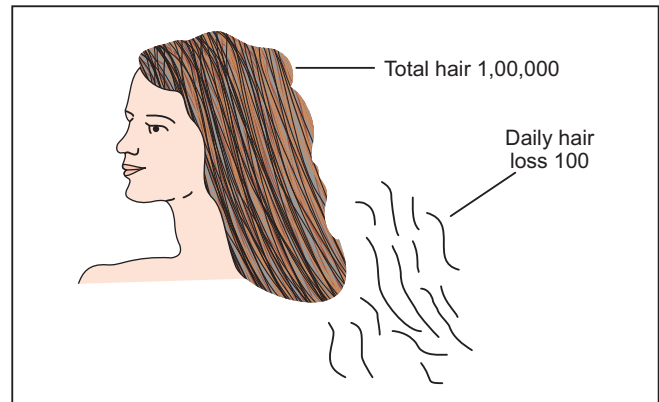


Fig. 7.27. Human scalp contains about 100,000 hair. Each hair grows for 1000 days and is then shed.

Definitions

- ❖ **Alopecia:** Alopecia means loss of hair. There are two types of alopecia (Fig. 7.28):
 - *Non-cicatricial alopecia* (Table 7.3).
 - *Cicatricial alopecia* (Table 7.3).
- ❖ **Hirsutism:** Hirsutism is the presence of excess terminal hair on the body of female in a male distribution, *i.e.*, pattern of terminal hair distribution that is androgen dependent (beard and mustache region, chest, infraumbilical area and tips of shoulders).

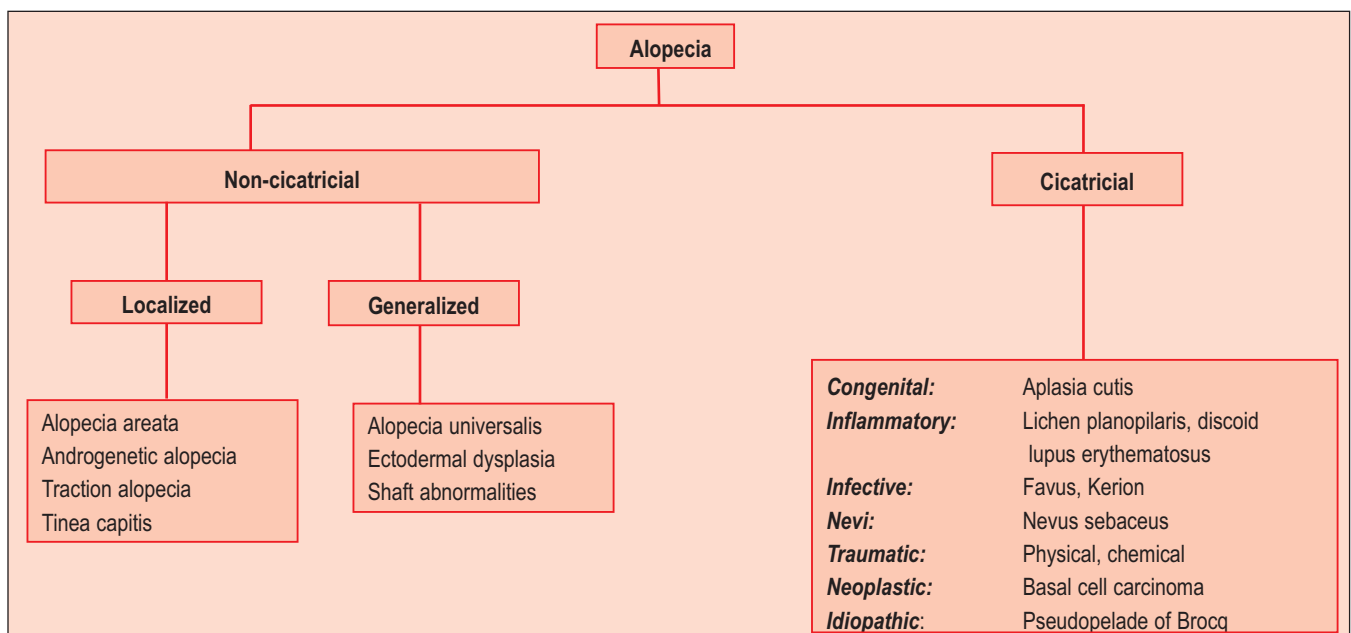


Fig. 7.28. Causes of alopecia.

20. **Trichogram:** done by plucking the hair and determining the proportion of anagen and telogen hair, under the microscope.

Table 7.3. Differences between cicatricial and noncicatricial alopecia

Cicatricial alopecia	Noncicatricial alopecia
Scarring present	Scarring absent
Hair follicles destroyed, so irreversible	Hair follicles not destroyed, so generally reversible
Skin shiny and follicular openings absent	Follicular openings visible
Signs of inflammation visible, e.g., papules, pustules, scaling, and hyperpigmentation	Absent
e.g., pseudopelade	e.g., alopecia areata

- ❖ **Hypertrichosis:** Hypertrichosis is presence of excess terminal hair in any part of the body, with no special pattern.

Alopecia Areata (AA)

Synopsis

Etiology: Immunologically mediated.

Morphology: Noncicatricial, noninflammatory alopecia. Presents as discoid areas of hair loss with exclamation mark hair at the edge.

Course: Unpredictable; spontaneous recovery with regrowth initially of gray hair. Or progresses to *alopecia totalis* (whole scalp) or *alopecia universalis* (whole body).

Site: Scalp, less frequently beard, eyebrows, and eyelashes. Sometimes generalized.

Treatment: *Localized lesions:* <6 months: no treatment; >6 months: topical steroids.

Extensive lesions: Response to treatment unpredictable. Minoxidil, psoralens with UVA/UVA sol (topical and systemic) and steroids (topical and systemic).

Etiology

The pathogenesis of AA is uncertain and following factors are incriminated:

- ❖ **Immunological factors:** AA is considered an immunological disease because of:
 - Association of AA with other auto-immune diseases (auto-immune thyroid disease, pernicious anemia, vitiligo, and atopy). Moreover, it responds to immunosuppressives.
 - Cytokines produced by dermal papillae in

lesions not only attract lymphocytes to perifollicular region but also stimulate them to multiply.

- As opposed to normal hairs, strong major histocompatibility complex (class I and class II) immunoreactivity found in affected follicles.
- ❖ **Genetic factors:** AA may be present in some families, so it may have a genetic basis.
- ❖ **Emotional factors:** In some patients, AA is precipitated by emotional stress.

Epidemiology

- ❖ **Prevalence:** AA is a common type of alopecia.
- ❖ **Gender:** Both males and females are equally affected.
- ❖ **Age:** Can start at any age.

Clinical Features

Morphology

- ❖ AA typically presents as a discoid patch of alopecia (Fig. 7.29), which shows no scaling, papules, inflammation or **atrophy**²¹.
- ❖ Presence of **exclamation mark hair**²² at the periphery of the lesion is pathognomonic (Fig. 7.29).

Sites of predilection

- ❖ Most frequently on scalp (Fig. 7.30), mustache, and beard area.
- ❖ Sometimes on eyelashes and eyebrows (Figs. 7.29B, 7.30).

Variants

- ❖ Some patients lose hair in a band-like pattern at the periphery of scalp (**ophiasis**, Fig. 7.31A).
- ❖ Others lose all the hair from their scalp (**alopecia totalis**, Fig. 7.31B).
- ❖ While a few patients show loss of hair from the whole body (**alopecia universalis**; Fig. 7.31C).

Alopecia totalis, alopecia universalis, and ophiasis all have a poor prognosis.

Associations

Nails

Pitting and thinning of nail plate (Fig. 7.32). These pits are fine unlike the coarse pits of psoriasis.

21. **Atrophy:** sometimes a lesion of AA may appear shiny and depressed.

22. **Exclamation mark hair:** is hair which is broken-off about 4 mm from the scalp, due to a constriction in the shaft. The broken hair is paler and narrower than the normal hair.

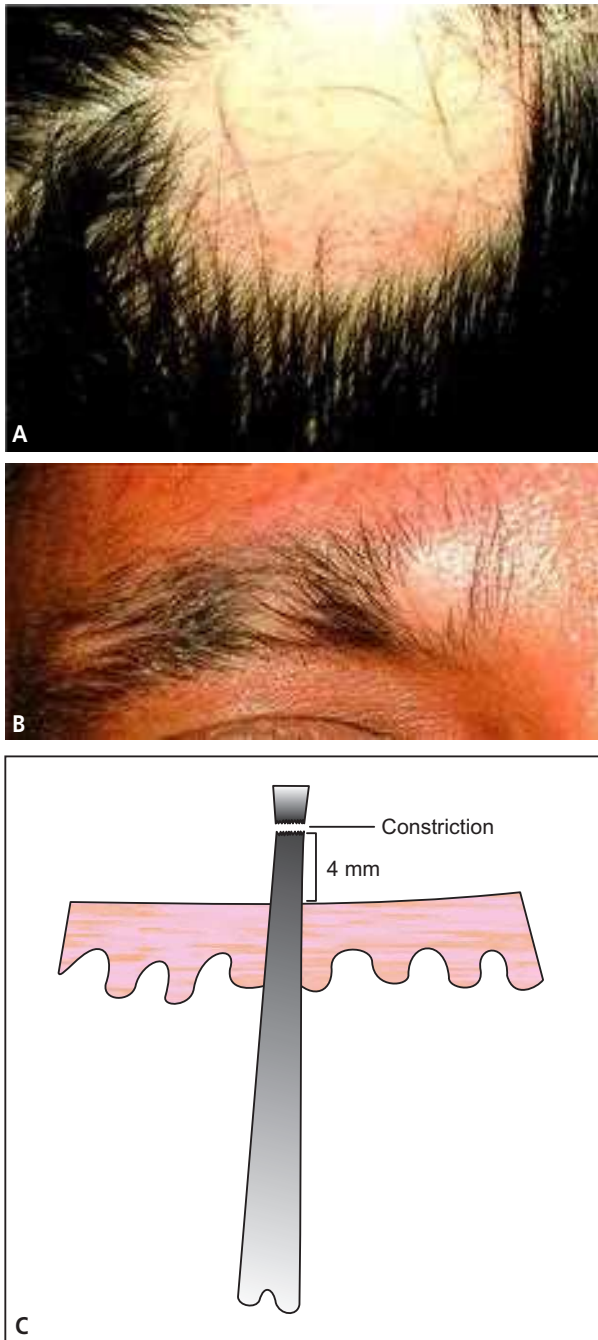


Fig. 7.29. Alopecia areata: A: alopecia with no scaling or inflammation or scarring, Exclamation mark hair, pathognomonic of alopecia areata present. B: multiple patches of alopecia areata of eyebrows. C: exclamation mark hair is constricted just above the skin surface.

Course

Course of AA is not predictable.

- ❖ Single lesions usually recover within a few

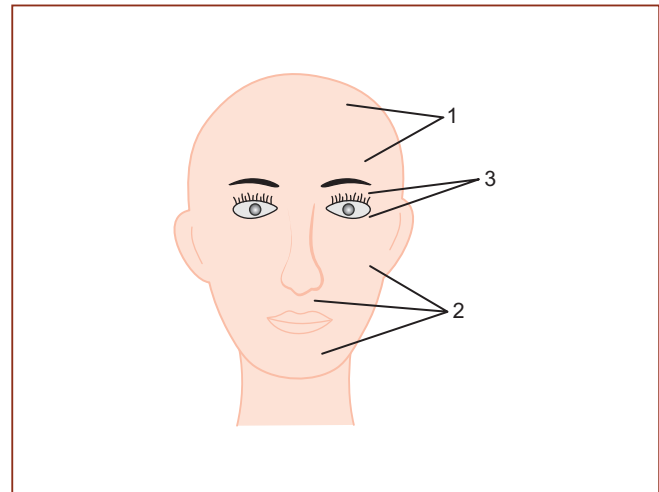


Fig. 7.30. Sites of alopecia areata: scalp is most frequently involved, followed by beard and mustache area.

months. Regrowth begins at the center of the lesion and initially the “new” hair is fine and gray (Fig. 7.33), but gradually regains normal thickness and color. In elderly, the “regrown” hair may remain gray.

- ❖ If the lesions recur or more lesions appear, the regrowth is slower. Recovery in some patches may occur along with progress of the disease in other areas.
- ❖ **Poor prognostic features:**
 - Early (childhood) onset.
 - Associated history of atopy.
 - Widespread alopecia (alopecia totalis and universalis).
 - Ophiasis.

Investigations

- ❖ Generally none needed.
- ❖ If suspected, rule out other autoimmune diseases.

Diagnosis

Points for diagnosis

Diagnosis of AA is based on:

- ❖ Presence of noncicatricial patch of hair loss with no inflammation (scaling, erythema, and papulation).
- ❖ Presence of exclamation mark hair at edge of the patch. Regrowth with gray hair, in center of lesion.

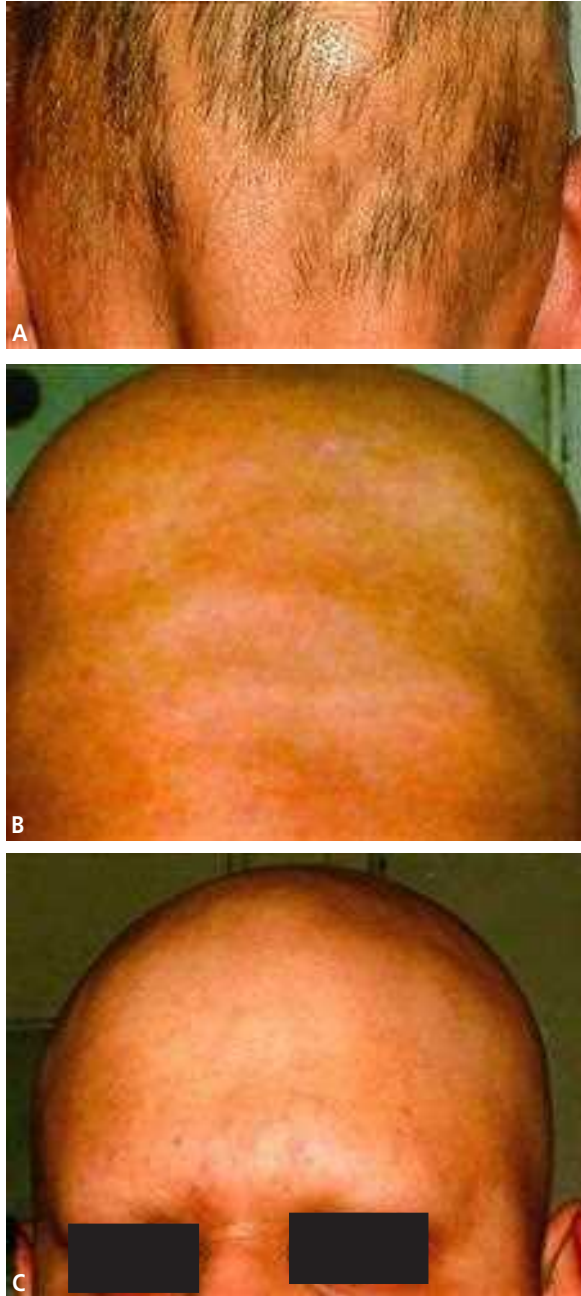


Fig. 7.31. Variants of alopecia areata: A: ophiasis, band-like hair loss. B: alopecia totalis, loss of hair from the whole scalp. C: alopecia universalis, alopecia of the whole body. Note loss of scalp hair, eyelashes and eyebrows.

- ❖ Commonly on scalp, sometimes beard, moustache, eyebrows, and eye lashes. Occasionally entire body.
- ❖ Nail changes.

Differential diagnosis

AA should be differentiated from:

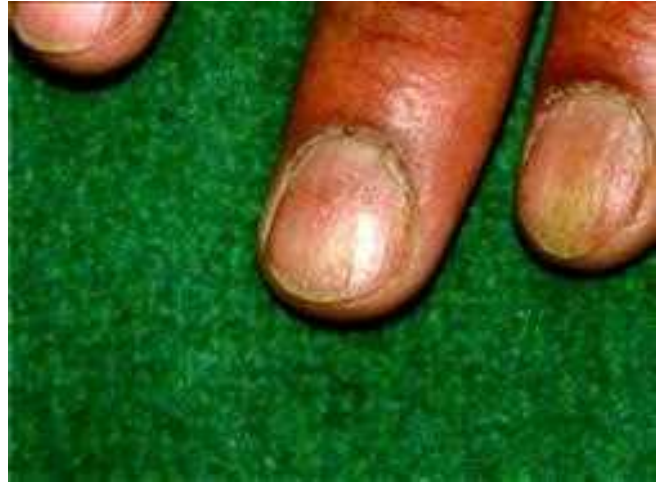

Fig. 7.32. Nails in alopecia areata: fine pitting and thinning of nail plate.

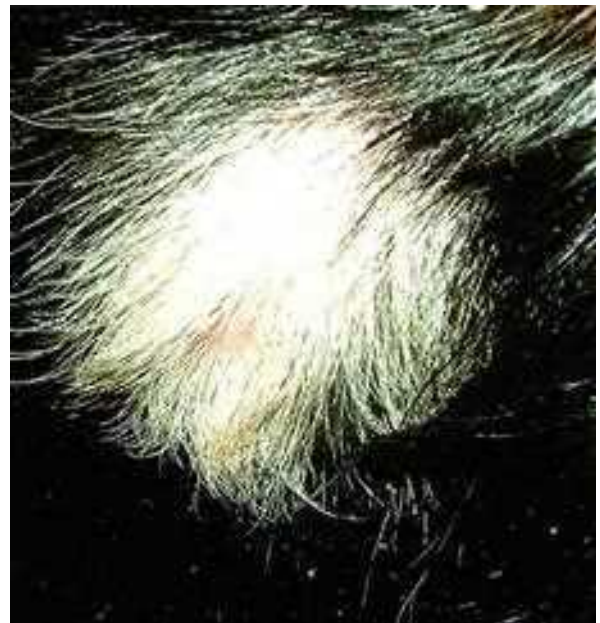

Fig. 7.33. Alopecia areata: regrowing hair is usually gray, at least initially.

a. Tinea capitis

<i>Tinea capitis</i>	AA
<i>Inflammation:</i> scaling and inflammation prominent	Absent
<i>Alopecia in centre:</i> complete	Incomplete
<i>Condition of hair:</i> hair remaining in patch lusterless and easily pluckable	Exclamation mark seen

b. Cicatricial alopecia

Cicatricial alopecia	AA
Hair follicles: destroyed, so hair loss irreversible	Not destroyed, so reversible
Skin: shiny and follicular openings absent	Follicular openings visible
Signs of inflammation: may be present	Absent
Associated features: evidence of lichen planus, discoid lupus, at other sites	Exclamation mark hair seen; regrowing hair gray

Treatment (Table 7.4)**Few lesions**

- ❖ **<6 months duration:** Observe, as spontaneous regrowth frequent.
- ❖ **>6 months duration:** Topical therapy with steroids, minoxidil, PUVA/PUVA sol.

Extensive lesions

- ❖ **Oral steroids:**
 - May be used, but withdrawal often results in a relapse.
 - Given as daily/weekly doses. Weekly doses of steroids given as **oral mini pulse**²³.
 - Associated with side effects.
- ❖ **Psoralens and UVA (PUVA):**
 - Used in extensive lesions.
 - Can be combined with oral steroids given as OMP in rapidly progressing and extensive lesions.
- ❖ Contact sensitizers like diphencyprone have shown promising results.
- ❖ Cosmetic cover in the form of wigs for alopecia totalis.

Androgenetic Alopecia (AGA)**Table 7.4.** Medical treatment of alopecia areata

Single/few lesions <6 months	Observe. Spontaneous recovery frequent
Single/few lesions >6 months or rapid progress	Topical steroids Topical minoxidil (2–5%) Topical psoralen +UVA/UVA sol
Extensive lesions Alopecia totalis/universalis	Oral steroids (can be given as OMP) ²³ Oral psoralens with UVA/UVA sol Contact sensitizers like diphencyprone

Synonym: Male pattern alopecia**Synopsis**

Etiology: Genetic predisposition and androgen dependent.

Males: Show typical pattern of hair loss.

Females: Present with diffuse hair loss.

Treatment in males: Topical minoxidil, low-dose oral finasteride (an antiandrogen), and surgery.

Treatment in females: Topical minoxidil, oral antiandrogens. Surgery less useful.

Etiology

Basic pathology is **miniaturization of hair follicles**²⁴.

Genetic

The exact mode of inheritance is not known, but gene association studies have identified association of AGA with polymorphism of androgen receptor gene on X chromosome.

Hormonal

- ❖ **Males:** Alopecia is distinctly androgen dependent. So does not develop in males castrated at puberty.
- ❖ **Females:** Though thought to develop in genetically strongly predisposed in presence of elevated androgens, most women diagnosed to have AGA **do not** have elevated circulating levels of androgens.

Clinical Features**Males**

- ❖ Terminal hair is replaced by fine vellus hair.
- ❖ Different **patterns of hair loss**²⁵ in males are shown in Fig. 7.34.

Females

- ❖ Terminal hair is replaced by fine vellus hair.
- ❖ Hair loss in women may be diffuse often initially manifesting as widening of the central parting (Figs. 7.35A and B).

Course

- ❖ Some patients develop the alopecia early in life while others develop alopecia later and the inheritance of the two conditions may be distinct.

23. **Oral mini pulse:** also known as OMP; entails use of weekly oral steroids (usually betamethasone) with view to reduce side effects of steroids without compromising the response. Given as betamethasone initially 5 mg once or twice a week, then tapered gradually.

24. **Miniaturization of hair follicles:** progressive transformation of terminal hair follicles into vellus follicles.

25. **Pattern of hair loss:** in males goes by the Hamilton–Norwood grading and in females by Ludwig grading.




Fig. 7.34. Androgenetic alopecia: patterns of hair loss in males (Hamilton Norwood grading).

- ❖ Hair loss is progressive with a tendency to follow similar pattern in family members.

Associations

- ❖ In women, features of hyperandrogenism may be present in the form of hirsutism, acne, and clitoromegaly.
- ❖ Always rule out polycystic ovary disease (PCOD).

Investigations

- ❖ **Males:** No investigations required.
- ❖ **Females:** Most women with AGA, do not have other evidence of virilization. However, full evaluation to rule out an androgen secreting pathology desirable if:
 - Hair loss sudden in onset, rapidly progressive and advanced.
 - AGA accompanied by menstrual disturbances, hirsutism, or recrudescence of acne

Diagnosis

Males

AGA in males has a typical presentation.

Females

AGA in females should be differentiated from other causes of diffuse hair loss like chronic telogen effluvium.

Treatment

Men

Topical minoxidil (2–5%)

- ❖ Slows hair loss and may even stimulate growth of new hair.
- ❖ Hair growth is temporary because if medication is withdrawn the hair fall restarts. So it is important to ensure, before initiating therapy, that

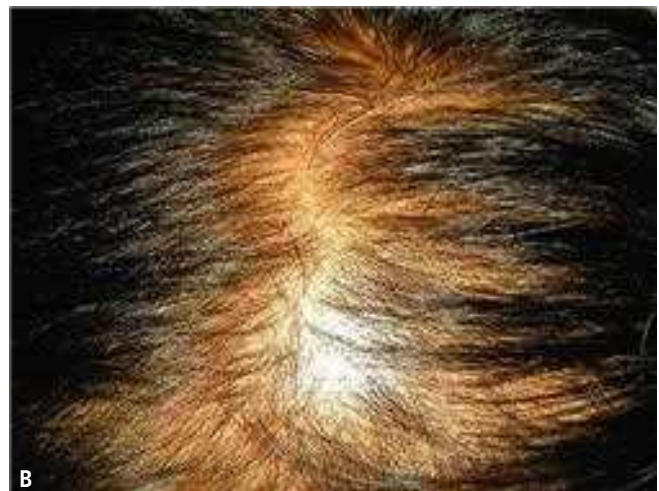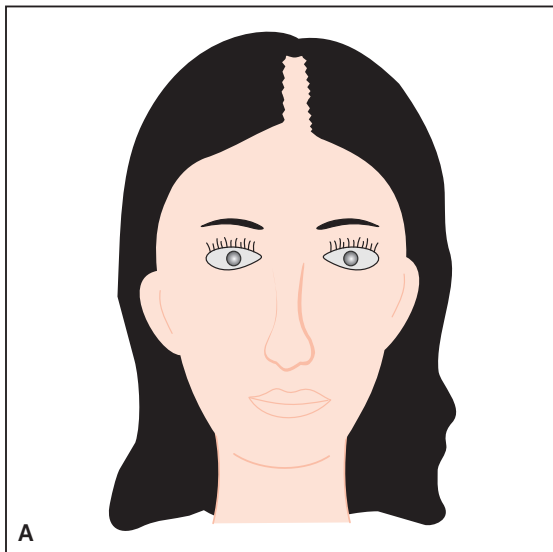


Fig. 7.35. Androgenetic alopecia in females: A: diagrammatic representation. B: initially appears as widening of central parting.

patient is motivated enough to apply minoxidil for life.

Antiandrogens

- ❖ Should be used cautiously in males.
- ❖ Finasteride (1 mg daily), a 5 α -dihydrotestosterone reductase inhibitor has been used successfully in male patients with minimal side effects.

Surgery

- ❖ Surgical procedures are based on the principle of **donor dominance**²⁶.
- ❖ Attempts to relocate occipital hair over the alopecic scalp.
- ❖ Techniques used are **follicular unit transplantation** and **follicular unit extraction**.

Wigs

Ordinary wigs are used. Or techniques to weave small wigs with the existing hairs have been used.

Women

Topical minoxidil (2–5%)

May be as effective (or ineffective!) as in males.

Systemic antiandrogens

- ❖ Antiandrogens like finasteride, cyproterone acetate (with ethinyl estradiol), and spironolactone have been used with some success.
- ❖ More effective in women with evidence of hyperandrogenism.

Surgery

Since the alopecia is diffuse, surgical techniques are not helpful in females.

Miscellaneous Causes of Alopecia

Telogen Effluvium

Etiology

- ❖ Hair follicles pass through three phases (anagen, catagen, and telogen).
- ❖ Adjoining hair follicles are not synchronous in their cycle, but sometimes anagen (growth) phase of several adjoining hair follicles is aborted and all enter telogen (resting) phase at the same time. All these hair are then shed simultaneously and this is called telogen effluvium.
- ❖ Several triggers can precipitate telogen effluvium (Table 7.5).

Table 7.5. Etiology of telogen effluvium

Infections	Typhoid, malaria, dengue, chikungunya
Childbirth	Especially prolonged and difficult
Surgical trauma	Minor/major surgery
Hemorrhage	Surgical, traumatic
Emotional stress	Examinations, marital discord

Clinical features

- ❖ Varying degrees of diffuse hair loss, occurring 2–3 months after precipitating stimulus.
- ❖ Severe cases associated with anemia and **Beau's lines** of the nails.
- ❖ **Chronic telogen effluvium (CTE)**:
 - Is idiopathic.
 - Occurs in women, 40–50 years of age.
 - Shedding develops insidiously and persists for >6 months. Patient complains of losing >100 hairs over long periods, resulting in reduced volume of hair.
 - No widening of parting and no miniaturizing of hair follicles.

Investigations

- ❖ A detailed history and examination is usually adequate. About 25% of patients do not give history of antecedent illness.
- ❖ **Trichogram**: If done, shows telogen count of 25%.

Treatment

- ❖ Time is a great healer. Hair fall stops spontaneously in 2–3 months, though hair growth which follows may be incomplete.
- ❖ **CTE**: Minoxidil, 2% may be tried.

Traction Alopecia

Etiology

Constant or prolonged traction due to:

- ❖ Tight hair styles, *e.g.*, in India in Sikh males (and females) due to tight hair styling; school going girls who wear tight hair styles, like ponytail.
- ❖ Hot combing (to straighten curly hair), so in Negroes.

Clinical features

Presentation

- ❖ Area of alopecia shows short broken hair (Figs. 7.36A and B).

26. **Donor dominance**: implies that the hair which is transplanted from occipital region retains its insensitivity to androgens, *i.e.*, does not miniaturize even when transplanted.

- ❖ Folliculitis (inflammation of hair follicle) may be seen, especially in those with curly hair.

Sites

Depends on the hair style; usually in the frontal area or on the margin of scalp, which is the area of maximum traction.

Progress

Reversible in the early stages.

Diagnosis

The diagnosis is based on:

- ❖ Pattern of hair loss.
- ❖ Tight hair styles.
- ❖ Absence of exclamation mark hairs and scaling, but presence of folliculitis.

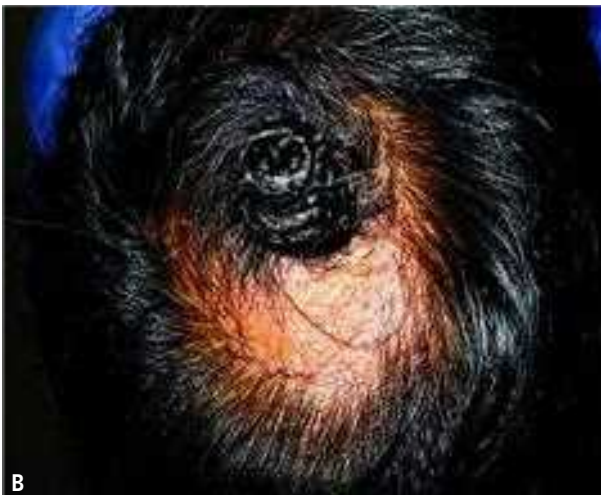
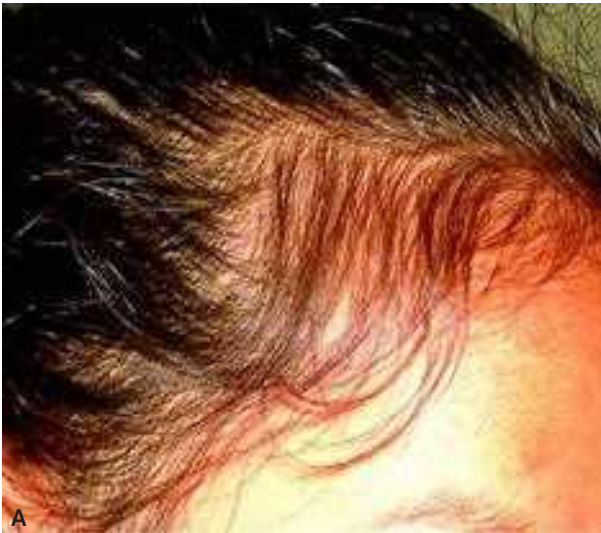
Fig. 7.36. Traction alopecia: A and B: short broken hair, at sites of traction.

Treatment

Patient should change hair style.

Trichotillomania

- ❖ A hair pulling tic.
- ❖ Patients usually young women, pull hair, often to relieve pain.
- ❖ Present with patch of alopecia with hairs of different lengths growing in different directions (Fig. 7.37).
- ❖ Psychiatric evaluation and management required.

Patchy Hair Loss Due to Skin Diseases

Scalp infections

- ❖ **Bacterial folliculitis:** May be followed by small areas of nonscarring and rarely scarring alopecia.
- ❖ **Tinea capitis**²⁷: Causes noncicatricial alopecia. Rarely cicatricial alopecia (kerion, favus).

Papulosquamous disorders

- ❖ **Lichen planus:** Results in scarring alopecia (Fig. 7.38).
- ❖ **Discoid lupus erythematosus:** Causes cicatricial alopecia.
- ❖ **Psoriasis:** Does not usually cause alopecia; if it occurs, the alopecia is reversible.

Cicatricial Alopecia

- ❖ Cicatricial alopecia is permanent hair loss due to destruction of hair follicles.

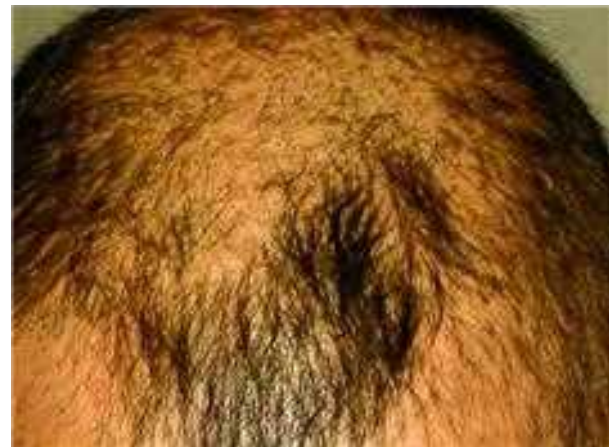

Fig. 7.37. Trichotillomania: patchy hair loss. Typically hair of different lengths and growing in different directions present in the patch.

27. **Tinea capitis:** is dermatophytic (fungal) infection of scalp.

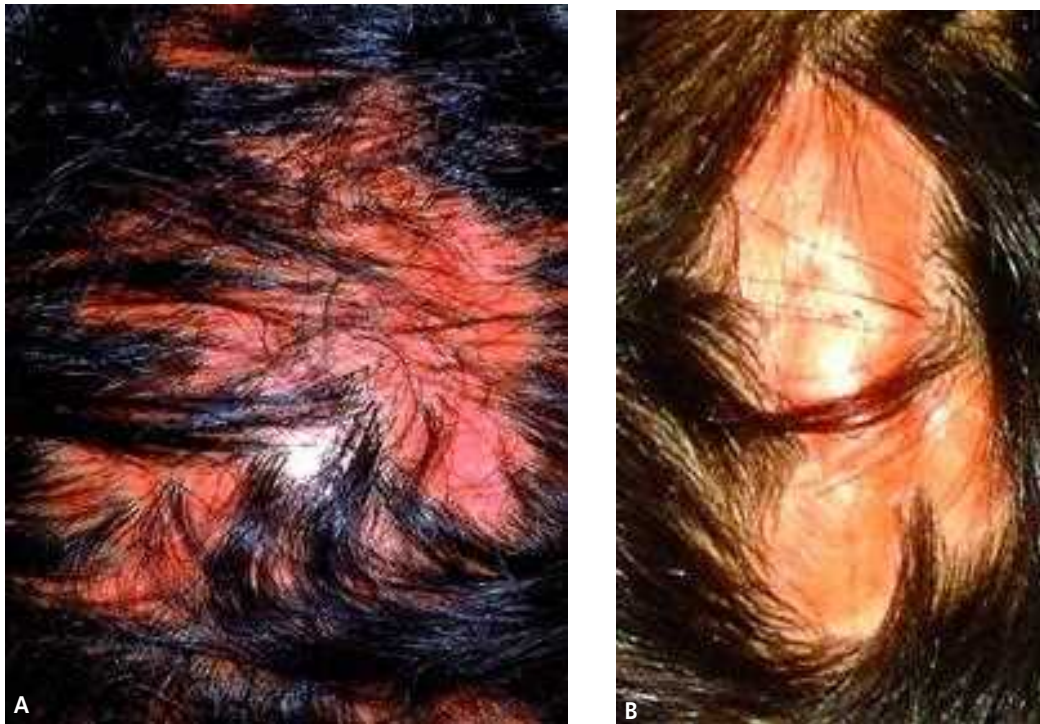


Fig. 7.38. Cicatricial alopecia: A: pseudopelade of Brocq, scarring alopecia which presents as patches of cicatricial alopecia with “foot prints in snow” appearance. B: due to aplasia cutis, present since birth.

- ❖ There are several known causes of cicatricial alopecia (Fig. 7.28; P. 129). Of these, lichen planopilaris and discoid lupus erythematosus are the commonest.
- ❖ **Pseudopelade of Brocq:** A scarring alopecia for which no cause identified. Presents as patches of cicatricial alopecia with “**foot prints in snow**” appearance.
- ❖ Differentiation from noncicatricial alopecia is important (Table 7.3; P. 130).
- ❖ Treatment:
 - Treat primary disorder.
 - Since hair loss permanent, hair transplantation or use wigs.

Hirsutism

Synopsis

Definition: Presence (in women) of terminal hair in distribution which is androgen dependent.

Etiology: Most cases idiopathic, familial or racial; only occasionally associated with androgen secreting tumors.

Clinical features: Only diagnosed in females. Terminal hairs in distribution of male.

Investigations: Significant hormonal changes not seen in patients with normal menstrual cycle. Full endocrinological evaluation is needed only for hirsutism associated with menstrual irregularities and virilization.

Treatment: Cosmetic treatment mainstay; some benefit with systemic antiandrogen treatment.

Hirsutism is presence (in women) of terminal hair in distribution which is androgen dependent.

Etiology

The causes of hirsutism are shown in Table 7.6. However, in many women, no cause can be identified.

Clinical Features

- ❖ Excess growth of terminal hair in beard area, (Fig. 7.39A) mustache, chest, shoulder tips, periareolar, and infraumbilical region (Fig. 7.39B).
- ❖ Begins at puberty and progresses with age.
- ❖ Androgenetic alopecia, acne, menstrual irregularities, infertility, weight gain, and virilization may be present.

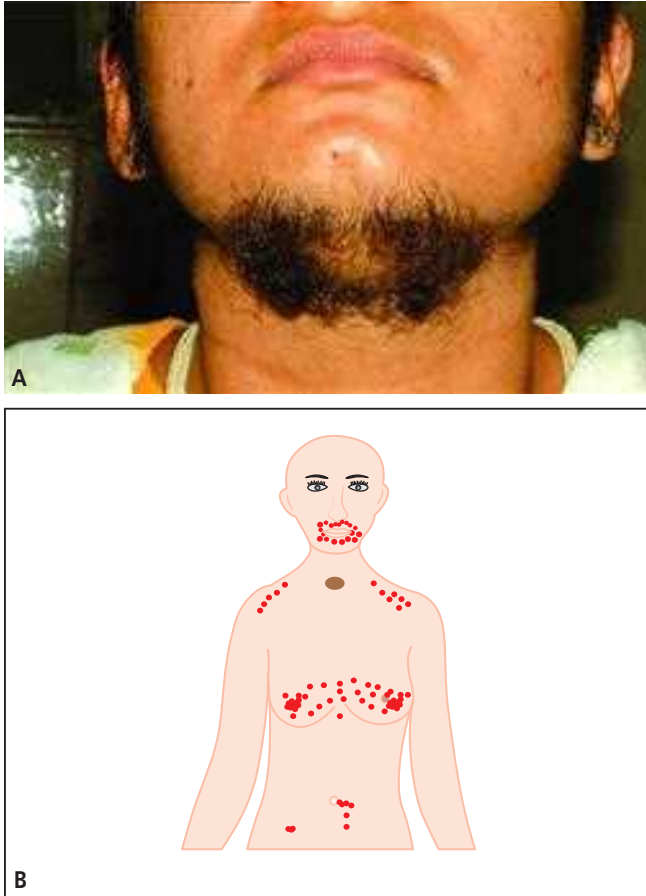


Fig. 7.39. Hirsutism: A: terminal hair in the beard region. B: distribution of terminal hair in hirsutism.

Investigations

Extensive investigations are required, only if there is history of:

- ❖ Rapid weight gain.
- ❖ Menstrual irregularities.
- ❖ Virilization of early onset with rapid progress.

Tests done in such cases include:

- ❖ Gynecological evaluation, including pelvic ultrasound for ovarian size.
- ❖ Levels of circulating testosterone and other androgens, sex-hormone binding globulin, estrogen, progesterone, and prolactin.

Treatment

- ❖ Treat underlying disorder.
- ❖ **Cosmetic procedures**²⁸: Procedures like bleaching, waxing, and thermolysis help in improving cosmetic appearance.

Table 7.6. Etiology of hirsutism

1. Racial		
2. Familial		
3. Hormonal	Ovarian	Menopause Polycystic ovaries Arrhenoblastoma
	Adrenal	Cushing syndrome Virilizing tumors Adrenogenital syndrome Acromegaly
	Pituitary	Hyperprolactinemia
4. Iatrogenic		Anabolic steroids Progesterone

- ❖ **Antiandrogens:** Cyproterone acetate, spironolactone, finasteride, and flutamide have been used.
- ❖ **Eflornithine:** Used topically, reduces hair growth.
- ❖ **Laser therapy:** Two lasers which are useful in hair removal are diode laser (for lighter hair) and Q-switched Nd:YAG laser (for darker hair).

Hypertrichosis (Table 7.7)

- ❖ Hypertrichosis is excessive growth of terminal hairs, but one which does not follow an androgen-induced pattern (Figs. 7.40A and B).
- ❖ Localized and generalized varieties are recognized (Table 7.7).

Table 7.7. Causes of hypertrichosis

Localized	Spinal dysraphism (Fig. 7.40A) Melanocytic nevi Postinflammatory
Generalized	Hypertrichosis lanuginosa (Fig. 7.40B) (congenital, acquired) Drugs (minoxidil, corticosteroids, psoralens, phenytoin) Hepatic porphyrias

Disorders of Nails

Structure

Anatomy (Fig. 7.41)

- ❖ **Nail plate:** Is made of hard keratin and is produced by nail matrix. It grows from the matrix, over the nail bed terminating at the free margin.

28. **Cosmetic procedures:** the simplest way to get rid of unsightly hair is shaving. However, this has two main disadvantages: hair becomes visible within 24-48 hours and appears as a stubble. However, the belief that shaving increases hair growth is totally misplaced.

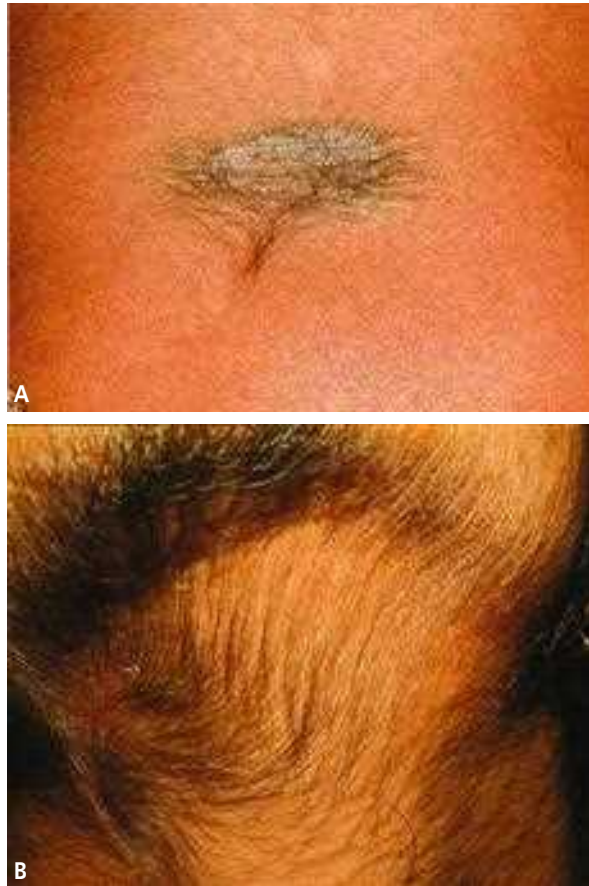

Fig. 7.40. Hypertrichosis: A: localized hypertrichosis: localized area of terminal hair over spinal dysraphism; B: generalized hypertrichosis: congenital hypertrichosis lanuginosa.

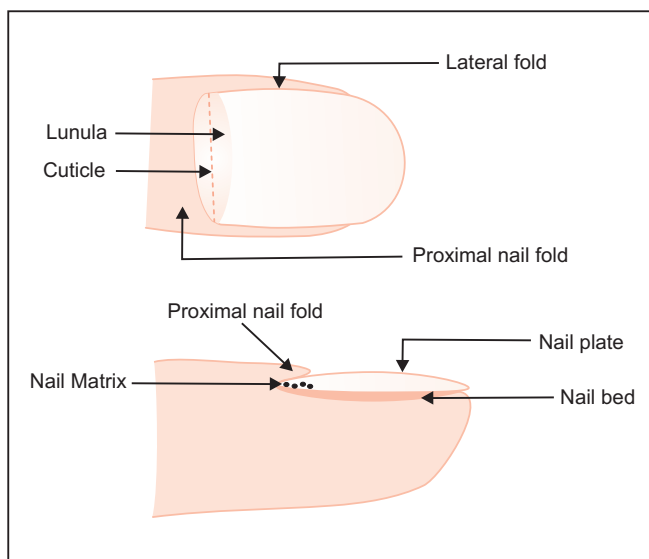


Fig. 7.41. Structure of nail.

- ❖ **Nail matrix:** Produces the nail plate. Rests under the proximal nail fold. **Lunula** is the visible white semicircular portion.
- ❖ **Nail bed:** Nail plate rests on the nail bed; the longitudinal ridges and grooves on the under-surface of the nail plate interdigitate with similar undulations on the dorsal aspect of the nail bed.
- ❖ **Nail folds:** Nail plate is surrounded by nail folds on three sides (the proximal nail fold and two lateral nail folds).
- ❖ **Cuticle:** Is a thin extension of skin of the proximal nail fold onto the nail plate. The cuticle seals the potential blind space (between the nail fold and nail plate) which would otherwise harbor microorganisms and cause problems.

Growth

- ❖ Finger nails grow about 1 mm/week while toe nails grow slower than finger nails.
- ❖ Growth of nails gradually decreases with age.

Disorders of Nails

- ❖ Diseases of nails predominantly cause cosmetic disfigurement, though some may be symptomatic. Sometimes changes in nails help to corroborate diagnosis of a skin disease or be a clue to systemic disease.
- ❖ Diseases of nails are classified as:
 - Congenital.
 - Traumatic.
 - Infectious.
 - Neoplastic.
 - Secondary to dermatological disease.
 - Secondary to systemic disease.

Congenital Abnormalities of Nails

Congenital abnormalities of nail can occur as an isolated nail change or be part of a syndrome.

Pachyonychia congenita

- ❖ Rare, autosomal dominant disorder.
- ❖ Nails plates (Fig. 7.42A) are grossly thickened (tenting).
- ❖ Associated with thickening of skin on pressure points.
- ❖ Oral lesions in the form of leukoplakia (Fig. 7.42B).

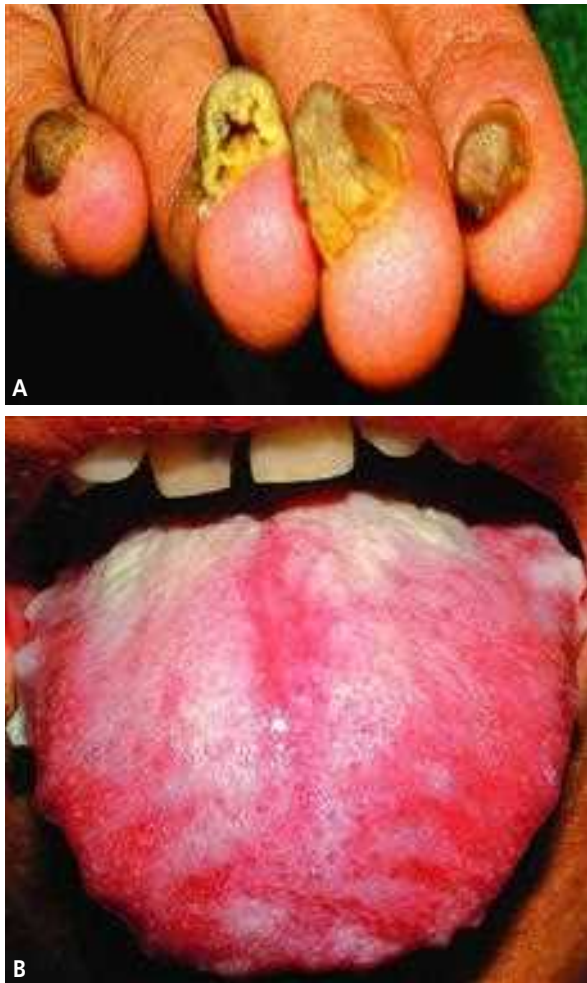


Fig. 7.42. Pachyonychia congenita: A: tenting of nail plate present since birth. B: leucoplakia.

Nail Changes Due to Trauma

Splinter hemorrhages

- ❖ Linear hemorrhages are seen under the nails of manual workers due to minor trauma.
- ❖ Also seen in psoriasis of nail and subacute bacterial endocarditis.

Subungual hematomas

- ❖ Caused by trauma (often trivial), especially around the nail fold.
- ❖ Dark areas of altered blood move distally as the nail grows.
- ❖ Differentiate from subungual melanoma.

Chronic injury

Pressure and injury from ill-fitting shoes can result in several changes:

- ❖ **Onychogryphosis:** Gross thickening and curving of nail.

- ❖ **Ingrowing toe nail:** Compounded by improper cutting of nails, when a tiny spicule of nail embeds into the lateral nail fold.
- ❖ **Onycholysis:** Separation of the nail plate from nail bed.

Changes due to nervous tics

Nail biting

Nail biting is frequently encountered not only in children but also in adults. Nails which are bitten:

- ❖ Are short and irregular.
- ❖ Have frayed cuticles.

Tic dystrophy

- ❖ Habit of picking cuticle of nail or repeatedly rubbing it.
- ❖ Causes a groove in the center of the nail plate with transverse ridges radiating from the groove, similar to a ladder (Fig. 7.43A).

Chemical injury

Nails can be damaged by several chemicals.

- ❖ **Detergents:** Detergents and wet work cause lamellar splitting of distal end of nail plate

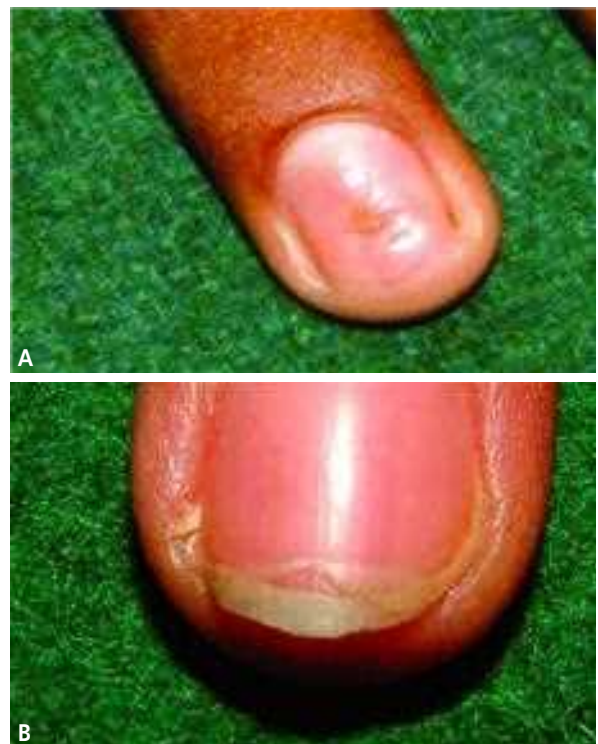

Fig. 7.43. Changes in nails due to injury. A: tic dystrophy, with groove in center of the nail plate with transverse ridges radiating from the groove. B: lamellar dystrophy: splitting of distal end of nail plate into layers.

(Fig. 7.43B). It is frequently seen in housewives, bakers, cooks, and hair dressers.

- ❖ **Cosmetics:** Adhesives of artificial nails and formaldehyde in nail hardeners can damage the nail plate.

Infections

Onychomycosis

Onychomycosis is fungal infection of nails *cf.*, **tinea unguium**²⁹.

Etiology

- ❖ **Dermatophytes:** Caused by one of the following three dermatophytes:
 - *Trichophyton rubrum* (commonest and most resistant to treatment).
 - *Trichophyton mentagrophytes: var interdigitale*.
 - *Epidermophyton floccosum*.
- ❖ **Other fungi:** Like candida

Clinical features (Fig. 7.44)

- ❖ **Morphology:**
 - Nail plate is yellow and thick and crumbles easily (so is tunneled). There is subungual hyperkeratosis, which is friable.

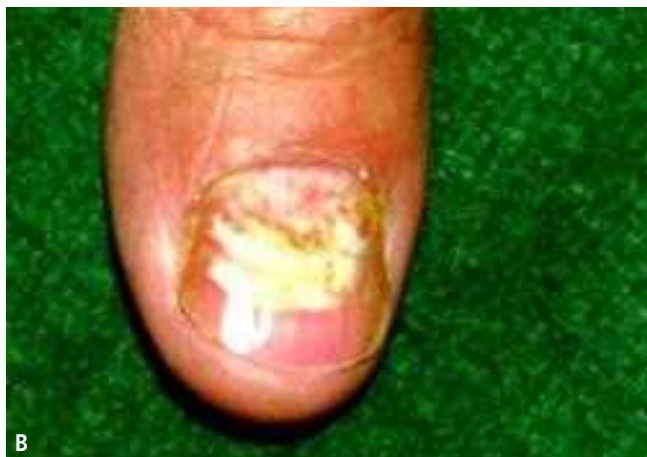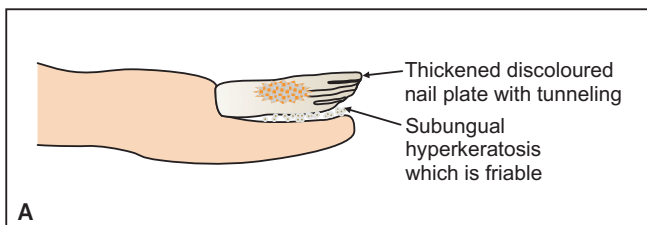


Fig. 7.44. Tinea unguium: A and B: thick, tunneled, discolored nail plate with onycholysis.

- Involvement starts at the distal edge and spreads proximally.

- ❖ **Sites of involvement:** Toe nails more frequently involved than finger nails and only a few nails are asymmetrically affected.

❖ Associations:

- *Finger nail involvement:* with tinea cruris.
- *Toe nail involvement:* with tinea pedis.

Diagnosis

Onychomycosis should be differentiated from:

a. Psoriasis of nails

Psoriasis of nails	Onychomycosis
<i>Symmetry:</i> symmetrical involvement of several nails	Asymmetrical involvement of few nails
<i>Site:</i> begins proximally	Usually begins distally
<i>Pitting:</i> very frequent	Not seen
<i>Nail plate:</i> thickened and discolored	Thickened, discolored and tunneled
<i>Subungual debris:</i> does not crumble because it is firm	Friable

Investigations

- ❖ Potassium hydroxide preparation of nail clippings shows fungal hyphae.
- ❖ Culture for fungus.

Treatment

- ❖ Therapy with systemic terbinafine (if dermatophytes on culture) or itraconazole (if no culture available or non dermatophytes on culture) is necessary, if disease is symptomatic or cosmetically disfiguring.
- ❖ Topical therapy (amorolfine/ciclopirox) useful if single nail involved in distal half.

Paronychia

Paronychia is inflammation of nail folds and could be acute or chronic.

Acute paronychia

❖ Etiology:

- Staphylococcus enters the nail fold (through breaks in the skin of nail fold or cuticle).
- *Predisposing factors:* including chronic paronychia, nail biting, and hang nails.

❖ Clinical features:

- Nail fold is swollen, red, and tender.
- Pus may be visible under the nail fold or on the nail bed.

29. **Onychomycosis:** refers to infection of nails by any fungus. Tinea unguium, on the other hand, is one type of onychomycosis which is caused by dermatophytes.

- May be associated with lymphadenopathy and constitutional symptoms.

❖ **Treatment:**

- Systemic antistaphylococcal antibiotics (erythromycin and cloxacillin)
- If need be, surgical drainage.

Chronic paronychia

❖ Is an inflammatory dermatosis of nail folds with secondary effects on the nail matrix and nail growth.

❖ **Etiology:**

- **Microbial colonization**³⁰: the space between nail plate and proximal nail fold is colonized by *Candida*, *Staphylococcus*, and Gram-negative bacteria.
- **Predisposing factors:**
 - Wet work (prolonged immersion of hands in water), so frequently seen in housewives, bakers, hair dressers, and domestic helps.
 - Thumb (finger) sucking.
 - Diabetes mellitus.
 - Candidal vulvovaginitis.
 - Vigorous pushing back of cuticle (as done during manicures).

❖ **Clinical features:**

- Nail fold is swollen and rolled (Fig. 7.45).
- Sometimes a bead of pus can be expressed from under the nail fold.
- Over a period of time, adjacent nail plate becomes ridged and discolored.

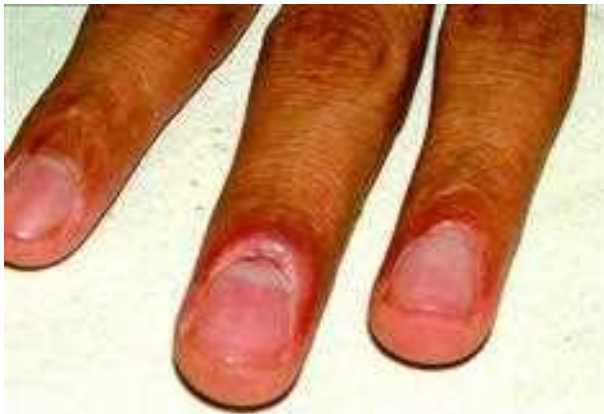

Fig. 7.45. Chronic paronychia: tender, swollen and rolled proximal nail fold. Note loss of cuticular extension.

❖ **Investigations:** The following should be ruled out:

- Diabetes mellitus.
- Vaginal candidal infection.
- Secondary bacterial infection.

❖ **Diagnosis:** Paronychia should be differentiated from dermatophytic infection of nail plate.

❖ **Treatment**

- **Preventive measures:** Are important.
 - Avoid prolonged exposure to wet work.
 - Use protective **rubber gloves**³¹ whenever prolonged exposure to water is expected.
 - Control predisposing factors like diabetes.
- **Therapeutic measures:**
 - Topical antibiotics (gentamycin, ciprofloxacin), and antifungal (clotrimazole) preferably in lotion formulations.
 - Systemic antibiotics may help in more inflamed lesions.
 - Weekly fluconazole, 150 mg, in recurrent disease.

Nails in Skin Diseases

Psoriasis (Fig. 7.46)

Nails are involved in 50% patients with psoriasis and several changes are seen:

❖ **Pits:** Is the most frequent change.

- Pitting in nail psoriasis is deeper (than alopecia areata) and irregular.
- Pitting of nails also occurs in several other skin diseases (Table 7.8).

❖ **Subungual hyperkeratosis:** This is due to psoriasis of the nail bed. Subungual hyperkeratosis is also seen in tinea unguium but in this, the hyperkeratosis is friable, tunneled, and easily removable and fungal hyphae can be demonstrated in the debris using a potassium hydroxide mount.

Table 7.8. Causes of pitting of nails

Psoriasis	Deeper, irregular pits
Alopecia areata	Finer pits; lunula mottled
Dermatitis	Irregular pits accompanied by cross ridges
Idiopathic	

30. **Space between the nail fold and nail plate:** is normally sealed by the cuticular extension over the nail plate.

31. **Use of rubber gloves:** this should be advised cautiously because if the water trickles into the glove (as it often does), the condition can get aggravated.

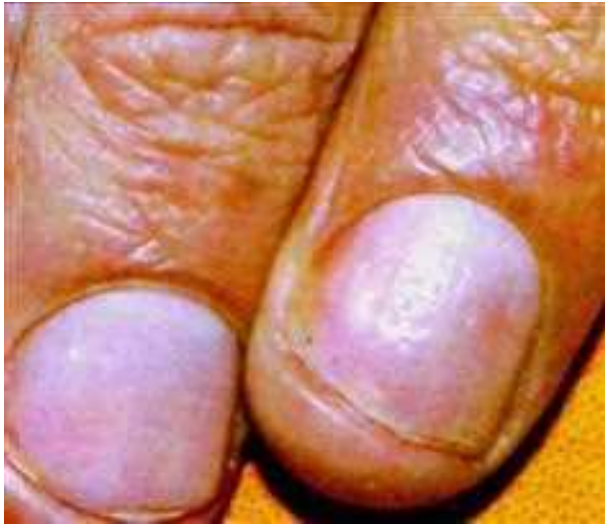

Fig. 7.46. Psoriatic nails: coarse pitting of the nails is the most frequent change.

- ❖ **Other changes:** Other changes seen are:
 - *Onycholysis:* Separation of the distal nail plate from the nail bed is frequent.
 - *Nail plate thickening and yellowish discoloration*
 - *Oil spots:* yellow red discoloration in centre of nail. Very typical of psoriasis

Lichen planus

- ❖ Ten percent of patients with lichen planus have nail changes.
- ❖ Thinning of the nail plate along with discoloration and irregular longitudinal grooves and ridges is the commonest change.
- ❖ **Pterygium**³²: Prolongation of the proximal nail fold onto the nail bed, splitting, and subsequent destruction of the nail. Seen in severe cases. (Fig. 7.47).

Dermatitis

- ❖ Nail involvement occurs if dermatitis involves proximal nail fold.
- ❖ Changes seen include pitting (which is coarse), discoloration of nails, and deep irregular cross ridges (Fig. 7.48). Move distally, as the nail grows.

Trachyonychia

- ❖ Presents as a grey rough surface (Fig. 7.49) affecting all nail plates (hence **20-nail dystrophy**).
- ❖ Mainly associated with alopecia areata, psoriasis, and lichen planus.

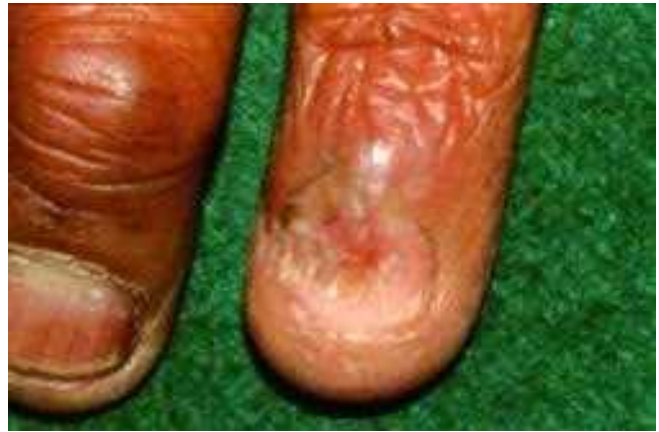

Fig. 7.47. Lichen planus of nails: pterygium of the nail is formed when the proximal nail fold extends onto and fuses with the nail bed, resulting in destruction of nail.

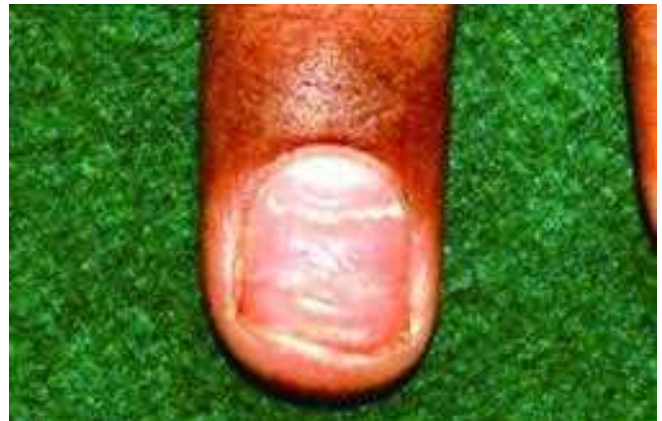

Fig. 7.48. Pitting of nails in dermatitis: note the coarse pitting and deep irregular cross ridging.

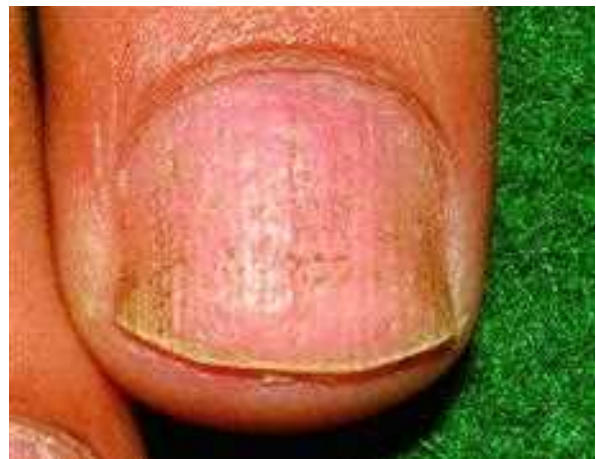

Fig. 7.49. Trachyonychia: presents as a grey rough surface of plates, affecting all 20 nail plates.

32. **Pterygium:** wing-shaped. Remember, pterygium in the eye and pterygoid process of sphenoid bone are both wing shaped.

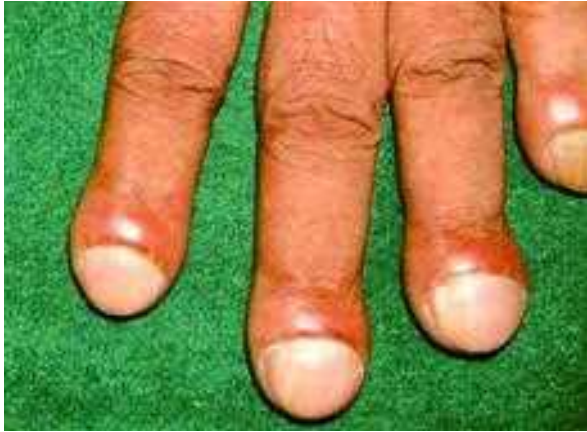

Fig. 7.50. Clubbing of nails: loss of angle of the nail.

- ❖ Self-limiting in children.
- ❖ May respond (usually temporarily) to potent topical, locally injected, and systemic steroids.

Nails in Systemic Diseases

Nails may provide a clue to systemic diseases.

Clubbing

- ❖ Bulbous enlargement of terminal phalanx with an increase in the angle between the nail plate and nail fold (Fig. 7.50).
- ❖ Seen in chronic lung disease, cyanotic heart disease; rarely familial.

Color changes

Leuconychia

- ❖ Nails are white.
- ❖ Associated with hypoalbuminemia like cirrhosis of liver.

Melanonychia

- ❖ Nails are pigmented.
- ❖ Due to nevi, malignant melanoma and drugs (phenothiazines, chloroquine and minocycline).

Half and half nails

- ❖ Proximal half of nail is white and the distal half brown or red (Fig. 7.51); seen in patients with chronic renal failure.
- ❖ **Terry's nails:** Proximal 4/5th of nail is white while distal tip is normal; seen in liver disease.

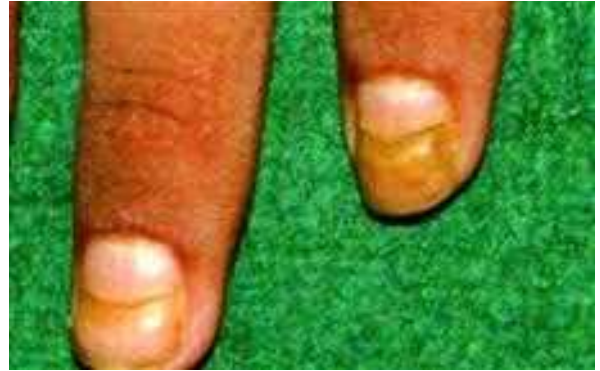

Fig. 7.51. Half and half nail: proximal part of nail plate is white and distal part brown. Seen in renal disease.

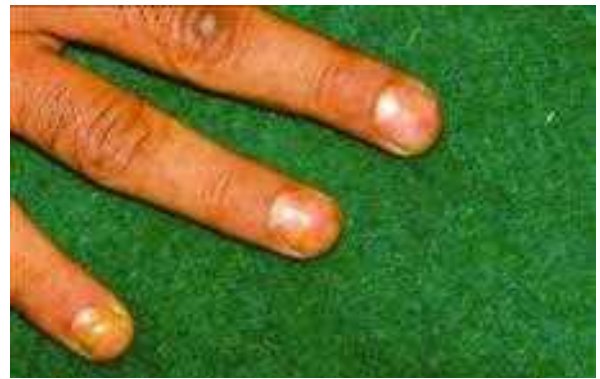

Fig. 7.52. Beau's lines: transverse grooves present in all nails.

Deformities of nail plate

Koilonychia

- ❖ Nail plate is thin and in severe cases there may be spooning of the nail.
- ❖ Associated with iron deficiency anemia.

Beau's lines

- ❖ Transverse grooves appear simultaneously on all nail plates (Fig. 7.52). The grooves move distally as nail grows, and disappear in 6 months.
- ❖ Seen a few weeks after any severe and acute illness.

Nail fold changes

- ❖ Telangiectasia, erythema, and thrombosed capillaries may be seen in connective tissue diseases.
- ❖ Cuticles may be frayed in connective tissue diseases, in nail biters, and due to cosmetics.

Chapter Outline

Basis of Skin Color

Normal skin pigments[○]

Abnormal skin pigments[○]

Pathogenesis of Pigmentary Disorders

Pathogenesis of hypopigmentation[○]

Pathogenesis of hyperpigmentation[○]

Disorders of Hypopigmentation

Oculocutaneous albinism[○]

Piebaldism[○]

Vitiligo[●]

Postinflammatory hypopigmentation[○]

Disorders of Hyperpigmentation

Melasma[●]

Freckles[●]

Lentigines[○]

Hyperpigmentation due to endocrine disorders[○]

Hyperpigmentation due to drugs[○]

Basis of Skin Color

- ❖ Skin color depends mainly on:
 - Pigments present in the skin.
 - Apart from pigments, blood flow in skin also determines its color.
- ❖ Pigments in skin may be:
 - Those normally present in skin.
 - Those which are not normally present in the skin.

Pigments Normally Present in Skin

- ❖ Skin color depends on the presence of several **chromophores** (Table 8.1).
- ❖ **Melanin**, synthesized by **melanocytes**, is the most important pigment.

Table 8.1. Pigments normally present in skin

Chromophore	Color
Melanin <ul style="list-style-type: none">• In epidermis• In dermis	Brown Blue
Oxyhemoglobin	Red
Deoxygenated hemoglobin	Blue

Melanocytes

- ❖ Melanocytes are present in basal layer of epidermis and their dendrites interdigitate with keratinocytes.
- ❖ A melanocyte with a number of associated keratinocytes (about 36) forms an **epidermal melanin unit** (Fig. 8.1).
- ❖ Melanocytes contain discrete organelles called **melanosomes**, which synthesize melanin.
- ❖ There are two types of melanin:
 - Brown-black **eumelanin** is present in spherical melanosomes.

[●]Should know

[○]Good to know

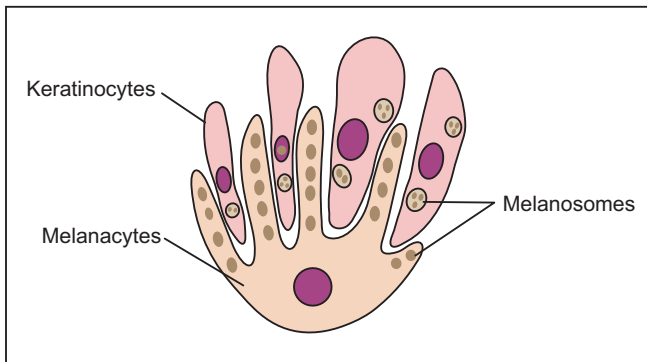


Fig. 8.1. Epidermal melanin unit: dendrites of one melanocyte interdigitates with about 36 keratinocytes.

- Red-brown or yellow **pheomelanin** is present in ovoid melanosomes.
- ❖ Once formed, the melanosomes are injected into the keratinocytes by dendrites of melanocytes.

Melanogenesis

Steps of melanogenesis

The steps of **melanogenesis** (melanin synthesis) are shown in Fig. 8.2.

Control of melanogenesis

Synthesis of melanin is influenced by:

- ❖ **Constitutional skin color:** The darker skin colors are dark, not because they contain more

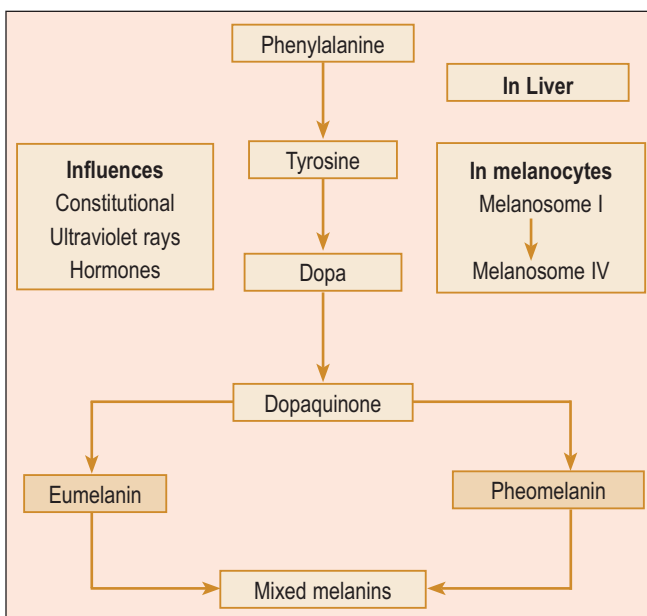


Fig. 8.2. Synthesis of melanin.

melanocytes but because their melanocytes produce more melanosomes, which are larger and are broken down less rapidly than those of the Caucasoids. So, the number of melanocytes in the darker races and Caucasoids is not different, but their activity is.

- ❖ **Ultraviolet radiation (UVR):** The most important stimulus for melanogenesis is UVR. Pigmentation induced by light (called **tanning**) occurs in two phases:
 - **Immediate pigmentation:** is caused by exposure to UVA and is due to:
 - Photo-oxidation of the preformed melanin.
 - Rearrangement of melanosomes.
 - **Delayed pigmentation:** is caused by exposure to both UVA and UVB and is due to:
 - Proliferation of melanocytes.
 - Increased tyrosinase activity.
 - Increased melanosome production.
 - Increased transfer of newly formed melanosomes from melanocytes to keratinocytes.
- ❖ **Hormones:**
 - Several hormones influence melanogenesis.
 - Most important is **melanocyte stimulating hormone** secreted by pituitary gland.

Abnormal Skin Pigments

- ❖ Sometimes pigments which are normally not present in skin, appear in skin and alter its color (Table 8.2).
- ❖ These pigments may be:
 - **Endogenous:** like hemosiderin.
 - **Exogenous:** like topical applications, dietary items, tattoos, etc.

Pathogenesis of Pigmentary Disorders

Pathogenesis of Hypopigmentation

Hypopigmentation of skin is of two types (Table 8.3):

- ❖ **Melanopenic¹ hypopigmentation:** In which there is a decrease in number of melanosomes and can be due to (Table 8.3):
 - **Anatomical defect of melanocytes:** Absent/damaged melanocytes².

1. **Penic:** devoid of; so melanopenic means devoid of melanin.
 2. **Damage to melanocytes:** including defective dendritic processes.

Table 8.2. Abnormal skin pigments

	Cause	Color
Endogenous		
<i>Hemoglobin derived</i>	Methemoglobin	Blue
	Sulfhemoglobin	Blue
	Carboxyhemoglobin	Pink
	Bilirubin	Yellow
	Hemosiderin	Brown
Exogenous		
<i>Drugs</i>	Clofazimine	Red orange
	Minocycline	Blue black
	Phenothiazines	Slate gray
<i>Topical applications</i>	Silver nitrate	Black
	Gentian violet	Violet
	Brilliant green	Green
	Potassium permanganate	Brown
	Dithranol	Mauve
	Iodine	Yellow
<i>Diet</i>	Carotene	Orange
<i>Tattoo pigments</i>	Carbon	Blue black
	Cobalt	Blue
	Chrome	Green
	Mercury	Red
	Iron	Brown

Table 8.3. Causes of melanopenic hypopigmentation/depigmentation

Anatomical defects of melanocytes: <i>absent/damaged melanocytes:</i> <ul style="list-style-type: none"> ❖ Vitiligo ❖ Piebaldism ❖ Chemicals, <i>e.g.</i>, rubber ❖ Postinflammatory
Functional defect of melanocytes: <i>defective tyrosine metabolism:</i> <ul style="list-style-type: none"> ❖ Pityriasis versicolor ❖ Endocrine disorders ❖ Albinism

➤ *Functional defect of melanocytes:* Defective tyrosine metabolism

- ❖ **Nonmelanopenic hypopigmentation:** Due to abnormalities of vasculature, *e.g.*, nevus anemicus.

Pathogenesis of Hyperpigmentation

- ❖ Increased skin color can be due to endogenous or exogenous pigments (Tables 8.1 and 8.2).

Table 8.4. Causes of hyperpigmentation due to increased melanin

Epidermal pigmentation <ul style="list-style-type: none"> <i>Increased number of melanocytes</i> <ul style="list-style-type: none"> ❖ Lentigines ❖ Cafe au lait macules ❖ Malignant melanoma <i>Increased activity of melanocytes</i> <ul style="list-style-type: none"> ❖ Freckles ❖ Exposure to ultraviolet light ❖ PUVA treatment ❖ Endocrine disorders
Dermal pigmentation <ul style="list-style-type: none"> ❖ Mongolian spots ❖ Nevus of Ota ❖ Postinflammatory hyperpigmentation

- ❖ Commonest cause of hyperpigmentation is presence of (excess amount of) melanin (Table 8.4). Melanin may be present in:
 - *Epidermis:* too much melanin in epidermis produces brown pigmentation (Fig. 8.3A).
 - *Dermis:* melanin present in dermis produces bluish gray rather than brown pigmentation (Fig. 8.3B) (**optical effect or Tyndall effect**)³.
- ❖ Tattoos are a common cause of pigmentary change due to the exogenous pigment (Table 8.2).
- ❖ Color of the abnormal pigments is often pathognomonic. However, sometimes, it is difficult to identify the chromophore responsible for pigmentation, *e.g.*, brown pigmentation caused by hemosiderin (when blood extravasates) can resemble to pigmentation caused by melanin.

Disorders of Hypopigmentation

Oculocutaneous Albinism (OCA)

Synopsis

Inheritance: Autosomal recessive.

Variants: Two main variants: tyrosinase-positive (less severe) and tyrosinase-negative (more severe).

Molecular defect: Absent or sparse production of melanin.

Clinical features: Complete absence of melanin in skin, hair, and eyes.

Complications: Eye complications and skin neoplasia.

Treatment: Aggressive photoprotection. Regular surveillance for neoplasia.

3. **Tyndall effect:** scattering of light of different wavelengths to different degrees. Melanin present in dermis appears violaceous (blue gray) because of lesser scattering of light of longer wavelengths (red) while shorter wavelengths (violet) are scattered (read reflected) more.

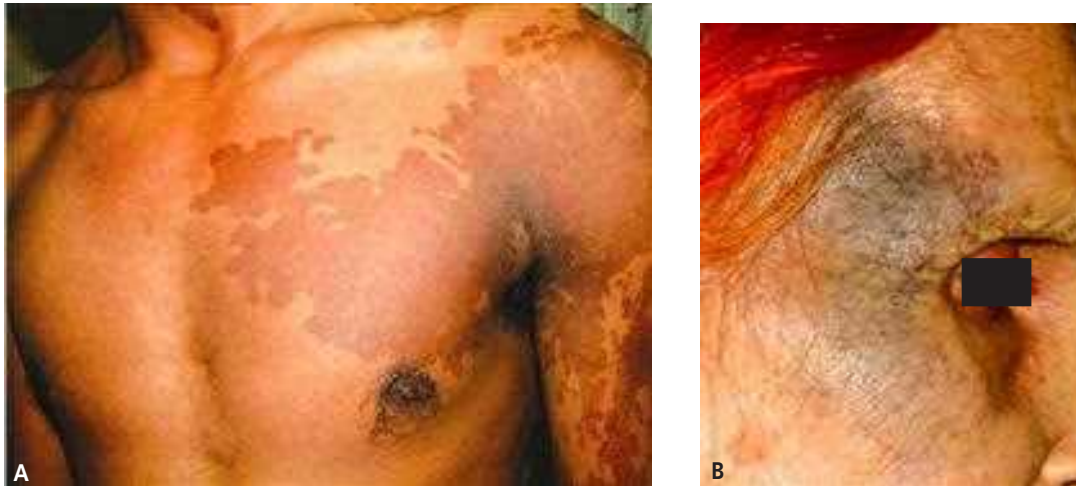

Fig. 8.3. Hyperpigmentation: A: too much melanin in epidermis causes brown pigmentation. B: melanin in dermis causes gray pigmentation.

Etiology

❖ **Inheritance:** Autosomal recessive.

❖ **Pathogenesis:**

- Very little or no melanin is produced in the skin, hair, and eyes (iris and retina) due to complete/partial absence of tyrosinase.
- Depending on partial/complete absence of tyrosinase, two main types of OCA are recognized:
 - Tyrosinase-positive OCA.
 - Tyrosinase-negative OCA.

Epidemiology

❖ **Prevalence:** Rare disorder (prevalence 1: 10,000). Both types of albinism occur with equal frequency.

Clinical Features

Prototype features

- ❖ At birth, there is complete absence of pigment in skin, hair, and eyes (iris and retina; Fig. 8.4).
- ❖ With age, patients with tyrosinase-positive OCA develop some pigment in skin, iris, and hair. Some patients even develop freckles on the photo-exposed parts.
- ❖ Melanocytic nevi do develop in patients with OCA, but they are not pigmented.
- ❖ These patients can even develop melanomas, but these too are amelanotic.

Associated features

❖ **Eye:** Eye involvement **always present** in the

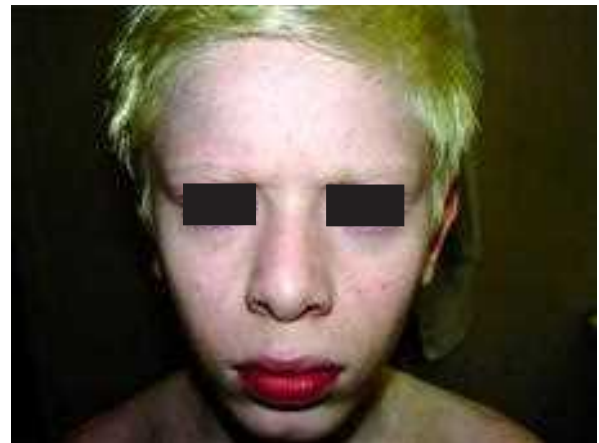

Fig. 8.4. OCA: complete absence of pigment in skin, hair, and eyes.

form of photophobia, poor eye sight, translucent irides, nystagmus, and red reflex.

❖ **Developmental abnormalities:** Small stature and mental retardation frequent.

Complications

Skin neoplasia, especially squamous cell carcinoma induced by ultraviolet rays, develop on photo-exposed parts due to lack of protective melanin.

Investigations

Done to differentiate between tyrosinase-positive and tyrosinase-negative albinism.

Hair bulb test

❖ Plucked hairs are incubated with dihydroxyphenylalanine.

- ❖ Hair of patients with tyrosinase-positive albinism turns black.

Diagnosis

Points for diagnosis

Diagnosis of albinism is based on:

- ❖ **Family history** may be negative, but consanguinity is an important marker of OCA.
- ❖ Generalized absence of pigment in the skin, hair, and eyes, with onset at birth.
- ❖ Eye changes *must* be present to make a diagnosis of OCA.
- ❖ Small stature and mental retardation frequent.

Differential diagnosis

Oculocutaneous albinism (OCA) needs to be distinguished from:

a. Vitiligo

Vitiligo	OCA
Onset: begins in later life	At birth
Course: depigmentation may progress or regress	Freckling may develop on photo-exposed parts over period of time
Eye involvement: eye changes not seen	Eye changes <i>always</i> present
Response to treatment: partial/near complete response to treatment	No response to treatment

b. Piebaldism

Piebaldism	OCA
Onset: at birth	At birth
Morphology: localized areas of depigmentation present symmetrically with islands of hyperpigmentation	Generalized depigmentation with some areas pigmentation in photo-exposed parts
Hair: white forelock; rest of scalp hair pigmented	All hair have pigment dilution
Eye involvement: depigmentation of eye brows and lashes	Universal

Treatment

- ❖ No effective treatment to pigment skin and eye.
- ❖ Patient's quality of life can be improved by:
 - Use of UV protective sunglasses.
 - Aggressive photoprotection by using appropriate clothing and broad-spectrum sunscreens.
- ❖ Regular surveillance for cutaneous malignancies; if these occur, they should be treated appropriately.

- ❖ **Prenatal diagnosis:** May be offered to parents who already have an affected issue. A biopsy of the fetal skin is taken in fourth month and examined by electron microscopy for arrested development of melanosomes.

Piebaldism

Etiology

- ❖ Autosomal dominant inheritance.
- ❖ Melanocytes are absent in affected areas.

Clinical Features

- ❖ Lesions are present at birth.
- ❖ Depigmented macules typically with islands of normomelanotic or hypermelanotic macules within area of depigmentation (Fig. 8.5A).
- ❖ White forelock (which may eventually disappear); central area of face and trunk. And proximal parts of limbs with acral sparing.

Treatment

- ❖ Photoprotection is essential.
- ❖ PUVA therapy can be tried.
- ❖ Grafting (blister/melanocyte).

Vitiligo

Synopsis

Etiology: Autoimmune etiology with familial predisposition.

Morphology: Depigmented (milky white) macules with scalloped margins; leucotrichia in old lesions. Koebner's phenomenon in active phase.

Site: Anywhere, more on pressure points.

Patterns: Segmental vitiligo and nonsegmental vitiligo (which includes focal, generalized, universal, acrofacial, and mucosal)

Associations: Alopecia areata and thyroid disorders.

Treatment: *Localized lesions:* Topical steroids (new lesions) or topical PUVA (old lesions). *Extensive lesions:* Systemic PUVA sometimes combined with oral steroids (if rapidly progressing).

Etiology

Exact etiology of vitiligo is not known and different patterns of vitiligo may have different pathogenesis.

❖ Genetic:

- Genetic factors definitely important, since 20% of patients have a positive family history.
- Inheritance may be polygenic.

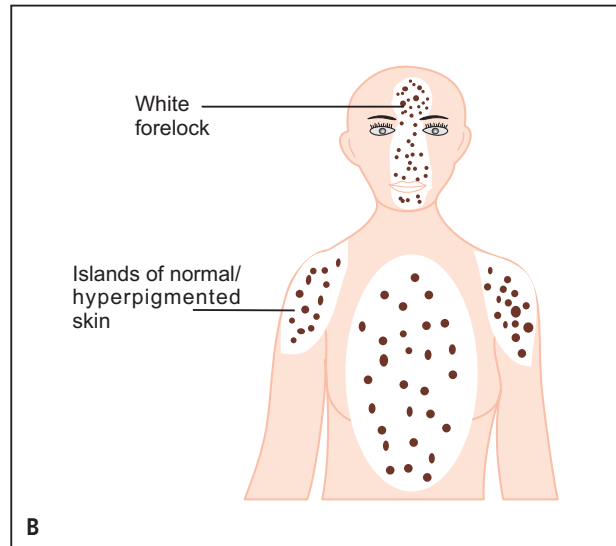
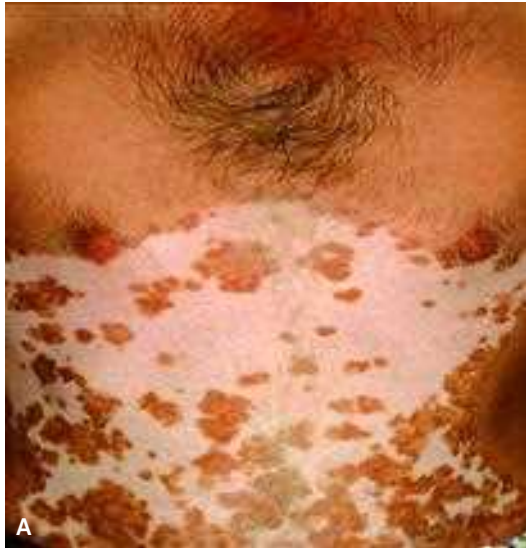

Fig. 8.5. Piebaldism: A: depigmented macules with islands of normomelanotic macules within the area of depigmentation in central area of trunk. B: distribution of lesions. Central area of face and trunk and proximal parts of limbs with acral sparing.

- ❖ **Autoimmune hypothesis:** Evidence which points to an autoimmune etiology includes:
 - Frequent association with other autoimmune disorders like alopecia areata and thyroid disorders.
 - Presence of antibodies to melanocytes.
 - Presence of lymphocytes in early lesions.
- ❖ **Neurogenic hypothesis:** Segmental vitiligo is present along a dermatome in distribution of nerves, suggesting a neurogenic origin. It has been hypothesized that a toxin, which destroys melanocytes, is released at the nerve endings.

Epidemiology

- ❖ **Incidence:** Occurs in about 1% of population. Affects all races.
- ❖ **Gender:** No gender predilection.
- ❖ **Age:** Affects all ages; peak incidence between 10 and 30 years.

Clinical Features

Morphology

- ❖ Characterized by depigmented macules, which are chalky or milky white. Sometimes, pigment loss is partial (Fig. 8.6) and occasionally, three shades (**trichrome**) are seen in the same lesion—depigmented center, surrounded by a hypopigmented rim, which in turn has normal pigmented skin around it (Fig. 8.7).

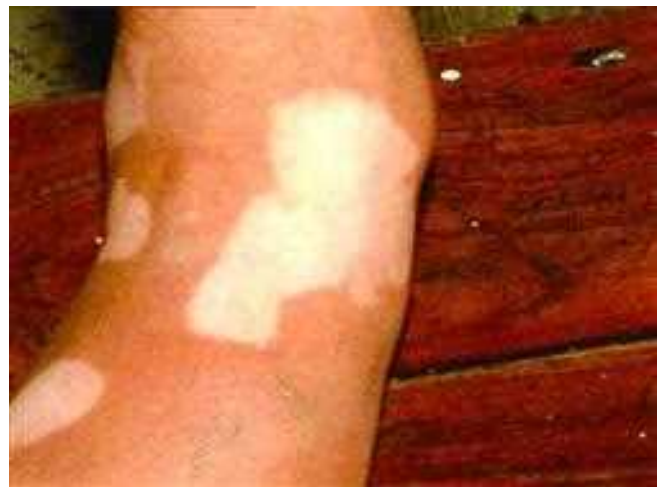

Fig. 8.6. Vitiligo: depigmented macules.

- ❖ Macules have a scalloped outline and form geographical patterns on fusion with neighboring lesions (Fig. 8.8).
- ❖ Hairs in the lesions may remain pigmented, though in the older lesions the hairs may lose their pigment (**leucotrichia**) (Fig. 8.9).

Sites

Lesions can occur in any part of the body. Areas subjected to repeated friction and trauma are frequently affected, *e.g.*, the dorsal aspect of hands and feet, elbows, and knees (Fig. 8.10).

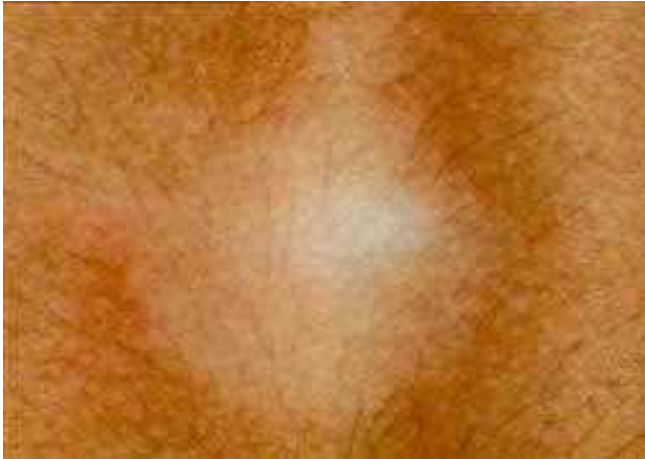

Fig. 8.7. Trichrome vitiligo: depigmented macules with a halo of hypopigmentation surrounded by normal pigmentation.

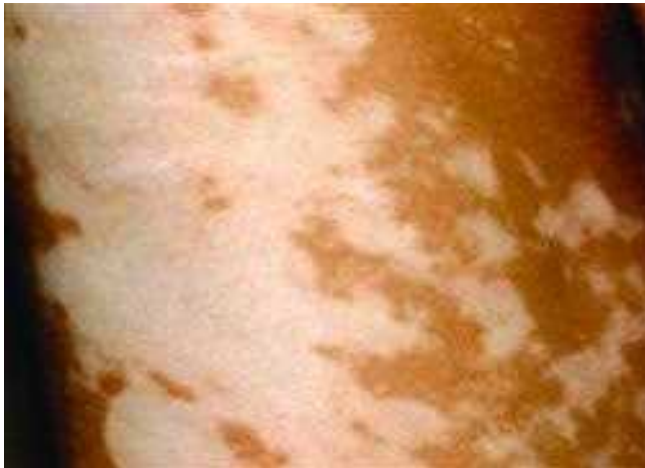

Fig. 8.8. Vitiligo: geographic shapes due to confluence of individual lesions.

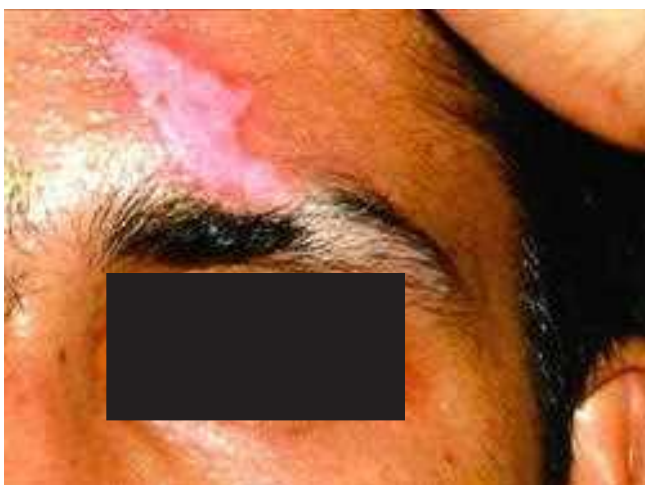

Fig. 8.9. Vitiligo: leucotrichia or depigmented hair in a patient with segmental vitiligo.

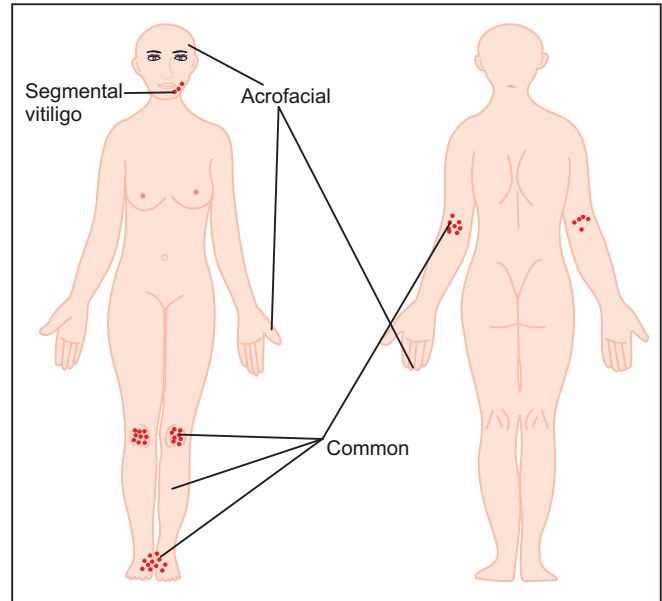


Fig. 8.10. Vitiligo: sites of predilection.

Patterns

Several patterns of vitiligo are recognized.

Vitiligo vulgaris

- ❖ Commonest type.
- ❖ Occurs after second decade.
- ❖ May be slowly or rapidly progressive.
- ❖ Family history is frequently present.

Segmental vitiligo (Fig. 8.11)

- ❖ Occurs in children.
- ❖ Not associated with an autoimmune disease.

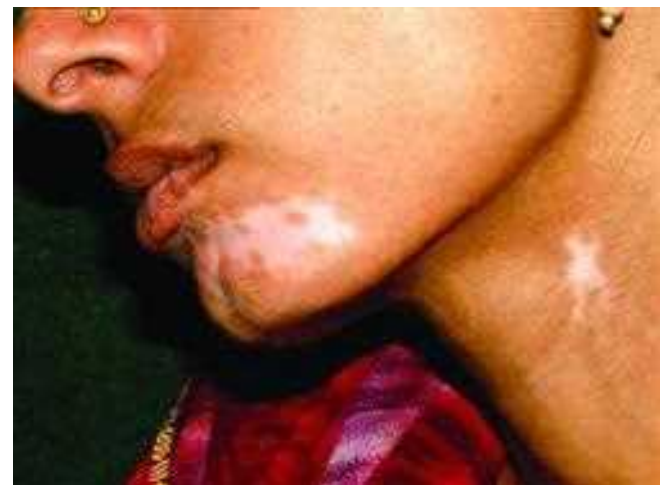

Fig. 8.11. Segmental vitiligo: depigmentation is segmental.

- ❖ Depigmentation is dermatomal or quasi-dermatomal. Most frequently (50%) seen in distribution of trigeminal nerve (mandibular division).
- ❖ Has a stable course, *i.e.*, lesions increase initially (6–12 months) and then remain static.
- ❖ Leucotrichia on the depigmented areas (Fig. 8.9) as well as away from vitiliginous areas frequently seen. Margins are feathery.
- ❖ Distant lesions uncommon.
- ❖ Response to treatment less than satisfactory.

Generalized vitiligo

- ❖ Extensive lesions.
- ❖ Variants of generalized vitiligo are:
 - *Acrofacial vitiligo* (Fig. 8.12): vitiligo predominantly seen periorificially (around eyes and on lips on the face) and acral parts (perirungual area, palms, and soles). This type of vitiligo is more resistant to therapy due to absence of hair in the affected parts.
 - *Lip-tip vitiligo*: when lips, tip of penis, the vulva and nipples are involved.
 - *Vitiligo universalis*: widespread vitiligo with only few areas of normal pigmentation; this type of vitiligo is often associated with multiple endocrinopathies.

Course

- ❖ Onset usually before age of 20 years.
- ❖ Usually slowly progressive, but sometimes can progress rapidly. Segmental vitiligo progresses initially but stabilizes in about 6 months.



Fig. 8.12. Acrofacial vitiligo: involvement of face and acral parts.

- ❖ Spontaneous repigmentation is seen in 10–20% of patients, especially in the sun-exposed parts.
- ❖ Acrofacial vitiligo is more resistant to treatment.

Prognostic factors

Following factors indicate poor response to treatment:

- ❖ Long-standing disease.
- ❖ Leucotrichia.
- ❖ Acrofacial lesions.
- ❖ Lesions on resistant areas, *i.e.*, bony prominences, nonfleshy areas, nonhairy areas and mucosae, and on ankles, wrists, elbows, perirungual areas, nipples and areolae lips, and genitalia.

Associations

Vitiligo may be associated with a number of diseases.

- ❖ **Cutaneous disorders:** Alopecia areata, halo nevus (Fig. 8.13), atopic dermatitis, malignant melanoma, and morphea.
- ❖ **Endocrine disorders:** Diabetes mellitus, pernicious anemia, Addison's disease, hypoparathyroidism, hypothyroidism, and hyperthyroidism.

Diagnosis

Points for diagnosis

The diagnosis of vitiligo is based on:

- ❖ Age of onset (usually not present at birth).
- ❖ Depigmented macules (milky white) with scalloped borders.

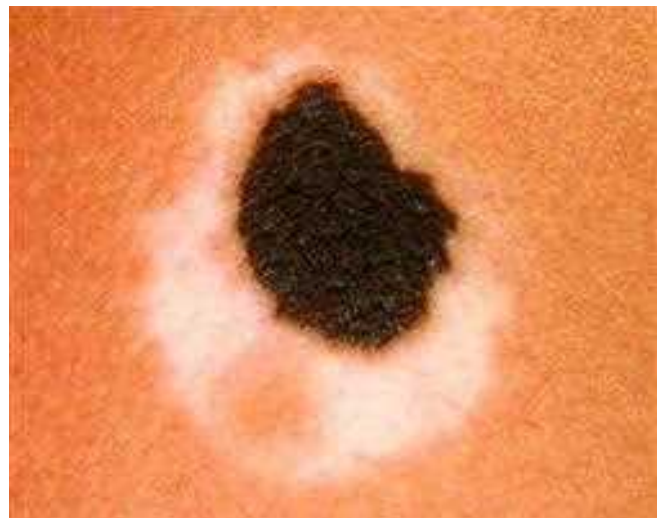

Fig. 8.13. Halo nevus: congenital melanocytic nevus with halo of vitiligo.

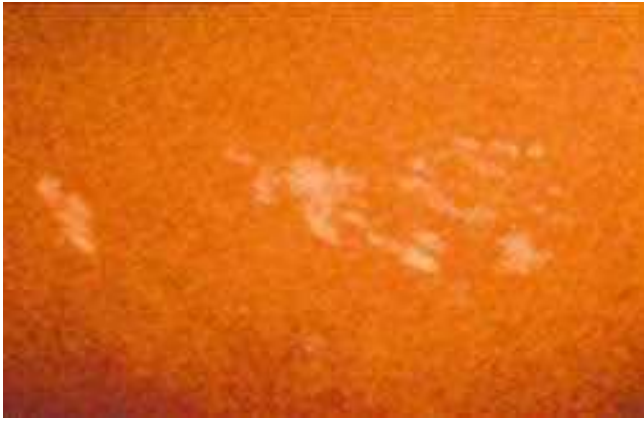

Fig. 8.14. Nevus achromicus: hypopigmented macules with feathered margins present since birth.

- ❖ Leucotrichia.
- ❖ **Koebner's phenomenon**⁴.
- ❖ Predilection for sites of trauma.

Differential diagnosis

Vitiligo should be distinguished from:

- a. Albinism (P. 149).
- b. Piebaldism (P. 149).
- c. Nevus achromicus (Fig. 8.14).

Nevus achromicus	Vitiligo
Onset: present at birth	Not present at birth
Distribution: segmental/focal	Segmental/focal/generalized
Morphology: feathered margins. Uniform pigment dilution	Scalloped margins. Shows islands of pigmentation
Hair: no leucotrichia	Leucotrichia

d. Leucoderma

Leucoderma is a term which includes all depigmented (white) lesions of skin including vitiligo (Table 8.5).

Table 8.5. Causes of leucoderma

Idiopathic	Vitiligo
Chemicals (Fig. 8.15A)	Hydroquinone (used in rubber industry) Substituted phenols (used in foot wear) Adhesives (used in stick-on bindis)
Inflammatory skin diseases (Fig. 8.15B)	Lupus vulgaris Discoid lupus erythematosus

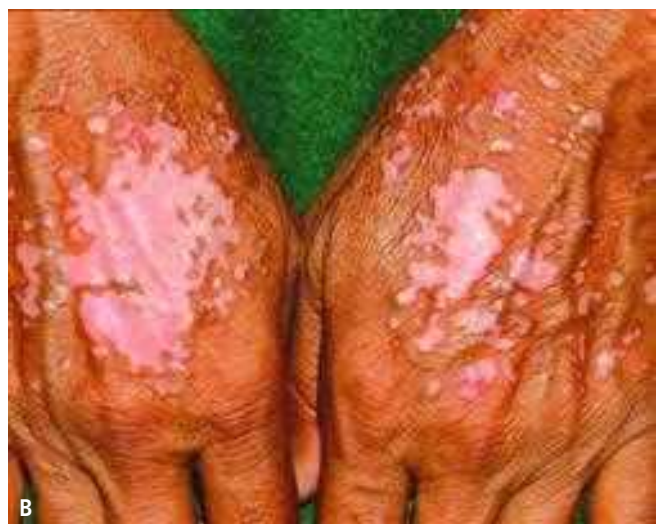
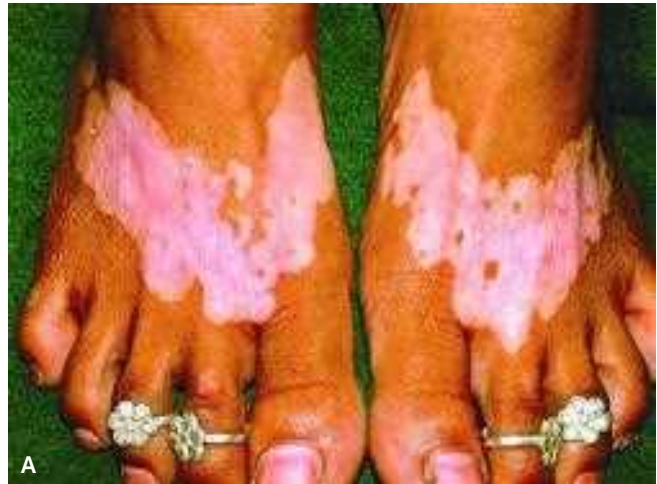
Fig. 8.15. Leucoderma: A: contact leucoderma due to substituted phenols in foot wear. B: leucoderma due to discoid lupus erythematosus.

Treatment (Table 8.6)

Though treatment of vitiligo is not very satisfactory, reasonable improvement can be expected in several patients. Treatment depends on:

- ❖ Age of patient.
- ❖ Extent of disease.
- ❖ Pattern of disease.
- ❖ Cosmetic disability.
- ❖ Effect on quality of life.

4. **Koebner's phenomenon or isomorphic phenomenon:** new lesions of original disease develop at sites of trauma. In vitiligo, manifests as linear depigmented macules.

Table 8.6. Guidelines for treatment of vitiligo

Localized disease	
New lesions	Topical steroids
Old lesions	Topical PUVA*/PUVA sol
Extensive disease	
New lesions	Oral steroids + PUVA*/PUVA* sol or NB-UVB**
Rapid increase	Oral steroids + PUVA*/PUVA* sol/NB-UVB**
Old lesions	Oral PUVA*/PUVA*sol/NB-UVB**
Intolerance to PUVA/NB-UVB	Oral steroids
Generalized lesions	Monobenzyl ether of hydroquinone

*PUVA/PUVA sol: psoralens + UVA psoralens + sunlight
 **NB-UVB: Narrow band UVB

General measures

- ❖ Reassurance and psychological support to the patient and family.
- ❖ Explanation about prognosis.

Physical modalities of treatment

Photochemotherapy

- ❖ Photochemotherapy is use of psoralens in combination with UVA exposure (PUVA). It forms the mainstay of therapy in vitiligo.

❖ **Psoralens:** Are naturally occurring tricyclic furocoumarins present in a large number of plants; some are synthesized. The most frequently used psoralens is 8-methoxypsoralen (8-MOP). Depending on the extent of disease, either topical (for localized disease) or systemic (for extensive disease) therapy is used.

❖ **UVA:** Is supplied by special chambers containing UVA emitting tubes. Or sunlight is used, when therapy is called PUVA sol.

❖ **Regimen:**

- **Topical PUVA/PUVA sol:** psoralen application (on alternate days) followed by exposure to gradually increasing doses (till mild erythema achieved) of sunlight or artificial source of UVA (Fig. 8.16). Dose of UVA needed with topical therapy is less than that needed with systemic therapy.
- **Systemic PUVA/PUVA sol:** 8-MOP, 0.6 mg/kg, orally on alternate days. Followed by exposure to gradually increasing doses (till mild erythema achieved) of sunlight or to artificial source of UVA (Fig. 8.16). Dose of UVA needed greater with systemic therapy.

❖ After exposure to UV rays, lesions are protected from the excessive exposure to sun by using broad-spectrum sunscreens, e.g., zinc oxide and avoiding peak sunlight.

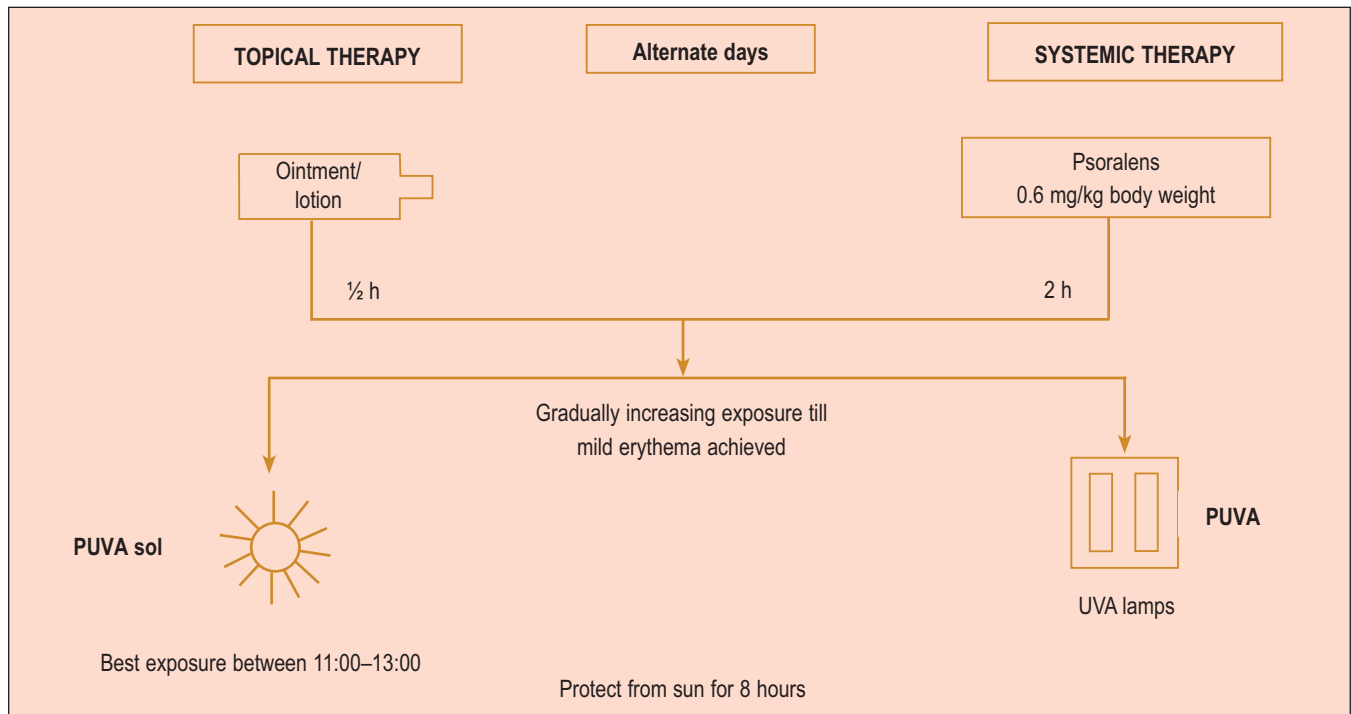


Fig. 8.16. Psoralen therapy: principles of treatment. Treatment is given on alternate days to avoid phototoxicity.

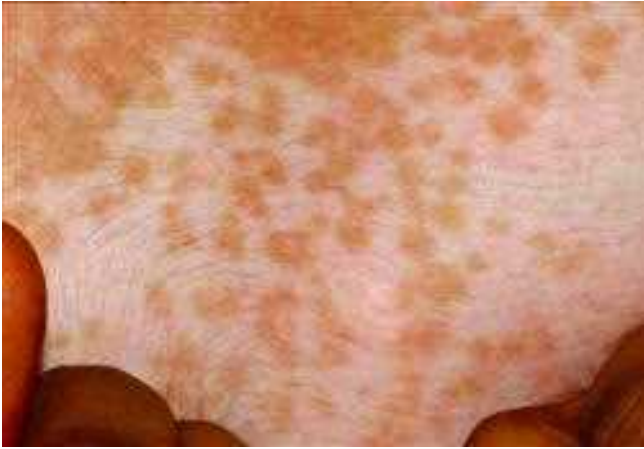


Fig. 8.17. Repigmentation in vitiligo: begins in perifollicular region.

❖ **Response:** Repigmentation is slow. It begins in perifollicular area and also periphery of lesions and gradually becomes confluent (Fig. 8.17). Repigmentation occurs most readily on face, neck, and hairy regions while acral and non-hairy parts are slow responders.

❖ **Side effects:**

- Systemic psoralen therapy is generally well-tolerated though some patients complain of nausea, epigastric discomfort, and giddiness.
- Excessive exposure (to sun or to UVA) results in **phototoxicity**⁵, which is more frequent with topical psoralens (Fig. 8.18). Phototoxic reactions are best treated by withdrawing psoralens and using topical corticosteroid therapy. A short course of systemic steroids may be needed, if the phototoxic reaction is severe or widespread.

Phototherapy

Two forms of phototherapy have been used in vitiligo:

❖ **Broadband UVB:** Is no longer used.

❖ **Narrow band UVB (311 nm):**

- **Indications:** in extensive disease (>10%). Especially indicated in children and in pregnant women and in patients in whom psoralens are contraindicated.
- **Regimen:** in gradually increasing doses of UVB, given from specialized chambers.
- **Side effects:** generally safe.

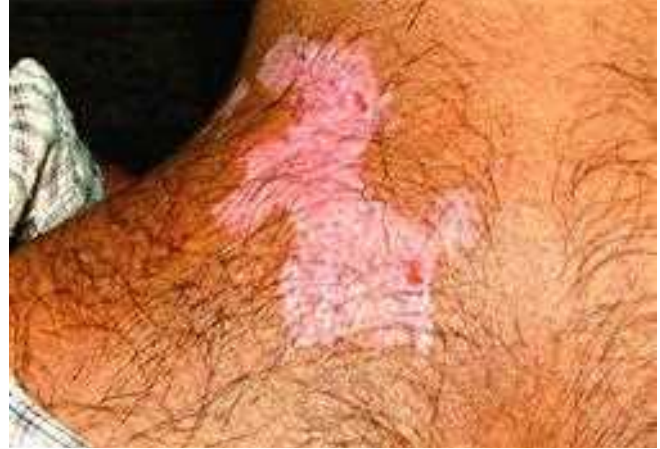

Fig. 8.18. Phototoxic reaction: in patient with vitiligo, due to topical PUVA therapy.

Medical treatment

Steroids

❖ **Topical steroids:** Are used for:

- Single lesions, (sometimes a few localized lesions) especially of recent origin.
- As adjuvant to other forms of therapy.

❖ **Systemic steroids:** Are used:

- When the patient cannot be given phototherapy/photochemotherapy.
- In rapidly progressive vitiligo, along with PUVA/PUVA sol.
- In vitiligo, unresponsive to psoralens.

❖ Side effects to steroids limit their use, though the recently devised weekly schedule (**oral mini pulse**⁶) probably causes fewer side effects than daily doses.

Other therapies

Many other drugs have been used, often empirically:

❖ **Tacrolimus and pimecrolimus:** For facial lesions where topical steroids cause side effects and color match with photochemotherapy may not be acceptable.

❖ **Levamisole:** As an immunomodulator, in weekly/fortnightly doses with variable results.

❖ **Khellin:** As part of photochemotherapy.

❖ **Placental extract.**

❖ **Depigmenting agents:**

5. **Phototoxicity:** clinically manifests as painful erythema, edema, and sometimes blistering (Fig. 8.18).

6. **Oral mini pulse (OMP):** an effort to circumvent side effects of oral steroids, without compromising clinical response. Steroids are given on a single day or on two consecutive days, every week.

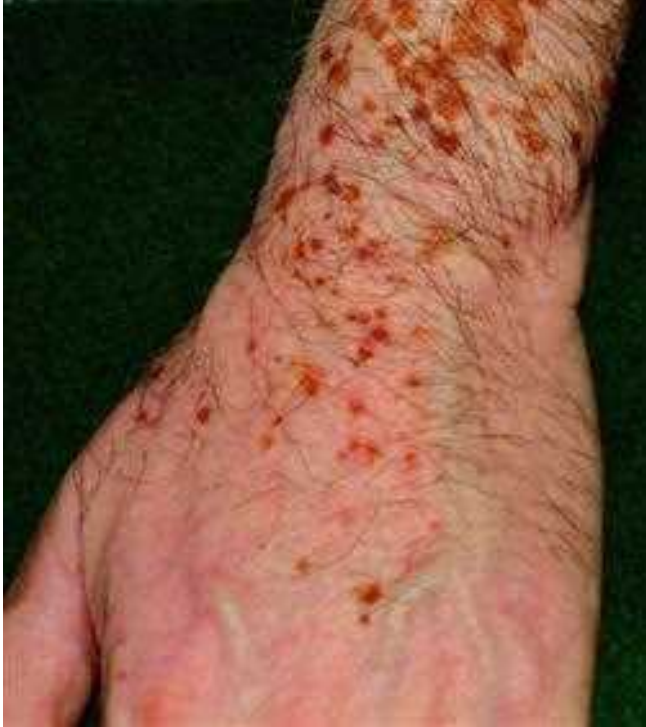

Fig. 8.19. Extensive vitiligo: few pigmented lesions can be removed using monobenzyl ether of hydroquinone.

- Like monobenzyl ether of hydroquinone.
- Used to depigment the few normally pigmented areas in patients with extensive vitiligo (Fig. 8.19). Depigmented skin of photo-exposed areas aggressively protected with sunscreens to prevent spotty repigmentation.

Surgical measures

- ❖ **Indications:** At sites poorly responsive to conventional therapy (ankles and knuckles), in a patient with stable disease (for at least 6 months).
- ❖ **Techniques:** Techniques available include:
 - Melanocyte transfer.
 - Blister grafting.
 - Punch grafting.
 - Split thickness skin grafting.

Postinflammatory Hypopigmentation

- ❖ Can occur after any skin disease (Table 8.7).
- ❖ Most conspicuous in darker races; may not be visible in whites.
- ❖ Presents either as hypopigmentation or depigmentation. Other changes like atrophy, scarring may be present.

Table 8.7. Causes of postinflammatory hypopigmentation

Hypopigmentation	Psoriasis Eczema Sarcoidosis
Depigmentation	Discoid lupus erythematosus Lupus vulgaris

Disorders of Hyperpigmentation

Different causes of hyperpigmentation are shown in Table 8.8.

Table 8.8. Causes of hyperpigmentation

Genetic	Café au lait macules Freckles Lentigines Xeroderma pigmentosum
Endocrine	Melasma Pregnancy Addison's disease Cushing's syndrome
Metabolic	Biliary cirrhosis Renal failure Porphyria
Nutritional	Protein energy malnutrition Pellagra Malabsorption Carcinomatosis
Drugs	Psoralens Minocycline Photosensitizing drugs ACTH Estrogens and progestogens
Skin diseases	Lichen planus Systemic sclerosis Cutaneous amyloidosis
Miscellaneous	Melanocytic nevi Epidermal nevi Mastocytosis

Melasma

Synonym: Chloasma

Etiology

❖ **Hormonal factors:**

- **Estrogens:** often first appears during pregnancy or in a patient taking oral contraceptives, indicating influence of female hormones.
- **Other factors:** melasma is not uncommon in males, so other factors may be working.

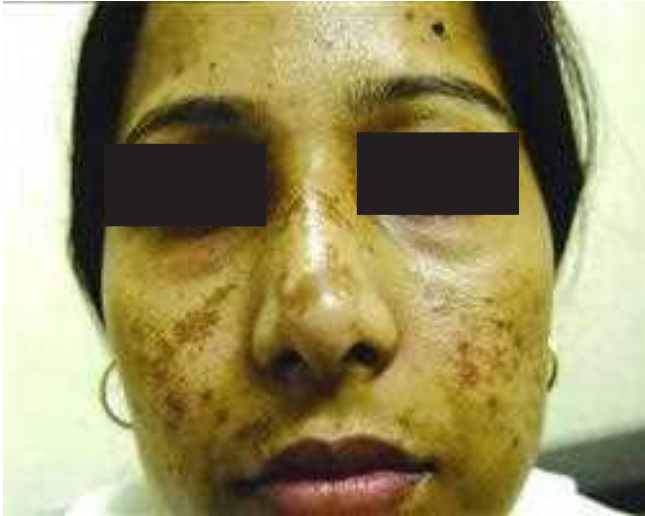

Fig. 8.20. Melasma: brown macular lesions with scalloped margins on the cheeks and nose.

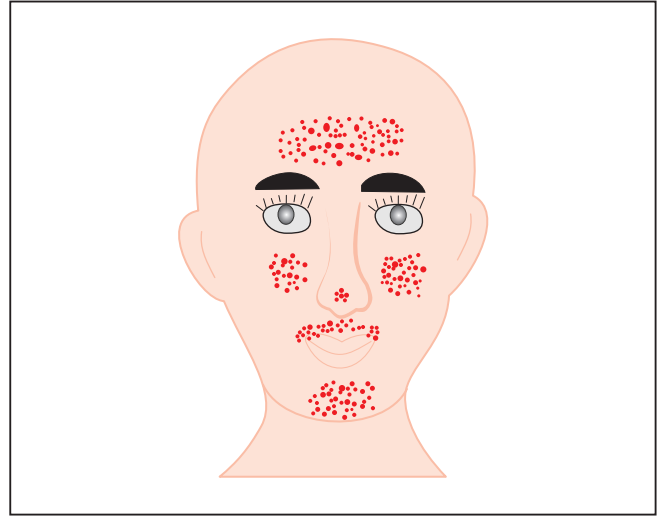


Fig. 8.21. Melasma: sites of predilection.

- ❖ **Sunlight:** Ultraviolet rays important, as melasma darkens after sun exposure.

Epidemiology

- ❖ **Prevalence:** Common problem.
- ❖ **Age:** Peak incidence 30–50 years.
- ❖ **Gender:** Females more frequently affected.

Clinical Features

Morphology

- ❖ Brown macular pigmentation with well-defined scalloped margins (Fig. 8.20).
- ❖ Pigmentation darkens on sun exposure.

Sites of predilection

Symmetrically on cheeks, nose, forehead, and chin (Fig. 8.21).

Treatment

Photoprotection

- ❖ Avoiding sun at its peak.
- ❖ Broad-rimmed hats/umbrellas
- ❖ Broad-spectrum sunscreens.

Medical treatment

- ❖ **Hydroquinone:** 2–4% topically. Used alone. Or as combination⁷ with retinoic acid⁸ (0.025–0.05%) and a topical steroid⁹ (like mometasone).
- ❖ **Azelaic acid:** Used topically as 10–20% cream. Is as efficacious as hydroquinone.
- ❖ Other agents used include:
 - Glycolic acid (6–12%).
 - Kojic acid (1–4%).

Chemical peeling¹⁰

- ❖ Chemical peeling is an important method of treating melasma.
- ❖ Agents used are:
 - Glycolic acid (70%).
 - Trichloroacetic acid (15–30%).

Freckles

Etiology

- ❖ **Inheritance:** Autosomal dominant genodermatosis, seen in red haired, and fair individuals.
- ❖ **Pathology:** Number of melanocytes is normal, but they produce more melanosomes.

7. **Combination:** of hydroquinone, retinoic acid, and steroid referred to as Kligman's regimen.

8. **Retinoic acid:** itself reduces pigmentation and also increases efficacy of hydroquinone.

9. **Steroid:** itself reduces pigmentation and also reduces irritation due to hydroquinone and retinoic acid.

10. **Chemopeeling or chemical peeling:** should always be done under supervision as overzealous or careless application of chemical may result in burns.

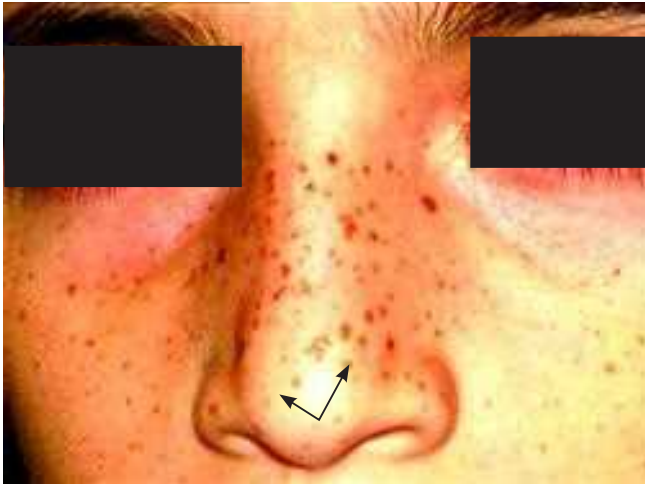

Fig. 8.22. Freckles: brown macules on photo-exposed parts. Note variation in color.

Clinical Features

Morphology

- ❖ Lesions are multiple, ill-defined brown macules, which become darker on sun exposure.
- ❖ Individual macules may show variegation in skin color (Fig. 8.22).

Sites of predilection

Photo-exposed areas (face, dorsolateral aspect of forearms, hands, and V of neck).

Treatment

- ❖ **Photoprotection:** Avoid sun at its peak; large rimmed hats/umbrellas; broad-spectrum sunscreens.
- ❖ **Topical depigmenting agents:** Like hydroquinone and azelaic acid can be tried.
- ❖ **Chemopeeling.**

Lentigines

Etiology

- ❖ May occur as part of a multisystem syndrome, e.g., Peutz-Jegher's syndrome or Cronkhite-Canada syndrome. Or occur in isolation.
- ❖ **Pathology:** Number of melanocytes is increased.

Clinical Features

Morphology

- ❖ Begin in childhood.

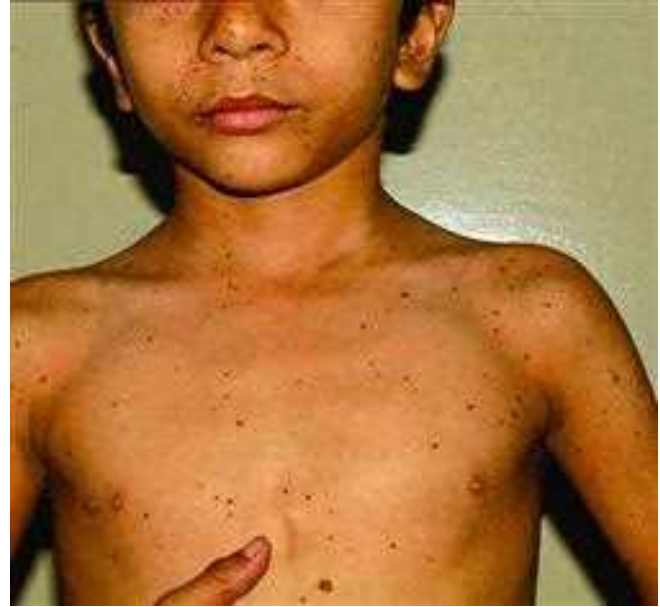

Fig. 8.23. Lentigines: dark brown, sharply demarcated macules. Can occur both on photo-exposed and covered parts.

- ❖ Light brown to dark brown uniformly colored macules, 1–10 mm across.
- ❖ Usually discrete.
- ❖ Have irregular but sharp margin (Fig. 8.23).

Sites of predilection

Any part of the body including mucosae (*cf.*, freckles, which occur on the photo-exposed parts).

Associations

- ❖ **Peutz-Jegher's syndrome:**
 - Autosomal dominant.
 - Scattered oral and acral lentigines.
 - Small intestinal polyps and ovarian tumors.
- ❖ **Cronkhite-Canada syndrome:**
 - Multiple lentigines on dorsae of hands.
 - Diffuse pigmentation of palms.
 - Nail abnormalities.
 - Alopecia.
 - Intestinal polyposis.
- ❖ **LAMB syndrome:**
 - Lentigines.
 - Atrial myxomas.
 - Blue nevi.
- ❖ **LEOPARD syndrome:**
 - Lentigines.
 - ECG abnormalities.
 - Ocular anomalies.

- Pulmonary stenosis.
- Abnormal genitalia.
- Retarded growth.
- Deafness.

Differential Diagnosis

Lentigines should be differentiated from:

a. Freckles.

Freckles	Lentigines
<i>Skin color:</i> in fair skinned	In any skin color
<i>Morphology:</i> less well-defined. Each lesion has color variation within. Also may be lighter or darker than neighboring lesion	Well-defined, with uniform color
<i>Distribution:</i> photo-exposed parts only	Any part of body including mucosae
<i>Sun exposure:</i> darken on exposure to sunlight	No change in color

Treatment

- ❖ Treatment is generally not required.
- ❖ Facial lesions may be removed by excision or by cryotherapy.

Hyperpigmentation due to Endocrine Diseases

Several endocrine disorders are associated with hyperpigmentation.

Pigmentation of Pregnancy

- ❖ **Darkening of skin:** Reversible (gradually fading after delivery) pigmentation, most noticeable on nipples, areolae, and linea alba.
- ❖ **Chloasma:** May begin during pregnancy. Or intake of oral contraceptive pills.

Pigmentation due to Increased ACTH Secretion

Increased ACTH secretion is seen in Addison's disease and Cushing's syndrome. Both associated with a variety of hyperpigmentary patterns:

- ❖ Chloasma-like pigmentation.
- ❖ Generalized pigmentation.
- ❖ Pigmentation localized to skin creases of palms and soles.
- ❖ Mucosal pigmentation.
- ❖ Pigmentation of scars.
- ❖ Pigmentation of photo-exposed parts.

Pigmentation of Thyroid Dysfunction

- ❖ Diffuse hyperpigmentation.
- ❖ Chloasma-like hyperpigmentation.

Hyperpigmentation due to Drugs

- ❖ Several drugs can cause hyperpigmentation.
- ❖ Sometimes the pigmentation caused by the drug is characteristic (Table 8.9).

Table 8.9. Drugs causing hyperpigmentation

Drugs	Type of pigmentation
Clofazimine	Orange pigmentation especially of leprosy lesions
Psoralens	Brown pigmentation
Minocycline	Blue black deposits in healing acne lesions Blue black discoloration of shins Blue black discoloration of mucosa
Bleomycin	Generalized hyperpigmentation
Busulfan	Generalized hyperpigmentation
Cyclophosphamide	Generalized hyperpigmentation

"This page intentionally left blank"

Chapter Outline

Disorders of Arteries

Raynaud's phenomenon[•]
Atherosclerosis[◦]
Decubitus ulcer[◦]
Arterial embolism[◦]

Disorders of Veins

Deep vein thrombosis[◦]
Thrombophlebitis[◦]
Stasis eczema and stasis ulcer[•]

Disorders of Small Blood Vessels

Telangiectasia[◦]
Erythrocyanosis[◦]
Erythromelalgia[◦]
Livedo reticularis[•]

Disorders of Lymphatic Vessels

Lymphedema[•]
Lymphangiectasis[•]

Disorders of Arteries

Raynaud's Phenomenon

Synopsis

Etiology: Vasospastic phenomenon with several causes: easy to remember TONIC! (**T**raumatic and **T**oxic, **O**cclusive, **N**eurological, **I**mmunological and **C**onnective tissue diseases). Connective tissue diseases *e.g.*, systemic sclerosis the commonest cause.

Clinical features: Pallor, Cyanosis, Redness of digits (**PCR**¹ in this order) on exposure to cold. Later loss of finger (toe) pulp, stellate digit tip ulcers and even gangrene.

Treatment: Protection from cold; nifedipine (30–60 mg daily) and other peripheral vasodilators. Sympathectomy in unresponsive, severe cases.

Etiology

- ❖ Raynaud's phenomenon is paroxysmal pallor of digits, followed by cyanosis and erythema precipitated by exposure to cold².
- ❖ It is a vasospastic disorder in which arterial spasm occurs due to:
 - Reflex sympathetic activity.
 - Increased sensitivity of certain receptors.
 - Release of vasoactive agents from platelets.
- ❖ There are several causes of Raynaud's phenomenon (Table 9.1) with systemic sclerosis (including **CREST**³) being the commonest cause.

1. PCR: Pallor, Cyanosis, Redness, in this order.
2. Sometimes by emotional stimuli.
3. **CREST**: a collagen vascular disease characterized by presence of **C**alcinosis cutis, **R**aynaud's phenomenon, **E**sophageal dysmotility, **S**clerodactyly, **T**elangiectasia.

[•]Should know
[◦]Good to know

Table 9.1. Causes of Raynaud's phenomenon

Connective tissue disorders	Systemic sclerosis System lupus erythematosus Mixed connective tissue disease
Arterial occlusion	Endarteritis obliterans
Neurological diseases	Peripheral neuropathy Syringomyelia
Toxins	Ergot Vinyl chloride
Hematological diseases	Cryoglobulinemia Polycythemia
Repeated trauma	Drills Vibrating machines
Primary	Raynaud's disease

Clinical Features

- ❖ Exposure to cold, precipitates pallor of digits, followed (in a few minutes) by painful cyanosis (Fig. 9.1A), then deep erythema (in that order—remember PCR¹) before returning to normal color.
- ❖ Over period of time, there is loss of digital pulp; later stellate digit tip ulcers develop (Fig. 9.1B) and eventually gangrene (Fig. 9.1C) may supervene.

Investigations

In patients with Raynaud's phenomenon, always rule out:

- ❖ Connective tissue diseases *e.g.*, systemic sclerosis.
- ❖ Cryopathies *e.g.*, cryoglobulinemia.
- ❖ Arterial diseases.
- ❖ Neurological diseases.

Treatment

- ❖ Reassurance.
- ❖ Rule out underlying diseases.
- ❖ **General measures:** Measures to prevent Raynaud's phenomenon include:
 - Avoiding triggers like exposure to cold, smoking, vibrating stimuli, and stress.
 - Keeping hands and feet covered (gloves and socks).
 - Dipping hands and feet in warm water, several times a day.
- ❖ **Medical measures:** Drugs used to treat Raynaud's phenomenon include:
 - *Calcium channel blockers*⁴: like nifedipine (30–60 mg daily) and diltiazem (60–120 mg daily in divided doses) are the mainstay of therapy.
 - *Angiotensin-receptor antagonists and ACE inhibitors*: losartan, 50 mg daily is useful in patients with primary Raynaud's phenomenon and scleroderma.
 - *Sildenafil*: in dose of 50–100 mg daily improves circulation and symptoms in patients with secondary Raynaud's phenomenon resistant to vasodilatory therapy.

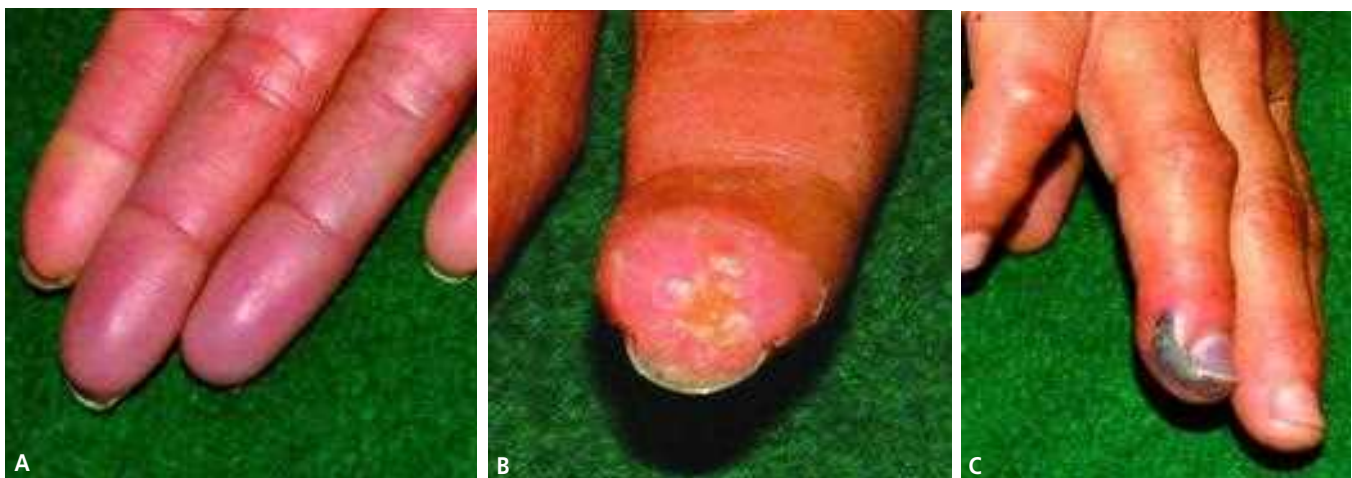


Fig. 9.1. A: Raynaud's phenomenon: area of pallor followed by cyanosis and then erythema on exposure to cold. B: finger tip stellate scars. This patient had systemic sclerosis. C: finger tip gangrene.

4. **Calcium channel blockers:** postural hypotension is a major adverse reaction to nifedipine. Diltiazem is a less effective, but a safer alternative.

- *Others*: nicotinic acid or topical glyceryl trinitrate may reduce severity and frequency of Raynaud's phenomenon.
- ❖ **Surgical measures**: Digital sympathectomy may be tried in severe or tissue-threatening disease.

Atherosclerosis and Arterial Ulcers

Atherosclerosis is a patchy deposition of lipid (mainly as cholesterol) within the intima of arterial wall.

Etiology

Predisposing factors

- ❖ Cigarette smoking.
- ❖ Hypertension.
- ❖ Diabetes.
- ❖ Lipid-rich diet.
- ❖ Hyperlipidemia.
- ❖ Lack of exercise.
- ❖ Obesity.
- ❖ Genetic predisposition.

Clinical Features

Patients with atherosclerotic vessels of lower extremities may present to a dermatologist with:

- ❖ Intermittent claudication and nocturnal cramps.
- ❖ **Ischemia**:
 - Feet are cold and pale. Skin shows trophic changes like atrophy and loss of hair.
 - Peripheral pulses are diminished or absent.
 - Gangrene
- ❖ May develop **arterial ulcers** which:
 - Are present on toes and feet.
 - Are excruciatingly painful and indolent.
 - Are irregular, have a pale or gray black floor that lacks granulation tissue but may be covered with slough, or may have islands of normal looking skin. When deep, may have bare tendons in its base. There is no pigmentation or lipodermatosclerosis in the surrounding skin (*cf.*, venous ulcers). Exudation is minimal (Fig. 9.2).

Investigations

- ❖ Blood sugar and serum lipid profile.
- ❖ Doppler ultrasound studies may assist in diagnosis.

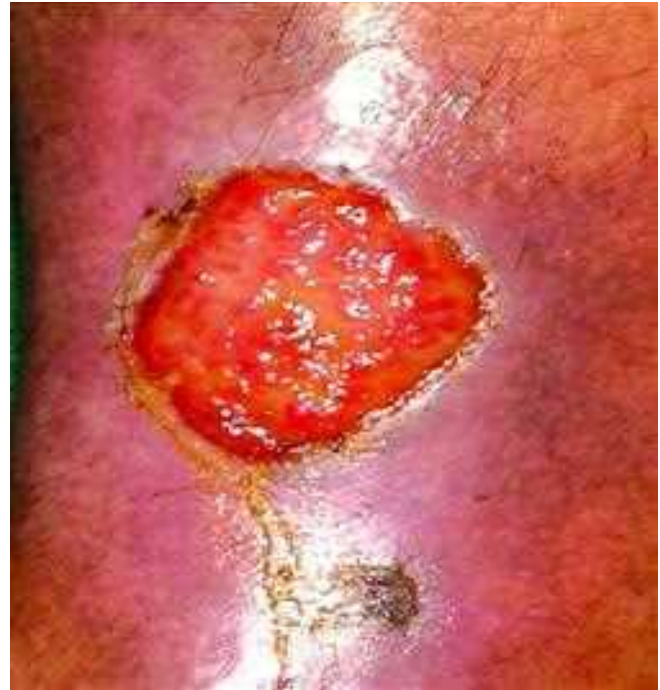

Fig. 9.2. Arterial ulcer: on dorsal aspect of foot. Ulcer has a pale floor covered with slough. There is often no pigmentation or lipodermatosclerosis in surrounding skin.

Treatment

- ❖ Avoid/treat triggering factors.
- ❖ Rest.
- ❖ Antibiotics especially against anaerobes⁵.

Arterial Embolism

- ❖ Causes include dislodged thrombi (from atheromas), fat emboli, infected emboli (from bacterial endocarditis, septicemia), and tumor emboli.
- ❖ Depending on the size of artery blocked, emboli can cause ulcers (embolism of small arteries) or gangrene (embolism of larger vessels).

Decubitus Ulcer

Synonym: Pressure sore

Etiology

- ❖ Continuous pressure on skin over bony prominences causes pressure sores.

5. **Antibiotics against anaerobes:** metronidazole.

- ❖ Factors contributing to formation of pressure sores are:
 - Prolonged immobility, *e.g.*, due to fracture of neck of femur, paraplegia, and coma.
 - Neurological diseases.
 - Vascular diseases including atherosclerosis.
 - Metabolic diseases like diabetes.
 - Nutritional diseases like malnutrition and general debility.

Clinical Features

Morphology

- ❖ Initially manifests as an area of persistent erythema.
- ❖ Followed by development of blister, which ruptures to form an erosion, which deepens.
- ❖ As deeper tissues are damaged, an eschar forms over the ulcer.

Sites of predilection

Occurs most frequently over the sacrum, ischial tuberosity, greater trochanter, and on the tuberosity of calcaneus and lateral malleolus.

Treatment

- ❖ **Prophylaxis:** Very important because it is easier to prevent decubitus ulcers than to treat them. Prevented by:
 - Regular turning of recumbent patients.
 - Using antipressure mattresses.
 - Treating anemia, hypoproteinemia, and diabetes.
- ❖ **Specific measures:** Once formed, decubitus ulcers are treated by:
 - Cleaning with normal saline or antibacterial solutions.
 - Giving systemic antibiotics, if ulcer is infected.
 - Plastic reconstruction of area, in young patients, once ulcer begins to look healthy.

Disorders of Veins

Deep Vein Thrombosis (DVT)

Etiology

DVT is caused by⁶ (Table 9.2):

- ❖ Hypercoagulability.
- ❖ Alteration in blood flow.
- ❖ Damage to vessel wall.

Table 9.2. Common causes of deep vein thrombosis

Hypercoagulability	Thrombocythemia Polycythemia Postoperative period Infection Hemorrhage
Altered blood flow	Pregnancy Immobility
Damaged vessel wall	Physical Chemical Infection of adjacent tissue
Miscellaneous causes	Smoking Behcet's disease

Clinical Features

- ❖ Often asymptomatic.
- ❖ When symptomatic, onset is usually acute with swelling, pain, and cyanosis. Pain worsens on dorsiflexion of foot (**Homan's sign**). Calf tenderness may be present.
- ❖ Lower extremities are most frequently involved.
- ❖ **Complications:**
 - *Acute:* an infrequent acute complication is pulmonary embolism.
 - *Chronic:* may develop varicose veins, stasis dermatitis, and stasis ulcer.

Treatment

- ❖ **Prevention of DVT:** Is very important.
 - Early ambulation after surgical procedures, childbirth, and fractures.
 - Reduction in weight.
 - Regular walking/exercise.
- ❖ **Anticoagulants:** Initially (first 24–48 h) low-molecular weight heparin followed by warfarin. Monitoring done by the prothrombin time, expressed as international normalized ratio (INR). A ratio between 2.0 and 3.0 needs to be achieved for adequate anticoagulation with a low risk of bleeding.
- ❖ **Thrombolytic regimen:** Doubtful value.

Thrombophlebitis

- ❖ Thrombus forms in an inflamed vein.
- ❖ Affected vein appears as a tender, erythematous cord on lower extremity.
- ❖ **Constitutional symptoms:** Fever and malaise may be present.

6. **Caused by:** easily remembered as HAD: **H**ypercoagulability, **A**ltered blood flow, **D**amaged blood vessel. Often referred to as **Virchow's triad**.

- ❖ **Treatment:** Rest and nonsteroidal antiinflammatory drugs.

Stasis Eczema and Stasis Ulcer

Synopsis

Etiology: Venous hypertension.

Morphology: Starts as edema followed by eczema characteristically surrounded by pigmentation and sclerosis. Later, ulceration occurs. Ulcers often large and indolent with floor covered with red granulation tissue.

Site: Medial malleolus.

Complications: Bacterial infection; eczematization; infrequently malignant transformation.

Treatment: General measures like compression bandage and foot end elevation; local hygiene and treatment of secondary infections. Skin grafting for healing ulcers and surgery for incompetent perforators.

Etiology

Anatomy of leg veins

- ❖ Venous drainage of legs depends on efficient functioning of three components (Fig. 9.3):
 - Superficial veins.
 - Deep veins.
 - Perforators.
- ❖ Blood in superficial veins drains into deep veins through the perforators (located in the lower part of the leg) with the help of gravity when the calf muscles relax.
- ❖ Deep veins in the calf pump the blood to the heart when the calf muscles contract (**calf muscle pump**). Reflux is prevented by valves.

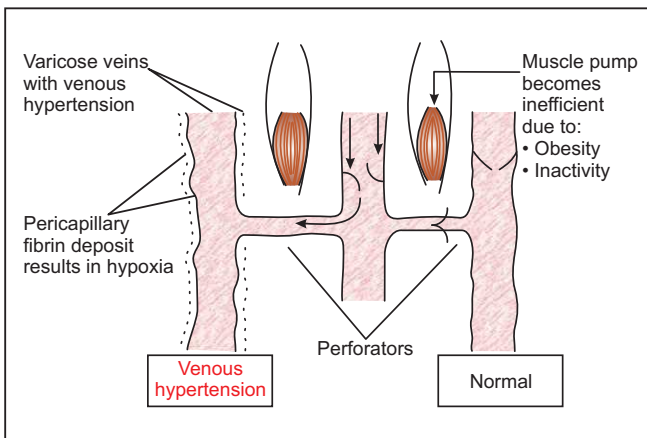


Fig. 9.3. Pathogenesis of venous leg ulcers. SV: superficial veins; DV: deep veins.

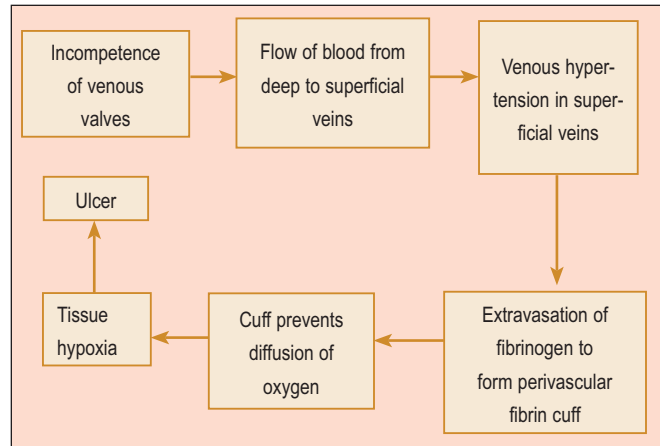


Fig. 9.4. Pathogenesis of stasis ulcer.

Pathogenesis of stasis dermatitis and ulcers

The basic reason for development of stasis eczema is venous hypertension in legs (Fig. 9.4).

Clinical Features

Morphology

Stasis eczema

- ❖ Stasis eczema usually begins with pitting pedal edema, which later evolves into induration, especially around the ankles.
- ❖ Over a period of time, brownish pigmentation (due to hemosiderin released from the breakdown of extravasated red cells) appears. Pigmentation initially punctate, later confluent (Fig. 9.5A).
- ❖ Long-standing cases present with ivory white plaques with dilated capillary loops. This combination of findings is called **lipodermatosclerosis** (Fig. 9.5B).

Stasis ulcer

- ❖ Also called venous ulcers.
- ❖ Ulcers develop frequently following trivial trauma.
- ❖ Ulcers are well-demarcated, with variable depth but they extend peripherally often attaining large size, because of poor healing. Floor of ulcer is edematous and made of unhealthy granulation tissue.
- ❖ With rest and proper management, the ulcer heals in two ways:
 - Epithelialization from the edge.
 - Appearance of scattered small gray islands of skin over the floor.

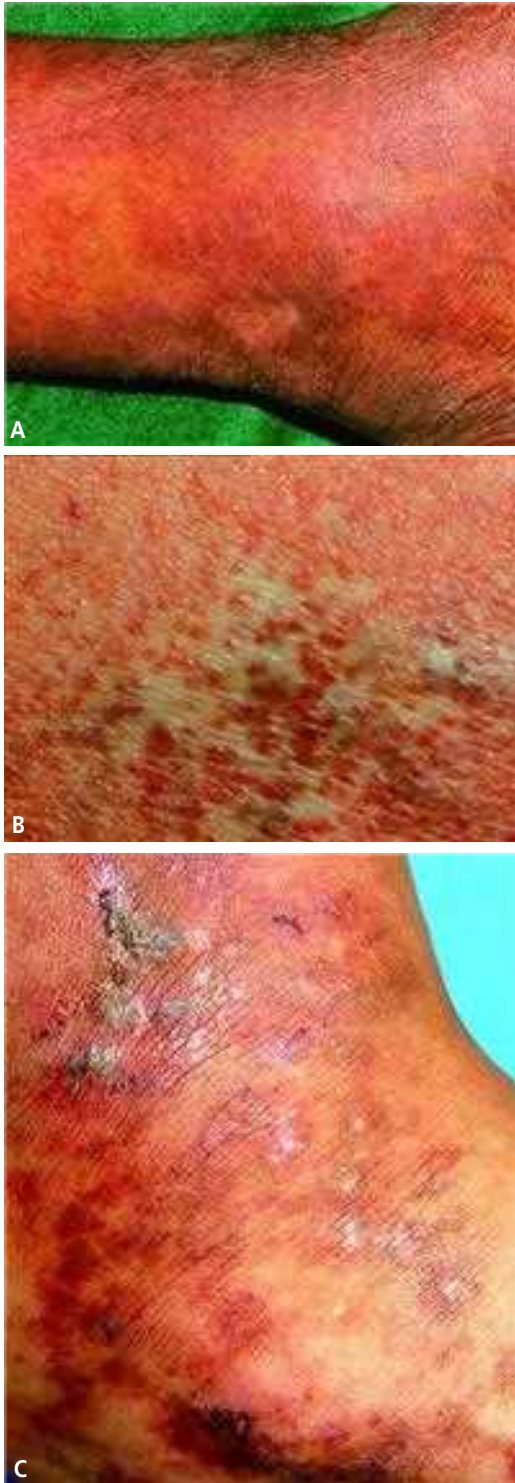


Fig. 9.5. Stasis dermatitis: A: punctate and confluent pigmentation B: lipodermatosclerosis: ivory white plaques with dilated capillary loops. C: dermatitis with characteristic pigmentation.

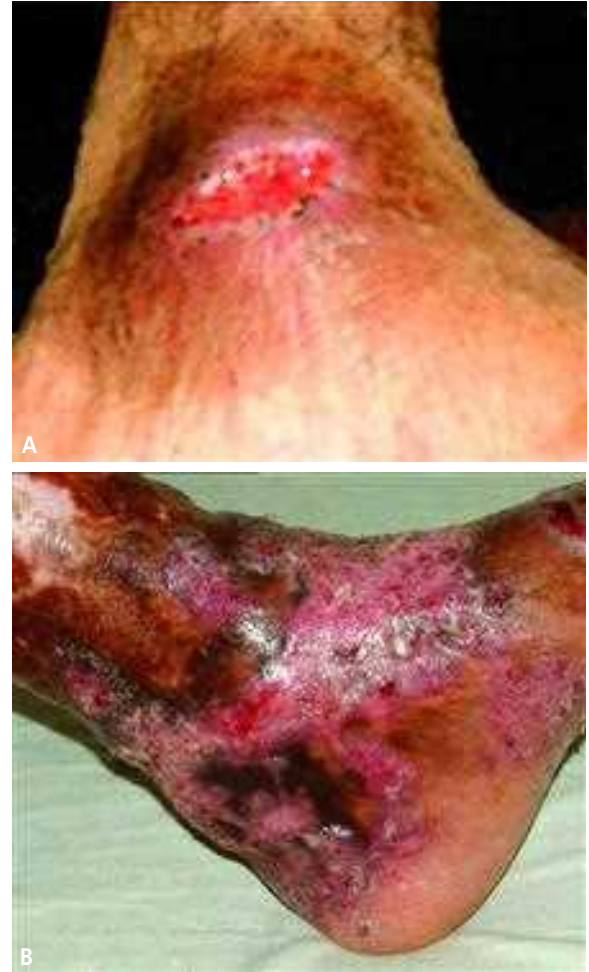

Fig. 9.6. Stasis ulcer: A: well-demarcated ulcer with variable depth at characteristic site near medial malleolus. B: scarring and atrophy may develop when stasis ulcer heals.

Site

Stasis dermatitis occurs over **gaiter**⁷ area of the leg (Fig. 9.5A and B). Venous ulceration occurs typically over the medial malleolus (Fig. 9.6).

Complications

- ❖ **Bacterial infection:** Ulcer may be complicated by cellulitis, lymphangitis, and septicemia.
- ❖ **Allergic contact dermatitis:** To topical applications (lanolin, neomycin, and parabens are notorious) is not uncommon and should be suspected, if there is an acute exacerbation of the dermatitis.

7. **Gaiter:** elastic/band/metal worn to hold the socks up. Also used by farmers working in the fields to hold trousers up. Gaiter area extends from mid calf to just below medial malleolus.

- ❖ Prolonged disease with recurrent ulceration may give the leg, look of an “**inverted champagne bottle**”.
- ❖ Squamous cell carcinoma should be ruled out if the edge is rolled or the base is hyperplastic. However, remember that stasis ulcers may frequently show **pseudoepitheliomatous hyperplasia**, which is not a malignant change but is often mistaken for squamous cell carcinoma. In this, the base is edematous with abundant granulation tissue and the edge is swollen and rolled out.

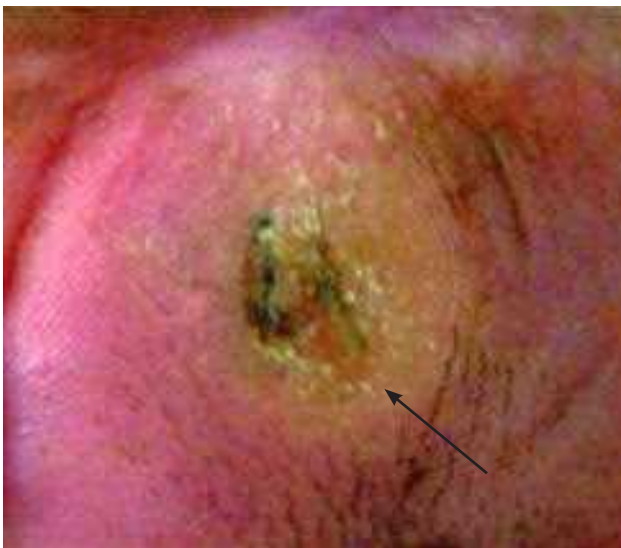

Fig. 9.7. Trophic ulcer: punched out ulcer. This one is healing. Note surrounding callus.

Table 9.3. Causes of chronic leg ulcers

Infections	Tuberculosis Deep fungal infections
Venous disease	Stasis ulcer
Arterial disease	Atherosclerosis Buerger's disease Systemic sclerosis
Small vessel disease	Diabetes Vasculitis Systemic lupus erythematosus
Neuropathy	Leprosy Diabetes Syphilis
Trauma	

Diagnosis

The diagnosis of venous ulcer is made on the basis of:

- ❖ Location, most typically on the medial malleolus.
- ❖ Stasis ulcers are often large and indolent. Brown pigmentation and sclerosis of surrounding skin (lipodermatosclerosis) are characteristics.

Differential diagnosis

Venous ulcers are commonest cause (Table 9.3) of leg ulcers and these should be differentiated from other causes of leg ulcers (Table 9.4).

Table 9.4. Differential diagnosis of leg ulcers

<i>Etiology</i>	<i>Location</i>	<i>Pain</i>	<i>Temperature of foot</i>	<i>Morphology of ulcers</i>
Venous	Medial aspect of ankles	Painless or minimally painful	Warm	<ul style="list-style-type: none"> ❖ Irregular ❖ May be large in diameter and of varying depth ❖ Floor of red granulation tissue ❖ Surrounding induration and pigmentation
Arterial	Toes, feet	Severe pain	Cold with absent peripheral pulses	<ul style="list-style-type: none"> ❖ Irregular (polycyclic) ❖ May be deep ❖ Floor black/gray with no granulation tissue. Islands of normal looking skin may be present
Vasculitic	Anywhere on legs	Painful	Warm	<ul style="list-style-type: none"> ❖ Begin as palpable purpura ❖ Punched out, shallow ulcer
Trophic	Pressure points, e.g., metatarsal arch, heel	Painless	Warm	<ul style="list-style-type: none"> ❖ Deep ulcers ❖ Surrounded by hyperkeratotic thick callus (Fig. 9.7) ❖ May be secondarily infected
Malignant	Any site	Generally painless	Warm	<ul style="list-style-type: none"> ❖ Everted edges ❖ Indurated ❖ Regional lymphadenopathy

Treatment

A multipronged approach is necessary.

General measures

Elevation of affected limb

- ❖ Helps healing by:
 - Facilitating venous drainage.
 - Decreasing pedal edema.
 - Decreasing tissue hypoxia.
- ❖ While lying, the foot should be elevated 12–18 cm above the hip. Even while sitting, it is preferable not to hang the feet but to place it on a foot stool.

Compression bandages and stockings

- ❖ Help by reducing edema and facilitating venous return.
- ❖ **Usage:**
 - Initially, compression bandages are used; later compression stocking can be used.
 - *Compression:* bandages are closely wrapped from the forefoot to just below the knee covering even the area of the ulcer (over a dressing). The bandage is left in place continuously even at night.
 - *Compression:* stockings (from toes to knee) are used once ulcer has healed. They can be removed at night but should be put on, first thing in the morning before getting down from bed.

Exercise

- ❖ Weight reduction is important in overweight patients.
- ❖ Though walking in moderation is beneficial, at other times it is best to keep the legs elevated.
- ❖ Leg exercises, massage, and ultrasonic treatment to the skin around the ulcers may help.

Local therapy

Cleaning of ulcers

- ❖ The ulcer is gently cleaned with **hydrogen peroxide**⁸ or saline.
- ❖ If the ulcer has adherent crusts, it is best to immerse the leg in a tub of warm saline to loosen the crusts preferably after applying an emollient.

- ❖ The ulcer is then dressed with bland dressings (paraffin tulle and zinc oxide), which should only be changed weekly or, at best, twice a week.

For infected ulcers

- ❖ Infected ulcers should be cleaned frequently (sometimes even twice a day!) with hydrogen peroxide⁸ or potassium permanganate or sodium hypochlorite applied as wet compresses.
- ❖ The ulcer is then dressed with povidone iodine or antibiotic dressings.
- ❖ Prolonged use of topical antibiotics may result in bacterial resistance or may cause contact dermatitis. Bacterial resistance does not develop with povidone iodine. If the eczema worsens after application of a medication, contact dermatitis should be suspected.

Systemic therapy

Symptomatic therapy

- ❖ **Analgesics:** Venous ulcers are painless but analgesics may be needed, when dressing is being changed.
- ❖ **Antibiotics**⁹: Used for infected ulcers. May be started empirically. Or after doing bacteriological cultures.
- ❖ **Other treatments:**
 - *Stanozolol:* prevents affected skin from ulceration by reducing lipodermatosclerosis, but once ulcer has developed, it has no benefit.
 - *Pentoxifylline:* hastens healing of ulcers, because of fibrinolytic properties; it also decreases blood viscosity and reduces the adhesiveness of platelets.
 - *Oxerutins:* reduce extravasation from the capillaries, so reduce edema thereby hastening healing.

Surgical therapy

- ❖ **Surgery on ulcer:** Can be done using:
 - Autologous punch or split-thickness grafts.
 - Synthetic films.
 - Epidermis grown in tissue culture.
 - Stem cells.
- ❖ **Surgery for varicose veins:** Incompetent perforators need to be operated.

8. **Hydrogen peroxide:** releases oxygen (which effervesces) and helps to loosen crusts.

9. **Antibiotics:** used include erythromycin, cloxacillin, ciprofloxacin, and to cover anaerobes, metronidazole.

Disorders of Small Blood Vessels

Telangiectasia

- ❖ Telangiectasia are permanently dilated, visible small vessels in the skin (Fig. 9.8).

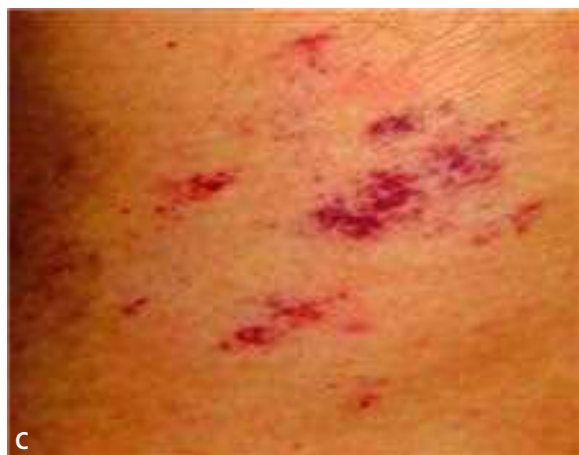
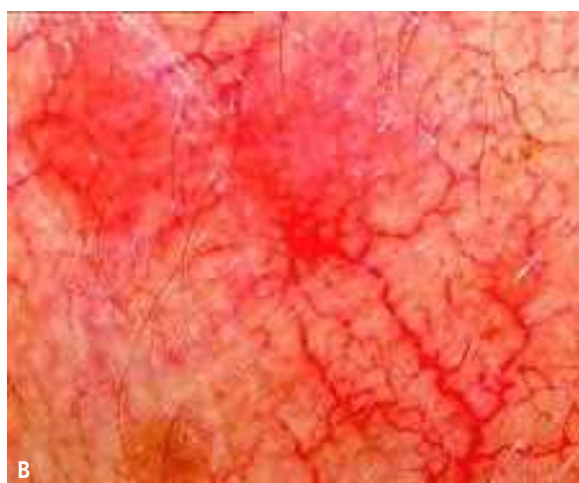
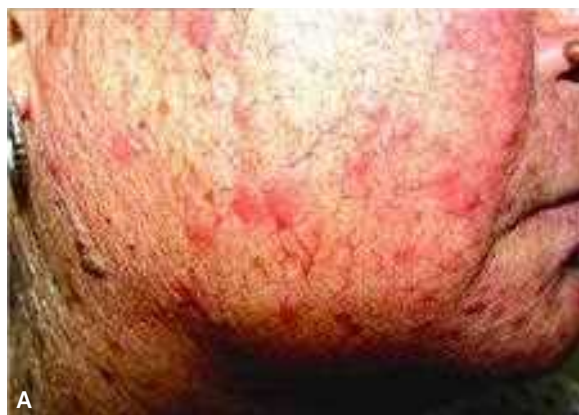Fig. 9.8. Telangiectasia: A: small dilated vessels which are visible. B: spider nevi: telangiectatic vessels which arise from a central arteriole. C: nevoid telangiectasia: congenital or acquired patches of superficial telangiectasia in a unilateral linear distribution.

Table 9.5. Causes of telangiectasia

Primary telangiectasia	Hereditary hemorrhagic telangiectasia Ataxia telangiectasia Generalized essential telangiectasia Nevoid telangiectasia
Secondary telangiectasia	Connective tissue diseases Rosacea Dermal atrophy Photoaging Liver disease Topical steroid application

- ❖ They appear in a variety of forms:
 - Linear.
 - Punctate.
 - Stellate (also called **spider nevi**).
- ❖ Telangiectasia can be due to several causes (Table 9.5).

Erythrocyanosis

- ❖ Seen in fat, young women.
- ❖ Presents as deep red mottled discoloration.
- ❖ Buttocks, thighs, and lower legs.

Erythromelalgia

- ❖ Idiopathic. Or secondary to polycythemia vera, lupus erythematosus, diabetes, and hypertension.
- ❖ Hands become red, hot, and painful on exposure to heat.
- ❖ Aspirin gives symptomatic relief.

Livedo Reticularis

Etiology

Livedo reticularis occurs due to stasis in the capillaries farthest from their arterial supply resulting in a reticulate pattern. It can be:

- ❖ **Physiological:** As seen in newborns, when it is called **cutis marmorata**.
- ❖ **Primary**
- ❖ **Secondary:** When it can be associated with autoimmune connective tissue disorders, vascular occlusion, hyperviscosity states, and cryopathies (Table 9.6).

Clinical Features

- ❖ Asymptomatic, net-like, marbled cyanosis of the skin (Fig. 9.9).
- ❖ Most frequently seen on the extremities; infrequently on the trunk.

Table 9.6. Secondary causes of livedo reticularis

Autoimmune	Connective tissue disorders Antiphospholipid syndrome
Vascular occlusion	Atherosclerosis
Hyperviscosity states	Polycythemia Thrombocythemia
Cryopathies	Cryoglobulinemia Cold agglutininemia

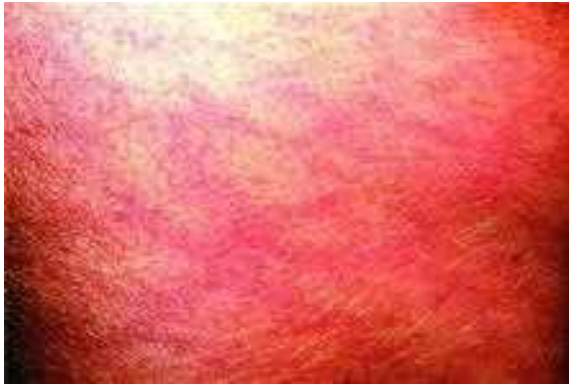

Fig. 9.9. Livedo reticularis: net-like marbled cyanosis.

Treatment

- ❖ Treat underlying cause.

Disorders of Lymphatic Vessels

Lymphedema

Lymphedema is due to inadequate drainage of interstitial tissue fluid by lymphatic vessels.

Table 9.7. Causes of lymphedema

Primary	
Congenital	
Familial	
Idiopathic	
Secondary	
Infections	Filariasis Lymphangitis Cellulitis Cat scratch fever
Lymph node obstruction	LN excision Malignant infiltration Radiation injury
Myxedema	

Etiology

There are several causes of lymphedema (Table 9.7) but in the tropics, filariasis is the commonest cause.

Clinical Features

- ❖ Initially, the edema is soft and pitting. Later, indurated and nonpitting.
- ❖ Skin thickens and follicles become prominent (Fig. 9.10A).
- ❖ Over period of time, the skin becomes pebbled and develops pseudopapillary growths (Fig. 9.10B) and hyperkeratosis (**elephantiasis nostras verrucosa**).
- ❖ Lower extremities are more frequently involved. Begins in the distal part of limb and progresses proximally. Also in genitals (Fig. 9.10C).
- ❖ Recurrent cellulitis, a common complication.

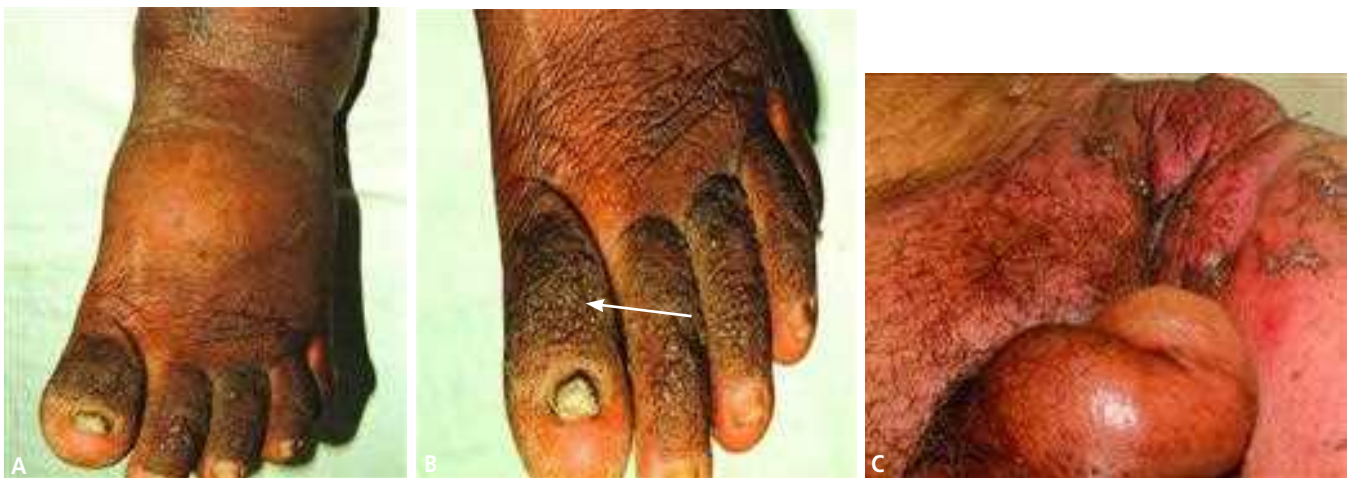

Fig. 9.10. Lymphedema: A: swelling of the leg. B: note pebbling of skin and pseudopapillary growths and hyperkeratosis (elephantiasis nostras verrucosa) on toes. C: malignant lymphedema due to secondaries in inguinal lymphnodes. Note: penile edema.

Treatment

Important to minimize edema to prevent subcutaneous fibrosis.

- ❖ Foot end elevation.
- ❖ Compression bandages and stockings.
- ❖ Prophylactic use of long-acting antibiotics, like penicillin to prevent recurrent cellulitis.
- ❖ Occasional (not regular) use of diuretics.
- ❖ Pneumatic decompression.
- ❖ Surgical procedures like removal of subcutaneous tissue and creating lymphovenous anastomoses.

Lymphangiectasis

Synonym: Acquired or secondary lymphangioma

- ❖ **Etiology:** Usually associated with lymphedema and due to :
 - *Neoplasia:* obstruction of lymph nodes in neoplasia either due to direct infiltration, surgical intervention (block dissection) or radiotherapy.
 - *Infections:* scarring of lymph nodes due to infections, *e.g.*, scrofuloderma.
- ❖ **Morphology:** Circumscribed groups of tense, thin-walled vesicles, which may ooze lymph spontaneously or after trauma (Fig. 9.11).
- ❖ **Sites:** Genitalia (vulva and scrotum) and lower extremities.

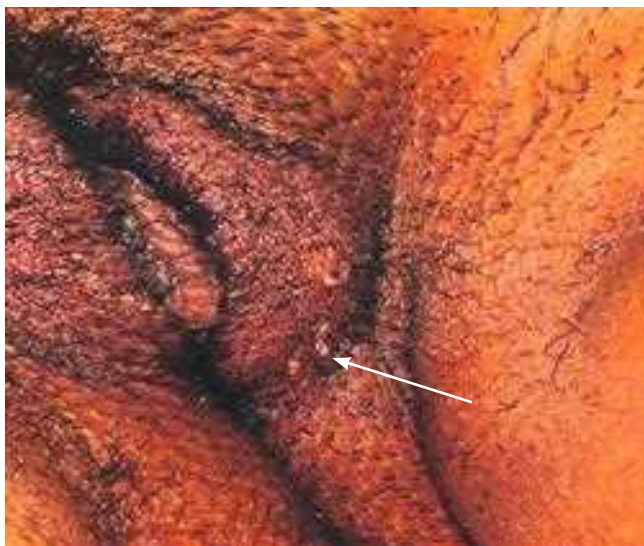

Fig. 9.11. Lymphangiectasis: circumscribed groups of tense, thin-walled vesicles on vulva, in patient who had scrofuloderma of the inguinal nodes.

❖ Treatment:

- Reduction of underlying lymphedema (easy on leg, difficult on genitalia, where compression is not possible).
- Control of infection.
- Palliative destruction of the “lymph vesicles” by laser or diathermy.

"This page intentionally left blank"

Chapter Outline

Erythema

Erythema multiforme syndrome•

Urticaria and Angioedema

Pathogenesis•

Classification of urticaria•

Clinical features•

Diagnosis•

Treatment•

Vasculitis

Hypersensitivity vasculitis◦

Polyarteritis nodosa◦

Granulomatous vasculitis◦

Pigmented purpuric dermatosis◦

Related disorders

Panniculitis◦

Pyoderma Gangrenosum◦

Sweet's syndrome◦

Introduction

- ❖ Several exogenous and endogenous stimuli trigger vascular responses in skin.
- ❖ The main changes occur in the dermis and include:
 - Vascular dilatation, manifesting as **erythema**.
 - Dermal and subcutaneous edema, manifesting as **urticaria** and **angioedema**.
 - Vessel wall inflammation (**vasculitis**), resulting in extravasation of blood, manifesting as **palpable purpura**.
- ❖ Initially, epidermis is normal. In later stages, epidermal necrosis may develop due to vascular occlusion.

Erythema

Erythema is a manifestation of several cutaneous reactions (Table 10.1).

Table 10.1. Causes of erythema of skin

Localized erythema	
❖ Palmar erythema	Pregnancy Liver diseases
❖ Annular erythema (Fig. 10.1A)	Infections Internal malignancies
❖ Discoid erythema (Fig. 10.1B)	Fixed drug eruption Erythema multiforme
❖ Malar erythema	Systemic lupus erythematosus
Generalized erythema	
❖ Scarletiform eruptions	Scarlet fever Drugs
❖ Morbilliform eruptions	Viral infections Drugs
❖ Roseolar eruptions	Secondary syphilis Drugs
❖ Toxic erythema	Idiopathic Stevens–Johnson syndrome–toxic epidermal necrolysis complex

•Should know

◦Good to know

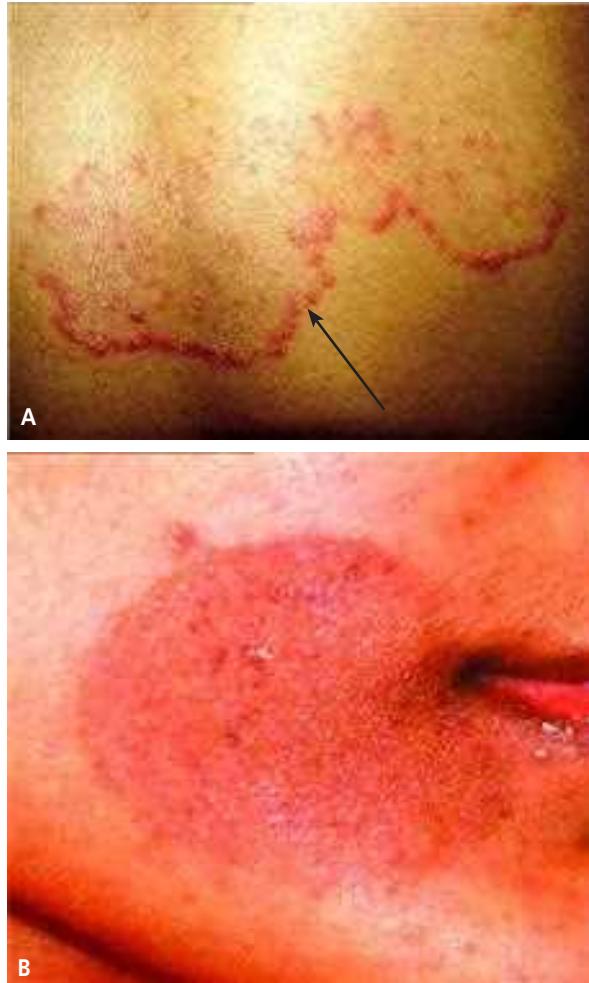

Fig. 10.1. Erythema: A: annular erythema due to erythema annulare centrifugum. Note the active edge has a trail of scales. B: discoid erythema due to fixed drug eruption.

Erythema Multiforme Syndrome (EMS)

Synopsis

Terminology: Two main subtypes: *Erythema multiforme* and *SJS–TEN complex*: SJS, BSA¹ <10%; SJS–TEN overlap, BSA 10–30%; TEN, BSA >30%.

Etiology: *Erythema multiforme*: HSV. *SJS–TEN complex*: Drugs (anticonvulsants and sulfonamides) most commonly; infections (*Mycoplasma*) less commonly.

Clinical features: *Erythema multiforme*: Target lesions characteristic. *Mucosal lesions*: infrequent (hemorrhagic crusting of lips). *SJS–TEN complex*: Generalized erythema with crinkled surface; epidermal denudation common. *Mucosal lesions*: universal; oral, eye, nasal, and genital.

Distribution: *Erythema multiforme*: Acral parts (symmetrically) and face. *SJS–TEN complex*: Face and central trunk initially. Later becomes generalized.

Complications: Mortality. Scarring of eyes.

Treatment: Removal/treatment of trigger. Also: *Erythema multiforme*: Symptomatic treatment. *Recurrent erythema multiforme*: Suppressive acyclovir (400 mg twice daily × 12 months). *SJS–TEN complex*: Good nursing care. Maintenance of nutrition, fluid, and electrolyte balance. Role of corticosteroids controversial. Intravenous IgG and cyclosporine helpful.

Terminology

Two main subtypes of EMS.

- ❖ ***Erythema multiforme***: Fairly common, recurrent, mild, predominantly cutaneous eruption triggered mainly by herpes simplex virus (HSV).
- ❖ ***Stevens–Johnson syndrome–toxic epidermal necrolysis complex (SJS–TEN complex)***: Uncommon, nonrecurrent, severe mucocutaneous eruption triggered most frequently by drugs. SJS–TEN complex is clinically graded into:
 - SJS: when BSA¹ involvement is <10%.
 - SJS–TEN overlap: when BSA involvement is 10–30%.
 - TEN: when BSA involvement is >30%.

Etiology

EMS is a cutaneous reaction pattern to a variety of triggers.

- ❖ ***Erythema multiforme***: Triggered mainly by HSV infection.
- ❖ ***SJS–TEN complex***: Triggered by a variety of agents (Table 10.2).

Table 10.2. Etiology of SJS–TEN complex

Drugs	<i>Anticonvulsants</i> : carbamazepine, phenytoin, barbiturates, lamotrigine <i>Chemotherapeutic agents</i> : sulfonamides, penicillin <i>NSAIDs</i> : butazones <i>Others</i> : allopurinol, nevirapine
Infection	<i>Bacterial</i> : <i>Mycoplasma pneumoniae</i> <i>Viral</i> : hepatitis A <i>Fungal</i> : histoplasmosis
Others	Systemic lupus erythematosus, graft vs host reaction, lymphoreticular malignancies
Idiopathic	5% of patients

1. BSA: Body surface area.

Epidemiology

- ❖ **Prevalence:** EM is a fairly common disorder.
- ❖ **Age:** Any age, but predominantly a disease of adolescents and young adults.
- ❖ **Gender:** Slight female preponderance.

Clinical Features

Onset

❖ *Erythema multiforme (EM):*

- An antecedent history of HSV (type 1, more frequent. Or type 2, less frequent) present in more than 70% of patients. Latent period²: about 1 week.
- *Prodromal symptoms:* minimal.
- Lesions appear in crop(s), usually single, sometimes multiple.

❖ *SJS–TEN complex:*

- An antecedent history of drug intake (Table 10.2) present in a large majority of patients. Most recently added drug most suspect. Latent period: 1–3 weeks; shorter for rechallenge.
- *Prodromal symptoms*³: common and sometimes severe.
- Onset sudden.

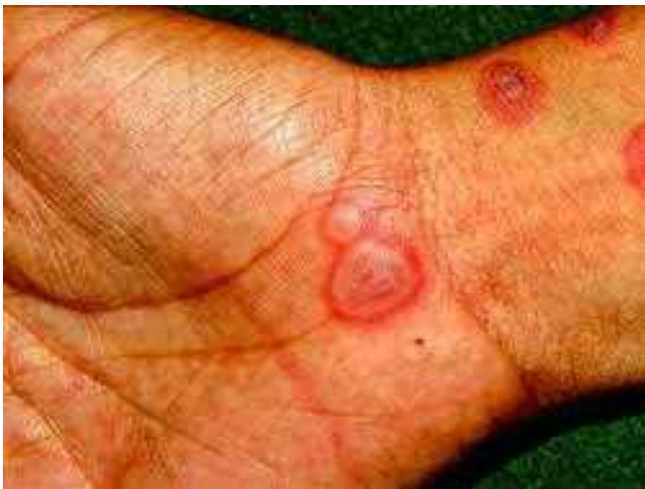

Fig. 10.2. Erythema multiforme: target lesion in acral parts. Target lesion consists of three concentric components—central dusky erythema, sometimes surmounted with vesicle/bulla, surrounded by a pale edematous ring which is in turn surrounded by an erythematous halo.

Morphology

❖ *Erythema multiforme:*

- Typical lesion of EM is a **target lesion**, which consists of three concentric components (Fig. 10.2):
 - Central dusky erythema, sometimes surmounted with a vesicle/bulla.
 - Pale edematous ring.
 - Erythematous halo.
- Larger lesions may have a central bulla and marginal ring of vesicles⁴.

❖ *SJS–TEN complex:*

- Appear as diffuse erythematous lesions, with a typically crinkled surface. Initial lesions may or may not be targetoid, but they rapidly coalesce into large sheets of dusky erythema. Some form flaccid, sometimes hemorrhagic blisters (Fig. 10.3A and B) and exhibit a positive Nikolsky sign.
- Eventually large areas of skin get denuded exposing erythematous oozing dermis, resembling second degree thermal burns.

Sites of predilection

- ❖ *Erythema multiforme:* Acral parts⁵ and face (Fig. 10.4).
- ❖ *SJS–TEN complex:* Involvement extensive. Starts from face, neck, chest and central trunk, and then rest of the body. Coalescence and denudation of skin more on face and neck in SJS–TEN overlap. Generalized in TEN.

Mucosal lesions

❖ *Erythema multiforme*

- Involvement less frequent (20%) and mild. Restricted to oral mucosa.
- Manifests as mild crusting of lips and occasional erosions in oral mucosa.

❖ *SJS–TEN complex*

- Involvement invariable, often severe. Involves not only oral mucosa (100%) and eyes (90%) but also genital and nasal mucosa (50%).
- Manifestations include:
 - *Oral mucosa:* Hemorrhagic crusting of lips. Also bullae which rapidly rupture

2. **Latent period:** time from clinical manifestations of HSV infection or drug exposure to onset of EM/SJS–TEN rash.

3. **Prodromal symptoms:** in the form of malaise, bodyache, and fever (flu-like).

4. Called **herpes iris of Bateman**.

5. **Acral parts:** palms and soles, dorsae of hands and feet, and distal part of arms and legs.

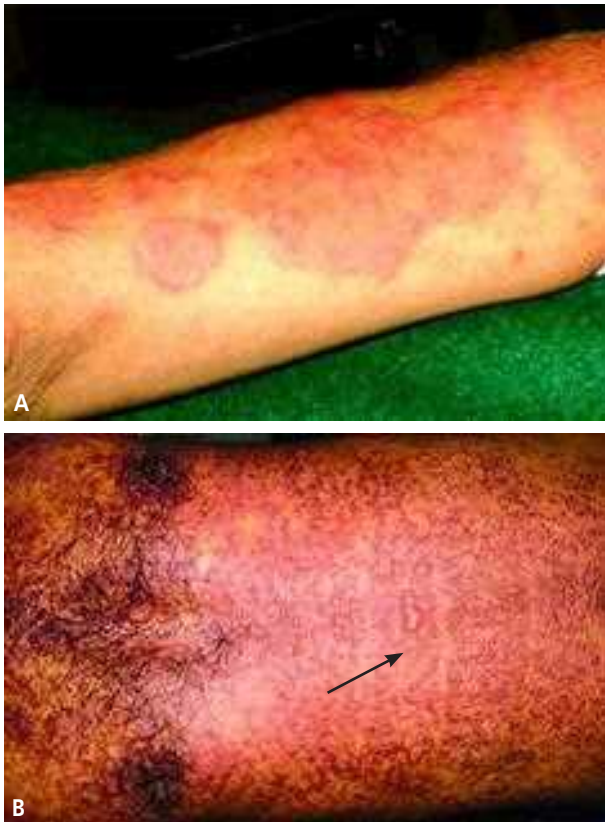


Fig. 10.3. A and B: SJS–TEN complex: appears as diffuse erythematous lesions, with a typically crinkled surface. Initial lesions may or may not be targetoid but they rapidly coalesce into large sheets of dusky erythema. Some form flaccid, sometimes hemorrhagic blisters.

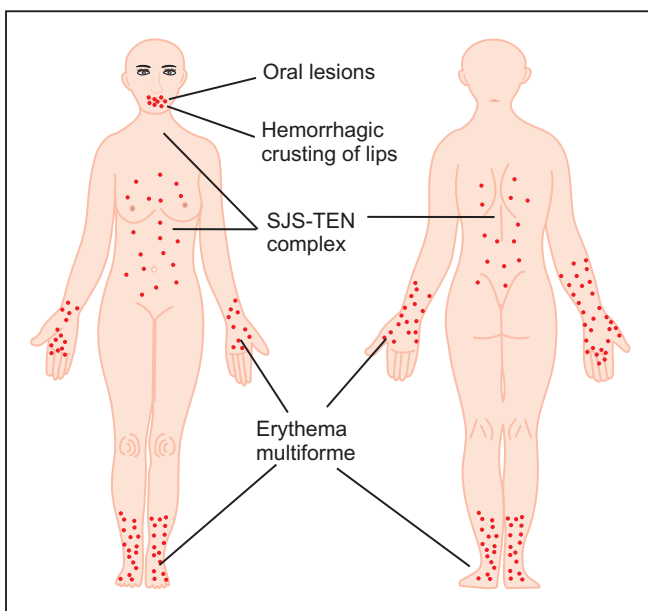


Fig. 10.4. Sites of predilection of erythema multiforme and SJS–Ten complex.

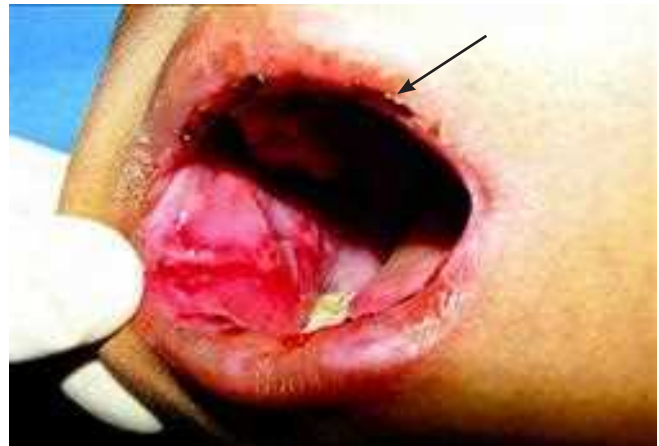

Fig. 10.5. SJS–TEN complex: extensive erythema and erosions in buccal mucosa and hemorrhagic crusting on lips.

to form erosions (Fig. 10.5) covered with grayish white slough.

- **Eye:** Purulent conjunctivitis, corneal erosions with possible sequelae like corneal opacities, synechiae, and even blindness.
- **Genital mucosa:** Erosions which may be complicated by urinary retention.
- **Nasal mucosa:** Erosions.

Course

- ❖ **Erythema multiforme:** Self-limiting. May recur.
- ❖ **SJS–TEN complex:** In absence of complications, healing of denuded skin begins within a couple of days and is complete within 3 weeks, except on pressure points and periorificial areas. Skin, which has not denuded, is shed in sheets (especially on palms and soles).

Complications

Complications are frequent in SJS–TEN complex, especially in extensive disease:

- ❖ **Secondary infection:** Of skin. And septicemia.
- ❖ **Complications of skin failure:** Electrolyte imbalance, temperature dysregulation, protein loss, and cardiac complications.
- ❖ **Tracheobronchial involvement:** May lead to asphyxia.
- ❖ **Eyes:** Corneal opacities, synechiae, and even blindness.

Investigations

Biopsy

Histopathology is distinctive:

- ❖ Epidermal cell necrosis.
- ❖ Papillary dermal edema.
- ❖ Endothelial swelling.
- ❖ Lymphohistiocytic perivascular infiltrate.

To Identify the triggers

- ❖ Careful history with regard to drug intake.
- ❖ History, examination, and investigations like chest X-ray to rule out infections (HSV and *Mycoplasma*).

Diagnosis

Erythema multiforme

Points for diagnosis

Diagnosis of erythema multiforme is based on:

- ❖ An antecedent history of HSV (oral/genital) infection.
- ❖ Only minimal prodrome.
- ❖ Appearance of target lesions (center dusky + bulla with erythematous halo) in crops.
- ❖ Predominant acral (symmetrical) and facial distribution.

Differential diagnosis

EM needs to be differentiated from:

a. Urticaria

Urticaria	EM
Morphology: wheals. If annular have a pale center	Initial urticarial plaque. Develops a dark center
Bullae: absent	Common
Lasts: 12–24 h	Much longer
Distribution: any part of body	Acral parts

SJS–TEN complex

Points for diagnosis

The diagnosis of SJS–TEN complex is based on:

- ❖ History of drug intake 1–3 weeks prior to onset of rash.
- ❖ Prodrome common and often severe.
- ❖ Sudden appearance of large areas of diffuse erythema with typically crinkled surface; ± target lesions. Rapidly coalesce, form blisters (flaccid), and denude. Positive Nikolsky sign.
- ❖ Face, neck, and central trunk initially; generalized later.
- ❖ Mucosal involvement universal: oral, eye, genital, and nasal.
- ❖ Systemic manifestations common and severe.

Differential diagnosis

SJS–TEN complex needs to be differentiated from:

b. Bullous pemphigoid (BP)

BP	SJS–TEN complex
Chronic eruption	Acute eruption. Patient toxic
Tense, large, and hemorrhagic bullae. Often do not rupture but roof settles down	Bullae surrounded by rim of erythema; bullae usually rupture, sometimes in sheets.
Oral lesions uncommon	Erosions in buccal mucosa; hemorrhagic crusts on lips

Treatment

Remove the cause

- ❖ Infections should be treated appropriately. In case of HSV associated EM, acyclovir may be given.
- ❖ All drugs should be withdrawn. If that is not possible, substitute with chemically unrelated drugs.

Symptomatic treatment

EM

Symptomatic treatment with antihistamines and calamine lotion.

Recurrent EM

- ❖ HSV infection is often the cause of recurrent EM. Suppressing long-term therapy with acyclovir (400 mg, twice daily × 6–12 months) may help.
- ❖ Suppressing acyclovir also helps in recurrent EM, even in the absence of clinically overt HSV infection.

SJS–TEN complex

- ❖ **Nursing care:** Extremely important and includes:

- Maintenance of a patent airway.
- Good nutrition.
- Proper fluid and electrolyte balance.
- Suspension beds for patients with extensive lesions.
- Prevention of secondary infection, by intensive barrier nursing, use of prophylactic antibiotics (but only if necessary).
- Thermoregulation.
- Care of mouth and eyes.

- ❖ **Systemic steroids**

- Role is debatable.

- Many dermatologists use a short course of steroids (about 80 mg prednisolone equivalent daily) during the acute phase. Even given as bolus pulse therapy.
- Usually relieve constitutional symptoms.
- ❖ **Newer modalities:** Cyclosporine and intravenous IgG are promising.

Urticaria and Angioedema

Synopsis

Terminology: Two main subtypes: *Urticaria*: Due to edema of dermis. *Angioedema*: Due to edema of dermis and subcutis.

Etiology: Edema of dermis and subcutis due to mediators released from mast cells. Degranulation of mast cells mediated by IgE, complement, directly by drugs or idiopathic.

Triggers: Physical stimuli (scratching, cold, sunlight, pressure, etc.), dietary and inhaled allergens, and drugs. Often no cause.

Clinical features: Itchy evanescent wheals in *urticaria*. Less evanescent, not itchy in *angioedema*. Linear in *dermographism*; small wheals in *cholinergic urticaria*.

Complications: Laryngeal edema, anaphylaxis.

Treatment: Remove triggers. Antihistamines (often combination) mainstay of treatment. Oral steroids in anaphylaxis and recalcitrant urticaria. Immunosuppressives (methotrexate, azathioprine, and cyclosporine) in resistant disease.

Urticaria is a heterogeneous group of disorders characterized by itchy wheals, which develop due to evanescent edema of dermis (and sometimes of subcutis).

Pathogenesis

- ❖ Basic pathology is vasodilatation of vessels and leakage of fluid into the surrounding tissues.
- ❖ Though several mediators are involved, **histamine** released from **mast cells** plays a key role.
- ❖ Histamine is released from mast cells by several mechanisms:
 - Antigen-induced IgE mediated release
 - Classical complement pathway induced.
 - Direct induced by drugs and chemicals.

Classification of Urticaria

Urticaria is classified either based on chronicity or on pathogenesis.

Depending on Duration

Based on its chronicity, urticaria is classified into:

- ❖ **Acute urticaria:** Urticaria of <6 weeks duration⁶. Etiological trigger is more likely to be identified in acute urticaria.
- ❖ **Recurrent acute urticaria:** This is recurrent episodes of urticaria, each episode lasting <6 weeks.
- ❖ **Chronic urticaria:** When urticaria is of >6 weeks duration. An etiological trigger is less likely to be identified in chronic urticaria.

Depending on Pathogenesis

Depending on the probable pathogenetic mechanism, urticaria is classified into several types (Table 10.3).

Table 10.3. Causes of urticaria

Idiopathic	
Physical	Dermographic Cholinergic Cold Heat Solar Delayed pressure
Hypersensitivity	
Autoimmune	
Drug induced	
Contact	
Inherited	Hereditary angioedema

Clinical Features

General Features

- ❖ **Symptoms:** Itching is prominent, especially if wheals are superficial. However, patients tend to rub rather than scratch their lesions, so scratch marks are not seen.
- ❖ **Morphology:** Lesions begin as erythematous macules, which rapidly evolve into pale pink edematous wheals with a surrounding flare (Fig. 10.6). Larger lesions annular with paler centre.

6. **6 weeks:** cut off is arbitrary.

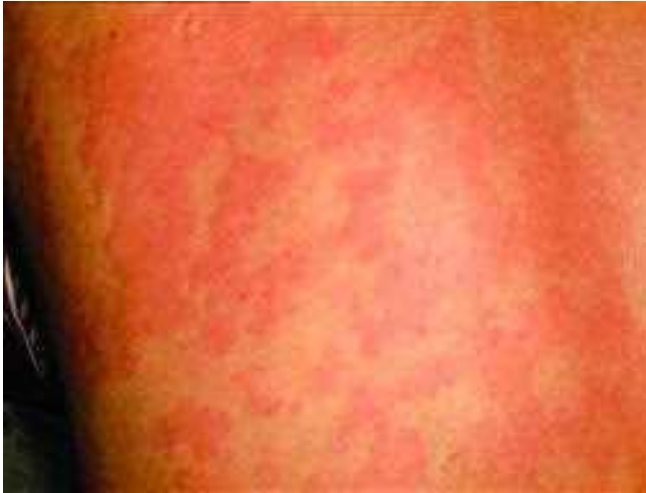

Fig. 10.6. Urticaria: pale pink edematous wheals with a surrounding flare.

- ❖ **Evolution:** Wheals last a few hours and resolve within 24–48 h leaving behind normal skin. Wheals of cholinergic urticaria subside within a few minutes.
- ❖ **Number and size:** Number and size of wheals are variable. Cholinergic urticaria (a type of physical urticaria) is characterized by pinpoint wheals.
- ❖ **Shape:** Shape can be circular, annular, serpiginous or bizarre (Fig. 10.7). Dermographic urticaria is characterized by linear wheals.
- ❖ **Angioedema:** Half the patients with urticaria have associated episodes of **angioedema** in which pale pink swellings occur especially on the face affecting eyelids and lips (Fig. 10.8).

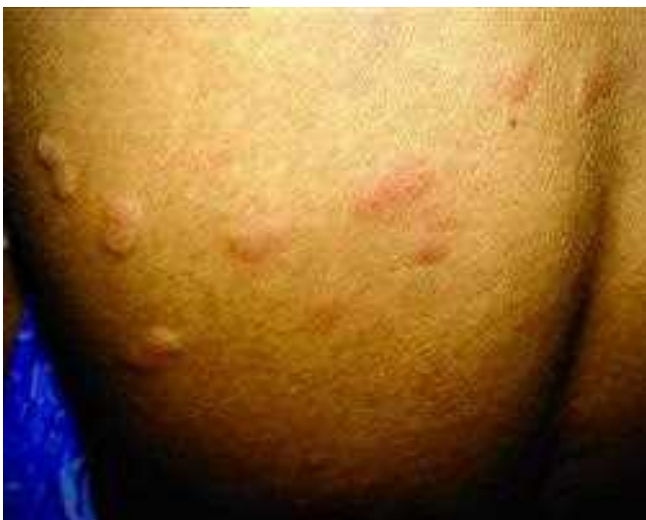

Fig. 10.7. Urticaria: itchy pink wheals.

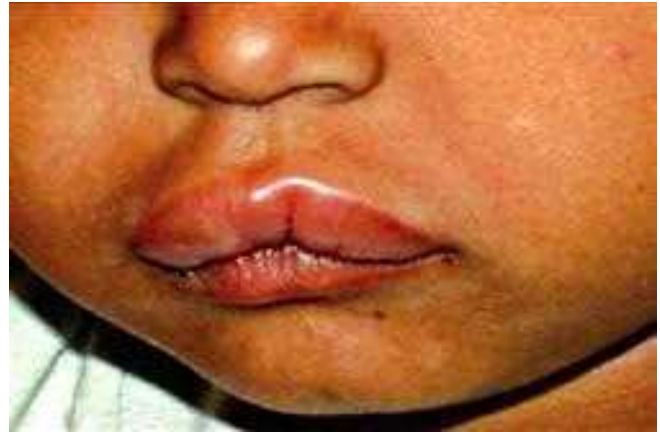

Fig. 10.8. Angioedema: pale pink swelling of lips. May be associated with swelling of tongue, pharynx, and larynx.

May also be associated with swelling of tongue, pharynx, and larynx (when the patient may present to the medical emergency). Itching is minimal and the swelling may last for several days.

- ❖ **Associated features:** Urticaria may be associated with systemic symptoms in form of:
 - Malaise and fever.
 - Headache.
 - Abdominal pain, diarrhea, and vomiting.
 - Arthralgia.
 - Dizziness and syncope.
 - Anaphylaxis (with severe acute urticaria).

Physical Urticaria

Physical urticaria is a subgroup of urticaria in which a specific physical stimulus produces reproducible whealing (Table 10.4). Dermographic urticaria and cholinergic urticaria are common varieties of physical urticarias.

Hypersensitivity Urticaria

- ❖ Commonest type of acute urticaria, due to IgE-mediated hypersensitivity to specific antigens.
- ❖ Triggers of hypersensitivity urticaria are listed in Table 10.5.

Autoimmune Urticaria

- ❖ Thirty percent of patients with chronic urticaria have circulating auto-antibodies present in their sera.
- ❖ Patients show a positive autologous serum skin test (**ASST**).

Table 10.4. Clinical features of different types of physical urticarias

Type of urticaria	Precipitating factors	Morphology of lesions	Comments
Dermographic urticaria (Fig. 10.9A)	Rubbing, scratching	Linear wheals	Young adults
Cholinergic urticaria (Fig. 10.9B)	Sweating (anxiety, strenuous work, gustatory stimuli)	Small, very transient wheals	Adolescents, worse in winters <i>Variant:</i> cholinergic itching
Cold urticaria	Cold stimuli (wind, drinks)	Small/large wheals	Associated occasionally with cryopathies
Solar urticaria	Sun exposure	Lesions on photo-exposed parts	Exclude erythropoietic protoporphyria
Delayed pressure urticaria	Sustained pressure	Urticaria develops 3–6 h after pressure. Lasts for 12–72 h. Buttocks (prolonged sitting), hands (in manual workers), under feet (prolonged walking), and waist (tight underclothes)	Associated chronic (ordinary) urticaria in 30% of patients

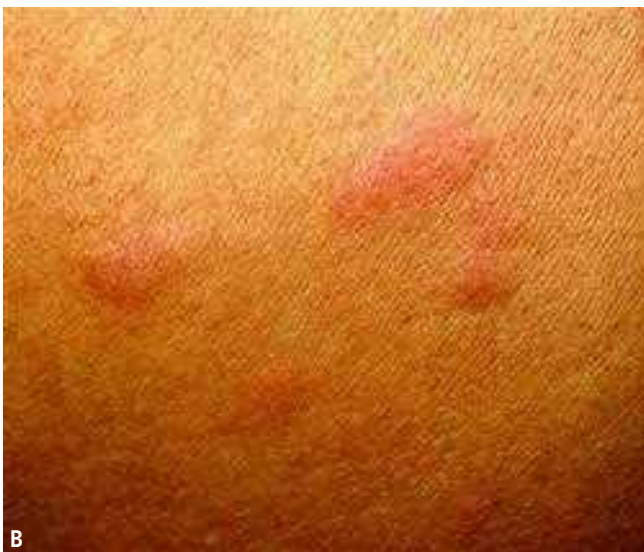

Fig. 10.9. Physical urticaria: A: dermographic urticaria: linear wheals at sites of scratching. B: cholinergic urticaria: small very evanescent wheals.

Table 10.5. Causes of hypersensitivity urticaria⁷

1. Infections	5. Injections
2. Infestations	6. Insect bites
3. Ingestions	7. Instillation
4. Inhalations	

- ❖ Urticaria more severe, persistent often with systemic manifestations.
- ❖ May be less responsive to antihistamines and require immunosuppressive therapy.

Drug-Induced Urticaria

Drugs cause urticaria by different mechanisms (Table 10.6).

Table 10.6. Drugs causing urticaria

Direct degranulation of mast cells Aspirin Indomethacin
Interfering with arachidonic acid metabolism Opiates: morphine, codeine NSAIDs Sulfonamides Curare Radioactive contrast
Through IgE Penicillin
Through complement system Blood products

7. **Causes of hypersensitivity urticaria:** often remembered as 7 Ins (not sins!).

Hereditary Angioedema

- ❖ Autosomal dominant inheritance.
- ❖ Due to deficiency of inhibitor of C₁ esterase, resulting in consumption of complement.
- ❖ Family history usually present.
- ❖ Manifests as angioedema precipitated by trauma (even minor ones like tooth extraction). Urticaria is absent.
- ❖ **Associated features:** Recurrent abdominal pain and vomiting. Edema of soft tissues, including laryngeal edema and anaphylaxis.

Course (Fig. 10.10)

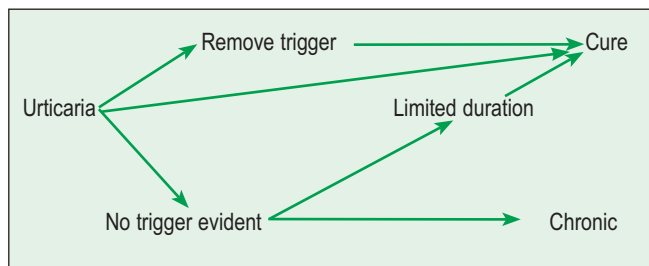


Fig. 10.10. Course of urticaria.

Complications

- ❖ Anaphylactic reactions with laryngeal edema and asphyxiation; edema of tracheobronchial tree leading to asthma.
- ❖ Interference with sleep due to itching.
- ❖ Sedation due to antihistamines (taken as treatment) may interfere with day-to-day working.

Diagnosis

Two questions need to be answered.

- ❖ Is it urticaria?
- ❖ Which type of urticaria?

Is it Urticaria?

The diagnosis of urticaria is based on the presence of:

- ❖ Evanescent and erythematous wheals.
- ❖ Lesions subside within 72 h⁸ leaving behind normal skin (*i.e.*, no pigmentation, scaling or atrophy).

Differential diagnosis

Urticaria is easy to diagnose but needs to be differentiated from the following conditions:

a. Insect bite hypersensitivity (IBH)

IBH	Urticaria
<i>Morphology:</i> initial response urticarial. Evolves into a papule instead of subsiding (so called papular urticaria)	Transient wheals. Subsides in < 72 h and on subsidence leave normal skin
<i>Central punctum:</i> prominent	Not seen
<i>Scratch marks:</i> frequent	Absent

b. Erythema multiforme (EM)

EM	Urticaria
<i>Morphology:</i> initial urticarial plaque develops a dark center	Wheal, if it becomes annular develops a paler center
<i>Bullae:</i> seen sometimes	Absent
<i>Distribution:</i> mainly acral	Anywhere on body
<i>Mucosal lesions:</i> in form of erythema and erosions	In form of angioedema

c. Urticarial vasculitis (Fig. 10.11)

Urticarial vasculitis	Urticaria
<i>Lasts:</i> >72 h	<72 h
<i>Subside:</i> with scaling, bruising, and hyperpigmentation	Without residual changes
<i>Associated with:</i> abdominal pain and arthritis	Only occasionally abdominal pain
<i>C₃ levels:</i> low	Normal
<i>Histopathology:</i> shows vasculitis	No vasculitis

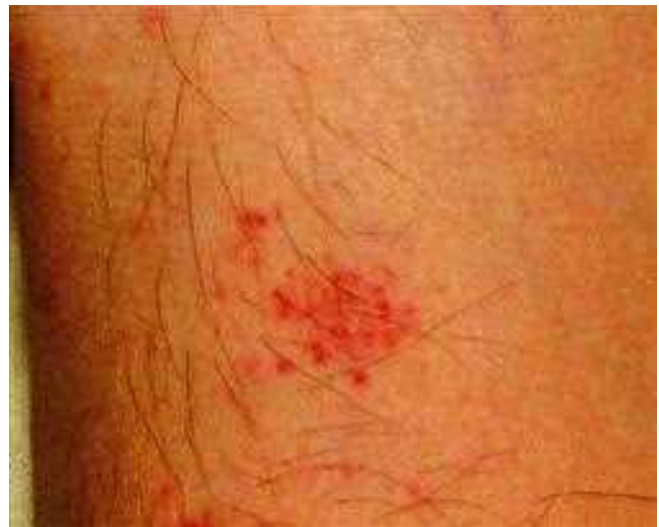

Fig. 10.11. Urticarial vasculitis: urticarial lesions which subside after more than 72 h with bruise-like hyperpigmentation. Often associated with abdominal pain and arthritis.

8. Angioedema may last longer.

Which Type of Urticaria

- ❖ **History:** A good clinical history often helps to clinch the diagnosis. Laboratory tests are only seldom more helpful than a well-taken history. The history should include:
 - Any physical stimuli which aggravate the urticaria.
 - Careful history of drug intake, including history of intake of over-the-counter drugs, *e.g.*, acetyl salicylic acid.
 - History suggestive of any infection.
- ❖ **System review:** To rule out an underlying disease.
- ❖ **Investigations:** Usually based on clues from the history:
 - *Routine screening tests:* in chronic urticaria (not in acute urticaria), screening tests such as complete blood counts, erythrocyte sedimentation rate, routine biochemical tests, and urine and stool examination may need to be done.
 - *Diet elimination test:* to rule out food allergies, if history so suggests.
 - *Provocation of urticaria*⁹: by using appropriate physical tests, *e.g.*, dermographism can be reproduced by stroking skin with blunt object.
 - *Autologous serum skin test (ASST)*¹⁰: done in autoimmune urticaria.

Treatment

Principles of management of urticaria are discussed in Table 10.7.

Eliminate Triggers

Trigger (drugs, foods, inhalants, etc.), if identifiable should be removed. More easily done in acute urticaria than in chronic.

Drugs used

Antihistamines

Basis of use

- ❖ Histamine is the main mediator of urticaria. H₁

Table 10.7. Management of urticaria

Type	Treatment
Dermographic urticaria	Avoid scratching Antihistamines
Cholinergic urticaria	Avoid cholinergic stimuli Antihistamines
Cold urticaria	Avoid exposure to cold Antihistamines
Solar urticaria	Avoid sun exposure Sunscreens Antihistamines Beta-carotene PUVA*
Hypersensitivity urticaria	Remove cause Antihistamines (generally H ₁ -blockers, sometimes H ₂ -blockers). Steroids, if associated angioedema present Avoidance of some drugs (aspirin, opiates)
Autoimmune urticaria ¹¹	Antihistamines Immunosuppressives (azathioprine, cyclosporine, methotrexate)
Hereditary	Avoid trauma
Angioedema	Androgenic steroids

* PUVA: Psoralens + UVA.

receptor activation causes itch, wheal and flare while H₂ receptors play a small role in causing wheals.

- ❖ So, H₁ antihistamines are first line of treatment. They act as **inverse agonists**¹² of H₁ receptors.

Classification

Two groups of H₁ antihistamines are available:

- ❖ **Conventional or sedating antihistamines:** *e.g.*, pheniramine (25 mg), chlorpheniramine (2, 4 mg), hydroxyzine (10, 25 mg) and promethazine (10, 25 mg). All need to be given 2–3 times daily.
- ❖ **Newer or nonsedating antihistamines:** *e.g.*, cetirizine¹³ (10–20 mg daily), levocetirizine (5 mg daily), fexofenadine (120–180 mg daily), olopatadine (10 mg daily), loratadine (10 mg daily). Can be given as a single daily dose.

9. **Provocation of urticaria:** lesions can only be provoked if patient is not on antihistamines for at least 48 h.

10. **ASST:** performed by injecting 0.05 ml of patient's own serum intradermally into a forearm, with saline used as control on contralateral arm.

11. **Autoimmune urticaria:** more resistant to treatment with antihistamines and would sometimes warrant use of immunosuppressives.

12. **Inverse agonist:** binds to the same receptor binding site as an agonist for that receptor and reverses constitutive activity of receptors.

13. **Cetirizine:** though promoted as a nonsedating antihistamine, cetirizine does cause sedation in some patients.

Dose and schedule

- ❖ Minimum dose of antihistamine which controls the urticaria should be given.
- ❖ It is often necessary to combine antihistamines of two different groups, *e.g.*, sedating and nonsedating or a long-acting and short-acting antihistamines.
- ❖ In patients who continue to be nonresponsive, H₂ antihistamines can be added.

Adverse effects❖ **Sedation:**

- Conventional antihistamines are sedating but there is a remarkable individual variation. Warn the patient to avoid driving and working on machines as antihistamines slow down reflexes.
- Newer antihistamines like fexofenadine, loratadine and levocetirizine are not sedating.

- ❖ **Cardiotoxicity:** Some antihistamines like terfenadine¹⁴, when taken above recommended doses, cause prolongation of QT interval and ventricular tachycardia.

❖ **Teratogenicity:**

- Antihistamines are best avoided during the first trimester.
- If that is not possible, then chlorpheniramine and promethazine can be prescribed.

Others

- ❖ **Adrenergic drugs:** Adrenaline parenterally, pseudoephedrine or terbutaline may help some patients.

❖ **Corticosteroids:**

- Routine use should be avoided.
- Used for recalcitrant urticaria in tapering doses and definitely in anaphylaxis, which is a life-threatening condition.

- ❖ **Other immunosuppressives:** Azathioprine, cyclosporine, methotrexate.

Strategy for Treating Urticaria**Acute urticaria**

- ❖ Treat with antihistamines.
- ❖ Combine if single does not work, preferably from two different groups.

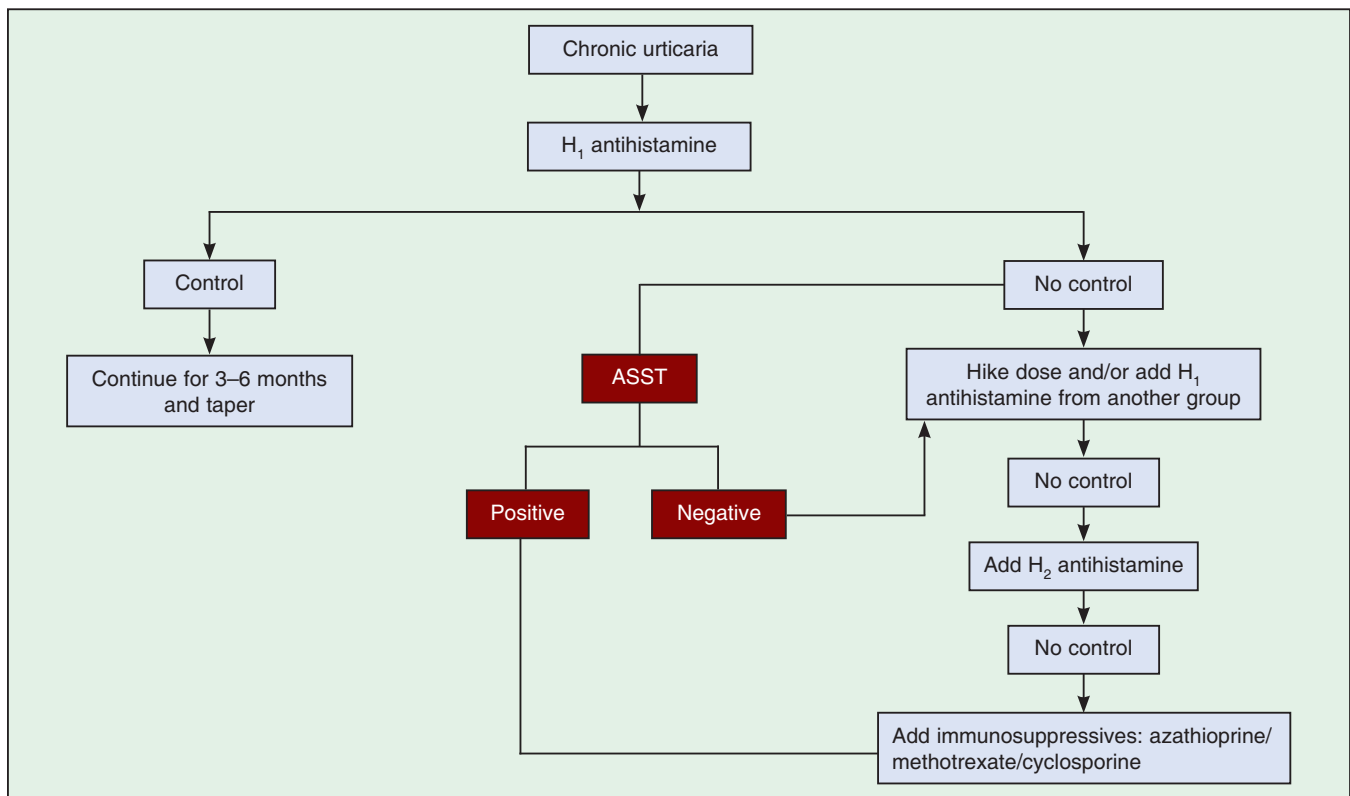
Chronic urticaria (Fig. 10.12)

Fig. 10.12. Algorithm for management of chronic urticaria. Color chart in settings where ASST (autologous serum skin test) is being done.

14. **Terfenadine:** no longer available in most countries.

Anaphylaxis (Table 10.8)

Table 10.8. Treatment of anaphylaxis

❖ Respiratory assistance:
➤ Maintain patent airway.
➤ Oxygen supplementation.
➤ Assisted respiration.
➤ Tracheostomy, if needed.
❖ Medical treatment:
➤ Adrenaline injection (1:1000), 0.3–0.5 ml subcutaneous or intramuscular (never intravenous).
➤ Chlorpheniramine, (20 mg) slowly intravenous.
➤ Hydrocortisone, 100 mg intravenous.

Vasculitis

- ❖ Vasculitis is inflammation of blood vessels.
- ❖ Clinical features and classification (Table 10.9) of vasculitis depends on:
 - Size of blood vessel involved.
 - Type of inflammation.
 - Organs involved.
- ❖ Vasculitis can be triggered by:
 - Infections.
 - Drugs.
 - Immunological diseases.
 - Malignant diseases.

Table 10.9. Classification of vasculitis

Type of vasculitis	Blood vessels involved	Inflammation
Hypersensitivity vasculitis Variant: Henoch–Schönlein purpura	Postcapillary venules	Neutrophilic infiltrate
Polyarteritis nodosa	Small and medium-sized arteries	Initially neutrophils, later mononuclear infiltrate
Wegener's granulomatosis	Small arteries and veins	Granulomatous infiltrate
Nodular vasculitis	Probably medium-sized venules	Granulomatous infiltrate with lobular panniculitis
Pigmented purpuric dermatosis	Capillaries	Minimal infiltrate

Hypersensitivity Vasculitis

Synonym: Leucocytoclastic vasculitis and others

Synopsis

Etiology: Infections (hepatitis B and others), drugs, systemic lupus erythematosus, and dysproteinemias.

Morphology: Painful, palpable purpura. Less frequently nodules and ulcers.

Sites: Lower extremities and less frequently upper extremities.

Variants: *Henoch–Schönlein purpura*: skin lesions, intestinal involvement (melena), renal involvement and arthritis.

Investigations: Histopathological confirmation. Rule out intestinal involvement (stool for occult blood) and renal involvement (urine for RBC casts).

Treatment: *Mild cases:* symptomatic treatment. *Systemic involvement:* aggressive treatment with systemic steroids and immunosuppressives.

Etiology

Triggers

- ❖ **Infections:** Overt, but more often occult infection. Hepatitis B virus infection (30% of patients), hepatitis C virus, and β hemolytic streptococcal infection.
- ❖ **Drugs:** Sulfonamides, antitubercular drugs, and anticonvulsants.
- ❖ **Others:** Systemic lupus erythematosus, reticuloendothelial malignancies and dysproteinemias.

Pathogenesis

Immune complexes, deposited in walls of post-capillary venules, activate complement and attract neutrophils which induce vasculitis.

Clinical Features

Morphology

- ❖ Typical lesion is painful **palpable purpura**¹⁵ which manifests as bright red, well-demarcated macules and papules with central purpura.
- ❖ Some lesions develop central ulceration due to necrosis of overlying skin.
- ❖ Lesions appear in crops.

15. **Palpable purpura:** palpable purpura is a hallmark of vasculitis. Lesions are palpable because of perivascular inflammation and extravasation of red cells.

Sites of predilection

- ❖ Most frequently on lower extremities, especially legs.
- ❖ Less frequently on upper extremities.

Variants

Henoch–Schönlein purpura

- ❖ Often preceded by an upper respiratory infection.
- ❖ Children.
- ❖ Clinically characterized by triad of:
 - Palpable purpura (Fig. 10.13).
 - Arthritis.
 - Abdominal pain.
- ❖ Immunopathology: Characterized by deposition of IgA in vessel walls.
- ❖ Rule out renal involvement by urine microscopy (RBC casts).
- ❖ Rule out intestinal involvement by stool examination (occult blood).

Course and prognosis

- ❖ Cutaneous lesions are self-limiting, unless complicated by ulceration.
- ❖ Systemic involvement not frequent.

Investigations

Investigations are required to:

- ❖ Confirm diagnosis.
- ❖ Identify trigger.
- ❖ Rule out systemic involvement.

Confirming diagnosis

Biopsy confirms the diagnosis. The findings include:

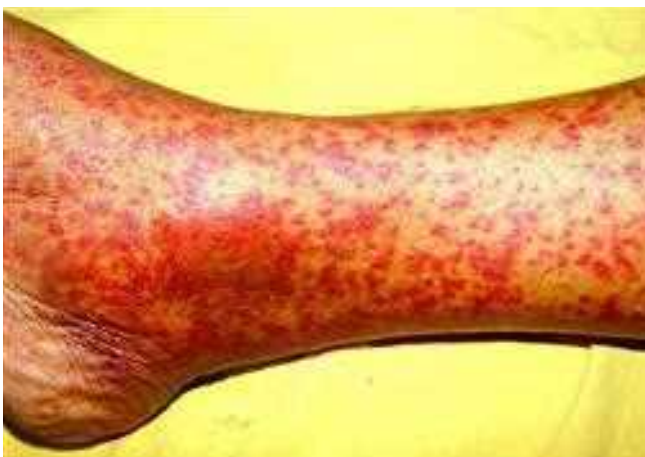

Fig. 10.13. Hypersensitivity vasculitis: palpable purpura on lower extremities.

- ❖ **Histopathology:** Perivascular (around small vessels) neutrophilic infiltrate and nuclear debris.
- ❖ **Immunopathology:** Perivascular deposition of immune complexes containing IgM.

Identifying trigger

Though often it is not possible to identify the cause, it is necessary to:

- ❖ Rule out intake of drugs by careful history.
- ❖ Rule out underlying infection, especially hepatitis B and C infection.

Ruling out systemic involvement

- ❖ Physical examination, chest X-ray, erythrocyte sedimentation rate and biochemical parameters to monitor the function of other systems is important.
- ❖ Urine analysis (for proteinuria and casts) is important because many cutaneous vasculitis have associated renal involvement.

Treatment

General measures

- ❖ **Eliminate triggers:** Triggers should be identified and removed.
- ❖ Bed rest.

Mild disease

If skin lesions are mild and there is no systemic involvement, following may help:

- ❖ Colchicine, 0.5 mg thrice a day (adult dose).
- ❖ Dapsone, 100 mg a day.

Severe disease

When there is evidence of systemic disease (renal, nervous system, gastrointestinal system) or skin lesions are severe, a more aggressive approach is needed with:

- ❖ Corticosteroids.
- ❖ Immunosuppressive agents like azathioprine and methotrexate.

Polyarteritis Nodosa (PAN)

PAN is a necrotizing vasculitis of small and medium-sized arteries.

Etiology

Caused by a variety of triggers:

- ❖ **Infections:** β hemolytic streptococcal infection, hepatitis B and C virus.

- ❖ **Malignancies:** Lymphoreticular malignancies like B-cell lymphomas.
- ❖ **Immunotherapy.**

Classification

Two disease subtypes recognized:

- ❖ **Cutaneous PAN:**
 - Disease self-limiting.
 - Only cutaneous manifestations.
- ❖ **PAN with systemic involvement:**
 - Disease progressive.
 - Multisystem disease with involvement of kidneys, heart, and gastrointestinal tract.

Clinical Features

Cutaneous lesions

- ❖ Tender subcutaneous nodules, along the line of arteries (Fig. 10.14), with purpura or ulceration of overlying skin.
- ❖ Livedo reticularis (net-like erythema).

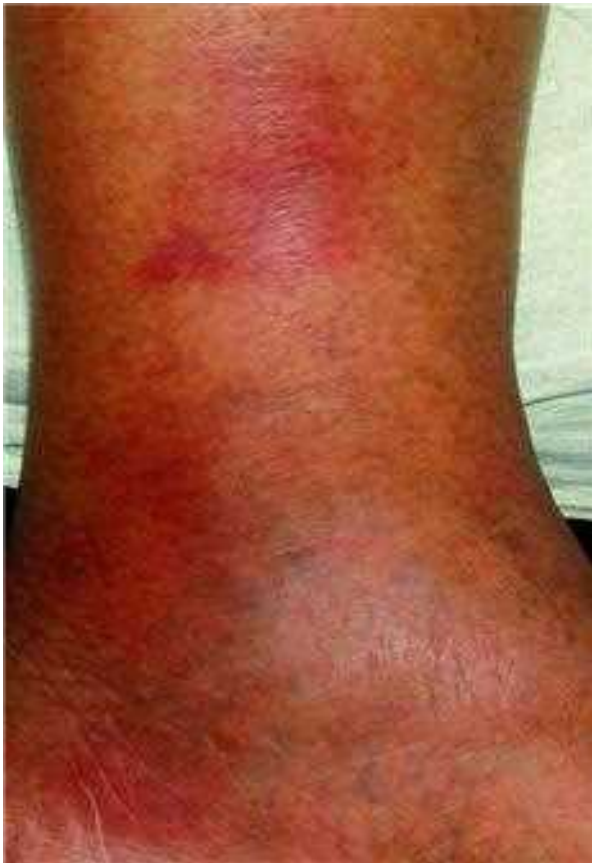

Fig. 10.14. Polyarteritis nodosa: tender subcutaneous nodules, along the line of arteries on a background of livedoid change.

Systemic features

- ❖ **Kidneys:** Manifests as nephritis with or without hypertension; but NOT glomerulonephritis.
- ❖ **Heart:** Manifests as ischemic heart disease.

Course

- ❖ **Cutaneous PAN:** Self-limiting.
- ❖ **PAN with systematic involvement:** Disease progressive.

Investigations

Investigations are required to:

- ❖ Confirm diagnosis.
- ❖ Identify trigger.
- ❖ Rule out systemic involvement.

Confirming diagnosis

- ❖ Histopathological confirmation may be difficult, as arterial involvement is segmental. Sural nerve/muscle biopsy helpful.
- ❖ Nonspecific parameters of disease activity include:
 - Elevated ESR.
 - Leucocytosis.
 - Low levels of circulating complement.
- ❖ P-ANCA.

Identifying cause

Rule out underlying:

- ❖ Infections.
- ❖ Neoplasia.
- ❖ Autoimmune diseases.

Systemic involvement

Does not affect lungs, but rule out involvement (generally by angiography) of:

- ❖ Kidneys (not glomerulonephritis, but infarcts and hypertension).
- ❖ Heart.
- ❖ Liver.
- ❖ Gastrointestinal tract.

Diagnosis

PAN should be differentiated from:

- ❖ Panniculitis.
- ❖ Wegener's granulomatosis.
- ❖ Vasculitis of systemic lupus erythematosus.

Treatment

- ❖ **Cutaneous PAN:** Low-dose systemic steroids are sufficient.

- ❖ **PAN with systemic involvement:** Combination of steroids and immunosuppressives like cyclophosphamide.

Granulomatous Vasculitis

Two types of granulomatous vasculitis recognized:

- ❖ Large vessel (*e.g.*, Wegener's granulomatosis).
- ❖ Small vessel.

Wegener's Granulomatosis

- ❖ **Triad of:** Systemic small vessel vasculitis, necrotizing granulomatous inflammation of upper and lower respiratory tracts and glomerulonephritis.
- ❖ **Etiology:** Unknown. Probably amplified immune response to an antigenic stimulus, such as an infection.
- ❖ **Constitutional symptoms:** Fever, malaise, and weight loss.
- ❖ **Skin lesions:**
 - Present in 50% of patients.
 - Symmetrical ulcers and papules on extremities.
- ❖ **Systemic involvement:** Eyes, upper and lower respiratory tract, and kidneys.
- ❖ **Investigations:**
 - *Serology:* cANCA positive.
 - *Biopsy:* systemic small vessel vasculitis (initially polymorphs, later mononuclear cells), necrotizing granulomatous inflammation of upper and lower respiratory tracts and glomerulonephritis.
- ❖ **Treatment:** Oral steroids and immunosuppressives.

Pigmented Purpuric Dermatitis (PPD)

Etiology

Unknown.

Epidemiology

- ❖ **Prevalence:** Not uncommon.
- ❖ **Gender:** Usually males.
- ❖ **Age:** Adolescents and adults.

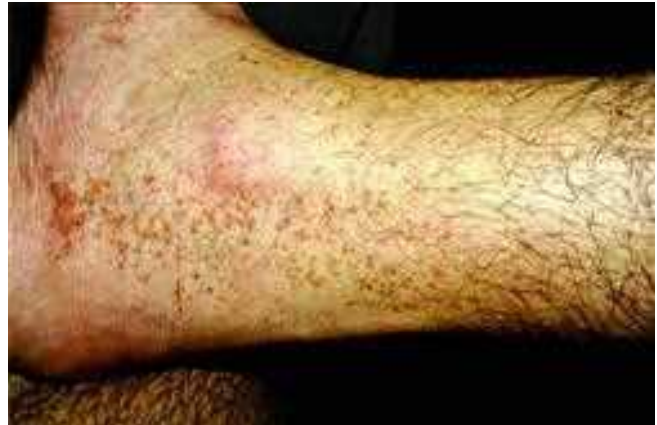

Fig. 10.15. Pigmented purpuric dermatosis: brown cayenne pepper spots on the garter area.

Clinical Features

Morphology

- ❖ Irregular macules (Fig. 10.15), which are orange brown¹⁶ (**cayenne pepper spots**)¹⁷.
- ❖ Only occasionally purpuric lesions discernible.

Site

- ❖ Lower part of legs (gaiter area).
- ❖ Proximal parts may be affected occasionally.

Course

Self-limiting.

Treatment

- ❖ May well be left alone.
- ❖ Hydroquinone topically in an anxious patient.

Other Related Disorders

Panniculitis

Panniculitis is the inflammation of panniculus (subcutaneous fat), which presents as deep-seated painful nodules. Based on the site of inflammation, panniculitis is classified as:

- ❖ Lobular panniculitis *e.g.*, nodular vasculitis.
- ❖ Septal panniculitis *e.g.*, erythema nodosum.

Nodular Vasculitis

Synonyms: Erythema induratum. Of Bazin (for *M. tuberculosis* induced nodular vasculitis) and of

16. **Brown color:** brown color in PPD is due to deposition of hemosiderin in dermis and also excessive melanin in epidermis.

17. **Cayenne pepper:** hot tasting, red powder made from the pods of a capsicum plant.

Whitfield (for nontuberculosis induced nodular vasculitis).

Etiology

Triggers

- ❖ **Erythema induratum of Bazin:** *M. tuberculosis*.
- ❖ **Erythema induratum of Whitfield:** Other triggers.

Pathogenesis

Immune complexes, deposited in the walls of medium-sized venules¹⁸, induce granulomatous inflammation.

Clinical features

Predisposing factors

- ❖ Middle aged women with stubby legs.
- ❖ Exposure to cold.

Morphology

- ❖ Initially an erythematous, tender (sometimes asymptomatic), deep seated (subcutaneous) nodule(s) or plaque(s) (Fig. 10.16).
- ❖ Develop a bluish-red hue and become fluctuant.
- ❖ Eventually ulcerate. Ulcers punched out with a ragged margin.
- ❖ Heal slowly with atrophic scars.

Sites of predilection

- ❖ Unilateral.
- ❖ Calves. Rarely shins.

Course

Chronic and recurrent. Heals with scarring.

Associations

- ❖ Rule out tuberculosis.
- ❖ Livedo reticularis and varicose veins.

Systemic involvement

Usually none.

Investigations

Confirming the diagnosis

- ❖ **Biopsy:** Lobular panniculitis with an eventual granulomatous vasculitis.

Identifying the cause

- ❖ **Rule out tuberculosis:** Tuberculin test and chest X-ray.
- ❖ Rule out other infections.

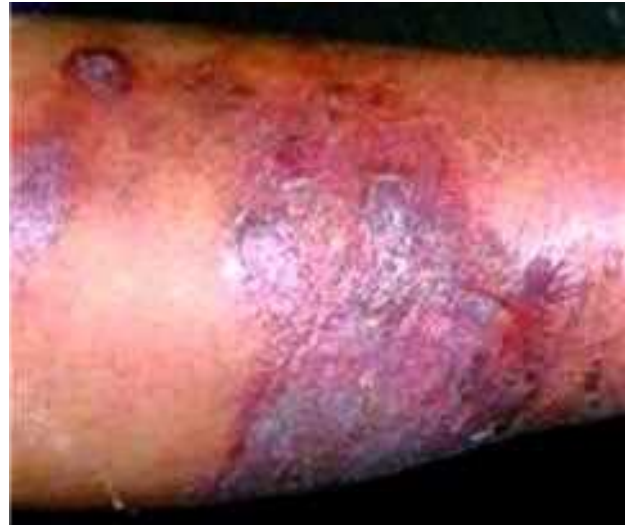

Fig. 10.16. Nodular vasculitis: erythematous nodules and plaques on calf. The nodules sometimes ulcerate.

Diagnosis

Points of diagnosis

Diagnosis of nodular vasculitis is based on:

- ❖ Presence of chronic erythematous, deep seated nodules which eventually ulcerate.
- ❖ Involvement of calves. May be unilateral.
- ❖ Biopsy confirmatory.

Differential diagnosis

Nodular vasculitis should be differentiated from:

- a. *Erythema nodosum* (P. 190)

Treatment

Eliminate triggers

In case of tuberculosis, a course of antitubercular treatment.

Mild disease

- ❖ Rest.
- ❖ NSAIDs.
- ❖ Potassium iodide, dapsone, and tetracycline.

Severe disease

- ❖ Short course of steroids.

Erythema Nodosum (EN)

Etiology

Triggers

Several triggers identified (Table 10.10).

18. Sometimes arterioles.

Table 10.10. Causes of erythema nodosum

Infections	
Bacteria	Streptococcus, tuberculosis, yersinia
Fungi	Coccidioidomycosis
Viruses	Infectious mononucleosis, hepatitis B
Others	Amoebiasis, giardiasis, Chlamydia
Others	
Drugs	Sulfonamides, bromides, oral contraceptives
Miscellaneous	Sarcoidosis, Behcet's disease, ulcerative colitis, connective tissue diseases, malignancies, pregnancy.

Pathogenesis

Immune complexes, deposited in the walls of blood vessels, induce both an acute (polymorphonuclear) and chronic (granulomatous) inflammation.

Clinical features**Morphology**

- ❖ Indurated, very tender, erythematous, deep seated nodules which evolve by changing color from red to violaceous to yellow before subsiding¹⁹. They appear like erythema or a bruise but feel like a nodule (Fig. 10.17). Lesions are usually oval, sometimes arciform.
- ❖ Never ulcerate. Heal without scarring.

Sites of predilection

- ❖ Bilaterally symmetrical.
- ❖ Shins, sometimes knees and arms.

Constitutional symptoms

- ❖ Fever and malaise.
- ❖ Arthralgia of ankle.

Course

Spontaneous resolution in 6 weeks. Crops may continue to appear.

Investigations

Investigations are required to:

- ❖ Confirm diagnosis.

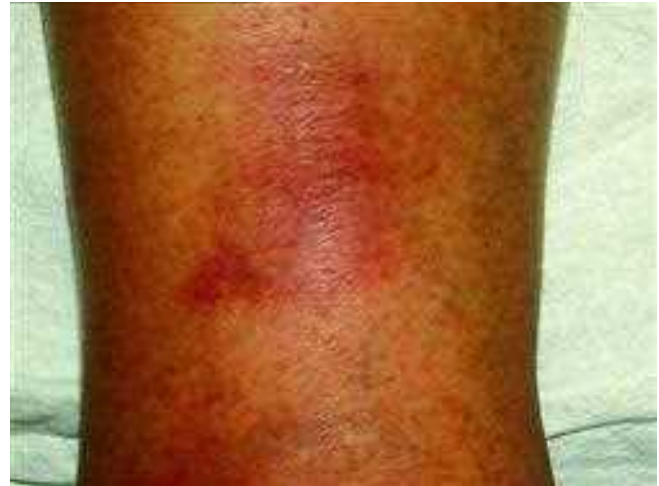

Fig. 10.17. Erythema nodosum: erythematous, deep seated nodules which subside with bruise-like discoloration.

- ❖ Identify cause.
- ❖ Look for systemic involvement.

Confirming diagnosis

Biopsy shows septal panniculitis but no vasculitis²⁰.

Identifying cause

- ❖ Rule out underlying diseases by a careful history, physical examination, and investigations.
- ❖ Radiological examination of chest to rule out tuberculosis and sarcoidosis.
- ❖ Mantoux test to evaluate for tuberculosis²¹.
- ❖ ASO titer to rule out streptococcal infection.

Diagnosis**Points for diagnosis**

Diagnosis of EN is based on:

- ❖ Presence of tender (often very) erythematous, deep seated nodules which do not ulcerate.
- ❖ Bilaterally on shins.
- ❖ Biopsy confirmatory.

Differential diagnosis

Erythema nodosum (EN) should be differentiated from:

19. Like a bruise.

20. **No vasculitis:** EN being considered here to differentiate from other nodules on legs.

21. **Tuberculosis:** EN is a companion of primary tuberculosis.

a. Nodular vasculitis (NV)

NV	EN
<i>Symptoms:</i> moderately painful or asymptomatic.	Very painful and tender
<i>Morphology:</i> erythematous, deep seated nodules, which ulcerate and heal with scarring.	Erythematous, deep seated nodules, which undergo color change but do not ulcerate. No scarring.
<i>Distribution:</i> calves; may be unilateral	Shins; usually symmetrical
<i>Course:</i> recurrent	Appears in crops.
<i>Histopathology:</i> lobular panniculitis with vasculitis	Septal panniculitis with no vasculitis

Treatment

- ❖ Identify and eliminate the cause. Treat streptococcal infection or tuberculosis with appropriate drugs.
- ❖ Anti-inflammatory drugs.
- ❖ Potassium iodide may help.
- ❖ Thalidomide.

Pyoderma Gangrenosum

- ❖ Pyoderma gangrenosum (PG) is a rare, non-infectious neutrophilic dermatosis commonly associated with underlying systemic disease.
- ❖ Immune-mediated process important. More than 50% of patients have associated systemic disease including inflammatory bowel disease (IBD), arthritis, hematological malignancies, and monoclonal gammopathies.
- ❖ A papule, pustule or bulla which evolves into a rapidly progressive (usually >1 cm/day) painful, necrotic ulcer with an irregular, undermined, violaceous border (Fig. 10.18), and pain out of proportion to size of ulcer. Heals with cribriform scarring.
- ❖ Rapid response to oral steroids.

Sweet's Syndrome

- ❖ Is a neutrophilic dermatosis.
- ❖ May be classical (triggered by upper respiratory and other infections, IBD, and pregnancy), malignancy associated, or drug associated.
- ❖ Skin lesions consist of multiple, erythematous to violaceous tender papules or nodules that

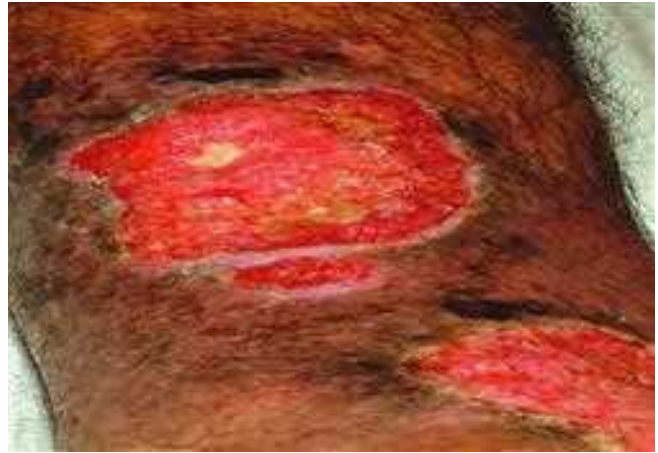

Fig. 10.18. Pyoderma gangrenosum: necrotic ulcer with an undermined, violaceous border, and pain out of proportion to size of ulcer. Heals with cribriform scarring.

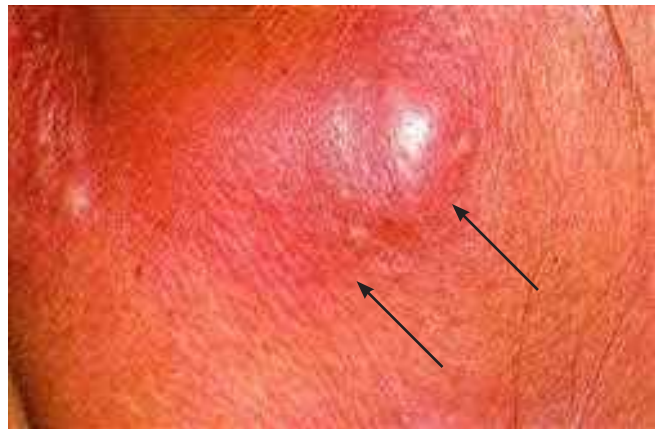

Fig. 10.19. Sweet's syndrome: erythematous to violaceous tender papules or nodules that coalesce to form irregular plaques. Note pseudovesiculation due to prominent dermal edema and tiny pustules.

coalesce to form irregular plaques (Fig. 10.19). Later lesions may appear **pseudovesicular** because of prominent dermal edema and may be studded with tiny pustules.

- ❖ Arms, face, and neck.
- ❖ Herpetiform aphthae in oral mucosa and conjunctivitis in eyes.
- ❖ Fever and neutrophilic leukocytosis invariable.
- ❖ Systemic steroids, standard therapy. Other agents used include colchicine and potassium iodide.

Cutaneous Response to Physical Stimuli

11

Chapter Outline

Response to Light

- Basics of photodermatology•
- Normal cutaneous response to UVR•
- Photodermatoses•
- Photoprotection•

Response to Cold

- Chilblains◦
- Acrocyanosis◦
- Sclerema neonatorum◦

Response to Heat

- Acute thermal injury◦
- Chronic thermal injury◦

Response to Radiation

- Effects of radiation at cellular level◦
- Acute effects of radiation on skin◦
- Chronic effects of radiation on skin◦

Response to Light

Basics of Photodermatology

Solar Spectrum

- ❖ Solar spectrum consists of **electromagnetic (EM) radiations**¹ extending from very short (wavelength) cosmic rays, X-rays, and γ -rays through ultraviolet, visible, and infrared radiation to the long (wavelength) radio and television waves.
- ❖ Terrestrial part of solar spectrum, however, is confined to wavelengths between 290 and 4000 nm.²
- ❖ Light having wavelength between 200 and 400 nm is called **ultraviolet radiation (UVR)** and is classified as:
 - **UVC** (200–290 nm): does not reach Earth's surface as it is filtered by the ozone layer of the atmosphere.
 - **UVB** (290–320 nm): constitutes 0.5% of solar radiation reaching Earth's surface; reaches only up to the epidermis; causes sunburn; does not pass ordinary glass.
 - **UVA** (320–400 nm): constitutes 95% of solar radiation reaching Earth's surface; penetrates both epidermis and dermis; causes photoaging and tanning of the skin; passes through ordinary window glass. Is further classified into:
 - UVA 2: 320–340 nm.
 - UVA 1: 340–400 nm.
- ❖ **Visible light:** Extends between 400 and 700 nm; is part of EM spectrum perceived by eyes.
- ❖ **Infrared radiation:** Extends beyond 700 nm; is responsible for heating effect.

1. **Electromagnetic radiation:** any kind of radiation which consists of alternating electric and magnetic fields and which can be propagated even in vacuum.
2. **nm (nanometer):** 1 nm = 10^{-9} m = 10 Å°.

•Should know
◦Good to know

Human Exposure to UVR

Human exposure to UVR occurs from Sun and from artificial sources of light.

Sun

Sun is the main source of exposure to UVR and contains UVR, visible light, and infrared rays.

Artificial light sources

Humans are exposed to artificial sources of light intentionally (e.g., recreational and for tanning), unintentionally (e.g., occupational), and for therapeutic reasons (e.g., phototherapy).

Normal Cutaneous Response to UVR

Even normal skin reacts in several ways to the exposure to UVR (Fig. 11.1, Table 11.1).

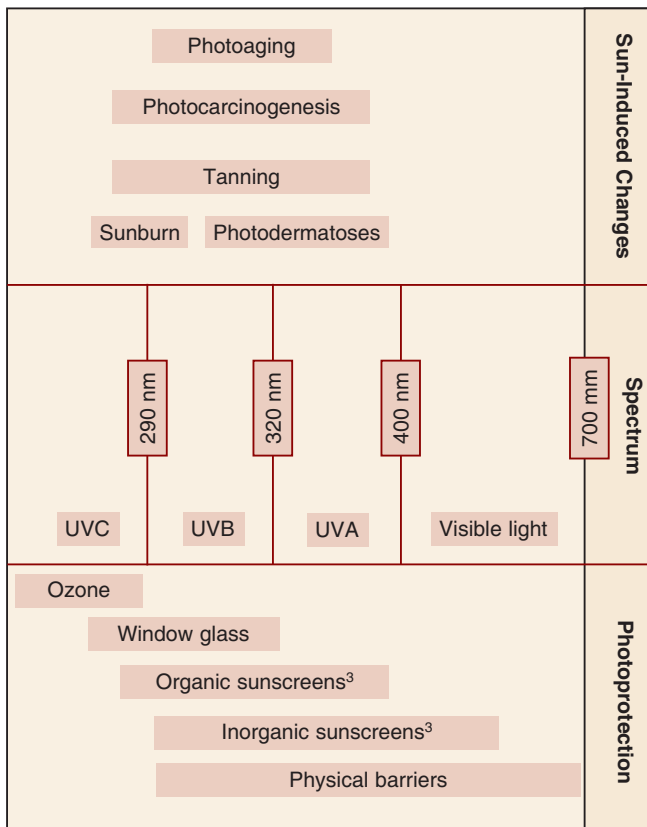


Fig. 11.1. Changes induced in the skin by light and methods of protection.

Table 11.1. Changes in skin due to exposure to light

Response	Action spectrum
Sunburn	UVB
Tanning	
❖ Immediate	UVA
❖ Delayed	UVA, UVB
Hyperplasia	UVB
Photoaging	
❖ Epidermis	UVB
❖ Dermis	UVA, UVB
Immunological changes	UVA, UVB, visible light
Vitamin D synthesis	UVB
Photocarcinogenesis	UVB, UVA

Sunburn

Cause

- ❖ **Action spectrum⁴:** UVB which induces release of cytokines in skin, resulting in pain, redness, erythema edema and even blistering.
- ❖ **Skin type⁵:** Most frequent and intense in individuals who are skin type I and II.

Clinical features

- ❖ Seen in light skinned.
- ❖ Areas overexposed to UVR become painful and deeply erythematous after several hours.
- ❖ Redness peaks at 24 h and subsides over next 48–72 h, followed by sheet-like peeling of skin and then hyperpigmentation (Figs. 11.2 and 11.3).

Treatment

Prevention

- ❖ Avoiding overexposure to sun (e.g., sunbathing), especially by light-skinned individuals.

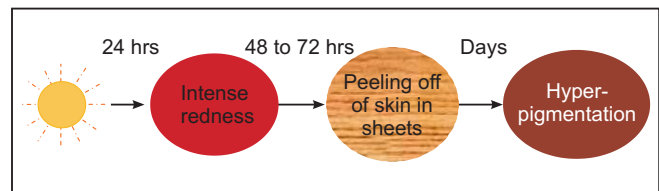


Fig: 11.2. Sunburn: evolution of lesions.

3. **Organic sunscreens:** previously called chemical sunscreens; **inorganic sunscreens:** previously called physical sunscreens.

4. **Action spectrum:** wavelength which produces the response most effectively.

5. **Skin type:** Skin type or skin color has been classified into six types (I–VI) based on the ability of the skin to burn or to tan. Lighter skin types (I/II) burn but do not tan, while darker skin types (type V/VI) tan but do not burn.

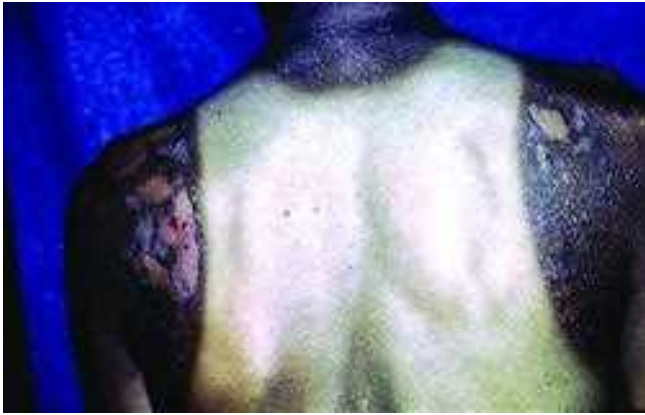

Fig. 11.3. Sunburn: peeling of skin in sheets. Note distinct sparing of covered parts.

- ❖ Using protective clothing and sun shades.
- ❖ Using UVB protective sunscreens.

Symptomatic treatment

- ❖ Calamine lotion provides comfort.
- ❖ Topical steroids help, if used early.
- ❖ Nonsteroidal anti-inflammatory drugs like aspirin not only relieve pain but also the inflammation.

Tanning

Etiology

Following exposure to UVR, pigmentation occurs in two phases:

- ❖ **Immediate pigmentation:** Occurs within 5 min of exposure to UVA and is due to:
 - Photo-oxidation of already formed melanin.
 - Rearrangement of melanosomes.
- ❖ **Delayed pigmentation:** Begins about 24 h after exposure to both UVB as well as UVA. It is due to:
 - Proliferation of melanocytes.
 - Increased activity of enzymes in melanocytes resulting in increased production of melanosomes.
 - Increased transfer of newly formed melanosomes to adjoining keratinocytes.

Clinical features

- ❖ Pigmentation following exposure to light occurs in two phases:
 - *Immediate pigmentation:* begins about 5 min after exposure and lasts for about 15 min.

Table 11.2. Skin type and response to UVR

Skin type	Burns	Tans
I, II	++	-/+
III, IV	+/-	+
V, VI	-	++

- *Delayed pigmentation:* begins about 24 h after exposure and lasts for several days.
- ❖ Degree of pigmentation depends on the constitutional skin color. Lighter skins burn on UV exposure while darker skins tan (Table 11.2).

Hyperplasia

- ❖ **Action spectrum:** UVB (and UVC).
- ❖ **Advantages:** Protects skin against further harmful effects of UVR.

Photoaging

Etiology

- ❖ Photoaging involves changes in epidermis and dermis.
- ❖ **Action spectrum:** Epidermis is affected primarily by UVB and dermis by both UVA and UVB.

Manifestations

- ❖ Photoaged skin appears dry, deeply wrinkled, leathery and irregularly pigmented. Comedones are present, especially around the eyes (Fig. 11.4).

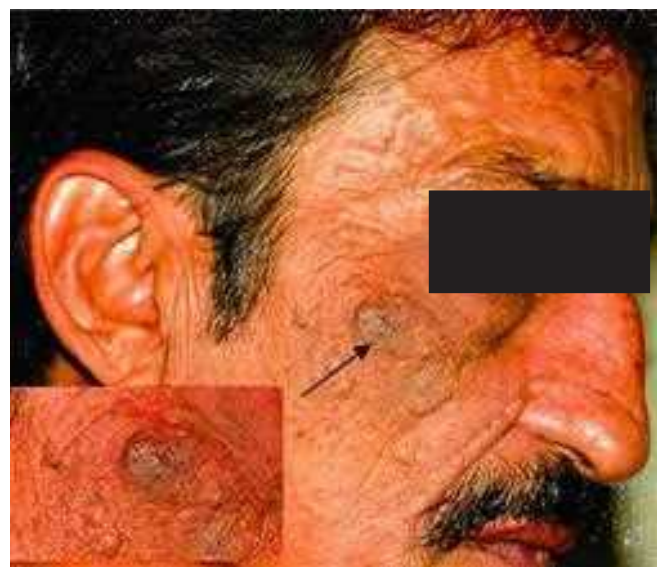

Fig. 11.4. Photoaged skin: wrinkled, leathery, and irregularly pigmented. Inset: note comedones.

- ❖ Histologically, photoaged skin shows marked **elastotic degeneration**.

Immunological Changes

Pathogenesis

- ❖ **Action spectrum:** UVB, UVA, and visible light.
- ❖ **Effect:** Immunological changes are due to:
 - Reduced antigen presentation capacity of the Langerhans cells.
 - Stimulation of abnormal antigen presentation by macrophages.

Manifestations

Exposure to UVR:

- ❖ Inhibits contact allergic dermatitis and delayed hypersensitivity reactions.
- ❖ Inhibits tumor rejection, resulting in an increased incidence of cutaneous and extracutaneous malignancies.

Photocarcinogenesis

- ❖ **Action spectrum:** UVB mainly but also UVA.
- ❖ Skin types I and II are most susceptible.
- ❖ Photocarcinogenesis occurs because:
 - DNA damage occurs due to chronic exposure to UVB and to lesser extent UVA and this damage is incompletely repaired.
 - UVR also causes immunosuppression, resulting in decreased tumor surveillance and rejection.

Photodermatoses

Common photodermatoses (Table 11.3) seen in clinical practice include idiopathic photodermatoses, photodermatoses induced by drugs and chemicals, genetic, and metabolic dermatoses and some skin diseases which are photoaggravated.

Table 11.3. Common photodermatoses

Idiopathic photodermatoses	Polymorphic light eruption
Drug/chemical-induced photodermatoses	Photoallergic eruption Phototoxic eruption Chronic actinic dermatitis
Genetic and metabolic dermatoses	Xeroderma pigmentosum Porphyrias Pellagra
Photoaggravated dermatoses	Systemic lupus erythematosus Discoid lupus erythematosus

Polymorphic Light Eruption (PMLE)

Etiology

- ❖ **Action spectrum:** UVA (more frequently incriminated) or UVB (less frequently).
- ❖ Probably a delayed hypersensitivity to a **neoantigen** produced by the action of UVR on an endogenous antigen.

Epidemiology

- ❖ **Prevalence:** Fairly common dermatosis.
- ❖ **Gender:** Female preponderance.
- ❖ **Age:** Usually in third to fourth decade.

Clinical features

Morphology

- ❖ Described as polymorphic eruption, but in a given patient lesions are usually monomorphic.
- ❖ Small, itchy, papules, papulovesicles or eczematous plaques on an erythematous background (Fig. 11.5).
- ❖ Develop 2 h to 2 days after exposure to UVR.

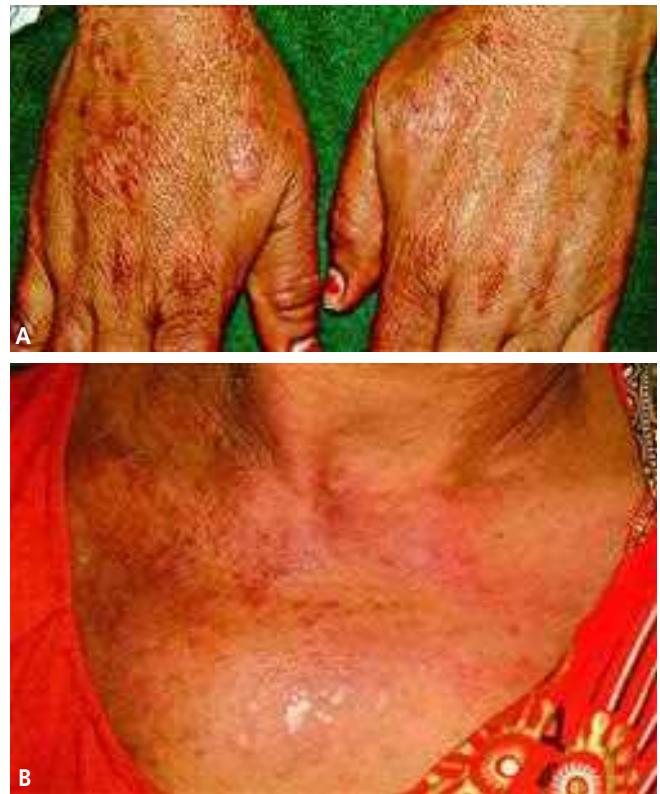

Fig. 11.5. Polymorphic light eruption: A: eczematous plaques on the dorsal aspect of hands. B: erythematous papules and plaques on V on the chest.

Sites of predilection

Most frequently seen on the sun-exposed areas—dorsae of hands, nape of neck, 'V' of chest, and dorsolateral aspect of forearms. Face and **covered parts**⁶ are occasionally involved.

Course

Recurrent problem, begins in spring and persists through summer.

Variants

❖ **Photosensitive lichenoid eruption:** Small, barely perceptible, shiny papules (Fig. 11.6); which become confluent. Seen on the dorsolateral aspects of the forearms and 'V' of chest-neck, mainly in fair complexioned women. Face is invariably spared.

❖ **Actinic prurigo.**

Treatment

❖ **Photoprotection:**

- Avoid exposure to sunlight.
- Use of appropriate clothing.
- **Sunscreens:** Important to use UVA sunscreens (*i.e.*, inorganic sunscreens. Or those containing benzophenones, avobenzone, tinosorb, mexoryl).

❖ **Symptomatic treatment:**

- Topical/systemic steroids, depending on severity.
- Antihistamines.

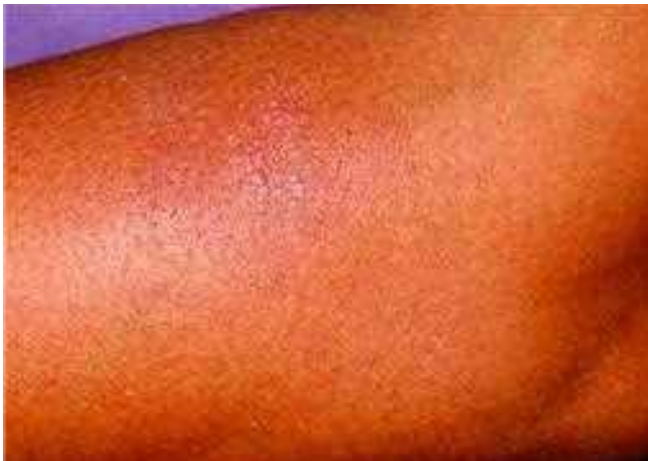

Fig. 11.6. Photosensitive lichenoid eruption: small, shiny papules on dorsolateral aspect of forearms.

❖ **Hardening of skin:** With gradually increasing doses of UVB or PUVA⁷.

❖ **Unremitting PMLE:** Azathioprine, thalidomide, and cyclosporine are useful.

Chemical and Drug-induced Photodermatoses**Etiology**

Common drugs/chemicals causing photodermatoses are listed in Table 11.4.

Pathogenesis

Chemical and drug-induced photodermatoses could be (Table 11.5):

- ❖ *Phototoxic.*
- ❖ *Photoallergic.*

Table 11.4. Drugs/chemicals producing photodermatoses

Phototoxic reactions	Photoallergic reactions
Systemic agents	
Doxycycline Frusemide Griseofulvin Nalidixic acid Naproxen Piroxicam Psoralens Sparfloxacin Tetracyclines	Tetracyclines
Topical agents	
Psoralens Tar	Sunscreens Fragrances Plants of <i>Compositae</i> family, <i>e.g.</i> , <i>Parthenium hysterophorus</i>

Table 11.5. Pathogenic differences between phototoxic and photoallergic reactions

	Phototoxic reaction	Photoallergic reaction
Type of reaction	Non-immunological	Immunological response to a photoproduct created from chemical by light
Occurrence	In all individuals exposed to chemical and light in adequate dose	Occurs in sensitized individuals

6. **Covered parts:** in PMLE, the parts of the body most frequently involved are those which are not photoexposed in winters but are photoexposed in summers, *e.g.*, forearms. This explains the fact that face is often spared.

7. **PUVA:** Psoralens + UVA.

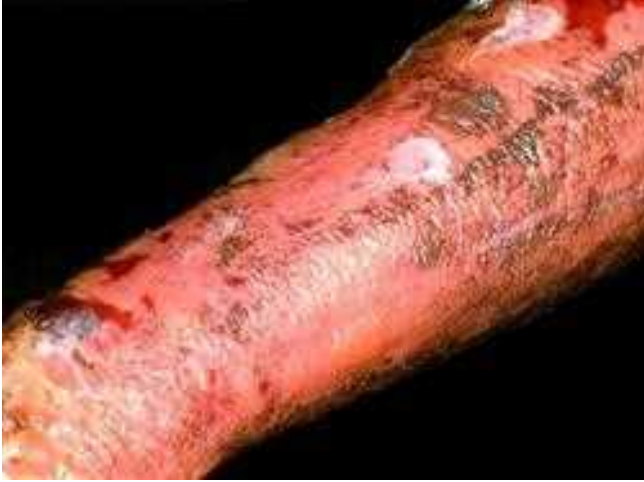

Fig. 11.7. Phototoxic reaction: erythema, edema after psoralen and UVA therapy in a patient with vitiligo.

Clinical features

Phototoxic reactions

- ❖ **Dose of drug/chemical needed:** Large.
- ❖ **Latent period:** Reaction immediate (within minutes to hours) after exposure to light and can occur after first exposure.
- ❖ **Morphology:** Initially, there is erythema, edema, and vesiculation (Fig. 11.7), followed by desquamation and peeling, and finally the lesions heal with hyperpigmentation (similar to sunburn).
- ❖ **Location:**

- **Involves:** lesions sharply limited to photo-exposed parts, such as hands, dorsolateral aspect forearms, 'V' of the chest, nose, and chin.
- **Spare:** lesions absent in photoprotected sites like upper lip, area under nose, the eyelids, the submental region (Fig. 11.8). Also depth of skin folds in photo-exposed areas spared.

Photoallergic reactions

- ❖ **Dose of drug/chemical needed:** Small.
- ❖ **Latent period:** Reaction occurs on second or third day. Also does not occur on first exposure but after second or later exposures.
- ❖ **Symptoms:** Itching often severe. Aggravated after sun exposure.
- ❖ **Morphology:** Photoallergic reactions are similar to phototoxic reactions but are more eczematous (Fig. 11.9).
- ❖ **Location:**
 - Predominantly on photo-exposed areas.
 - Covered areas sometimes involved in severe disease, but with lower intensity.

Investigations

Phototoxic reactions

No investigations required.

Photoallergic reactions

- ❖ Photopatch tests (Fig. 11.10) to confirm diagnosis of photoallergic dermatosis.

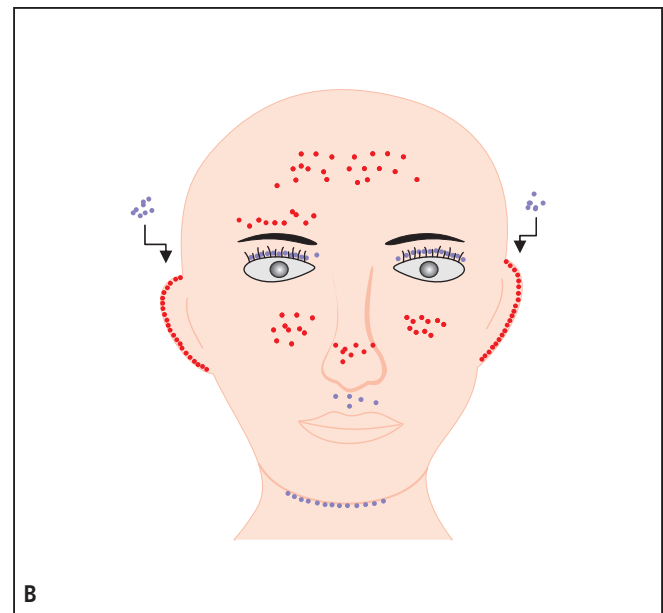
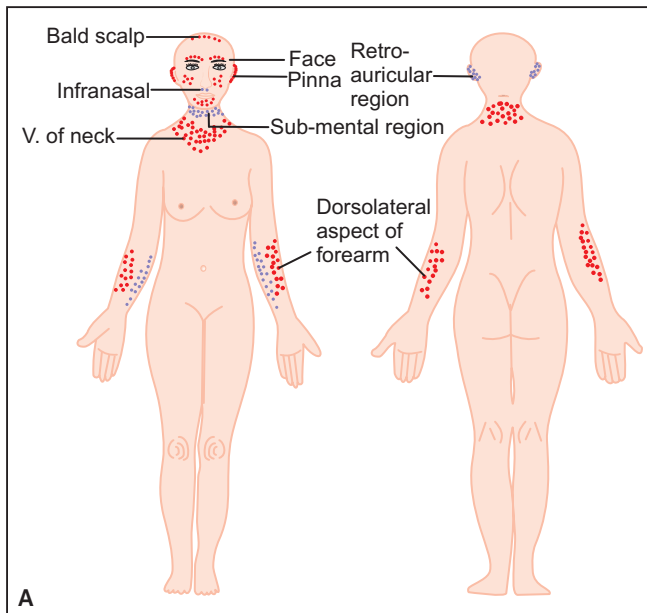


Fig. 11.8. Photoallergic reaction: A: sites of predilection on body. B: sites of predilection on face. Red: involved skin. Blue: uninvolved skin.

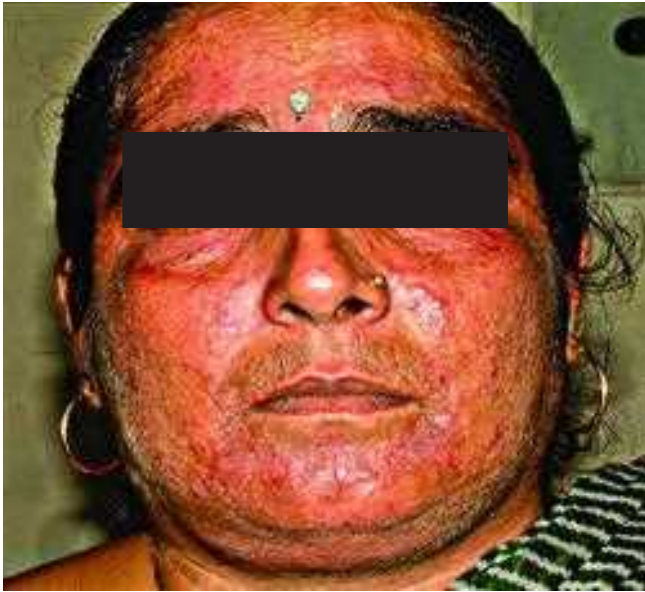

Fig. 11.9. Photoallergic reactions: exudative plaques at characteristic sites.

- ❖ Antigens applied in duplicate panels for 24 h. One panel is irradiated with UVA at 24 h and reoccluded. Both panels are read at 48 h and 96 h.
- ❖ A photoallergic contact dermatitis, if present, manifests at 48 h. The negative control patch which has not been irradiated rules out allergic contact dermatitis (Table 11.6).

Diagnosis

The diagnostic feature of any photodermatosis is its distribution (Fig. 11.9).

- ❖ Though clinically, phototoxic and photoallergic

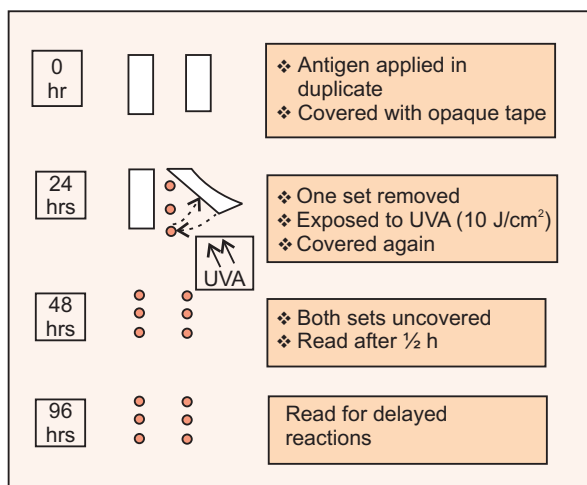


Fig. 11.10. Photopatch test.

Table 11.6. Interpretation of photopatch test

Reaction at UVA exposed site	Reaction at unexposed site	Interpretation
–	–	No allergy
++	0	Photoallergy
++	++	Contact allergy
++	+	Contact allergy with photoaggravation

Table 11.7. Differences in manifestations of phototoxic and photoallergic reactions

	Phototoxic reactions	Photoallergic reactions
Amount of drug/chemical required	Large	Small
Latent period	Immediate	Delayed
Occurrence after first exposure	+	–
Symptoms	Pain/burning	Itching
Morphology	Erythema and edema ± bullae	Ecematous
Location	Strictly to photo-exposed areas	Can spill onto photocovered areas
Photopatch test	Negative	Positive

reactions are similar. There are some differences between them (Table 11.7).

Photoallergic reactions should be differentiated from:

a. Airborne contact dermatitis (ABCD).

ABCD	Photoallergic dermatitis
Lids and retroauricular areas involved	Spared
Front of neck involved; submental area involved	Back of neck involved. Submental area spared
Cubital fossa involved	Dorsolateral aspect of forearm involved
Depth of skin creases involved	Spared
Photosensitivity absent/minimal	Marked
Responds to avoidance of antigen	Responds to avoidance of antigen or sun exposure
Patch test positive	Photopatch test positive

Treatment

Phototoxic reactions

- ❖ **Photoprotection** (P. 199)

- ❖ **Withdrawal of drug:** Only necessary, if excessive exposure to UVR cannot be avoided.
- ❖ **Symptomatic treatment:**
 - Topical steroids.
 - Nonsteroidal anti-inflammatory drugs.

Photoallergic reactions

- ❖ **Photoprotection:** Very important. (P. 199)
- ❖ **Withdrawal of drug:** Also very important. Substitution with a chemically unrelated drug is essential (*cf.*, phototoxic reaction).
- ❖ **Symptomatic treatment:**
 - *Mild disease:* Topical steroids and antihistamines.
 - *Severe disease:* Systemic steroids, azathioprine, and methotrexate in severe dermatosis.

Chronic Actinic Dermatitis (CAD)

Several variants recognized, the most severe called **actinic reticuloid**.

Etiology

- ❖ **Action spectrum:** UVA/UVB and visible light.
- ❖ **Predisposing diseases:** Photocontact dermatitis, airborne contact dermatitis, and drug-induced dermatitis; probably increase cutaneous immune recognition of endogenous antigens in the presence of UVR, predisposing to development of severe persistent sensitivity to UVR and visible light.

Clinical features

- ❖ **Symptoms:** Extreme photosensitivity.
- ❖ **Morphology:** Itchy, confluent, initially eczematous plaques, which develop marked lichenification over period of time (Fig. 11.11) giving appearance of **leonine facies**.
- ❖ **Sites:** Photo-exposed sites—face, neck (back, sides and V area), and dorsae of hands involved. Interestingly, depth of the skin creases (which are exaggerated due to lichenification) relatively spared.

Treatment

- ❖ **Photoprotection:** Absolute protection from sunlight using conventional measures including broad-spectrum sunscreens.
- ❖ **Symptomatic treatment:** Topical and systemic steroids give symptomatic relief. Antihistamines to relieve itching.
- ❖ **Desensitization:** With narrow band UVB/PUVA helps many patients.

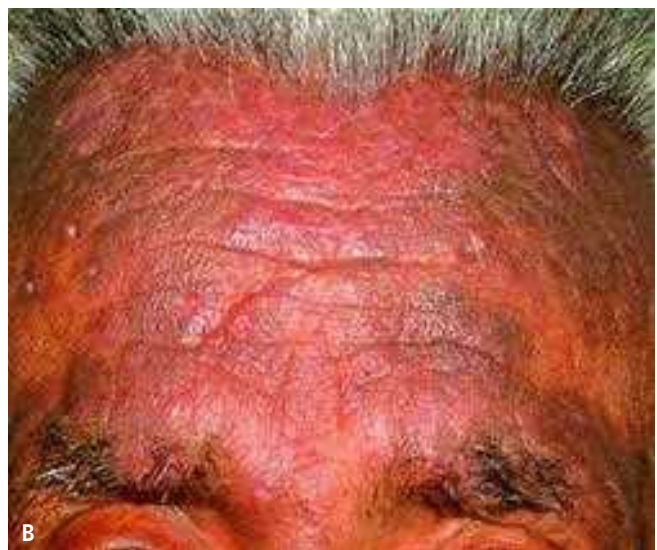
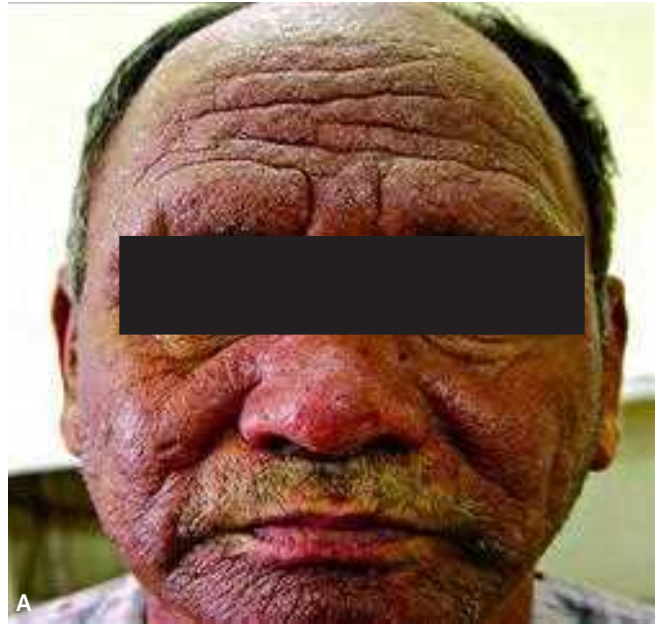
Fig. 11.11. Chronic actinic dermatitis: A: confluent lichenified plaques on photo-exposed parts. B: sparing of depth of skin creases and depth of upper lids.

- ❖ **In severe cases:** Thalidomide and azathioprine used in recalcitrant cases.

Actinic Cheilitis

- ❖ Provoked by chronic, excessive exposure to sun.
- ❖ Dry scaling, a tendency to fissure and atrophic changes beneath and around the lesion (Fig. 11.12). Premalignant.
- ❖ Sun protection paramount. Ablated using 5 fluorouracil, cryosurgery or laser.

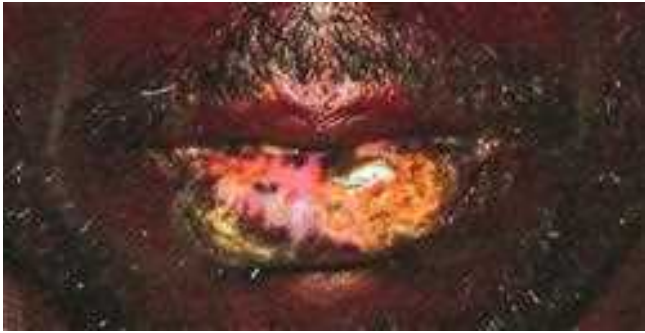

Fig. 11.12. Actinic cheilitis: inflammation, scaling, and edema of lower lip.

Photoprotection

Solar radiation can be both a boon or bane to the skin (Table 11.8). Photoprotection entails protection of skin from sun rays and other sources of light to prevent the adverse effects (Table 11.9).

Table 11.8. Benefits and adverse effects of sunlight

Benefits	Adverse effects
Tanning*	Sunburn
Vitamin D synthesis	Photoaging
Improvement in some dermatoses	Decreased immunosurveillance Carcinogenesis
	Photodermatoses
	Aggravation of some dermatoses

*Not always considered beneficial.

Table 11.9. Photoprotective factors

Natural factors	Atmospheric factors	Ozone Pollutants Clouds
	Biologic factors	Melanin Keratin
Physical factors	Clothing	Close weaves, dark colors, specially treated fabrics.
	Sunshades	Umbrella, hats
Artificial factors	Topical sunscreens	Inorganic* Organic**
	Systemic photoprotection	PUVA β carotene Antimalarials

* Earlier called physical sunscreens.

** Earlier called chemical sunscreens.

Natural Protection Against Sunlight

Ozone

- ❖ Ozone, present in the stratosphere, is formed by the action of UVC on the atmospheric oxygen.
- ❖ It filters out potentially dangerous radiation below 285 nm (UVC).
- ❖ Depletion of ozone layer (at poles) may reduce efficacy of this filter.

Pollutants and clouds

- ❖ Particulate matter, like dust and smog, reduces the intensity of light reaching the earth's surface due to the scattering effect.
- ❖ Shorter wavelengths, (UVA and UVB) are scattered more than the visible light. So scatter of UVB > of UVA > of visible light.

Melanin

- ❖ Melanin is essential for protecting skin against the damaging effects of solar radiation. Darker the skin, greater the protection.
- ❖ So, lighter skin types are more prone to acute (sunburn) and chronic (photoaging and malignancies) effects of sunlight.

Artificial Photoprotection

Topical sunscreens

Topical sunscreens reduce effects of UVR on skin by two methods:

- ❖ Absorption.
- ❖ Reflection.

Protection provided by sunscreens

There are several indices used to measure efficacy of sunscreens:

- ❖ **Sun protective factor (SPF)**
 - Is a measure of protection **against UVB** (and not UVA). A high SPF of sunscreen does not equate with broad spectrum of action.
 - Indicates the number of times exposure to UVB can be increased following application of sunscreen before it produces erythema⁸.
- ❖ **Prevention of persistent pigment darkening (PPD)**
 - Is a measure of protection **against UVA**.
 - Indicates the number of times exposure to UVA can be increased following application of sunscreen before it produces PPD.

8. **SPF 15:** this means that after application of an SPF-15 sunscreen, sun exposure can be increased 15 times, before it produces erythema.

Table 11.10. Sunscreens, their properties, and uses

Inorganic sunscreens	Organic sunscreens
Properties	
Reflect light (UVR and visible light), so are broad spectrum	Absorb selective bands of UVR, so are narrow spectrum
Cosmetically less acceptable because opaque	Cosmetically acceptable
Immunologically inert	Can cause contact sensitivity especially para aminobenzoic acid (PABA)
Examples	
Zinc oxide Titanium dioxide	UVB absorbent PABA* derivatives Cinnamates
	UVA absorbent Benzophenones Avobenzone
	Broad spectrum Tinosorb Mexoryl

* PABA: PABA itself is infrequently used now because of high potential for sensitization. Most sunscreens today are marketed as PABA-free.

❖ **Star rating system:**

- Is ratio of UVA to UVB protection offered by sunscreens.
- One-star products provide least ratio of UVA protection while five-star products provide highest ratio.

Classification of sunscreens

Depending on their mode of action, sunscreens can be classified into (Table 11.10):

- ❖ **Inorganic sunscreens.**
- ❖ **Organic sunscreens.**

Systemic sunscreens

Chloroquine and hydroxychloroquine

- ❖ Used in photodermatoses like discoid lupus erythematosus and systemic lupus erythematosus.
- ❖ Regular ophthalmological examination advisable during therapy.

β carotene

Is effective in some types of porphyrias.

Phototherapy and photochemotherapy

Patients with photodermatoses like polymorphic light eruption, chronic actinic dermatoses, and solar urticaria may be desensitized using:

- ❖ Psoralens + UVA (PUVA).
- ❖ Narrow band UVB.

Response to Cold

Skin reacts both normally and abnormally to exposure to cold and several skin diseases can be caused by exposure to cold (Table 11.11).

Table 11.11. Diseases caused by cold

Frost bite
Chilblains
Acrocyanosis
Livedo reticularis
Cold urticaria
Sclerema neonatorum
Subcutaneous fat necrosis of newborn

Chilblains

Etiology

- ❖ Develop when skin is exposed to cold (above freezing point) followed by warmth.
- ❖ Due to combination of:
 - Arteriolar constriction (during cooling).
 - Venular constriction (during warming)

Epidemiology

- ❖ **Prevalence:** Common problem in winters.
- ❖ **Gender:** More in females.
- ❖ **Age:** Adolescents and young adults.

Clinical Features

Morphology

- ❖ Appear as itchy (sometimes painful), erythematous to purplish, edematous plaques (Fig. 11.13).
- ❖ Blisters and ulcers develop in severe cases.

Sites of predilection

- ❖ Commonly, proximal phalanges of toes and fingers.
- ❖ Less commonly, nose, ears, and heels.

Treatment

Prevention

- ❖ Keep predisposed parts warm, using loose insulated clothing, and maintaining ambient temperature.
- ❖ Avoid immobility of limbs to maintain circulation.
- ❖ Prophylactic exposure to UVR at the beginning of winter may help.

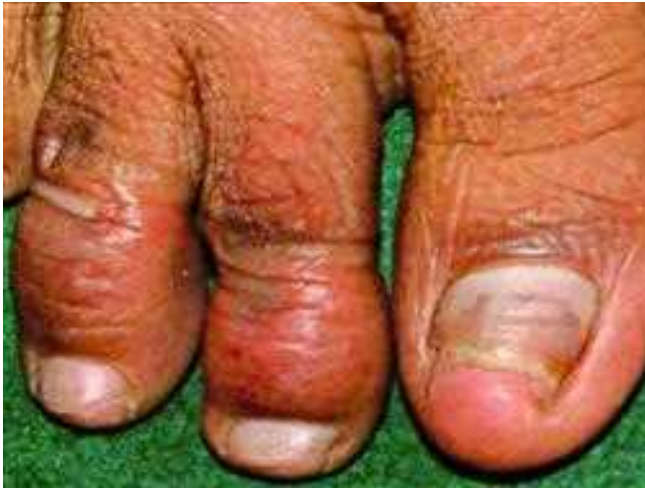

Fig. 11.13. Chilblains: erythematous edematous plaque. One digit is showing blistering.

Therapy

- ❖ Rest.
- ❖ Topical antibiotics, if blistering present.
- ❖ Oral nifedipine (40–60 mg daily) or nicotinamide (1.5 g daily) started at onset of winter.

Acrocyanosis

Etiology

Usually familial. Occurs due to:

- ❖ Abnormal arteriolar response to cold.
- ❖ Hyperviscosity of blood due to cold.

Clinical Features

- ❖ Affected limb becomes dusky and cold, when exposed to cold.
- ❖ Hands and feet; less frequently ears, nose, and cheeks.

Treatment

- ❖ Protection from cold.

Sclerema Neonatorum

Etiology

- ❖ Predisposing factors include prematurity, sepsis, dehydration, and sudden exposure to cold.
- ❖ How cold injury triggers sclerema neonatorum is debatable, but may be related to uniqueness of infant fat which contains higher ratio of saturated to unsaturated fatty acids.

Clinical Features

- ❖ Neonate is premature and ill (sepsis, dehydrated, and hypothermic).
- ❖ Begins in the first week of life.
- ❖ Diffuse, rapidly spreading, induration of skin and subcutaneous tissue.
- ❖ Spares palms, soles, and scrotum.
- ❖ High mortality.

Diagnosis

Sclerema neonatorum should be differentiated from:

a. Subcutaneous fat necrosis (SFN)

SFN	Sclerema neonatorum
Age: older child	Within first week of birth
Comorbidities: child less ill	Very ill child
Morphology: discrete, red-violaceous, mobile plaques, and nodules	Diffuse, ill-defined, rapidly spreading induration
Distribution: face, neck; buttocks spared	Throughout body; buttocks involved

Treatment

- ❖ Gentle rewarming (though cold injury probably only one of many predisposing factors).
- ❖ Rehydration and correction of electrolyte imbalance.
- ❖ Treat septicemia.

Response to Heat

Acute Thermal Injury

A few salient features on management of patient with burns include:

- ❖ Patients preferably managed in burns unit with special care facilities because burn patients prone to several organ failures. Acute respiratory failure is the commonest.
- ❖ Fluid resuscitation.
- ❖ Initial wound excision.
- ❖ **Biological wound closure:** This can be done by using:
 - Autografts.
 - Cryopreserved allografts.
 - Several newer agents.
- ❖ **Definitive wound closure:** Using several permanent skin substitutes.

❖ *Rehabilitation, reconstruction, and reintegration.*

- Functional.
- Social.

Chronic Thermal Injury

Erythema Ab Igne

Etiology

- ❖ Is due to damage to blood vessels from long-term exposure to intense local heat (*e.g.*, from an open fire, hot water bottle or heating pad).
- ❖ Lesions appear reticulate due to the arrangement of underlying vascular network.

Clinical features

Morphology

- ❖ Begins as erythema, followed by brown net-like pigmentation with telangiectasia, scaling, and atrophy (Fig. 11.14).
- ❖ Rarely, squamous cell carcinoma (SCC) may supervene.

Sites of predilection

- ❖ Lesions are seen on areas of intense heat application.
- ❖ Legs, thighs, lower abdomen (**kangri-induced erythema ab igne**), and back (hot water bag).

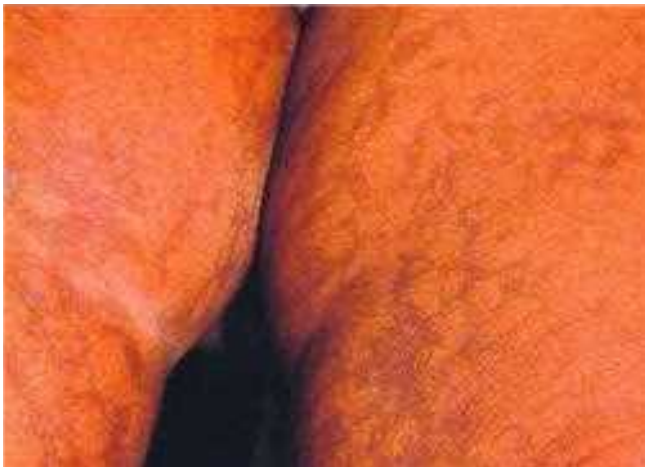

Fig. 11.14. Erythema ab igne: reticulate pigmentation with scaling and telangiectasia.

Treatment

Careful surveillance for development of SCC.

Response to Ionizing Radiation

Effects of Ionizing Radiation at Cellular Level

Radiation has the following effects at cellular level:

- ❖ **Loss of ability to divide** (*i.e.*, ability to reproduce): Is lost in most cell lines after only 3–4 Gy.⁹
- ❖ **Loss of function:** Occurs after exposures of about 100 Gy.
- ❖ **Chromosomal damage:** Radiation has the following effects on chromosomes:
 - Inhibits synthesis of DNA.
 - Causes chromosome and chromatid aberrations.
 - Oncogene activation and subsequent malignancies following chromosomal changes.
- ❖ **Cell cycle effects:** Radiation inhibits cell division:
 - Dividing cells are more radiosensitive than nondividing cells.
 - Cells in G₂ and M phases of cell division are most sensitive.
- ❖ **Cell death:** Radiation causes cell death in the following ways:
 - Reproductive cell death, *i.e.*, the cells do not divide and eventually die.
 - Apoptosis or programmed cell death by necrosis. This is an important mechanism of post radiation cell death in tumors and is a measure of radiosensitivity of tumors.

Acute Effects of Ionizing Radiation on Skin

Roentgen Erythema

- ❖ Normal reaction of skin to single exposure of radiation is either a biphasic erythema (following superficial radiation) or a triphasic erythema (following deep radiation).
- ❖ First phase erythema occurs at 24 h and lasts 2–3 days.
- ❖ Second phase begins at 7 days and lasts 2–3 weeks.
- ❖ Third phase¹⁰ begins at 7 weeks and lasts for a further 2–3 weeks.

9. **Gy:** is defined as the absorption of one joule of ionizing radiation by one kilogram of human tissue.

10. **Third phase erythema:** occurs only after deep radiation.

Acute Radiation Dermatitis

Etiology

Acute radiation dermatitis follows:

- ❖ Accidental overexposure to radiation.
- ❖ High-dose radiotherapy.
- ❖ Faulty radiation technique.

Clinical features

- ❖ Begins with erythema, edema, and pruritus (Fig. 11.15) followed by vesiculation.
- ❖ After initial subsidence, painful erythema, edema, vesiculation, and erosions recur in second week and depending on dose of radiation may lead to necrosis, ulceration, and even gangrene. The response may be triphasic with high-dose exposure to radiation.
- ❖ Mild to moderate reactions subside in 4–12 weeks but severe reactions take longer.
- ❖ Sequelae are hyperpigmentation, depigmentation, atrophy, and telangiectasia.

Treatment

- ❖ Avoid compounding damage with chemicals (like soaps, detergents, and antiseptics), sun exposure or trauma. Use only water to clean the area and pat the area dry.
- ❖ For dry lesions, use creams, while for wet lesions use compresses.
- ❖ Topical and systemic steroids are of debatable value.

Chronic Effects of Ionizing Radiation on Skin

Etiology

- ❖ **Therapeutic exposure:** When small but frequent doses of radiation are used to treat benign cutaneous lesions.
- ❖ **Occupational exposure.**

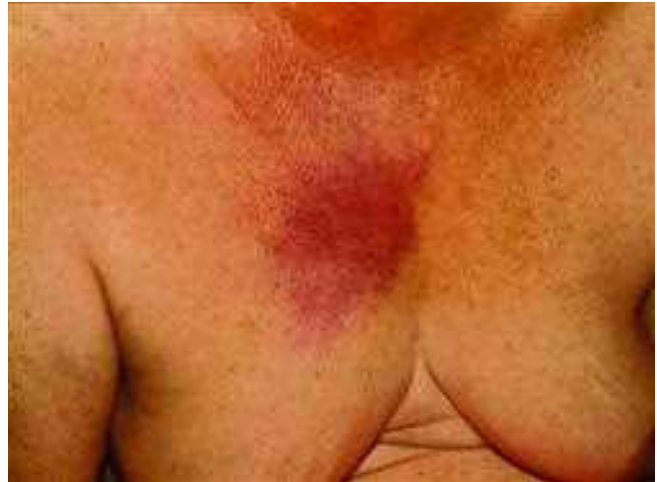

Fig. 11.15. Acute radiation dermatitis: localized area of erythema and edema.

Clinical Features

- ❖ Skin is itchy, thin, dry, and hairless.
- ❖ Telangiectasia, hyperpigmentation, hypopigmentation, and hyperkeratotic lesions.
- ❖ Spontaneous or post-traumatic painful ischemic ulcers may develop.
- ❖ Squamous cell carcinoma.

Treatment

Prevention

- ❖ Standardization of radiation treatment regimens using cones and filters.
- ❖ Avoidance of inadvertent exposure to radiation.

Symptomatic

- ❖ Emollients.
- ❖ Mild topical steroids.

"This page intentionally left blank"

Chapter Outline

Pathogenesis

- Immunological drug reactions•
- Nonimmunological drug reactions•
- Special reactions•

Morphology of Drug Reactions

- Exanthematous eruptions•
- Erythroderma•
- Epidermal necrolysis•
- Acute generalized exanthematous pustulosis◦
- Fixed drug eruption•
- Photosensitive eruption•
- Vasculitis•
- Urticaria and angioedema•
- Lichenoid eruption•
- Acneiform eruption•
- Pigmentation•
- Alopecia◦
- Increased hair growth◦
- Xerosis and ichthyosis◦
- Rare patterns of drug eruption◦
- Exacerbation of pre-existing dermatoses◦

Drugs and their Pattern of Reaction

- Antibiotics•
- Steroids•
- Nonsteroidal anti-inflammatory drugs•
- Anticonvulsants•
- Antituberculous drugs•

Course

- Exanthematous reactions•
- Epidermal necrolysis•
- Fixed drug eruption•

Management

- Investigations•
- Diagnosis•
- Treatment•

- Should know
- Good to know

Introduction

- ❖ An adverse drug reaction (ADR) is any noxious change which is suspected to be due to a drug. It occurs at doses normally used in man, requires treatment or decrease in dose of drug and requires caution in the future use of the same drug.
- ❖ Cutaneous reactions are among the most frequently observed ADRs.
- ❖ Almost any drug can cause skin and mucosal reactions.
- ❖ Reaction pattern may be distinct, *e.g.*, in toxic epidermal necrolysis (TEN). Or the drug may cause an eruption similar in its clinical appearance to a cutaneous disease like lichen planus or psoriasis.

Pathogenesis

ADRs can occur due to (Table 12.1):

- ❖ Immunological mechanisms.
- ❖ Nonimmunological mechanisms, including certain special reactions.

Immunological Drug Reactions

Mechanism

Immunological ADRs can be:

- ❖ **IgE-mediated:** *e.g.*, urticaria, anaphylaxis.
- ❖ **Immune complex-mediated:** *e.g.*, vasculitis.
- ❖ **Cell-mediated:** *e.g.*, contact dermatitis.

Characteristics

Immunologically mediated ADRs:

- ❖ Are less predictable.
- ❖ Are not the normal pharmacological effects of drug but are due to hypersensitivity which has developed during a previous exposure either to the drug or to a chemically related compound.

Table 12.1. Pathogenesis of drug reactions

Immunological
❖ IgE-mediated reactions
❖ Cytotoxic reactions
❖ Immune complex-mediated reactions
❖ Cell-mediated hypersensitivity
Nonimmunological
Predictable
❖ Side effects
❖ Overdosage
❖ Cumulative toxicity
❖ Delayed toxicity
❖ Drug interactions
❖ Facultative effects
❖ Exacerbation of pre-existing skin conditions
❖ Teratogenicity
❖ Mutagenicity
Unpredictable
❖ Idiosyncratic reactions
❖ Intolerance
Special reactions
❖ Jarisch–Herxheimer reactions
❖ Infectious mononucleosis-ampicillin reaction

- ❖ Occur only in a minority of patients receiving the drug.
- ❖ Can develop even with low doses.
- ❖ Appear after a latent period (required for the immune response to develop), which may vary from a few seconds to a few days.

Nonimmunological Drug Reactions

Mechanism

Nonimmunological ADRs can be:

- ❖ **Side effects:** Due to unwanted pharmacological effects *e.g.*, stretch marks from systemic steroids, anagenic alopecia due to cytotoxic agents.
- ❖ **Overdosage:** Due to increased intake.
- ❖ **Cumulative effect:** Due to accumulation of drug because of:
 - *Defective metabolism*, *e.g.*, when there is hepatic dysfunction.
 - *Defective excretion*, *e.g.*, when there is renal disease.
- ❖ **Delayed toxicity:** *e.g.*, keratoses and skin tumors that appear many years after ingestion of inorganic arsenic.
- ❖ **Drug interactions:** *e.g.*, toxicity of methotrexate is increased when tetracyclines are given simultaneously.

- ❖ **Facultative effect:** Due to alteration in ecological balance, *e.g.*, vaginal candidiasis when broad-spectrum antibiotics are used.
- ❖ **Teratogenicity:** Thalidomide, retinoids, and cytotoxic drugs are proven teratogens.
- ❖ **Mutagenicity:** Anticancer drugs and radioisotopes are proven mutagens.
- ❖ **Idiosyncratic:** An odd, unpredictable reaction peculiar to an individual.

Characteristics

Nonimmunological ADRs:

- ❖ Are predictable.
- ❖ Affect all patients who take adequate amount of drug since immunological pathways are not involved.
- ❖ Large amounts of drug are usually required to initiate the reaction.
- ❖ May develop with the first dose.

Special Reactions

- ❖ Patients with syphilis when treated with penicillin develop exacerbation of pre-existing lesions (**Jarisch–Herxheimer reaction**).
- ❖ Patients with infectious mononucleosis when treated with ampicillin develop an exanthematous rash.

Patterns of Drug Reactions

ADRs manifest in skin in a variety of morphological patterns (Table 12.2).

Table 12.2. Clinical patterns of common drug reactions

Exanthematous eruptions and DRESS
Erythroderma
Epidermal necrolysis
Acute generalized exanthematous pustulosis
Fixed drug eruption
Photosensitive eruption
Vasculitis
Urticaria and angioedema
Lichenoid eruptions
Acneiform eruptions
Pigmentation
Alopecia
Increased hair growth
Xerosis and ichthyosis
Exacerbation of pre-existing dermatoses

Exanthematous Eruptions

Clinical Features

- ❖ Commonest drug eruption.
- ❖ Always itchy.
- ❖ Lesions are present symmetrically and frequently begin on the trunk and spread centrifugally (Fig. 12.1).

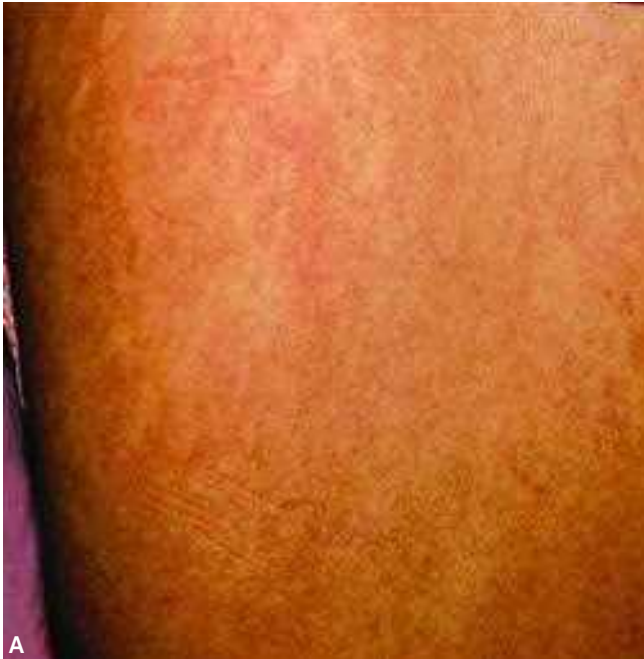

Fig. 12.1. Exanthematous eruption: A: due to carbamazepine. B: due to isoniazid.

- ❖ Eruption occurs in three clinical patterns:
 - Morbilliform or measles-like.
 - Scarletiform or scarlet fever-like.
 - Papulosquamous.
- ❖ Rash begins within 1–2 week of starting the therapy and subsides (with desquamation) 1–2 weeks after stopping the drug.
- ❖ **Drug rash with eosinophilia and systemic symptoms syndrome (DRESS):**
 - Also known as DHS (drug hypersensitivity syndrome).
 - *Drugs implicated:* anticonvulsants¹ (phenytoin, carbamazepine, phenobarbital, and lamotrigine), sulfonamides (*e.g.*, dapsone).
 - *Cutaneous manifestations:* facial edema conspicuous. Also generalized papulopustular or exanthematous rash, which may evolve to exfoliative dermatitis.
 - *Systemic manifestation:* lymphadenopathy², hematological abnormalities (hypereosinophilia and presence of atypical lymphocytes/mononucleosis) and organ involvement such as hepatitis, nephritis, pneumonitis, myocarditis and hypothyroidism, and encephalitis, occurring after 3–6 weeks of drug therapy.
 - *Mortality:* 10%.

Drugs Implicated

- ❖ **Common:**
 - *Penicillins:* ampicillin typically causes an exanthematous eruption in most patients with infectious mononucleosis.
 - *Sulfonamides:* including diuretics and hypoglycemics.
 - *Anticonvulsants:* phenytoin, barbiturates, lamotrigine, and carbamazepine.
 - *Antitubercular drugs:* isoniazid and rifampicin.
- ❖ **Others:** Allopurinol, nevirapine, and phenylbutazone.

Erythroderma (Exfoliative Dermatitis)

Clinical Features

- ❖ Entire skin surface (>90%) becomes erythematous, edematous, and scaly (Fig. 12.2).

1. **DRESS due to anticonvulsants:** also called **anticonvulsant hypersensitivity syndrome**. There may be cross reactivity between anticonvulsants even from different groups.
 2. **Lymphadenopathy:** in at least two sites to qualify for diagnosis of DRESS.

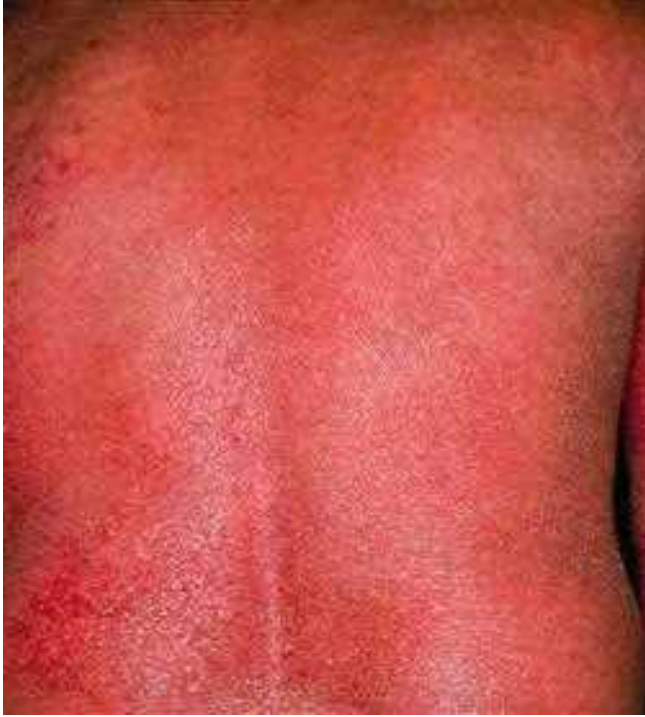

Fig. 12.2. Erythroderma: generalized erythema, edema and scaling.

Drugs Implicated

Drugs which can trigger erythroderma³ include:

- ❖ **Common:** Sulfonamides, penicillins, anticonvulsants (barbiturates and carbamazepine).
- ❖ **Others:** Phenylbutazone, isoniazid, and gold.

Epidermal Necrolysis

Also called Stevens–Johnson syndrome–toxic epidermal necrolysis (SJS–TEN) complex.

Clinical Features

Onset

- ❖ History of antecedent drug intake (1–3 weeks prior to onset of rash) is present. Most recently added drug probable suspect.
- ❖ Prodromal symptoms common and often severe.

Morphology

- ❖ Begins as diffuse dusky erythema typically with crinkled surface. Initial lesions may be targetoid.

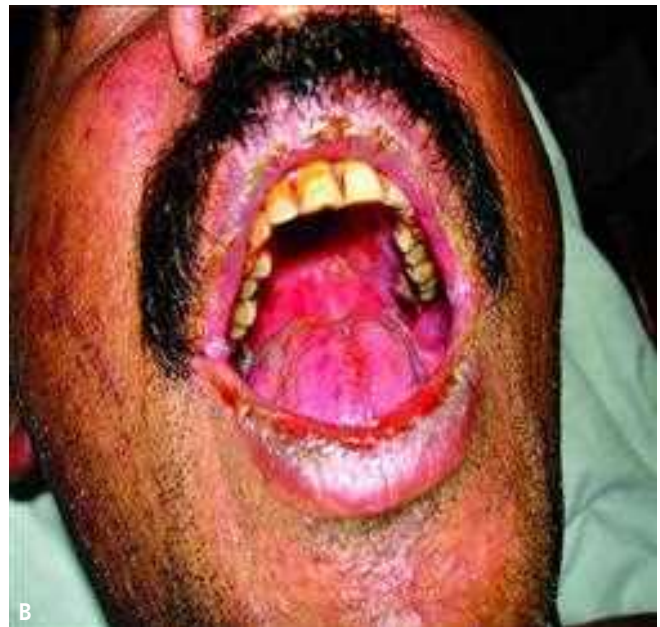
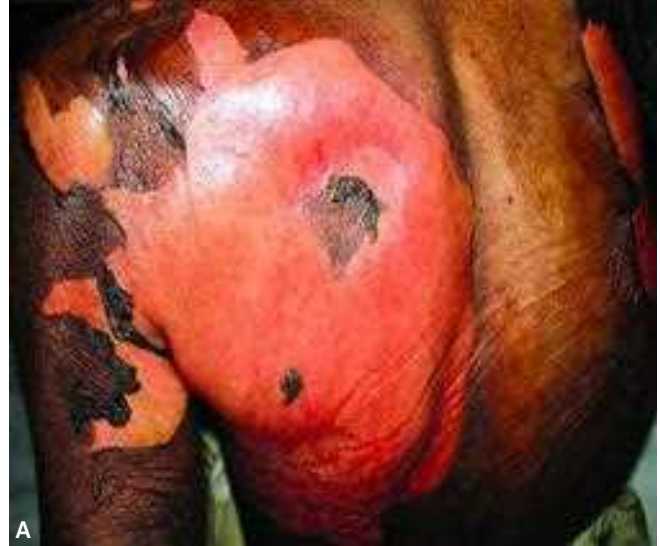
Fig. 12.3. Toxic epidermal necrolysis: A: large areas of skin denude, exposing red oozing dermis. B: hemorrhagic crusting of lips and diffuse erythema of oral mucosa.

- ❖ Lesions rapidly coalesce into large sheets of erythema. Soon flaccid (sometimes hemorrhagic) blisters develop. Eventually, large areas of skin denude, exposing red oozing dermis (Fig. 12.3A).

Sites of predilection

- ❖ Involvement extensive. Starts from face, neck, chest, and central trunk.

3. **Erythroderma:** caused most frequently.

- ❖ Soon coalesce (especially face and neck) and become generalized.

Mucosal lesions

- ❖ Involvement of mucosa universal. Oral mucosa (100%), eyes (90%), genital and nasal mucosa (50%).
- ❖ **Manifestations:**
 - *Oral mucosa:* hemorrhagic crusting of lips. Bullae, which rupture to form erosions, covered with grayish white slough. Or diffuse erythema (Fig. 12.3B).
 - *Eyes:* purulent conjunctivitis, corneal erosions.
 - *Genital and nasal mucosae:* hemorrhagic crusting.
 - *Complications:* sepsis, electrolyte imbalance, multiorgan failure, death.

Drugs Implicated

- ❖ **Common:** Antibiotics and related compounds (sulfonamides, quinolones, and cephalosporins), anticonvulsants (barbiturates, phenytoin, carbamazepine, and lamotrigine) **antituberculous** drugs, NSAIDs (salicylates, ibuprofen, paracetamol, and oxicam group).
- ❖ **Others:** Cyclophosphamide, nitrogen mustard, allopurinol, and nevirapine.

Acute Generalized Exanthematous Pustulosis

- ❖ **Morphology:** Small pustules develop rapidly on an erythematous background (Fig. 12.4).

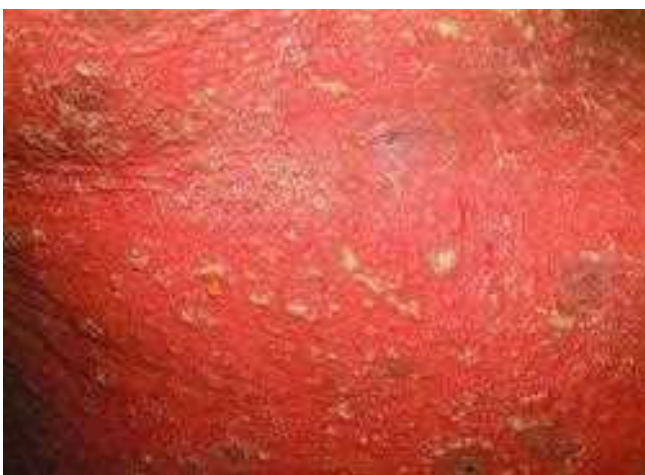

Fig. 12.4. Acute generalized exanthematous pustulosis: small pustules develop rapidly on an erythematous background.

- ❖ **Distribution:** Often starts on face or in flexural areas, rapidly becoming generalized.
- ❖ **Associations:** May be associated with fever and malaise, but generally the patient is not particularly unwell. Transient renal abnormalities noted in about third of patients.
- ❖ **Course:** Pustulosis develops within 24 h of drug administration, may last for 1–2 weeks and then resolves with desquamation.
- ❖ **Drugs incriminated:** Antibiotics (ampicillin, amoxicillin, and spiramycin) implicated in 80% of patients.

Fixed Drug Eruption (FDE)

Clinical Features

- ❖ Appear as well-defined circular, deeply erythematous plaques (Fig. 12.5A), which sometimes develop central bullae.
- ❖ Subside leaving behind slate-gray hyperpigmentation, which persists in between acute episodes (Fig. 12.5B).
- ❖ Lesions recur at the same site, each time the drug is taken, usually 8–16 h after the intake of drug.
- ❖ Mucocutaneous junctions (lip and glans) most frequently involved. Limbs more frequently involved than trunk.
- ❖ Diagnosis confirmed by provocation.

Drugs Implicated

- ❖ **Common:** Sulfonamides (cotrimoxazole, dapsone), tetracyclines, NSAIDs (naproxen, aspirin, ibuprofen), fluoroquinolones, metronidazole.
- ❖ **Others:** Barbiturates.

Photosensitive Eruption

Always exclude drug-induced photosensitivity in any photosensitive eruption.

Clinical Features

- ❖ Itchy erythematous papules and plaques (Fig. 12.6).
- ❖ Photo-exposed parts.

Drugs Implicated

- ❖ **Common:** Antimicrobials (sulfonamides, tetracyclines, quinolones, and griseofulvin), phenothiazines, and psoralens.
- ❖ **Others:** Ampicillin.

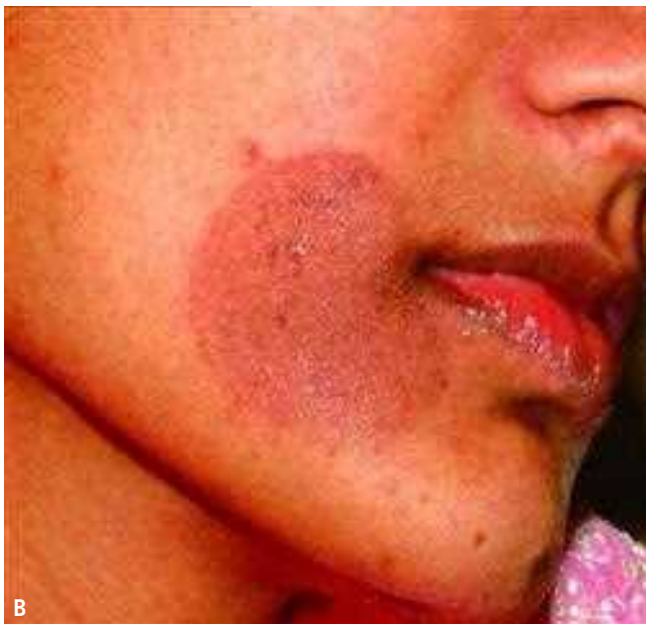
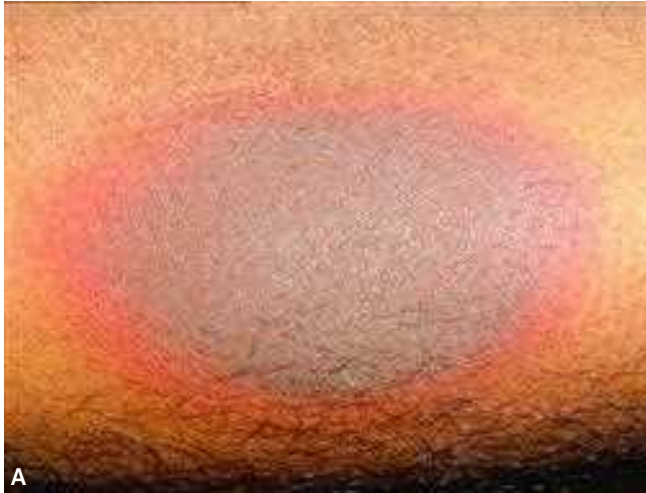
Fig. 12.5. Fixed drug eruption: A: active lesion is a well-defined, oval-circular, deeply erythematous plaque, which sometimes develops a central bulla and recurs at same site on drug intake. B: subsides to leave behind slate-gray hyperpigmentation, which persists in between acute episodes.

Vasculitis

Pathogenesis

Due to deposition of immune complexes around the blood vessels.

Clinical Features

Vasculitis triggered by drugs can manifest as:

- ❖ Urticarial vasculitis.
- ❖ Palpable purpura.
- ❖ Necrotic ulcers.
- ❖ Nodular vasculitis.

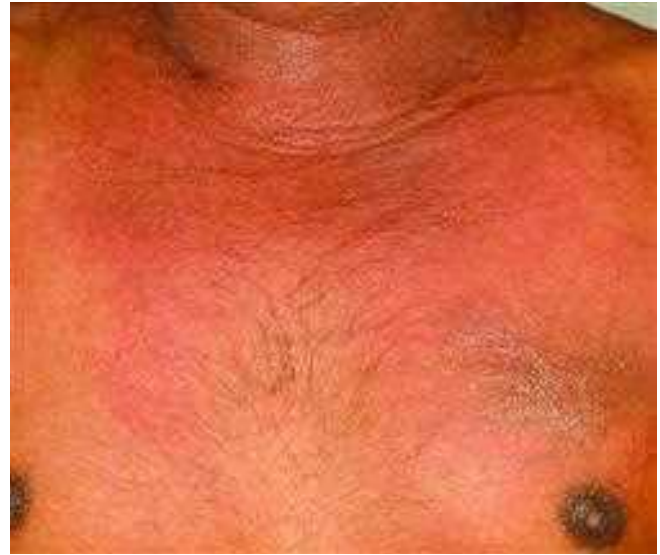

Fig. 12.6. Photosensitive eruption: Itchy erythematous lesions on photo-exposed parts.

Drugs Implicated

- ❖ **Common:** NSAIDs (phenylbutazone, indomethacin, and aspirin), diuretics, antimicrobials (sulfonamides tetracyclines, ampicillin, and erythromycin).
- ❖ **Others:** Phenytoin, fluoxetine, and methotrexate.

Urticaria and Angioedema

Pathogenesis

Drugs cause urticaria by:

- ❖ Direct degranulation of mast cells.
- ❖ Interfering with arachidonic acid metabolism.
- ❖ IgE-mediated degranulation of mast cells.
- ❖ Complement-mediated degranulation of mast cells.

Clinical Features

Urticaria (Fig. 12.7) and angioedema can occur independently or may also be part of a severe and generalized reaction (anaphylaxis), which includes bronchospasm and circulatory collapse.

Drugs Implicated

- ❖ **Drugs which directly degranulate mast cells:**
 - Aspirin.
 - Indomethacin.
- ❖ **Drugs which interfere with arachidonic acid metabolism:**
 - Opiates: morphine and codeine.

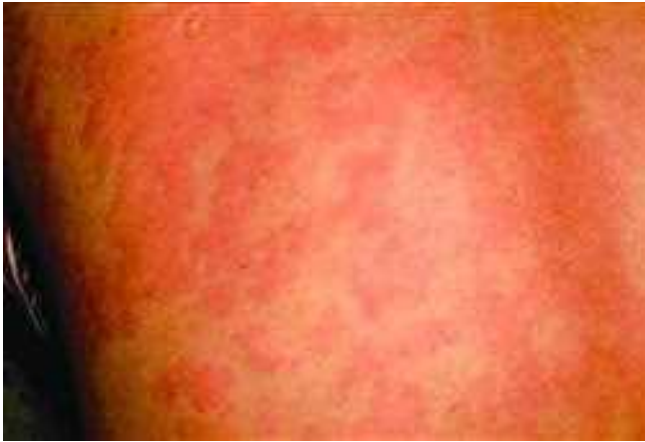

Fig. 12.7. Urticaria: due to salicylates.

- Sulfonamides.
- Curare.
- Radioactive contrast.
- ❖ **Drugs which mediate urticaria through IgE:**
 - Penicillin.
- ❖ **Drugs which mediate urticaria through complement system:**
 - Blood products.

Lichenoid Eruption

Clinical Features

Drug-induced lichenoid eruption closely resembles lichen planus (LP), but differs from LP in that:

- ❖ Lesions are eruptive and numerous.
- ❖ Scaling and eczematous component conspicuous.
- ❖ Mucosal and nail involvement infrequent.
- ❖ Trunk preferentially involved.

Drugs Implicated

- ❖ **Common:** Gold, antimalarials and tetracyclines.
- ❖ **Others:** Dapsone, phenothiazines, levamisole, penicillamine and captopril.

Acneiform Eruption

Suspect drug-induced acne in patients who rapidly develop extensive papulopustular lesions especially on trunk.

Clinical Features

- ❖ Lesions can occur at any age (usually after adolescence).

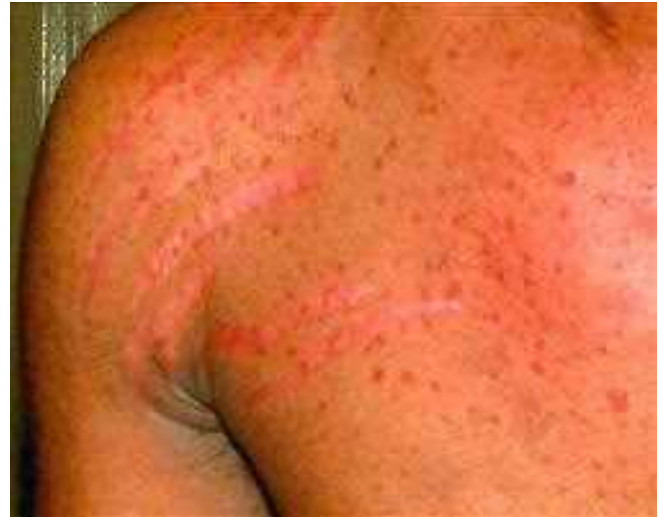

Fig. 12.8. Acneiform eruption: due to steroids. Note the striae.

- ❖ Lesions are monomorphic (*cf.*, acne vulgaris which is polymorphic) and never comedonal.
- ❖ Truncal lesions more prominent than facial lesions (Fig. 12.8).

Drugs Implicated

- ❖ **Common:** Oral steroids, androgens, antituberculous drugs, oral contraceptives and anticonvulsants.
- ❖ **Others:** Iodides, bromides and lithium.

Pigmentation

Pathogenesis

Drug-induced alteration in skin color is due to:

- ❖ Increased melanin synthesis, *e.g.*, psoralens.
- ❖ Cutaneous deposition of drug or metabolite, *e.g.*, minocycline.
- ❖ Postinflammatory hyperpigmentation.
- ❖ Hormonal effect, *e.g.*, melasma like pigmentation with oral contraceptives.

Drugs Implicated

- ❖ **Clofazimine**⁴ which imparts an orange-brown color to the skin (Fig. 12.9A). Usually associated with ichthyosis.
- ❖ Oral contraceptives, which trigger chloasma.
- ❖ In large doses, phenothiazines induce a blue-gray pigmentation in sun-exposed skin.
- ❖ Heavy metals cause a generalized brown pigmentation.

4. **Clofazimine:** antileprosy drug.

- ❖ Psoralens and UVA.
- ❖ Anticancer drugs, *e.g.*, bleomycin, cyclophosphamide, fluorouracil, hydroxyurea and methotrexate.
- ❖ Gold.
- ❖ Minocycline, which causes bluish pigmentation of acne scars (Fig. 12.9B) and also oral mucosa.

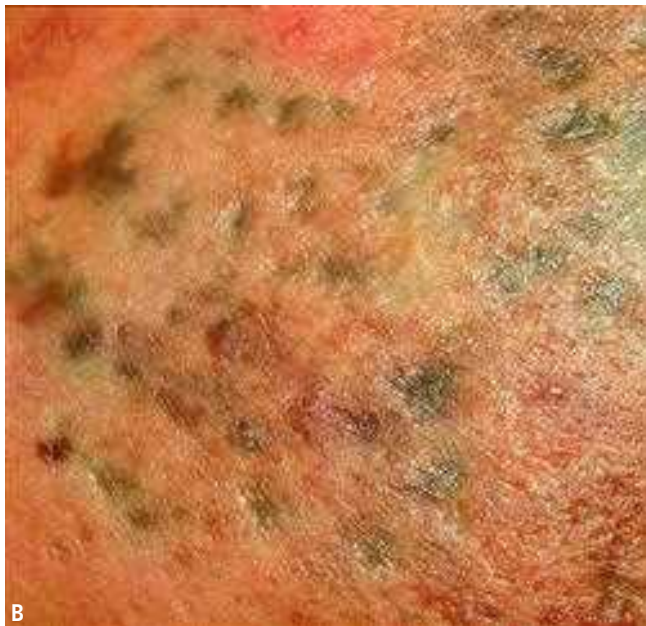
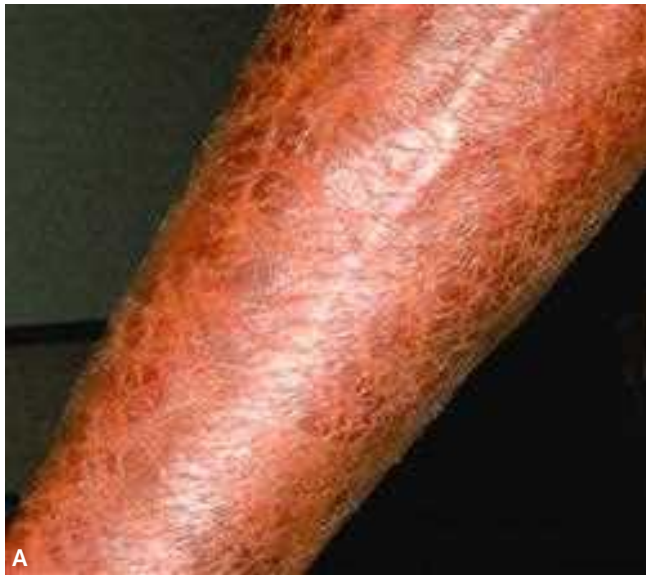
Fig. 12.9. Drug-induced pigmentation A: clofazimine-induced hyperpigmentation and ichthyosis. B: minocycline-induced pigmentation of acne scars.

Alopecia

Diffuse hair loss may be seen during or after therapy with the following drugs:

- ❖ Retinoids: acitretin, isotretinoin.
- ❖ Cytotoxic agents.
- ❖ Anticoagulants.
- ❖ Antithyroid drugs.
- ❖ Danazol.
- ❖ Oral contraceptives.

Increased Hair Growth

Clinical Features

Two patterns of increased hair growth recognized:

- ❖ Hypertrichosis⁵.
- ❖ Hirsutism⁵.

Drugs Implicated

- ❖ **Hypertrichosis:** Psoralens and UVA, phenytoin, minoxidil, penicillamine, and cyclosporine A.
- ❖ **Hirsutism:** Oral steroids, anabolic steroids and oral contraceptive pills.

Xerosis and Ichthyosis

Clinical Features

The skin can become rough and scaly. The ichthyosis may be limited to skin lesions (as seen in clofazimine-induced ichthyosis).

Drugs Implicated

- ❖ **Common:** Clofazimine (Fig. 12.7), oral retinoids (Fig. 12.10).
- ❖ **Others:** Lipid lowering agents, nicotinic acid, and lithium.

Rare Patterns of Drug Eruption

- ❖ **Bullous eruptions:** Bullae may develop at pressure sites in drug-induced coma.
- ❖ **Eczematous eruptions:** This uncommon pattern occurs mainly when a patient sensitized by topical application of a drug is given the same drug systemically. Penicillin, sulfonamides, neomycin, and local anesthetics should be considered in the etiology.

5. **Hypertrichosis:** means increased hair growth, in no particular pattern while **hirsutism** is increased hair growth in androgen sensitive areas.

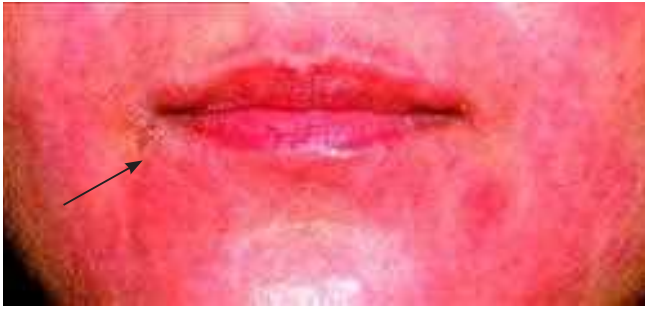

Fig. 12.10. Drug-induced xerosis: isotretinoin-induced xerosis.

Exacerbation of Pre-existing Dermatoses

Several drugs can exacerbate pre-existing skin diseases.

- ❖ **Psoriasis:** May be made worse by giving beta-blockers, antimalarials, and lithium.
- ❖ **Acne:** May be exacerbated by androgens, steroids, anticonvulsants, and lithium.

Drugs and their Pattern of Reaction

Antibiotics

Antibiotics frequently cause rashes. However, infections, especially viral infections are often associated with exanthems and these are often misdiagnosed as drug eruptions, when in fact they are viral exanthems.

Penicillins

Penicillins are one of the commonest causes of allergic reactions. The different types of adverse events seen with penicillin include:

- ❖ Morbilliform (measles-like) eruption:
 - Itchy erythematous rash.
 - Most patients with infectious mononucleosis develop a morbilliform rash if ampicillin or amoxicillin is administered to them.
- ❖ Erythroderma.
- ❖ Urticaria.
- ❖ Epidermal necrolysis.
- ❖ Anaphylactic reactions, sometimes severe and life-threatening.

Tetracyclines

These are responsible for several patterns of drug eruptions:

- ❖ Fixed drug eruption.
- ❖ Photosensitivity.
- ❖ Minocycline accumulates in tissues and produces brown or gray hyperpigmentation of the mucosa, sun-exposed areas and at sites of inflammation as in healing lesions of acne (Fig. 12.7B).

Steroids

- ❖ **Systemic steroids:** Cutaneous side effects of systemic steroids include:
 - Flushed, moon face (**Cushingoid facies**; Fig. 12.11A).
 - Cutaneous atrophy, striae (Fig. 12.11B).
 - Hirsutism, steroid acne (steroid folliculitis, Fig. 12.6).
 - Increased susceptibility to cutaneous infections, *e.g.*, dermatophytic infections which may manifest as **tinea incognita** (Fig. 12.11C) as well as extensive and recurrent pyodermas.
- ❖ **Topical steroids:** Side effects of topical steroids depend on the potency and formulation of the steroid, whether used under occlusion or not, area of use and whether used on intact or disrupted skin. The side effects include (Fig. 12.12):
 - Atrophy of skin.
 - Hypopigmentation.
 - Telangiectasia.

Nonsteroidal Anti-inflammatory Drugs

Aspirin

- ❖ Can aggravate urticaria because of immunological as well as direct degranulation of mast cells.
- ❖ Anaphylaxis.
- ❖ Ecchymosis: due to platelet abnormalities.
- ❖ **Systemic adverse effects:** Nephropathy, bone marrow depression, and gastric hemorrhage.

Anticonvulsants

Anticonvulsants are common causes of ADRs.

Carbamazepine

- ❖ 3–12% of patients develop rashes.
- ❖ Different patterns seen include:
 - Morbilliform eruptions.
 - Epidermal necrolysis.
 - DRESS.

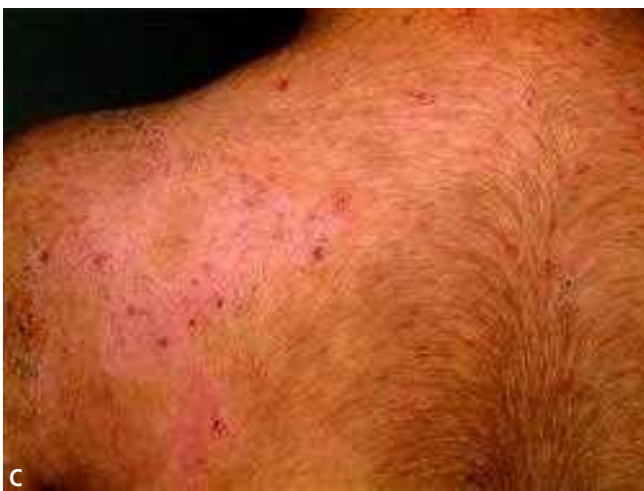
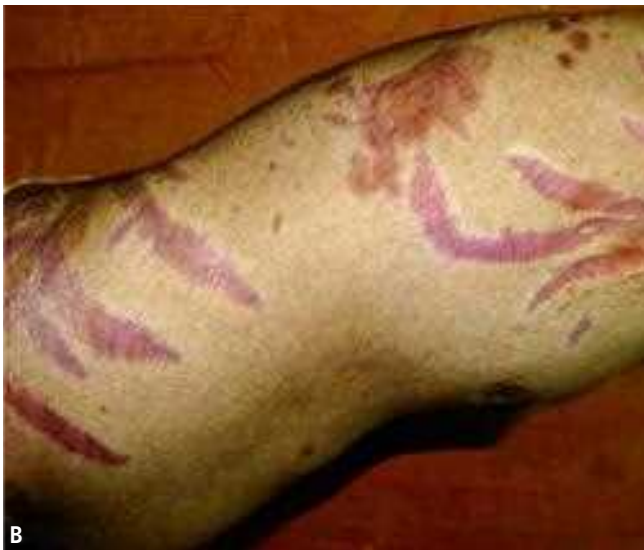
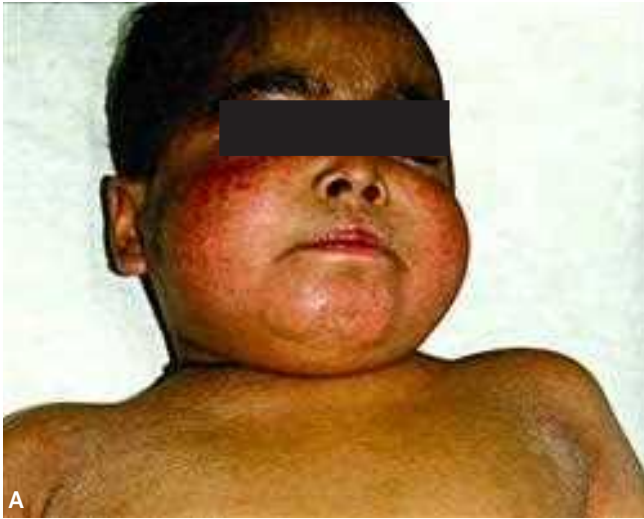Fig. 12.11. Side effects of steroids: A: Cushingoid facies: a common side effect of systemic steroids. B: striae: a side effect of both systemic and topical steroid therapy. C: tinea incognita.

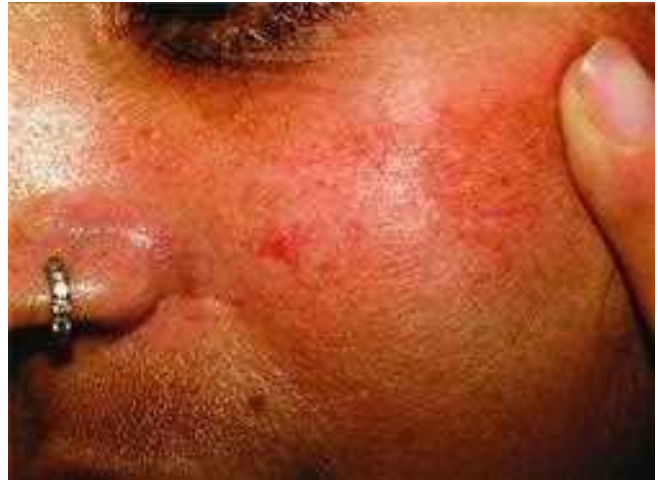

Fig. 12.12. Side effects of topical steroids: atrophy, telangiectasia, and hypopigmentation.

Phenytoin

Phenytoin can cause

- ❖ Exanthematous eruptions.
- ❖ Epidermal necrolysis.
- ❖ DRESS.
- ❖ Gum hypertrophy (Fig. 12.13).

Antituberculous Drugs

Several types of ADRs develop to antituberculous drugs.

Isoniazid

- ❖ Monomorphic acneiform eruption.
- ❖ Urticaria.
- ❖ Purpura.

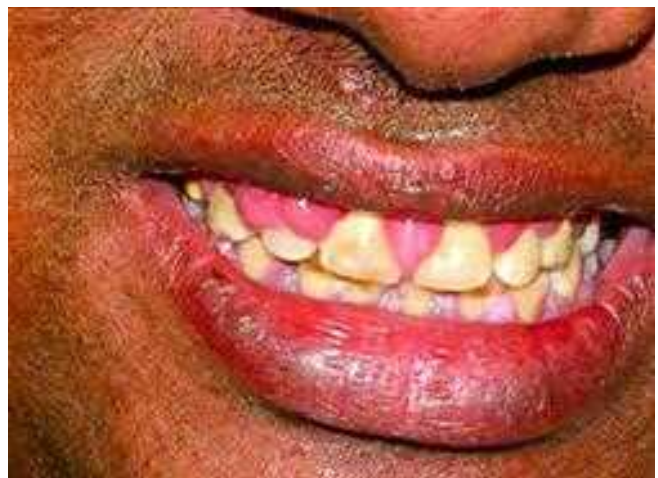

Fig. 12.13. Gum hypertrophy: a side effect of phenytoin.

- ❖ LE-like syndrome.
- ❖ Pellagrous dermatitis.
- ❖ Epidermal necrolysis.
- ❖ Exfoliative dermatitis.

Rifampicin

- ❖ Erythema multiforme.
- ❖ Pemphigus-like eruption.
- ❖ Thrombocytopenia.

Course

Onset of the eruption depends on:

- ❖ Type of reaction.
- ❖ Whether it is the first exposure to the drug or re-exposure.
- ❖ On the drug itself.

The course of drug eruption depends on:

- ❖ Type of exposure: first or re-exposure.
- ❖ Type of reaction.
- ❖ Health of patient.

The speed of clearance of depends on:

- ❖ Type of reaction.
- ❖ Rapidity with which the drug is eliminated.
- ❖ Institution of steroid therapy.

Exanthematous Reactions

- ❖ Start 2–3 days after re-exposure to the drug.
- ❖ If the reaction occurs during the first exposure itself, the eruption characteristically begins later, often coming up about the ninth day or even later. It may occur even after the drug has been stopped.

Epidermal Necrolysis (EN)

- ❖ Usually begins during re-exposure to drug, when it starts on second–third day. During first exposure, if drug is being given for >7 days, EN may begin on the ninth day or later. It sometimes develops, even after the drug has been stopped.
- ❖ In the absence of complications, denuded skin begins to heal within a few days and healing is complete within 3 weeks, usually with hyperpigmentation.
- ❖ Often disease is complicated by secondary

infection, skin failure, corneal scarring, and even death.

Fixed Drug Eruption⁶

- ❖ Occurs at the same site every time the drug is administered.
- ❖ If only some of the hyperpigmented spots get reactivated when a patient takes a drug, then the patient may be reacting to more than one drug.

Management

Investigations

- ❖ **Provocation tests**⁷: Need to be done to:
 - Find the culprit drug in patients taking many drugs.
 - Find alternative safe drugs.
- ❖ **Prick tests and in vitro tests**: For allergy are not reproducible and **so are of no value**.

Diagnosis

Points for diagnosis

- ❖ Does the rash itself suggest a drug eruption (*e.g.*, FDE or erythema multiforme) and fits with a well-recognized pattern caused by one of the drugs the patient is taking (*e.g.*, FDE from sulfonamides drugs)?
- ❖ Exclude a known dermatosis (such as lichen planus, dermatophytic infection, scabies or psoriasis) as well as skin manifestations of an underlying disorder (*e.g.*, systemic lupus erythematosus).
- ❖ The possibility of a drug eruption should be kept in mind when an atypical rash is seen.
- ❖ Every effort must be made to temporally correlate the onset of the rash with drug history.
- ❖ Check for a past history of drug reaction with the same or related drugs.
- ❖ Was any drug introduced just a few days before the eruption appeared? Often (not always!), the drug to be introduced last is the most likely culprit, though it is never too early or too late to develop a drug rash: a patient can develop an eruption to a drug even if he has been taking the drug for several years!

6. **Fixed drug eruption**: if the patient with FDE takes the 'culprit' drug, the FDE spots become erythematous within 24 hours.

7. **Provocation tests**: provocation in the more severe drug eruptions like SJS–TEN complex is controversial.

Differential Diagnosis

Differential diagnosis depends on the morphological pattern of drug rash.

Exanthematous drug reaction

Exanthematous drug reactions should be differentiated from:

a. Viral exanthems

Viral exanthems	Exanthematous drug reaction
Itching: less	Often severe
Morphology: monomorphic and may have a pattern of evolution	Polymorphic; no pattern of evolution
Begins: face and spreads	Trunk
Course: usually self-limiting	May progress, if drug not stopped

Treatment

Withdrawal of Drug

- ❖ The most effective approach is to withdraw the drug but the decision to stop the drug depends on several factors:
 - Severity of reaction and its reversibility.
 - Probability of drug having caused the reaction.
 - Nature of drug.
 - Availability of chemically unrelated alternatives in case of life-saving drugs.
- ❖ Withdrawal is, however, not always possible because:
 - Of difficulty in identifying the culprit in case of polypharmacy, e.g., antituberculous drugs.
 - Drug may be essential and no alternative is available.

Adjuvant Therapy

Adjuvant therapy depends upon the type of eruption.

Urticaria

- ❖ Antihistamines are helpful and it is advisable to combine antihistamines belonging to two different groups
- ❖ Oral steroids are best avoided unless:
 - There is a history of laryngeal edema.
 - Urticaria is recalcitrant.

Anaphylactic reactions

Require special treatment.

- ❖ Ensure that the airway is not compromised. Provide oxygen supplementation, assisted respiration and even do an emergency tracheostomy.
- ❖ Injection adrenaline⁸ (1:1000), 0.3–0.5 ml should be given subcutaneously or intramuscularly⁹.
- ❖ Chlorpheniramine maleate (10–20 mg), intravenous.
- ❖ Hydrocortisone (100 mg) should be given intravenously to prevent further deterioration in severely affected patients.
- ❖ Patients should be observed for 6 h after their condition is stable, as delayed deterioration is known.

Exanthematous reactions

- ❖ **Mild reactions:** Can be controlled with topical soothing agents like calamine lotion or cold cream. Combine with oral antihistamines.
- ❖ **Severe reactions:**
 - Systemic corticosteroids.
 - IV IgG has been successfully used in DRESS.

Photosensitive eruptions

- ❖ Photoavoidance and photoprotection is important.
- ❖ **Symptomatic treatment:** For less severe disease
 - Soothing agents.
 - Topical steroids.
 - Antihistamines.
- ❖ **Immunomodulators and immunosuppressives:** For severe disease
 - Systemic steroids.
 - Azathioprine.
 - Methotrexate.
 - Thalidomide.

Stevens–Johnson syndrome–toxic epidermal necrolysis complex

- ❖ Supportive care with skin and eye hygiene, management of fluid and electrolyte balance and maintenance of temperature.
- ❖ Systemic corticosteroids (though the benefit is controversial) are often used.
- ❖ Intravenous immunoglobulins (IgG) and cyclosporine are a recent advance.

8. **Adrenaline:** epinephrine.

9. **Intramuscular:** never intravenous.

Autoimmune Connective Tissue Diseases

13

Chapter Outline

Introduction

- Nomenclature^o
- Classification[•]
- Pathogenesis^o

Lupus Erythematosus

- Discoid lupus erythematosus[•]
- Subacute cutaneous lupus erythematosus^o
- Systemic lupus erythematosus[•]

Dermatomyositis[•]

- Etiology
- Epidemiology
- Clinical features
- Investigations
- Diagnosis
- Treatment

Scleroderma

- Etiology[•]
- Classification[•]
- Systemic sclerosis[•]
- Morphea[•]

Miscellaneous Disorders

- Lichen sclerosus et atrophicus[•]
- Mixed connective tissue disease^o
- Behcet's disease^o
- Panniculitis^o
- Rheumatoid arthritis^o

[•]Should know
^oGood to know

Introduction

Nomenclature

- ❖ The older term for these disorders was **collagen vascular diseases** but this is a misnomer as there is no evidence that collagen is at fault.
- ❖ Since there is substantial evidence to suggest that these disorders are mediated immunologically, the term **autoimmune connective tissue diseases** has also been used for them.
- ❖ The diseases have also been collectively called **rheumatological diseases**, because joint involvement is a prominent feature of these diseases.

Classification

Diseases in this group present as a spectrum ranging from benign cutaneous variants to severe, often fatal, multisystem diseases (Table 13.1).

Pathogenesis

- ❖ Most prominent feature is inflammation of the connective tissue, resulting in changes in skin, joints, and other organs.

Table 13.1. Classification of connective tissue diseases

	<i>Lupus erythematosus</i>	<i>Dermatomyositis</i>	<i>Scleroderma</i>
Mild localized disease	Discoid lupus erythematosus		Morphea
Moderate disease	Subacute lupus erythematosus	Juvenile dermatomyositis	Limited systemic sclerosis
Aggressive, multisystem disease	Systemic lupus erythematosus	Adult dermatomyositis	Diffuse systemic sclerosis

Table 13.2. Serological markers of connective tissue diseases

Antibody against	Nucleoprotein (ANA)		ds DNA	Ro/SS-A	Sm (ENA)*	RNP**	Centromere	Histones
Disease	% Positivity	IF pattern						
LE [†]			-					
DLE	35 (low titer)	Homogeneous, speckled	-		Rarely			
SCLE	80	Homogeneous, speckled	10%	60%	10%			
SLE	100 (high titer)	Peripheral, homogeneous, speckled	70%	20%	30%		Rarely	Drug-induced LE
DM ^{††}	20	Speckled				Occasionally		
SSc ^{†††}	90	Speckled, nucleolar					50%, in limited variety	
MCTD ^{††††}	100	Speckled			100%	High titer diagnostic		

* Extractable nuclear antigen

** Ribonucleoprotein

†LE: Lupus erythematosus

††DM: Dermatomyositis

†††SSc: Systemic sclerosis

††††MCTD: Mixed connective tissue disease.

- ❖ Antibodies formed against cellular components may be triggering tissue injury (Table 13.2).

Lupus Erythematosus (LE)

Diseases included are:

- ❖ Discoid lupus erythematosus (DLE) and disseminated DLE.
- ❖ Subacute cutaneous lupus erythematosus (SCLE).
- ❖ Systemic lupus erythematosus (SLE).

Discoid Lupus Erythematosus (DLE)

Synopsis

Etiology: Unknown etiology; aggravation on exposure to ultraviolet rays.

Morphology: Annular, erythematous, discoid, plaque(s) with follicular plugging and adherent scales. Central depigmentation, scarring and peripheral erythema, and hyperpigmentation.

Sites: Face, ears, and scalp. Also below neck in disseminated variant.

Investigations: Biopsy characteristic. Direct immunofluorescence shows IgG deposit at dermoepidermal junction.

Treatment: Photoprotection. *Localized lesions:* Potent topical or intralesional steroids. *Disseminated/resistant lesions:* Hydroxychloroquine.

Etiology

- ❖ Etiology unknown, but **ultraviolet radiation (UVR)** is known to exacerbate DLE in about 70% of patients.
- ❖ UVR exacerbates DLE by:
 - Inducing neoantigen expression and this antigen triggers a dysregulated immune response.
 - Releasing immune mediators which induce inflammation.
 - Inducing autoreactive T cells which induce inflammation.

Epidemiology

- ❖ **Incidence:** DLE is seven times less common than SLE.
- ❖ **Age:** Peak incidence in fourth decade.
- ❖ **Gender:** Female preponderance (male:female ratio 1:2).

Clinical Features

Morphology

- ❖ Characteristic lesion is a well-demarcated, discoid/annular, erythematous plaque with adherent scales (Fig. 13.1).
- ❖ When the scale is removed, its undersurface shows keratotic spikes which have occupied the dilated pilosebaceous canals (**carpet tack sign**¹).

1. **Carpet tack:** similar to under surface of a tacked carpet.

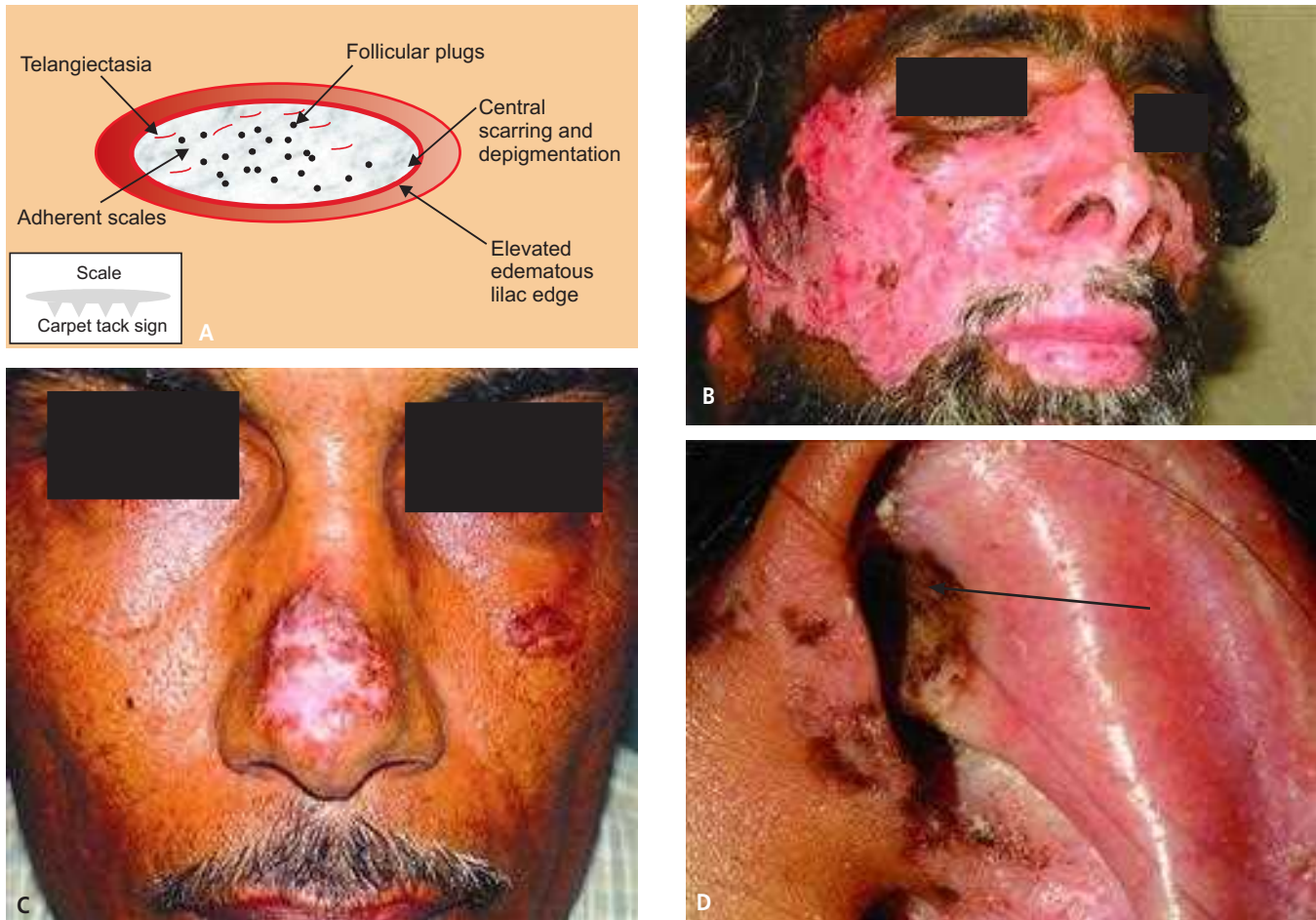


Fig. 13.1. Discoid lupus erythematosus: A: well-defined annular plaque with adherent scales and follicular plugs. Inset: when scales are removed, the under surface shows keratotic spikes, which have occupied the dilated pilosebaceous canals (carpet tack sign) B: large lesion. C: early lesion. D: lesion in concha showing follicular plugs.

When not covered by scales, these horny collections are visible as follicular plugs (Fig. 13.1A).

- ❖ The center of the lesion is atrophic, scarred, and depigmented with telangiectasia.
- ❖ The active border is elevated, sometimes edematous and shows lilac erythema and hyperpigmentation.

Sites

- ❖ Lesions seen predominantly on the sun-exposed areas of face, on scalp, and characteristically in external ear (Fig. 13.2).
- ❖ When lesions occur below the neck, the disease is termed **disseminated DLE**; in which, lesions

occur on dorsolateral aspect of forearms, trunk and sometimes on the lower extremities.

Mucosal lesions

- ❖ In 25% of patients with DLE, mucosal lesions are present.
- ❖ Most frequently seen on lips and buccal mucosa.
- ❖ Present as sharply margined plaques with scalloped borders, surrounded by radiating white striae and telangiectasia.

Variants

- ❖ Hypertrophic DLE.
- ❖ Lupus profundus² (Fig. 13.3).
- ❖ Lupus panniculitis.

2. **Profundus**: meaning deep seated, *e.g.*, miliaria profundus, morphea profundus, and LE profundus.

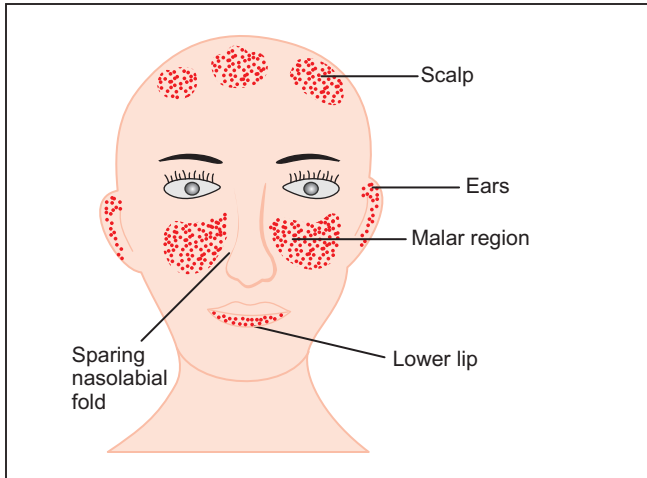


Fig. 13.2. Discoid lupus erythematosus: Distribution of lesions.

Course

- ❖ DLE lesions run a chronic course.
- ❖ Rarely (<5%) progresses to SLE.

Complications

- ❖ Lesions usually heal with ugly depigmentation and scarring, which is not cosmetically acceptable.
- ❖ Cicatricial alopecia is a sequelae of scalp lesions (Fig. 13.4).
- ❖ Occasionally (<5% of patients), progress to SLE.

Investigations

To confirm diagnosis

Biopsy

- ❖ Diagnosis of DLE is established by a biopsy.
- ❖ Specimens of DLE lesions should be sent for:
 - *Histopathology* (Fig. 13.5A) is characterized by:
 - Hyperkeratosis.
 - Epidermal atrophy with follicular plugs.
 - Basal cell degeneration.
 - Perivascular and periappendageal lymphocytic infiltrate.
 - *Direct immunofluorescence* (Fig. 13.5B): Shows linear deposits of IgG, IgM, IgA, and C3 at dermoepidermal junction.

To rule out SLE

Even though the chance of progressing to SLE is remote, screening for systemic involvement may be done:

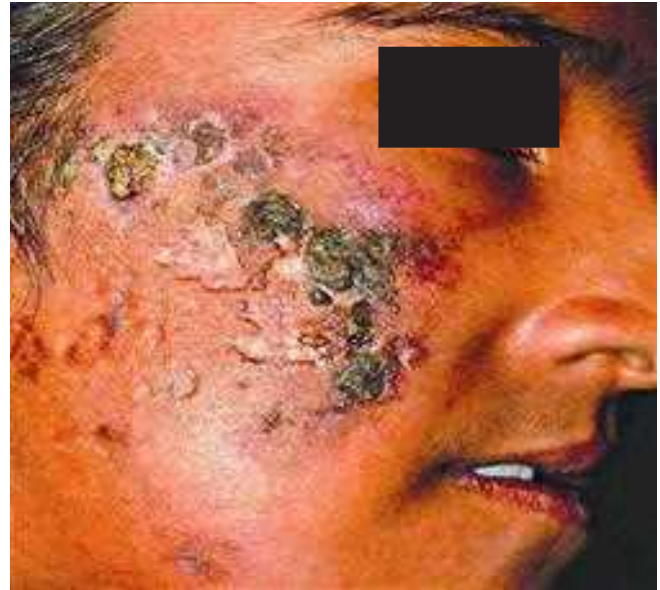

Fig. 13.3. Lupus profundus: deep-seated, subcutaneous nodule with overlying skin either normal (when termed lupus panniculitis) or showing lesions of DLE.

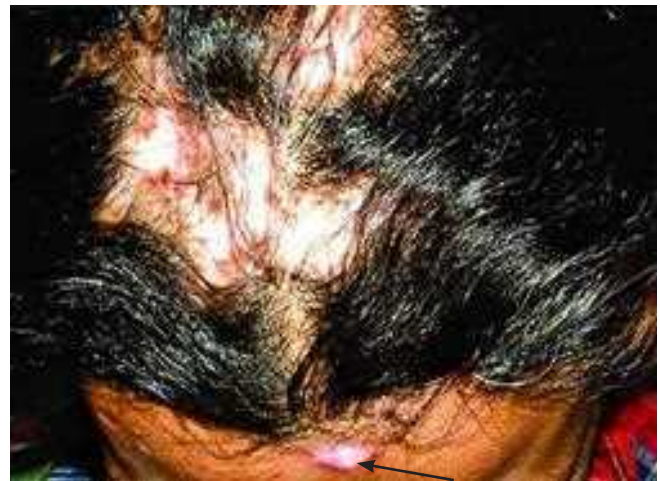

Fig. 13.4. Discoid lupus erythematosus: causing scarring alopecia. Note typical lesion on forehead.

❖ *Antinuclear antibody:*

- Seen in 5–20% of patients.
- Homogeneous pattern more common than speckled
- ❖ Hemogram.
- ❖ Urine examination.

Diagnosis

Points for diagnosis

Diagnosis of DLE is based on the presence of:

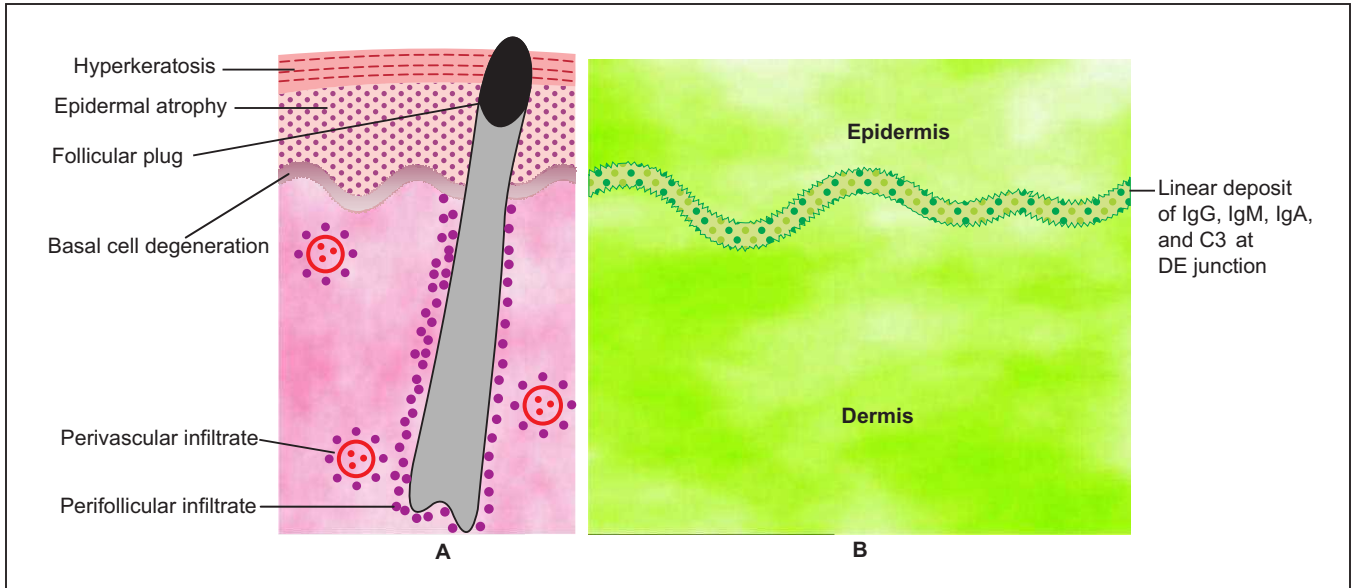


Fig. 13.5. Discoid lupus erythematosus: A: histopathology shows hyperkeratosis, epidermal atrophy with follicular plugs, basal cell degeneration and perivascular and periappendageal lymphocytic infiltrate. B: immunopathology shows linear deposit of IgG, IgM, IgA, and C3 at dermoepidermal junction.

- ❖ Annular, discoid plaques with adherent scales, showing “carpet tack” keratotic spikes on the undersurface.
- ❖ Central depigmentation and peripheral hyperpigmentation and erythema.
- ❖ Typical distribution on face, ears, and scalp.

Differential diagnosis

DLE needs to be differentiated from:

a. Psoriasis

Psoriasis	DLE
Plaque: discoid plaques; only infrequently is center clear when it shows pigmentary changes	Annular plaques; center shows atrophic scarring and depigmentation
Scales: loose, silvery scales with positive Auspitz sign	Adherent scales, with positive carpet tack sign
Follicular plugging: absent	Conspicuous
Distribution: symmetrical distribution especially on pressure points (elbows, knees, lower back) and scalp	Face, ears, scalp
Facial lesions: uncommon	Invariable
Oral lesions: rare	In 25% of patients

b. Lupus vulgaris (LV)

LV	DLE
Plaque: annular or arcuate plaque with an indurated border of papules and nodules, which exhibit “apple jelly” appearance on diascopy	Annular plaque with violaceous halo
Centre: atrophy and scarring with nodules characteristically present in scarred area	Central atrophy and scarring with adherent scales and follicular plugs
Follicular plugs: absent	Conspicuous
Distribution: face, buttocks	Face, ears, scalp

Treatment

General measures

- ❖ Photoprotection.
- ❖ Reassurance.

Localized lesions

- ❖ **Topical steroids:** Initiate with potent steroids³ followed by moderately potent steroids (for maintenance).
- ❖ **Intralesional steroids:** If lesions do not respond to topical steroids, treat with intralesional triamcinolone acetonide (10 mg/ml diluted to 2.5 mg/ml).

3. **Potent steroids:** DLE is one of the few conditions warranting use of potent topical steroids on face.

Extensive lesions

Patients with extensive lesions need systemic therapy with:

❖ **Antimalarials:**

- Systemic antimalarials such as hydroxychloroquine (expensive, but less toxic) and chloroquine (cheap, more toxic) may be needed.
- Prior to initiation of therapy with antimalarials, a baseline ophthalmological examination is necessary because these drugs rarely do cause irreversible retinal damage.

❖ **Others:**

- Oral steroids.
- Thalidomide.
- Dapsone.

Subacute Cutaneous Lupus Erythematosus

Synopsis

Etiology: Autoimmune. Both UVA and B rays incriminated.

Morphology: Two main types of skin lesions; commoner nonscarring papulosquamous plaques and less common polycyclic lesions.

Sites: Neck, trunk, forearms, and face.

Visceral involvement: Nephritis and neurological involvement only in 10%.

Investigations: Sixty percent have antibodies to cytoplasmic antigen Ro/SS-A.

Treatment: Photoprotection. Antimalarials, steroids, and immunosuppressives.

Etiology

Cause of subacute cutaneous lupus erythematosus (SCLE) is unknown, but many mechanisms have been postulated.

- ❖ **Autoimmune:** Involves an antibody-dependent cellular cytotoxic attack on basal cells by K cells bridged by Ro-SS-A antigen.
- ❖ **Genetic:** Since strongly associated with HLA-B8, DR3 haplotype may reflect a genetic predisposition to production of anti-Ro/SS-A antibodies.
- ❖ **Ultraviolet rays:** Both UVA and UVB rays incriminated.

Epidemiology

- ❖ **Incidence:** Comprises about 10% of patients with LE.

❖ **Age:** Peak incidence in fifth decade.

❖ **Gender:** Female preponderance.

Clinical Features

Cutaneous lesions

Morphology

Two types of cutaneous lesions are seen:

- ❖ Nonscarring papulosquamous plaques, in two-thirds of patients (Fig. 13.6A).
- ❖ Annular, polycyclic lesions, in one-third of patients (Fig. 13.6B).

Sites of predilection

Lesions are seen above the waist, particularly around the neck, trunk, and dorsolateral aspect of forearms. Facial lesions less frequent.

Associations

- ❖ Photosensitivity.
- ❖ Diffuse nonscarring alopecia.
- ❖ Arthritis.
- ❖ Fever.

Course

- ❖ Course of SCLE is chronic. The lesions are slow to heal but on healing do not leave behind depigmentation or scarring (*cf.*, DLE).
- ❖ 15–20% of patients with SCLE develop acute cutaneous LE (ACLE) or classic DLE-like lesions.

Complications

About 50% patients meet the criteria for SLE. However, systemic manifestations of SLE such as nephritis and central nervous system disease develop only in 10% of patients.

Investigations

- ❖ **Biopsy:** For histopathological and immunopathological confirmation.
- ❖ **Serological studies:** Sixty percent of patients have antibodies to cytoplasmic antigen Ro/SS-A.
- ❖ **Ruling out systemic involvement:** Evaluation to rule out systemic involvement should be done.

Diagnosis

Points for diagnosis

The diagnosis of SCLE is based on:

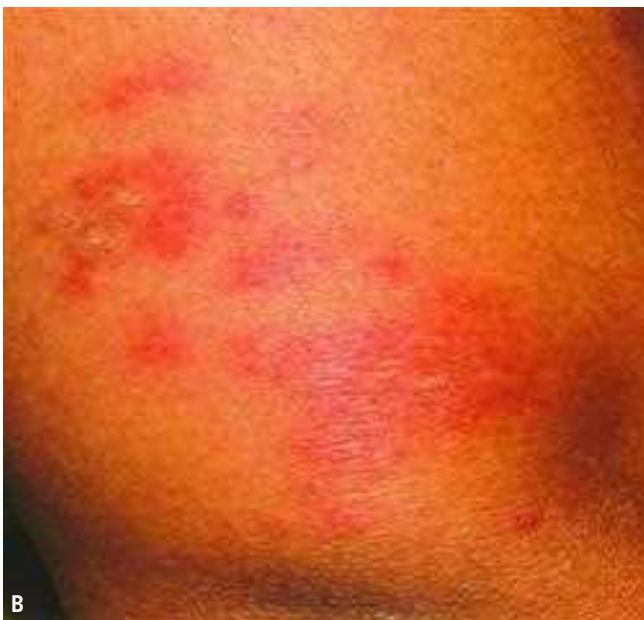
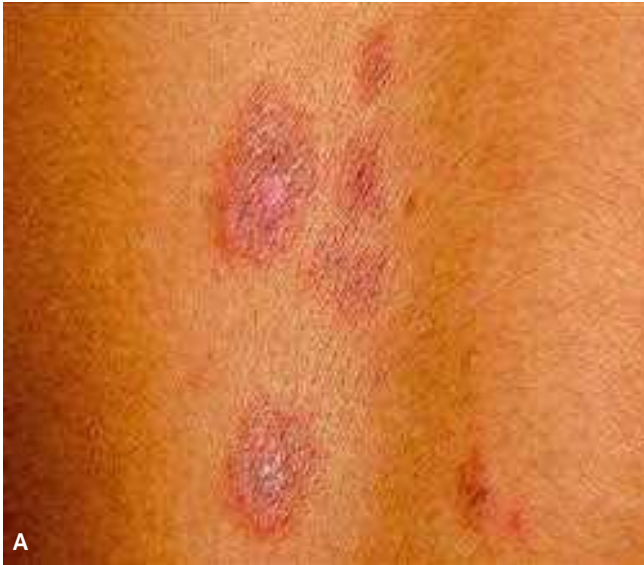
Fig. 13.6. Subacute cutaneous lupus erythematosus: A: nonscarring papulosquamous plaques on the trunk. B: annular and polycyclic lesions

- ❖ Presence of either papulosquamous plaques or annular polycyclic lesions.
- ❖ Lesions on neck, trunk, and dorsolateral aspect of forearms and less frequently face.
- ❖ Presence of antibodies against Ro/SS-A.

Differential diagnosis

SCLE should be differentiated from:

a. DLE

DLE	SCLE
<i>Morphology:</i> annular lesions with central scarring and depigmentation	Annular papulosquamous lesions with central hypopigmentation but no scarring
<i>Induration:</i> present	Less
<i>Scales:</i> adherent scales with keratotic spikes on the under surface	Psoriasiform scales, <i>i.e.</i> , loose scales
<i>Sequelae:</i> scarring and depigmentation	No sequelae
<i>Distribution:</i> face, ears	Neck, upper trunk, forearms. Less frequently face
<i>Constitutional symptoms:</i> infrequent	Often present

Treatment

- ❖ Photoprotection.
- ❖ Antimalarials such as hydroxychloroquine are needed in the acute phase.
- ❖ Systemic steroids need to be given, if the patient does not respond to antimalarials.

Systemic Lupus Erythematosus (SLE)

Synopsis

Etiology: Autoimmunity, genetic predisposition, and triggered by UVR.

Skin lesions: Malar rash, DLE-like lesions, photosensitivity, oral lesions, and lupus hair.

Sites: Photo-exposed parts.

Systemic involvement: Polyarthritis, nephritis, psychosis.

Investigations: Characteristic histopathology. Positive lupus band test. Antinuclear antibodies in all patients. Antibodies to dsDNA in 70% of patients.

Treatment: Aggressive photoprotection. Antimalarials for cutaneous disease. Oral steroids and immunosuppressives, if systemic involvement.

Etiology

- ❖ **Autoimmunity:** Presence of antibodies to DNA, to nuclear proteins and other cellular antigens indicates an autoimmune pathogenesis.
- ❖ **Genetic:** Predisposition is suggested by:
 - Association with MHC class II DR genes (HLADR 2 and DR3).
 - Concordance in monozygotic twins.
 - Association of LE-like lesions with inherited deficiency of complement.

❖ **Triggers:**

- **Ultraviolet radiation:** exposure to sunlight or artificial light is frequently associated with aggravation of lesions.
- **Drugs:**
 - Several drugs (procainamide, hydralazine, isoniazid, chlorpromazine, and dilantin) are implicated in inducing SLE.
 - Skin lesions are infrequent in drug-induced LE.
- **Viral infections:**
 - The role of viral infections in pathogenesis of SLE is not clear.
 - Virus-like particles have been demonstrated in endothelial cells of lesional skin by electron microscopy.
 - Viral infections may exacerbate SLE.

Clinical Features*Cutaneous lesions**Morphology*

- ❖ **LE-specific lesions:** LE-specific lesions seen include:
 - Butterfly rash in the form of erythema and edema on the malar area and nose (Figs. 13.7A and B) with characteristic sparing of nasolabial folds.
 - Papulosquamous lesions on photo-exposed parts. Lesions on dorsae of fingers usually spare the skin over the knuckles (Fig. 13.8A)
 - DLE-like discoid lesions.
 - Photosensitivity.
- ❖ **LE nonspecific lesions**
 - **Vascular lesions:**
 - Periungual telangiectasia and ragged cuticles.
 - Vasculitic lesions.
 - Raynaud's phenomenon and sclerodactyly.
 - **Oral ulcers.**
 - **Alopecia:** especially at the frontal margin of the scalp (Fig. 13.8B); the hair is lusterless, short and broken (**lupus hair**).

Sites of predilection

Lesions are seen mainly on the photo-exposed parts (Fig. 13.9).

Systemic features

- ❖ Constitutional symptoms like fever.
- ❖ Systemic features (Table 13.3).

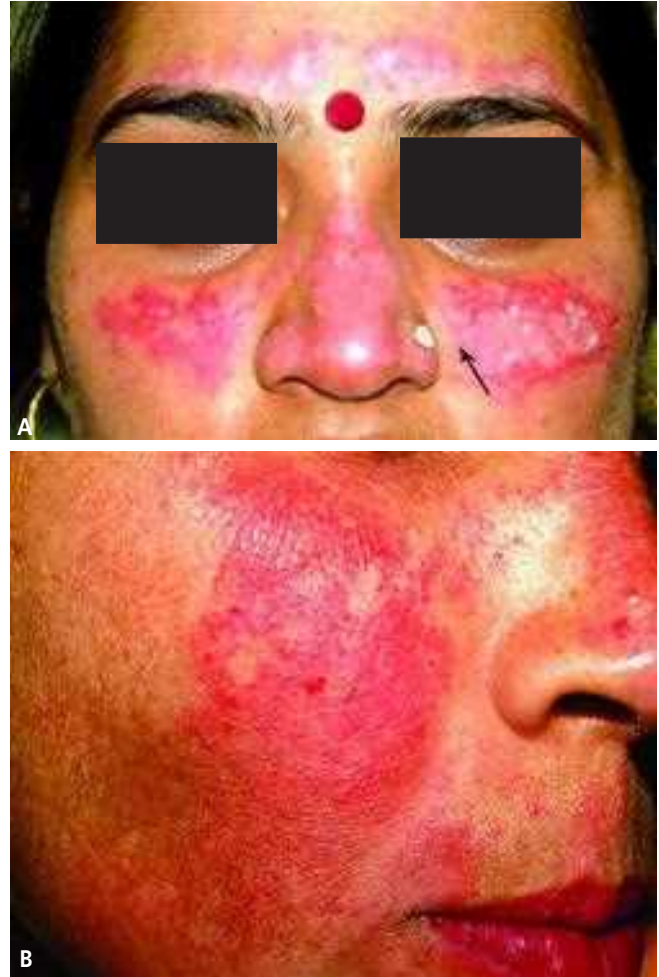

Fig. 13.7. Systemic lupus erythematosus: A: butterfly rash, characterized by edema, erythema, and scaling. B: butterfly rash characterized by erythema, edema, and telangiectasia. Note conspicuous sparing of nasolabial folds in both patients.

Course

- ❖ Skin lesions may be transient, recurrent or run a prolonged course and are a good reflection of the systemic activity of the disease.
- ❖ Common causes of morbidity are renal dysfunction, cardiac and respiratory complications, and arthritis.

Complications

- ❖ Renal involvement causes morbidity and may be fatal.
- ❖ Other organ dysfunction may also lead to morbidity and mortality.
- ❖ Children born to affected mothers (with active or quiescent disease) are liable to develop **neonatal LE** with transient, annular skin lesions, and complete heart block.

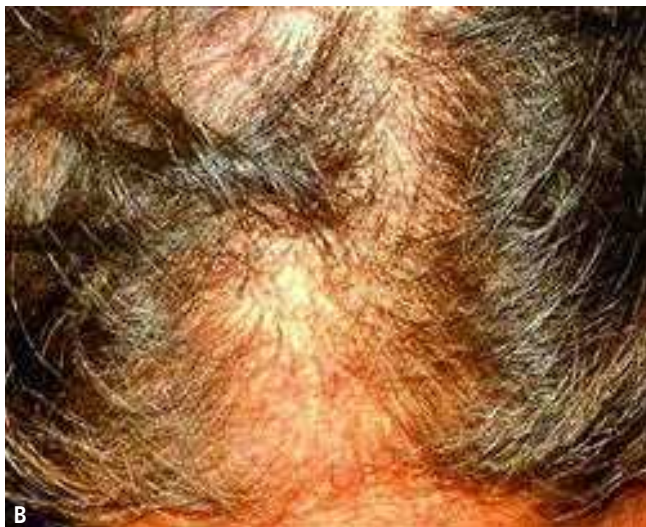
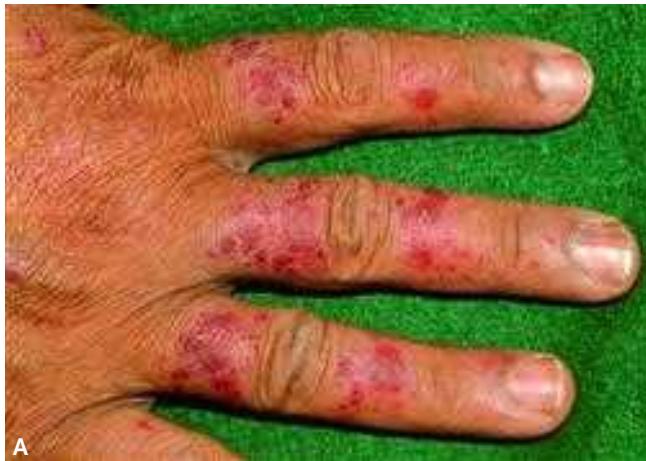
Fig. 13.8. Systemic lupus erythematosus: A: lesions on dorsae of digits sparing knuckles. B: lupus hair which is short, lusterless hair in the frontal area.

Investigations

In a patient suspected of having SLE, investigations need to be done to:

- ❖ Confirm diagnosis of SLE.
- ❖ Determine extent of organ involvement.

Confirming diagnosis of SLE

Biopsy

Both histopathological and immunohistological findings in SLE are distinctive.

- ❖ **Histopathology:** Skin biopsy shows characteristic changes (Fig. 13.10A).
- ❖ **Immunohistology:** Direct immunofluorescence studies show (Fig. 13.10B):

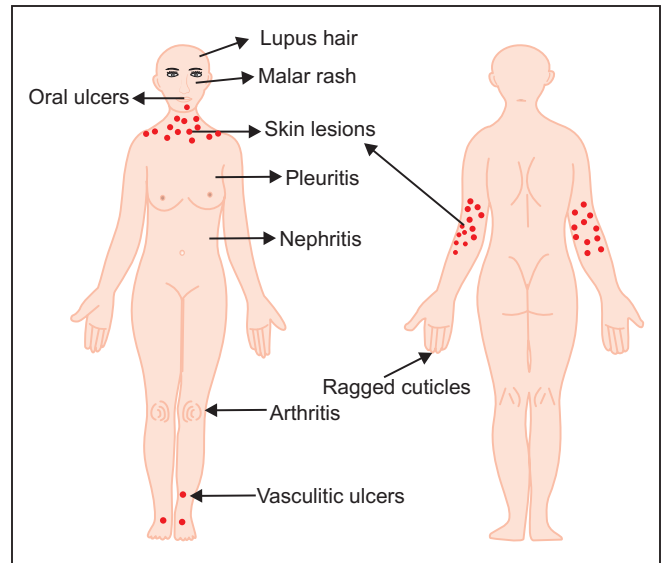


Fig. 13.9. Systemic lupus erythematosus: common manifestations.

Table 13.3. Simplified criteria for diagnosing SLE

Criteria*	Explanation
Malar rash	Fixed erythema over the malar eminences; spares nasolabial folds
Discoid rash	DLE-like lesions
Photosensitivity	Skin rash
Oral ulcers	Usually painless
Arthritis	Nonerosive arthritis
Serositis	Pleuritis, pericarditis
Renal disease	Persistent proteinuria, cellular casts
Neurological disease	Seizures, psychosis
Hematological disease	Hemolytic anemia, leukopenia, lymphopenia, thrombocytopenia
Immunological disease	Anti-DNA antibody, anti-Sm antibody or persistent (>6 months) serological test for syphilis.
Antinuclear antibodies (ANA)	Abnormal titer of ANA by immunofluorescence

* Four of these should be present simultaneously or serially.

- Deposition of IgG in a band-like pattern at the dermoepidermal junction in lesional skin and often in the nonlesional skin (**lupus band test**). IgM, IgA, and C3 may also be found individually or together. A positive **lupus band test**⁴ is diagnostic of LE.

4. **Lupus band test:** (LBT): conventionally, LBT is said to be positive if immunoreactants are deposited in linear band at dermoepidermal junction in nonlesional skin.

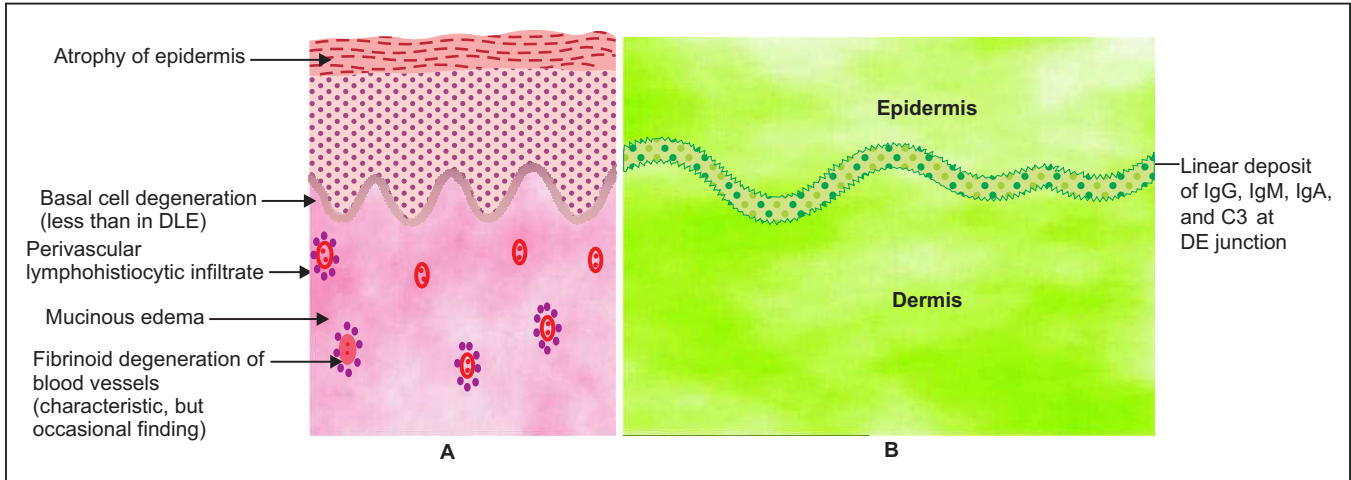


Fig. 13.10. Systemic lupus erythematosus: A: histopathology characterized by atrophy of epidermis, basal cell degeneration (which is less than in DLE), perivascular lymphocytic infiltrate, and typically fibrinoid degeneration of vessels and upper dermal mucinous edema. B: immunohistology characterized by linear deposit of IgG, IgM, IgA, and C3 at dermoepidermal junction and perivascularly.

- Presence of lupus band test in uninvolved skin from covered parts of body (e.g., buttocks) generally indicates renal involvement.

Serology

Antibodies to a variety of cellular and nuclear antigens are present in SLE (Table 13.2):

- ❖ **Antinuclear antibodies (ANA)**
 - ANA are antibodies to nuclear proteins.
 - High titers of ANA are present in SLE.
 - A variety of patterns of ANA are described. Some of these patterns are seen in other connective tissue diseases as well (Table 13.3).
 - Peripheral: Characteristic of SLE.
 - Homogeneous: Also seen in DLE, and SCLE.
 - Speckled: Also seen in DLE, SCLE, systemic sclerosis, and mixed connective tissue disease
 - Nucleolar: Usually not seen in SLE, but in systemic sclerosis.
- ❖ **Antibodies to double-stranded DNA (dsDNA)**
 - Antibodies to dsDNA are seen in 70% of patients with SLE and 10% with SCLE.
 - Are specific for SLE. Not seen in drug-induced LE and other autoimmune connective tissue diseases.
- ❖ **Other serological markers**
 - Antibodies to extractable nucleic acid (Sm) in 30%.

- Antibodies to histones are seen in **drug-induced LE**⁵.
- Hypocomplementemia (total and C3).

Presence of ANA, antibodies to dsDNA and low levels of total complement are characteristic of SLE.

Establishing the extent of disease

Tests should be done to rule out internal organ involvement (Table 13.4).

Table 13.4. Laboratory findings in SLE

Hematological tests	Anemia Leukopenia Thrombocytopenia ↑ ESR ⁶
Urine	Proteinuria Hematuria Cellular casts
Renal function tests	↑ Blood urea and creatinine ↑ 24 h urinary protein
Liver function tests	
X rays	
<i>Chest:</i>	Pleural thickening, infiltration of lung and reticulation
<i>Joints:</i>	Soft tissue swelling
<i>Contrast studies of gut</i>	

5. **Drug-induced LE:** drugs known to precipitate LE include procainamide, hydralazine, isoniazid, chlorpromazine, and dilantin.
 6. **ESR:** elevated in all autoimmune connective tissue disorders in an active disease except systematic sclerosis.

Diagnosis

Points for diagnosis

A simplified version of American Rheumatological Association criteria for diagnosis of SLE is shown in Table 13.2.

Differential diagnosis

SLE should be differentiated from:

a. Polymorphous light eruption (PMLE)

PMLE	SLE
Morphology: itchy, eczematous plaques	Persistent, fixed erythema over malar area or discoid rash. Other types of skin lesions also seen
Oral lesions: absent	Frequently present
Constitutional symptoms: infrequent	Frequent
Arthritis: absent	Frequent
Antibodies: ANA, antibodies to dsDNA negative	Positive

b. Dermatomyositis

Dermatomyositis	SLE
Facial lesions: periorbital heliotrope	Malar rash
Hand lesions: Gottron's papules on knuckles typical	Lesions on skin between knuckles
Proximal muscle weakness: prominent	May be present
ANA: infrequently positive	Invariably positive

c. Other connective tissue diseases

Like mixed connective tissue disease should be differentiated.

Treatment

Photoprotection

- ❖ Avoidance of exposure to sunlight especially at **noon**⁷ is important.
- ❖ **Sunscreens**⁸ (with efficient UVA blocking agent) should be advocated in all patients.
- ❖ Wearing of tightly woven clothing and broad rimmed hats.

Symptomatic treatment

Symptomatic treatment is necessary with:

- ❖ Antihypertensives : For hypertension.
- ❖ Anticonvulsants : For seizures.
- ❖ NSAIDs : For arthritis.

Antimalarials

- ❖ Chloroquine (4 mg/kg) and hydroxychloroquine (6.5 mg/kg) are the drugs of choice for cutaneous disease.
- ❖ Baseline and six-monthly ophthalmological check up and routine hematological and liver function evaluation mandatory.

Corticosteroids

- ❖ Systemic steroids, even large doses, needed in presence of organ dysfunction.
- ❖ Can be given daily or as “monthly pulse therapy” of either methylprednisolone, betamethasone, or dexamethasone.
- ❖ Dose tapered as the disease responds.

Immunosuppressive agents

- ❖ Immunosuppressive agents, like cyclophosphamide (2–3 mg/kg/day), azathioprine (1.5 mg/kg/day), and methotrexate (7.5–25 mg/week), used as adjuncts and steroid sparing agents, in the presence of progressive renal and other organ involvement. Dose reduced after initial disease control (6 weeks).
- ❖ Bolus cyclophosphamide drug of choice for renal involvement.

Dermatomyositis

Synopsis

Etiology: Autoimmune disorder.

Subtypes: Two subtypes; a self-limiting (though deforming) juvenile variety and a progressive adult variety which may be associated with internal malignancies.

Skin lesions: Periorbital heliotrope erythema, Gottron's papules and Gottron's sign, periungual telangiectasia. Calcinosis in the juvenile variety.

Systemic involvement: Proximal myositis, cardiomyopathy, and joint involvement.

Investigations: Look for evidence of muscle involvement (increased levels of CPK and aldolase; EMG and histopathological evidence of myositis). ANA may be negative. Look for internal neoplasia in the middle-aged and elderly, but not in children. Skin biopsy not diagnostic.

Treatment: Steroids form the mainstay of therapy along with immunosuppressives (methotrexate and azathioprine), especially for myositis, because of steroid sparing effect.

7. **Noon sun:** the midnoon Sun is the strongest because the distance traversed by rays is shortest, so the dissipation of energy is least.
 8. **Sunscreens:** sunscreens should be applied regularly at 3–4 h intervals to be effective. We generally recommend application of sunscreen at 8 AM, 12 noon, and 4 PM. Remember fluorescent tubes and energy saving lights, which are frequently used for lighting, emit UVA. So, sunscreens need to be used even after sunset, and even when indoors.

Dermatomyositis is a disease characterized by autoimmune inflammatory injury to striated muscle and skin.

Etiology

- ❖ Etiology and pathogenesis of dermatomyositis are unknown.
- ❖ **Genetically determined autoimmune response:** Inflammatory nature of muscle and skin changes coupled with humoral autoimmune abnormalities suggests that DM may be a genetically determined aberrant autoimmune response to environmental agents, *e.g.*, a myotropic virus.

Epidemiology

- ❖ **Incidence:** Rare.
- ❖ **Age:** Two peak incidences are seen:
 - *Childhood variant:* seen in children less than 10 years of age.
 - *Adult variant:* seen between ages of 40–60 years.
- ❖ **Gender:** Females affected twice as frequently as males.

Clinical Features

Cutaneous Features

- ❖ Severely itchy lesions.
- ❖ **Heliotrope⁹ erythema:** Faint lilac erythema, periorbitally (Fig. 13.11), usually associated with edema.

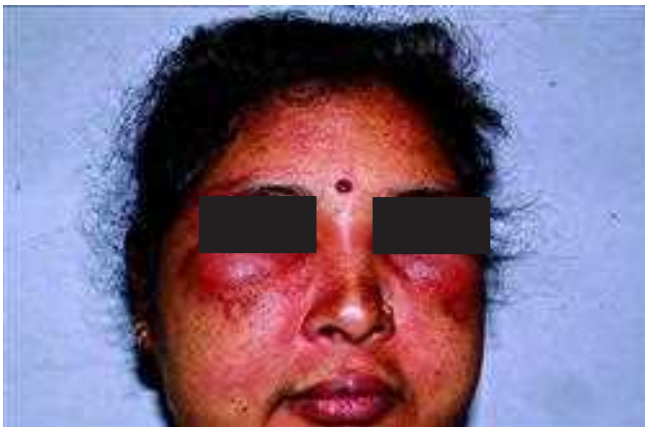

Fig. 13.11. Dermatomyositis: periorbital edema and faint lilac erythema (heliotrope erythema).

- ❖ **Gottron's papules:** Violaceous, atrophic papules over the knuckles and pressure points (Fig. 13.12A).
- ❖ **Gottron's sign:** Symmetrical, lilac erythema and edema over interphalangeal or metacarpophalangeal joints, elbows, and knees (Fig. 13.12B).
- ❖ Nail fold telangiectasia and cuticular hemorrhages.
- ❖ Malar erythema and edema (less frequent than in SLE).
- ❖ **Poikiloderma:** Hyperpigmentation, hypopigmentation, telangiectasia, and atrophy (Fig. 13.13).

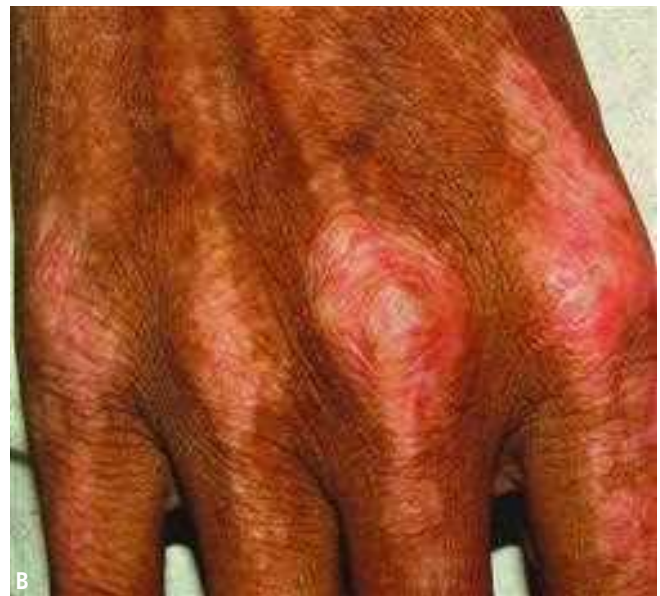
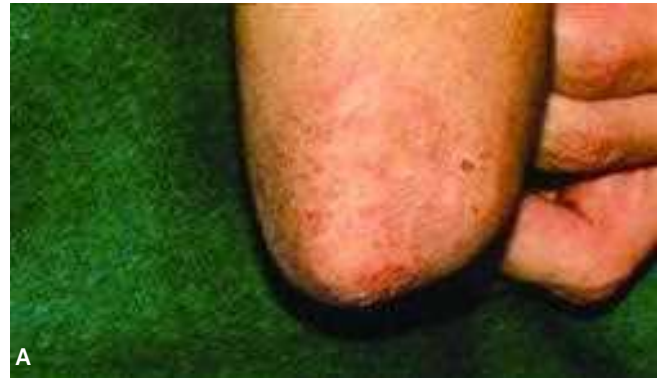
Fig. 13.12. Dermatomyositis: A: Gottron's papules: atrophic papules on the joints. B: Gottron's sign: erythema on the joints. Sometimes the lesions are linear.

9. **Heliotrope:** also a lilac-colored flower.

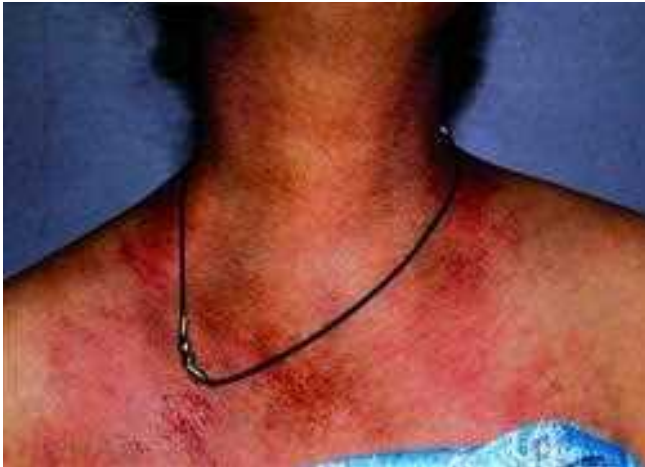

Fig. 13.13. Dermatomyositis: poikiloderma (telangiectasia, atrophy and hyperpigmentation) on the neck.

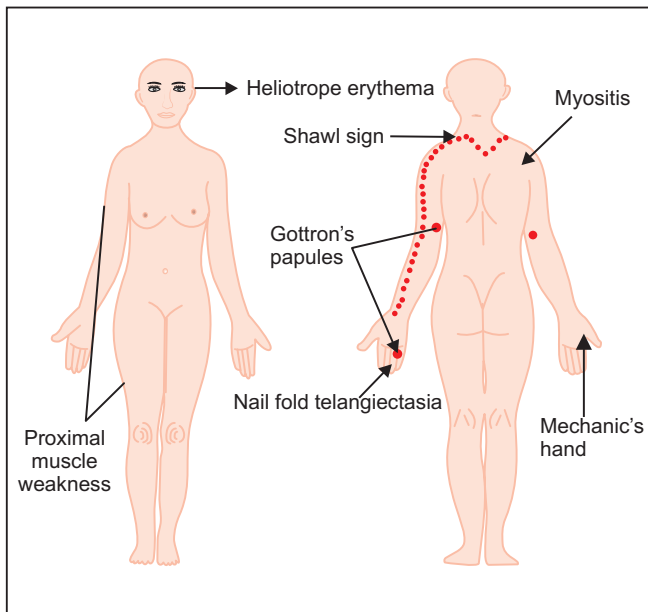


Fig. 13.14. Dermatomyositis: cutaneous manifestations.

- ❖ **Shawl sign:** Symmetrical confluent violaceous erythema extending from dorsolateral aspect of hands, forearms and arms to deltoid region, shoulders, and neck (Fig. 13.14).
- ❖ **Mechanic's hand:** Confluent symmetric hyperkeratosis along ulnar aspect of thumb and radial aspect of fingers.

- ❖ **Calcinosis cutis:** Seen only in the juvenile variant, this is the presence of hard calcium deposits in the skin.

Systemic Features

- ❖ **Myositis:** Presents as a symmetrical weakness of **proximal muscles**¹⁰. In long-standing cases, contractures develop. Calcinosis can occur in juvenile dermatomyositis.
- ❖ **Difficulty in speech and swallowing.**
- ❖ **Cardiomyopathy.**
- ❖ **Raynaud's phenomenon.**
- ❖ **Arthralgia.**
- ❖ **Malignancies:** One-third of adult patients with dermatomyositis have an underlying malignancy in form of carcinoma of lungs, ovaries, and breasts.

Course

Childhood variant

- ❖ Self-limiting disease.
- ❖ May be complicated by contractures of muscles and calcinosis cutis.

Adult variant

- ❖ Prolonged, progressive course unless treated adequately.
- ❖ In one-third of patients, an underlying malignancy may be associated. Onset of dermatomyositis in such cases may coincide with onset of the tumor and may improve when the tumor is removed.

Investigations

Confirming Diagnosis of Dermatomyositis

Skin biopsy

Skin biopsy from Gottron's papules is not diagnostic.

Myositis

Involvement of muscles is confirmed by:

❖ Biochemical markers:

- **Muscle enzymes:** elevated levels of circulating muscle enzymes such as creatine phosphokinase (most specific and sensitive), serum aldolase, SGOT, SGPT, and LDH.
- **Urinary creatine:** is elevated.

10. **Proximal muscle weakness:** patients complain of difficulty in getting up from squatting position and climbing stairs (due to weakness of lower girdle muscles) and combing hair (due to weakness of shoulder muscles).

- ❖ **Electromyography.**
- ❖ **Muscle biopsy**¹¹: Shows muscle inflammation, destruction of muscle fibers, and later fibrosis.

Serology

Antinuclear antibodies (speckled) are positive in 20% of patients.

Looking for Underlying Malignancy

- ❖ One-third of adult patients with dermatomyositis have an underlying malignancy. So they should be evaluated accordingly.
- ❖ The most frequent associations are carcinoma of lung (males), ovary and breast (females).

Diagnosis

Points for diagnosis

The diagnosis of dermatomyositis is based on the criteria shown in Table 13.5.

Differential Diagnosis

Dermatomyositis (DM) should be differentiated from:

- SLE (P. 227)*
- Systemic sclerosis (SSc)*

SSc	DM
<i>Reynaud's phenomenon</i> : very frequent	Less frequent
<i>Face</i> : binding down, beaking nose, matt like telangiectasia	Heliotrope rash
<i>Acral parts</i> : sclerodactyly, resorption of digits, finger tip ulcers.	Gottron's papules and sign
<i>Systemic involvement</i> : lungs, gut, kidneys	Less frequent. Muscle involvement present.

c. Steroid-induced myopathy

- ❖ Myopathy may be induced/aggravated by systemic steroids.
- ❖ If in doubt, steroid dose is doubled; if the myopathy improves, the muscle weakness was due to disease but if the weakness increases, it is due to steroids.

Table 13.5. Criteria for diagnosis of dermatomyositis

Diagnostic criteria	
❖ Typical skin rash.	
❖ Symmetric proximal muscle weakness with or without dysphagia or respiratory muscle involvement.	
❖ Abnormal muscle biopsy specimen.	
❖ Elevation of skeletal muscle-derived enzymes.	
❖ Abnormal electromyogram.	
Confidence limits for diagnosis of dermatomyositis	
Definite dermatomyositis	Rash and three other diagnostic criteria.
Probable dermatomyositis	Rash and two other diagnostic criteria.
Possible dermatomyositis	Rash and one other diagnostic criteria.

Treatment

General Measures

- ❖ Rest initially; physiotherapy to prevent contractures.
- ❖ Protection from sunlight.
- ❖ Antihistamines, for itching.

Systemic Steroids

- ❖ Mainstay of therapy. Early institution of steroid therapy is associated with better prognosis.
- ❖ **Dose:** Given as daily doses (1 mg/kg/day of prednisolone equivalent). Or as monthly pulses (betamethasone or dexamethasone, 100 mg for three consecutive days). Most patients on daily doses need 1–3 months of treatment with full doses. The dose is then tapered to maintenance dose.
- ❖ **End point of therapy:** Improvement of muscle strength, normalization of muscle enzyme levels and improvement in cutaneous inflammation.

Immunosuppressives

A quarter of the patients with dermatomyositis need immunosuppressives.

Drugs used

- ❖ **Methotrexate:** 10–25 mg/week.
- ❖ **Azathioprine:** 1–2 mg/kg/day.
- ❖ **Cyclosporine:** 5 mg/kg/day.

11. **Muscle biopsy:** it is best to do muscle enzymes then electromyography and then do muscle biopsy.

Indications

- ❖ Myositis: Responds to methotrexate.
- ❖ Dermatomyositis not responding to conventional doses of steroid (as steroid sparing agents).

Scleroderma

Etiology

- ❖ Scleroderma is a chronic disease of unknown etiology that affects the microvasculature and loose connective tissue.
- ❖ It is characterized by fibrosis and obliteration of vessels in the skin, lungs, gastrointestinal tract, kidneys, and heart.
- ❖ It may occur in a localized form or as a systemic disease.

Classification (Table 13.6)

Table 13.6. Classification of scleroderma

Systemic scleroderma
<ul style="list-style-type: none"> ❖ Limited systemic sclerosis (lSSc) ❖ Diffuse systemic sclerosis (dSSc)
Localized scleroderma
<ul style="list-style-type: none"> ❖ Localized morphea ❖ Linear morphea ❖ Morphea profundus ❖ Generalized morphea

Systemic Sclerosis (SSc)

Synopsis

Etiology: Unknown. Autoimmune pathogenesis most likely. Exposure to chemicals (silica, polyvinyl chloride) and drugs (bleomycin) can result in SSc-like disease.

Variants: Limited systemic sclerosis (lSSc), diffuse systemic sclerosis (dSSc).

Skin manifestations: Raynaud's phenomenon, binding down of skin, fingertip ulcers, gangrene of digits, telangiectasia and dyschromia.

Systemic manifestations: Arthritis, pulmonary fibrosis, esophageal dysmotility and renal involvement.

Cause of death: Renal failure and respiratory failure.

Investigations: Skin biopsy, presence of anticentromere antibody (in lSSc), and Scl-70 (in dSSc), chest X ray, pulmonary function tests and upper gut contrast studies.

Treatment: Unsatisfactory. Vasodilators for Raynaud's phenomenon. D-penicillamine for skin binding. Corticosteroids and immunosuppressives (methotrexate, cyclophosphamide) for other organ involvement.

Etiology

Though etiology of SSc disease is not known, factors which may be important include:

- ❖ Endothelial injury.
- ❖ Increased synthesis of collagen by fibroblasts, leading to fibrosis.

Several pathogenic mechanisms have been postulated for these changes:

- ❖ **Immunological injury:** Is the most likely mechanism because of:
 - Frequent association with other autoimmune diseases like SLE and dermatomyositis as also overlap of signs and symptoms with these diseases.
 - Presence of autoantibodies like ANA (in 60–70% of patients), anticentromere antibodies (ACA) and Scl 70.
- ❖ **Chemical injury:** Changes similar to SSc may be seen with:
 - *Occupational exposure:* to polyvinyl chloride, silica, chloroethylenes, and other organic solvents.
 - *Drugs:* bleomycin.
- ❖ **Miscellaneous causes:** Sclerosis similar to SSc is also seen in the following conditions:
 - *Graft vs host reaction:* e.g., after bone marrow transplant.
 - *Exposure to occupational vibrations:* e.g., use of drill machines.

Epidemiology

- ❖ **Incidence:** More frequent than SLE and dermatomyositis.
- ❖ **Age:** Any age, but uncommon in children. Most frequent after age of 40.
- ❖ **Gender:** Four times more common in females. In males seen most frequently in coal miners.

Clinical Features

Onset

Begins with nonpitting edema of hands and feet associated with Raynaud's phenomenon and skin changes which progress at different rates.

Skin manifestations

Raynaud's phenomenon

- ❖ Most frequent and earliest symptom.
- ❖ Characterized by pallor, cyanosis and finally hyperemia of finger tips and toes on exposure to cold.

- ❖ Worse in winter (logical!).
- ❖ Eventually leads to:
 - Finger tip stellate ulcers (Fig. 13.15A).
 - Loss of finger pulp.
 - Gangrene.

Binding down

- ❖ Preceded by a phase of edema of hands and feet.
- ❖ Skin feels indurated and stiff and is difficult to pinch.
- ❖ Begins from acral parts and progresses proximally. Also involves face, neck and less frequently trunk.

- ❖ Leads to sclerodactyly¹² and contractures in acral parts (Fig. 13.15B).

Changes in facial features (Fig. 13.15B)

- ❖ Mask-like (expressionless) face.
- ❖ Smoothing of normal facial lines (Fig. 13.16A).
- ❖ Mat-like telangiectasia (Fig. 13.16B).
- ❖ Beaking of nose.
- ❖ Thinning of lips.
- ❖ Difficulty in opening of mouth.
- ❖ Radial furrowing around mouth (Fig. 13.17).

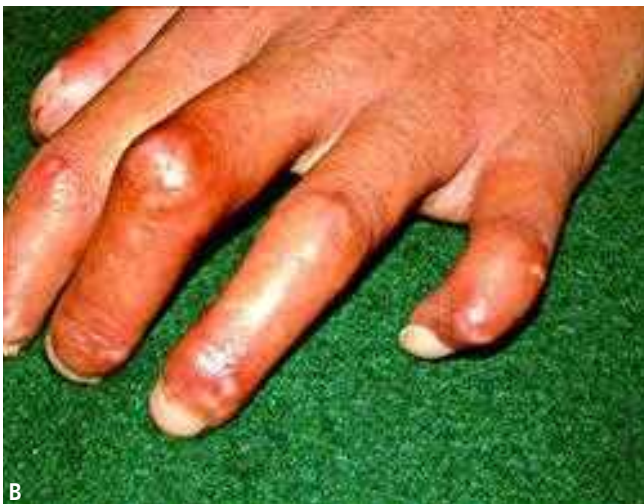
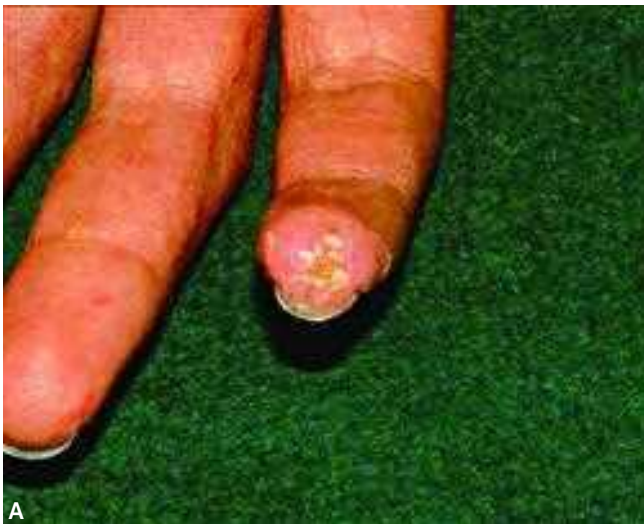
Fig. 13.15. Systemic sclerosis: A: finger tip stellate ulcers. B: sclerodactyly and contractures.

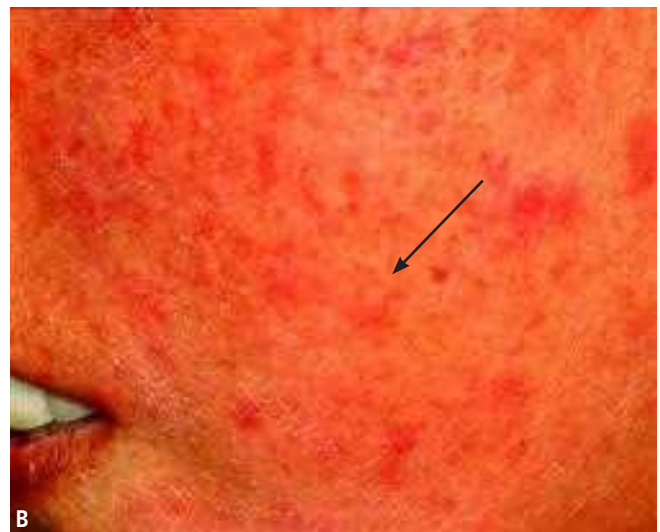
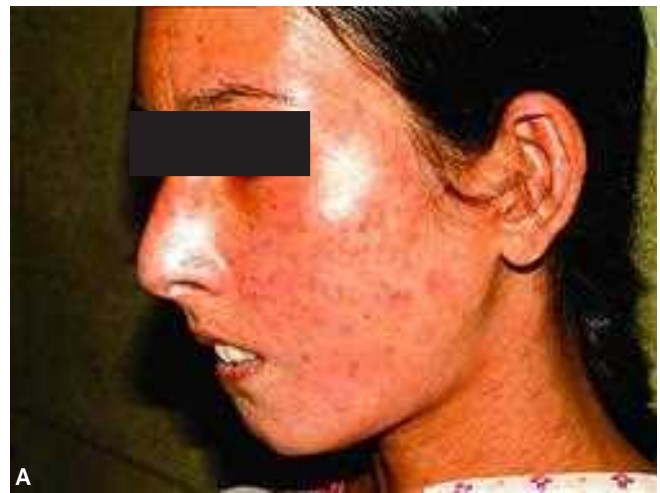
Fig. 13.16. Systemic sclerosis: A: facies which is characterized by smoothing of facial lines, beaking of nose, thinning of lips. B: mat-like telangiectasia.

12. **Sclerodactyly:** localized thickening and tightness of skin of digits.

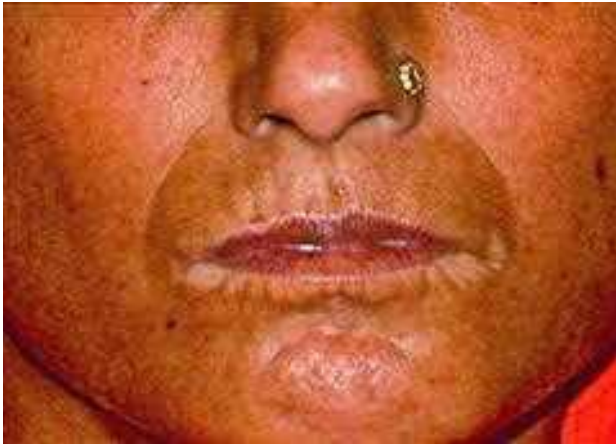

Fig. 13.17. Systemic sclerosis: perioral radial furrows.

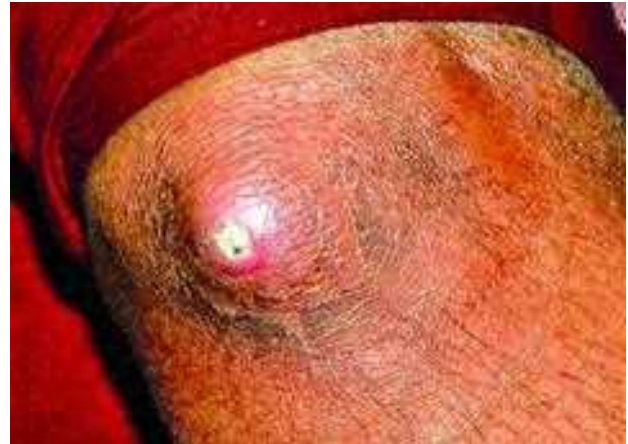

Fig. 13.18. Systemic sclerosis: calcinosis cutis in which white chalky material extrudes. Usually occurs on bony prominences.

Miscellaneous skin changes

- ❖ **Salt-pepper dyschromatosis**, manifesting as combination of punctate hypopigmentation and hyperpigmentation
- ❖ Generalized pigmentation.
- ❖ Periungual telangiectasia.
- ❖ Calcinosis cutis on elbows, knuckles, and malleoli (Fig. 13.18).

Systemic manifestations

Gastrointestinal system

- ❖ Reflux esophagitis, due to loss of tone of the esophageal sphincter, is the most common systemic complaint.
- ❖ Dysphagia, due to esophageal dysmotility is also frequently encountered.
- ❖ Constipation, diarrhea, and malabsorption.

Musculoskeletal system

- ❖ Arthritis.
- ❖ Proximal muscle weakness.

Respiratory system

- ❖ Diffuse pulmonary fibrosis in dSSc and pulmonary hypertension in lSSc. Results in decreased diffusion capacity due to alveolitis and fibrosis.
- ❖ Manifests initially as exertional dyspnea, then dyspnea at rest but symptoms poor predictors of lung function.
- ❖ Radiological investigation of choice for pulmonary fibrosis is high-resolution CT scan.

Pulmonary function abnormalities (especially diffusion capacity) more sensitive than chest X ray. Also indicator of prognosis.

Cardiac involvement

- ❖ In 50–70% of patients.
- ❖ Conduction defects and pericarditis. Right ventricular hypertrophy due to pulmonary hypertension.

Renal involvement

- ❖ In 50% of patients.
- ❖ May eventually lead to renal failure.

Variants

CREST syndrome

Variant of SSc with better prognosis. Manifests with:

- ❖ **C**alcinosis cutis.
- ❖ **R**aynaud's phenomenon.
- ❖ **E**sophageal dysmotility.
- ❖ **S**clerodactyly.
- ❖ **T**elangiectasia: On hands, face, upper trunk, and even mucosae.
- ❖ ACA more frequently seen, while Scl-70 less frequently seen.
- ❖ Treat with peripheral vasodilators.

Course

Two clinical subsets of SSc with different prognosis recognized:

Diffuse SSc (dSSc)	Limited SSc (lSSc)
<i>Progress:</i> onset of binding down of skin within 1 year of onset of Raynaud's phenomenon	Raynaud's phenomenon for years, before onset of scleroderma.
<i>Distribution:</i> truncal and acral involvement.	Restricted to acral parts and face.
<i>Pulmonary involvement:</i> early and significant pulmonary involvement in form of interstitial lung disease.	Late involvement of lungs in the form of pulmonary hypertension in 10%.
<i>Other features:</i> oliguric renal failure, diffuse gut involvement myocardial involvement	Skin calcification, telangiectasia. Gut involvement late.
<i>Nail folds:</i> capillary dilatation with drop outs.	Without capillary dropouts.
<i>Serology:</i> Scl-70 in 30% of patients.	ACA in 70% of patients.

Other prognostic features

- ❖ Males have a worse prognosis.
- ❖ Later onset disease indicates rapid down hill course.

Investigations

Confirming the diagnosis of SSc

Skin biopsy

Characteristically shows extensive sclerosis of dermis.

Serological findings

Antibodies present in SSc are:

- ❖ ACA: Indicative of lSSc.
- ❖ Scl-70: Indicative of dSSc.

Establishing extent of disease

Patients need to be investigated to find extent of involvement (Table 13.7).

Diagnosis

Points for diagnosis

Patients should fulfil the major criteria or at least two minor criteria for diagnosis.

- ❖ **Major criteria:** Scleroderma proximal to digits, affecting limbs, face, neck, or trunk.
- ❖ **Minor criteria:**
 - Sclerodactyly.
 - Digital pitted scarring.
 - Bilateral basal pulmonary fibrosis.

Table 13.7. Evaluation of a patient with systemic sclerosis

System	Investigations
Respiratory system	CXR high-resolution CT radiological investigation of choice Pulmonary function tests: lowered diffusion capacity.
Gastrointestinal system	Barium swallow: atonic dilated esophagus with air in resting stage Esophageal manometry, radionuclide transit very sensitive
Kidneys	Urine examination, 24-h urinary protein Blood urea, serum creatinine
Cardiovascular system	Electrocardiogram
Musculoskeletal system	X-rays of joints Muscle enzymes

Differential diagnosis

Diagnosis of SSc is usually not difficult but early SSc should be differentiated from:

- a. Sclerosis seen in porphyria cutanea tarda.
- b. Occupational scleroderma due to exposure to polyvinyl chloride monomers.
- c. Other causes of Raynaud's phenomenon.

Treatment

General measures

Avoidance of cold

An important prophylactic measure achieved by:

- ❖ Wearing gloves and socks even before onset of winter.
- ❖ Dipping hands and feet in warm saline several times a day. This produces significant symptomatic improvement and reduces number of episodes of Raynaud's phenomenon.
- ❖ Using warm water for personal and domestic chores (especially in winter).

Avoidance of smoking

Helps in Raynaud's phenomenon.

Symptomatic treatment

Raynaud's phenomenon

- ❖ Vasodilators improve blood flow in the acral parts, so they reduce frequency and severity of Raynaud's phenomenon. Sometimes esophageal symptoms worsen.

- ❖ Drugs used are:
 - Nifedipine, 20 mg three times daily.
 - Diltiazem, less frequently used.
 - Prostacyclin and iloprost, which are synthetic prostacyclin analogues, are useful in critically ischemic digits.

Reflux esophagitis

- ❖ Omeprazole and cisapride.
- ❖ If bacterial overgrowth, treat with broad-spectrum antibiotics.

Immunosuppressives

Steroids

- ❖ Can be used in small, daily doses. Or as monthly bolus dose (100 mg of either dexamethasone parenterally or betamethasone orally, for three consecutive days).
- ❖ Give symptomatic relief. Probably do not alter course.

Other immunosuppressives

- ❖ Methotrexate, azathioprine, cyclophosphamide, and cyclosporine.
- ❖ Used as steroid sparing agents and in aggressive visceral disease.

Others

D-penicillamine

- ❖ Interferes with cross-linking of collagen.
- ❖ Indicated in early aggressive dSSc.
- ❖ Given initially in daily dose of 250 mg, increased every 2–3 months up to 750–1500 mg/day.
- ❖ Treatment should be given for 1–2 years.
- ❖ Skin induration responds in many patients. It also retards pulmonary involvement; however, incidence of renal disease may increase.
- ❖ **Side effects:** Hematological abnormalities, appearance of autoimmune diseases (pemphigus) and nephrotic syndrome.

Morphea

Etiology

Unknown. Not associated with systemic symptoms.

Epidemiology

- ❖ **Prevalence:** Rare.

- ❖ **Gender:** Females affected three times more frequently.

- ❖ **Age:** Seventy five percent of patients have onset between 20 and 50 years.

Clinical Features

Morphology

- ❖ Circumscribed, indurated brown plaques with a lilac (looks hyperpigmented in dark skin) halo (Fig. 13.19). Sweating may be reduced on the lesion and hair may be absent.
- ❖ Usually single, may be multiple.

Site

Upper trunk, buttocks, and legs.

Variants

Linear scleroderma

- ❖ Linear indurated plaque(s).
- ❖ Lower extremities and upper extremities (Fig. 13.20A). Lesions on the fronto-parietal region

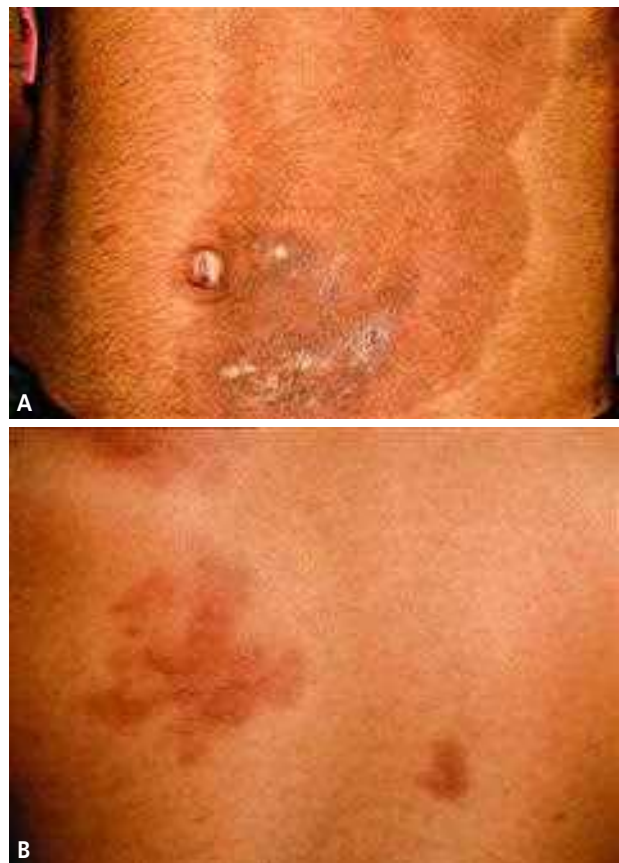

Fig. 13.19. Morphea: circumscribed indurated brown plaques. A: single large lesion. B: multiple small lesions.

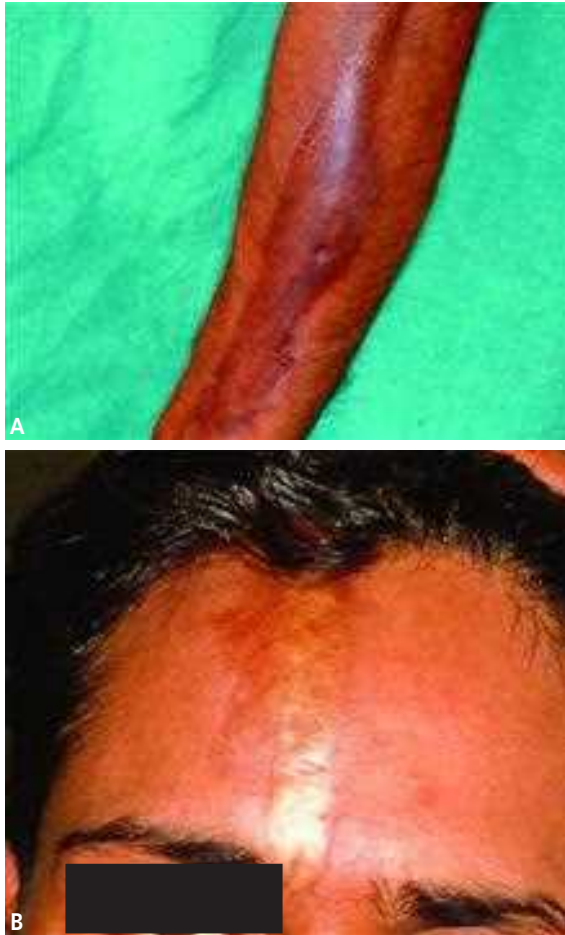

Fig. 13.20. Linear morphea: A: linear hyperpigmented indurated plaque on leg. B: linear atrophic plaque on the fronto-parietal region is called en coup de sabre.

result in a linear atrophic depression called **en coup de sabre**¹³ (Fig. 13.20B).

Morphea profundus

- ❖ Subcutaneous morphea.
- ❖ Appears as skin colored, indurated deep-seated plaque.

Generalized morphea

- ❖ Widespread, multiple plaques.
- ❖ Not associated with systemic disease.

Investigations

Biopsy

Shows dermal sclerosis and “apparent pulling up of appendages”.

Antinuclear antibodies

Only very infrequently present.

Diagnosis

Points for diagnosis

The diagnosis of morphea is based on:

- ❖ Circumscribed, indurated plaque(s) with lilac (hyperpigmented) halo.
- ❖ Trunk, buttocks.
- ❖ Typical histology.

Differential diagnosis

Morphea should be differentiated from:

a. Lichen sclerosis et¹⁴ atrophicus (LSA)

LSA	Morphea
<i>Morphology:</i> discrete small lesions which become confluent.	Indurated plaques
<i>Color:</i> ivory white	Brown, though initially may be hypopigmented
<i>Follicular plugs:</i> prominent	Absent

Treatment

Localized disease

- ❖ Topical steroids
- ❖ Topical tacrolimus, pimecrolimus

Extensive disease

- ❖ Chloroquine
- ❖ Photochemotherapy with psoralens and UVA.
- ❖ Narrow band (UVB).

Miscellaneous Disorders

Lichen Sclerosus et Atrophicus

Etiology

Unknown.

Clinical Features

- ❖ More frequent in women.
- ❖ Nongenital lesions asymptomatic, while genital lesions itchy.
- ❖ Ivory white sclerotic plaques with follicular plugs (Fig. 13.21A). Sometimes guttate lesions seen (Fig. 13.21B).
- ❖ Can occur on any part of the body:
 - *Nongenital lesions:* neck and trunk.

13. **En coup de sabre:** made by a stroke of sword.

14. *et:* latin for ‘and’; also used in *et al.*, which means “and others”.

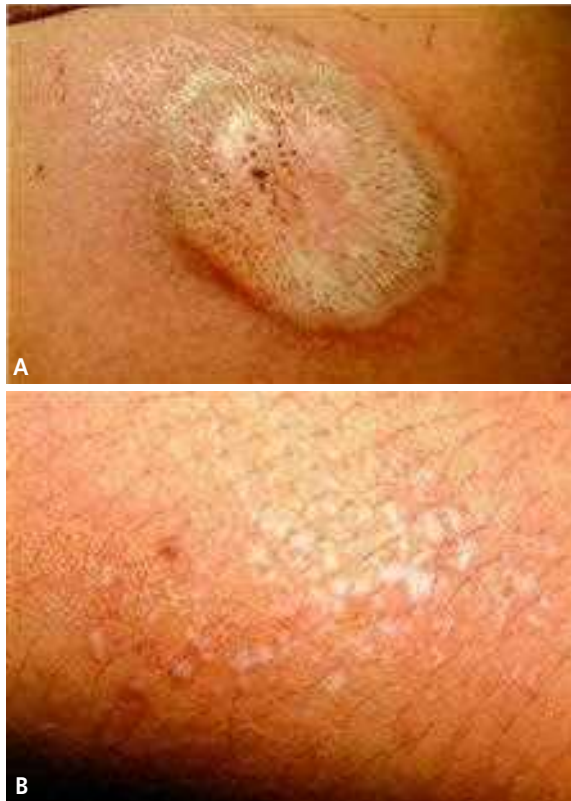

Fig. 13.21. Lichen sclerosus et atrophicus: A: ivory white sclerotic plaques with follicular plugs. B: guttate lesions

- *Genital lesions:* vulva (Fig. 13.22) and glans.
- ❖ Genital lesions may be complicated by:
 - Vulval carcinoma in females.
 - Stenosis of urethral meatus in males.

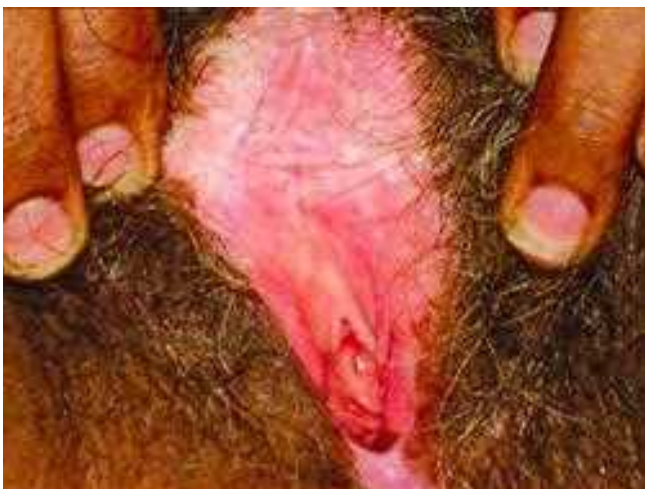

Fig. 13.22. Lichen sclerosus et atrophicus: ivory white, sclerotic plaques.

Treatment

- ❖ Potent steroids initially, followed by moderately potent steroids.
- ❖ Topical tacrolimus, pimecrolimus.

Mixed Connective Tissue Disease (MCTD)

Etiology

Autoimmune disorder showing overlap of SLE with:

- ❖ SSc.
- ❖ Dermatomyositis.
- ❖ Other connective tissue disorders.

Clinical Features

- ❖ Female preponderance.
- ❖ Raynaud's phenomenon with scleroderma, finger tip ulcers and even gangrene.
- ❖ Arthritis, serositis, and myositis.
- ❖ Malar rash and Gottron's papules (Fig. 13.23).
- ❖ Periungual telangiectasia.
- ❖ Esophageal dysmotility and pulmonary involvement common.
- ❖ Neuropsychiatric disease and renal involvement less common.
- ❖ Vasculitis: Palpable purpura, erythema nodosum and leg ulcers.

Investigations

Confirming diagnosis of MCTD

- ❖ **ANA:** All patients have:
 - Speckled pattern of ANA.

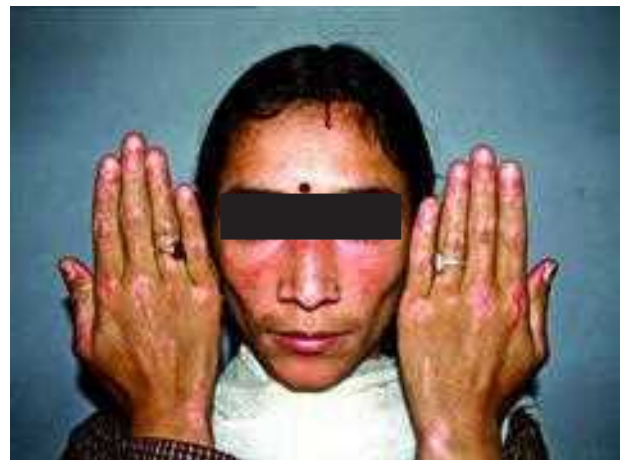

Fig. 13.23. Mixed connective tissue disease: overlap of SLE with dermatomyositis and systemic sclerosis. Note Gottron's papules, malar rash, and beaking of nose.

- High titer of antibody to ENA (Sm), which is sensitive to digestion with ribonuclease.
- ❖ **Direct immunofluorescence:** Shows speckled staining of epidermal nuclei of skin.

Establishing extent of involvement

The patient needs to be investigated to find the extent of involvement (Table 13.8).

Table 13.8. Laboratory findings in MCTD

Hematological tests	Anemia Leukopenia Thrombocytopenia ↑ ESR
Serological tests	Speckled ANA (100%) Antibodies to ENA (100%) Hypergammaglobulinemia Rheumatoid factor VDRL
Gastrointestinal tract Barium swallow	Esophageal dysmotility
Respiratory system CXR Pulmonary function tests	Diffuse reticulation Reduced diffusion capacity
Renal function tests	Usually normal

Treatment

- ❖ Nonsteroidal anti-inflammatory agents for arthritis, fever, and myalgia.
- ❖ Chloroquine and hydroxychloroquine for photosensitivity.
- ❖ Corticosteroids and immunosuppressives usually in combination for systemic disease.

Behcet's Syndrome (BS)

Synopsis

Etiology: Unknown.

Mucocutaneous features: Recurrent, persistent and extensive oral and genital aphthous ulcers; erythema nodosum, pathergy.

Systemic features: Ophthalmological and neurological manifestations.

Treatment: *Mucocutaneous lesions:* Thalidomide and colchicine. *Systemic involvement:* Oral steroids and immunosuppressives.

Etiology

- ❖ **Genetics:** Based on significant association with HLA B51.
- ❖ **Autoimmunity:** Based on presence of:

- Circulating autoantibodies against intermediate filaments found in mucous membranes, cardiolipin, and neutrophil cytoplasm.
- Circulating immune complexes and reduced levels of complement.
- Perivascular deposition of immune complexes.
- Decreased ratio of T-helper (CD4) to T-suppressor (CD8) cells.
- ❖ **Infections:** Infectious agents (*e.g.*, streptococci, herpes simplex virus) may trigger a vasculitis in genetically predisposed individuals.

Epidemiology

- ❖ **Prevalence:** More frequent in Eastern hemisphere.
- ❖ **Age:** Most frequent in age 20–30 years.
- ❖ **Gender:** Male preponderance.

Clinical Features

Mucocutaneous manifestations

- ❖ **Aphthous ulcers** (Figs. 13.24A):
 - Extremely painful.
 - Have a necrotic floor surrounded by a halo of erythema.
 - Recurrent, numerous, and large (sometimes huge!).
 - Oral and genital mucosae.
- ❖ Cutaneous pustular vasculitic lesions (Fig. 13.24C).
- ❖ Erythema nodosum-like lesions.
- ❖ Palpable purpura.
- ❖ Superficial thrombophlebitis.

Extracutaneous manifestations

- ❖ **Eye changes:** Hypopyon, anterior, and posterior uveitis.
- ❖ **Arthritis.**
- ❖ **Meningoencephalitis.**
- ❖ **Intestinal ulcers.**

Course and complications

- ❖ BS is a chronic disease.
- ❖ Eye involvement may lead to blindness.

Diagnosis

BS is diagnosed primarily by clinical criteria (Table 13.9), because of absence of a pathognomonic laboratory test.

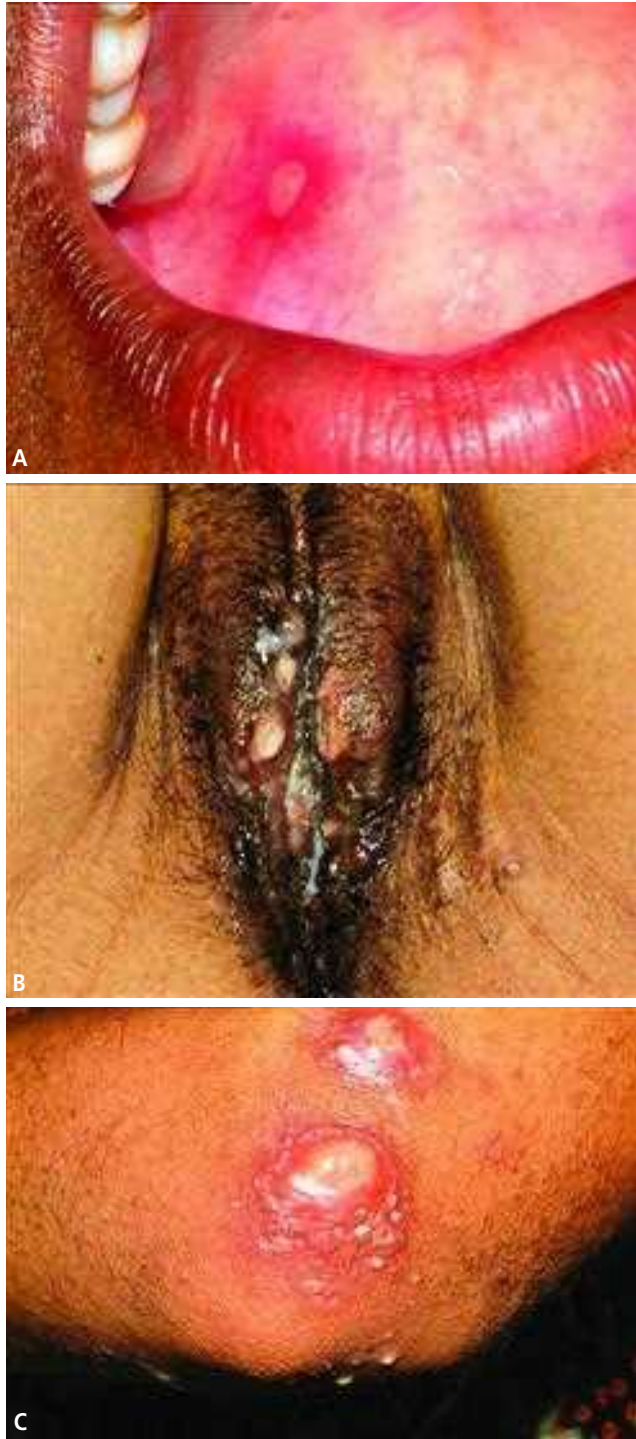

Fig. 13.24. Behcet's syndrome: A: aphthous ulcers with necrotic floor and surrounded by erythematous halo on palate. B: lesions on genitalia. C: cutaneous pustular vasculitic lesions.

Table 13.9. Revised international criteria for diagnosis of Behcet's disease (2007)

Diagnosis of Behcet's syndrome made with a score of 3 points	
2 points	Ocular lesions (posterior uveitis, anterior uveitis, and sequelae)
2 points	Genital aphthosis
1 point	Pathergy ¹⁵
1 point	Vascular lesions (phlebitis, large vein thrombosis, aneurysm, and arterial thrombosis)
1 point	Skin lesions confined to pustular vasculitis (erythema nodosum, palpable purpura, etc.)
1 point	Oral aphthosis

Treatment

Mucocutaneous lesions

- ❖ **Topical agents:** Steroids, tacrolimus, and local anesthetics.
- ❖ **Colchicine:** 0.6 mg orally, 2–3 times a day.
- ❖ **Thalidomide:** 100 mg thrice a day, gives dramatic response but should not be used in women in reproductive age because of teratogenic potential.

Systemic disease

- ❖ Corticosteroids.
- ❖ Azathioprine.
- ❖ Cyclophosphamide.

Panniculitis

Panniculitis is inflammation of subcutaneous tissue.

Etiology (Table 13.10)

Table 13.10. Etiology of panniculitis

Primary	Idiopathic lobular panniculitis ¹⁶
Secondary	
<i>Physical</i>	Traumatic panniculitis Cold panniculitis Pressure panniculitis
<i>Chemical</i>	Steroid withdrawal Oil panniculitis
<i>Others</i>	Connective tissue diseases, like SLE Pancreatic disorders Malignancies

15. **Pathergy:** development of pustular lesions at sites of trauma.

16. **Idiopathic lobular panniculitis:** earlier called Weber–Christian panniculitis.

Classification

Depending of site of inflammation, panniculitis is classified into:

- ❖ Septal panniculitis.
- ❖ Lobular panniculitis.

Clinical Features

❖ Skin lesions:

- Tender, ill-defined, erythematous, subcutaneous (deep seated) nodules (Fig. 13.25). Sometimes, the nodules may rupture to discharge oily fluid.
- Legs, thighs, buttocks, and abdominal wall.

❖ **Constitutional symptoms:** Fever, malaise, and arthritis.

❖ **Course:** Depends on underlying disease.

Investigations

Investigations are needed to:

- ❖ To establish the diagnosis.
- ❖ To find the cause.
- ❖ To find out extent of disease.

Establish the diagnosis

A deep biopsy (to include subcutaneous fat) would confirm the diagnosis. The type of panniculitis is established by:

- ❖ Finding whether it is septal or lobular panniculitis.
- ❖ Whether there is a concomitant vasculitis.
- ❖ Type of infiltrate.

To find the cause

- ❖ Complete blood count and erythrocyte sedimentation rate, chest X-ray, serum lipase, and serum α 1-antitrypsin.
- ❖ ANA to rule out underlying connective tissue diseases.

Treatment

Specific treatment

- ❖ Removal of trigger.
- ❖ Depends on the cause.

Symptomatic treatment

- ❖ Rest.
- ❖ Local heat.
- ❖ Nonsteroidal anti-inflammatory agents.

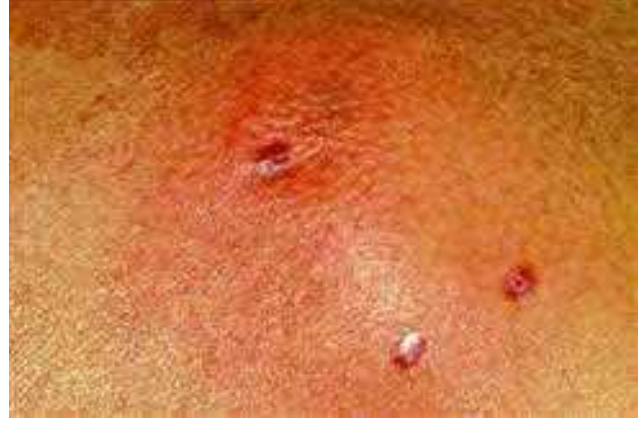

Fig. 13.25. Panniculitis: erythematous, ill-defined, tender deep-seated nodule on abdomen.

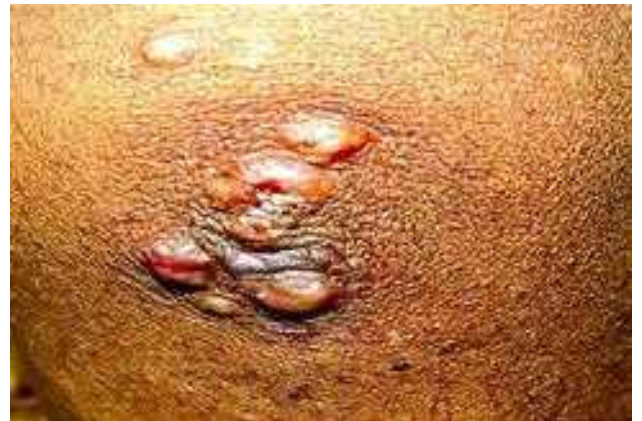

Fig. 13.26. Rheumatoid nodules: marble-like nodules on the elbow.

Rheumatoid Arthritis

Though it is unusual for patients with rheumatoid arthritis to present initially to dermatologist, cutaneous manifestations are not uncommon and include:

❖ Rheumatoid nodules:

- Seen in 20% of seropositive patients.
- Marble-like nodules (Fig. 13.26) which may ulcerate.
- Most commonly along ulnar border of forearm. Less commonly, on dorsa of hands and knees and pressure points.

- ❖ Tiny finger-tip infarcts.
- ❖ Purpura and vasculitic ulcers.
- ❖ Palmar erythema.

Infections

14

Chapter Outline

Skin Flora

Resident flora

Diseases caused by resident flora[•]

Bacterial Infections

Pyodermas[•]

Cutaneous tuberculosis[•]

Leprosy[•]

Other mycobacterial infections[◦]

Viral Infections

Warts[•]

Molluscum contagiosum[•]

Varicella-zoster infections[•]

Herpes simplex virus infections[•]

Maculopapular viral exanthems[•]

Fungal Infections

Dermatophytic infections[•]

Pityriasis versicolor[•]

Candidiasis[•]

Deep fungal infections[•]

- ❖ Infections of the skin can be caused by bacteria, viruses, and fungi.
- ❖ These micro-organisms enter skin through various routes such as direct contact, through airborne route through vectors, through fomites, and sexually. Sometimes, the patient may be harboring the infectious agent in internal organs and the skin gets infected either contiguously or hematogenously. Occasionally, the normal skin flora become pathogenic.

Skin Flora

The normal skin is inhabited by:

❖ **Resident flora:**

- Present permanently.
- Multiply in the skin.
- Usually nonpathogenic.

❖ **Transient flora:**

- Derived from exogenous sources.
- Do not multiply in the skin.
- Often pathogenic.

Resident Flora

Synopsis

Organisms: *Staphylococcus epidermidis*¹, *Corynebacterium spp.*, *Propionibacterium spp.*, and *Malassezia spp.* (a yeast). Harmless organisms, residing and multiplying on skin.

Location: Present in stratum corneum, crevices of skin and hair follicles. Intertriginous areas most populated.

Function: Are first line of defense against pathogenic microbes.

Diseases produced: Usually asymptomatic presence. Under favorable conditions, may cause pitted keratolysis, erythrasma, and trichomycosis axillaris.

[•]Should know

[◦]Good to know

1. *S. epidermidis*: coagulase-negative Staphylococcus.

Table 14.1. Resident flora of skin

Resident flora	Location
<i>Staphylococcus epidermidis</i>	On surface of skin, moist sites
<i>Corynebacterium spp.</i> ²	Aerobic, in moist sites
<i>Propionibacterium spp.</i> ²	Anaerobic, in depth of hair follicle
<i>Brevibacterium spp.</i> ²	Aerobic, in moist sites
<i>Malassezia spp.</i>	In superficial part of hair follicle

Organisms

- ❖ Resident skin flora consists of a mixture of several microorganisms (Table 14.1).
- ❖ ***Staphylococcus aureus***³ (*S. aureus*) is not a part of normal resident flora of the skin. However, a small percentage of people do carry it in their nostrils, axillae, and perineum. Nasal carriage is universal in hospital-born babies (so in most of us!) but reduces in infancy and then rises again in childhood and adulthood.

Location of Resident Flora (Table 14.1)

Microorganisms are not present uniformly on the skin. They are present in clusters in:

- ❖ Crevices in stratum corneum.
- ❖ Hair follicles (either superficially or in the deeper parts).

They are most numerous in:

- ❖ Moist intertriginous sites (axillae and groins).
- ❖ Areas rich in hair follicles and sebaceous glands (scalp and face).

Functions of Resident Flora

Resident flora are important defense mechanisms against pathogenic organisms because they:

- ❖ Compete with pathogenic organisms for nutrients.
- ❖ Produce antibiotics and other chemicals which inhibit growth of pathogens.
- ❖ Modify secretions of skin to make skin a less favorable habitat for pathogens.

Diseases Caused by Resident Flora

- ❖ Resident flora do not cause disease under normal conditions.
- ❖ In presence of predisposing factors, (like moisture especially in intertriginous areas and feet) these microbes overgrow resulting in disease.

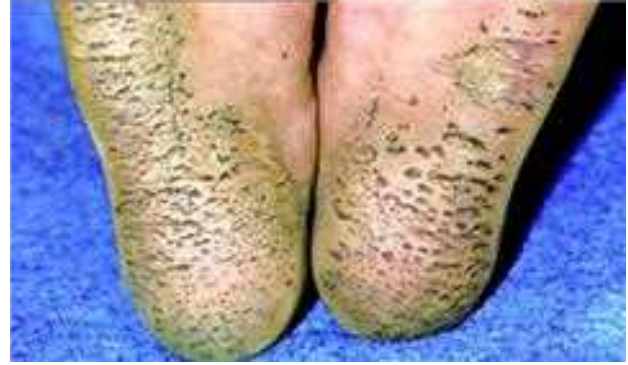

Fig. 14.1. Pitted keratolysis: fine, punched-out often elongated pits which become confluent to give a cribriform pattern.

Pitted Keratolysis

Etiology

- ❖ **Causative agents:** *Corynebacterium spp.* probably *Micrococcus sedentarius* and some other organisms.
- ❖ **Predisposing factors:** Summer, plantar hyperhidrosis, keratoderma, and occlusive foot wear.
- ❖ **Pathogenesis:** Pits formed due to digestion of keratin by bacteria.

Clinical features

- ❖ Fine, punched-out often elongated pits becoming confluent to give a cribriform pattern (Fig. 14.1).
- ❖ Feet are wet, soggy, and foul smelling. Patients often have keratoderma and hyperhidrosis.
- ❖ Soles (usually pressure points and often web spaces). Rarely palms.

Treatment

- ❖ Topical antibiotics (erythromycin and sodium fusidate) and benzoyl peroxide (5% gel/cream) during the active stage.
- ❖ Excessive sweating (hyperhidrosis) should be controlled with topical aluminium chloride. Or botulinum toxin.

Erythrasma

Etiology

- ❖ **Causative agent:** *Corynebacterium minutissimum*.
- ❖ **Predisposing factors:** Warm humid climate.

Clinical features

- ❖ Asymptomatic, well-defined, irregular, scaly, uniformly pink but more frequently brown

2. ***S. aureus***: coagulase-positive Staphylococcus.

3. Often collectively referred to as **coryneform bacteria**.

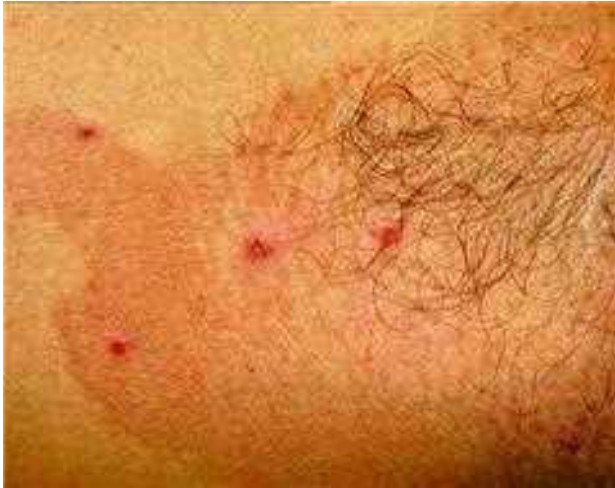

Fig. 14.2. Erythrasma: well-defined, hyperpigmented macule, usually in intertriginous areas. Note wrinkled surface.

macules. Creasing or wrinkling of lesions is characteristic (Fig. 14.2). Depth of the flexures may macerate.

- ❖ Interdigital spaces (between toes), axillae, groins, and submammary area.

Investigations

- ❖ **Wood's lamp:** Lesions fluoresce coral pink.
- ❖ **Scrapings:** Potassium hydroxide or a Gram or Giemsa stained mount may show bacteria and fine filaments.

Treatment

- ❖ **Localized lesions:** Topical imidazoles (antifungal agents). Or antibiotics (erythromycin, sodium fusidate). Or 5% benzoyl peroxide gel used for 2 weeks.
- ❖ **Extensive lesions:** Oral antibiotics (clarithromycin 1 g single oral dose).
- ❖ **Relapsing lesions:** Clarithromycin 1 g single oral dose. Also use antibacterial (povidone-iodine) soap.

Trichomycosis Axillaris

Etiology

- ❖ Not a fungal infection (name being a misnomer).
- ❖ Due to abnormal proliferation of commensal coryneform bacteria in axillae (and rarely pubis).

Clinical features

- ❖ Patient complains of malodor and yellow-brown staining of area of clothes in contact with axillae.
- ❖ On examination, the axillary (rarely pubic) hairs are beaded with yellow, brown or black concretions (Fig. 14.3).

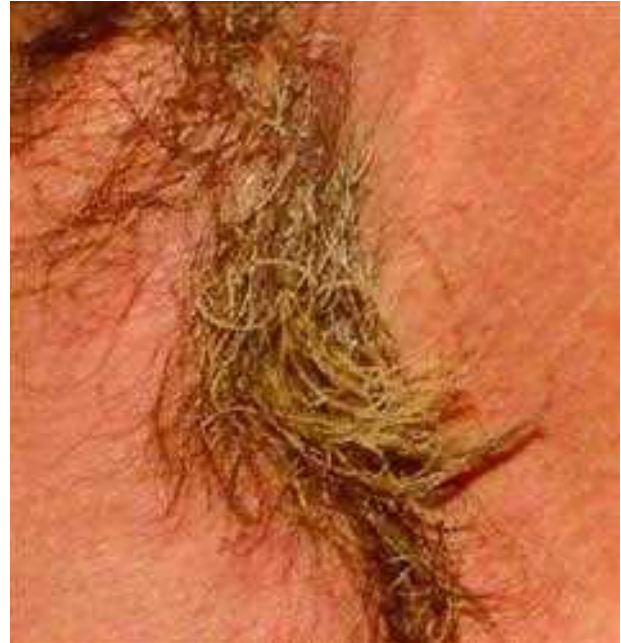

Fig. 14.3. Trichomycosis axillaris: axillary hair beaded with yellow concretions.

Investigations

Concretions are made up of thin colonies of Gram-positive bacilli.

Treatment

- ❖ Use of antiperspirant.
- ❖ Regular shaving.
- ❖ Benzoyl peroxide washes. Or 5% gel.

Bacterial Infections

Pyodermas

Synopsis

Etiology: Predominantly caused by *S. aureus* (localized and follicular infections) or *S. pyogenes* (spreading infections like erysipelas and cellulitis). Rule out underlying disease (*skin*: scabies, fungal infections; *systemic*: diabetes, malnutrition, and immunocompromised states) in recurrent lesions.

Clinical features: *S. aureus* causes localized lesions like bullous impetigo, impetigo contagiosa (sometimes), ecthyma (some), and follicular infections (folliculitis, furuncles, carbuncles). *S. pyogenes* causes spreading infections (cellulitis and erysipelas) and sometimes impetigo contagiosa and ecthyma.

Treatment: *Localized infections:* Topical antibiotics. *Extensive infections:* Systemic antibiotics: streptococcal infections respond to penicillins or erythromycin and staphylococcal infections need aggressive treatment with flucloxacillin, amox-clavulanic acid combination, methicillin *etc.* Local hygiene and drainage of pus hasten relief.

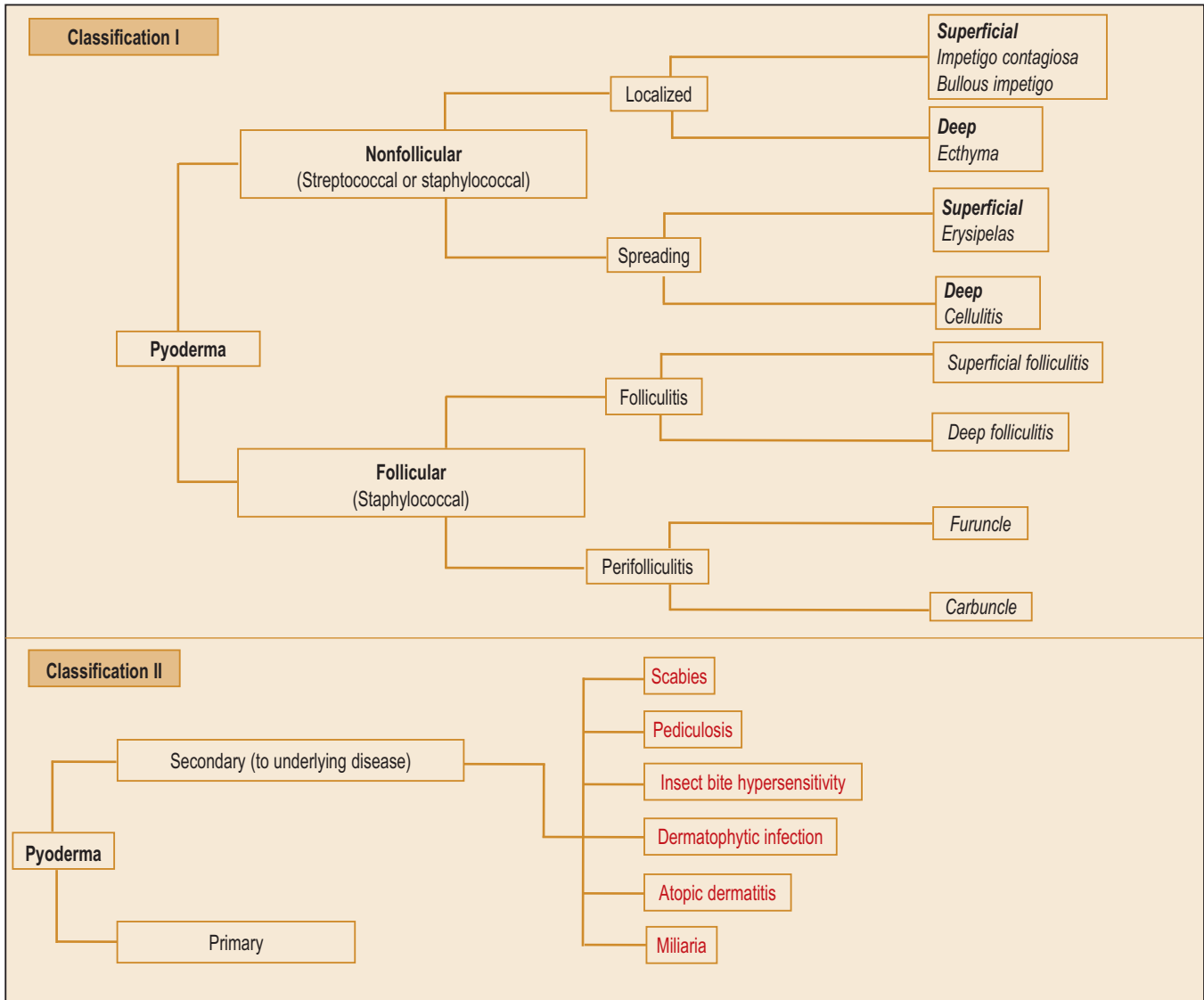


Fig. 14.4. Classification of pyoderma.

Pyodermas are infections of skin and appendages. They are commonly caused by *S. aureus*, *Streptococcus pyogenes* (*S. pyogenes*) or both (Table 14.2). Pyoderma can be classified (Fig. 14.4):

- ❖ **As follicular or nonfollicular:**
 - *Follicular pyoderma:* are caused by *S. aureus*. Includes folliculitis, furuncles, and carbuncles.
 - *Nonfollicular pyoderma:* can be caused by either *S. pyogenes* or *S. aureus* or both. Includes impetigo contagiosa, ecthyma, erysipelas, and cellulitis.
- ❖ **As superficial or deep**
 - *Superficial pyoderma:* are caused by both *S. aureus* and *S. pyogenes*. Includes impetigo contagiosa, bullous impetigo, erysipelas, and superficial folliculitis.
 - *Deep pyoderma:* are caused by both *S. aureus* and *S. pyogenes*. Includes ecthyma, cellulitis, deep folliculitis, furuncles, and carbuncles.
- ❖ **As localized or spreading**
 - *Localized pyoderma:* can be caused by *S. aureus* or *S. pyogenes*. Includes impetigo contagiosa, bullous impetigo, ecthyma, folliculitis, furuncles, and carbuncles.
 - *Spreading pyoderma:* are caused by *S. pyogenes*. Includes erysipelas, and cellulitis.
- ❖ **As primary or secondary**
 - *Primary pyoderma:* when there is no underlying predisposing disease.

Table 14.2. Bacteria causing pyodermas

<i>Staphylococcus aureus</i>	
Nonfollicular	Bullous impetigo Impetigo contagiosa* Ecthyma*
Follicular	Superficial folliculitis Deep folliculitis Furuncle Carbuncle
<i>Streptococcus pyogenes</i>	
Localized	Impetigo contagiosa* Ecthyma*
Spreading	Erysipelas Cellulitis

*Caused by *S. aureus* and/or *S. pyogenes*

- **Secondary pyoderma:** when there is underlying predisposing disease which could be:
 - Skin disease like scabies, pediculosis, insect bite hypersensitivity, fungal infections, atopic dermatitis, and miliaria.
 - Systemic disease like diabetes, HIV infection.

Impetigo Contagiosa

Etiology

- ❖ Impetigo contagiosa is caused either by:
 - *S. aureus* (in developed countries).
 - *S. pyogenes* (gp A).
 - Or by both.
- ❖ Recurrent impetigo should prompt search for underlying disease.

Epidemiology

- ❖ **Prevalence:** Frequent, often occurring in epidemics.
- ❖ **Age:** Preschool and young school children.
- ❖ **Gender:** In adults, males > females.

Clinical features

Morphology

- ❖ Thin-walled bulla (seldom seen) on an erythematous base, ruptures rapidly to form an exudative plaque covered with honey-colored crusts (Fig. 14.5). The lesion spreads peripherally without central healing and many lesions may coalesce to form polycyclic plaques. Removal of the crust reveals an erosion. On

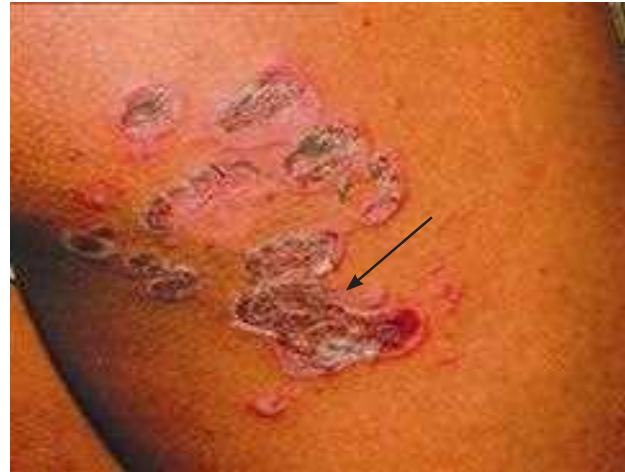

Fig. 14.5. Impetigo contagiosa: multiple crusted lesions with an erythematous halo. Spread without healing. Note polycyclic edge.

- drying, the crust falls leaving erythema which fades without scarring.
- ❖ Usually multiple lesions.
- ❖ Regional lymphadenopathy is frequent in severe disease (90%).
- ❖ Constitutional symptoms may occur occasionally.
- ❖ Untreated, may evolve into ecthyma (P. 248).

Sites of predilection

- ❖ Face (periorificial, especially around the mouth and nose), most frequent site of involvement.
- ❖ Extremities and scalp, less frequently.

Complications

- ❖ Eczematization, a frequent complication.
- ❖ Acute poststreptococcal glomerulonephritis⁴ in 25% patients infected with nephritogenic strains (type M-49).

Investigations

- ❖ **Gram stain:** Of exudate shows polymorphs with intracellular and extracellular Gram-positive cocci in chains (streptococci) or clusters (staphylococci).
- ❖ **Culture:** Of pus to identify etiological agent and also antibiotic sensitivity.

Diagnosis

Points for diagnosis

- Diagnosis of impetigo contagiosa is based on:
 - ❖ Patient is a child.

4. Rheumatic fever is not a complication of streptococcal impetigo.

- ❖ Appearance of multiple, crusted (honey-colored) lesions with an erythematous halo, predominantly on the face (periorificial areas).
- ❖ Gram stain and pus culture establish the etiological agent.

Differential diagnosis

Impetigo contagiosa should be differentiated from:

a. Bullous impetigo

Bullous impetigo	Impetigo contagiosa
Caused by: <i>S. aureus</i>	<i>S. aureus</i> or <i>S. pyogenes</i> or both
Prevalence: sporadic	Frequent, often epidemic
Age: usually infants	Children
Morphology of bulla: bullae thick walled, persistent and may become large	Thin walled and transient
Erythematous halo: absent	Common
Crusts: thin, varnish-like	Honey colored and thick
Central clearing: present	Not seen
Lymphadenopathy: rare	Frequent
Mucous membranes: may be involved	Involvement rare
Site: on face and other parts	Predominantly on face

b. Herpes simplex (HSV) infection

HSV infection	Impetigo contagiosa
Morphology: grouped vesicles; rupture to form polycyclic erosions	Plaque covered with honey-colored crusts. Several lesions coalesce to form polycyclic plaque.
Site: around and within mouth	Periorificial

Treatment

Measures to prevent spread

Measures to reduce transmission include:

- ❖ Encouraging hand washing.
- ❖ Instituting treatment early.

General measures

- ❖ Local hygiene, including cleaning with soap and water.
- ❖ Gentle removal of crusts, often after softening with topical agents.

Specific measures

Even if specimens have been taken for culture, specific treatment should be instituted before the report is available.

- ❖ **Localized lesions:** Topical antibiotics like fusidic acid or mupirocin.

❖ Extensive lesions. Or if lymphadenopathy or constitutional symptoms present:

- Systemic antibiotics (erythromycin group to cover both *Staphylococcus* and *Streptococcus*) given for 5–7 days.
- If response is poor (indicating resistant *Staphylococcus*), amoxicillin–clavulanic acid (25 mg/kg/day) or cephalexin (50 mg/kg/day) can be tried.

Bullous Impetigo

Etiology

Certain strains of *S. aureus* (group II, type 55 and 77).

Epidemiology

- ❖ **Prevalence:** Sporadic.
- ❖ **Age:** Newborn and infants.

Clinical features

Morphology

- ❖ Bullae, containing turbid fluid, without or minimal erythematous halo (Fig. 14.6); rupture after a few days to form thin, varnish-like crusts. Lesions may heal in the center to form annular plaques.
- ❖ Mucous membranes may be involved.

Sites of predilection

Face. Sometimes widely and irregularly distributed, often favoring the sites of existing skin disease.

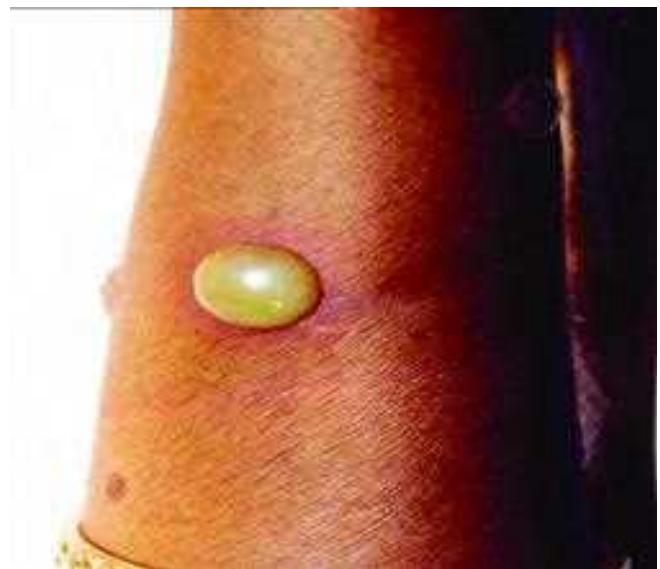

Fig. 14.6. Bullous impetigo: intact bulla with turbid fluid.

Complications

- ❖ Regional lymphadenopathy (rare).
- ❖ Staphylococcal scalded skin syndrome.

Investigations

- ❖ **Gram stain:** Polymorphs with intracellular and extracellular Gram-positive cocci in clusters.
- ❖ **Culture:** *S. aureus*. Antibiotic sensitivity important to determine.

Diagnosis

Points for diagnosis

Diagnosis of bullous impetigo is based on:

- ❖ Patient is an infant.
- ❖ Presence of bullae, which rupture to form plaques surmounted with varnish-like crusts. Lesions heal in center to form annular plaques
- ❖ Presence of *S. aureus* in pus culture.

Differential diagnosis

Differentiate from:

- Impetigo contagiosa* (P. 246).

Treatment

General measures

- ❖ Local hygiene including cleaning with soap and water.
- ❖ Crusts can easily be removed.

Specific measures

- ❖ **Localized lesions:** Topical antibiotics (sodium fusidate, mupirocin, and nadifloxacin).
- ❖ **Extensive lesions:** Systemic antistaphylococcal antibiotics (flucloxacillin, amoxicillin–clavulanic acid combination, methicillin or erythromycin).

Staphylococcal Scalded Skin Syndrome (SSSS)

Etiology

S. aureus infection present at distant sites, like middle ear (otitis media), lungs (pneumonitis) and less frequently, skin (trivial wounds, rarely bullous impetigo) produces an exotoxin (**exfoliative toxin**) which spreads hematogenously and causes a split in the upper layers of epidermis.

Clinical features

- ❖ Infants.
- ❖ Onset is acute with fever and skin tenderness.
- ❖ Initial erythema and tenderness (sometimes extreme) is followed by superficial peeling of

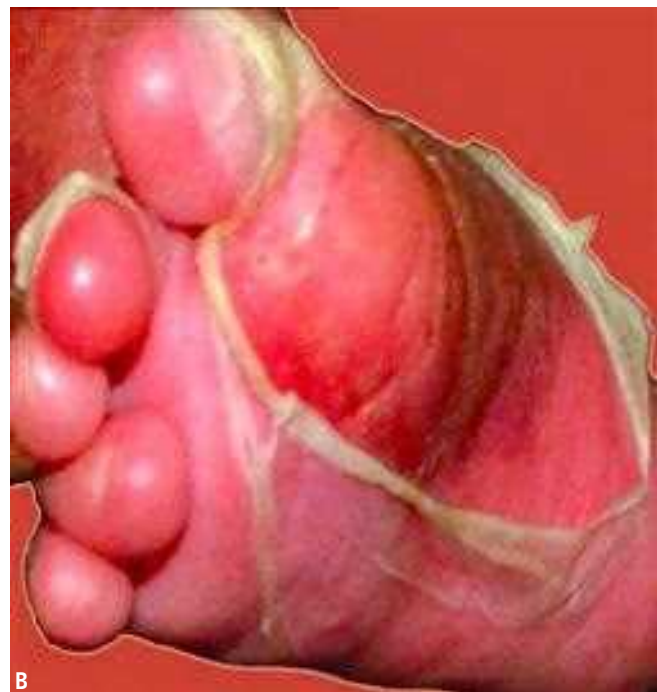
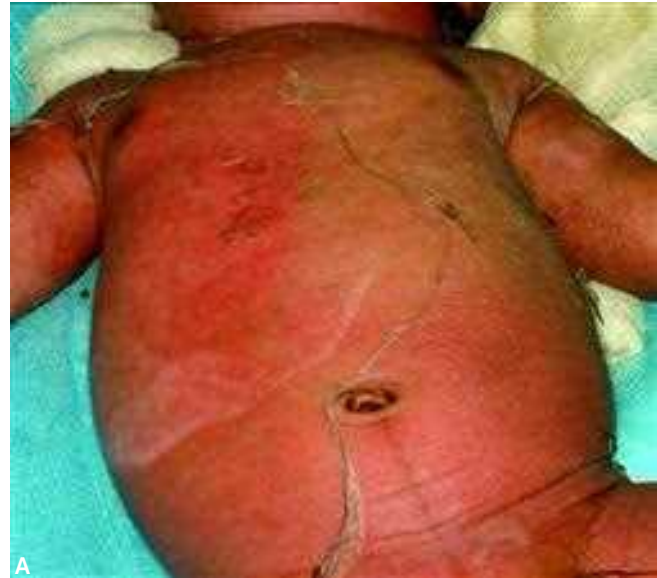
Fig. 14.7. Staphylococcal scalded skin syndrome: A: superficial peeling of skin in thin sheets in an infant. B: peeling of skin to reveal moist erythematous floor.

the skin in thin sheets (Fig. 14.7) to reveal moist erythematous floor. Clinically, the skin appears scalded.

- ❖ Mucous membranes spared.
- ❖ Good prognosis, with low mortality.

Investigations

- ❖ **Gram stain and pus culture:** Lesions do not contain any microorganisms.

Diagnosis

Points for diagnosis

The diagnosis of SSSS is based on:

- ❖ Patient is an infant.
- ❖ Superficial peeling of skin preceded by erythema and tenderness.
- ❖ Absence of mucosal lesions.

Differential diagnosis

SSSS should be differentiated from:

a. Epidermal necrolysis (EN).

EN	SSSS
Etiology: drugs	<i>S. aureus</i> infection at distant focus
Age: at any age	Occurs in infancy
Constitutional symptoms: conspicuous	Absent
Skin lesions: deep peeling	Superficial peeling
Mucosal involvement: severe	Absent
Treatment: Remove trigger. Supportive care. Steroids may help	Antistaphylococcal antibiotics

Treatment

- ❖ Supportive and nursing measures are important.
- ❖ Aggressive treatment, initially intravenous later oral antistaphylococcal antibiotics (dicloxacillin, amoxicillin–clavulanic acid combination).

Ecthyma

A deeper pyoderma, often a consequence of neglected impetigo contagiosa.

Etiology

- ❖ **Microbes:** *S. pyogenes* or *S. aureus* or both.
- ❖ **Predisposing factors:** Poor hygiene, malnutrition, minor injuries, insect bites, and scabies.

Clinical features

- ❖ Small bulla or pustule appears on an erythematous base. Rapidly forms a crusted (often heaped-up), indurated, tender plaque, with an erythematous, edematous areola (Fig. 14.8A and B).
- ❖ Removal of adherent crust reveals an irregular punched out ulcer.
- ❖ Heals with scarring.
- ❖ Seen on legs, thighs, and buttocks.

Treatment

- ❖ Local hygiene.
- ❖ Treat/address predisposing factors.
- ❖ Systemic antibiotics, effective against

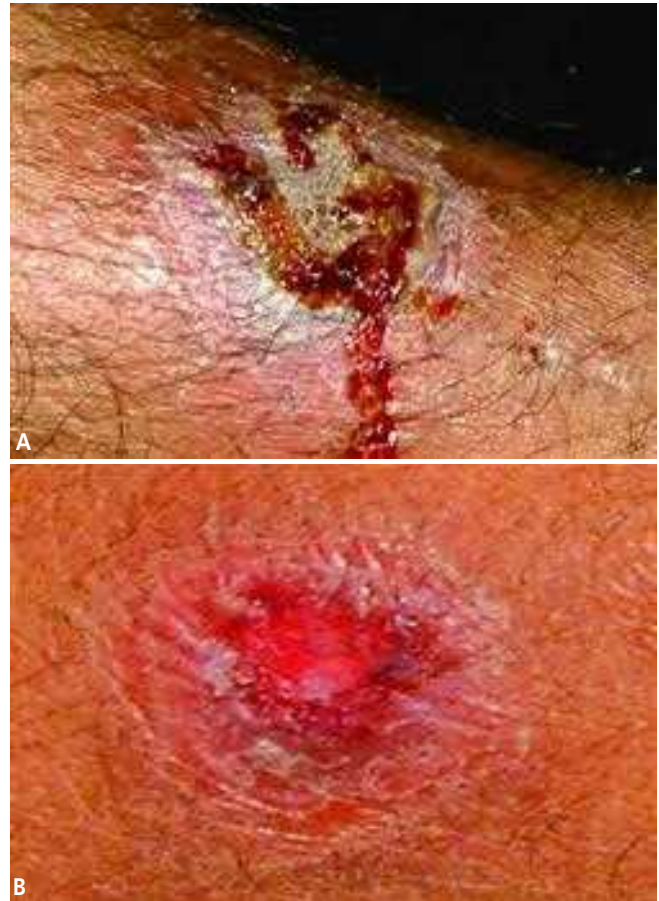

Fig. 14.8. Ecthyma: A: heaped up crusted indurated tender plaque with erythematous edematous areola. B: Removal of adherent crust reveals an irregular punched out ulcer.

Streptococcus and Staphylococcus (penicillin or erythromycin group).

Superficial Folliculitis

Etiology

Folliculitis is not always infectious and can be classified as:

- ❖ **Infectious** : *S. aureus*.
- ❖ **Chemicals** : Due to mineral oils, petrolatum and vegetable oils, (occupational/cosmetic exposure).
- ❖ **Mechanical** : Pseudofolliculitis
 - After shaving in the beard region.
 - Postwaxing folliculitis.

Clinical features

- ❖ Dome-shaped follicular pustules (Fig. 14.9).
- ❖ Legs. Less frequently forearms. Pseudofolliculitis

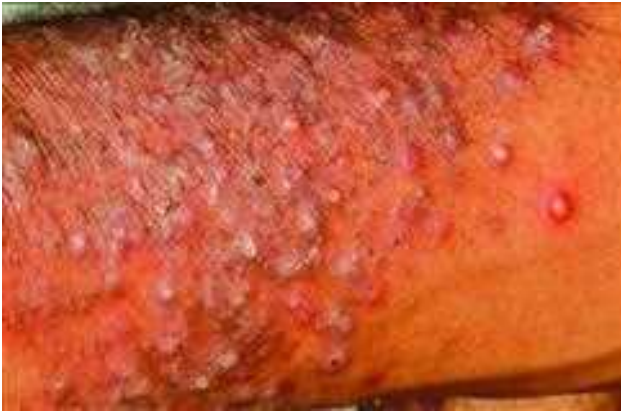

Fig. 14.9. Folliculitis: dome-shaped follicular pustules.

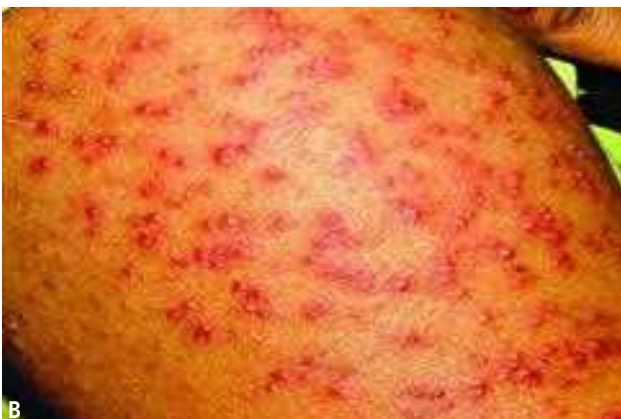
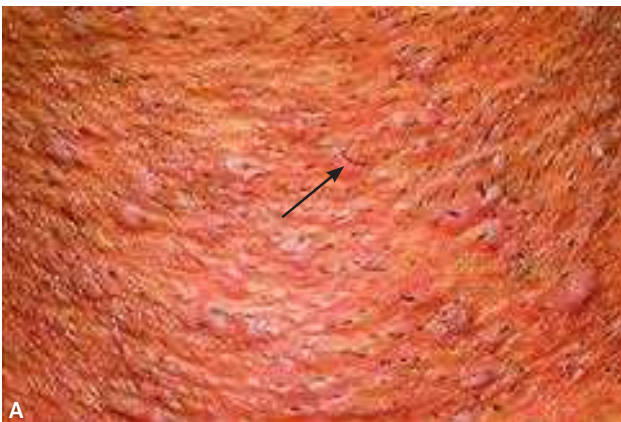
Fig. 14.10. Pseudofolliculitis A: in beard region. Note reentry of hair. B: postwaxing folliculitis: seen in about 10% of subjects who epilate hair by waxing. Not infectious but a pseudofolliculitis.

seen in the beard area (after shaving), thighs, and arms (after epilation by waxing; Figs. 14.10A and B).

Treatment

- ❖ **Infectious folliculitis:** Topical antibiotics for localized lesions and systemic antibiotics for extensive lesions.
- ❖ **Chemical and mechanical folliculitis:**
 - *Removal of trigger:* removal of chemical exposure. Correction of shaving/waxing technique.
 - Topical steroid-antibiotic combination. Retinoic acid helps in pseudofolliculitis.

Deep Folliculitis

Etiology

S. aureus.

Clinical features

- ❖ Deep seated, erythematous follicular papules and pustules.
- ❖ Beard area (called **sycosis⁵ barbae**) and scalp are commonly involved.

Treatment

Systemic antibiotics.

Acne Keloidalis

Etiology

- ❖ Chronic inflammatory process involving the hair follicle.
- ❖ Role of *Staphylococcus debatable*.

Clinical features

- ❖ Occurs in postpubertal males.
- ❖ Chronic follicular keloidal papules and pustules. May remain discrete. Or fuse to form linear plaques.
- ❖ Nape of neck (Fig. 14.11).

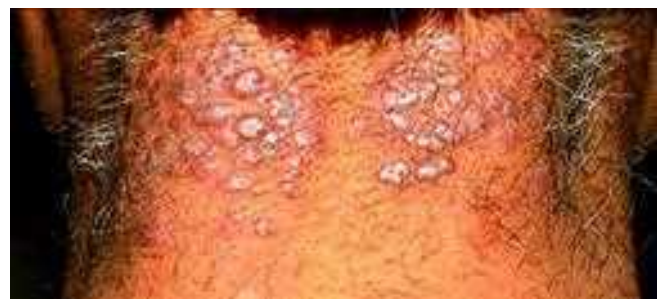

Fig. 14.11. Acne keloidalis: irregular follicular keloidal papules on the nape of the neck.

5. **Sycosis:** from its resemblance to a ripe fig.

Treatment

Antibiotic–steroid combination.

Furuncles (Boils)

Deep-seated follicular and perifollicular infection.

Etiology

- ❖ **Etiology:** *S. aureus*.
- ❖ **Predisposing factors:** Especially for recurrent furunculosis
 - Nasal/perineal carriage of *S. aureus*.
 - Diabetes, HIV infection.
 - Underlying skin disease, e.g., scabies and atopic dermatitis.

Clinical features

- ❖ Adolescent boys most susceptible.
- ❖ Pain, often throbbing.
- ❖ Usually one to two tender, firm red, follicular nodules which become necrotic and discharge their central core (Fig. 14.12). Lesions heal with barely perceptible scarring.
- ❖ Hair-bearing, friction prone sites, e.g., face, (especially perinasal area) axillae, buttocks, legs and perineal region.
- ❖ Lymphadenopathy and fever may occur occasionally.

Investigations

- ❖ No investigations in patients with sporadic lesions.
- ❖ Recurrent furunculosis (chronic furunculosis) requires further evaluation for:

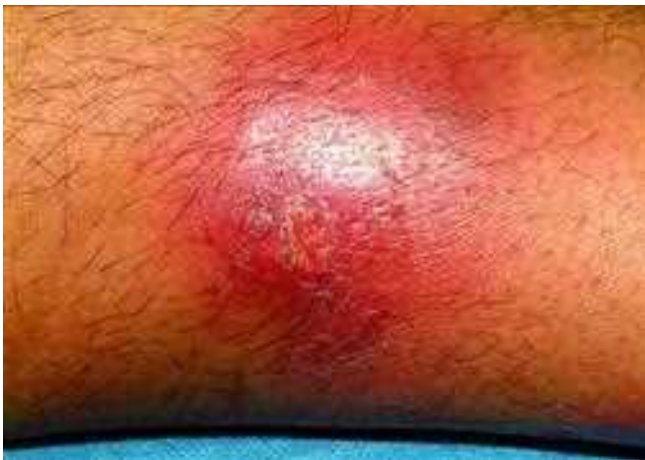

Fig. 14.12. Furuncle: perifollicular, erythematous nodules on the thigh ready to discharge necrotic center.

- Underlying skin diseases (infestations, eczematous skin conditions).
- Diabetes.
- Pus culture from lesions.
- *Carrier state:* culture from other sites (nares, perineal region) to exclude carrier state in patients. Carrier state should also be excluded in close contacts.
- *Detailed immunological workup:* is **not** required unless infection occurs very frequently or there are other definite indications.

Treatment

Acute episodes

- ❖ Moist hot fomentation.
- ❖ Appropriate antibiotics: Topical (mupirocin, sodium fusidate), if few lesions. Systemic anti-staphylococcal drugs (flucloxacillin), if many lesions.
- ❖ Surgical incision and drainage of pus.

Chronic (recurrent) furunculosis

- ❖ Appropriate antibiotics.
- ❖ Exclude and treat carrier state with topical mupirocin applied intranasally and in perineum. Or systemic **rifampicin**⁶.

Carbuncle

Deep infection of contiguous hair follicles, seen most frequently in diabetics and in patients on steroid therapy.

Etiology

- ❖ *S. aureus*.
- ❖ **Predisposing factors:**
 - Diabetes.
 - Systemic steroid therapy.

Clinical features

- ❖ Adult males.
- ❖ Constitutional symptoms, like fever, always present. Lesions excruciatingly painful.
- ❖ Tender, lobulated, indurated, intensely erythematous plaque discharging pus from many openings (Fig. 14.13). Heals with scarring.
- ❖ Back, (commonest site) neck, thighs.

Investigations

- ❖ Pus culture sensitivity should be done.
- ❖ Rule out diabetes.

6. **Rifampicin:** 600 mg daily on empty stomach, for 7–10 days.

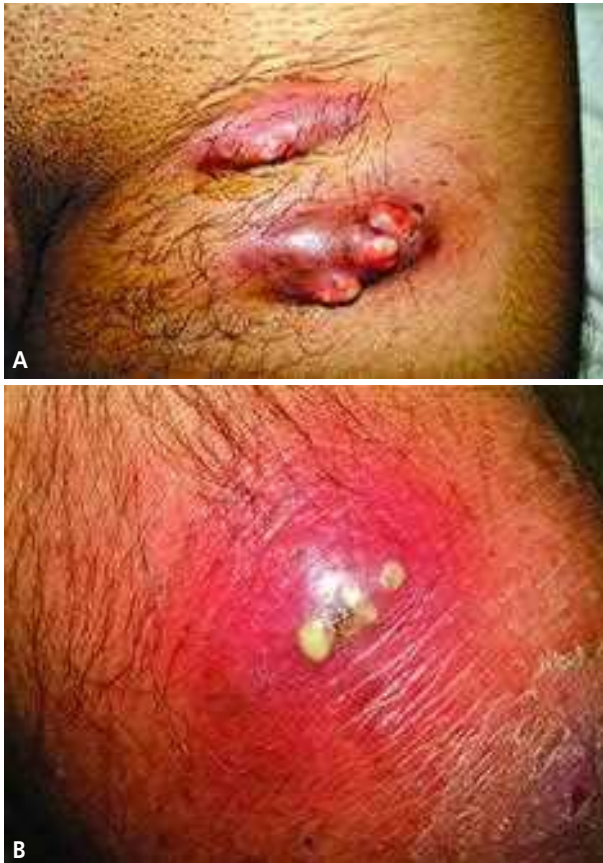

Fig. 14.13. Carbuncle: A and B: tender, lobulated indurated, plaques ready to discharge pus from many openings.

Treatment

- ❖ Moist hot fomentation.
- ❖ Drainage of the deep-seated pockets of pus, though this may be difficult.
- ❖ Aggressive treatment with flucloxacillin or other penicillinase-resistant antibiotics.

Erysipelas and Cellulitis

Erysipelas is a superficial spreading pyoderma, while cellulitis is deeper and often the two coexist.

Etiology

- ❖ *S. pyogenes*. Less frequently *S. aureus*⁷. Organisms enter through a superficial break in the skin (thorn prick, web intertrigo and surgical wounds).
- ❖ **Predisposing factors:** Especially for recurrent infection, lymphedema, venous stasis, web intertrigo, and obesity.

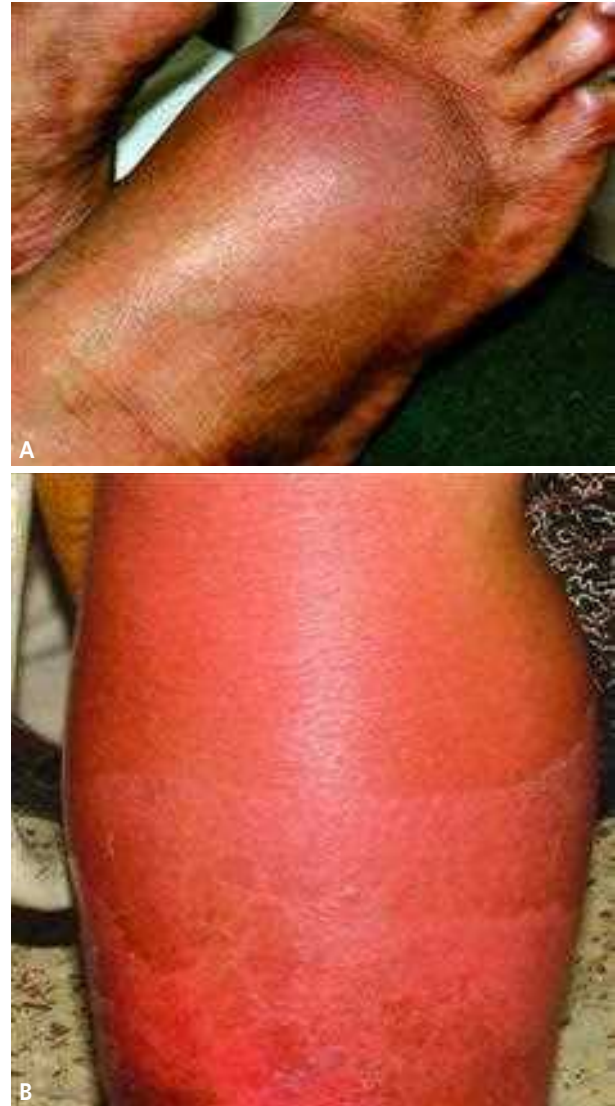

Fig. 14.14. Cellulitis: A and B: erythematous excruciatingly tender plaque that extends into subcutaneous tissue. The edge is not sharply defined.

Clinical features

- ❖ **Symptoms:** Constitutional symptoms invariable and start before the onset of skin lesions. Lesions are very painful.
- ❖ **Morphology:** Both appear as acute erythematous, warm, indurated (firm to hard), rapidly spreading plaques. In erysipelas, the margin is sharply defined and superficial vesiculation (sometimes hemorrhagic) may occur on the plaque. In cellulitis, the lesion is ill-defined and deeper (Fig. 14.14). Skip areas characteristic.
- ❖ **Site:** Lower limbs; less frequently upper limbs and face.

7. Cellulitis caused by *S. aureus* seen usually as a sequelae of manipulated furuncle or in surgical wounds.

❖ **Complications:**

- Lymphadenopathy frequent.
- Facial erysipelas, if untreated, may prove fatal.
- Recurrences may occur in the same area and result in lymphedema which further predisposes to recurrent infection.

Treatment**Symptomatic treatment**

- ❖ Rest.
- ❖ Limb elevation.
- ❖ Nonsteroidal anti-inflammatory drugs to relieve pain and reduce inflammation.

Specific treatment

- ❖ Acute episodes respond dramatically to parenteral penicillin. Erythromycin is used in penicillin-sensitive patients or in patients in whom cellulitis is complication of manipulated furuncle.
- ❖ Recurrent episodes managed with chemoprophylaxis with long-acting penicillin (**benzathine penicillin**)⁸.

Cutaneous Tuberculosis**Synopsis**

Etiology: *M. tuberculosis*. Clinical variants depend on the host's immunity and route of entry.

Clinical features: Three important variants:

- ❖ *Lupus vulgaris*: Well-defined, annular/arcuate plaques with peripheral erythematous nodules (apple jelly nodules on diascopy). Center is depigmented with paper thin, atrophic scar; nodules may appear in the scar. Face and buttocks are common sites.
- ❖ *Scrofuloderma*: Contiguous involvement of skin from an underlying tuberculous focus (lymph node, bone, and joint). Manifests as chronic sinuses with hyperpigmented undermined edges.
- ❖ *Tuberculosis verrucosa cutis*: Inoculation (*i.e.*, exogenous) tuberculosis. Single, indurated, verrucous plaque. Usually on acral parts.

Investigations: Biopsy confirmatory. Culture of *M. tuberculosis* only infrequently positive from some lesions. Look for tuberculosis in other organs.

Treatment: Eight weeks of four drugs (INH, rifampicin, ethambutol, and pyrazinamide) followed by 16 weeks of two drugs (INH and rifampicin).

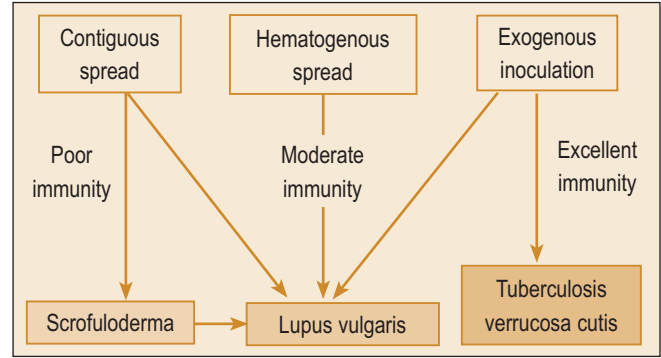


Fig. 14.15. Spectrum of cutaneous tuberculosis.

Etiology

- ❖ *Mycobacterium tuberculosis* (*M. tuberculosis*).
- ❖ Infection with atypical mycobacteria can clinically closely resemble *M. tuberculosis* infection of the skin.

Pathogenesis (Fig. 14.15)

Manifestations of *M. tuberculosis* infection of skin depend on several factors:

❖ **Immunity of host:**

- *M. tuberculosis* specific immunity: depending on whether the exposure to bacteria is primary or secondary.
- *General immunity of host*: depending on nutritional status, immunosuppression, *etc.*

❖ **Route of entry:** Of organism into skin, (hematogenous or contiguous spread or exogenous inoculation).

❖ **Bacterial load.****Clinical Features**

Common presentations (Table 14.3) of cutaneous tuberculosis include:

- ❖ Lupus vulgaris.
- ❖ Scrofuloderma.
- ❖ Tuberculosis verrucosa cutis.
- ❖ Tuberculides.

Lupus vulgaris**Morphology**

- ❖ Single (or few) lesions.
- ❖ Well-demarcated, annular (Fig. 14.16A) or arcuate (Fig. 14.16B) plaques which slowly extend

8. **Benzathine penicillin:** long-acting penicillin, given as 1.2 million units, intramuscularly every 2–3 weeks, after ruling out penicillin hypersensitivity.

Table 14.3. Classification of tuberculosis

Source	Clinical presentation
Exogenous source	Tuberculous chancre (rare) Tuberculosis verrucosa cutis
Endogenous source	
Contiguous spread	Scrofuloderma
Auto-inoculation	Orificial tuberculosis
Hematogenous spread	Miliary tuberculosis Lupus vulgaris Gumma
Eruptive	Tuberculides

centrifugally. Periphery shows erythematous to brownish, deep-seated nodules which on **diascopy**⁹ may stand out as **apple jelly nodules**¹⁰. Over period of time, the center becomes atrophic (paper thin), depigmented and scarred. Characteristically, new nodules may appear within area of scarring (Fig. 14.16B).

Sites of predilection

- ❖ Buttocks, upper extremities, and face.

Complications

- ❖ Ulceration.
- ❖ Hypertrophic lesions.
- ❖ Rarely, squamous cell carcinoma.

Scrofuloderma

Scrofuloderma is a cutaneous tuberculosis due to direct extension of infection from an underlying tuberculous focus present either in lymph nodes (cervical, less often axillary and inguinal), a bone or a joint.

Morphology

- ❖ Initially the lesion manifests as a bluish red, painless swelling, which breaks open after several weeks to form sinuses (Fig. 14.17A).
- ❖ Mouth of the sinus is irregular and has a blue, undermined edge (Fig. 14.17B). The sinuses discharge watery or caseous material.
- ❖ Ulcers, when present, are linear or serpiginous with undermined, bluish edge, and a floor with granulation tissue.
- ❖ Base formed of underlying tuberculous focus—matted lymph nodes, bone or joint.

Sites of predilection

- ❖ Cervical (most frequent) axillary and inguinal lymph nodes.

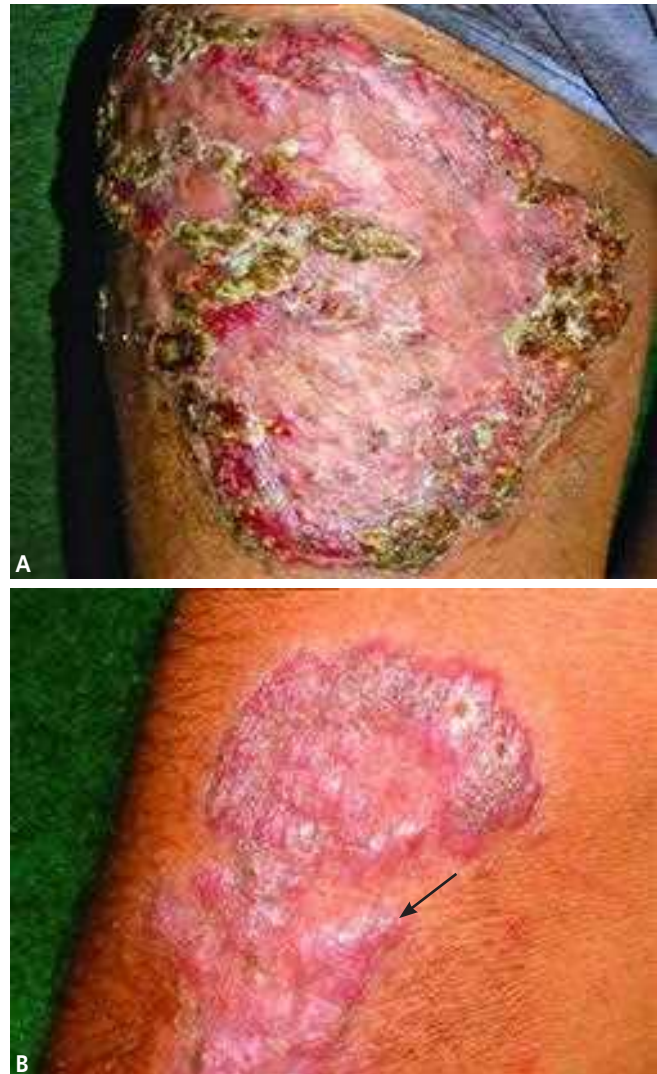

Fig. 14.16. Lupus vulgaris: A: well-defined annular plaque with central scarring. B: sometimes the lesion is arcuate. Note nodules in scar

- ❖ Legs, from tuberculous osteomyelitis and skin over sternoclavicular joint.

Tuberculosis verrucosa cutis

Morphology

- ❖ Single, indolent verrucous (warty) nodule with a serpiginous edge and an erythematous areola (Fig. 14.18). The base is indurated. Clefts and fissures of the warty plaque discharge pus and the center may show some scarring.
- ❖ Lymphadenopathy is rare.

9. **Diascopy:** lesion is pressed with a clean glass slide to blanch the erythema. The basic character of the nodule then becomes obvious.

10. **Apple jelly nodules:** characterized by yellow-brown nodules with tiny darker granules. On probing, the nodules are soft jelly like.

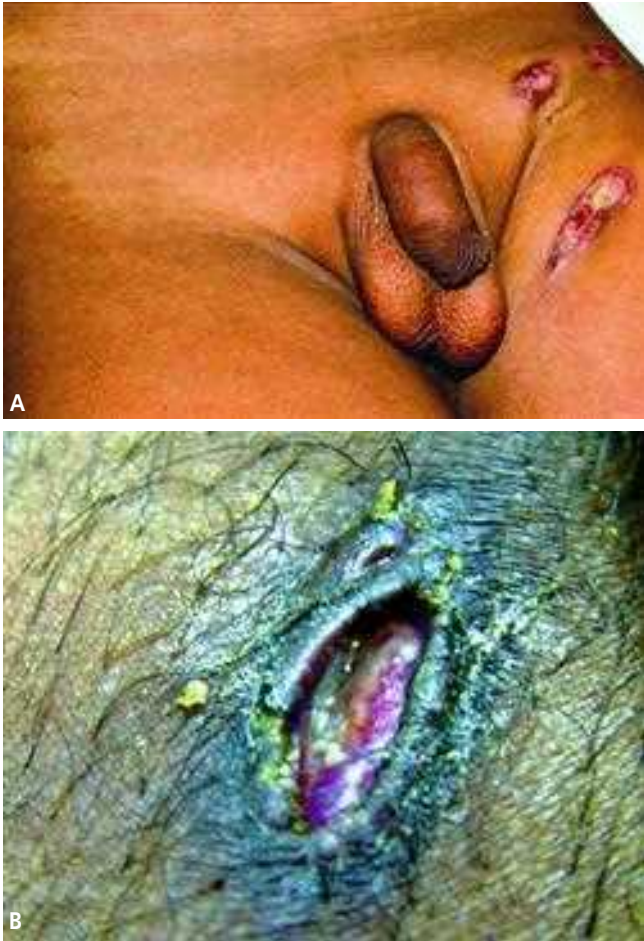

Fig. 14.17. Scrofuloderma. A: commonly follows rupture of tubercular lymphadenitis. B: mouth of the sinus is undermined and hyperpigmented.

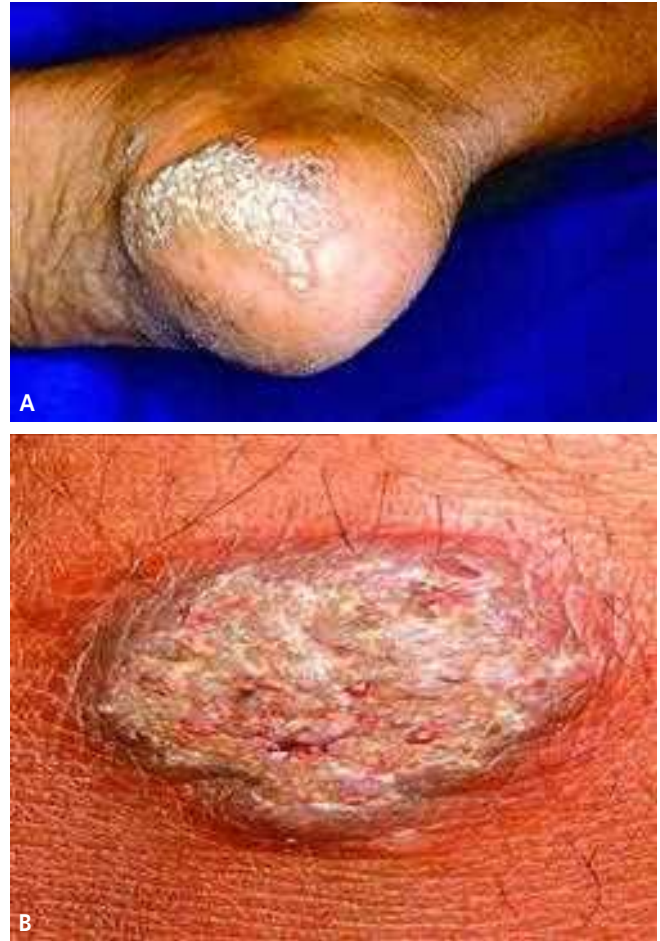

Fig. 14.18. Tuberculosis verrucosa cutis: A and B: verrucous plaque on trauma-prone sites. There is invariably an underlying induration.

Sites of predilection

Trauma-prone sites like hands and feet.

Tuberculides

- ❖ Group of diseases which may be a hypersensitivity reaction to *M. tuberculosis*.
- ❖ They are characterized by the following:
 - Evidence of manifest or past tuberculosis.
 - A positive tuberculin test.
 - Tuberculous granuloma on histology, often with caseation.
 - Absence of bacilli in skin biopsy specimens and culture, although PCR may detect mycobacterial DNA in some forms.
 - Response to antitubercular treatment.
- ❖ The well-established tuberculides include:
 - *Lichen scrofulosorum* (Fig. 14.19).
 - *Papulonecrotic tuberculide*.

Investigations

To confirm diagnosis of tuberculosis

Biopsy

Caseating granuloma (Fig. 14.20) is pathognomonic of tuberculosis though there may be differences between the morphological variants.

Isolation of *M. tuberculosis*

- ❖ Acid fast bacilli in pus and culture of *M. tuberculosis* may be possible, but only from some lesions (<10%).
- ❖ Usefulness of polymerase chain reaction in identifying *M. tuberculosis* from skin is doubtful.

Mantoux test

To rule out concomitant tuberculosis in other organs

- ❖ **Chest X-ray:** To rule out pulmonary tuberculosis.

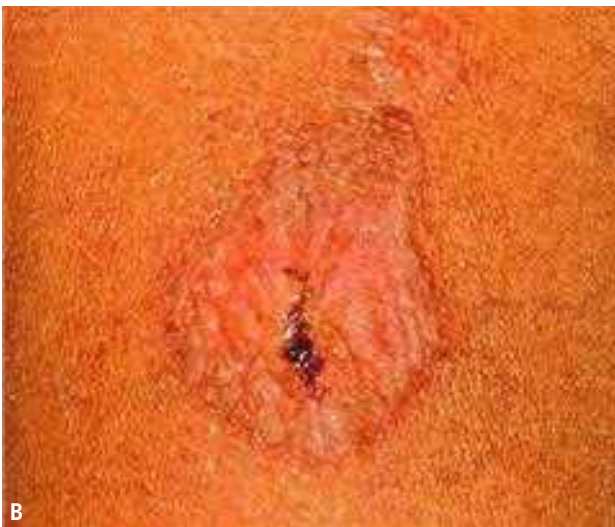
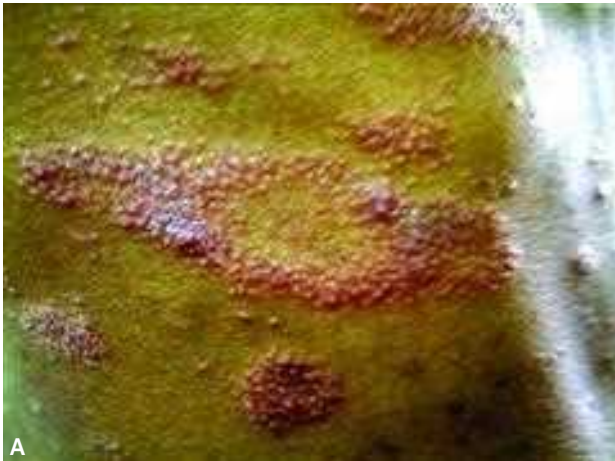
Fig. 14.19. Lichen scrofulosorum: A: grouped shiny papules on trunk. B: strongly positive Mantoux test in the same patient.

- ❖ **X-ray of bones/joints:** To rule out underlying bone or joint tuberculosis in scrofuloderma.
- ❖ **Fine needle aspiration cytology:** Of enlarged lymph nodes.

Diagnosis

Points for diagnosis

The diagnosis of cutaneous tuberculosis is based on:

- ❖ Chronicity of lesions.
- ❖ Characteristic morphology:
 - *Lupus vulgaris*: annular/arcuate, indurated, brownish plaque(s) with periphery showing deep-seated nodules with apple jelly appearance on diascopy and central atrophy and depigmentation. New nodules continue to develop in scarred area.

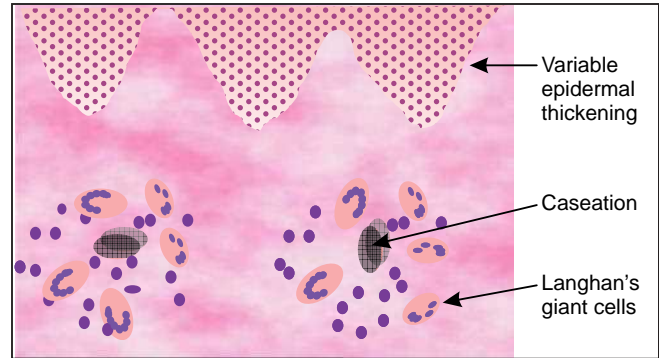


Fig 14.20. Histopathology of tuberculosis: shows a caseating granuloma.

- *Scrofuloderma*: multiple sinuses with undermined edge at the mouth; arises from underlying, matted lymph nodes (frequently) or bone or joint (less frequently).
- *Tuberculosis verrucosa cutis*: appears as a single, indurated, verrucous plaque with a serpiginous edge and may show some scarring at the center; lesions on trauma prone sites.
- ❖ Characteristic histology of a caseating granuloma.

Differential diagnosis

Lupus vulgaris (LV)

Needs to be differentiated from:

a. Discoid lupus erythematosus (DLE)

DLE	LV
Plaque: not indurated with hyperpigmented border.	Indurated with deep-seated nodules at periphery
Centre: depigmented, atrophic center. Adherent scales and follicular plugs	Depigmented and scarred. Nodules may appear in a scarred area
Location: face, scalp, ears	Face, buttocks

Tuberculosis verrucosa cutis (TVC)

Should be differentiated from:

a. *Verruca vulgaris (VV)*

VV	TVC
Number of lesions: usually multiple lesions	Single
Discharge: absent	Serous discharge from clefts
Scarring: absent	Scarring in center
Induration: absent	Present

Treatment

Standard antituberculosis therapy with four drugs for 8 weeks followed by two drugs for 16 weeks is

recommended (Table 14.4). Drugs should be taken on an empty stomach, once daily.

Table 14.4. Treatment of cutaneous tuberculosis

	Duration	Drugs	Daily dose
Intensive phase	8 weeks	Isoniazid	5 mg/kg
		Rifampicin	10 mg/kg
		Ethambutol	15 mg/kg
		Pyrazinamide	30 mg/kg
Maintenance phase	16 weeks	Isoniazid	5 mg/kg
		Rifampicin	10 mg/kg

Leprosy

Synopsis

Etiology: *Mycobacterium leprae*. Manifestations depend on patient's (cell mediated) immunity.

Diagnostic criteria: At least 1 of the 2 following cardinal criteria should be present: (a) Hypopigmented/erythematous skin lesion(s) with involvement of peripheral nerves (thickening of nerves, sensory impairment and/or motor weakness). (b) Positive skin smears for AFB.

Main organs/tissues involved: Skin and peripheral nerves.

Morphology: *Prototype skin lesion:* atrophic, hypopigmented, an(hypo)esthetic macules or plaques (with papules and nodules seen in lepromatous end of spectrum) with loss of appendages (so absent hair and sweating). Depending on number, size, symmetry, morphology and degree of sensory deficit in skin lesions and numbers of nerves affected, classified as: *Indeterminate leprosy:* Ill-defined macule (always a macule) ± sensory impairment on face of children. *Tuberculoid leprosy (TT):* Single (or few), well-defined anesthetic lesion(s). Regional nerve(s) thickened. *Borderline tuberculoid (BT):* Few, well-defined, hypoesthetic lesions with satellite lesions. Few nerves involved. *Borderline (BB):* Multiple, bilateral (not symmetrical) annular plaques (inverted saucer appearance) with hypoesthesia. Few nerves involved. *Borderline lepromatous (BL):* Multiple (with tendency to symmetry), minimally hypoesthetic ill-defined lesions. Many nerves (bilateral, tendency to symmetry) involved. *Lepromatous leprosy (LL):* Widespread symmetrical normoesthetic macules, papules, nodules, and infiltration. Symmetrical nerve involvement with glove and stocking sensory impairment. Systemic (eyes, testes, and reticuloendothelial system) involvement common.

Reactions: Two recognized: *Type 1* seen in borderline leprosy (BT, BB, BL) and *type 2* (ENL) in BL and LL.

Complications: Motor palsies (claw hand, foot drop and facial palsy), trophic ulcers, and eye complications.

Diagnosis: *Of leprosy:* Based on cardinal features. *Of type of leprosy:* Based on clinical, histological, immunological and bacteriological criteria (Ridley–Jopling classification).

Treatment: For purpose of therapy, classified into *paucibacillary* (PB) and *multibacillary* (MB) leprosy (five or fewer lesions and more than five lesions, respectively). Multidrug therapy. *In PB:* with daily dapsone 100 mg **and** monthly supervised rifampicin 600 mg × 6 months. *In MB:* with daily dapsone 100 mg and clofazimine 50 mg **and** monthly supervised rifampicin 600 mg and clofazimine 300 mg × 12 months. *Reactions: Type 1:* oral steroids, and NSAIDs; *Type 2:* oral steroids, NSAIDs, and thalidomide.

Control strategy: With lowering prevalence (elimination: prevalence <1/10,000), focus shifted to prevention of disability and medical rehabilitation (PODMR) and reconstructive surgery (RCS).

Etiology

- ❖ *Mycobacterium leprae* (*M. leprae*), an acid fast organism.
- ❖ Route of infection not established, but current evidence favors respiratory transmission.
- ❖ Type of disease which develops, depends on the host's immunological response and not on the virulence of the organism.
- ❖ *M. leprae* cannot be cultured *in vitro* but can be grown in **animal models** like:
 - Mouse foot pad.
 - Thymectomized irradiated mice.
 - Nude mice.
 - Nine-banded armadillos.

Epidemiology

Leprosy is a global disease. Prevalence of leprosy has fallen substantially and most endemic countries including India have achieved elimination of leprosy (Table 14.5). There are several factors for this gratifying fall in prevalence of leprosy:

- ❖ Institution of multidrug therapy, as recommended by WHO.

Table 14.5. Epidemiology of leprosy

Global new cases detected (2009)	2,44,796
Global prevalence (2009)	0.354/10,000
New cases detected in India (2009)	1,33,717
Prevalence of leprosy in India (2009)	0.72/10,000

- ❖ Availability of potent antileprosy drugs.
- ❖ Better surveillance and control strategies.

Two terms need definition when we discuss control strategies in leprosy:

- ❖ **Elimination of leprosy:** Reduction in prevalence of leprosy to below 1/10,000 population, so that it is no longer a public health problem.
- ❖ **Eradication of leprosy:** Complete absence of transmission due to total disappearance of disease causing organism.

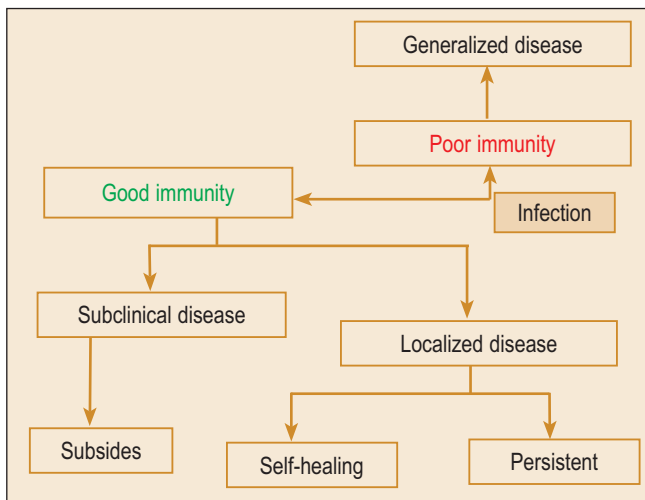


Fig. 14.21. Relationship between clinical disease and immunological status of patient in leprosy.

While it may be feasible to eliminate leprosy as a public health problem in near future, it would probably take much longer to eradicate the disease.

With lowering prevalence, the focus of control strategies has shifted to:

- ❖ Prevention of disability and medical rehabilitation (PODMR).
- ❖ Reconstructive surgery (RCS).

Pathogenesis (Fig. 14.21)

- ❖ Studies on pathogenesis of leprosy are hampered by:
 - Long incubation period.
 - Absence of culture medium.
 - Paucity of animal models.
- ❖ There is no difference in the virulence of the organism causing localized or generalized disease.
- ❖ The clinical features of leprosy depend on the immunological status of the host:

- If the host mounts a good cell-mediated response, the infection is localized and does not spread.
 - If the host does not mount an immunological response to *M. leprae*, the infection is disseminated in skin and viscera.
- ❖ Both T-cell and macrophage dysfunction occur in lepromatous leprosy.

Classification

Ridley–Jopling classification

Depending on clinicopathological, immunological, and bacteriological features (Fig. 14.22), leprosy is classified into polar (stable) leprosy and borderline (unstable) leprosy (**Ridley–Jopling classification**):

- ❖ Tuberculoid leprosy (TT)
 - ❖ Borderline tuberculoid (BT)
 - ❖ Mid borderline (BB)
 - ❖ Borderline lepromatous (BL)
 - ❖ Lepromatous leprosy (LL).
- } Unstable leprosy } Stable or polar leprosy

Only the two polar forms, tuberculoid leprosy (TT, seen in patients with very good immunity) and lepromatous leprosy (LL, in patients with poor immunity) are stable; the other forms (borderline group) of leprosy are unstable, *i.e.*, the disease may worsen from BT→BB→BL; in contrast, with treatment (with antileprosy drugs), the disease may move in the opposite direction (BL→BB→BT).

There are three other types of leprosy which are seen:

- ❖ Indeterminate leprosy.
- ❖ Histoid leprosy.
- ❖ Neuritic leprosy.

Other classifications

- ❖ Madrid classification
- ❖ Indian classification.

Clinical Features

Cardinal signs

- ❖ According to WHO, in an endemic area, an individual should be regarded as having leprosy if he or she shows ONE of the following cardinal signs:
 - ❖ Skin lesion(s) consistent with leprosy with definite sensory loss, with or without thickened nerves.
 - ❖ Skin smears positive for acid fast bacilli.
 - ❖ A person presenting with skin lesions or with symptoms suggestive of nerve damage, in whom

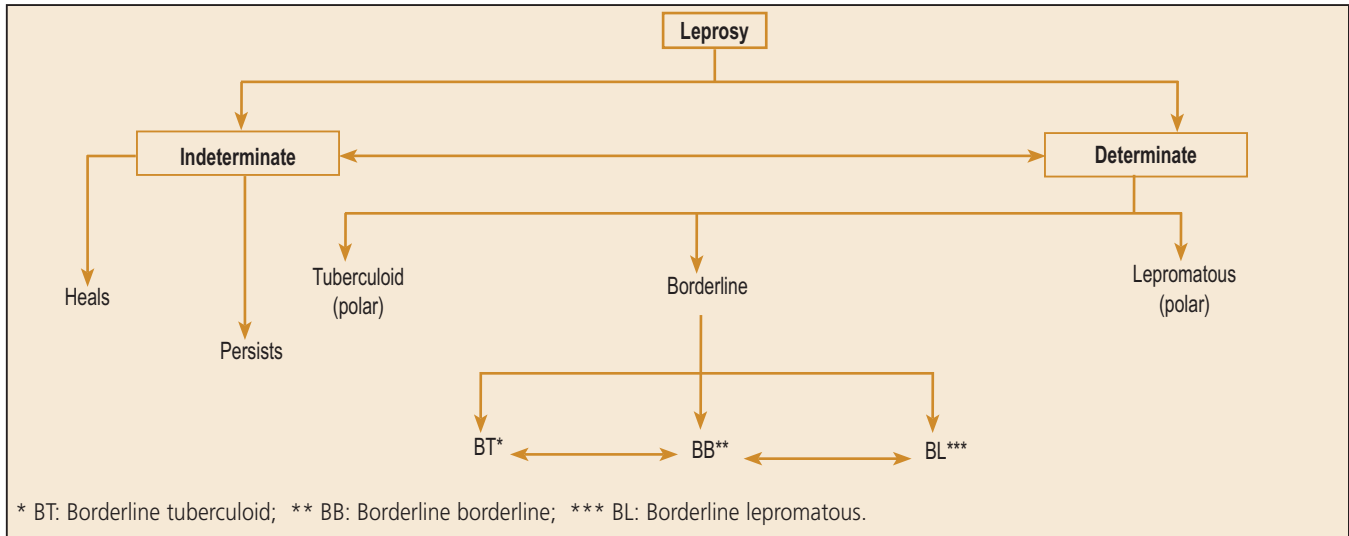


Fig. 14.22. Leprosy: Ridley–Jopling classification.

the cardinal signs are absent or doubtful, should be called a 'suspect case' in absence of an obvious alternate diagnosis. Such individuals should be counselled and advised to follow up if signs persist for more than 6 months or if there is any worsening. Suspect cases may be also sent to referral clinics with more facilities for diagnosis.

Prototype skin lesion(s)

- ❖ Can be single (TT) or multiple (LL).
- ❖ Are usually hypopigmented, though may be erythematous.
- ❖ Are usually macules or plaques though in BL and LL, papules or nodules may be seen.
- ❖ May be well-defined (TT, BT) or poorly defined (BL, LL). A well-defined plaque of leprosy has 'cliff edge' (⊔) and a less-defined plaque has a sloping edge (⊓).
- ❖ Show epidermal atrophy, so the lesions appear shiny. When nodules of BL and LL patients subside, there may be dermal atrophy.
- ❖ Show loss of appendages (so absent hair and sweating). This is more conspicuous in TT and BT, so these lesions may appear dry.
- ❖ Show an(hypo)esthesia. Lesions of TT are anesthetic, of BT, BB, BL are hypoesthetic (more for BT, less for BL) while those of LL may be normoesthetic. The first sensation to be affected is nociception (temperature and pain).

Nerve involvement

- ❖ Thickened peripheral nerves is typical. Apart from larger nerve trunks, a feeder nerve to the skin lesion may be thickened.
- ❖ A thickened nerve is accompanied by signs of nerve damage¹¹ in form of loss/reduction of sensation in skin lesions (most in TT, least in LL) or in distal part of extremities—**glove and stocking anesthesia** (in BL, LL) and weakness of muscles supplied by the affected nerve.
- ❖ Nodularity (in TT, BT) and tenderness (in reactions) may be present.

Positive skin smears

- ❖ Smears are taken from skin lesions, ear lobules, eye brows, and sometimes dorsae of fingers.
- ❖ In a small proportion of patients (BL, LL and few BB and indeterminate) on Zeihl–Neelsen staining, rod-shaped, red-stained leprosy bacilli may be seen.

Indeterminate leprosy

- ❖ Seen on face of children, in endemic areas.
- ❖ **Always a macule**; ill-defined, atrophic, hypoesthetic, or normoesthetic¹², hypopigmented or slightly erythematous lesion with or without nerve thickening (Fig. 14.23).

11. **Signs of nerve damage:** nerve thickening by itself, without sensory/motor impairment, is often not a reliable sign of leprosy.

12. **Normoesthetic:** very often, small lesions of leprosy on face do not have a sensory deficit because of rich innervation and overlap of distribution.

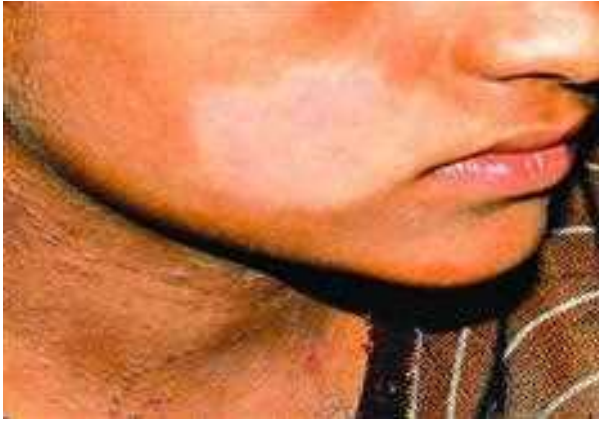

Fig. 14.23. Indeterminate leprosy: ill-defined, hypopigmented, hypoesthetic lesion on the face; the lesion is always macule.

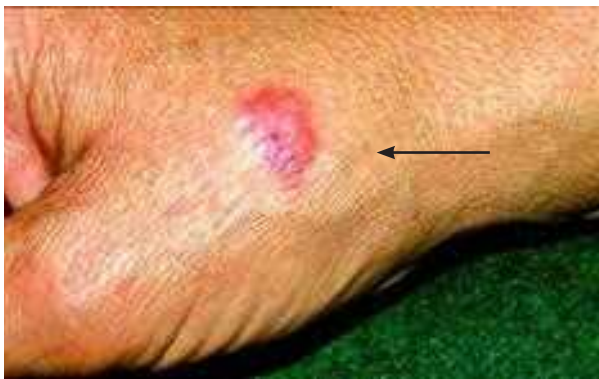

Fig. 14.24. Tuberculoid leprosy: well-defined hypopigmented, hypoesthetic plaque. Note the feeder nerve.

Tuberculoid leprosy (TT)

- ❖ Localized form of infection—very infrequent.
- ❖ One (or two), asymmetrically located lesions.
- ❖ Well-defined, hypopigmented, anesthetic macule(s) or plaque(s), often with an active border (Fig. 14.24). The lesions show hair loss and impairment of sweating.
- ❖ A superficial feeder nerve or a single regional nerve is often thickened and may even be nodular¹³.

Lepromatous leprosy (LL)

LL is a systemic disease, characterized by extensive cutaneous, neural, and systemic involvement.

Facial lesions (Fig. 14.25)

- ❖ Diffuse infiltration of the face, ear lobules, and alae nasi (Figs. 14.25A and B).

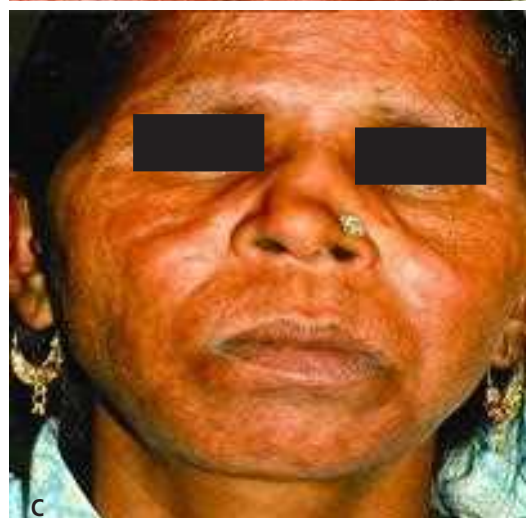
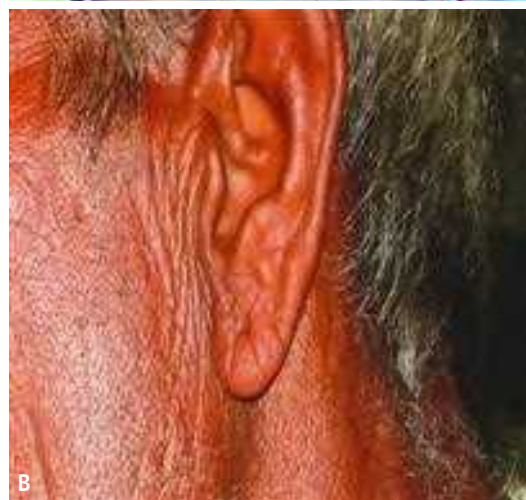
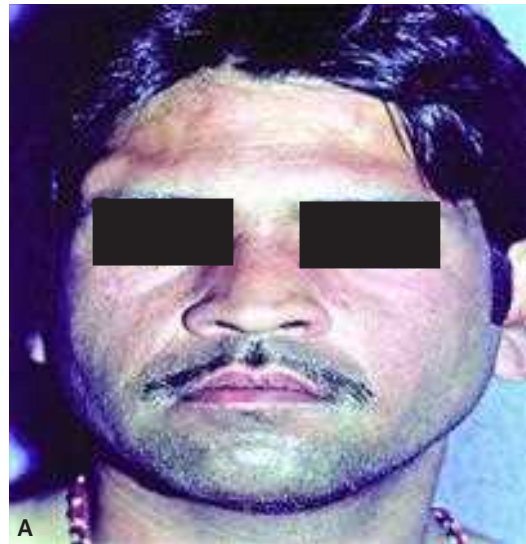Fig. 14.25. Lepromatous leprosy: A: diffuse infiltration of face. B: infiltration of ear lobule. C: nasal deformity and supraciliary madarosis.

13. Nodularity of nerve indicates localization of infection.

- ❖ Loss of lateral third of the eyebrows—**supraciliary madarosis** (Fig. 14.25C).
- ❖ Facial deformities are now rare (Fig. 14.25C).

Cutaneous lesions (Figs. 14.26 and 14.27)

- ❖ Numerous, symmetrically distributed lesions.
- ❖ Three different types of skin lesions are seen:
 - *Macules*: small, hypopigmented/erythematous ill-defined (often barely perceptible),

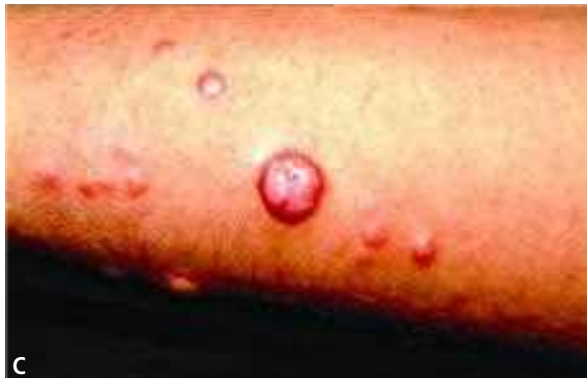
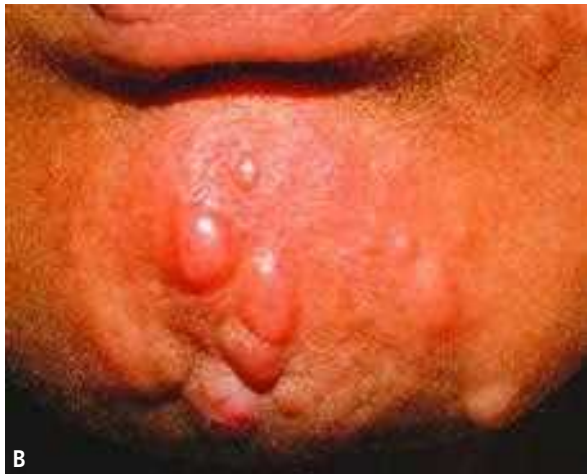
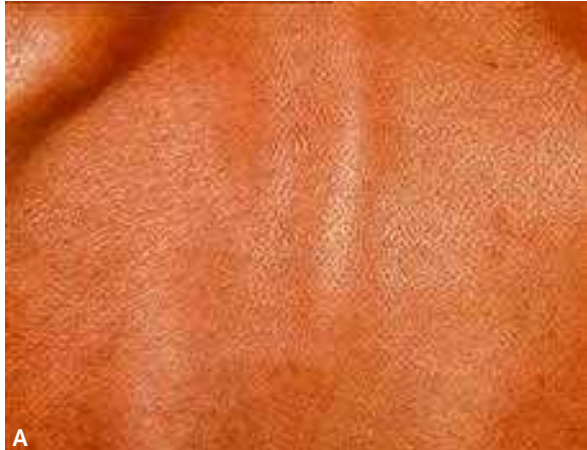Fig. 14.26. Lepromatous leprosy: A: multiple barely perceptible lesions on back. B: lepromatous nodules on infiltrated skin on chin. C: histoid nodules on normal skin.

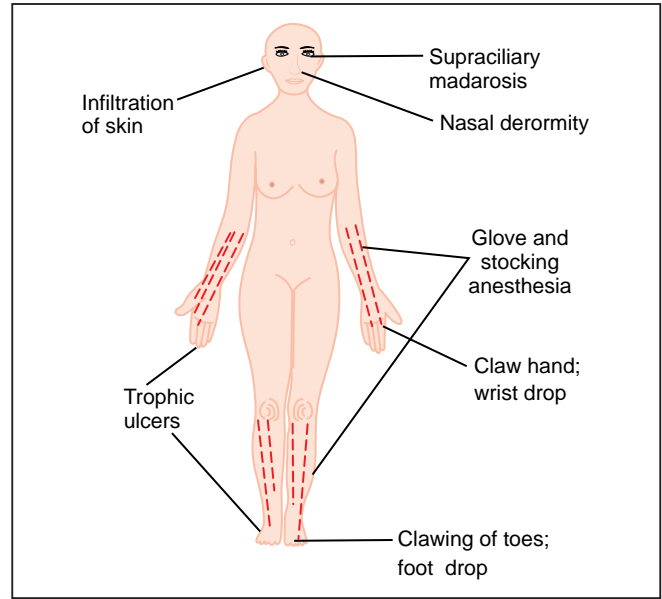


Fig. 14.27. Lepromatous leprosy: some clinical manifestations.

mostly confluent macules (Fig. 14.26A). Hypoesthesia is minimal.

- *Papulonodules*: most frequent type of lesions in LL. Ill-defined, dull red papules and nodules on diffusely infiltrated skin (Fig. 14.26B).
- *Histoid leprosy*: a distinct variant of LL characterized by presence of well-demarcated, juicy cutaneous and subcutaneous nodules (Fig. 14.26C), present on normal looking skin (*cf.*, lepromatous nodules are ill defined and present on infiltrated skin).

- ❖ Other manifestations of leprosy include peripheral anesthesia, trophic ulcers, and motor dysfunction (Fig. 14.27).

Nerve involvement (Figs. 14.27 and 14.28)

- ❖ Bilaterally symmetrical peripheral nerve thickening.
- ❖ Nerves may become tender, especially in type 2 reaction.
- ❖ Nerve function impairment (NFI) occurs late in lepromatous leprosy and manifests as glove and stocking anesthesia (and consequent trophic changes including trophic ulcers) and motor deficits (Fig. 14.27).

Systemic involvement

Systemic involvement is common and manifests as:

- ❖ Lymphadenopathy.
- ❖ Hepatosplenomegaly.
- ❖ Ocular involvement.
- ❖ Testicular atrophy.

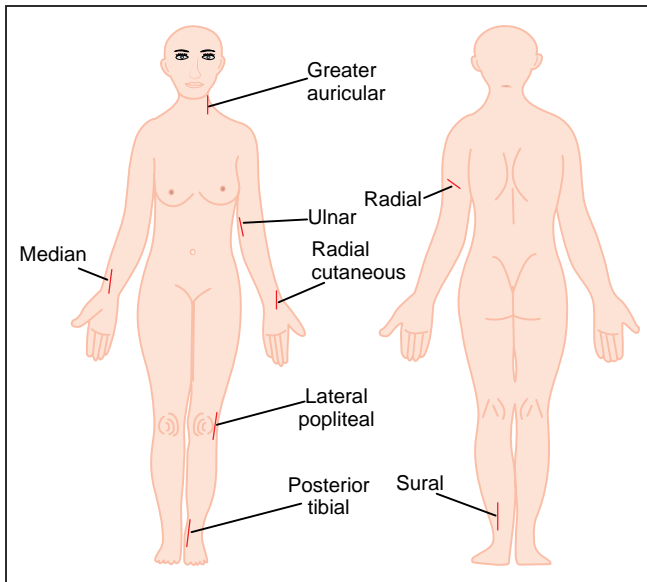


Fig. 14.28. Lepromatous leprosy: nerve involvement.

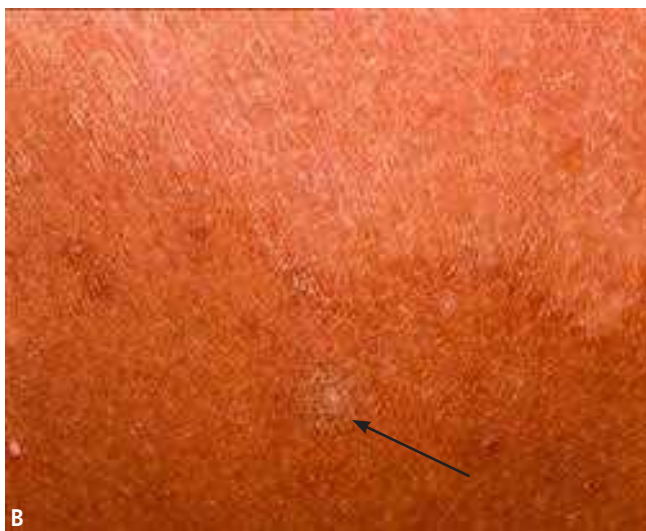
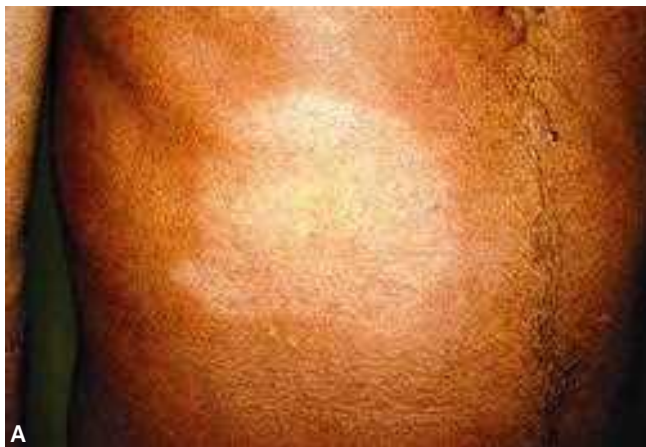
Fig. 14.29. Borderline tuberculoid leprosy: A: well-defined, hypoesthetic, erythematous plaque. B: with a satellite lesion.

BT leprosy

Lesions are large, hypopigmented macules or plaques. They differ from TT in that they are:

- ❖ Less sharply demarcated, having satellite lesions (Figs. 14.29A and B).
- ❖ More in number.
- ❖ Less asymmetrical.
- ❖ Less hypoesthetic.
- ❖ Few nerves may be asymmetrically thickened.

BL leprosy (Fig. 14.30)

Resembles LL, but differs from it in that:

- ❖ Lesions are bilateral, less symmetrical.

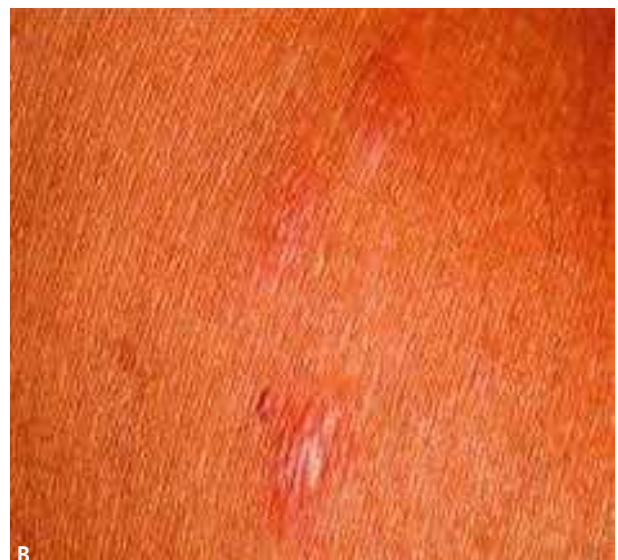
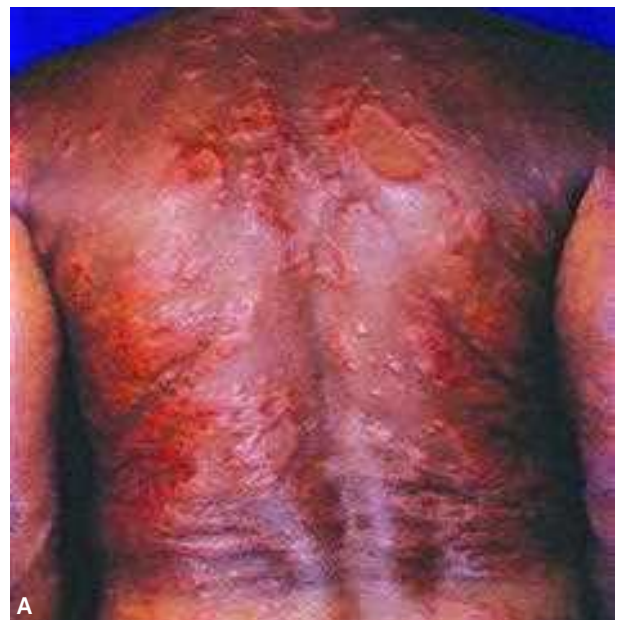
Fig. 14.30. Borderline lepromatous leprosy: A: multiple plaques present almost symmetrically. B: lesions are small and ill defined.

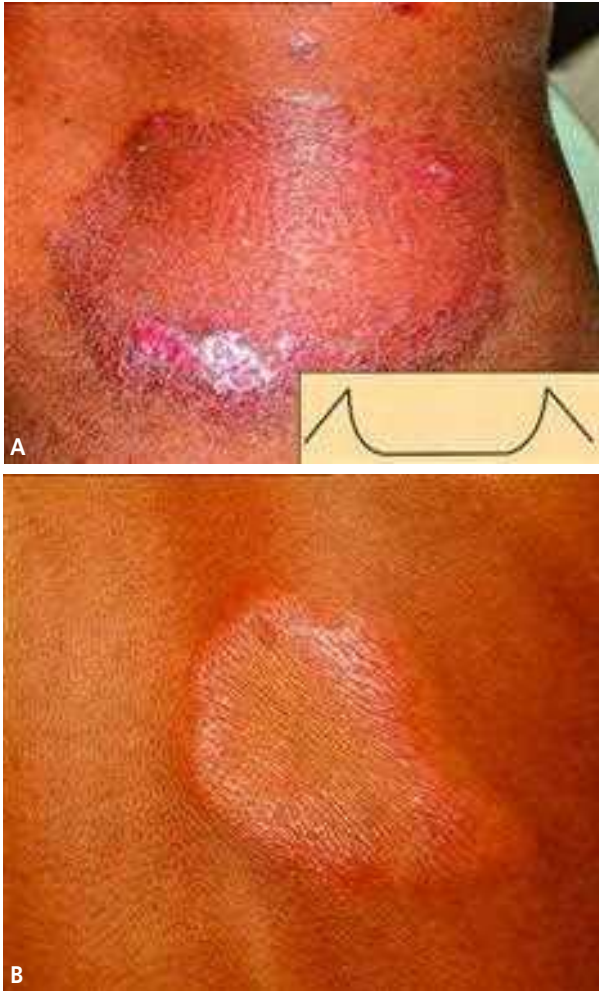

Fig. 14.31. Borderline leprosy: erythematous, annular plaques. B: lesion with an inverted saucer appearance. Inset: inverted saucer appearance.

- ❖ Lesions may be hypoesthetic.
- ❖ Are small but larger than LL.
- ❖ Peripheral nerve involvement is bilateral, with tendency to asymmetry.

BB leprosy (Fig. 14.31)

- ❖ Numerous lesions, distributed asymmetrically.
- ❖ Lesions are characteristically erythematous, raised annular plaques with central clearing and sloping edges (**inverted saucer appearance**).
- ❖ Lesions are hypoesthetic.
- ❖ Multiple, asymmetrically thickened nerves.

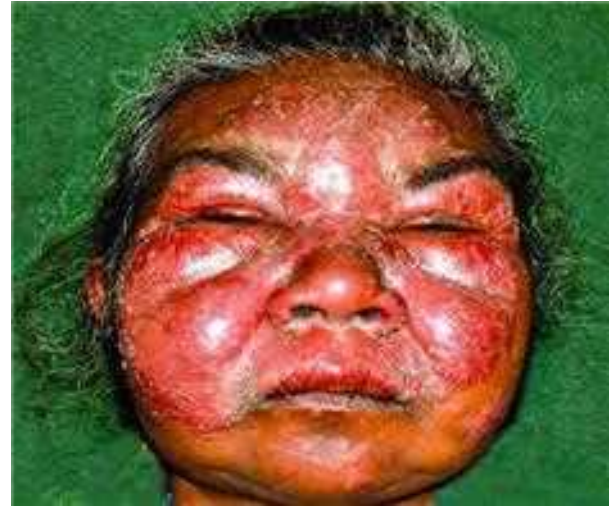

Fig. 14.32. Leprosy in type 1 reaction: erythema, edema and scaling of pre-existing lesions.

Reactions in leprosy (lepra reactions)

- ❖ Reactions in leprosy are acute episodes in the chronic course of leprosy.
- ❖ Two types of reactions occur in leprosy—type 1 and type 2 reactions.

Type 1 lepra reaction

- ❖ Occurs in borderline leprosy (the unstable varieties—BT, BB and BL).
- ❖ **Pathogenesis:** Is due to **alteration in the host's CMI**. Depending on whether there is an improvement or deterioration of CMI, type 1 reaction can be:
 - *Upgrading reaction or reversal reaction:* when CMI improves, as seen in patients on treatment (BL→BB→BT).
 - *Downgrading reaction¹⁴:* when cell-mediated immunity (CMI) worsens, as seen in the natural course of the disease and in **pregnancy¹⁵** (BT→BB→BL).

❖ **Manifestations:** Characterized by:

- Erythema, edema, and scaling of the pre-existing lesions (Fig. 14.32).
- Appearance of new lesions.
- Neuritis, clinically manifesting as nerve tenderness, and appearance of increasing new areas of sensory impairment and motor deficits.

14. **Downgrading reaction:** some leprologists do not subscribe to the concept of downgrading reaction and believe it to be natural down hill course of untreated disease.

15. **Pregnancy:** a natural state of depressed CMI.

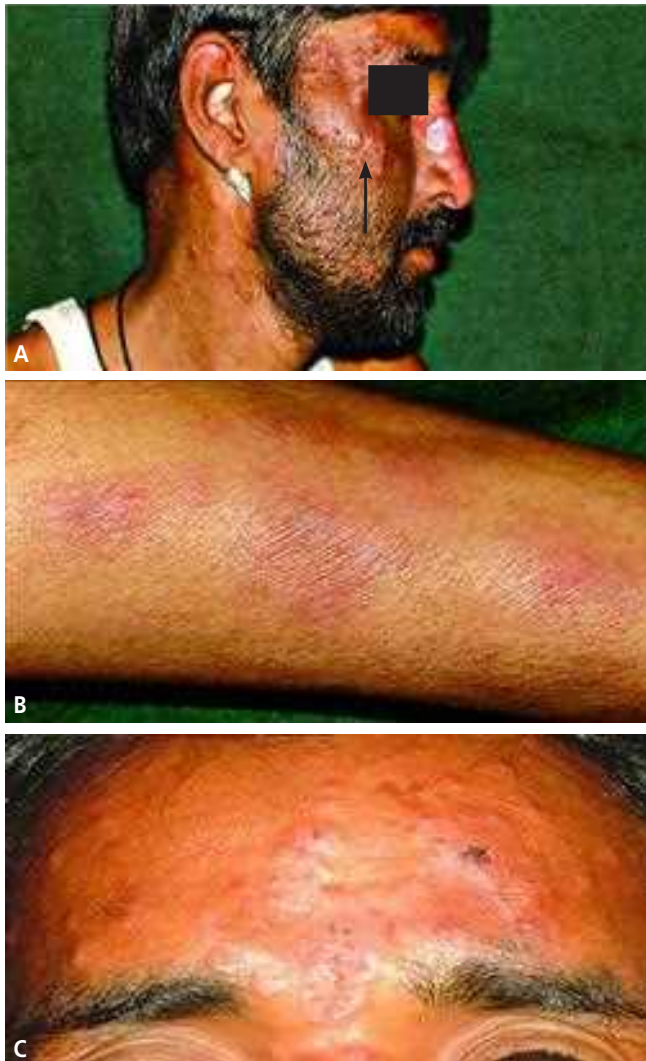

Fig.14.33. Erythema nodosum leprosum: A: evanescent, tender, erythematous nodules. B: close up of lesions. C: necrotic ENL.

Type 2 lepra reaction (erythema nodosum leprosum or ENL)

- ❖ Occurs most commonly in LL and sometimes in BL leprosy.
- ❖ **Pathogenesis: Immune complex reaction**¹⁶.
- ❖ **Manifestations:** Characterized by:
 - ENL: appearance of several tender, evanescent, erythematous nodules on face, flexures, and legs (Figs. 14.33A and B); sometimes these lesions may become pustular and ulcerate (necrotic ENL; Fig. 14.33C).
 - Neuritis.

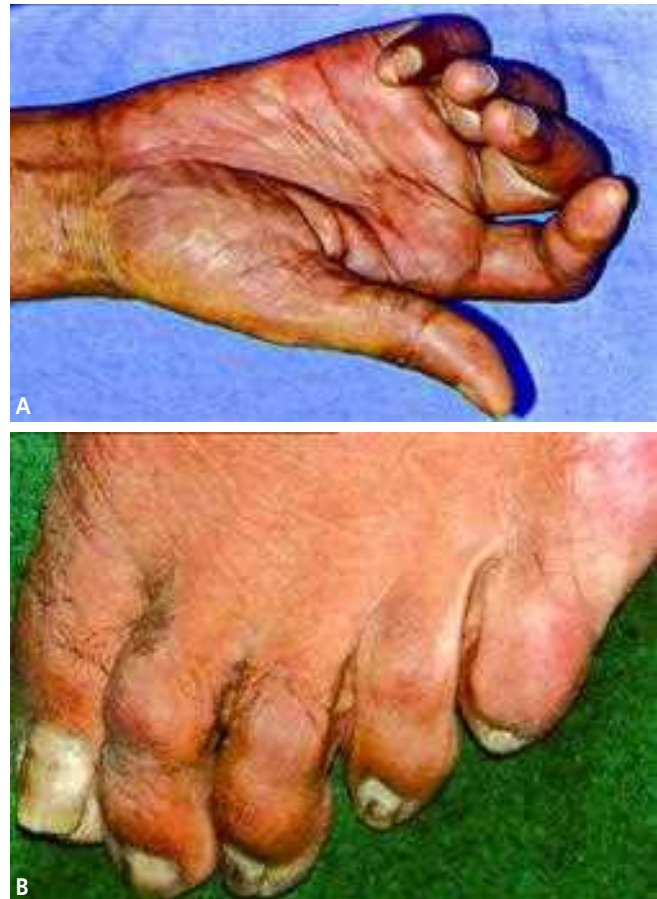

Fig. 14.34. A: Claw hand: a 36-year-old patient developed progressive weakness of the muscles of his hands associated with neuritis of ulnar and median nerves. B: clawing of toes: he also had clawing of the toes due to involvement of posterior tibial nerve.

- Arthralgia, orchitis, and iridocyclitis.
- Fever.

Complications of leprosy

Deformities

- ❖ **Motor deficits:** In form of claw hand (ulnar and median nerve; Fig. 14.34A) clawing of toes (posterior tibial nerve; Fig. 14.34B) and foot drop (common peroneal nerve) are more pronounced in tuberculoid end of the spectrum and may be due to silent or overt neuritis (as in reactions).
- ❖ **Facial deformities:** Though facial palsy may be seen (Fig. 14.35), severe deformities are rare (Fig. 14.25C).

16. **Immune complex reaction:** remember, there is an excess of antigen load in BL and LL as well as an increased amount of antibody production due to depressed CMI.

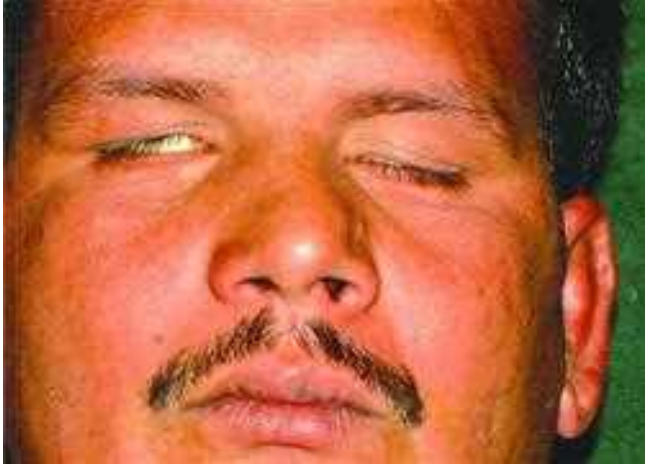

Fig. 14.35. A: Facial palsy: can result in exposure keratitis due to incomplete closure of the eyes.

Trophic ulcers

Develop frequently in LL because sensory impairment appears before motor weakness and the patient continues to “misuse” his hands and feet (Fig. 14.36).

Disabilities

Disabilities in leprosy are graded as:

❖ **Disabilities of hands and feet:** Graded as:

- *Grade 0:* no anesthesia, no visible deformity/damage.
- *Grade 1:* anesthesia present, no visible deformity/damage.
- *Grade 2:* visible deformity present.

❖ **Disability of eyes:** Graded as:

- *Grade 0:* no eye problem due to leprosy.
- *Grade 1:* eye problem due to leprosy but vision not severely affected (vision 6/60 or better. Can count fingers at 6 m).
- *Grade 2:* severe visual impairment (vision less than 6/60, cannot count fingers), lagophthalmos, iridocyclitis, and corneal opacities.

Diminution of vision

Due to a combination of:

- ❖ Diminished corneal sensation.
- ❖ Lagophthalmos.
- ❖ Recurrent iridocyclitis.

Renal involvement

Renal involvement may occur during the course of the disease but is more frequent during type 2 reactions, especially if they are recurrent.

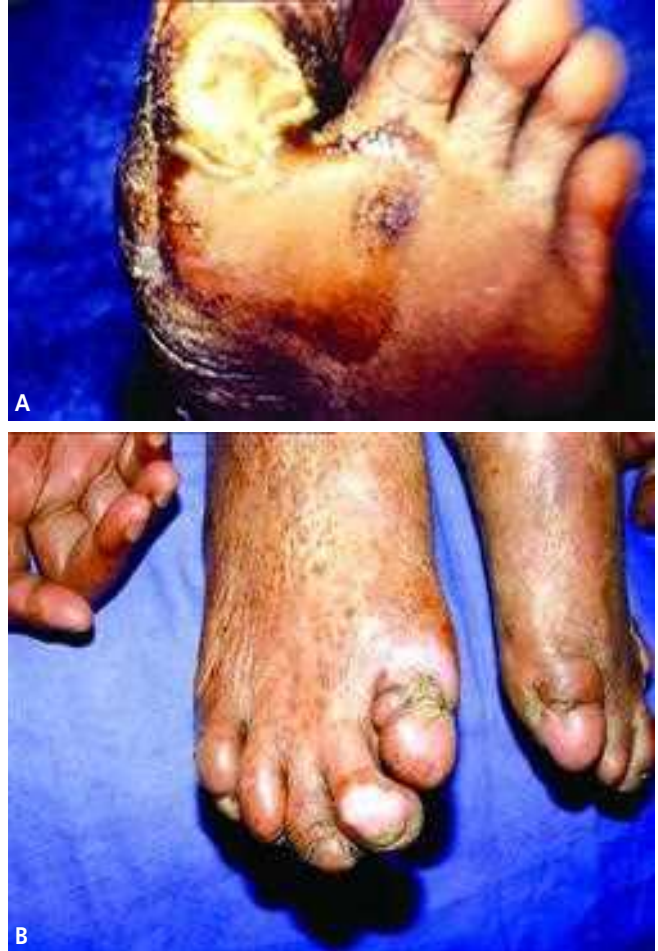

Fig. 14.36. A: Trophic ulcer: well-defined punched out ulcer with hyperkeratotic margins. Ulcers are painless and occur on pressure points. B: over period of time, there is resorption of digits.

Testicular dysfunction

Both impotence and infertility may occur in males with MB leprosy (BL, LL) due to direct infiltration and recurrent orchitis, which occurs during reactions.

Investigations

Tests to confirm diagnosis of leprosy

Slit smear¹⁷

- ❖ Slit smear examination should be done in all patients suspected to have leprosy.
- ❖ Smears are taken from the lesions, from ear lobules and eyebrows and are stained using modified Ziehl–Neelsen method.

17. **Slit smear:** bacteriological index (BI) is done by scoring the number of AFB/high power field using a logarithmic scale.

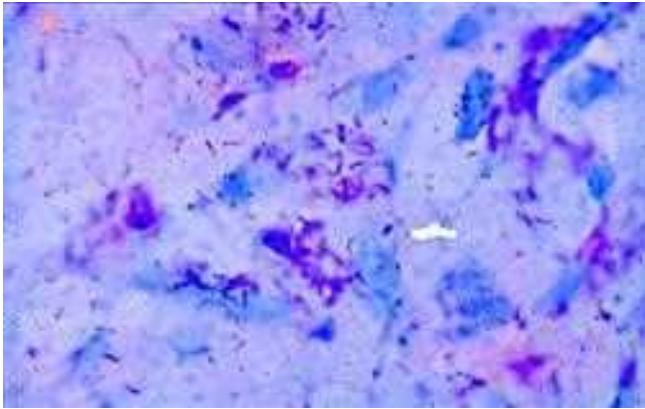


Fig. 14.37. Slit smear: AFB positive. Slit smear is taken from the eyebrows, ear lobes and skin lesions and stained with modified Ziehl-Neelsen method.

- ❖ Presence of AFB (Fig. 14.37) in suggestive skin lesions, even in the absence of sensory deficit, confirms the diagnosis of leprosy. Smears also help in deciding the therapeutic regimen. All patients who are AFB positive should be given multibacillary treatment, irrespective of the clinical presentation.

Histopathology (Fig. 14.38)

Biopsy is important for:

- ❖ Confirming diagnosis of leprosy.
- ❖ Classification of leprosy.

The two characteristic histopathological features in leprosy are:

❖ Granuloma

- *At the tuberculoid end of the spectrum:* the granuloma is well-defined and made up of epithelioid cells, giant cells, and lymphocytes.

- *At the lepromatous end of the spectrum:* the granuloma is ill-defined and full of foamy macrophages laden with AFB.

- ❖ **Nerve involvement:** Including perineural infiltrate, neuritis, and destruction of nerve.

Lepromin test

- ❖ This is not a diagnostic test but is of prognostic value.
- ❖ Lepromin positivity indicates good immunity to *M. leprae* and that the patient has been able to contain the infection, *i.e.*, he has tuberculoid (or borderline tuberculoid) leprosy.
- ❖ Lepromin negativity indicates that the patient has BB, BL or LL type of leprosy.

Tests to evaluate systemic involvement

Hematological parameters

- ❖ **Anemia:** Frequently seen in patients with LL; hemolysis occurs in all patients taking dapsone but usually is of little concern unless the patient is glucose-6 phosphate dehydrogenase deficient.
- ❖ **Leucocytosis:** And an elevation of erythrocyte sedimentation rate are seen in type 2 lepra reaction.

Renal function tests

Renal involvement is seen in LL and in patients with recurrent type 2 lepra reactions.

Radiological examination

- ❖ **Chest X-ray:** Ruling out concomitant pulmonary tuberculosis is important, because otherwise, a patient with associated tuberculosis would receive antituberculous monotherapy with monthly doses of rifampicin.

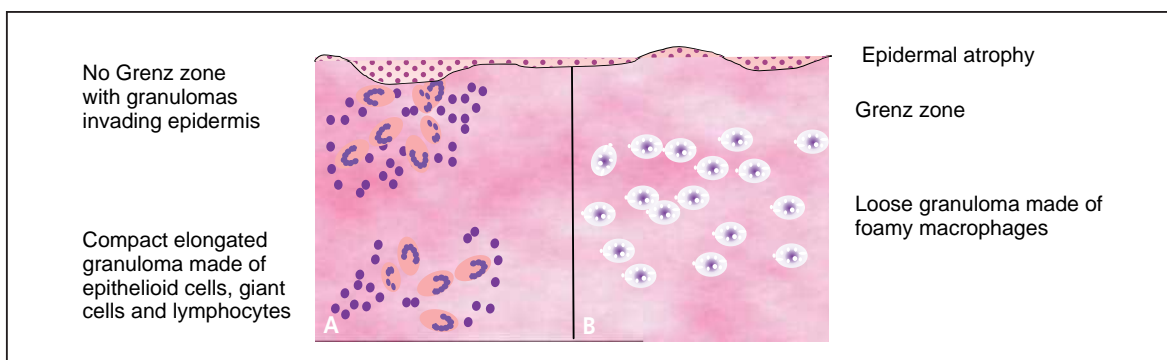


Fig. 14.38. Histopathology of leprosy: A: tuberculoid leprosy: characterized by epidermal atrophy and epithelioid cell granuloma with giant cells and plenty of lymphocytes. The granuloma is typically elongated (along nerves and appendages) and impinges the epidermis. B: lepromatous leprosy: characterized by epidermal atrophy and granuloma consisting of foamy macrophages laden with AFBs and no giant cells or lymphocytes. The granuloma is typically diffuse and separated from epidermis by Grenz zone.

❖ **X-rays of hand and feet:** In patients with trophic ulcers to rule out involvement of underlying bones.

Diagnosis

Points for diagnosis

Cardinal signs of leprosy

- ❖ According to WHO, in an endemic area, an individual should be regarded as having leprosy if he or she shows ONE of the following cardinal signs:
 - Skin lesion(s) consistent with leprosy¹⁸ with definite sensory loss, with or without thickened nerves.
 - Skin smears positive for acid fast bacilli.
- ❖ A person presenting with skin lesions or with symptoms suggestive of nerve damage, in whom the cardinal signs are absent or doubtful should be called a “**suspect case**” in absence of an obvious alternate diagnosis. Such individuals should be counselled and advised to follow up

if signs persist for more than six months or if there is any worsening. Suspect cases may be also sent to referral clinics.

Type of leprosy

After diagnosis of leprosy is established, for a clinician it is important to find out the type of leprosy the patient has (Table 14.6).

Differential diagnosis

Macular lesions

Macular lesions of leprosy need to be differentiated from:

a. Pityriasis versicolor (PV)

PV	Leprosy
<i>Located on:</i> upper trunk; less frequently on fore-arms/face	Anywhere on the body, but spares scalp, axillae and groins
<i>Morphology:</i> small perifollicular scaly macules which may become confluent	Macules, plaques, nodules. Scaling absent ¹⁹
<i>Sensations:</i> normal	Impaired

Table 14.6. Profile of clinical types of leprosy

	TT	BT	BB	BL	LL
Skin lesions					
<i>Number</i>	Single/few	Few	Several	Numerous	Innumerable
<i>Size</i>	Variable	May be large	Variable	Small	Small
<i>Sensations</i>	Anesthetic	Hypoesthetic	Hypoesthetic	Hypoesthetic	Normoesthetic
<i>Symmetry</i>	Asymmetrical	Asymmetrical	Bilateral but asymmetrical	Tendency to symmetry	Symmetrical
<i>Morphology</i>	Macule/plaque; well-defined	Plaques; well-defined with satellite lesions	Plaques; with sloping edge (inverted saucer appearance)	Macules/papules nodules, plaques; ill-defined	Macules/papules; nodules/plaques, ill-defined
Nerves	Single trunk, related to lesion; may be nodular	Asymmetrical, few nerves; thickened with anesthesia in distribution of nerve	Several nerves asymmetrically, thickened	Almost symmetrical nerve thickening; glove and stocking anesthesia	Symmetrical nerve thickening; glove and stocking anesthesia
Reactions	Stable	Type I	Type I	Type I/Type II	Type II
Lepromin	+	+/-	-	-	-
Histology					
<i>Granuloma</i>	Well-defined, epithelioid cell granuloma	Epithelioid cell granuloma		Ill-defined macrophage granuloma with many lymphocytes	Ill-defined, foamy macrophage granuloma
<i>Grenz zone</i>	-	+	++	++	++
AFB	-	-	+/-	+	++

18. **Skin lesion consistent with leprosy:** hypopigmented or erythematous macules or plaques with epidermal atrophy, loss of appendages, and sensory impairment.
 19. Scaling absent in leprosy except in reactional states.

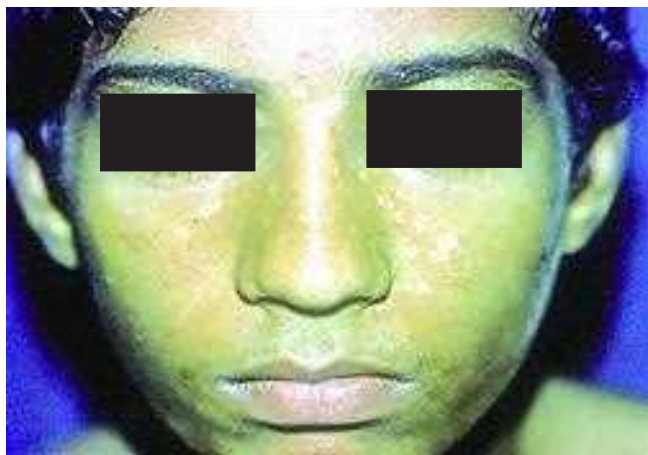


Fig. 14.39. Pityriasis alba: scaly, ill-defined macule on face.

b. Pityriasis alba (PA)

Both indeterminate leprosy and pityriasis alba are seen on the face of children.

Pityriasis alba (Fig. 14.39)	Indeterminate leprosy
Morphology: scaly, hypopigmented macule	Atrophic, hypopigmented macule
Sensations: normal	Hypoesthesia or normal sensation
Nerves: not thickened	Nerve thickening+/-

c. Vitiligo

Vitiligo	Leprosy
Morphology: depigmented (may be erythematous, if on phototherapy or photochemotherapy). Always macular.	Hypopigmented/erythematous macules. Nodules, plaques may be present.
Sensations: normal	Decreased
Hair: depigmented (leucotrichia)	Decreased in number

Nodular lesions

Nodular lesions of leprosy should be differentiated from:

a. Post kala-azar dermal leishmaniasis (PKDL)

Hypopigmented and nodular lesions may be both seen in same patient in both conditions.

PKDL	LL
Location: nodular lesions in the periorificial region and hypopigmented macules on center of trunk	Nodular lesions on ears, supraorbital areas and hypopigmented macules bilaterally symmetrical.
Infiltration of ears: absent	Present
Nerves: not thickened/tender	Thickened ± tender
Sensory deficit: nil	Glove and stocking sensory deficit
Skin smear: show LD bodies	AFB

20. Resistant *M. leprae* are not responsible for relapses in leprosy, which is due to “persisters” *M. leprae* which are fully susceptible to conventional antileprosy drugs.

Treatment

General measures

- ❖ Reassuring patient.
- ❖ Education regarding low contagiousness.
- ❖ Advice regarding sensory impairment especially with regard to hands and feet.
- ❖ Care of hands, feet, and eyes.
- ❖ Counseling regarding regularity of treatment.

Treatment of disease

WHO regimen (Table 14.7)

For the purpose of therapy, leprosy is classified into **paucibacillary** (less bacterial load) and **multibacillary** (more bacterial load).

Table 14.7. WHO recommendation for treatment of leprosy in adults

	PB*	MB
Definition	5 or < lesions	> 5 lesions
Duration of therapy	6 months to be completed in 9 months	12 months to be completed in 18 months
Drugs		
Supervised (monthly)	Rifampicin, 600 mg	Rifampicin, 600 mg + Clofazimine, 300 mg
Not supervised (daily)	Dapsone, 100 mg	Dapsone, 100 mg + Clofazimine, 50 mg

*ROM: Rifampicin (600 mg), Ofloxacin (400 mg) and Minocycline (100 mg) is given as a single dose for single lesion leprosy (without any clinical nerve thickening).

Newer drugs

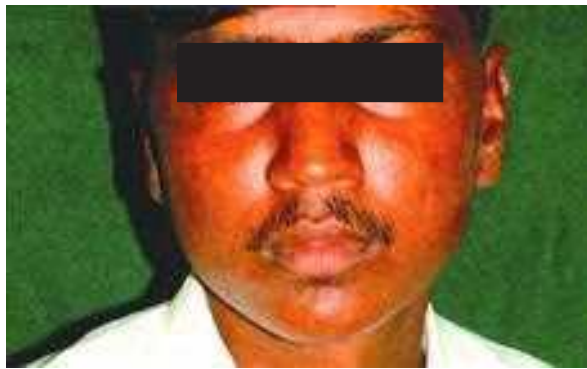Alternate drugs are often necessary in case of:

- ❖ **Resistance**²⁰: Drug sensitivity studies greatly hampered due to absence of *in vitro* culture techniques for *M. leprae*. Several factors encourage development of drug resistance:
 - Monotherapy, as in pre 1982 era.
 - Suboptimal doses of drugs.
 - Erratic and irregular therapy.
- ❖ **Intolerance**: New drugs are also necessary in case of intolerance to conventional therapy (Table 14.8).
- ❖ **Comorbidities**: In patients with hepatic dysfunction, rifampicin and dapsone are best avoided, so alternate drugs necessary.

The new drugs that have emerged as useful alternatives include:

Table 14.8. Side effects of antileprosy drugs

Drug	Side effects
Dapsone	Hemolytic anemia Drug eruptions: exfoliative dermatitis, toxic epidermal necrolysis Hepatitis
Rifampicin	Hepatitis Drug eruptions
Clofazimine	Ichthyosis Pigmentation (Fig. 14.40) Gastrointestinal side effects

**Fig. 14.40.** Clofazimine-induced hyperpigmentation.

- ❖ Ofloxacin.
- ❖ Sparfloxacin.
- ❖ Minocycline.
- ❖ Clarithromycin.

Treatment of lepra reactions

- ❖ During reactions it is important not to stop antileprosy drugs.
- ❖ Regimens for treating type 1 and type 2 lepra reactions depend on severity of the reaction (Table 14.9).

Table 14.9. Management of lepra reactions

	Type I reactions	Type II reaction
Mild	NSAIDs*	NSAIDs*
Moderate	NSAIDs* Oral steroids	NSAIDs* Thalidomide** Chloroquine Clofazimine
Severe	NSAIDs* Oral steroids	Thalidomide** Oral steroids (for impending nerve damage, orchitis, necrotic ENL) Parenteral antimony

*Nonsteroidal anti-inflammatory drugs.

**Now available in India. Absolutely contraindicated in females in the reproductive age group.

Treatment of complications in leprosy (Table 14.10)

Table 14.10. Treatment of complications in leprosy

Trophic ulcers	Rest Non-weight-bearing splints Antibiotics
Motor deficits	Physiotherapy Splints (Fig. 14.41) Surgical correction
Iridocyclitis	Topical steroids Oral steroids
Orchitis	Oral steroids

Leprosy vaccines

- ❖ Development of leprosy vaccine is hindered by inability to grow *M. leprae* in artificial media. Several candidate vaccines have been investigated:
 - BCG.
 - BCG + killed *M. leprae*.
 - Killed *M. leprae*.
 - *Mw*.
 - ICRC bacillus.
- ❖ Leprosy vaccines have been used for:
 - *Immunoprophylaxis*: to reduce the transmission of leprosy, e.g., in contacts.
 - *Immunotherapy*: along with chemotherapy in highly bacillated patients, so as to hasten clearance of bacillus.

Other Mycobacterial Infections

- ❖ **Etiology**: Several other mycobacteria can infect skin:
 - *M. marinum*.
 - *M. ulcerans*.
- ❖ **Manifestations**: These infections manifest as acute ulcers on edematous and erythematous base (Fig. 14.42). Sometimes, the lesions may resemble cutaneous tuberculosis.
- ❖ Lymph nodes may or may not be enlarged.
- ❖ **Treatment**:
 - *M. marinum* infection responds to an 8-week course of cotrimoxazole.
 - *M. ulcerans* infection may be difficult to treat.

Viral Infections

The viral diseases being discussed in this section are those which primarily involve the skin and

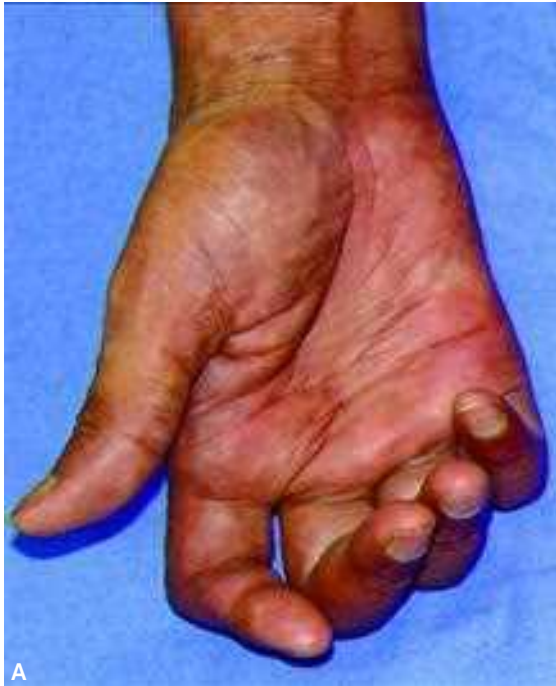

Fig. 14.41. Splints: splints are regularly used in deformities in leprosy.

not systemic viral infections, which manifest with exanthem (or enanthem) as one of their many manifestations.

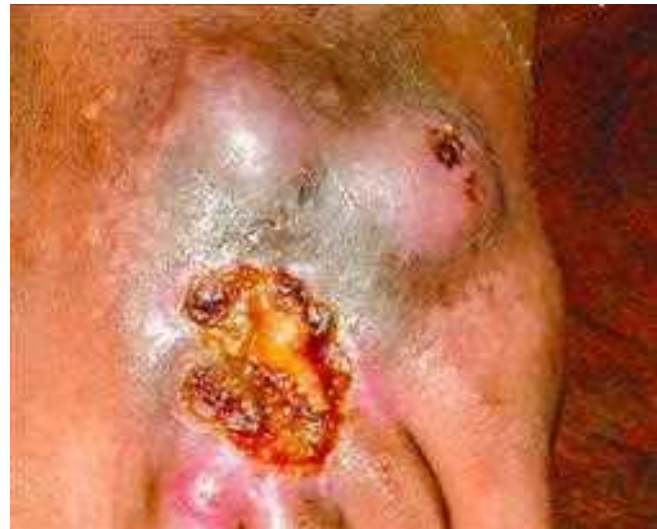

Fig. 14.42. Atypical mycobacterial infection: acute ulcers on erythematous and edematous base.

Warts (Verruca)

Synopsis

Etiology: Human papilloma virus (HPV); more than 100 types; a good association between HPV type and clinical features. A number of clinical variants, depending on the type of virus, mode of entry, and immune status of host.

Verruca vulgaris: Verrucous papules; on hands and feet.

Superficial palmoplantar warts: Superficial, confluent, painless warts; on palms, soles.

Deep palmoplantar warts: Deeper, discrete, painful warts; on palms, soles.

Verruca plana: Flat, smooth papules; on face.

Filiform warts: Elongated warts; on face and scalp.

Epidermodysplasia verruciformis: In genetically predisposed. Extensive lesions (plane warts—like and pityriasis versicolor-like). Malignant potential in photo-exposed parts.

Anogenital warts: Sexually transmitted, genital warts.

Treatment: Depends on age of patient, number, and site of lesions. Wart paint: Palmoplantar warts and common warts. Cryotherapy: Common warts. Electrocautery: Filiform warts.

Etiology

- ❖ **Human papilloma virus (HPV)** is a DNA virus which has not been cultured *in vitro*.

- ❖ With polymerase chain reaction techniques, more than 100 types of HPV identified.
- ❖ Association exists between HPV type and the clinical disease caused (Table 14.11).

Table 14.11. Clinical manifestations and HPV type

Clinical manifestations	HPV type
Verruca vulgaris	2, 4, 27
Palmoplantar warts	1, 2, 4, 57
Verruca plana	3, 10
Epidermodysplasia Verruciformis	3, 5, 8, 9
Anogenital warts	6*, 11*, 16**, 18**, 31**, 33**

*Low oncogenic potential

**High oncogenic potential

Epidemiology

Age

- ❖ **Nongenital warts:** Most frequent in children and young adults, in whom the incidence may approach 10%.
- ❖ **Anogenital warts:** In adolescents and adults, though occasionally may be seen in children.

Transmission

- ❖ **Nongenital warts:** Transmitted through direct skin-to-skin contact and by auto-inoculation.
- ❖ **Anogenital warts:**
 - *Sexual transmission:* both heterosexual and homosexual.
 - *Vertical transmission:* mother with anogenital warts can transmit infection to the newborn, during vaginal delivery. The infection manifests as **laryngeal papillomas** in infant.

Clinical Features

Warts present clinically as:

- ❖ Verruca vulgaris.
- ❖ Palmoplantar warts.
- ❖ Verruca plana.
- ❖ Filiform warts.
- ❖ Epidermodysplasia verruciformis.
- ❖ Anogenital warts.

Verruca vulgaris (common warts)

Usually asymptomatic.

Morphology

- ❖ Single or multiple, circumscribed, firm papules with verrucous (hyperkeratotic) dry, stippled surface (Fig. 14.43A and B).

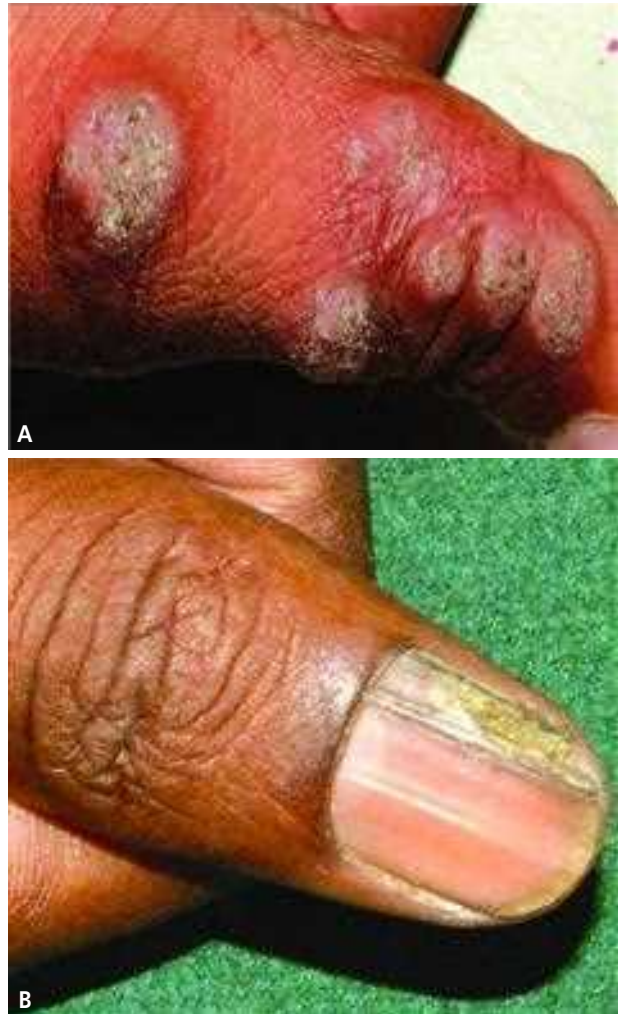

Fig. 14.43. Verruca vulgaris: A: multiple circumscribed, verrucous papules. B: subungual lesion, distorting nail.

- ❖ About 60% of common warts resolve spontaneously.

Sites

Can occur anywhere on the body, but most frequently seen on back of hands, fingers, knees, and feet.

Palmoplantar warts

Palmoplantar warts are of two types:

- ❖ Superficial palmoplantar warts.
- ❖ Deep palmoplantar warts.

Superficial palmoplantar warts (mosaic warts)

- ❖ Usually painless.
- ❖ **Morphology:** Hyperkeratotic papules and plaques consisting of multiple, small warts, which are tightly packed (Fig. 14.44).
- ❖ **Sites:** Soles and less often palms.

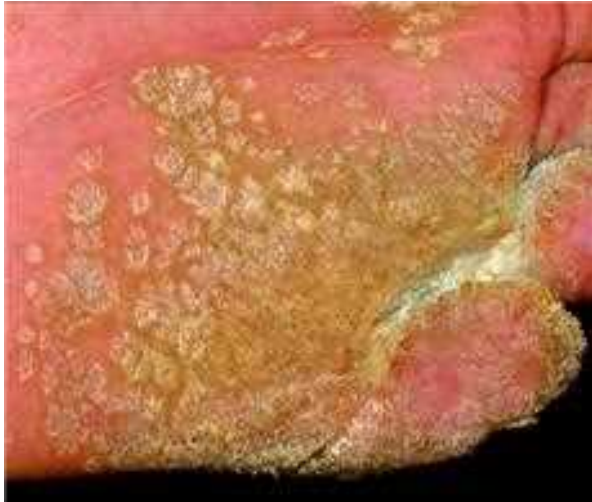

Fig. 14.44. Superficial palmoplantar (mosaic) warts: tightly packed multiple lesions.

Deep palmoplantar warts (myrmecia)

- ❖ Painful (sometimes excruciatingly so!).
- ❖ **Morphology:** Hyperkeratotic, deep-seated papules (barely visible above the skin surface), surrounded by a horny collar and the wart actually becomes apparent as a soft granular brown papule, only when the collar is pared. Further paring reveals punctate black dots (representing thrombosed capillary loops). Even when multiple, deep plantar warts always remain discrete.
- ❖ **Sites:** Soles; less often on palms and on sides of fingers.

Verruca plana (plane warts)

Morphology

- ❖ Multiple, slightly elevated, flat smooth papules (Fig. 14.45).
- ❖ Skin colored or darker lesions; may have an erythematous halo.
- ❖ Lesions may be arranged linearly (pseudo **Koebner's phenomenon**) due to auto-inoculation.

Site

Face and on dorsal aspects of hands.

Filiform warts

Morphology

Asymptomatic, thin elongated, firm projections arising from a horny base (Fig. 14.46).

Site

Most frequently on the face (inoculation by shaving) and scalp.

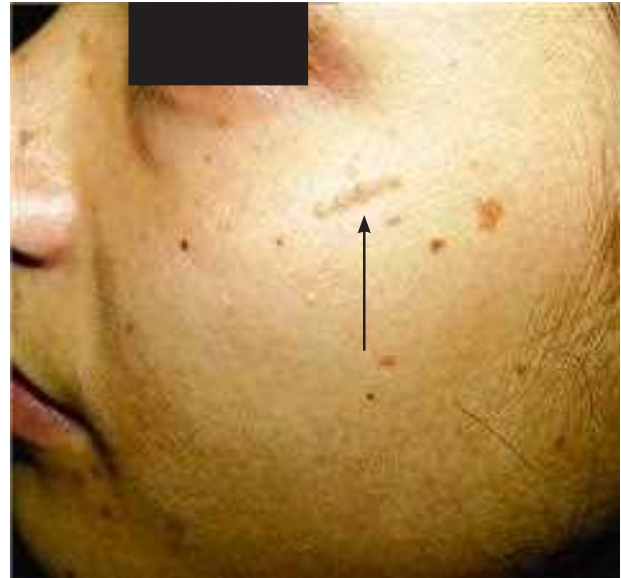

Fig. 14.45. Plane warts: multiple, skin-colored papules. Note pseudo Koebner's phenomenon.

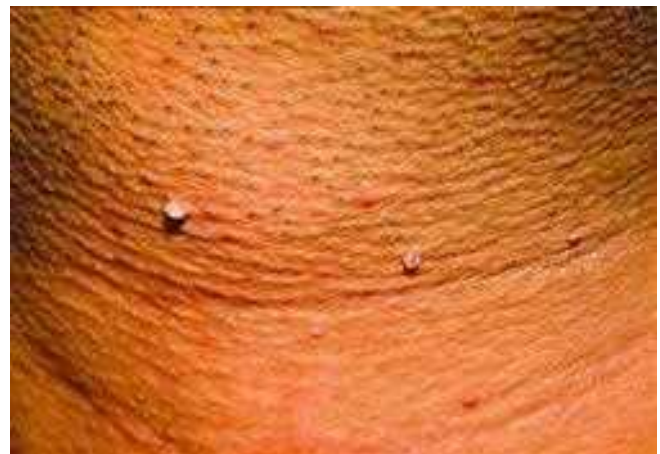

Fig. 14.46. Filiform warts: thin, firm projections in the beard region.

Epidermodysplasia verruciformis

Rare inherited disorder, characterized by defective cell-mediated immunity to certain types of HPV (3, 5, 8, 9) resulting in wide spread lesions.

- ❖ Two types of lesions are seen:
 - Plane wart-like lesions, many of which become confluent on face and acral parts (Fig. 14.47A).
 - Pityriasis versicolor-like irregular, scaly macules on trunk (Fig. 14.47B).
- ❖ Development of Bowen's disease and invasive squamous cell carcinoma is frequent on photo-exposed parts.

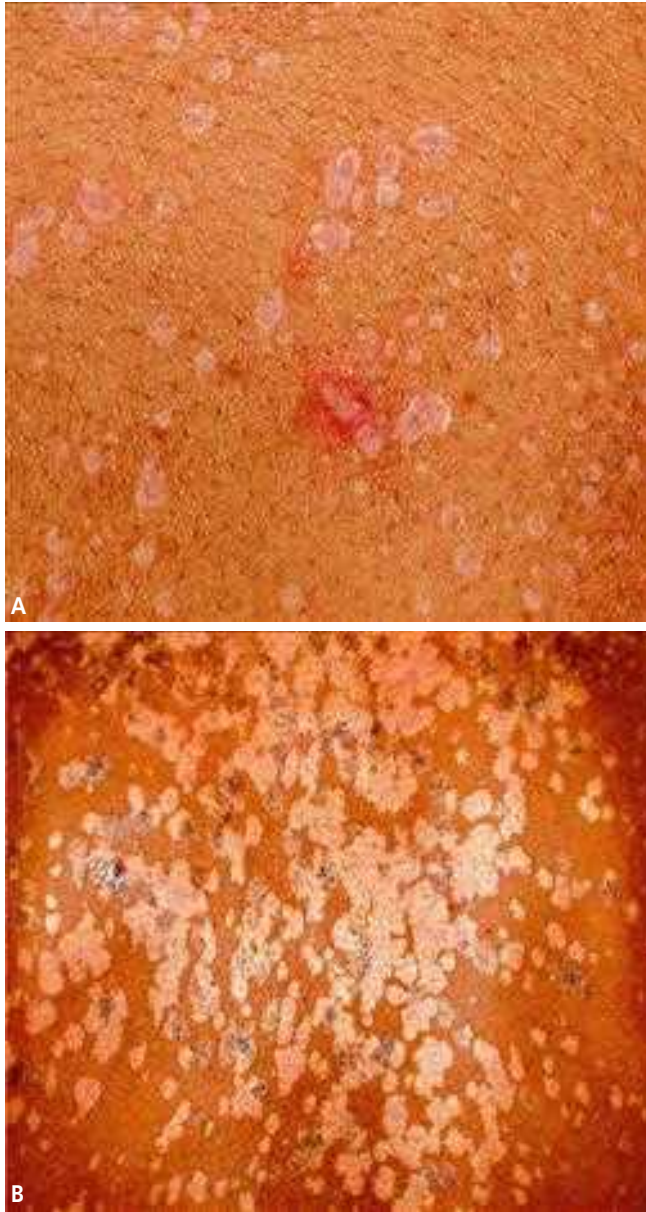

Fig. 14.47. Epidermodysplasia verruciformis: A: plane wart like lesions. B: pityriasis versicolor-like macules.

Anogenital warts

- ❖ Sexually transmitted disease.
- ❖ A variety of clinical variants, *e.g.*, condyloma acuminata, papular warts, and Bowenoid papulosis.
- ❖ Most frequently on the glans, perianal region, vulva, and cervix.

Course of warts

Spontaneous resolution

- ❖ In healthy individuals most warts resolve spontaneously (30% in 6 months and 60% in

12 months) as the host mounts an immune response.

- ❖ When wart is spontaneously regressing, punctate areas of blackish discoloration (due to capillary thrombosis) appear on surface and the wart resolves with no sequelae.

Persistent warts

- ❖ Mosaic warts very recalcitrant.
- ❖ In immunocompromised individuals, (on immunosuppressive therapy, with lymphoreticular malignancies or with HIV infection) warts are persistent, extensive, and have an oncogenic potential.

Complications of warts

- ❖ Large genital lesions may obstruct labor in pregnant women.
- ❖ **Malignant transformation:** Seen in:
 - *Cervical infection with high-risk HPVs (16, 18):* is the main cause of cervical carcinoma *in situ*, though it must be emphasized that cervical infection even with high-risk HPVs, generally has a benign outcome. Malignant potential, however, increases in the background of immunosuppression.
 - *HIV infection:* malignant potential of oncogenic HPV increases in the presence of immunosuppression.
 - *Epidermodysplasia verruciformis:* Bowen's disease and invasive squamous cell carcinoma develops in photo-exposed areas.

Diagnosis

Points for diagnosis

Warts are diagnosed on the basis of:

- ❖ Characteristic warty appearance with a rough, dry stippled surface.
- ❖ Presence of pseudo Koebner's phenomenon, especially in plane warts.
- ❖ Typical histology (Fig. 14.48).

Differential diagnosis

Warts should be differentiated from:

a. Molluscum contagiosum (MC)

MC	Verruca
Morphology: smooth, dome-shaped, pearly white papules	Hyperkeratotic (verruca vulgaris) or flat topped (plane warts) or elongated, (filiform warts) papules
Surface: central umbilication	Verrucous
Core: central core can be extruded	No central core

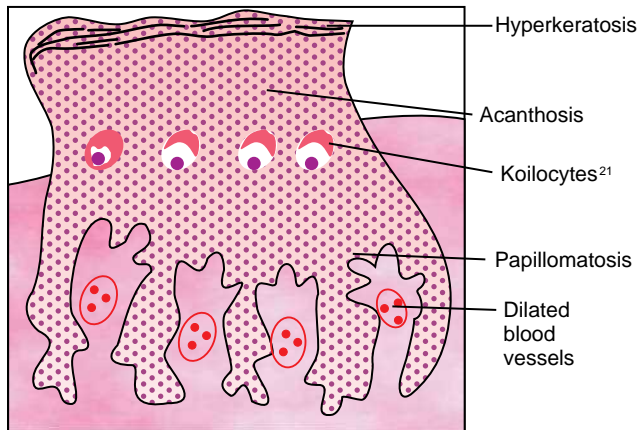


Fig. 14.48. Verruca vulgaris: histology.

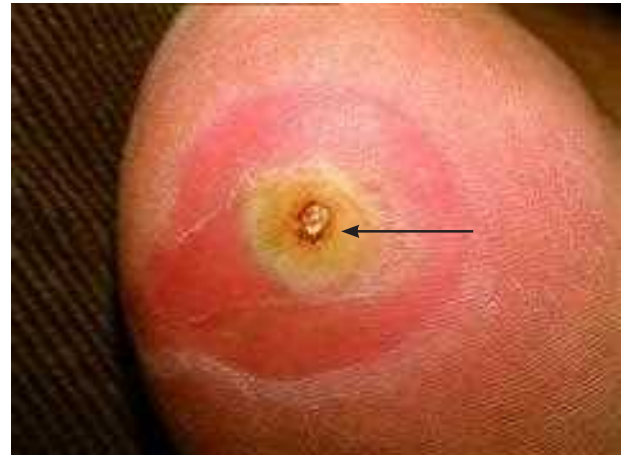

Fig. 14.49. Corns: hyperkeratotic papules over which the skin markings continue uninterrupted. Note central keratinous core

b. Corns (Fig. 14.49)

Corns	Plantar warts
Location: at points of pressure	Anywhere
Skin markings: continue over lesions	Skin markings interrupted
On paring: keratinous core seen	Black dots seen

Treatment

- ❖ Treatment of viral warts depends on
 - Site.
 - Number of lesions.
 - Type of lesions.
 - Age of patient.
- ❖ More than 50% of warts resolve spontaneously.
- ❖ Whichever method is used, there will be some failures and recurrences and some successes.

Treatment options

Several methods of treatment are available:

Cryotherapy

- ❖ **Cryogens:** Liquid nitrogen, carbon dioxide, and nitrous oxide.
- ❖ **Technique:** A cotton-tipped applicator dipped in cryogen is applied firmly to the wart till a small halo of freezing appears on adjoining normal skin. Or can be sprayed using a cryo-can. Blistering is not a prerequisite for effective treatment.
- ❖ **Disadvantages:** Pain. And post-treatment depigmentation.

Electric cautery and radiofrequency ablation (RFA)

❖ Indications:

- *Filiform warts:* treatment of choice.
- *Verruca vulgaris:* small and medium sized warts.

❖ Techniques: Electrofulguration, RFA.

Topical agents

- ❖ **Salicylic acid (10–25%):** Keratolytic, so reduces thickness of wart and induces an inflammatory response.
- ❖ **Wart paint:** Contains salicylic acid (a keratolytic agent) and lactic acid in a quick drying collodion or acrylate base.
 - **Indications:** treatment of choice for palmo-plantar and periungual warts, especially in children. Should not be used on facial lesions and anogenital warts.
 - **Method:** wart is softened by soaking in warm water for about 10 min. Paint is then applied carefully so as to cover the wart but not surrounding skin. Before next application, the dead tissue and old paint are removed, the feet soaked in warm water and wart paint reapplied. Warts on the plantar surface are best occluded because occlusion enhances penetration. Wart paint may need to be used daily for 3 months.
- ❖ **Retinoic acid (0.05–0.1%):** Topically is useful in plane warts because of keratolytic action.

21. **Koilocytes:** are large keratinocytes with eccentric pyknotic nucleus surrounded by perinuclear halo.

❖ **Formalin²² soaks**

- Ideal for multiple small plantar warts.
- Feet are soaked in 4% formalin solution for about 10 min.
- Few patients develop allergic contact dermatitis to formalin.

Mechanical removal

Mechanical removal using a curette followed by cauterization of the bleeding base using trichloroacetic acid (TCA) 50% is a frequently used method when other facilities are not available.

Treatment protocol (Table 14.12)**Table 14.12. Treatment options in warts**

Type of warts	Treatment options
Verruca vulgaris	Cryotherapy Electric cauterly, RFA Wart paint (not on face, anogenital region) Mechanical removal
Palmoplantar warts	Wart paint Cryotherapy Formalin soaks
Filiform warts	Electric cauterly, RFA
Plane warts	Trichloroacetic acid touch Retinoic acid
Epidermodysplasia verruciformis	Acitretin
Anogenital warts	Podophyllin/podophyllotoxin Imiquimod Cryotherapy

Molluscum Contagiosum (MC)**Synopsis**

Etiology: Pox virus.

Morphology: Usually multiple, umbilicated pearly white papules.

Treatment: Mechanical destruction, chemical cauterization or cryotherapy. Wart paint, if several lesions.

Etiology**Agent**

Pox virus.

Transmission

- ❖ Direct spread.

- ❖ Fomites (clothes and towels).
- ❖ Sexual transmission.

Clinical Features**Morphology (Fig. 14.50)**

- ❖ Usually multiple.
- ❖ Pearly white, dome-shaped papules which are umbilicated. Under a hand lens, may have a mosaic appearance. On piercing the umbilicated center, a white cheesy material can be extruded.
- ❖ **Pseudoisomorphic phenomenon:** Due to auto-inoculation, can give rise to lesions arranged linearly along line of trauma.

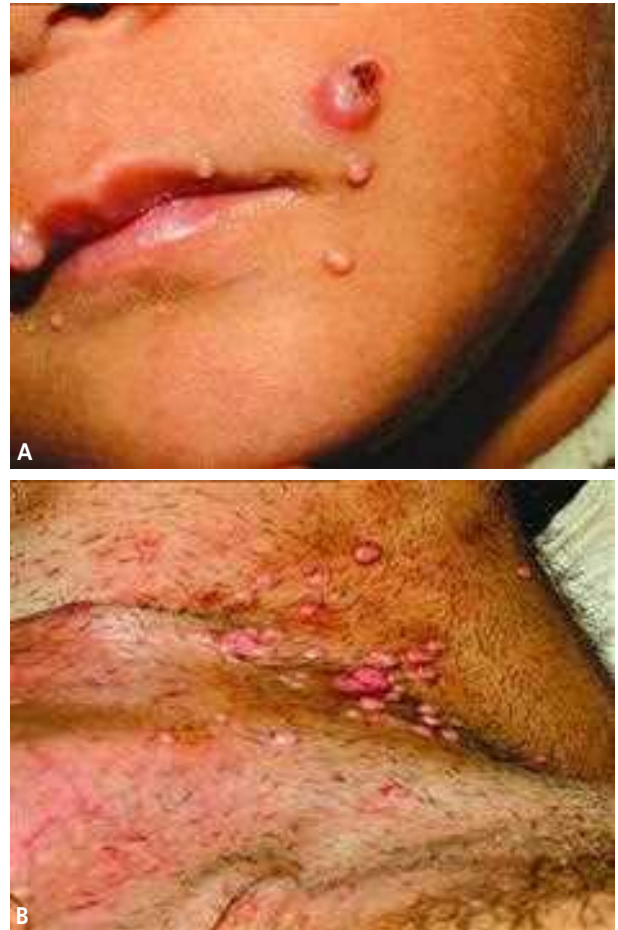


Fig. 14.50. Molluscum contagiosum: A: pearly white, umbilicated, dome-shaped papules on face of a child. B: anogenital area of sexually active adults.

22. **Formalin:** is 37% formaldehyde in water.

Sites of predilection

- ❖ Any part of the body.
- ❖ Anogenital region: Sexually transmitted MC.
- ❖ Widespread and several lesions, seen in atopics (due to scratching and extensive use of topical steroids) and in immunocompromised patients (HIV infection) due to defective cell-mediated immunity.

Course

- ❖ Self-limiting. Lesions usually clear spontaneously in about a year usually without any scarring (though some lesions may resolve with scarring).
- ❖ Large solitary lesions may not resolve spontaneously.
- ❖ Lesions persistent, extensive, and difficult to treat in immunocompromised individuals and in patients with atopic dermatitis.

Complications

- ❖ Secondary infection.

Investigations

- ❖ In children, usually none needed. In doubtful cases, cytological examination of expressed material reveals large eosinophilic intracytoplasmic inclusion bodies.
- ❖ In adult patients with extensive and persistent lesions, underlying HIV infection should be ruled out.

Diagnosis

Points for diagnosis

Diagnosis of MC is based on:

- ❖ Presence of pearly white umbilicated papules.
- ❖ Extrusion of the cheesy core through the central crater; characteristic cytological appearance of the expressed material.

Differential diagnosis

MC should be differentiated from:

- Verruca vulgaris* (P. 272).
- Cryptococcosis*.

Treatment

Treatment depends on age of the patient and number of lesions (Table 14.13).

Table 14.13. Treatment options in molluscum contagiosum

Children	Few lesions	May resolve spontaneously
	Several lesions	Wart paint Mechanical extirpation followed by chemical cautery after using EMLA ²³
Adults	Few lesions	Mechanical extirpation followed by chemical cautery
	Several lesions*	Cryotherapy Wart paint

*Rule out underlying HIV infection

Varicella-Zoster Infections

Varicella

Synonym: Chicken pox.

Synopsis

Etiology: Varicella-zoster virus.

Prodrome: Fever and malaise.

Morphology: Crops of papules with erythematous halo; rapidly become vesicular (dew drops on rose petal appearance), then pustular. Eruption at different stages present. Heal with minimal scarring unless complicated by secondary infection or hemorrhagic lesions (as seen in immunocompromised). Adults usually have a more severe eruption.

Site: Centripetal distribution.

Prophylaxis: Live attenuated vaccine.

Treatment: Specific antiviral therapy (acyclovir 800 mg, five times daily × 7–10 days) in adults and in immunocompromised individuals. None needed in children.

Etiology

- ❖ **Varicella-zoster virus.**
- ❖ Highly contagious, spread by droplet route. Patient infectious for 1–2 days before the exanthem appears and for 4–5 days thereafter (total infectious period 5–7 days), *i.e.*, till the last crop of vesicles has crusted. Incubation period is 2 weeks.

Clinical features

Prodrome

Low-grade fever and malaise.

Morphology (Fig. 14.51)

- ❖ Lesions appear in crops.
- ❖ Itchy papules that rapidly turn into clear superficial vesicles and then pustules. At any

23. **EMLA:** a local anesthetic.

particular time, lesions at different stages of evolution are present.

- ❖ Typical vesicle of varicella is superficial and thin walled and it looks like a drop of water lying on, rather than in the skin. The irregular perivesicular erythema give the lesions a “**dew drop on rose petal**” appearance (Fig. 14.51B).
- ❖ Eventually, the lesions crust in a few days and heal, usually, without scarring. Sometimes, however, depressed scars or hypopigmentation may develop.
- ❖ Oral lesions may be present (Fig. 14.51C).

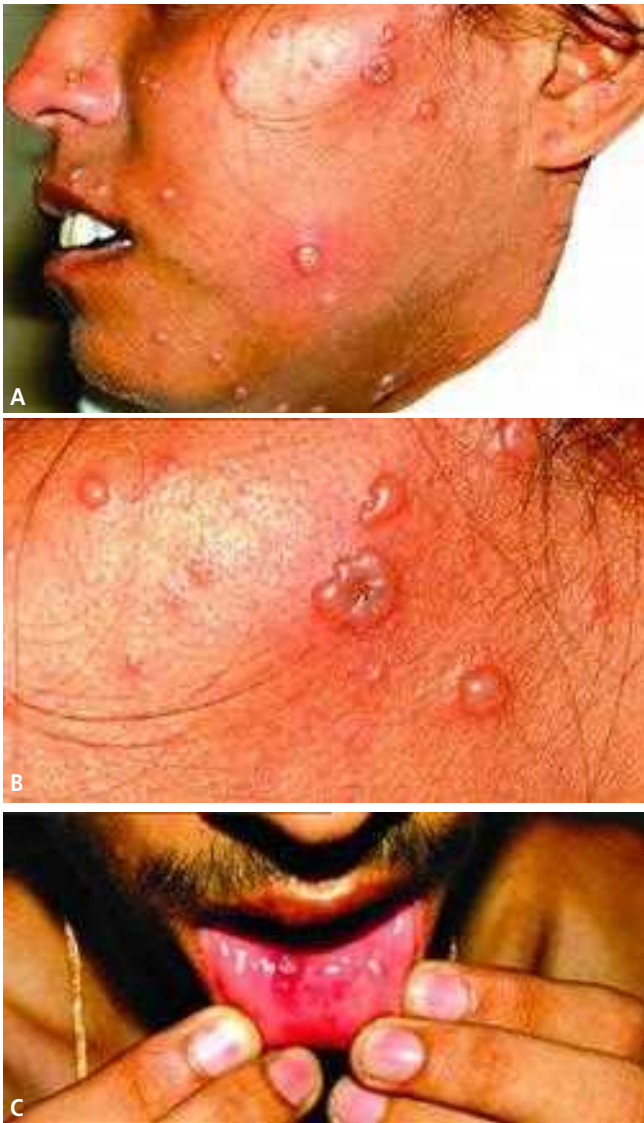

Fig. 14.51. A: Chicken pox: multiple vesicles in different stages of evolution. B: “dew drop on a rose petal” appearance. C: oral lesions.

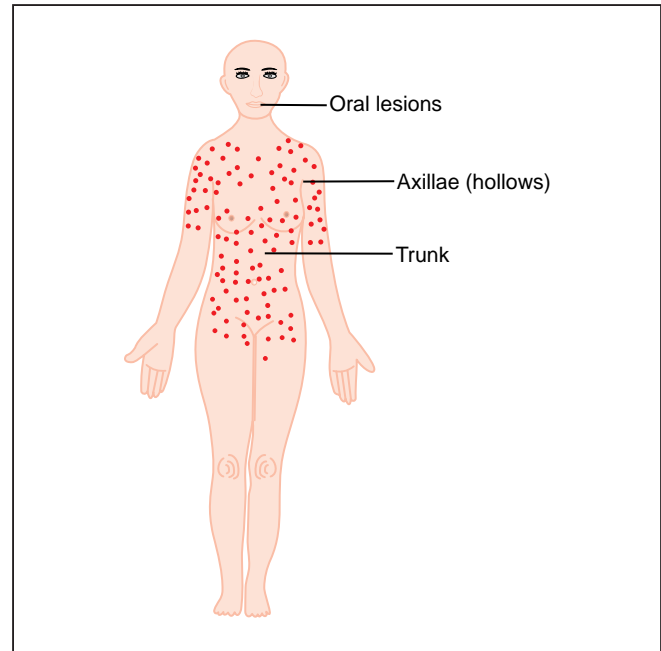


Fig. 14.52. Chicken pox: sites of predilection.

Sites of predilection (Fig. 14.52)

Lesions most profuse on the trunk (covered parts) and least on face and limbs (**centripetal distribution**). Also more profuse in hollows.

Course

- ❖ Runs a benign course in children.
- ❖ Adults have more severe disease with residual scarring.
- ❖ Hemorrhagic and lethal chicken pox occurs in immunocompromised individuals.
- ❖ Pneumonitis (manifesting as pulmonary opacities radiologically) may occasionally be seen.

Investigations

None are usually required.

Diagnosis

Points for diagnosis

Diagnosis of CP is based on:

- ❖ Prodrome of low-grade fever.
- ❖ Eruption of papules, vesicles and pustules in different stages of evolution appearing in crops.
- ❖ Typical “dew drop on a rose petal” appearance.
- ❖ Characteristic centripetal distribution.

Treatment (Table 14.14)

Table 14.14. Treatment of chicken pox

Mild cases (Children)	Calamine lotion Antihistamines
Severe cases (Adults, HIV+)	Acyclovir 800 mg, five times × 7–10 days Famciclovir 250 mg tds × 10 days
Prophylaxis	<ul style="list-style-type: none"> ❖ Live attenuated vaccine in susceptible patients. ❖ Hyperimmunoglobulin, if an immunocompromised individual is exposed to CP. To be given within 24–48 h of exposure.

Herpes Zoster

Synonym: Shingles

Synopsis

Etiology: Varicella-zoster virus. After an attack of chicken pox, virus lies dormant in sensory root ganglia. Zoster is a manifestation of its reactivation.

Morphology: Very painful, segmental eruption of grouped papules and vesicles on an erythematous, slightly edematous base. Self-limiting. Crust in a week.

Sites: Thoracic intercostal nerves, ophthalmic division of trigeminal nerve.

Complications: Postherpetic neuralgia (in elderly, when ophthalmic division of trigeminal nerve is involved and in immunocompromised). Sometimes, corneal ulcers in ophthalmic involvement. Facial palsy.

Treatment: Self-limiting. Symptomatic treatment with analgesics. Specific treatment with antivirals (acyclovir, famciclovir, and valacyclovir) in: (a) ophthalmic zoster (b) immunocompromised (c) severe zoster (hemorrhagic lesions), and (d) elderly (to reduces postherpetic neuralgia).

Etiology

- ❖ **Varicella-zoster virus.**
- ❖ After an attack of chicken pox, the virus lies dormant in the sensory root ganglion. Reactivation occurs, causing herpes zoster. Predisposing factors for reactivation are:
 - Old age.
 - Lymphoreticular malignancies, *e.g.*, Hodgkin's disease and leukemia.
 - Human immunodeficiency virus infection.
 - Sometimes without apparent cause.

Clinical features

Symptoms

Prodrome of segmental pain (usually excruciating!) begins 1–4 days before the eruption.

Morphology

- ❖ Erythema and edema are rapidly followed by appearance of grouped vesicles in a segmental distribution (Fig. 14.53). Vesicles rapidly become pustular and crust. Crusts fall off in about a fortnight and lesions heal with no (minimal) scarring.
- ❖ Mucous membranes within an affected dermatome may be involved.
- ❖ Draining lymph nodes are often enlarged.

Sites of predilection

- ❖ Unilateral segmental distribution, though lesions may affect more than one adjoining dermatome. A few stray lesions may be found outside the dermatomal distribution of the main lesions.
- ❖ Thoracic intercostal nerves and ophthalmic division of trigeminal nerve most frequently affected. Other spinal nerves also involved.

Complications

- ❖ **Postherpetic neuralgia:** Persistent neuralgic pain in some patients (in elderly, when ophthalmic division is involved and in immunosuppressed).
- ❖ Zoster of the ophthalmic division of trigeminal nerve may be associated with corneal ulcers and scarring. Eye involvement is indicated when vesicles are present on the side of the nose (**Hutchison's sign**).
- ❖ Secondary bacterial infection may occur.
- ❖ Generalized chicken pox-like eruption (often hemorrhagic) may complicate segmental zoster in immunocompromised individuals and in those with internal malignancies.
- ❖ Rarely, motor paralysis.

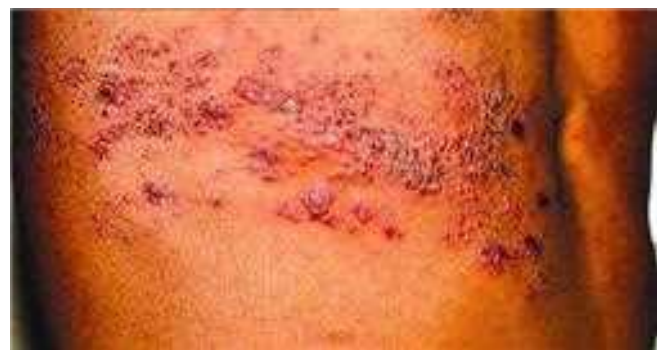

Fig. 14.53. Herpes zoster: vesicles on an erythematous base, arranged in a dermatomal distribution.

Investigations

- ❖ None usually required; in doubtful cases, presence of giant cells on cytopathology is confirmatory.
- ❖ Rule out an underlying immunodeficiency (lymphoreticular malignancies and HIV infection), if disseminated hemorrhagic lesions present.

Diagnosis

Points for diagnosis

Diagnosis of zoster is based on:

- ❖ Severe pain.
- ❖ Unilateral, segmental distribution.
- ❖ Presence of grouped vesicles on erythematous and edematous skin; rapidly evolve into pustules and then crust.

Treatment

Mild cases

- ❖ Treat pain with analgesics (round the clock).
- ❖ Treat secondary bacterial infection with broad-spectrum antibiotics.

Severe cases

- ❖ **Symptomatic treatment:** NSAIDs.
- ❖ **Specific treatment:** With antiviral drugs.
 - **Indications:** antiviral drugs are indicated in:
 - Severe cases (disseminated lesions, hemorrhagic lesions and multidermatomal lesions).
 - Immunocompromised patients.
 - Ophthalmic zoster.
 - **Antiviral drugs:** start within 72 h of an attack. Following drugs can be used:
 - Acyclovir: 800 mg, five times a day × 7 days (adult dose).
 - Famciclovir: 500 mg, three times a day × 7 days.
 - Valacyclovir: 1 g, three times a day × 7 days

Postherpetic neuralgia

- ❖ **Prevention:** Postherpetic neuralgia can be prevented by giving:
 - **Antiviral agents:** in acute phase.
 - **Oral steroids:** in patients, who are likely to develop neuralgia (elderly individuals) and cannot afford antiviral agents, a tapering course of prednisolone is recommended.

- ❖ **Treatment:** In patients with established postherpetic neuralgia, oral **gabapentin**²⁴ and **pregabalin**²⁵, and topical capsaicin cream can be tried.

Herpes Simplex Virus (HSV) infections

Synopsis

Etiology: HSV (type I and type II). Type I generally causes lesions above the waist, while type II causes genital infection. After primary infection (first infection), the virus lies dormant in sensory ganglion and gets activated from time to time.

Clinical features: Primary infection, more severe and associated with constitutional symptoms. Recurrent infection manifests as grouped papulovesicular lesions which rupture to form polycyclic erosions.

Complications: CNS complications may develop.

Treatment: Self-limiting. Long-term suppressive therapy with acyclovir, if yearly recurrences of genital herpes are >6 and in immunosuppressed individuals (HIV infection).

Etiology

Causative agent

HSV hominis; two main antigenic types:

- ❖ **Type I:** Usually causes herpes labialis and infections above the waist.
- ❖ **Type II:** Usually causes perigenital infection. But there is considerable overlap.

Transmission

Infection occurs *via* mucous membranes or traumatized skin either through:

- ❖ **Direct contact:** Usually occurs in children from an infected adult who is often asymptomatic yet shedding virus.
- ❖ **Sexual contact:** Usually in adults, herpes genitalis being the most common cause of infective genital ulcer disease. Again asymptomatic shedding important.

Pathogenesis

- ❖ When a person is infected, the disease may be symptomatic but more often is asymptomatic.
- ❖ After the first episode, the virus lies dormant in the sensory nerve ganglia but is capable of causing recurrent episodes of clinical infection during which the virus is shed.
- ❖ Viral shedding (though less often and less

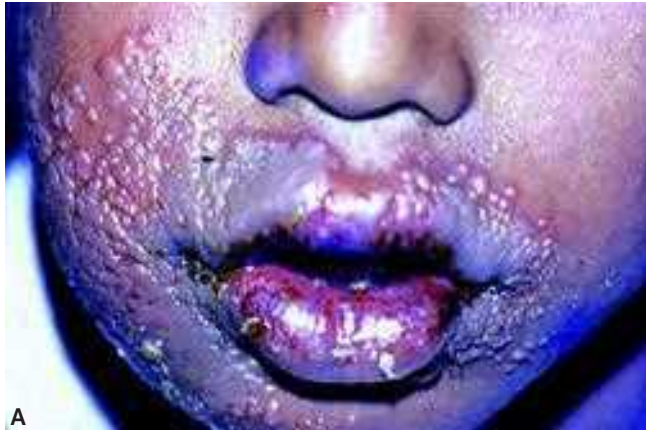24. **Gabapentin:** 900–1800 mg/day in three divided doses.

25. **Pregabalin:** 150 mg/day in two divided doses.

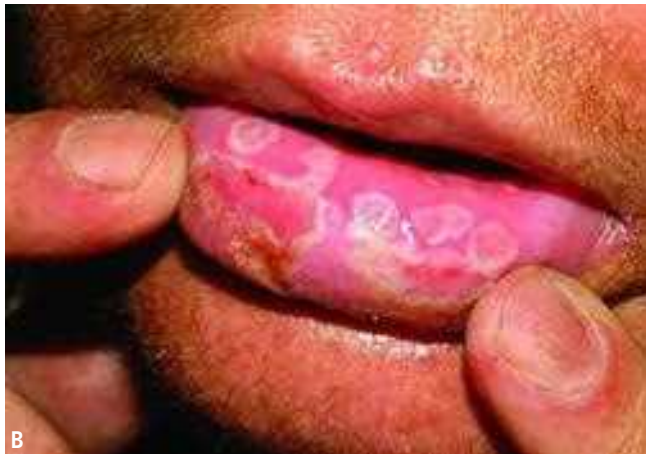severe) also occurs in the absence of clinical lesions (**asymptomatic shedding**).

Clinical Features

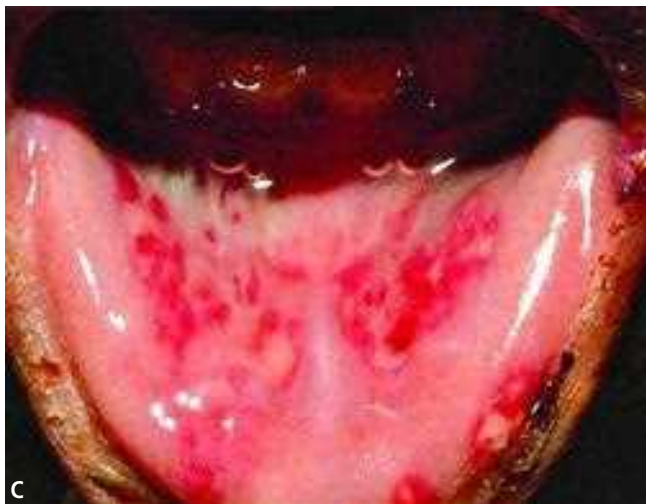The severity of clinical disease depends on whether the infection is primary or recurrent.



A



B



C

Fig. 14.54. Primary herpetic infection: A: grouped vesicles on an edematous base. B and C: polycyclic erosions on labial mucosa.

First episode disease

Primary type I infection

- ❖ Usually occurs in children.
- ❖ **Manifestations:**
 - May be asymptomatic.
 - Or may present as **acute gingivostomatitis:** characterized by closely grouped vesicles (Fig. 14.54), which rapidly form polycyclic ulcers covered with a yellow pseudomembrane. Heal in about a fortnight.
 - Malaise, fever, and lymphadenopathy are frequent.

Primary type II infection

- ❖ Usually in sexually active individuals. Seen on genitalia.
- ❖ Often asymptomatic especially in females.
- ❖ When symptomatic:
 - Manifests as grouped painful vesicles (appearing as white plaques), which rapidly erode to form polycyclic ulcers on erythematous background (Fig. 14.55).
 - Constitutional symptoms and inguinal lymphadenopathy seen.

Post primary infection

- ❖ This is primary infection usually with HSV type II in a patient who has some degree of immunity due to previous HSV type I infection or *vice versa*, (latter situation being less frequent).

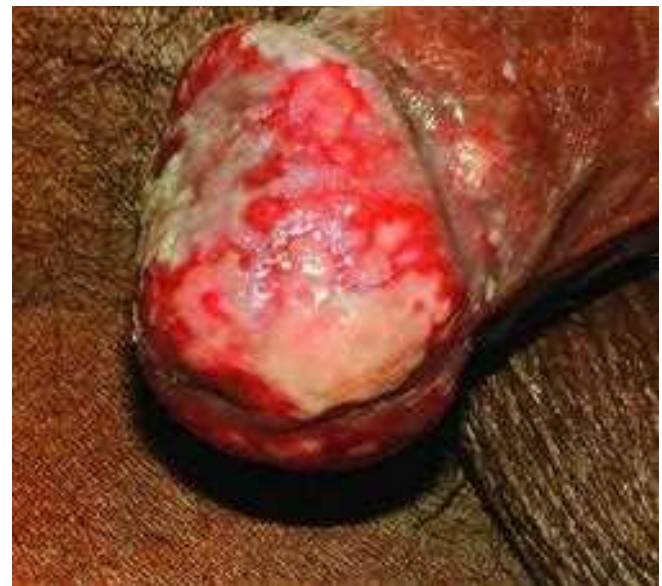

Fig. 14.55. Primary herpetic genital infection: grouped vesicles and polycyclic ulcers on erythematous background on glans.

- ❖ Manifestations are less severe than primary infection.

Recurrent infections

- ❖ Occur due to reactivation of virus from sensory nerve ganglia.
- ❖ Manifestations are precipitated by:
 - Upper respiratory infections associated with **fever**²⁶.
 - Ultraviolet radiation.
 - Stress.
 - Menstrual periods.
- ❖ Following a brief prodrome of burning and stinging, grouped vesicles appear on erythematous skin (Fig. 14.56A). Evolve into erosions with polycyclic margins (Fig. 14.56B), crust in 1–2 days, and rapidly heal without scarring, though a polycyclic area of hypopigmentation or depigmentation may remain (Fig. 14.56C).
- ❖ Recurrences usually occur on the same area and are more frequent with HSV type II than with HSV type I.
- ❖ Common sites of involvement are lips (HSV type I) and genitals (HSV type II).

Complications

- ❖ **Erythema multiforme.**
- ❖ **Disseminated cutaneous HSV infection:** Develops in neonates born to mothers with primary HSV genital infection. Or in immunosuppressed adults.
- ❖ **Eczema herpeticum**²⁷: Generalized HSV infection in patients with extensive atopic eczema, pemphigus, and other pre-existing dermatoses (Fig. 14.57).
- ❖ **Herpes simplex keratitis:** Results in recurrent **dendritic ulcers**, which may result in corneal opacities, leading to blindness.
- ❖ **Herpetic encephalitis.**

Investigations

Usually no investigations are needed for herpes labialis but for herpes genitalis, following investigations are helpful:

- ❖ **Identification of virus in tissues:**
 - *Tzanck smear* (Fig. 14.57B): a bed side test showing presence of multinucleated giant cells. Low sensitivity.

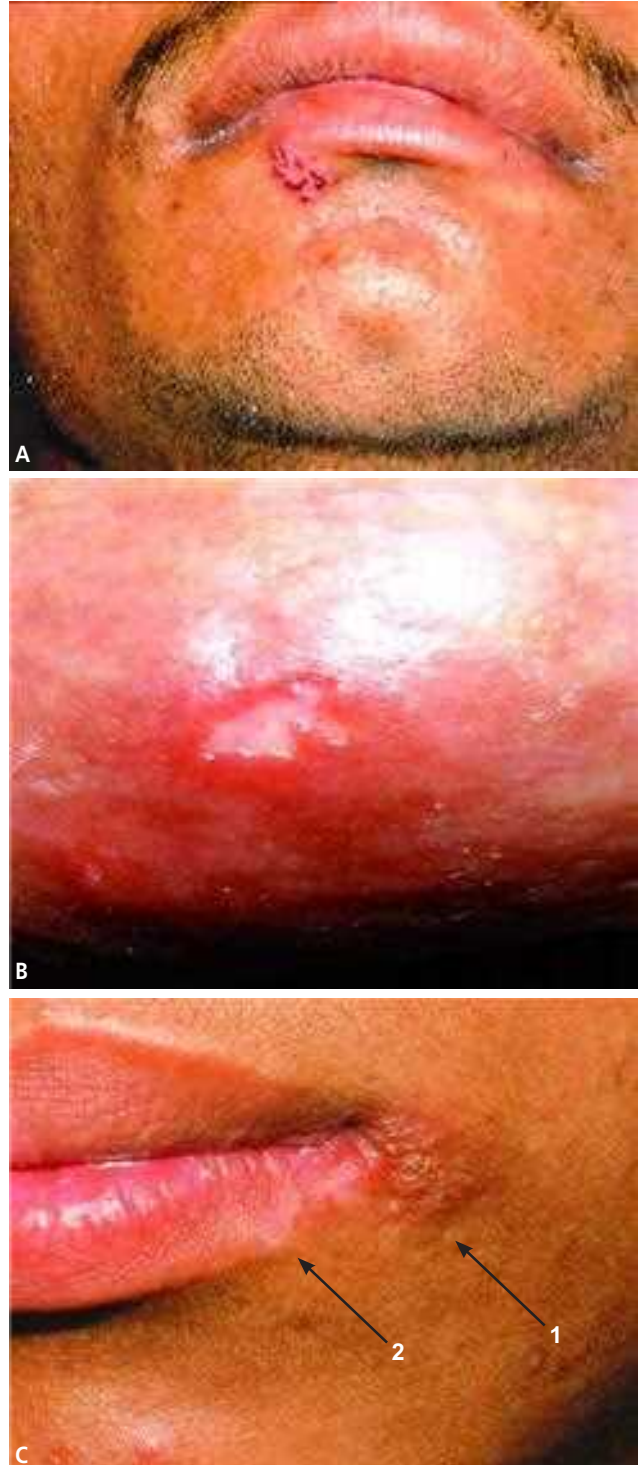

Fig. 14.56. Herpes simplex recurrent: A: presenting as grouped vesicular lesions. B: which evolve into erosions with polycyclic margins. C: patient with active lesions (1) as also an area of depigmentation with a polycyclic margin (2) at the site of previous episode.

26. **Fever:** precipitated by fever, hence the name fever/cold sores.

27. **Eczema herpeticum:** also called Kaposi varicelliform eruption.

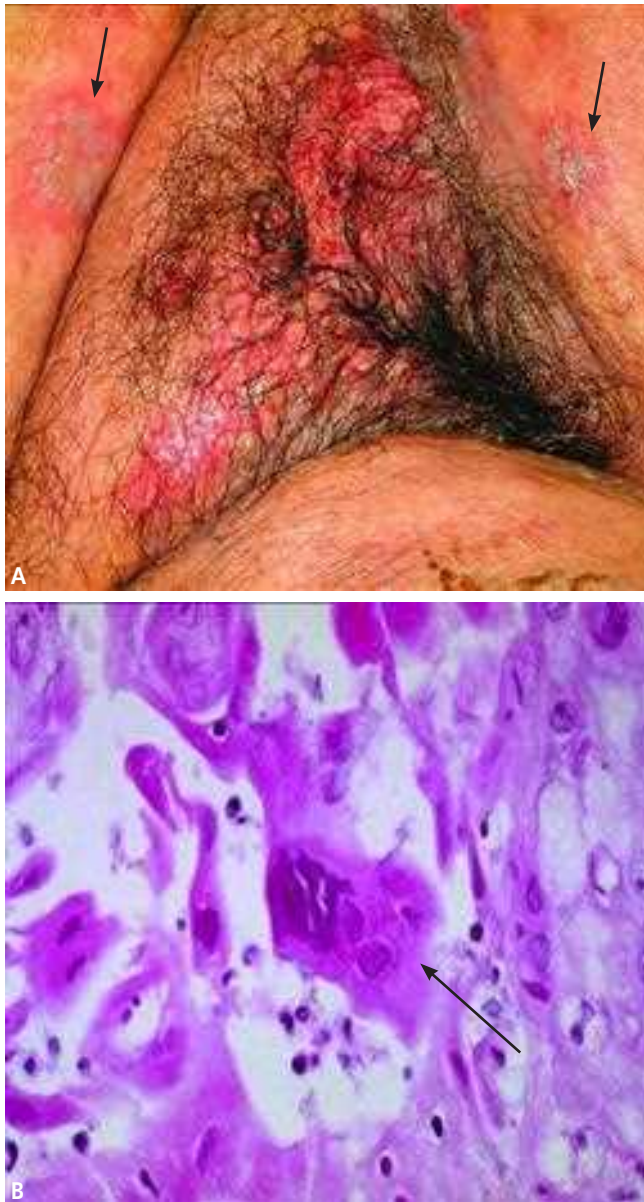

Fig. 14.57. Eczema herpeticum: A: generalized, grouped, vesicular lesions in a patient with underlying skin disease. B: Tzanck smear, showing multinucleated giant cells from the same patient.

- **Culture:** cytopathic effect in 1–5 days. Used as gold standard, but low sensitivity.
- **Fluorescent antibody test:** to HSV-1 and HSV-2, used to rapidly identify HSV in tissues. Test specific but not very sensitive.
- **Polymerase chain reaction:** very sensitive, very specific.
- ❖ **Serology:** Antibody titers rise with primary infection (IgM initially, IgG later). Though IgM levels fall, IgG levels persist. Are of doubtful

diagnostic significance in recurrent infections but help in primary infection.

Diagnosis

Points for diagnosis

Diagnosis of HSV infection is based on:

- ❖ Presence of grouped vesicles which rupture to give rise to polycyclic erosions; primary infection more symptomatic and severe and lesions may be covered with white/yellow pseudomembrane.
- ❖ Recurrences at same sites.

Differential diagnosis

HSV infection needs to be differentiated from:

a. Herpes zoster

<i>Herpes zoster</i>	<i>Herpes simplex</i>
<i>Prodrome:</i> of dermatomal pain	Of burning and stinging
<i>Morphology:</i> grouped vesicular lesions on an erythematous, edematous skin. Multiple such groups in dermatomal distribution	Grouped vesicular lesions on slightly erythematous skin; lesions in primary episode covered with pseudomembrane
<i>Recurrences:</i> single episode	Recurrences at same site

Treatment

Treatment depends on whether the attack is first episode or recurrent (Table 14.15).

Table 14.15. Principles of treatment HSV infection

First episode	
	Acyclovir, 200 mg, five times/day × 7 days Famciclovir, 250 mg, three times/day × 7 days Valacyclovir, 1 g, two times/day × 7 days
Recurrent episodes	
Herpes labialis	Symptomatic treatment
Herpes genitalis	Either: ❖ Episodic treatment with acyclovir, 200 mg, five times/day × 5 days ❖ Suppressive treatment (if >6 episodes/year): acyclovir 400 mg twice daily for 12 months.
Complications	
Disseminated infection Eczema herpeticum Encephalitis	Parenteral acyclovir
Immunosuppressed patients	Suppressive treatment

Maculopapular Viral Exanthems

Measles (*Rubeola*)

- ❖ **Incubation period:** 10 days.
- ❖ **Prodrome:** 2–4 days. Fever, photophobia, conjunctival injection, and upper respiratory catarrh.
- ❖ **Mucosal involvement:** **Koplik's spots** in buccal mucosa.
- ❖ **Cutaneous lesions:** Maculopapular confluent rash (deep red to brown) which evolves in a cranio-caudal fashion and fades with scaling.
- ❖ **Treatment:** Symptomatic. Watch for pneumonitis.
- ❖ **Prophylaxis:** Measles vaccine.

German Measles

- ❖ Very mild disease.
- ❖ Risk of congenital malformations in fetus, if pregnant woman is infected.
- ❖ Lymphadenopathy, followed by a transient, faint, erythematous, discrete macular rash.

Kawasaki Syndrome (*Mucocutaneous Lymph Node Syndrome*)

- ❖ **Etiology:** An antecedent corona virus infection was thought to be the cause, though recently superantigens of bacterial origin have been implicated.
- ❖ **Age:** Occurs in childhood, often before age of 2 years.
- ❖ **Clinical features:**
 - Fever of 5 or more days without other explanation.
 - And four of five of the following criteria:
 - Bilateral painless nonexudative conjunctival infection.
 - Oropharyngeal lesions, fissured lips, red pharynx, and strawberry tongue.
 - Erythema of acral parts, edema of hands and feet, periungual desquamation.
 - Polymorphous exanthem.
 - Acute nonsuppurative cervical lymphadenopathy.
- ❖ **Complications:** Self-limiting (a fortnight), though a few patients develop myocarditis and coronary artery disease.
- ❖ **Treatment:** Gamma globulin and aspirin (to reduce the risk of cardiac complications) mainstay of therapy.

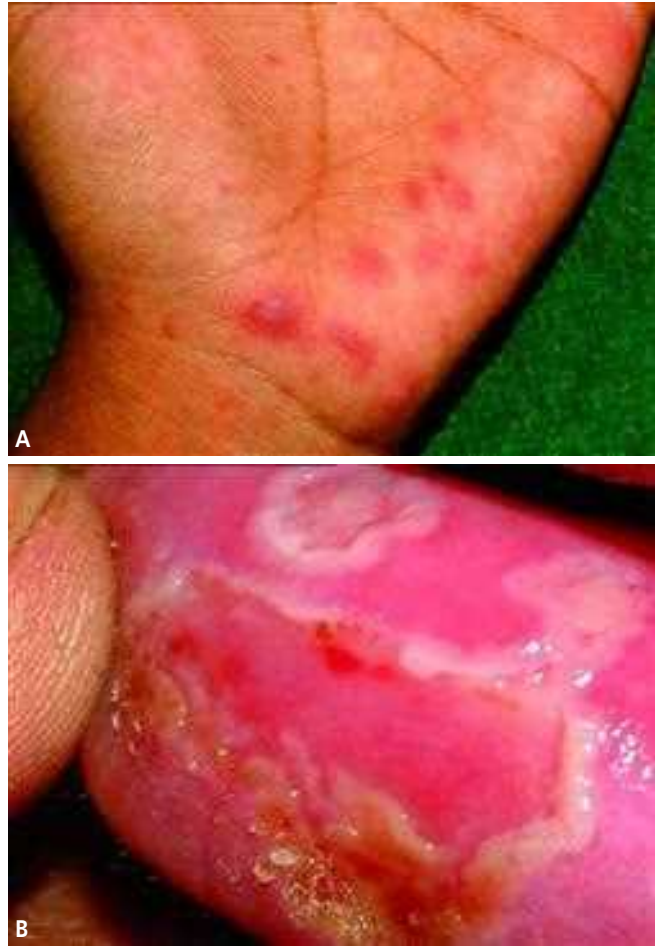

Fig. 14.58. Foot and mouth disease. A: painful oblong vesicles on hands (and feet). B: erosions in oral mucosa.

Hand, Foot, and Mouth Disease

- ❖ **Etiology:** Picorna virus infection of animals, which sometimes affects humans.
- ❖ **Age:** Occurs both in adults and children.
- ❖ **Clinical features:**
 - **Incubation period:** 2–18 days.
 - **Prodrome:** malaise, headache and fever, with burning in oral mucous.
 - **Mucocutaneous lesions:** painful vesicles in oral mucosa, and occasionally on palms, soles and interdigital skin. Vesicles are typically oblong (Figs. 14.58A and B).
 - Disease more severe in infants and children.
- ❖ **Treatment:** Symptomatic.

Fungal Infections

Fungal infections of the skin can be superficial or

deep (Table 14.16). Sometimes skin is affected as a part of systemic disease.

Table 14.16. Fungal infections of skin

Superficial fungal infections	Dermatophyte infection Pityriasis versicolor Candidiasis
Deep fungal infections	Mycetoma Sporotrichosis Chromoblastomycosis Subcutaneous phycomyosis
Systemic fungal infections	Histoplasmosis

Dermatophyte Infections (Ring Worm)

Synopsis

Etiology: Three genera of dermatophytes: *Trichophyton*, *Epidermophyton*, and *Microsporum*.

Morphology: *Prototype lesion:* Is an itchy, annular/arcuate polycyclic lesion with clear center and an active margin with papulovesicles and scaling. *Scalp lesions* manifest as discoid areas of noncicatrical alopecia with easily pluckable hair.

Sites: Lesions modified by site and named variously as *Tinea capitis* (scalp), *T. faciei* (face), *T. corporis* (trunk), *T. cruris* (groin), *T. pedis* (feet), *T. manuum* (hand), and *T. unguium* (nails).

Diagnosis: Typical clinical morphology as well as demonstration of fungal elements, using potassium hydroxide preparation.

Treatment: Topical therapy with imidazoles or allylamines for localized infection while nail infection, scalp infection, and extensive skin infection need to be treated with oral terbinafine or griseofulvin or itraconazole.

Etiology

- ❖ Three genera of dermatophytes infect skin and appendages (Table 14.17):
 - *Trichophyton*.
 - *Microsporum*.
 - *Epidermophyton*.
- ❖ Dermatophytes are keratinophilic fungi, living on dead keratin (so in stratum corneum).
- ❖ They induce inflammation in skin due to:
 - Permeation of their metabolic products into deeper layers.
 - Induction of delayed hypersensitivity.

Table 14.17. Genera of dermatophytes and the location of infection

Genera	Site of infection		
	Skin	Hair	Nails
Trichophyton	+	+	+
Microsporum	+	+	–
Epidermophyton	+	–	+

Clinical Features

Prototype lesion

- ❖ Is an annular or arcuate lesion which spreads **centrifugally**²⁸.
- ❖ The margin is active, showing papulovesiculation, pustulation, and scaling (Figs. 14.59A, B and C).
- ❖ Center is relatively clear, though in chronic lesions there may be nodules, hyperpigmentation and even **lichenification**²⁹ in the center.
- ❖ These features may be modified, depending on:
 - *Site of infection* (Fig. 14.60).
 - *Strain of fungus:*
 - **Anthropophilic fungi** (transmitted from human to human) induce less inflammation.
 - While **zoophilic fungi** (transmitted from animal to man) and **geophilic fungi** (from soil to man) induce significant inflammation.

Tinea capitis (tinea of scalp)

Age

Invariably a child³⁰.

Morphology

- ❖ Discoid patch of partial alopecia from which the hair can easily and painlessly be plucked.
- ❖ Degree of inflammation varies, depending on the strain of fungus, being more when tinea capitis is caused by zoophilic or geophilic species than with anthropophilic species.

Patterns

Three patterns are recognized:

28. **Centrifugally:** away from the center, like a fugitive!

29. **Lichenification:** thickening, hyperpigmentation, and increased skin markings.

30. **Tinea capitis in a child:** when making a diagnosis of *T. capitis* in an adult, think twice (may be thrice!).

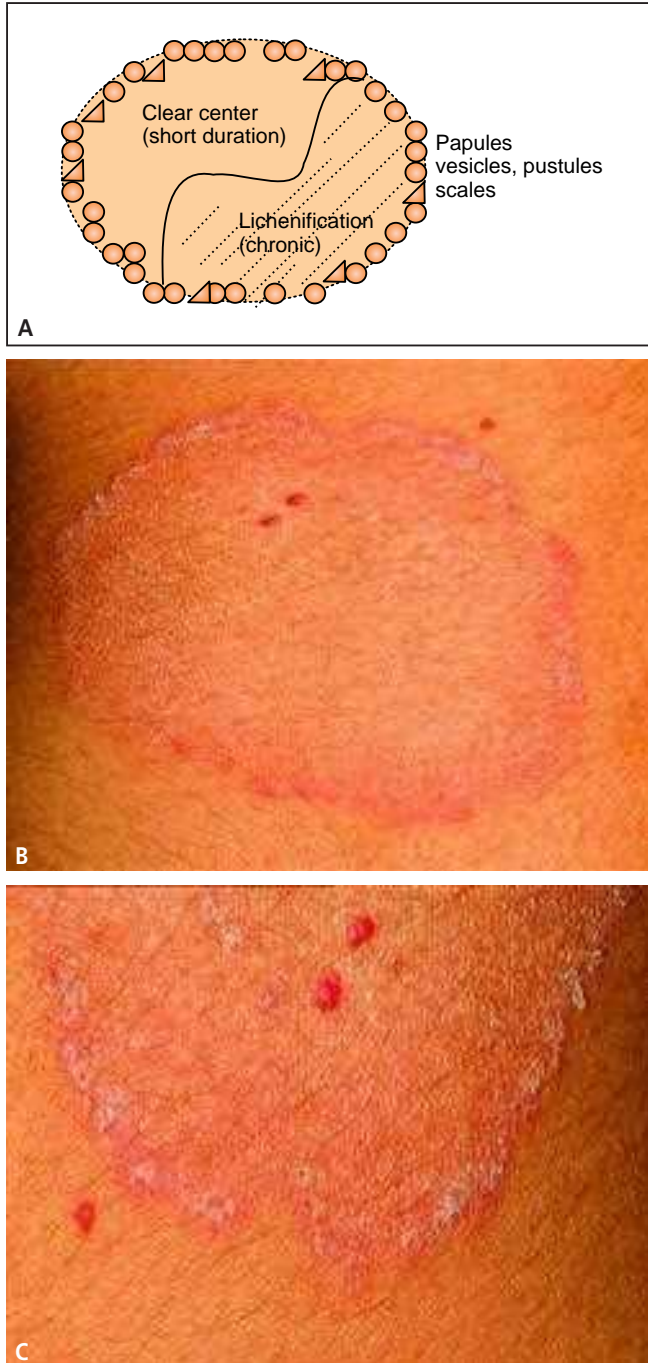

Fig. 14.59. Tinea: A: typical lesion. Margin is active with papules, vesicles, and pustules and the center is clear (if of short duration) or shows hyperpigmentation/lichenification/nodules (in chronic cases). B: typical annular plaque with activity at the edge and relative clearing in the center. C: edge of the lesion showing papulovesiculation and scaling.

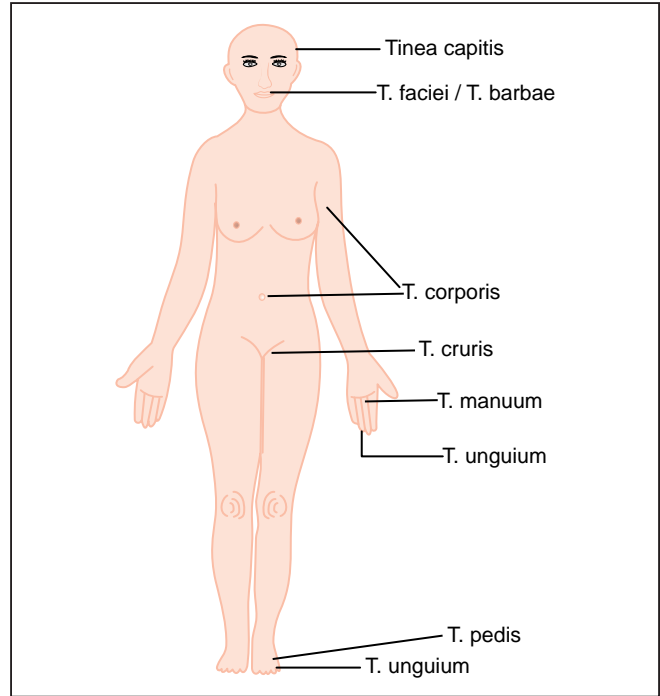


Fig. 14.60. Dermatophytic infection: sites and terminology.

❖ **Noninflammatory tinea capitis:**

- Caused by anthropophilic organisms (e.g., *T. verrucosum*), so less inflammation.
- Human to human spread occurs, so may occur in epidemics.
- Appear as partially bald areas with scaling most marked at the periphery. Hair present in the patch are lusterless, may break 3–4 mm from the scalp and can easily be plucked (Figs. 14.61A and B). The broken hair may appear as gray/black dots. There is very little inflammation (erythema, papules, and pustules).

❖ **Inflammatory tinea capitis (kerion)³¹:**

- Caused by zoophilic dermatophytes (e.g., *M. canis*), which elicit intense inflammation.
- Presents as a boggy swelling with pustulation. Often, the pus discharges from multiple orifices. Hair from such a swelling is easily and painlessly pluckable (Fig. 14.62).
- Lymphadenopathy (especially occipital) invariable.

31. **Kerion:** may also develop in the beard region of the face in adult males.

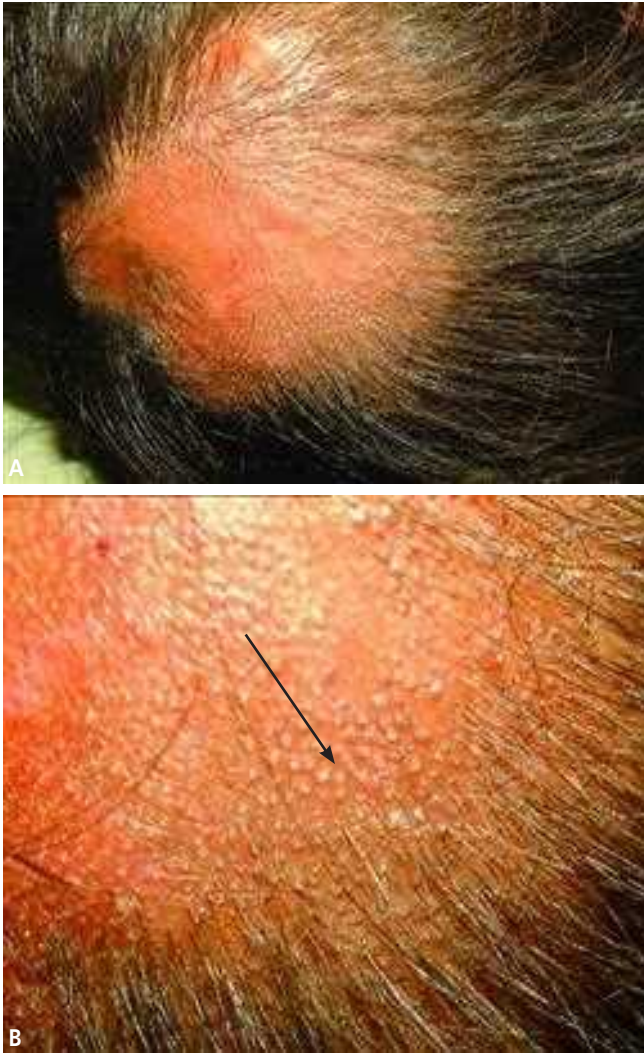

Fig. 14.61. Tinea capitis: A: area of nonscarring alopecia with scaling and minimal inflammation. B: note the broken hair and black dots.

❖ **Favus:**

- Caused by *T. schoenleinii*.
- Characterized by presence of foul-smelling, yellowish cup-shaped crusts entangling many scalp hair.
- Often results in cicatricial alopecia.

Tinea corporis (tinea of trunk and limbs)

Morphology

Annular/arcuate lesions with relative clearing in the center and an active periphery (Fig. 14.63).

Site

Infection of the glabrous skin, except palms, soles, and groins.

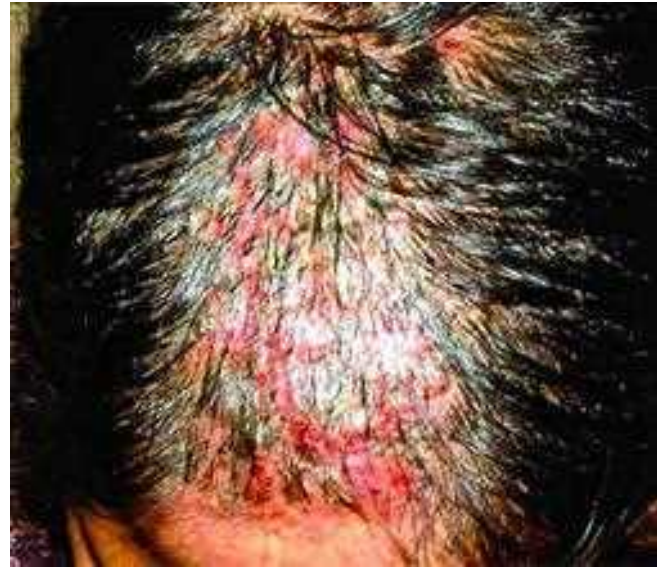

Fig. 14.62. Kerion: boggy swelling of scalp with easy pluckability of the hair.

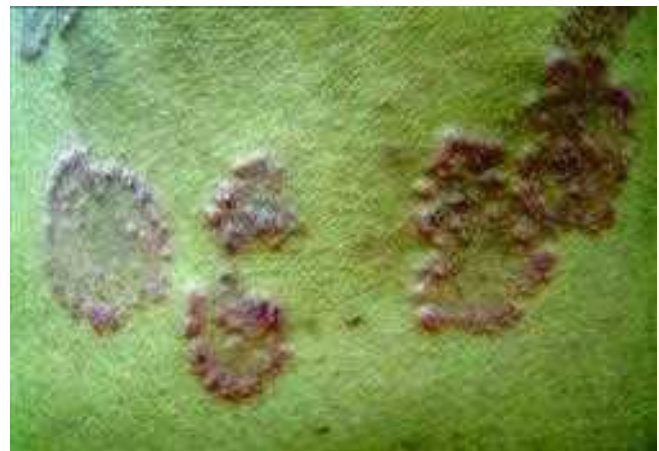

Fig. 14.63. Tinea corporis: annular lesions with active periphery showing papulation, vesiculation, and scaling.

Tinea incognito

- ❖ Dermatophytic infection of skin modified by steroid therapy.
- ❖ Atypical lesions (Figs. 14.64A and B), usually asymptomatic, poorly defined edge with minimal scales and papulovesicles.

Tinea cruris (tinea of groin)

Incidence

A very common condition.

Predisposing factors

- ❖ Summers and rainy season.

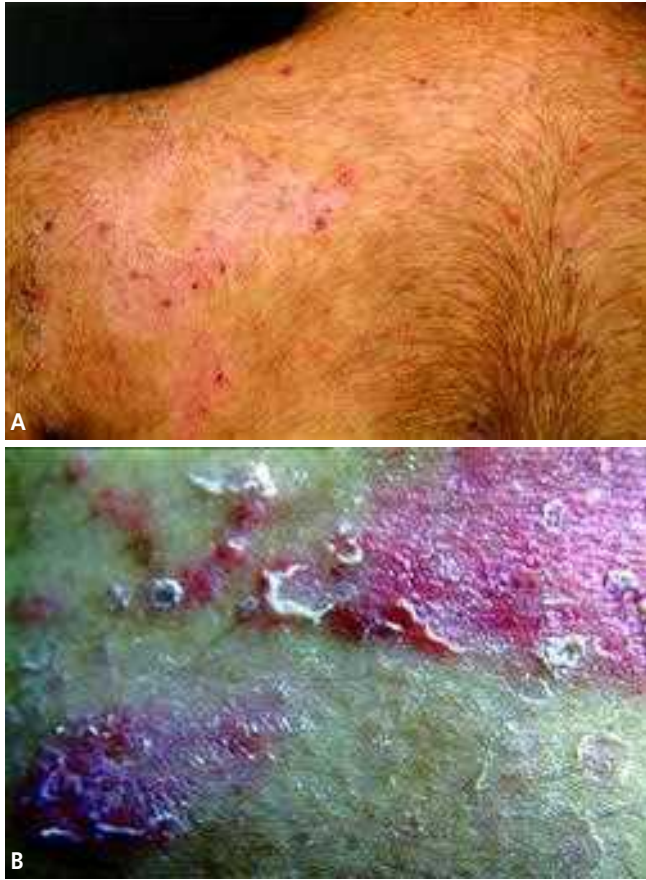

Fig. 14.64. Tinea incognito: A: loss of annularity. B: edge is frayed and not prominent.

- ❖ Occlusion; use of synthetic clothes.
- ❖ Affects men more often than women³² and adults more than children.

Site

Groins, genitalia, pubic area, perineal, and perianal areas.

Morphology

- ❖ Seen on the inner aspect of thighs as arcuate, sharply demarcated plaques with peripheral scaling, papulovesiculation, and pustulation.
- ❖ Lesions expand centrifugally and center clears.
- ❖ Chronic lesions may show hyperpigmentation, nodulation, and lichenification in center (Fig. 14.65).

Tinea pedis

Predisposing factors

- ❖ Hot moist weather.

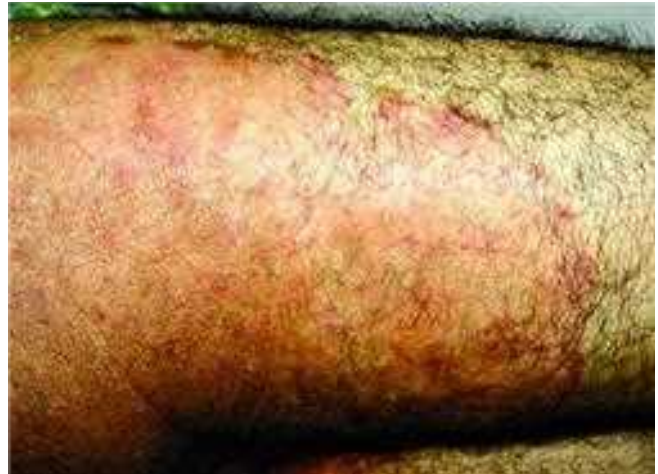

Fig. 14.65. Tinea cruris: arcuate lesion with active periphery on the inner aspect of thighs.

- ❖ Occlusive foot wear.
- ❖ Hyperhidrosis of soles.
- ❖ Sharing of wash places.
- ❖ Presence of tinea unguium.

Morphology

Three clinical patterns recognized:

- ❖ **Interdigital variant:** Interdigital scaling seen most frequently in the lateral two interdigital spaces (Fig. 14.66A) of the feet. When complicated by bacterial superinfection, labeled **athlete's foot**.
- ❖ **Hyperkeratotic variant:** Well-defined scaly plaque on the sole, usually unilateral.
- ❖ **Vesicular variant:** Recurrent vesiculation of soles (Fig. 14.66B).

Tinea manuum (tinea of hands)

- ❖ Dermatophytic infection of the hands is usually associated with tinea pedis.
- ❖ Lesions manifest as unilateral, well-defined plaques or as diffuse erythema of the palms with accumulation of fine scales in the creases (Fig. 14.67).

Tinea unguium (tinea of nails)

Tinea unguium is dermatophyte infection of nails (*cf.*, **onychomycosis**³³).

Incidence

- ❖ Tinea of toe nails is more frequent than that of finger nails and may be associated with tinea pedis.

32. No gender bias, this just an anatomical one!

33. **Onychomycosis:** any infection of nail caused by a fungus including dermatophytes, nondermatophytes, and yeasts.

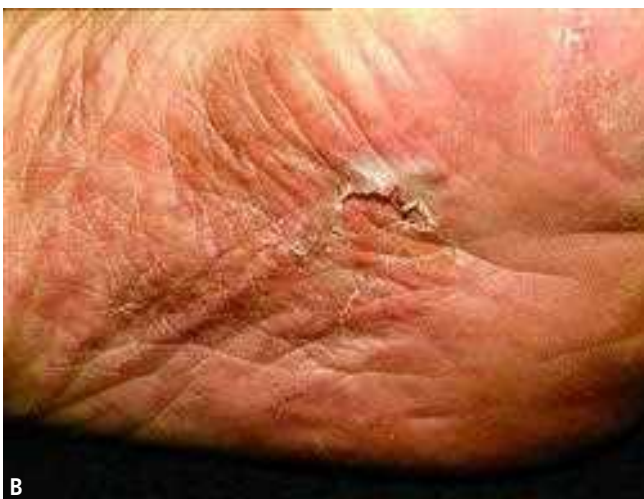
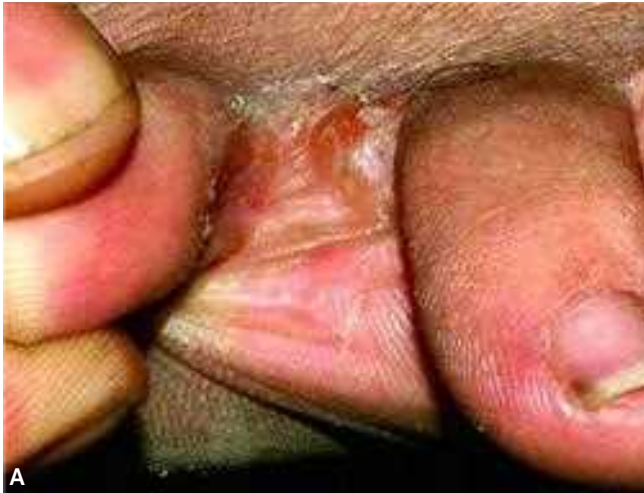
Fig. 14.66. Tinea pedis: A: interdigital variant: scaling, frequently in the lateral interdigital spaces. B: vesicular variant in which the vesicles have ruptured.

- ❖ Tinea of finger nails is associated with dermatophytic infection of other parts of the body, *e.g.*, tinea cruris.

Morphology

- ❖ Tinea unguium usually affects only a few nails and is asymmetrical.
- ❖ Nail involvement begins at the free edge of the **distal part of nail**³⁴ and the nail shows the following changes (Fig. 14.68):
 - Yellow-brown discoloration and crumbling and **tunneling** of nail plate.

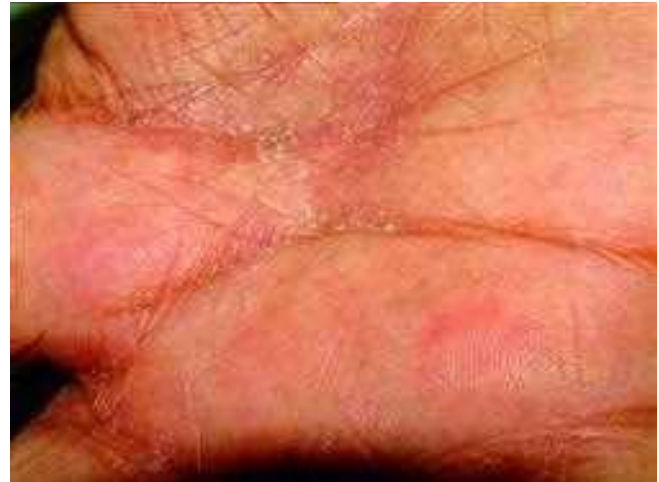

Fig. 14.67. Tinea manuum: erythema of palm with accumulation of fine scales in the creases.

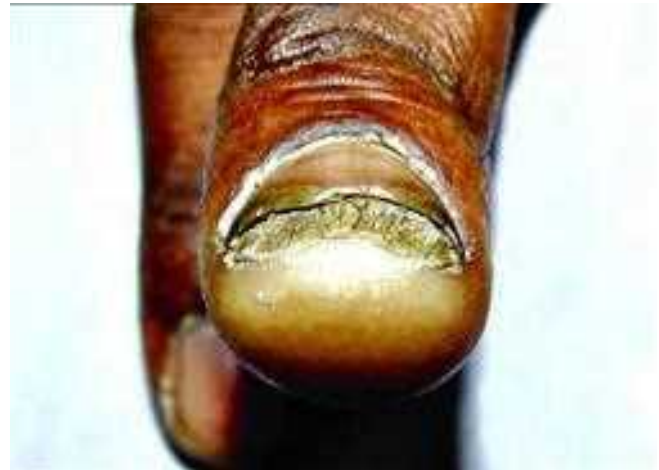

Fig. 14.68. Tinea unguium: thickened and discolored nail plate with tunneling; onycholysis is frequent.

- Collection of friable debris under the nail (**subungual hyperkeratosis**).
- Separation of nail plate from nail bed (**onycholysis**)³⁵.

Complications of tinea

- ❖ **Tinea incognito**³⁶ (P. 285).
- ❖ **Dermatophytide reaction:** Inflammatory tinea infection (*e.g.*, kerion, tinea pedis) may be associated with appearance of vesicles on the palms and soles (Fig. 14.69).

34. **Distal involvement:** some types of tinea unguium begin in proximal part of nail plate.

35. **Onycholysis:** “onycho” means nail; ‘lysis’ means breakdown or separation.

36. **Incognito:** means one whose identity is difficult to recognize, so tinea incognito is a tinea infection which is difficult to diagnose clinically.

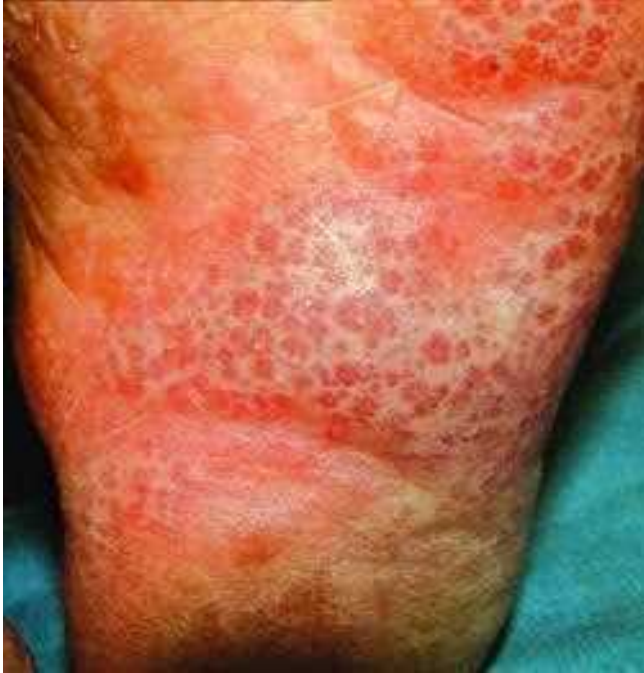

Fig. 14.69. Dermatophytide: vesicles on palms and soles associated with inflammatory tinea infection.

❖ **Cicatricial alopecia:** Though tinea capitis generally does not cause cicatricial alopecia, kerion (inflammatory tinea capitis) and favus can cause permanent hair loss.

Diagnosis

Points for diagnosis

The diagnosis of tinea is based on features shown in Table 14.18.

Table 14.18. Diagnostic features of tinea infection

Tinea corporis/cruris	<ul style="list-style-type: none"> ❖ Annular or arcuate lesion ❖ Periphery shows papulovesiculation and scaling and centre is relatively clear
Tinea capitis	<ul style="list-style-type: none"> ❖ Noninflammatory or inflammatory patch of alopecia ❖ Easy painless pluckability of hair
Tinea unguium	<ul style="list-style-type: none"> ❖ Asymmetrical involvement of few nails, which begins distally. ❖ Yellowish discoloration and thickening of nail plate. ❖ Nail plate shows crumbling. ❖ Friable debris under nail plate.

Differential diagnosis (Table 14.19)

Table 14.19. Differential diagnosis of dermatophyte infections

<i>T. capitis</i>	<i>T. corporis</i>	<i>T. cruris</i>	<i>T. unguium</i>
Alopecia areata (P. 132) Psoriasis Pityriasis capitis	Discoid eczema Pityriasis rosea (P. 55)	Candidal intertrigo (P. 293)	Nail psoriasis (P. 141)

Investigations

Potassium hydroxide (KOH) scraping

Simple, inexpensive, quick, and sensitive test.

Samples

Samples to be taken depend on the site of infection (Table 14.20).

Table 14.20. Specimen to be take in tinea infection

T. capitis	Plucked hair, black dots
T. cruris	Scales from edge
T. corporis	Scales from edge
T. unguium	Clippings of discolored nail plate; subungual debris

Technique

- ❖ Mount specimen on glass slide, adding 10% KOH (to dissolve the keratin). Keep for half an hour; nail clippings require longer (2 h) and warming (not boiling).
- ❖ Fungus is easily detected using the low power objective lens (10 ×) with the iris diaphragm closed and the condenser positioned down.

Interpretation (Table 14.21 and Figs. 14.70A and B)

Table 14.21. Interpretation of KOH mount

Tinea capitis	Branching hyphae Spores within (endothrix) (Fig. 14.70A) or around the hair (ectothrix)
Tinea cruris	Branching hyphae (Fig. 14.70B)
Tinea corporis	Branching hyphae (Fig. 14.70B)

Cultures

❖ Cultures need to be done when clinical suspicion is strong and KOH mount is negative. Or when it is necessary to identify the fungal species.

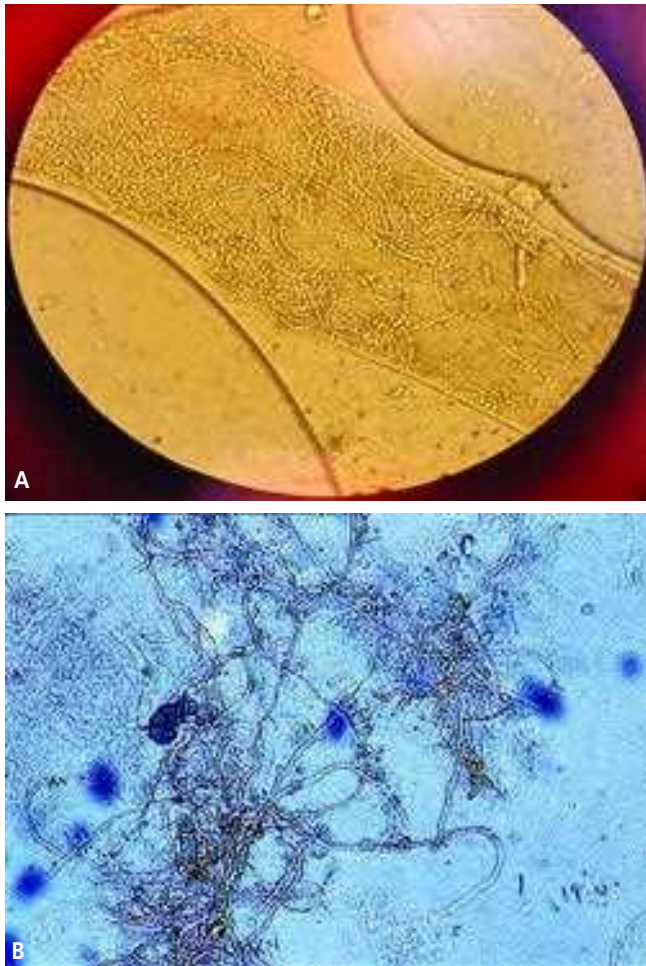


Fig. 14.70. KOH mount: A: spores inside hair shaft in tinea capitis. B: showing branching hyphae in tinea corporis.

- ❖ Send samples in a black paper envelope to the laboratory.
- ❖ Fungi are cultured on Sabouraud's dextrose agar. Growth may take up to 4 weeks.

Wood's light³⁷

- ❖ Wood's light examination is a useful method of screening outbreaks of tinea capitis in schools.
- ❖ Shine Wood's light (ultraviolet light) on the scalp; in many types of tinea capitis (though some fungi do not fluoresce), a green fluorescence is visible.

Treatment

Several factors determine the treatment modalities used:

- ❖ Site of lesions.
- ❖ Extent of lesions.
- ❖ Chronicity.
- ❖ Patient compliance.

Dermatophytic infections can be treated with topical as well as systemic antifungal agents. Topical agents are usually adequate for most localized skin infections. Systemic therapy is recommended in the following situations:

- ❖ Extensive dermatophytic infections.
- ❖ Tinea unguium.
- ❖ Tinea capitis.

General measures

- ❖ Keeping area dry.
- ❖ Avoiding use of synthetic clothes.
- ❖ In recurrent infection, prophylactic use of antifungal talc.

Topical agents (Table 14.22)

The topical antifungal agents include:

Table 14.22. Topical antifungals

Compound	Preparation	Comments
Azoles		
Miconazole, 2%	Cream	<ul style="list-style-type: none"> ❖ Broad spectrum (effective against dermatophytes, candida and Malassezia, also erythrasma) ❖ Fungistatic, so slow response (4–6 weeks) ❖ Low irritation/sensitization potential
Clotrimazole, 1%	Cream Lotion Powder	
Ketoconazole, 2%	Shampoo	
Econazole, 1%	Cream	
Sulconazole 1%	Cream	
Allylamines		
Terbinafine, 1%	Cream	<ul style="list-style-type: none"> ❖ Fungicidal, so rapid response (1–2 weeks) ❖ Narrow spectrum (effective against dermatophytes, Malassezia³⁸)
Butenafine, 1%	Cream	
Others		
Ciclopirox olamine, 1%	Cream Nail lacquer ³⁹	Broad spectrum
Amorolfine, 5%	Nail lacquer ⁴⁰	

37. **Wood's light:** a special lamp which emits light of 358 nm. Is an important bed side equipment for diagnosing certain skin infections (tinea fluoresces green, pityriasis versicolor yellow, erythrasma coral pink). Also used for accentuating barely perceptible brown pigmentation. And in porphyrias.

38. **Malassezia:** oral terbinafine is ineffective in pityriasis versicolor while topical is effective.

39. **Ciclopirox olamine nail lacquer:** used daily × 48 weeks for superficial onychomycosis including tinea unguium.

40. **Amorolfine nail lacquer:** once a week × 48 weeks for superficial onychomycosis including tinea unguium. Expensive

- ❖ **Azole derivatives:** Broad spectrum; imidazole derivatives like **miconazole**, **clotrimazole**, and **ketoconazole** are the mainstay of therapy in localized lesions of dermatophytes.
- ❖ **Allylamines:** Rapid response, so short course. Includes **terbinafine** and **butenafine**.
- ❖ **Morpholines:** Amorolfine, effective as a lacquer in fungal infections of nails, which would otherwise require systemic therapy.

Systemic therapy

Drugs available:

❖ **Terbinafine:**

- Fungicidal, so rapid response, fewer relapses.
- **Indications:** dermatophytic infections. Ineffective in pityriasis versicolor⁴¹ and candidiasis.
- **Dose:** 250 mg daily.
- **Duration of therapy:** varies with type of infection and site of involvement (Table 14.23).
- **Side effects:** taste disturbances, gut upsets. Rarely, hepatotoxic.

❖ **Griseofulvin:**

- Fungistatic.
- **Indications:** was the mainstay of systemic therapy for dermatophytic infection, now replaced by terbinafine. Continues to be drug of choice in tinea capitis. Ineffective in pityriasis versicolor and candidal infection.
- **Dose:** 10 mg/kg daily, after fatty meal.
- **Duration of therapy:** varies with type of infection and site involved (Table 14.23).
- **Side effects:** may cause persistent headache, nausea, vomiting, and skin eruptions; common cause of photosensitive reactions.
- **Avoid in:** pregnant women and in patients with liver failure, porphyria, and systemic lupus.
- **Drug interactions:** with coumarin anticoagulants and barbiturates.
- **Side effects:** taste disturbances, gut upsets. Rarely hepatotoxic.

❖ **Itraconazole:**

- Fungistatic.

- **Indications:** broad-spectrum antifungal agent, effective in dermatophytic infections, pityriasis versicolor, and candidal infection.
- **Dose:** 200–400 mg. To be taken with meals.
- **Side effects:** hepatotoxicity (but less than ketoconazole, so preferred) Avoid in children and pregnant and lactating women.
- **Drug interaction:** interacts with several drugs: H₂ receptor blockers, rifampicin, and warfarin.

Treatment protocols (Table 14.23)

Table 14.23. Treatment protocol for tinea infection

Tinea corporis	
Localized	Topical therapy (4 weeks)
Extensive	Oral terbinafine (2 weeks) Oral griseofulvin (4–6 weeks)
Tinea cruris	
Short duration	Topical therapy (4 weeks)
Chronic	Oral terbinafine (4–6 weeks) Oral griseofulvin (6–8 weeks)
Tinea capitis	
	Oral griseofulvin (8 weeks) Oral terbinafine (4–8 weeks)
Tinea unguium	
	Oral terbinafine (6 weeks for finger nails, 12 for toe nails) Oral itraconazole (2 pulses ⁴² for finger nails, 3 for toe nails) Oral griseofulvin (24 weeks for finger nails, 36 for toe nails)

Pityriasis Versicolor (PV)

Synopsis

Etiology: *Malassezia furfur*.

Morphology: Perifollicular, hypopigmented (or hyperpigmented), macules surmounted with branny scales.

Sites: Upper trunk, neck, upper arms.

Investigations: KOH mount shows characteristic 'spaghetti and meat ball' appearance.

Treatment: Topical imidazole derivatives, selenium sulfide. Systemic fluconazole, ketoconazole and itraconazole in extensive and recurrent lesions.

The old name **tinea**⁴³ versicolor should be discarded as PV is not caused by dermatophytes.

41. **Terbinafine:** oral is ineffective in pityriasis versicolor while topical terbinafine is.

42. **Pulse of itraconazole:** 400 mg daily for 7 days given every month.

43. **Tinea:** skin infection caused by dermatophytes. Term no longer used for malassezia infection. (Spell it correctly! *cf.*, taenia as in *Taenia solium* or tape worm.)

Etiology

*Malassezia furfur*⁴⁴ (earlier classified as *Pityrosporum ovale*), a commensal yeast.

Pathogenesis

- ❖ PV represents a shift in the relationship between host and resident yeast flora, the yeast overgrowing in hot and humid conditions.
- ❖ Releases carboxylic acid which causes hypopigmentation due to reduced tanning of skin.

Clinical Features

Symptoms

Asymptomatic.

Morphology

- ❖ Hypopigmented, (less frequently erythematous or hyperpigmented, so called **versicolor**⁴⁵) scaly, and perifollicular macules (Figs. 14.71A and B).
- ❖ Frequently coalesce but invariably the perifollicular character of the lesions is retained at the periphery of the lesions. (Fig. 14.71C).
- ❖ Scaling is branny and can be accentuated, if the lesion is scratched (*e.g.*, with help of a glass slide).

Sites of predilection

Upper trunk, often spreading to the neck and upper arms (Fig. 14.72).

Investigations

- ❖ KOH mount shows a mixture of short, branched hyphae and spores (Fig. 14.73) described as **spaghetti and meat ball appearance**.
- ❖ Culture is of little help.

Diagnosis

Points for diagnosis

Diagnosis of PV is based on presence of:

- ❖ Hypopigmented, perifollicular macules that become confluent. Lesions appear to be sitting on the skin.
- ❖ Branny scales, accentuated by scratching with glass slide.
- ❖ Upper trunk and neck.

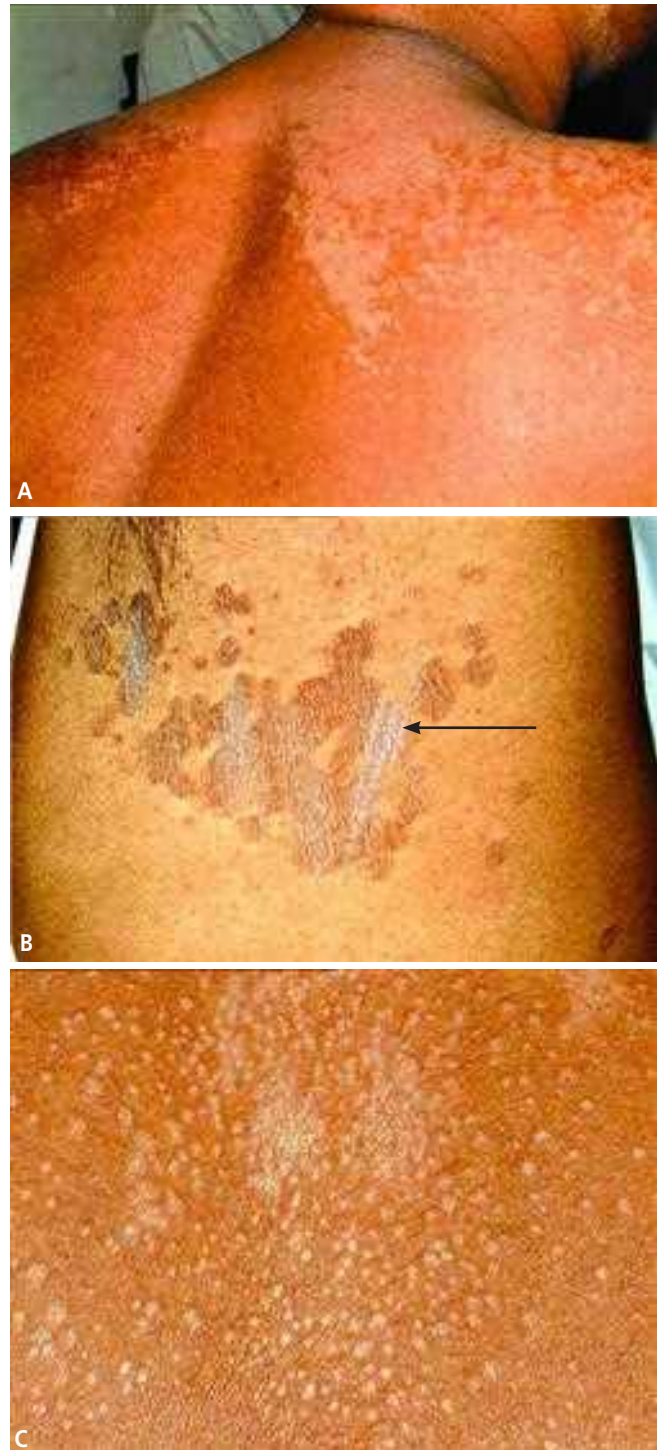

Fig. 14.71. Pityriasis versicolor: A: perifollicular, hypopigmented macules with branny scales. B: sometimes lesions are hyperpigmented. Note accentuation of scaling on scratching. C: perifollicular lesions.

44. *Malassezia furfur*: implicated in pityriasis versicolor and malassezia folliculitis. Latter characterized by follicular papules often surmounted by pustules. On trunk and chest. Usually adolescents and young adults.

45. **Versicolor**: variety of colors.

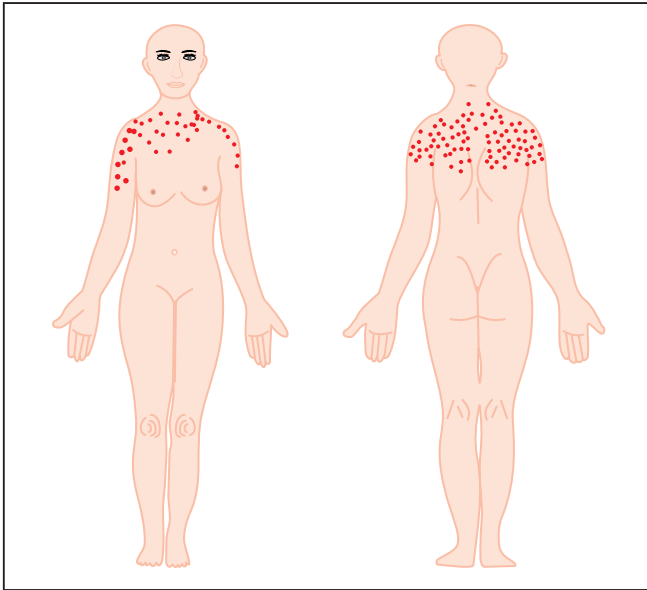


Fig. 14.72. Pityriasis versicolor: sites of predilection.

- ❖ KOH mount confirmatory.

Differential diagnosis

PV should be differentiated from:

a. Vitiligo

Vitiligo	PV
<i>Morphology:</i> well-defined depigmented macules (sometimes hypopigmented)	Hypopigmented, perifollicular lesions
<i>Scaling:</i> no scaling	Branny scaling
<i>Perifollicular orientation:</i> on treatment, repigmentation begins in perifollicular region	Initial lesions perifollicular.
<i>Leucotrichia</i> ⁴⁶ : present	Absent

b. Leprosy

Leprosy	PV
<i>Morphology:</i> hypopigmented, atrophic lesions (plaques and nodules may be +)	Always macular.
<i>Scaling:</i> seen in subsiding reaction	Scaly, perifollicular macules
<i>Loss of sensations:</i> conspicuous	Sensations preserved
<i>Hair:</i> may be lost	Hair preserved

Treatment

Though the fungal infection is controlled easily, the hypopigmentation often persists.

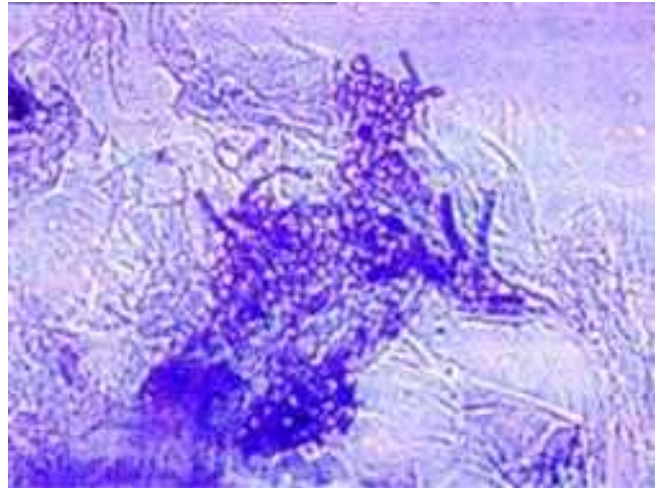


Fig. 14.73. Pityriasis versicolor: KOH mount showing spaghetti and meat ball appearance.

Topical agents

- ❖ **Imidazoles:** Ketoconazole, 2% applied daily for 4 weeks.
- ❖ **Selenium sulfide:** 2.5% lotion in a detergent base, used weekly for 4 weeks. It can cause irritation (prevented by diluting the lotion with water).

Systemic agents

Needed in extensive lesions or when recurrences are frequent:

- ❖ **Ketoconazole**, 200 mg daily for three consecutive days.
- ❖ **Fluconazole**, 400 mg single dose.
- ❖ **Itraconazole**, 200 mg daily for 7 days.

Candidiasis

Synopsis

Etiology: *Candida albicans*, a normal commensal becomes pathogenic in the presence of predisposing factors (diabetes, obesity, intake of antibiotics and oral contraceptives, immune suppression).

Clinical features: Variety of manifestations: Some benign like intertrigo, paronychia, oral and genital infections. Others more sinister like chronic mucocutaneous and systemic candidiasis.

Treatment: *Topical therapy:* Benign candidiasis. *Systemic therapy:* In recurrent disease, in immunocompromised patients, systemic candidiasis and chronic mucocutaneous candidiasis.

46. **Leucotrichia:** Leuco: white, **trichia:** hair. So white hair.

Etiology

- ❖ ***Candida albicans* (*C. albicans*)**, a dimorphous fungus (yeast and filamentous forms), exists as a commensal in oral mucosa (50% of normal humans) and vagina (25% of normal women).
- ❖ The commensal becomes pathogenic in the presence of following predisposing factors:
 - **Moisture:** areas of occlusion (intertriginous areas) and prolonged immersion in water (nail folds).
 - **Obesity:** friction and maceration in the folds encourages growth of candida.
 - **Diabetes** and other endocrinopathies.
 - Use of broad-spectrum antibiotics and metronidazole.
 - **Pregnancy and oral contraceptive pills:** due to change of vaginal flora.
 - **Immunocompromised states:** may lead to systemic candidiasis or to chronic mucocutaneous candidiasis. Oral candidiasis is the most common fungal infection seen in HIV-positive patients, occurring in 50% of HIV-positive patients and in 90% of AIDS patients.

Clinical Features

Candidal infection may present as:

- ❖ Acute mucocutaneous candidiasis.
- ❖ Chronic mucocutaneous candidiasis.
- ❖ Systemic candidiasis.

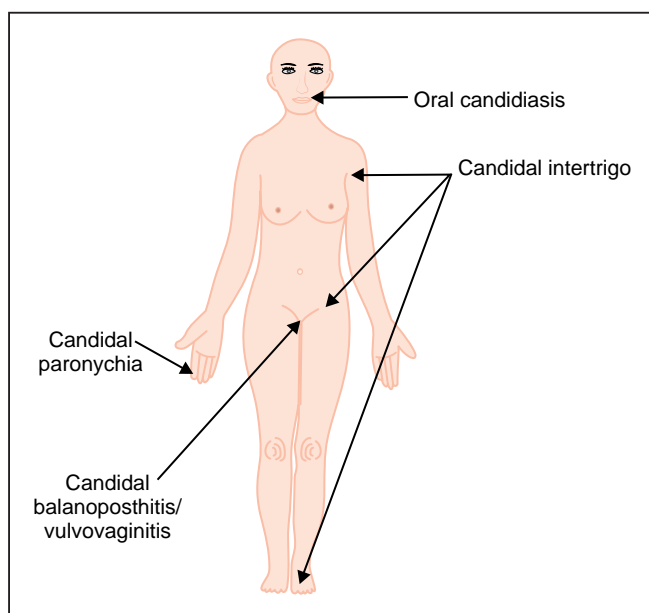


Fig. 14.74. Acute mucocutaneous candidiasis: sites of predilection.

Acute mucocutaneous candidiasis

The sites of predilection of acute mucocutaneous candidiasis are shown in Fig. 14.74.

Flexural candidiasis (*candidal intertrigo*)

- ❖ **Predisposing factors:** Obesity, moisture, wearing of occlusive clothing, and diabetes.
- ❖ **Morphology:** Begins in depth of fold (at sites of friction) as a moist glazed area of erythema and maceration. The edges show frayed scaling and satellite subcorneal pustules (Fig. 14.75A).
- ❖ **Sites of predilection:** Any skin fold (especially in obese individuals) can be affected. Inframammary area (in women), axillae and groins, natal cleft, and in between fingers and toes (Fig. 14.75B).

Candidal paronychia

- ❖ **Predisposing factors:** Wet work (cooks, bakers not to forget housewives), diabetes and presence of genital candidiasis (because of direct inoculation).

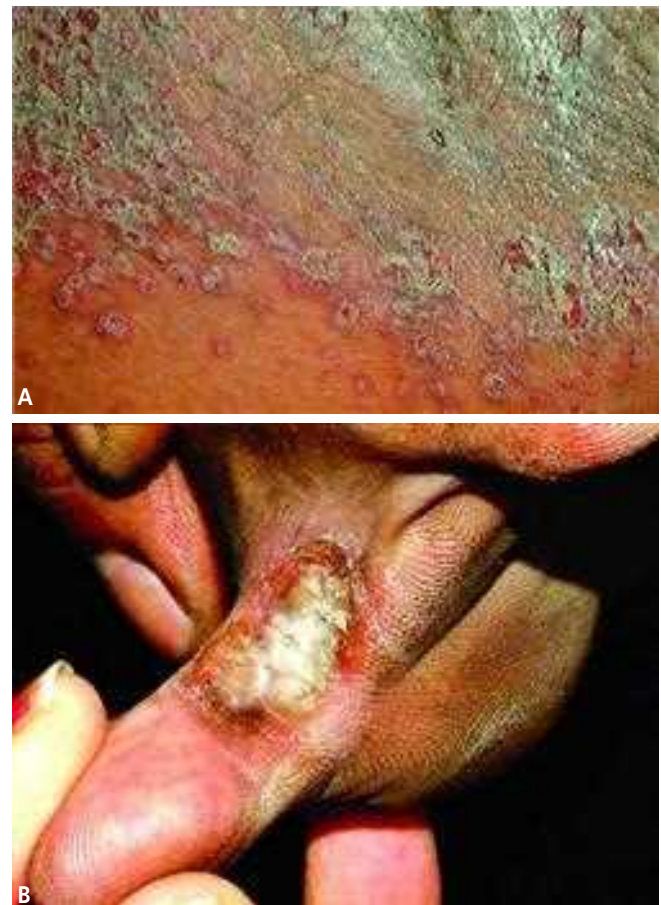

Fig. 14.75. Flexural candidiasis: A: frayed lesion in the groin with satellite pustules. B: maceration between toes.

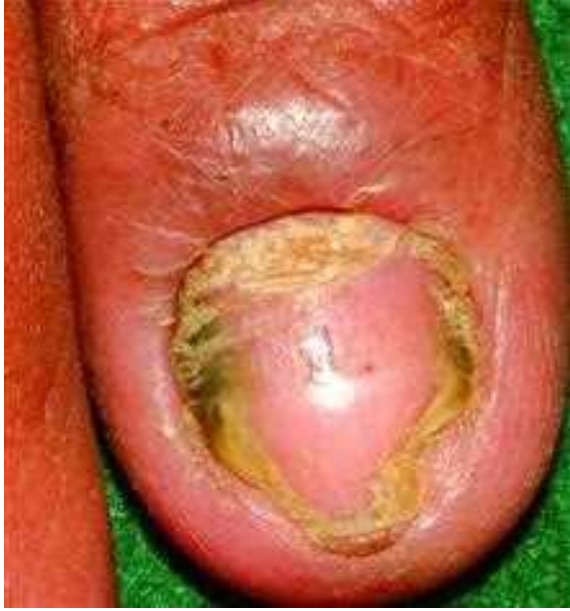

Fig. 14.76. Candidal paronychia: rolled proximal nail fold and loss of cuticle. Secondary nail changes in long-standing disease.

- ❖ **Morphology:** Cuticles are lost and proximal nail fold becomes red and rolled (Fig. 14.76). On pressing, small bead of pus can be expressed from under the proximal nail fold. Over period of time, the adjoining nail plate becomes yellow-brown and ridged.

Genital candidiasis

- ❖ **Predisposing factors:** Diabetes, pregnancy, use of oral contraceptives and broad-spectrum antibiotics. May be sexually transmitted.
- ❖ **Manifestations:** Depends on the gender of patient.
 - **Candidal vulvovaginitis:** presents as intense itching in the vulva and presence of white curdy vaginal discharge. When severe, the vulva becomes edematous and erythematous.
 - **Candidal balanoposthitis:**
 - Presents as fragile papulopustules on glans or coronal sulcus. Rupture to form well-defined, erythematous erosions, which may show a collarette of white scales (Fig. 14.77).
 - Sometimes presents with transient erythema and burning immediately after intercourse (due to hypersensitivity to candida) with a partner with candidal vulvovaginitis.

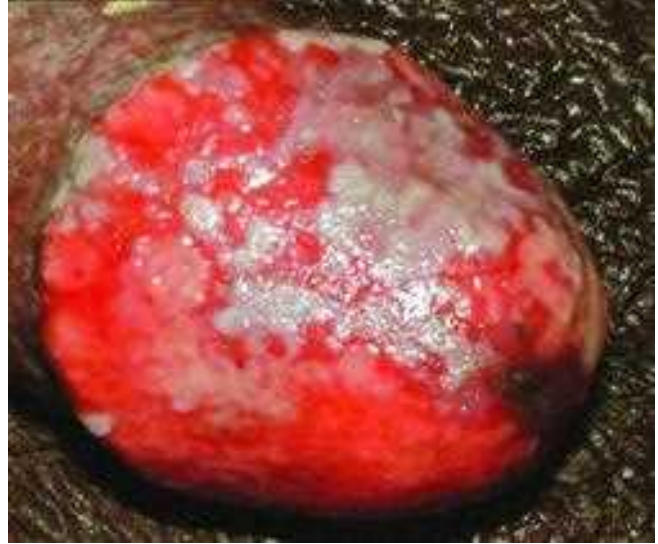

Fig. 14.77. Candidal balanoposthitis: curdy white membrane with erythematous erosions.

Oral candidiasis

Always a disease of diseased (except in neonates). Several different patterns recognized:

- ❖ **Acute pseudomembranous candidiasis (thrush):**
 - Most common form of oral candidiasis.
 - Seen in infants. Also older patients on broad-spectrum antibiotic and steroid therapy.
 - Presents as white adherent plaques, which are difficult to remove. On removal, an erythematous base is revealed.
 - Seen on buccal mucosa, tongue, palate, and gingiva.
- ❖ **Acute atrophic candidiasis:**
 - Seen on dorsal aspect of tongue as patchy depapillated areas.
- ❖ **Angular stomatitis (Fig. 14.78A):**
 - Usually in denture wearers.
 - Manifests as white plaques at the angle of the mouth.
- ❖ **Chronic atrophic candidiasis:**
 - In denture wearers.
 - Sharply defined areas of erythema and edema on the palate (area in contact with dentures).
- ❖ **Candidal leucoplakia:** Rough white-grey plaque on buccal mucosa or tongue with erythematous halo (Fig. 14.78B). Cannot be removed. Has premalignant potential.

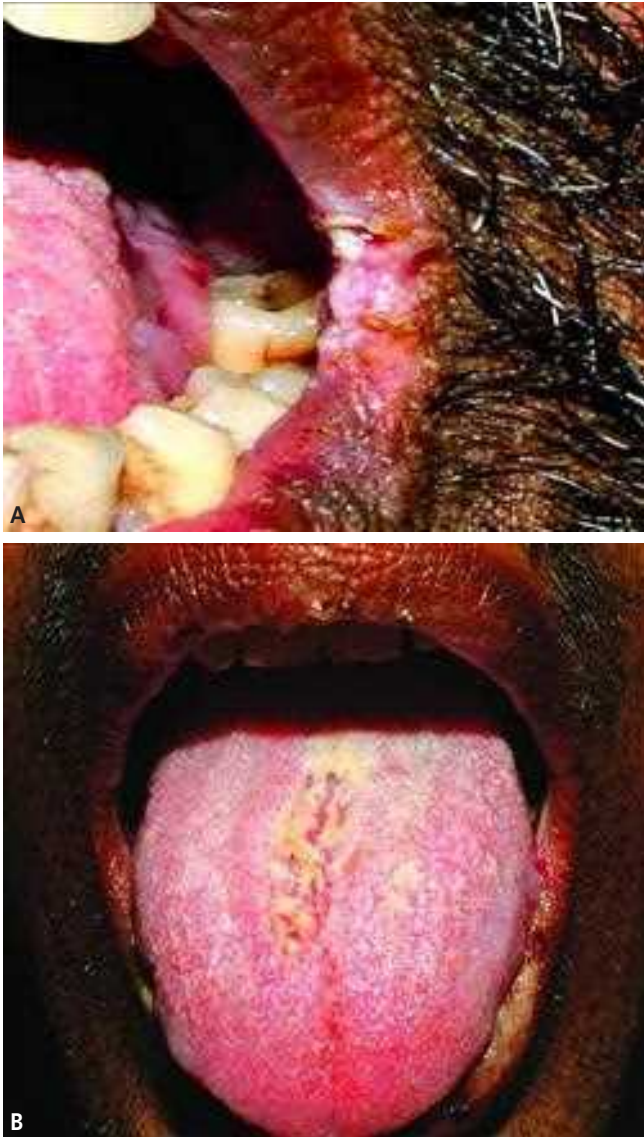

Fig. 14.78. Oral candidiasis: A: angular stomatitis: white plaque at the angle of mouth. B: candidal leucoplakia: rough white-grey plaque on dorsal aspect of tongue with erythematous halo.

Chronic mucocutaneous candidiasis

Heterogeneous group of clinical syndromes.

Predisposing factors

- ❖ **Genetic susceptibility:** Both autosomal recessive and dominant variants recognized.
- ❖ **Associated with endocrinopathies:** Associated with hypoparathyroidism, Addison's disease and thymomas.

Manifestations

Persistent candidal infection in oral mucosa (all forms), skin and nails.

Systemic candidiasis

- ❖ Seen against a background of severe illness, leucopenia, and immunosuppression (AIDS/iatrogenic).
- ❖ Cutaneous and visceral infections.

Investigations

- ❖ KOH mount shows budding yeasts and pseudohyphae.
- ❖ Culture from suspected lesion. A positive culture, however should be interpreted cautiously in the absence of a positive KOH mount.
- ❖ Rule out diabetes in patients with recurrent infection. Rule out immunocompromised states in recurrent/extensive/atypical disease.

Treatment

General measures

- ❖ Predisposing factors should be sought and eliminated. Diabetes mellitus should be ruled out and patients taking long-term broad-spectrum antibiotics (including metronidazole) should stop taking them.
- ❖ Intertriginous areas should be kept dry by adequate wiping after a bath. In paronychia, prolonged immersion in water is best avoided. Use of **gloves**⁴⁷ may help.

Specific treatment

Topical agents

Imidazoles (broad spectrum), amphotericin, and nystatin⁴⁸ are effective.

- ❖ **Candidal intertrigo:** Topical azoles (clotrimazole, miconazole, and ketoconazole) are effective.
- ❖ **Candidal paronychia:** Topical azole lotions and a topical antibiotic. If acute paronychia is superimposed, then a course of oral antibiotic therapy may facilitate response.
- ❖ **Oral candidiasis:** Lotions and oral suspensions of azoles. Or nystatin.
- ❖ **Genital candidiasis:** Imidazole pessaries for vaginal infection. Topical azoles for balanoposthitis.

47. **Gloves:** are a double edged sword. May worsen paronychia if water trickles into the glove!

48. **Nystatin:** specifically anticandida.

Systemic therapy

Systemic therapy is recommended in the following situations:

- ❖ **Candidal vulvovaginitis:** Single dose fluconazole (150 mg) or itraconazole (400 mg). Weekly doses of fluconazole (150 mg) for recurrent problem.
- ❖ **Recurrent oral candidiasis:** In immunocompromised patients (e.g., HIV infection), fluconazole, 150 mg weekly dose.
- ❖ **Chronic mucocutaneous candidiasis:** Requires prolonged therapy.

Deep Fungal Infections

Mycetoma

Etiology

- ❖ Two groups of organisms cause mycetoma, the species varying from geographic area to area (Table 14.24).
- ❖ Organism is implanted in skin of trauma-prone sites by a penetrating injury (often trivial).

Table 14.24. Organisms causing mycetoma

Actinomycetoma	Eumycetoma
<i>Nocardia brasiliensis</i>	<i>Madurella mycetomatis</i>
<i>Streptomyces somaliensis</i>	<i>Madurella grisea</i>
<i>Actinomadura madurae</i>	<i>Petriellidium boydii</i>

Epidemiology

- ❖ **Geographical distribution:** Most cases reported from dry tropics and subtropics. Habit of walking bare foot predisposes.
- ❖ **Gender:** Males > females.

Clinical features

Morphology

- ❖ Clinically, actinomycetoma and eumycetoma are similar.
- ❖ Begin as subcutaneous nodules, which slowly evolve into abscesses and draining sinuses (Fig. 14.79A). Over period of time, the surrounding tissue becomes hard due to fibrosis.
- ❖ Discharge may be serosanguinous or seropurulent and contains granules, which are usually dark (Fig. 14.79B) in eumycetoma and pale in actinomycetoma.

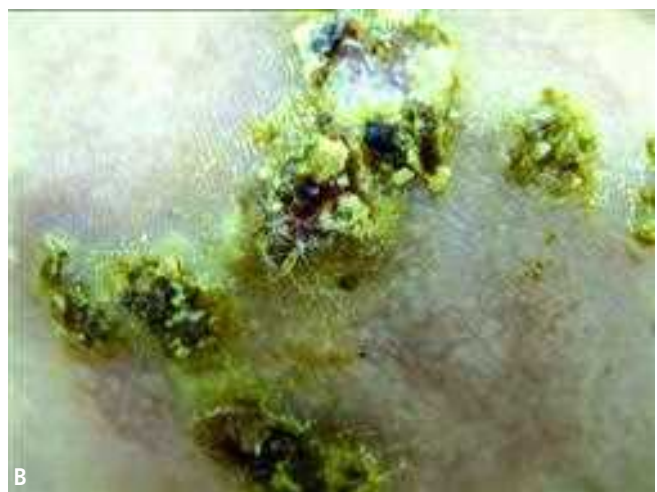
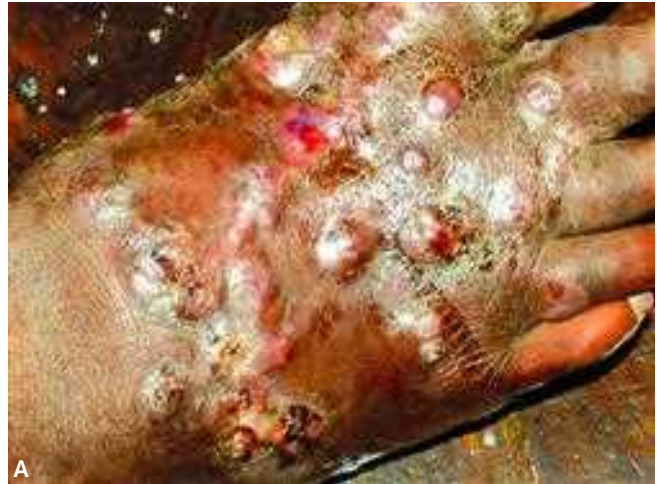
Fig. 14.79. Mycetoma: A: nodular, firm, hard swelling of the foot. B: black granules.

Sites of predilection

- ❖ **Foot**⁴⁹ is the most frequently involved site.
- ❖ Less commonly, other trauma prone sites like hands may be affected.
- ❖ Rarely, gluteal region and thighs may be involved.

Complications

- ❖ Involvement of deeper tissues (bones of feet and hands) may cause deformities in long-standing cases.

Investigations

Investigations need to be done to:

- ❖ Establish the diagnosis of mycetoma.
- ❖ Identify the causative organism (*actinomycetes* vs *eumycetes*).

49. **Foot:** so called Madura foot.

- ❖ Find the extent of local spread.

The following investigations should be done in all cases:

Examination of pus and granules

Examination of a KOH mount of granules helps to:

- ❖ Establish diagnosis of mycetoma.
- ❖ May help to differentiate actinomycetoma and eumycetoma because the filaments of actinomycetes are thinner than those of eumycetes.

Histology

To establish the diagnosis and may help to distinguish actinomycetoma and eumycetoma.

Culture

To confirm the causative agent and to differentiate eumycetoma from actinomycetoma.

X-ray of the affected part

- ❖ Indicates the extent of involvement.
- ❖ Lytic lesions in underlying bones more frequent in eumycotic mycetoma.

Diagnosis

Points for diagnosis

Diagnosis of mycetoma is based on:

- ❖ Presence of firm nodular swelling.
- ❖ Sinuses that discharge dark (eumycetoma) or pale colored (actinomycetoma) granules.
- ❖ Involvement of trauma prone sites, e.g., feet.

Treatment

Treatment depends on whether the mycetoma is actinomycotic or eumycotic.

Actinomycetoma

Responds to a 6–9 months course of combination of chemotherapeutic⁵⁰ agents like:

- ❖ Streptomycin + dapsone or co-trimoxazole.
- ❖ Co-trimoxazole + amikacin.
- ❖ Tetracyclines + streptomycin + rifampicin.
- ❖ Penicillins + gentamycin + co-trimoxazole.

Eumycetoma

The following modalities can be tried:

- ❖ **Medical treatment:** The following drugs may be tried:
 - Ketoconazole.

- Itraconazole.
- Amphotericin B in resistant cases.

- ❖ **Surgical intervention:** Deep debridement and even amputation may need to be done in case of recalcitrant lesions.

Sporotrichosis

- ❖ **Causative agents:** *Sporothrix schenckii*.

- ❖ **Morphology:** two main types:

- **Lymphangitic type:** manifests as an asymptomatic nodule which ulcerates. Over a period of time, a chain of asymptomatic nodules appear along the lymph vessels draining the area (Fig. 14.80A). Think of sporotrichosis when granulomatous plaques/nodules are aligned in a linear arrangement. Lesions may be joined by a deep-seated cord.
- **Fixed:** single infiltrated plaque (Fig. 14.80B).

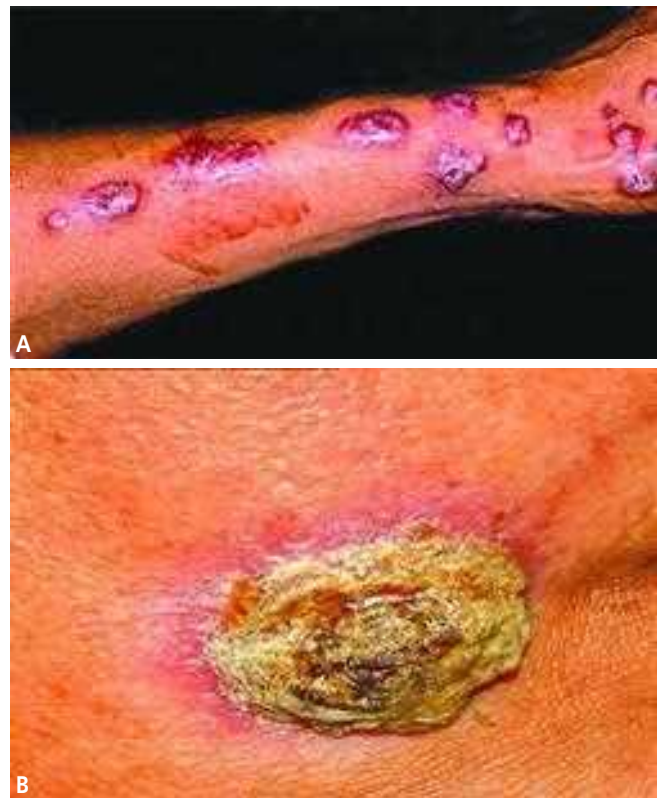

Fig. 14.80. Sporotrichosis: A: Lymphangitic type: ulcerated nodules are arranged in a linear fashion along the lymphatic drainage. B: fixed type.

50. **Chemotherapeutic agents:** often given in two steps: Aggressive phase and maintenance phase.

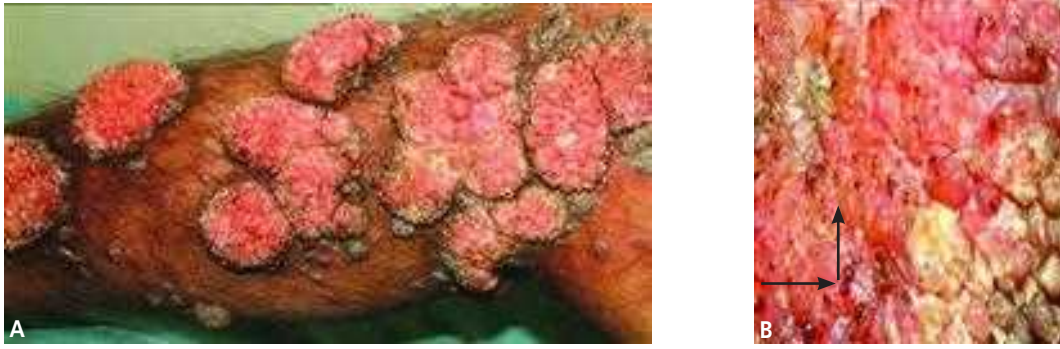

Fig. 14.81. Chromoblastomycosis: verrucous plaques on lower extremity. B: studded with black dots.

- ❖ **Treatment:** Saturated solution of potassium iodide. Or itraconazole.

Chromoblastomycosis

- ❖ Several fungi can cause chromoblastomycosis.
- ❖ **Morphology:** A painless warty papule, slowly enlarges to form a cauliflower-like hypertrophic plaque (Fig. 14.81A). Characteristically, surface is studded with black dots (Fig. 14.81B).
- ❖ **Sites of predilection:** Trauma prone sites.
- ❖ **Treatment:** Itraconazole, flucytosine, and amphotericin B.

Subcutaneous phycomycosis

- ❖ **Causative agents:** *Basidiobolus ranarum* and *Conidiobolus coronatus*.
- ❖ **Morphology:** Slowly spreading, painless subcutaneous swelling with smooth edge which can be raised by inserting a finger under it. Does not ulcerate (Fig. 14.82).
- ❖ **Sites of predilection:** two common sites:
 - Limbs.
 - Centrofacial region.
- ❖ **Treatment:** Potassium iodide gives gratifying response.

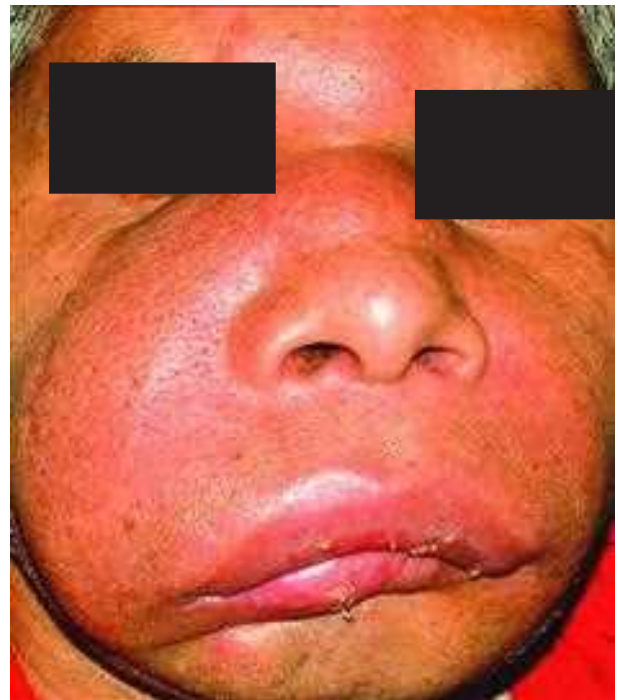

Fig. 14.82. Subcutaneous phycomycosis: well-defined firm plaque with a typical edge. Melts away with potassium iodide.

Sexually Transmitted Infections and HIV Infection

15

Chapter Outline

Sexually Transmitted Diseases

- Syphilis
- Chancroid
- Donovanosis
- Lymphogranuloma venereum
- Herpes genitalis
- Gonococcal infection
- Chlamydial genital tract infection
- Anogenital warts
- Molluscum contagiosum
- Candidal genital infection

Syndromic Management of STDs

- Basis of syndromic management
- Advantages of syndromic management
- Algorithms for syndromic management

HIV Infection and AIDS

- Etiology
- Epidemiology
- Natural history of HIV infection
- Acute retroviral syndrome
- Asymptomatic infection
- Early symptomatic stage of HIV infection
- AIDS
- Investigations
- Treatment

- Should know
- Good to know

Introduction

- ❖ The term for infections transmitted sexually has changed from venereal diseases (VDs) to sexually transmitted diseases (STDs) and now to sexually transmitted infections (STIs)¹.
- ❖ STIs have again come into focus due to arrival of human immunodeficiency virus (HIV) pandemic.
- ❖ These infections can be caused by several organisms (Table 15.1) and can have a variety of manifestations (Table 15.2).

Table 15.1. Etiology of common STIs

Diseases	Causative organisms
Syphilis	<i>Treponema pallidum</i>
Chancroid	<i>Haemophilus ducreyi</i>
Herpes genitalis	<i>Herpes simplex virus</i>
Donovanosis	<i>Klebsiella granulomatis</i>
Lymphogranuloma venereum	<i>Chlamydia trachomatis</i>
Gonococcal genital infections	<i>Neisseria gonorrhoeae</i>
Nongonococcal genital infections	<i>Chlamydia trachomatis</i> <i>Mycoplasma genitalium</i> <i>Ureaplasma urealyticum</i> <i>Gardnerella vaginalis</i> <i>Candida albicans</i>
Anogenital warts	<i>Human papilloma virus</i>

1. **Diseases transmitted sexually:** several terms used; an earlier term, VD included the classical five—syphilis, chancroid, gonorrhoea, lymphogranuloma venereum, and donovanosis. Later the term STDs was introduced to include all infections transmitted sexually and affecting the genitals. And now the term STIs is used to encompass infections transmitted sexually affecting not only the genitals but other organs as well, *e.g.*, hepatitis B.

Table 15.2. Manifestations of STIs

Manifestations	Diseases
Ulcers	Herpes genitalis Primary syphilis Chancroid Donovanosis
Discharge	Gonococcal infection Chlamydial infection Bacterial vaginosis Trichomoniasis Ureaplasma infection Mycoplasma infection
Lymphadenopathy	Chancroid Syphilis Herpes genitalis Lymphogranuloma venereum
Rash	Secondary syphilis HIV infection Lymphogranuloma venereum Scabies
Itching	Scabies HIV infection Pediculosis pubis
Nodules	Anogenital warts Molluscum contagiosum Kaposi's sarcoma Scabies

Sexually Transmitted Infections

Syphilis

Synopsis

Etiology: *Treponema pallidum*.

Transmission: Most frequently sexual; less frequently through blood transfusion and transplacentally (congenital syphilis).

Stages: Primary, secondary, latent, and tertiary.

Incubation period: 9–90 days.

Primary stage: Single, indurated, clean, painless ulcer, oozes serum on pressure. Shotty regional lymphadenopathy.

Secondary stage: Generalized rash (maculopapular, psoriasiform, even nodular *but never vesiculobullous*). Mucosal lesions (mucous patches and snail track ulcers), intertriginous condyloma lata and shotty, generalized lymphadenopathy.

Latent stage: No clinical lesions, only serological evidence of syphilis.

Tertiary stage: Cutaneous, mucosal and bone gumata. And cardiovascular and central nervous system involvement.

Investigations: *T. pallidum* (on dark ground microscopy) from chancre and from lesions of secondary syphilis especially condyloma lata. Serological tests for syphilis of two types: Nontreponemal tests (VDRL) which are more sensitive, so used for screening. And treponemal tests (FTA-abs, TPHA) which are more specific, so used to confirm diagnosis.

Treatment: *Early syphilis:* single dose of benzathine penicillin, 2.4 mega units. *Late syphilis:* three doses of benzathine penicillin, 2.4 mega units weekly. *Neurosyphilis:* aqueous benzyl penicillin is used. All given always after skin test dose.

Etiology

Causative agent

Treponema pallidum, a spirochete which is:

- ❖ Corkscrew shaped.
- ❖ Motile with characteristic movements, like **angulation**, bending, rotatory motion, and back and forth squiggle.

Transmission

Transmission of syphilis can be:

- ❖ **Acquired:**
 - *Sexual:* through unprotected sexual contact, this being the predominant method of transmission.
 - *Blood:* through contaminated blood and blood products.
 - *Accidental:* in health care workers, e.g., through needle prick injury.
- ❖ **Congenital:** Vertical transmission occurs *in utero* (transplacentally) or at the time of delivery. Infectivity of mother is higher if she has early stage of syphilis; before the fifth month of gestation, the fetus even if infected escapes severe damage due to its inability to mount an inflammatory response.

Epidemiology

Prevalence:

- The prevalence of syphilis depends on many factors:
 - Sexual promiscuity.
 - Population explosion.
 - Urbanization.

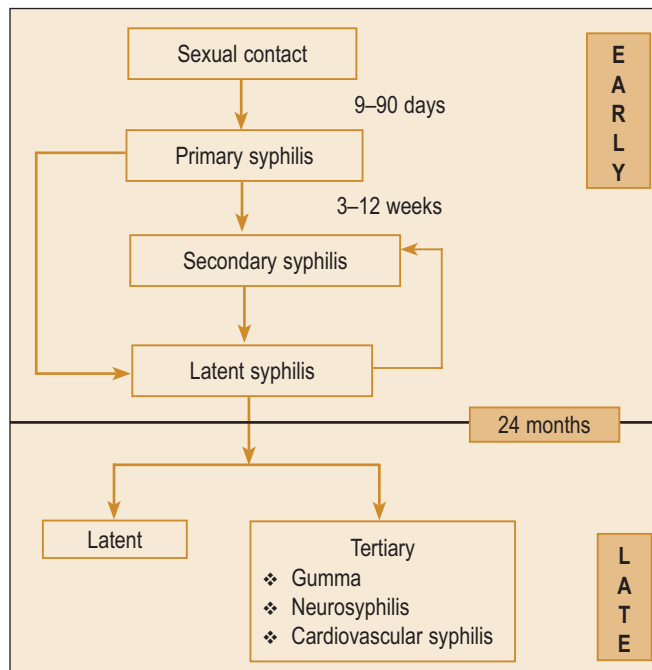


Fig. 15.1. Stages of syphilis: early syphilis is highly infectious while late syphilis is not infectious.

■ HIV pandemic.

- In developing countries, especially in the rural areas, syphilis is still the commonest cause of ulcerative STD. In developed countries, the prevalence of syphilis had waned but resurged with HIV pandemic.
- ❖ **Age:** Affects sexually active age group. Congenital syphilis in newborn.
- ❖ **Gender:** Women are infected more easily than men, but tend to be asymptomatic for primary syphilis and so often first present with secondary syphilis.

Classification

Syphilis can be classified into (Fig. 15.1):

❖ **Early syphilis:**

- Infection <24 months old.
- Lesions teeming with *T. pallidum* and so highly infectious.

❖ **Late syphilis:**

- Infection >24 months old.
- *T. pallidum* sparse and so not infectious.

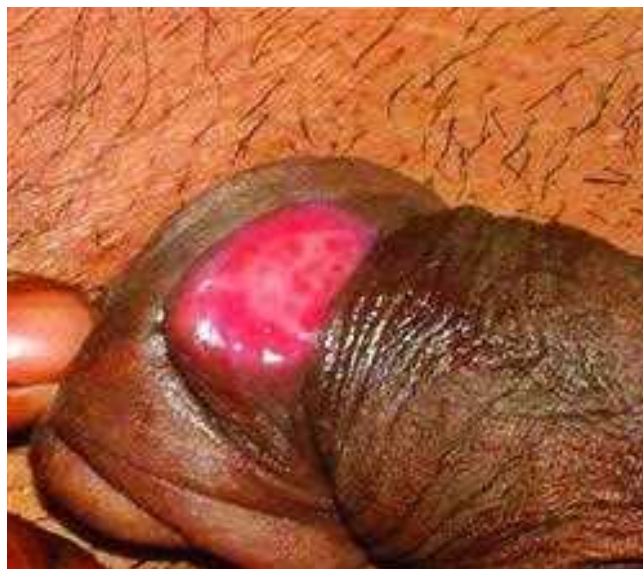

Fig. 15.2. Hunterian chancre: single, clean, painless indurated lesion.

Clinical Features

Incubation period

9–90 days.

Primary syphilis

Morphology

- ❖ In 50% of patients with primary syphilis, the typical lesion is called **Hunterian chancre**² is characterized by:
 - Being single, painless, regular, indurated, (described as button-like) reddish or brownish plaque which frequently ulcerates (Fig. 15.2). The ulcer has a clean floor and oozes clear serum on pressure.
 - Heals spontaneously (4–6 weeks) or on treatment, usually with a slightly atrophic scar.
- ❖ In the rest, the ulcers are atypical (painful, multiple or not indurated).

Location of ulcers

- ❖ **Males:** Coronal sulcus, glans, prepuce, and shaft of penis. Perianal area in homosexual males.
- ❖ **Females:** Labia minora, labia majora, and mons pubis. Sometimes in cervix or vagina, when disease is asymptomatic³.
- ❖ **Extragenital lesions:** Also seen on lips, nipples, and fingers.

2. **Hunterian chancre:** after Hunter, who inoculated himself with genital discharge from a prostitute and developed a syphilitic sore and gonorrhoea.

3. **Asymptomatic:** such women often first present with secondary syphilis.

Lymphadenopathy

- ❖ Inguinal lymphadenopathy.
- ❖ Multiple, small, shotty, firm (like lead shots) lymph nodes.

Secondary syphilis (SS)

SS is a systemic disease with cutaneous as well as extracutaneous manifestations.

Cutaneous lesions

- ❖ Skin lesions of SS may be few or numerous.
- ❖ Lesions are symmetrical initially, becoming asymmetrical later.
- ❖ The rash may have any morphology (macular, papular, papulosquamous, and nodular) but is never vesicular or bullous. The different morphological forms seen are:
 - *Roseolar syphilide*: symmetrical erythematous macular rash, often just perceptible.
 - *Papular syphilide*: most common rash of SS. Dull red papules, initially discrete. Over a period of time may coalesce to form annular lesions (Fig. 15.3A), which may be lichenoid.
 - *Psoriasiform lesions*: when scaling is predominant, the lesions appear psoriasiform.
 - *Malignant syphilide*: pustular, necrotic, and rupioid lesions may be seen in immunocompromised patients.
- ❖ **Palm and sole lesions**: Hyperpigmented, coppery red, scaly lesions. Or hyperkeratotic papules (Fig. 15.3B).
- ❖ **Condyloma lata**: In intertriginous area, the papules may erode superficially (Figs. 15.4A and B). Sometimes at commissures, the papules split (**split papules**; Fig. 15.4C).

Mucosal lesions (Figs. 15.5A and B)

Several types of mucosal lesions seen:

- ❖ **Mucous patches**: Dull erythematous plaques with grayish slough (Fig. 15.5A).
- ❖ **Snail-track ulcers**: Mucous patches with serpiginous erosions.

Lymphadenopathy

- ❖ Generalized, symmetrical, and rubbery lymphadenopathy.
- ❖ Axillary, cervical, and inguinal groups invariably enlarged. Lymph node groups like suboccipital, posterior cervical, and epitrochlear which are normally not enlarged in other diseases may also be enlarged, so a diagnostic clue.

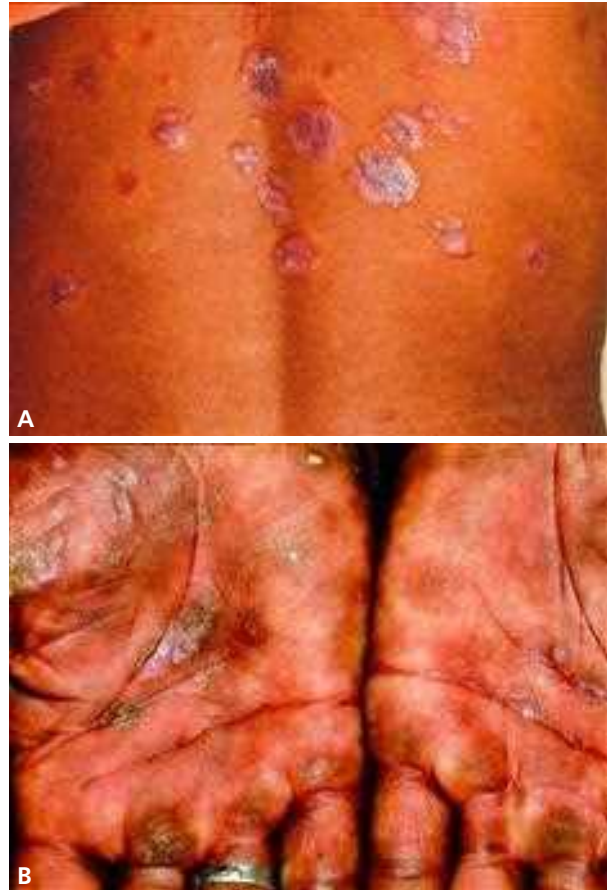

Fig. 15.3. Secondary syphilis: A: papular syphilide, characterized by discrete dull red papules, which coalesce over a period of time to form annular lesions which may be lichenoid or psoriasiform. B: coppery red, scaly papules on palms.

Systemic involvement

SS is a systemic disease with involvement of many organ systems:

- ❖ **Musculoskeletal system**: Periostitis and arthritis.
- ❖ **Ocular**: Iridocyclitis, uveitis, and choroidoretinitis.
- ❖ **Renal**: Nephrotic syndrome due to an immune complex glomerulonephritis.
- ❖ **Central nervous system**: Cerebrospinal fluid abnormalities.

Latent syphilis

Latent syphilis is the stage of syphilis where there is persistent seroreactivity⁴ in the absence of any clinical evidence of syphilis.

4. **Seroreactivity**: presence of antibodies in the serum.

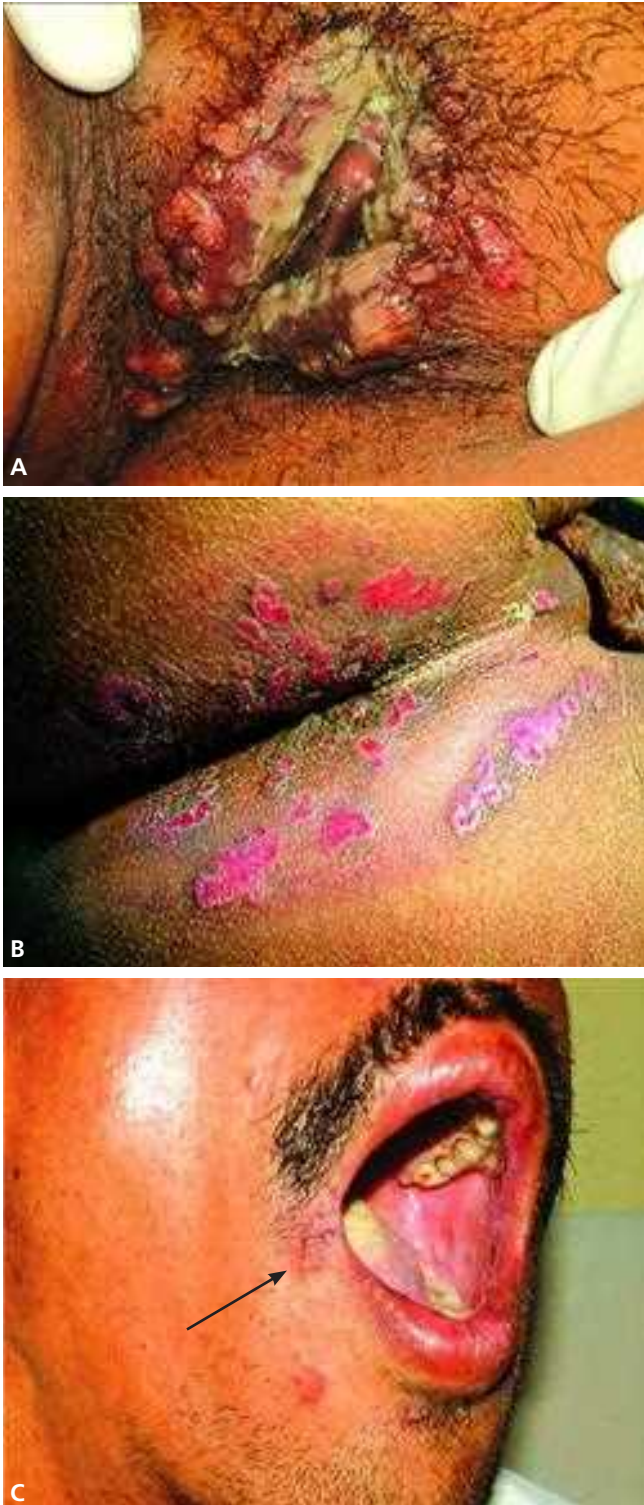

Fig. 15.4. Secondary syphilis: A: condyloma lata present as eroded papules in vulva. B: healing lesions in perianal area. C: split papules at the angle of mouth.

Tertiary syphilis

Several manifestations of tertiary syphilis are recognized (Table 15.3).

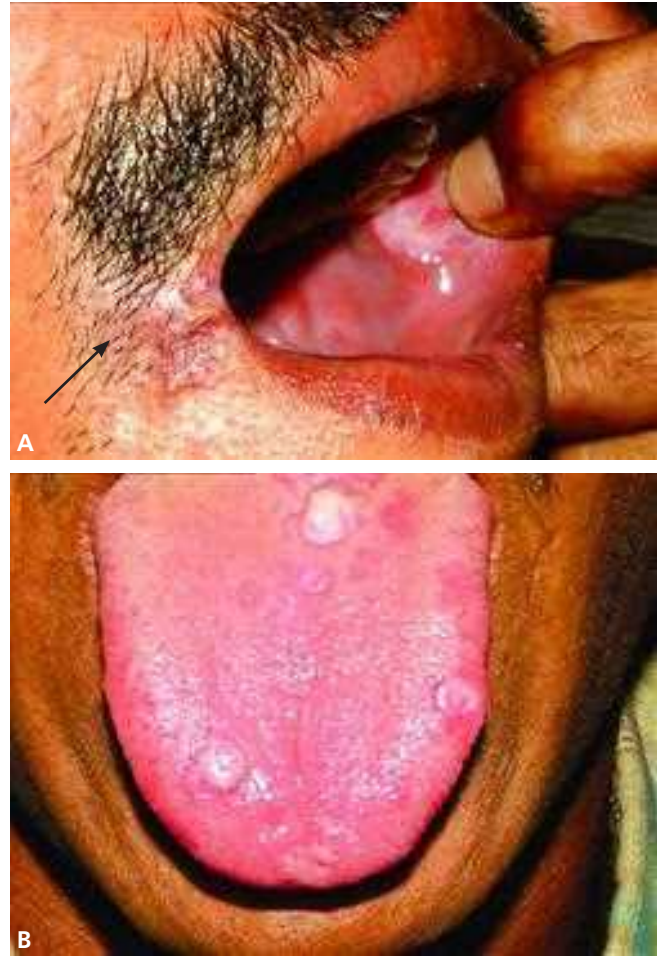

Fig. 15.5. Secondary syphilis: A: mucous patch which appears as an erythematous plaque with grayish slough. Note split papules at angle of the mouth. B: lesions on the tongue.

Table 15.3. Manifestations of tertiary syphilis

<i>Organ systems</i>	<i>Manifestations</i>
Skin	Nodular gummata Noduloulcerative gummata
Mucosae	Gummata
Musculoskeletal system	Gummatous osteitis Periostitis Sclerosing osteitis
Nervous system	Asymptomatic neurosyphilis Meningeal neurosyphilis Meningovascular neurosyphilis Parenchymatous neurosyphilis
Cardiovascular system	Uncomplicated aortitis Aortic insufficiency Aneurysm Coronary stenosis
Liver	Hepatic gummata

Mucocutaneous tertiary syphilis

- ❖ Prototype manifestation of tertiary syphilis in skin is the **gumma**.
- ❖ Gumma is a well-defined, punched out ulcer with wash-leather slough.

Neurosyphilis

- ❖ Asymptomatic.
- ❖ Or manifests as meningeal neurosyphilis or parenchymatous neurosyphilis.

Cardiovascular syphilis

- ❖ Aortitis.
- ❖ May lead to aortic insufficiency, aneurysm, and coronary stenosis.

Congenital syphilis

Syphilitic infection in pregnancy is highly deleterious to the fetus and can result in:

- ❖ Abortion of fetus.
- ❖ Stillbirth.
- ❖ Congenital syphilis.

Congenital syphilis manifests as:

Early congenital syphilis (Fig. 15.6)

This is seen within two years of birth and is highly infectious. Clinically, the child presents with:

- ❖ Low birth weight and anemia.
- ❖ **Cutaneous lesions:**
 - Morphologically, any type of skin lesion, including bullous lesions can occur (*cf.*, acquired syphilis).
 - Fissuring of lips, angles of mouth, and nasolabial folds.
- ❖ **Mucosal lesions:**
 - *Syphilitic rhinitis*: (**snuffles**) produces bloody nasal discharge.
 - *Pharyngitis and laryngitis*: result in a hoarse cry.
- ❖ **Musculoskeletal system:**
 - *Epiphysitis*: commonest musculoskeletal finding of congenital syphilis and manifests as:
 - Extreme pain, swelling, and tenderness of long bones.
 - Limbs are held immobile due to excruciating pain (**pseudoparalysis of Parrot**).
 - *Periostitis*.
 - *Dactylitis*.
- ❖ **Reticuloendothelial system:**
 - Hepatosplenomegaly.
 - Generalized lymphadenopathy.

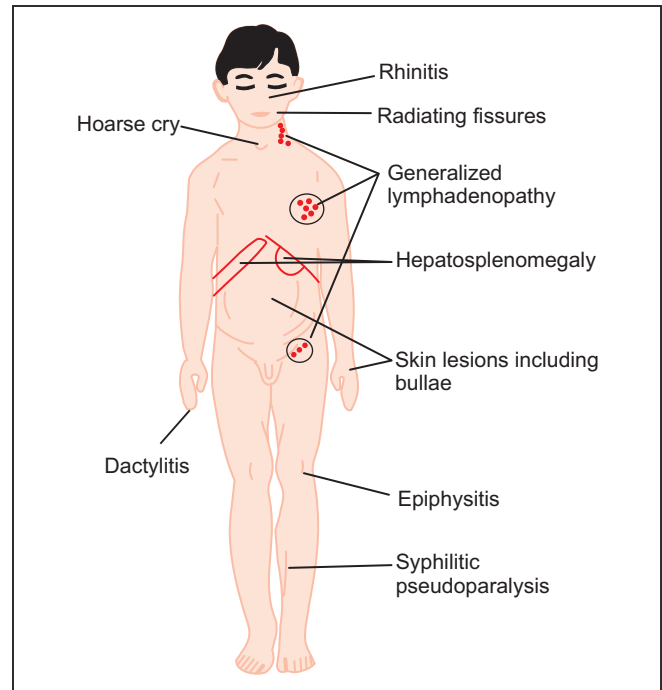


Fig. 15.6. Congenital syphilis: protean manifestations.

- ❖ **Central nervous system.**
- ❖ **Ocular involvement.**

Late congenital syphilis

- ❖ This is similar to late syphilis in adults but cardiovascular system involvement is infrequent.
- ❖ The manifestations can be grouped into:
 - Stigmata of congenital syphilis.
 - Lesions of active disease.

Investigations**Demonstration of *T. pallidum***

Demonstration of *T. pallidum* from lesions is the only absolutely specific diagnostic test for syphilis.

Specimen

- ❖ Serum exuding from lesions of early syphilis (primary and secondary).
- ❖ Caution when examining specimens from oral mucosa, since specimen may be reported falsely positive due to presence of commensal spirochetes.

Methods used

The methods used to demonstrate *T. pallidum* include:

- ❖ **Dark ground (DG) microscopy:** *T. pallidum* appears as a corkscrew-shaped organism

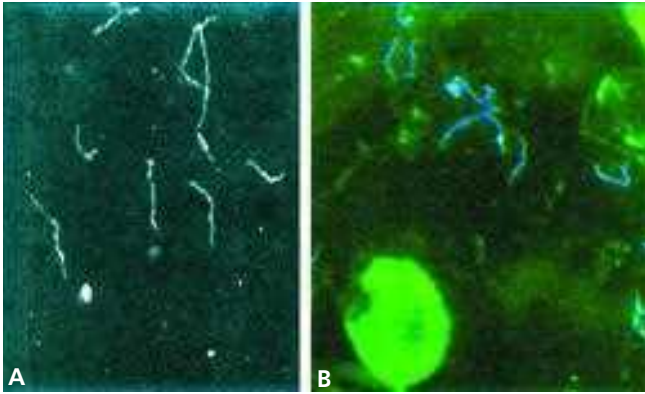


Fig. 15.7. *T. pallidum*: A: under dark field microscope. B: with fluorescent staining.

(Fig. 15.7A) with characteristic movements (especially **angulation**).

- ❖ **Direct fluorescent antibody technique** (Fig. 15.7B).
- ❖ **Polymerase chain reaction (PCR)**: Rapid, specific and sensitive, but expensive and used only as a research tool. Multiplex PCR available to detect concomitant *T. pallidum*, *Haemophilus ducreyi*, and HSV infection.

Serological tests for syphilis (STS)

STS detect antibodies that develop during the course of syphilis and other treponematoses. Two types of tests are available (Table 15.4):

- ❖ **Nontreponemal tests (reaginic tests).**
- ❖ **Treponemal tests.**

Table 15.4 Serological tests for syphilis

Nontreponemal tests	Treponemal tests
<ul style="list-style-type: none"> ❖ Flocculation tests <ul style="list-style-type: none"> ➢ Venereal disease research laboratory (VDRL) ➢ Rapid plasma reagin (RPR) ❖ Complement fixation tests 	<ul style="list-style-type: none"> ❖ <i>Treponema pallidum</i> hemagglutination (TPHA) ❖ Fluorescent treponemal antibody (FTA-Abs) ❖ Reiter treponemal complement fixation (RTCF) ❖ <i>Treponema pallidum</i> immobilization (TPI) test

Nontreponemal tests

These are **good screening tests** because they are sensitive⁵ but since there is a chance of false positives, these tests are **not very specific**⁵

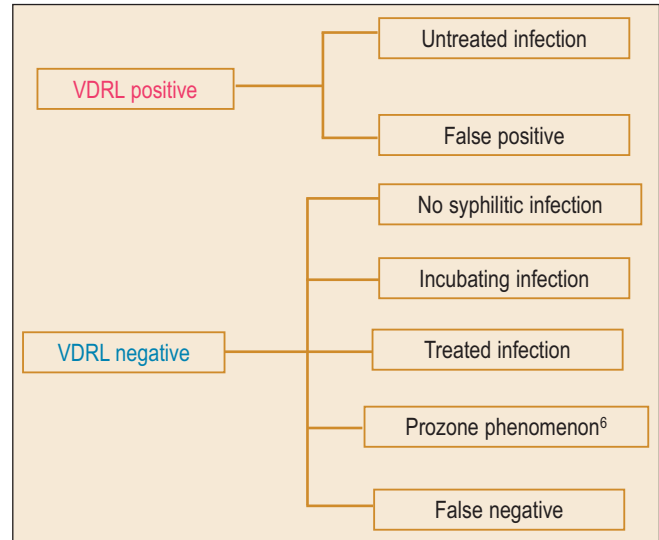


Fig. 15.8. VDRl: interpretation of positive and negative tests.

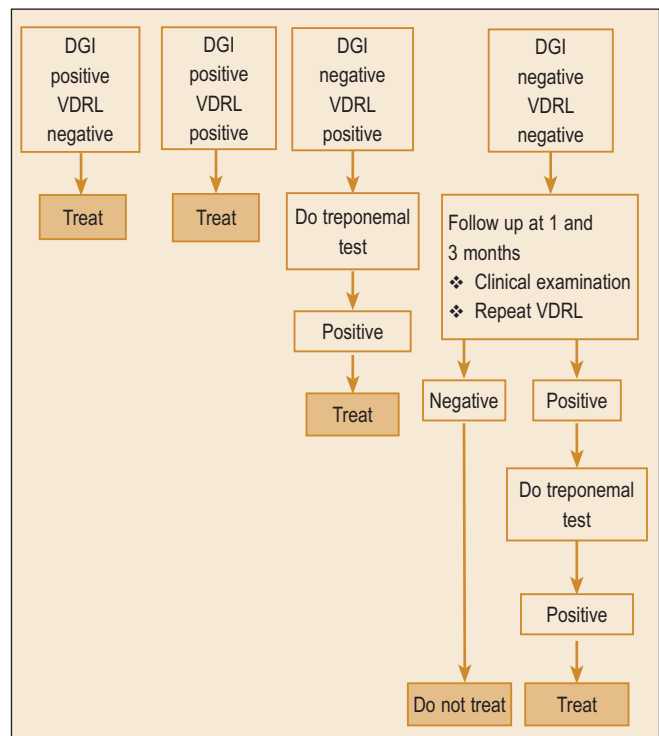


Fig. 15.9. Interpretation of laboratory tests for syphilis in a patient with clinical suspicion of syphilis.

(Figs. 15.8 and 15.9). The two important tests are VDRl and RPR.

5. **Sensitivity:** is ability of test to detect patients who have the disease, *i.e.*, a highly sensitive test detects all patients with the disease and there will be no false negatives (seNsitive test has no false NeGatives). **Specificity:** is ability of test to be negative in persons who do not have the disease, *i.e.*, a highly specific test will not be positive in patients not having the disease and there will be no false positives (sPecific test has no false Positives).

6. **Prozone phenomenon:** when its titer is high, the antibody may not be detected in undiluted serum and the VDRl may be falsely negative. This sometimes happens in secondary syphilis.

Treponemal tests

- ❖ Treponemal tests are **more specific**⁴ than non-treponemal tests.
- ❖ Once these tests become positive, they remain so for lifetime, so are not useful tests for follow up.
- ❖ A number of treponemal tests are available:
 - TPI test which is the most specific but is expensive, cumbersome, not very sensitive⁵ so is no longer used.
 - FTA (Abs).
 - TPHA is most frequently used.

Rule out other STIs

- ❖ Important to rule out other STIs, as these may be concomitantly transmitted.
- ❖ Conventionally, when a patient presents with genital ulcer disease (GUD) the following tests are done on the ulcer.
 - DG microscopy for *T. pallidum* (chancre).
 - Gram stain for *H. ducreyi* (chancroid).
 - Tzanck smear for multinucleated giant cells (herpes genitalis).
 - Tissue smear for bipolar inclusion bodies (donovanosis).
- ❖ An HIV and hepatitis B serology should be done in all patients.

Diagnosis

Primary syphilis

Points for diagnosis

Diagnosis of primary syphilis is based on:

- ❖ History of high-risk sexual behavior.
- ❖ Incubation period of 9–90 days.
- ❖ Single, indurated (button-like), painless, clean ulcer which oozes serum on pressure.
- ❖ Regional lymphadenopathy with discrete and shotty nodes.
- ❖ Demonstration of *T. pallidum* on DG microscopy; VDRL may be positive.

Differential diagnosis

Primary syphilis (chancre) should be differentiated from:

a. Chancroid

Chancroid	Chancre
Incubation period: short (3–5 days)	Longer (9–90 days)
Number: multiple	Single
Pain: present	Painless

Margin: irregular, ragged margin	Regular margin
Induration: not indurated	Button-like induration
On pressure: bleeds	Exudes serum
Lymphadenopathy: bubo	Shotty lymphadenopathy
DG microscopy: negative	Positive
VDRL: negative	+/-

b. Donovanosis (P. 309)

Secondary syphilis (SS)

Points for diagnosis

The diagnosis of SS is based on:

- ❖ Asymptomatic, bilaterally symmetrical (asymmetrical in later stages) rash which may be macular, papular, papulosquamous or nodular. Rash is *never vesicular*.
- ❖ Coppery hyperpigmented, scaly macules or hyperkeratotic papules on palms and soles.
- ❖ Condyloma lata (eroded papules) in perianal and other intertriginous regions.
- ❖ Mucosal lesions.
- ❖ Symmetrical, shotty, lymphadenopathy, typically suboccipital, and epitrochlear.
- ❖ Demonstration of *T. pallidum* from condyloma lata on DG microscopy and a (always!) positive VDRL.

Differential diagnosis

SS should be differentiated from:

a. Drug rash

Drug Rash	SS
Symptoms: itching	Usually asymptomatic except follicular and lichenoid lesions
History of: drug intake	Sexual exposure and a genital ulcer
Morphology: any morphology, including bullous	Never bullous
Mucosal lesions: show diffuse erythema or bullae	Mucous patches/snail track ulcer
Lymphadenopathy: may be present	Characteristically epitrochlear and suboccipital groups enlarged
Palm and sole lesions: similar to main rash	Coppery red, pigmented scaly macules/papules on palms and soles
Condyloma lata: absent	Present
DG microscopy and serology: negative	Positive (serology always so)

b. Pityriasis rosea (PR)

PR	SS
Symptoms: itchy rash	Asymptomatic
Morphology: annular lesions with collarette of scales	Variety of lesions; some types have psoriasiform scales
Typical lesions: herald patch typical	Condyloma lata and palmo-plantar lesions characteristic
Mucosal lesions: absent	Mucous patches and snail track ulcers
DG microscopy and VDRL: negative	Positive

Treatment**Counseling**

- ❖ Very important component of treatment.
- ❖ Advice on safe sex including use of condoms and encouraging single partner relationship.
- ❖ Avoidance of sex till healing of lesions.
- ❖ Partner management.
- ❖ Follow up testing for HIV, hepatitis B virus, and VDRL at 3 months and further if necessary.

The recommended treatment for syphilis is shown in Table 15.5.

Table 15.5. Treatment of different stages of syphilis

Early syphilis
Benzathine penicillin*, 2.4 mega units deep intramuscular (in two equally divided doses, one in each buttock)
<i>In penicillin-sensitive patients</i> Doxycycline, 100 mg twice daily × 14 days (not in pregnant women) or Erythromycin stearate 2 g daily (in four divided doses) × 14 days (in pregnant women)
Late syphilis
<i>Benign late syphilis and cardiovascular syphilis</i>
Benzathine penicillin*, 2.4 mega units intramuscular (<i>vide supra</i>) weekly, for three consecutive weeks
<i>In penicillin-sensitive patients</i> Doxycycline, 100 mg twice daily × 28 days (not in pregnant women) or Erythromycin stearate, 2 g daily × 28 days (in pregnant women). Some recommend penicillin desensitization
<i>Neurosyphilis</i>
Crystalline penicillin* 3–4 million units, four-hourly intravenous × 14 days
Congenital syphilis
Procaine penicillin*, 50,000 units/kg intramuscular, daily × 14 days.

*Always after testing for sensitivity.

Chancroid**Synopsis**

Etiology: *Haemophilus ducreyi*.

Incubation period: 3–5 days.

Morphology: Multiple, tender, ragged ulcers which bleed on manipulation.

Lymphadenopathy: Tender, inflammatory inguinal nodes (buboes) which may suppurate to form chancroid-like ulcers.

Investigations: Diagnosis based on clinical features as laboratory tests neither specific nor sensitive.

Treatment: Azithromycin, 1 g single dose. Or ceftriaxone, 250 mg intramuscular, single dose. Or ciprofloxacin, 1 g daily × 3 days; erythromycin base, 1.5 g daily × 7 days. Aspiration or incision and drainage (nondependent) of fluctuant buboes.

Etiology

- ❖ *Haemophilus ducreyi*, a Gram-negative bacillus.

Clinical Features**Incubation period**

3–5 days.

Morphology

- ❖ Multiple, superficial, tender, nonindurated ulcers (hence called **soft sore**).
- ❖ Undermined, friable ragged edge with an erythematous halo.
- ❖ Floor is covered with an exudate which on removal reveals a bleeding surface (Fig. 15.10).

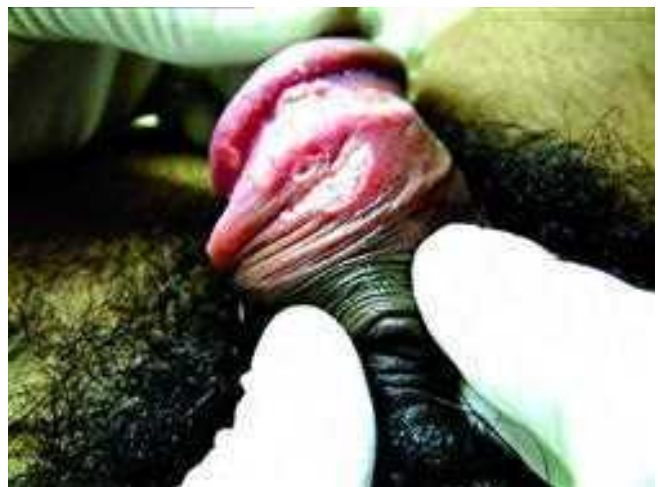

Fig. 15.10. Chancroid: multiple, dirty looking, tender ulcers.

Location of ulcers

- ❖ **Males:** Prepuce, frenulum, and coronal sulcus.
- ❖ **Females:** Fourchette, vestibule, and labia minora.

Lymphadenopathy

- ❖ In 50% of the patients, inguinal **bubo**⁷, usually unilateral, follows within a few days.
- ❖ Bubo may rupture to form chancroid-like ulcer at the mouth of the sinus.

Variants

Variants of chancroid include:

- ❖ **Dwarf:** Pinpoint lesions which may resemble Herpes genitalis.
- ❖ **Giant:** Large, usually single ulcer.
- ❖ **Phagedenic:** Necrotic ulcer due to secondary infection with **Vincent's fusospirochetes**.

Complications

Chancroid may be complicated by:

- ❖ **Bubo formation:** In the inguinal region, in 50% of patients.
- ❖ **Phimosis.**
- ❖ **Secondary infection:** Secondary infection with Vincent's fusospirochetes results in **phagedenic ulcer**, which may cause destruction of genitalia.

Investigations

Isolation of *H. ducreyi*

- ❖ **Smear:** Identified by:
 - *Gram staining:* is not very sensitive. May reveal Gram-negative bacilli in a **school of fish formation (or rail track appearance)**.
 - *Immunofluorescence technique:* not used routinely.
- ❖ **Culture:** Fastidious and difficult to culture.
- ❖ **Polymerase chain reaction (PCR):** Rapid, specific and sensitive but expensive and used only as a research tool. Multiplex PCR available to detect concomitant *T. pallidum*, and HSV infection.

Histopathological examination

Biopsy is not usually done, but may help in diagnosis.

Rule out other STIs

Important to rule out other STIs, as these may be concomitantly transmitted:

- ❖ Rule out other causes of GUD (*vide supra*, P. 306).
- ❖ An HIV and hepatitis B serology and VDRL should be done in all patients and patients appropriately managed. If negative, should be repeated after 3 months.

Diagnosis

Points for diagnosis

Diagnosis of chancroid is based on:

- ❖ History of high-risk sexual behavior.
- ❖ Short incubation period (3–5 days).
- ❖ Multiple, nonindurated, tender ulcers with ragged and undermined edges; ulcers bleed on touch.
- ❖ Inflammatory unilateral inguinal swelling, which may suppurate to form chancroidal ulcers.

Differential diagnosis

Ulcer of chancroid

- ❖ Should be differentiated from:
 - Primary syphilis* (chancre; P. 306).
 - Donovanosis* (P. 310).
 - Herpes genitalis* (P. 314).

Bubo of chancroid

- ❖ Should be differentiated from:
 - Bubo of *lymphogranuloma venereum* (P. 311).

Treatment

Counseling and education

Vide supra (P. 307)

Local treatment

- ❖ Local hygiene.
- ❖ Phimosis should be treated with a dorsal slit.
- ❖ Fluctuant bubo should be aspirated using a broad gauge needle, through a nondependent area. Though earlier incision and drainage was not recommended, it is now been recommended that it may be done in a nondependent area.

Systemic therapy

- ❖ **Antibiotics:**
 - Azithromycin, 1 g single oral dose.
 - Ceftriaxone, 250 mg intramuscular, single dose.
 - Ciprofloxacin, 1 g daily × 3 days.
 - Erythromycin base, 1.5 g daily × 7 days.

7. **Bubo:** inflammatory lymph node swelling, which may suppurate.

- ❖ **Anti-inflammatory drugs:** Like ibuprofen and paracetamol, for bubo and to relieve pain of genital ulcers.

Donovanosis

Synonyms: Granuloma venereum, granuloma inguinale

Synopsis

Etiology: *Klebsiella granulomatis*.

Morphology: Single or few, asymptomatic ulcers with an elevated, serpiginous edge, and beefy red floor. Subcutaneous nodules (pseudobuboes) in inguinal region may ulcerate. No lymphadenopathy.

Sites: Genital and perianal areas.

Complications: Large deforming lesions; malignant transformation.

Investigations: Tissue smear and histopathology show organisms as bipolar intracellular inclusions.

Treatment: Doxycycline (200 mg daily) or azithromycin (1 g once a week) for 3 weeks.

Etiology

Klebsiella (earlier known as *Calymmatobacterium*) *granulomatis*, a bacteria.

Clinical Features

Morphology

- ❖ Single (sometimes multiple), asymptomatic ulcer(s).
- ❖ Floor is made of beefy, exuberant granulation tissue which bleeds easily on manipulation (Fig. 15.11).
- ❖ Border is elevated and has a serpiginous outline.

Location of ulcers

- ❖ **Males:** Glans, prepuce, shaft of penis, perianal area, and penoscrotal junction.

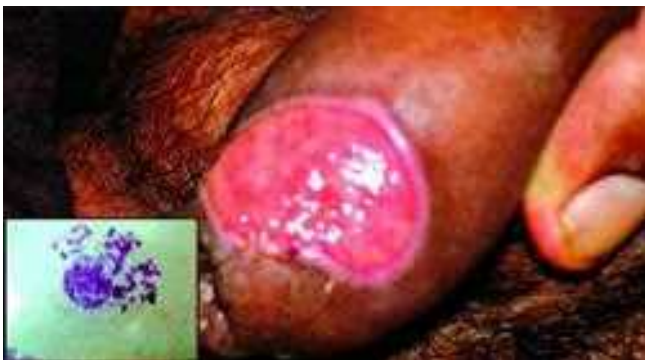

Fig. 15.11. Donovanosis: beefy red ulcer with exuberant granulation tissue in the floor. Inset: tissue smear showing intracellular bipolar inclusions.

- ❖ **Females:** Labia majora, mons veneris, and perianal area.

Lymphadenopathy

Not seen. Sometimes subcutaneous swellings appear in the inguinal region (**pseudobuboes**) and these may ulcerate to form typical ulcers of donovanosis.

Complications

- ❖ Giant ulcers.
- ❖ Destruction and deformity of genitalia.
- ❖ Rarely, malignant transformation.

Investigations

Tissue smear

- ❖ Made from a piece of crushed ulcer tissue.
- ❖ Stained with Giemsa or Leishman's stain.
- ❖ Organisms appear as intracellular (in macrophages) bipolar inclusions (**safety pin or telephone handle appearance**; Fig. 15.11 inset).

Biopsy

Needs to be done in two circumstances:

- ❖ When in a clinically strongly suspicious case, tissue smears are repeatedly negative.
- ❖ To rule out malignancy.

Diagnosis

Points for diagnosis

Diagnosis of donovanosis is based on:

- ❖ Presence of lesions in genital or perianal region.
- ❖ Exuberant ulcer with beefy red floor with a raised serpiginous margin.
- ❖ Absence of lymphadenopathy, though pseudobubo may be present in inguinal region.
- ❖ Tissue smear shows bipolar inclusions.

Differential diagnosis

Donovanosis should be differentiated from:

a. Chancre

Chancre	Donovanosis
Base: indurated	Firm
Floor: clean floor	Beefy red floor of granulation tissue
On pressure: oozes serum	Bleeds on manipulation
Edge: well-defined	Elevated and serpiginous
Lymphadenopathy: shotty	No lymphadenopathy

b. Chancroid

Chancroid	Donovanosis
Symptoms: painful	Asymptomatic
Number: multiple lesions	Single–few lesions
Base: soft	Firm
Floor: dirty looking, which bleeds on touch	Beefy red floor, which bleeds on touch
Lymphadenopathy: bubo.	No lymphadenopathy

Treatment**Counseling and education**

Vide supra (P. 307)

Specific treatment

- ❖ Doxycycline, 200 mg daily for 3 weeks.
 - ❖ Azithromycin, 1 g once a week for 3 weeks.
 - ❖ Erythromycin base, 2 g daily for 3 weeks.
- All drugs, often given till ulcers have healed.

Lymphogranuloma Venereum (LGV)**Synopsis**

Etiology: *Chlamydia trachomatis* serovars L1, L2, and L3.

Clinical features: Genital lesion not noticed. Presenting feature is enlargement of inguinal, femoral, and sometimes external iliac group of lymph nodes. Sign of groove characteristic.

Complications: Esthiomene.

Treatment: Doxycycline (200 mg) or erythromycin base (2 g) daily for 21 days. Aspiration of buboes.

Etiology

- ❖ One of the three serovars of *C. trachomatis* (L1, L2, or L3).
- ❖ Transmitted sexually.

Clinical Features**Incubation period**

3–12 days.

Morphology of lesions

Three stages of the disease are recognized:

- ❖ Primary stage.
- ❖ Inguinal syndrome.
- ❖ Genito-anorectal syndrome.

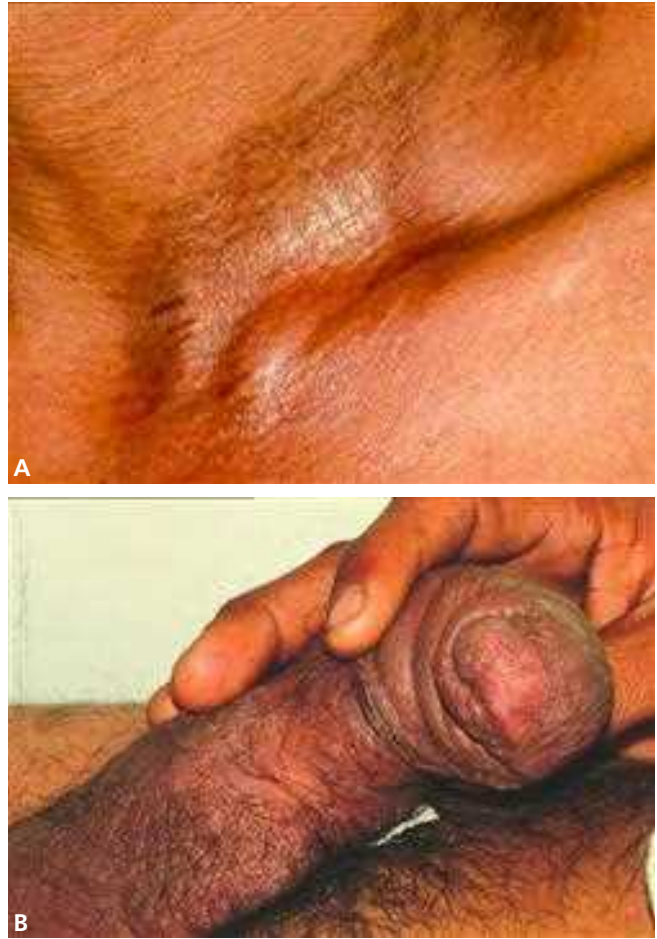


Fig. 15.12. Lymphogranuloma venereum: A: inflammatory swelling of inguinal lymph nodes and femoral lymph nodes both separated by inguinal ligament (sign of groove). B: lymphedema as a sequelae.

Primary stage

- ❖ An asymptomatic evanescent, herpetiform, or papular lesion.
- ❖ Usually not even noticed.

Inguinal syndrome

- ❖ Constitutional symptoms are present.
- ❖ Inflammatory swelling (**bubo**) of inguinal lymph nodes (Fig. 15.12) and sometimes femoral lymph nodes. When both the inguinal and femoral groups of lymph nodes are enlarged, they are separated by the inguinal ligament (**sign of groove**).
- ❖ Nodes suppurate at many sites giving rise to multiple sinuses with undermined edge (*cf.*, bubo of chancroid).
- ❖ External iliac nodes⁸, often enlarged.

8. **External iliac nodes:** to be palpated in iliac fossa.

Genito-anorectal syndrome

- ❖ Consists of hyperplastic and ulcerative changes on the genitalia, frequently associated with anorectal change.
- ❖ Manifestations are more frequent in women, with typical manifestation being **esthiomene**⁹.

Investigations

- ❖ **Demonstration of causative agent:** Genital, lymph node or rectal specimens (*i.e.*, lesion swab, bubo aspirate, and rectal swab respectively).
 - **Direct smear:** to identify **elementary and inclusion bodies** is not sensitive because of concomitant bacterial infection.
 - **Culture:** on cell lines (McCoy and Hela).
 - **Direct immunofluorescence.**
 - **Nucleic acid amplification tests.**
- ❖ **Serology:**
 - **Complement fixation test:** detection of antibodies in increasing dilutions (>1:64) is highly suggestive of LGV. A titer of >1:256 probably diagnostic.
 - **Microimmunofluorescence test:** more specific but not readily available.
- ❖ **Biopsy:** Of bubo may help.
- ❖ **Nonspecific tests:**
 - **Frei test:** obsolete intradermal test.
 - **Hypergammaglobulinemia:** resulting in increased total serum proteins.
- ❖ Always rule out concomitant STIs.

Diagnosis

Points for diagnosis

The diagnosis of LGV is based on:

- ❖ Presence of high-risk sexual behavior.
- ❖ Presence of transient genital lesion (often not even noticed).
- ❖ Presence of inflammatory inguinal adenitis, which may suppurate to form multiple sinuses.
- ❖ **Sign of groove:** Due to simultaneous enlargement of inguinal and femoral lymph nodes separated by inguinal ligament.
- ❖ Presence of constitutional symptoms.

Differential diagnosis

The bubo of LGV should be differentiated from that of:

a. Chancroid

Chancroid	LGV
Genital ulcer: present	Transient or absent
Number of groups: usually single group enlarged	Multiple groups of lymph nodes enlarged; enlargement of inguinal and femoral groups results in sign of groove
Sinus mouth: ruptures to form chancroidal ulcer at the mouth	Ruptures to form multiple sinuses with undermined edge
Constitutional symptoms: occasional	Frequent

Treatment

Counseling and education

Vide supra (P. 307)

Medical treatment

- ❖ Doxycycline, 200 mg daily for 21 days.
- ❖ Erythromycin, 2 g daily for 21 days.

Treatment of inguinal syndrome

- ❖ Hot fomentation and nonsteroidal antiinflammatory drugs to relieve pain.
- ❖ Fluctuant buboes should be aspirated using a wide-bore needle through normal, nondependent skin.

Treatment of complications

Genito-anorectal syndrome needs to be appropriately treated.

Herpes Genitalis (HG)

Synopsis

Etiology: *Herpes simplex virus* type II (less frequently HSV type I). Recurrent lesions.

Classification: First episode and recurrent.

Clinical features: Primary or first episode infection more severe, lasts longer. Lesions consist of grouped vesicular lesions on an erythematous base. Rupture to form polycyclic erosions.

Investigations: Multinucleated giant cells on Tzanck smear. Culture confirmatory.

Treatment: Symptomatic. Long-term suppressive acyclovir, given if six or more episodes/year.

Etiology

- ❖ *Herpes simplex virus (HSV)*. More than 90% of cases due to HSV type 2; the other 10% due to HSV type 1.

9. **Esthiomene:** occurrence together of elephantiasis and chronic ulceration of the vulva. A similar combination of elephantiasis and ulceration may occur in males, but since the problem is far more frequent in females, the term esthiomene is often restricted to the complication when it occurs in females.

- ❖ The primary disease is spread by sexual route. Following initial infection, the virus becomes dormant in dorsal nerve ganglia. Recurrences, a manifestation of reactivation of the virus; more frequent with HSV 2.
- ❖ Asymptomatic shedding important in transmission.

Epidemiology

- ❖ **Prevalence:** Commonest cause of genital ulcer disease in most areas.
- ❖ **Gender:** Males > females. Women usually asymptomatic, as infection in cervix.
- ❖ **Age:** Disease of sexually active.

Clinical Features

Manifestation of HG depends on whether the disease is:

- ❖ First episode HG.
- ❖ Recurrent HG.

First episode HG

Can either be:

- ❖ **Primary first episode HG:** Primary HSV genital infection in a patient with no previous exposure to HSV.
- ❖ **Post primary first episode HG:** First episode HSV genital infection in a patient who has already been exposed to another type of HSV (symptomatic or asymptomatic).

Constitutional symptoms

Fever and headache are prominent.

Morphology

- ❖ Painful, closely grouped, small vesicles, giving appearance of a white plaque (Fig. 15.13A), surrounded by a narrow zone of erythema. Vesicles soon rupture to form multiple superficial erosions/ulcers (Fig. 15.13B). Coalesce into polycyclic erosions.
- ❖ Bilateral noninflammatory lymphadenopathy.

Sites

- ❖ **Males:** Glans, prepuce, and coronal sulcus.
- ❖ **Females:** Labia. Many women have lesions in the cervix and such patients may just complain of vaginal discharge or may be asymptomatic.

Complications

- ❖ Secondary infection.
- ❖ Urinary retention.

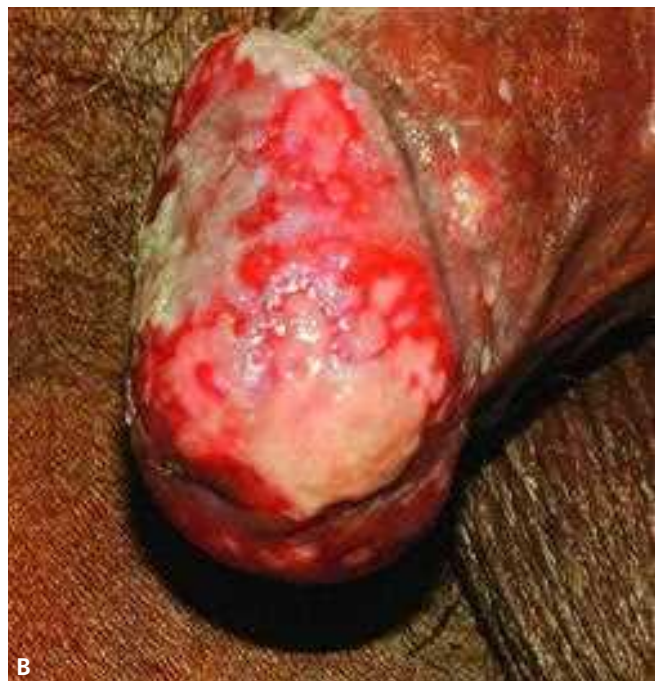
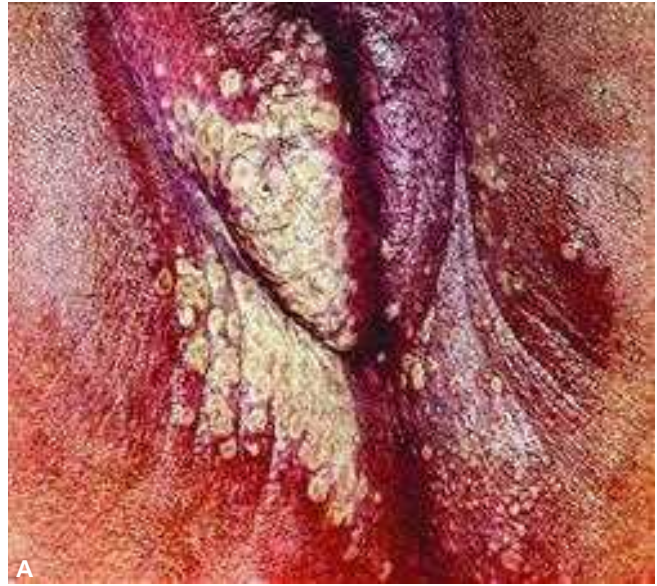
Fig. 15.13. Herpes genitalis: primary episode. A: vesicles, closely grouped together to give appearance of a white plaque. B: polycyclic ulcers on erythematous background on glans.

Recurrent HG

Due to reactivation of the dormant HSV.

Morphology

- ❖ Prodrome of burning sensation.
- ❖ Followed by eruption of small, grouped vesicles on an erythematous base (Fig. 15.14A).
- ❖ Vesicles rupture to form superficial polycyclic erosions (Fig. 15.14B), which heal without scarring.

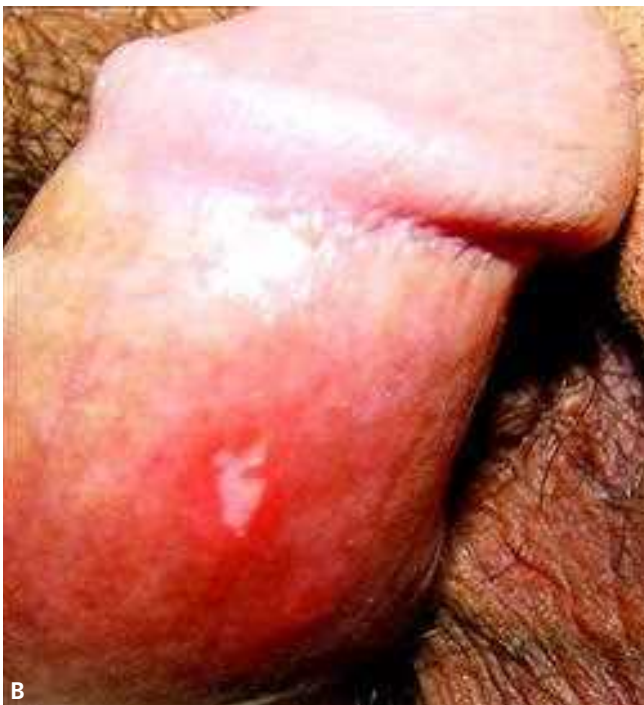
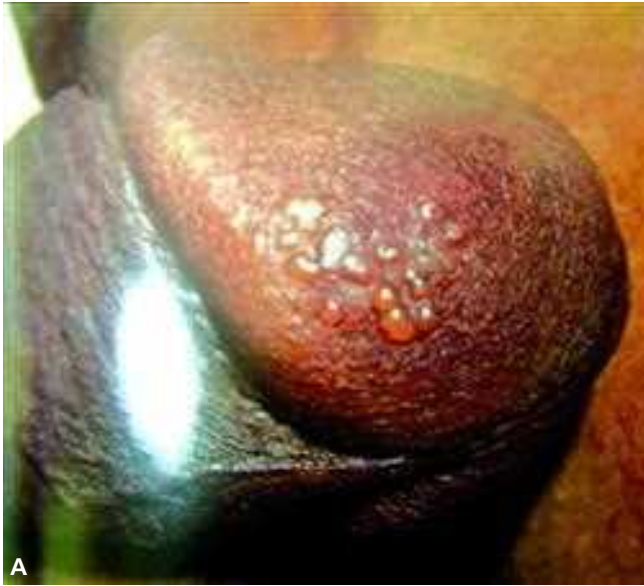
Fig. 15.14. Herpes genitalis: recurrent episode: A: grouped vesicles. B: rupture to form a polycyclic erosion.

- ❖ Lesions are more localized, less severe, and less painful than in the first episode infection.

Complications

Secondary infection.

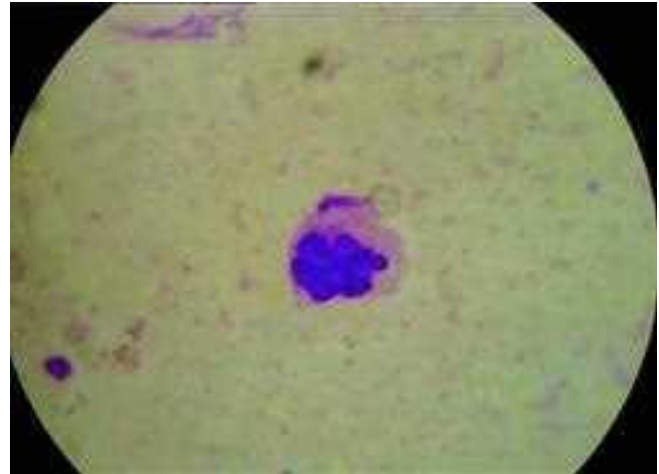


Fig. 15.15. Herpes genitalis: multinucleated giant cells in Tzanck smear

Course

- ❖ Recurrences more common with HSV 2 than HSV 1.
- ❖ With time, recurrences become less frequent and milder.

Investigations

Identification of virus

- ❖ **Tzanck smear:** Presence of multinucleated giant cells (Fig. 15.15). Low sensitivity.
- ❖ **Culture:** Isolation of HSV on tissue culture¹⁰. Low sensitivity (especially in recurrent lesions).
- ❖ **Fluorescent antibody test:** Identification of virus from lesions using fluorescent antibody staining.
- ❖ **PCR:** Rapid, specific, and sensitive but expensive and used only as a research tool. Multiplex PCR available to detect concomitant *T. pallidum*, *H. ducreyi*, and HSV infection.

Serology

- ❖ Serological screening for IgM antibodies is useful but presence of elevated levels of IgG antibodies does not differentiate between present and past infection.
- ❖ Recent **point of care tests**¹¹ based on glycoprotein G have high sensitivity and specificity.

10. **Tissue culture:** based on cytopathic effect. Typing done using antibodies. May be important to find type, as recurrences more frequent with type 2.

11. **Point of care tests (POCT):** are tests done at or near the site of patient care, increasing likelihood that patient will get test done and care team will receive the results quicker, allowing for immediate clinical management decisions to be taken.

Diagnosis

Points for diagnosis

Diagnosis of HG is based on:

- ❖ History of high-risk, unprotected sexual exposure.
- ❖ Recurrent episodes of lesions in the same area.
- ❖ Lesions consisting of grouped vesicles, which rupture to form polycyclic erosions with an erythematous halo.
- ❖ Presence of multinucleated giant cells in the Tzanck smear and identification of virus (tissue culture, PCR, and fluorescent antibody staining).

Differential diagnosis

HG should be differentiated from:

a. Chancroid (dwarf variant)

Dwarf chancroid	HG
<i>History:</i> no history of vesiculation but of tiny pustules	Grouped vesicles which rupture to form polycyclic erosions
<i>Lymphadenopathy:</i> inflammatory bubo which ruptures	Lymph nodes enlarged. Do not rupture

b. Fixed drug eruption (FDE)

FDE	HG
<i>History:</i> of preceding drug intake	Of unprotected sexual exposure
<i>Morphology:</i> active lesion is a well-defined erythematous plaque. Quiescent lesion is a circumscribed hyperpigmented macule	Acute lesions are grouped vesicles, which rupture to form superficial erosions
<i>Course:</i> activation on drug intake; subside with hyperpigmentation	Acute episodes, heal with no sequelae

Treatment

Counseling and education

- ❖ Very important component of treatment.
- ❖ Advice on safe sex including use of condoms and encouraging single partner relationship.
- ❖ Avoidance of sex till healing of lesions. Asymptomatic shedding of HSV also important
- ❖ Partner management.
- ❖ Follow up testing for HIV, hepatitis B virus and VDRL at three months and further if necessary.

Medical treatment

The aim of antiviral drugs is to hasten recovery and to prevent/reduce the number of recurrences.

Drugs available

- ❖ **Acyclovir:** most frequently used antiviral agent. Is available as:
 - *Topical preparation:* provides only minimal clinical benefit; marginally reduces viral shedding but does not prevent recurrences, **so not recommended.**
 - *Tablets:* acyclovir reduces viral shedding and hastens healing.
 - *Injectable preparation:* used in systemic disease and disseminated skin disease.
- ❖ **Famciclovir:** Better bioavailability than acyclovir.
- ❖ **Valacyclovir:** Better bioavailability than acyclovir.
- ❖ **Foscarnet:** Used in acyclovir-resistant HSV, as seen in HIV infection.

Treatment protocols (Table 15.6)

Table 15.6 Treatment protocol for herpes genitalis

1 st episode
Acyclovir, 400 mg, three times/day × 7 days Famciclovir, 250 mg, three times/day × 7 days Valacyclovir, 1 g, two times/day × 7 days
Recurrent episodes
<ul style="list-style-type: none"> ❖ Episodic treatment: initiated by patient himself in prodrome. Given for 5 days. <ul style="list-style-type: none"> ➢ Acyclovir, 200 mg, five times/day ➢ Famciclovir: 125–250 mg twice daily ❖ Suppressive treatment¹²: if >6 episodes/year, given for 12 months or longer <ul style="list-style-type: none"> ➢ Acyclovir: 400 mg twice daily ➢ Famciclovir: 125–250 mg twice daily
Immunosuppressed patients
Suppressive treatment

HG in pregnancy

- ❖ Transmission to newborn is more with HSV1 than HSV2.
- ❖ Women with recurrent HG offered suppressive therapy at and beyond 36 weeks of gestation.
- ❖ Cesarean section indicated only in women with active infection/prodrome at delivery and not for every woman with history of HG.
- ❖ Routine HSV serology and cultures not required.

12. **Suppressive treatment:** reduces recurrences and asymptomatic shedding.

Gonococcal Infection

Synopsis

Etiology: *Neisseria gonorrhoeae*, transmitted sexually; sometimes vertically (from mother to child) causing ocular infection in neonates.

Incubation period: 1–5 days.

Males: Urethritis manifesting as profuse urethral discharge and dysuria.

Females: Usually asymptomatic carriers; may have vaginal discharge.

Complications: Include infection of adjoining structures and glands. And late complications like urethral stricture (males) and pelvic inflammatory disease and infertility (females).

Diagnosis: Clinical suspicion confirmed in males by demonstration of Gram-negative intracellular diplococci on Gram stain. And in females by culturing the organism.

Treatment: Uncomplicated gonococcal infection: single oral dose of cefixime (400 mg) **or** ciprofloxacin (500 mg) **or** intramuscular ceftriaxone (125 mg); complicated infections need longer treatment.

Etiology

Causative agent

Neisseria gonorrhoeae (*N. gonorrhoeae*).

Transmission

- ❖ **Sexual transmission:** Most frequent method; male to female transmission more efficient than female to male transmission.
- ❖ **Vertical transmission:** From an infected mother to the newborn; results in ocular infection.

Pathogenesis

Infects columnar cells while stratified squamous epithelium and transitional cells usually escape infection. So, the following sites infected:

- ❖ **In males:** Urethra, Littre's and Cowper's glands, prostate, seminal vesicles, and epididymis.
- ❖ **In females:** Urethra, Bartholin's and Skene's glands, cervix, and fallopian tubes.
- ❖ **Extragenital sites:** Rectum and pharynx.

Epidemiology

- ❖ **Developed countries:**
 - An overall decreased prevalence in heterosexual men and women, but younger women more frequently infected.
 - An increased prevalence in homosexuals.
- ❖ **Developing countries:**

- **Africa:** incidence of 10% annually.
- **Asia:** gonococcus is the commonest cause of male urethritis and 30% of commercial sex workers may be harboring *N. gonorrhoeae*.

Clinical Features

Incubation period

1–5 days.

Manifestations

Clinically, gonorrhea manifests as:

- ❖ Asymptomatic infection.
- ❖ Symptomatic infection in males.
- ❖ Symptomatic infection in females.
- ❖ Metastatic infection.

Asymptomatic infection

- ❖ Rectal and pharyngeal infections are frequently asymptomatic.
- ❖ Endocervical infection is often asymptomatic.
- ❖ Urethral infection may occasionally be asymptomatic.

Symptomatic infection in males

- ❖ The most common manifestation is **anterior urethritis** which manifests as:
 - Painful micturition.
 - Urethral discharge which is purulent, profuse, thick, and creamy (Fig. 15.16).
 - Redness and edema of urethral meatus.
- ❖ The infection may spread to posterior urethra.
- ❖ **Complications (Table 15.7)**

Table 15.7. Complications of *N. gonorrhoeae* and *C. trachomatis* infections

	Males	Females
Acute		
Infection of adjoining glands	Tysonitis Litteritis	Bartholinitis Skenitis
Infection of adjoining tissues	Periurethral abscess Median raphe infection Proctitis	Proctitis Pelvic inflammatory disease
Ascending infection	Prostatitis Cystitis Epididymitis	Salpingitis Cystitis
Metastatic infection	Skin, joints, liver, heart, and bones	
Chronic		
	Stricture Infertility	Tubal factor infertility Ectopic pregnancy

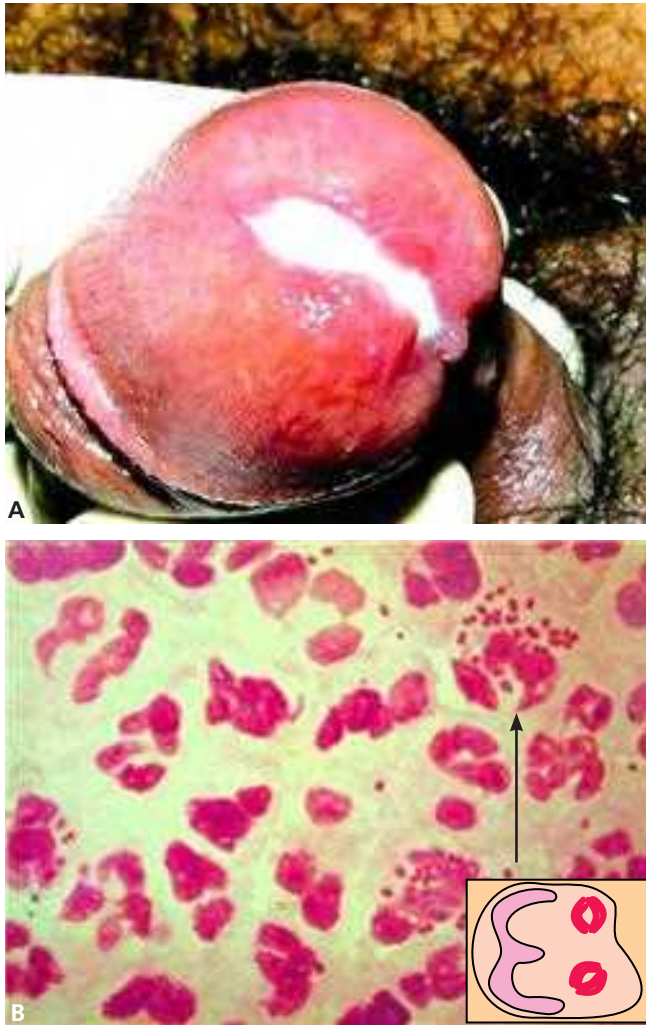

Fig. 15.16. Gonococcal urethritis: A: thick creamy discharge. B: Gram stain of urethral discharge showing Gram-negative intracellular and extracellular diplococci. Inset: polymorph with ICDC.

Symptomatic infection in females

- ❖ Primary site of infection is the endocervical canal and concomitant urethral infection is seen in about 75% of patients.
- ❖ Genital gonococcal infection in females is often asymptomatic.
- ❖ When symptomatic, female patients present with:
 - Genital discharge which may be scanty or profuse.
 - Dysuria and frequency and urgency of micturition.

Metastatic infections

Disseminated gonococcal infection (DGI) manifests in skin, joints, liver, heart, and bones.

Investigations

Smear examination

Specimens used

Urethral and endocervical discharge, pharyngeal and rectal swabs.

What is seen? (Fig. 15.16B)

On Gram-stained slides, in gonococcal infection, the following are seen:

- ❖ Polymorphs.
- ❖ Gram-negative kidney-shaped extracellular and intracellular diplococci (ICDC).

Interpretation

- ❖ **In males:** Smears are very sensitive for diagnosis of gonococcal urethritis (very few false negatives).
- ❖ **In females:** Smear is negative for ICDC in a third of infected patients, so culture needs to be done.

Culture

Media used

Two types of media are used.

- ❖ **Nonselective media:** Chocolate agar.
- ❖ **Selective media:** Modified Thayer-Martin medium and Chacko-Nair medium.

Interpretation

- ❖ **Males:** Culture is not necessary because of the high sensitivity of Gram-stained urethral smear. In pharyngeal and rectal gonococcal infection, however, culture is necessary for diagnosis.
- ❖ **Females:** Gram-stained endocervical smears may be negative in third of the infected cases, so culture of endocervical discharge is necessary.

Diagnosis

Points for diagnosis

The diagnosis of gonococcal genital infection is based on:

- ❖ Short incubation period of 1–5 days.
- ❖ Profuse, thick creamy discharge.
- ❖ Demonstration of ICDC (in the polymorphs) on Gram stain.
- ❖ Culture necessary in women.

Differential diagnosis

Gonococcal urethritis should be differentiated from:

a. Chlamydial urethritis

Chlamydial urethritis	Gonococcal urethritis
Incubation period: longer	1–5 days
Discharge: mucoid ¹³	Profuse, creamy
Gram stain: only polymorphs in urethral smear	Polys and Gram-negative ICDC

Treatment

General measures

- ❖ Sexual abstinence.
- ❖ Treatment of sexual partners.
- ❖ Avoidance of heavy work.
- ❖ Avoidance of alcohol intake.

Specific treatment

Specific treatment for uncomplicated and complicated gonococcal infection is shown in Table 15.8.

Table 15.8. Treatment schedule for gonococcal infections

Uncomplicated infection	Cefixime, 400 mg SOD ¹⁴ or Ceftriaxone, 125 mg IM, single dose or Ciprofloxacin 500 mg SOD ¹⁴
Complicated infection	Ceftriaxone, 1 g IM od × 7 days or Cefixime, 400 mg bd × 7 days

Chlamydial Genital Tract Infection

Synopsis

Etiology: *Chlamydia trachomatis*, serovars D–K.

Epidemiology: In developed countries, more common than gonococcal genital tract infection.

Clinical features: About 50% of patients are asymptomatic; mucoid discharge in the rest.

Treatment: Azithromycin 1 g SOD¹⁴. Or doxycycline 200 mg daily × 7 days.

Etiology

Chlamydia trachomatis (*C. trachomatis*) serovars D–K. Half of nongonococcal urethritis is caused by *C. trachomatis*.

Epidemiology

Prevalence

- ❖ **Developed countries:** 5% of general population may be harboring *C. trachomatis*.
- ❖ **Developing countries:**
 - **Sub-Saharan Africa:** 50% of women may be harboring *C. trachomatis*.
 - **India:** 10% of women may be infected with *C. trachomatis*.

Clinical Features

Incubation period

1–5 weeks.

Symptoms

- ❖ Almost 50% of patients may be asymptomatic.
- ❖ Dysuria, frequency, and urgency of micturition.

Signs

- ❖ Urethral discharge which is mucoid or mucopurulent. Sometimes, the discharge is thick and creamy.
- ❖ Vaginal discharge, but generally asymptomatic.

Complications (Table 15.7)

Investigations

Smear examination

Presence of five or more polymorphs cells in high power field with no demonstrable organisms on Gram stain is confirmatory for nongonococcal urethritis¹⁵.

Identification of *C. trachomatis*

- ❖ **Direct fluorescent antibody test:** Rapid, specific. Done on urethral/cervical samples.
- ❖ **Polymerase chain reaction:** Very specific and sensitive. Can be done on first void urine, to overcome difficulties in sample collection.
- ❖ **Culture:** In cell lines (McCoy, HeLa).
- ❖ **Others:** Including ligase chain reaction and nucleic acid hybridization.

13. **Mucoid discharge:** in a third of patients with gonococcal urethritis, the discharge may be mucoid. It is therefore prudent to treat for both gonococcus and Chlamydia, if laboratory investigations cannot be done, because it is difficult to clinically differentiate between chlamydial and gonococcal genital infections, and often the two may co-exist.

14. **SOD:** single oral dose.

15. **Urethritis:** defined as presence of five or > polymorphs/high power field in urethral smear. When Gram-negative intracellular diplococci (ICDC) are present, the cause of urethritis is gonococcal (but a concomitant chlamydial urethritis is present in 30% of patients with gonococcal urethritis). Other causes of urethritis are *Mycoplasma genitalium*, *Ureaplasma urealyticum*, and *Trichomonas vaginalis*.

Treatment

General measures

As for gonococcal infection (P. 317).

Specific treatment

- ❖ Azithromycin : 1 g as a SOD¹⁴.
- ❖ Doxycycline : 200 mg daily × 7 days.
- ❖ Tetracyclines : 2 g daily (on an empty stomach) × 7 days
- ❖ Erythromycin : 2 g daily × 7 days.

Anogenital Warts

Synopsis

Etiology: Human papilloma virus, type 6,11,16,18. Others less frequently.

Morphology: Several types. Most typical is condyloma acuminata, which is a soft, fleshy papule or nodule.

Complications: Malignant transformation especially in immunosuppressed HIV individuals, especially with oncogenic types 16,18.

Treatment: Podophyllin, podophyllotoxin, imiquimod, mechanical destruction, cryotherapy. Trichloroacetic acid and cryotherapy for pregnant women.

Etiology

Causative agents

Human papilloma virus (HPV) type 6, 11, 16, 18, (more frequently) 31, 33, 35, 39, 51–59 (less frequently).

Transmission

- ❖ **Sexual transmission:** Both heterosexual and homosexual.
- ❖ **Vertical transmission:** Causes laryngeal papillomatosis in newborn.

Clinical Features

Morphology

- ❖ Several morphological variants described. Typical one is called **condyloma acuminata**. Other types include **papular anogenital warts and Bowenoid papulosis**. Subclinical infection is frequent.
- ❖ Condyloma acuminata presents as soft, fleshy, sessile or pedunculated, pinkish or skin colored papules; initially small, they may enlarge to form cauliflower tumors (Fig. 15.17).

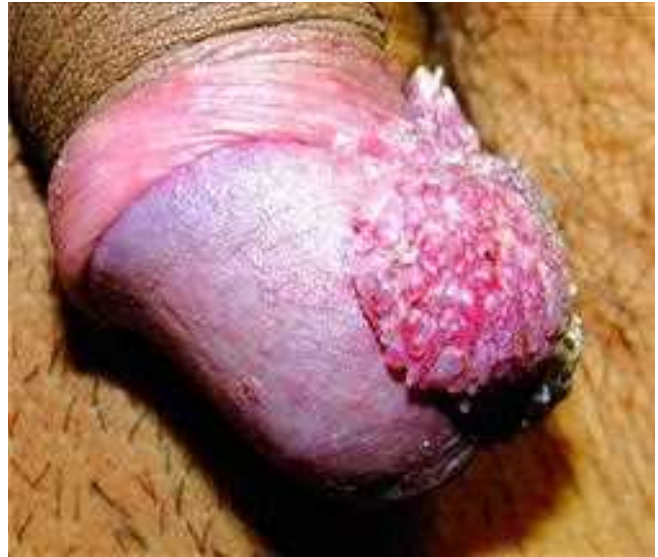

Fig. 15.17. Condyloma acuminata: large cauliflower-like lesion on the glans.

Sites of predilection

- ❖ **Males:** Frenulum, coronal sulcus, and the inner lining of prepuce (all moist areas).
- ❖ **Females:** Cervix, vulva, and vagina.

Complications

- ❖ Some HPV types (HPV 16, 18) are frequently associated with anogenital squamous atypia and less frequently with invasive carcinoma. Oncogenic potential enhanced in the presence of HIV-induced immunosuppression.
- ❖ Obstruction of labor by large vulval warts.
- ❖ Transmission from mother to child (**laryngeal papillomatosis**) during labor.

Course

- ❖ Spontaneous regression is seen in a third of patients.
- ❖ Malignant transformation of lesions caused by oncogenic types especially in background of HIV-induced immunosuppression. Infrequent.

Treatment

- ❖ Topical podophyllin¹⁶ (25%) or podophyllotoxin¹⁶ (0.5%). But should not be used in pregnancy.
- ❖ Imiquimod, 5% cream¹⁷. Avoid in pregnancy.
- ❖ 5 fluorouracil, 1–10%. Not in pregnancy.

16. **Podophyllin:** applied by physician, once a week, after protecting surrounding area with petroleum jelly. Washed after 4 h. Podophyllotoxin, self applied by patient twice daily on three consecutive days every week. Washed after 8–12 h.

17. **Imiquimod:** new immunomodulator. Applied once daily (6–10 h) at bed time, three times a week for up to 16 weeks.

- ❖ Trichloroacetic acid, 50–100%. Safe in pregnancy.
- ❖ Cryotherapy, with liquid nitrogen. Also safe in pregnancy.

Molluscum Contagiosum

Etiology

Two forms of infection recognized:

- ❖ Childhood variety, which is spread by skin-to-skin contact.
- ❖ Adult variety, which is sexually transmitted.

Clinical Features

- ❖ Pearly, white umbilicated papules (Figs. 15.18A and B) from which a white core can be extruded.
- ❖ On genitalia, scrotum, and groins.

Treatment

- ❖ Mechanical removal with a sharp curette.
- ❖ Cryotherapy with liquid nitrogen.

Candidal Genital Infection

Etiology

Etiological agents

- ❖ *Candida albicans*.
- ❖ Less frequently other species of *Candida*.

Transmission

In majority of patients, infection is not transmitted sexually, being an endogenous infection from gastrointestinal tract.

Predisposing factors

- ❖ Diabetes.
- ❖ Pregnancy.
- ❖ Patients on broad-spectrum antibiotics, contraceptive pills or steroids.
- ❖ HIV infection.

Clinical Features

Males

Manifests as **balanoposthitis** (Fig. 15.19), presenting either as:

- ❖ Discrete punctate eroded papulopustules on an erythematous glans. Rupture to form collarette of white scales.
- ❖ Diffuse erythema, immediately after intercourse with an infected partner. Due to hypersensitivity.

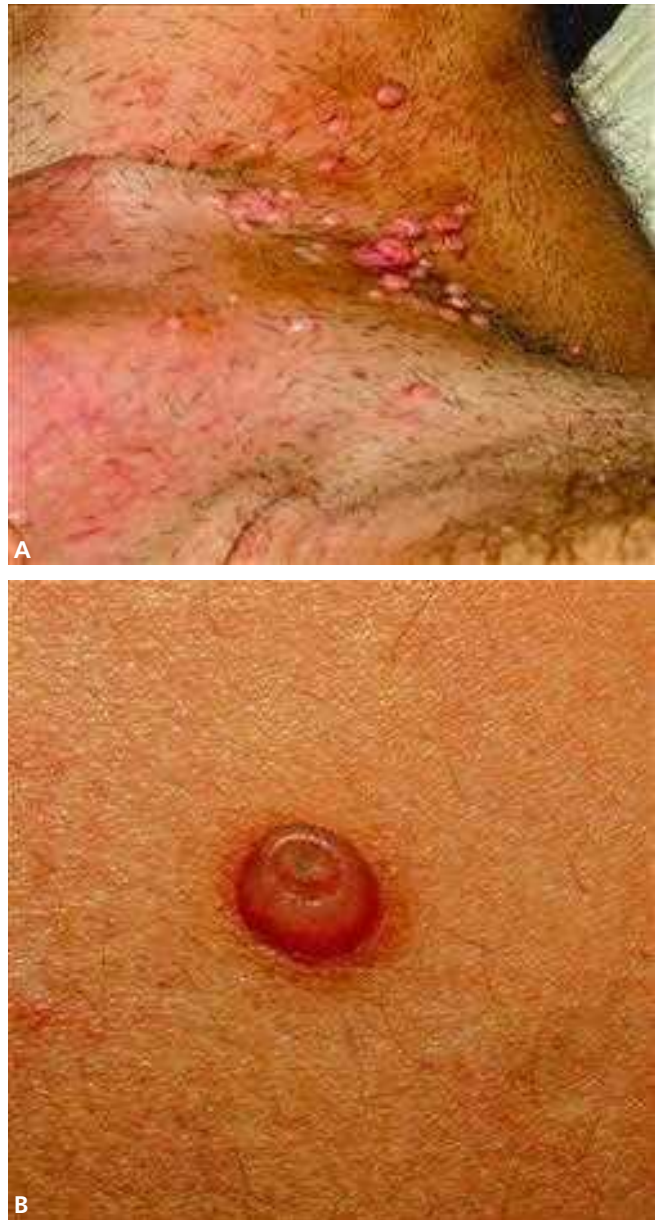

Fig. 15.18. Molluscum contagiosum: A: pearly, white umbilicated papules. B: close up showing central umbilication.

Females

Manifests as **vulvovaginitis** presenting with:

- ❖ Pruritus, dysuria, dyspareunia and thick, and curdy white vaginal discharge.
- ❖ Whitish plaques on erythematous vaginal wall. Edema and erythema of vulva and perineum.

Investigations

- ❖ **Potassium hydroxide mount:** Demonstration of yeast by microscopic examination of scrapings from glans or vaginal discharge.



Fig. 15.19. Candidal balanoposthitis: Discrete punctate eroded papulopustules on an erythematous glans.

❖ **Culture.**

❖ **Rule out diabetes:** In all patients.

Treatment

General measures

- ❖ Rule out and treat predisposing factors like diabetes.
- ❖ Treatment of sexual partners is not universally recommended but may be considered in women with recurrent vulvovaginitis.

Specific measures

Males

- ❖ **Topical therapy:** With antifungal agents
 - Clotrimazole, 1% cream.
 - Ketoconazole, 2% cream.
- ❖ **Systemic therapy:** If balanitis does not respond to topical therapy alone or is recurrent, a course of systemic anticandidal drugs can be tried:
 - Ketoconazole, 200 mg daily for 3 days.
 - Fluconazole, 150 mg once a week for 4 weeks or longer.

Females

- ❖ **Intravaginal therapy:** Is the mainstay of treatment:
 - Clotrimazole, 500 mg vaginal tablet, single dose.
 - Clotrimazole 100 mg, two vaginal tablets for 3 days.

❖ **Systemic therapy:** Recurrent and resistant cases would require systemic therapy, as for males.

Syndromic Management of STDs

Diagnosis and subsequent treatment of STDs can be:

- ❖ Etiologic.
- ❖ Presumptive.
- ❖ Syndromic.

Etiologic diagnosis based on clinical features as well as laboratory investigations, though ideal, has several disadvantages:

- ❖ Is expensive (sometimes prohibitively so!).
- ❖ Delays treatment.
- ❖ At most times and at most places, laboratory backup is not available.

Attempts to infer a presumptive etiological diagnosis based only on clinical manifestations eliminates the tedious and expensive laboratory component, but is very often inaccurate or incomplete (only about half of clinical diagnosis of STDs being correct). The low accuracy of clinical diagnosis is due to:

- ❖ Similarities of clinical appearance of various infections.
- ❖ Simultaneous infections with more than one organism.
- ❖ Atypical presentations.
- ❖ Presence of concomitant HIV infection.

The limitations of the clinical diagnosis without laboratory-assisted etiological diagnosis have led to development of **syndromic approach**.

Basis of Syndromic Management

- ❖ Syndromic approach uses clinical algorithms (flowcharts) based on an STD syndrome.
- ❖ Algorithms are formulated depending on several factors (Fig. 15.20) and then serve as a means to standardize case management, providing healthcare workers with easy guidelines as to who should receive which antibiotic treatment.
- ❖ The most feasible approach to prevent and control of STDs is to train the staff of primary health center (PHC), in syndromic management because:
 - Prevalence of STDs in the community is high (5–6%) and PHCs cater to the needs and demands of 80–90% of the rural and suburban populations, with 10% or more of

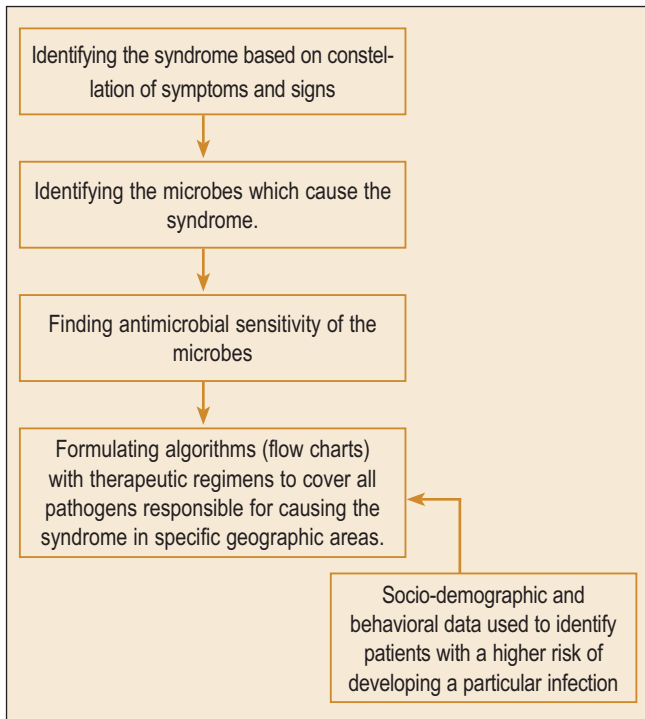


Fig. 15.20. Basis of syndromic approach.

their work being related to STDs and their complications.

- In resource-poor countries, diagnostic facilities at the PHC level are abysmally limited or nonexistent (microscopes only, but more often not even that!). Furthermore, where facilities are available, delays in the reporting of the tests are inevitable and the limitations of the techniques used for STD detection invariably hinder timely treatment of infectious cases.

Advantages of Syndromic Management

There are several pros and cons of syndromic approach (Table 15.9).

Components of Syndromic Management of STIs

Syndromic management of STIs consists of:

- ❖ Treatment (as per flow chart). Instructions for medication and follow-up.
- ❖ Education and counseling:
 - Educate and counsel client and sex partner(s) regarding RTIs/STIs, genital cancers, safer sex practices and importance of taking complete treatment.
 - Treat partner(s) wherever indicated.

Table 15.9. Advantages and disadvantages of syndromic approach

Advantages	Disadvantages
Simple, requiring minimal training. Can be integrated into PHC services and used even by health workers. Referral to higher center required only infrequently.	Global strategies cannot be formulated and needs to be adapted to specific region needs, requiring regular surveillance for antibiotic sensitivity
Inexpensive, as does away with expensive laboratory investigations	Increased cost of drugs, as patient may be treated for an infection, even if he does not harbor the microbe.
Allows for diagnosis and treatment in one visit (the first one!), as laboratory confirmation not needed	Low sensitivity and specificity especially for cervical infection in women
High rate of cure	Overtreatment.
Simplifies reporting and data collection for surveillance and planning	Does not give etiology of STDs
Helps to reduce spread of HIV, as both ulcerative STIs and those associated with discharges, facilitate the transmission of HIV.	

- Advise sexual abstinence during the course of treatment.
- Refer for voluntary counseling and testing for HIV, syphilis and hepatitis B.
- Consider immunization against Hepatitis B.
- Schedule return visit after 7 days to ensure treatment compliance as well as to see reports of tests if done.
- If symptoms persist, assess whether it is due to treatment failure or reinfection and advise prompt referral.
- ❖ Provide condoms and give instruction on how to use them.

Algorithms for Syndromic Management

Algorithms have been formulated for the management of several STIs but only the common syndromes (first four) will be discussed and these too have been simplified:

- ❖ Genital ulcer disease (Fig. 15.21).
- ❖ Urethral discharge (Fig. 15.22).
- ❖ Vaginal discharge (Fig. 15.23).
- ❖ Inguinal bubo (Fig. 15.24).
- ❖ Scrotal swelling.
- ❖ Lower abdominal pain in the female.
- ❖ Oral and anal STIs

Flow charts have also been formulated for special

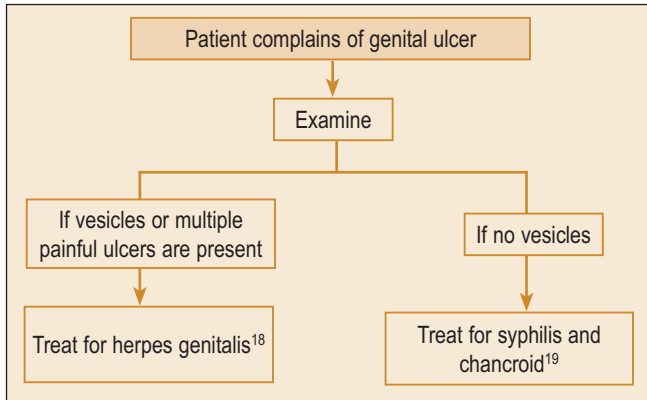


Fig. 15.21. Syndrome of genital ulcer disease.

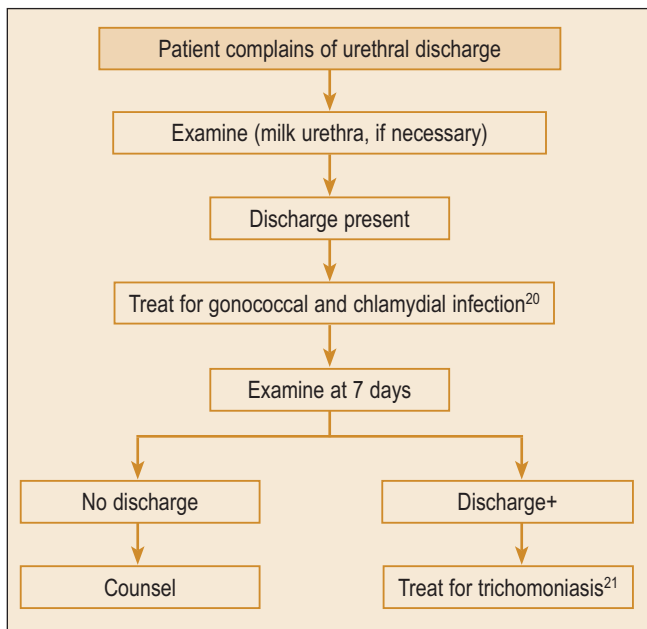


Fig. 15.22. Syndrome of urethral discharge.

populations:

- ❖ Flow chart for female sex workers.
- ❖ Flow chart for male and transgender sex workers.

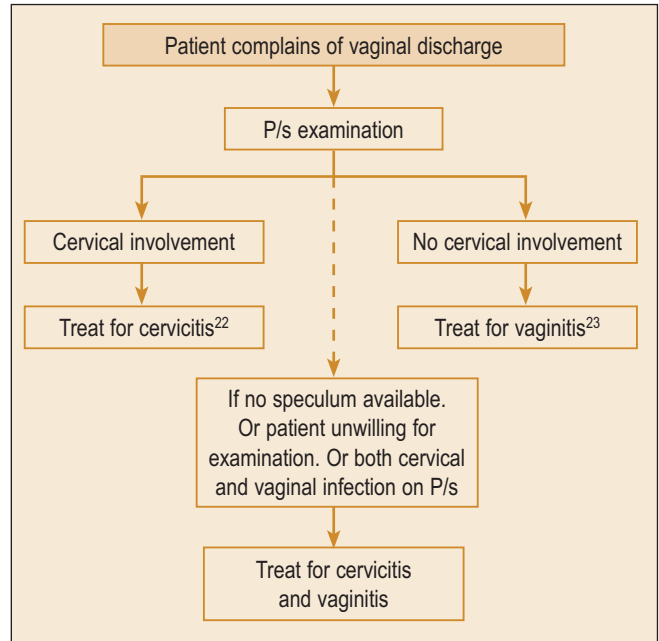


Fig. 15.23. Syndrome of vaginal discharge.

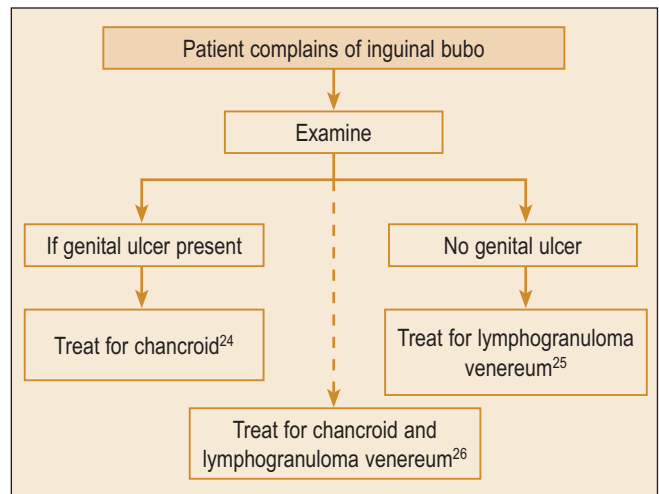


Fig. 15.24. Syndrome of inguinal bubo.

18. **Treatment of herpes genitalis:** acyclovir 400 mg, three times daily × 7 days.
19. **Treatment of syphilis and chancroid:** inj. benzathine penicillin 2.4 million units (half in each buttock) after testing for sensitivity and azithromycin, 1 g single oral dose or ciprofloxacin, 500 mg twice daily × 3 days.
20. **Treatment of gonococcal and chlamydial infection:** treated with single oral dose (SOD) of cefixime 400 mg plus azithromycin 1 g.
21. **Treatment of trichomoniasis:** secnidazole 2 g SOD or tinidazole 500 mg orally, twice daily for 5 days.
22. **Treatment of cervicitis:** cervicitis caused by *N. gonorrhoeae* and *C. trachomatis*. Treated with single oral dose (SOD) of cefixime, 400 mg plus azithromycin 1 g.
23. **Treatment of vaginitis:** vaginitis due to candida spp., *T. vaginalis* and bacterial vaginosis. Treated with secnidazole 2 g SOD or tinidazole 500 mg orally, twice daily for 5 days and fluconazole 150 mg SOD or clotrimazole 500 mg vaginal pessaries once.
24. **Treatment chancroid:** azithromycin, one SOD or ciprofloxacin, 500 mg twice daily × 3 days.
25. **Treatment of lymphogranuloma venereum:** doxycycline 100 mg twice daily × 21 days.
26. **Treatment of chancroid and lymphogranuloma venereum:** newer NACO recommendations recommend treatment for chancroid and LGV.

HIV Infection and AIDS

Etiology

Causative Agent

Human immunodeficiency virus (HIV).

Types of HIV

- ❖ There are two main types of HIV:
 - **HIV 1:** HIV-1 which has been classified into a major or M group and an outlier or O group. Group M consists of clades (subtypes) A to N. There is some geographic variation in distribution of the various subtypes:
 - India: subtype C, along with subtypes A, B, and E.
 - Africa: subtypes A, C, and D.
 - Other parts of World: subtype B.
 - **HIV 2:** HIV-2 is less frequently encountered; initially identified in West Africa, has now spread to many parts of Asia, including India.
- ❖ The clinical spectrum of both HIV-1 and HIV-2 induced diseases is almost identical, except that infection with HIV-2:
 - Is milder.
 - Progresses slowly (as it has longer incubation period).
 - Is poorly transmitted vertically (from mother to fetus).

Structure of HIV

HIV consists of two parts (Fig. 15.25):

- ❖ **Outer envelope:** Bilipid membrane in which the viral antigens (glycoproteins gp 120 and gp 41) are embedded. The glycoproteins are responsible for attachment of virus to the CD4 receptors of host cells and subsequent fusion of the virus envelope with the host cell membrane.
- ❖ **Inner core:** The inner core is bounded by a protein coat and contains three important viral enzymes:
 - Reverse transcriptase.
 - Integrase.
 - Protease.

Pathogenesis of HIV

- ❖ HIV is an enveloped RNA **retrovirus**²⁷.

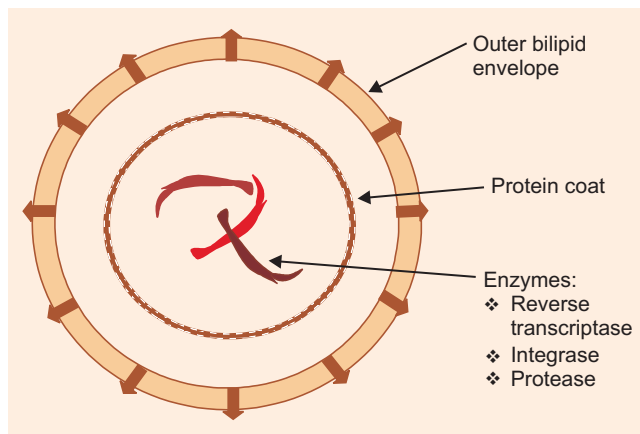


Fig. 15.25. Structure of HIV virus.

- ❖ Both HIV 1 and 2 infect the same target cells (CD4+ T cells²⁸, monocytes, macrophages, and dendritic cells, including Langerhan's cells) through the same CD4 receptors.
- ❖ On entering the T cells, the virus integrates its RNA genome into the host cell genome by first transcribing this genome into DNA (**HIV provirus**) with the help of enzyme reverse transcriptase.
- ❖ Provirus is then transcribed and translated along with the host-cell DNA to synthesize specific viral components, which eventually assemble to produce complete virus particles.
- ❖ At this time, antibodies against the virus are not present, *i.e.*, patient is seronegative. But he is highly infectious as the blood is teeming with the virus. So, this period is termed "**window period**" because the patient is infected but tests for antibodies are negative (false negative).
- ❖ Though some virions are killed, HIV continues to multiply rapidly, infecting more and more CD4 cells.
- ❖ The clinical manifestations depend on the effect on immune system:
 - In the early period of immune destruction, there is clinical latency, *i.e.*, the patient looks healthy and unless his blood is tested, he is not even suspected to be suffering from HIV infection.
 - Over period of time (Table 15.10) as immunosuppression progresses, patient becomes symptomatic.

27. **Retrovirus:** so named because of an unusual step in their life cycle—the synthesis of DNA from an RNA template, using the enzyme reverse transcriptase.

28. **CD4+ cells:** T helper cells.

Table 15.10. Disease progression to AIDS in HIV-infected individuals

	Percentage to AIDS (%)	Clinical latency
Typical progressors	70–80	8–10 years
Rapid progressors	10–15	Absent/brief
Long-term non-Progressors	5	Indefinite
Long-term survivors	5	8–10 years*

*But remain clinically stable.

Transmission

Routes of infection

HIV transmission takes place through the following routes:

- ❖ **Sexual intercourse** (vaginal/anal/oral): With an infected partner:
 - Man with woman (heterosexual).
 - Man with man (homosexual).
 - Woman with woman (?).
- ❖ **Transfusion:** With infected blood and blood products, transplantation of organ/tissue, and through artificial insemination.
- ❖ **Contaminated needles and syringes:** Seen most frequently in intravenous drug users (IDUs) when they share unsterilized needles and syringes.
- ❖ **Vertical transmission:** From an infected mother to child, *i.e.*, perinatal transmission (before, during and after delivery).
- ❖ **Nosocomial infection:** In hospital/health care settings on account of accidental needle stick injury or sharp instrument cuts, *etc.*, while treating an HIV/AIDS patient, though rare, does occur.

Efficiency of transmission

Efficiency of transmission depends on the route of infection (Table 15.11).

Heterosexual transmission

Male to female transmission is 2–17 times more efficient than female to male transmission because:

- ❖ Females have a larger surface area of mucosa exposed to their partner's genital secretions during intercourse as compared to men.
- ❖ Period of contact of female genital mucosa with semen is longer during sexual act.

Table 15.11. Efficiency of transmission of HIV

Mode of transmission	Efficiency of transmission (%)	Contribution to total infections in India (%)
Sexual intercourse	0.1–1	75–90
Blood transfusion	90–95	7–8
Vertical	20–40	1–5
IDU	1–10	2–7
Needle stick injury, tattooing, etc.	0.3	?

- ❖ Semen infected with HIV contains a higher concentration of the virus than secretions from female genital tract.
- ❖ Sex during menstruation and anal sex (due to trauma) enhances male to female transmission.

Homosexual transmission

More efficient than heterosexual transmission, because of concomitant trauma.

Vertical transmission

The rate of vertical transmission of HIV from mother to the fetus varies between 20–40% and depends on:

- ❖ **Maternal factors:** The following factors increase mother to child transmission:
 - High maternal viral load.
 - Presence of STDs in mother.
 - Breach in placental barrier.
- ❖ **Fetal factors:** The following factors increase mother to child transmission:
 - Genetic differences in fetal susceptibility.
 - Invasive procedures that breach the infant's or mother's skin (*e.g.*, fetal scalp electrodes, scalp blood sampling, episiotomy, and operative vaginal delivery).
- ❖ **Type of delivery:** Caesarean section may have a (debatable) protective effect.

Transmission through breast milk

- ❖ Infants are susceptible to infection because:
 - Immaturity of gastrointestinal tract due to reduced gastric acidity, thin mucosa and microvilli, and deficiency of IgA secreting cells.
 - Quantity of virus present in breast milk²⁹ may be significant if HIV infection in mother is of recent origin or the mother is a case of full-blown AIDS.

29. **Quantity of virus present in breast milk:** is normally small.

- ❖ **Risk of transmission:** Through breast milk depends on:
 - *Period of breast feeding.*
 - *Amount of exposure.*
 - *Infectivity of milk:* being highest in early infection and in full blown AIDS.
 - *Specific susceptibility:* of infant.
- ❖ **Should HIV positive mothers breast feed their sero-discordant infants?:** In developing countries risk of not breast feeding infants (diarrhea) far outweigh the risk of HIV transmission. However, the risk of transmission exceeds potential benefits of breast feeding after 3–7 months of age.

Epidemiology

The HIV/AIDS pandemic comprises many separate independent epidemics each involving a different mode of HIV transmission and each epidemic has developed at different times in different countries. The following are the chief characteristics of the HIV pandemic:

- ❖ High prevalence among patients with STDs.
- ❖ High prevalence among IDUs.
- ❖ High prevalence among general population in some areas of Africa (in Swaziland, the prevalence of HIV infection in adult population is 33%), and South and South East Asia.

Global Scenario

- ❖ Of the 33.3 million people living with HIV/AIDS (PLHAs) (Table 15.12),
 - 30.8 million are adults and 2.5 million are children.
 - 55% are men and 45% are women.
- ❖ Some trends seen include:
 - Steepest increase in HIV infection is in Eastern Europe and East Asia.
 - Sub Saharan Africa continues to be most affected with two-thirds of HIV patients living here (with male:female ratio of 5:7).

Indian Scenario

- ❖ National AIDS Control Programme III is progressing steadily towards the objective of halting and reversing HIV epidemic in India in period 2007–12.

- ❖ Of the 2.4 million PLHAs (Table 15.12),
 - 96.5% are adults and 3.5% are children.
 - 61% are men and 39% are women.
- ❖ Some trends seen include:
 - Declining prevalence in high-prevalence states indicating impact of sustained programme interventions.
 - Decrease in prevalence in pregnant women³⁰ especially in Southern states.
 - High level of prevalence in high-risk groups (men who have sex with men and IDUs).
 - Decreasing prevalence among SWs in areas where targeted interventions have been implemented.

Table 15.12. Epidemiology of HIV infection in 2009

	Global	India
No. of people living with HIV	33,300,000	2,400,000
New cases detected	2,600,000	130,000
Adult prevalence (%)	0.7	0.31

Natural History of HIV Infection

- ❖ Natural history of any disease refers to stages through which a disease passes if there is no intervention.
- ❖ The course of HIV infection from the time of initial infection to the development of full blown AIDS is divided into five stages (Table 15.13):
 - *Primary HIV infection:* which may manifest as acute retroviral syndrome or be asymptomatic.
 - *Clinical stage 1:* which may manifest as persistent generalized lymphadenopathy or be asymptomatic.
 - *Clinical stage 2:* which may manifest with unexplained symptoms, infections, oral lesions or itchy dermatoses.
 - *Clinical stage 3:* which may manifest with unexplained symptoms, infections, oral lesions itchy dermatoses or 'penic' hematological changes.
 - *Clinical stage 4:* which may manifest with wasting disease, infections, neoplasms and neurological disease.
- ❖ Recognizing these stages is useful in resource limited settings (as in Africa and Asia) and is an important research tool in studies of progression to symptomatic HIV infection in persons

30. **Prevalence in pregnant women:** is considered a surrogate marker of incidence/new infections in general population.

Table 15.13. WHO staging for HIV infection (2006)

Primary HIV infection
Asymptomatic Acute retroviral syndrome
Clinical stage 1
Asymptomatic Persistent generalized lymphadenopathy
Clinical stage 2
<i>Unexplained symptoms</i> 1. Unexplained moderate weight loss (<10% of presumed or measured body weight) <i>Infections</i> 2. Recurrent respiratory tract infections 3. Herpes zoster 4. Fungal infections of finger nails <i>Oral lesions</i> 5. Recurrent oral ulcerations 6. Angular cheilitis <i>Itchy dermatoses</i> 7. Papular pruritic eruptions 8. Seborrheic dermatitis
Clinical stage 3
Conditions where a presumptive diagnosis can be made on the basis of clinical signs or simple investigations: <i>Unexplained symptoms</i> 1. Unexplained chronic diarrhea for >1 month 2. Unexplained persistent fever (intermittent or constant) for >1 month 3. Unexplained severe weight loss (>10% of presumed or measured body weight) <i>Infections</i> 4. Severe presumed bacterial infections ³¹ 5. Pulmonary tuberculosis diagnosed in last 2 years <i>Oral lesions</i> 6. Oral candidiasis 7. Oral hairy leucoplakia 8. Acute necrotizing ulcerative stomatitis, gingivitis or periodontitis <i>Conditions where confirmatory diagnostic testing is necessary</i> 1. Unexplained anemia (<8.0 g/l) or neutropenia (<500/ μ l) or thrombocytopenia (<50,000/ μ l) for >1 month

aged 15 years or more who have had a positive HIV antibody test or other laboratory evidence of HIV infection.

Acute Retroviral Syndrome (ARS)

- ❖ Is manifestation of primary HIV infection.
- ❖ Occurs 2–3 weeks after infection.

Incidence

Though experienced by 80–90% of HIV infected patients, is only infrequently recognized as due to

Clinical stage 4
Conditions where a presumptive diagnosis can be made on the basis of clinical signs or simple investigations: 1. HIV wasting syndrome <i>Infections</i> 2. Pneumocystis pneumonia 3. Recurrent severe or radiological bacterial pneumonia 4. Chronic herpes simplex infection (orolabial, genital or anorectal of >1 months duration) 5. Esophageal candidiasis 6. Extrapulmonary tuberculosis <i>Neoplasms</i> 7. Kaposi's sarcoma <i>Neurological diseases</i> 8. Central nervous system toxoplasmosis 9. HIV encephalopathy Conditions where confirmatory diagnostic testing is necessary: <i>Bacterial infections</i> 1. Disseminated nontuberculous mycobacteria infection 2. Recurrent nontyphoidal salmonella septicemia <i>Fungal infections</i> 3. Extrapulmonary cryptococcosis including meningitis 4. Candidiasis of trachea, bronchi or lungs <i>Viral infections</i> 5. Visceral herpes simplex infection 6. Cytomegalovirus infection (retinitis or infection of an organ other than liver, spleen or lymph nodes) 7. Progressive multifocal leucoencephalopathy <i>Protozoal infections</i> 8. Cryptosporidiosis 9. Isosporiasis 10. Atypical disseminated leishmaniasis <i>Neoplasia</i> 11. Lymphoma (cerebral or B cell non-Hodgkin) 12. Invasive cervical carcinoma

HIV infection and is often dismissed as a flu-like illness.

Incubation Period

Two to three weeks, though may be much longer.

Clinical Features

The illness lasts 1–3 weeks and manifests as:

- ❖ **Symptoms:** Fever, pharyngitis, vomiting, headache, arthralgia, and myalgia.

31. **Severe presumed bacterial infections:** e.g., pneumonia, empyema, meningitis, bacteremia, pyomyositis, and bone or joint infection.

- ❖ **Cutaneous manifestations:** Maculopapular rash, mucosal (mouth, esophagus, and genital) ulceration.
- ❖ **Lymphoreticular system:** Lymphadenopathy and hepatosplenomegaly.
- ❖ **Neuropsychiatric manifestations:** Meningoencephalitis, neuropathies (peripheral neuropathy, facial palsy, Guillain–Barré syndrome, brachial neuritis, radiculopathy), and psychosis.

Investigations

Hematological

- ❖ Initial lymphopenia is followed by lymphocytosis.
- ❖ Depletion of CD4 cells with CD8 lymphocytosis. Presence of atypical lymphocytes, usually lasting 1–3 weeks.

Viral markers

- ❖ **HIV RNA:** Detection of HIV RNA is very sensitive, but expensive.
- ❖ **p24 antigen:** p24 antigen is detectable in 30% of patients with ARS.
- ❖ **Viral culture:** HIV can be cultured but technique is dangerous, labor intensive and not sensitive.

Serology

- ❖ Antibody tests may be negative in early illness.
- ❖ Anti-HIV IgM is detected earlier than IgG³².

Treatment

Recognition of this stage is important as institution of aggressive antiretroviral therapy (ART) in this stage, protects susceptible CD4 cells from HIV infection.

Asymptomatic Infection

(With or without persistent generalized lymphadenopathy, PGL).

Clinical Features

- ❖ Patient is clinically asymptomatic and is often diagnosed during screening for blood or organ donation or during routine check up.
- ❖ On examination, patient may have PGL.³³ PGL is of no prognostic value, though disappearance

of these lymph nodes may indicate onset of symptomatic HIV infection.

Investigations

- ❖ **Baseline investigations:** Complete hemogram, ESR, liver function tests, urine examination, chest X-ray, sonography of abdomen and pelvis, and Mantoux test need to be done.
- ❖ **Investigations to rule out other STDs:** Serological tests for syphilis and hepatitis B and C.
- ❖ **Investigations specific to HIV infection:**
 - CD4 cell count³⁴ decreases gradually at the rate of 60 cells/ml/year.
 - Evaluation of CD4/CD8 lymphocytes and estimation of HIV-1 viral load is optional in resource poor settings, if there is no plan to initiate antiretroviral therapy. However, these tests may help to decide initiation of chemoprophylaxis for opportunistic infections.

Treatment

- ❖ **Counseling:** Lifestyle modification including safer sex, refraining from organ donation, maintaining food and water hygiene.
- ❖ **Periodic follow up:** Every 3–6 months for evaluation, investigations, and counseling.

Early Symptomatic Stage of HIV infection

Previously known as AIDS-related complex (ARC)³⁵.

Clinical Features

Though the patient looks healthy, certain manifestations are seen:

- ❖ **Autoimmune disorders:**
 - Idiopathic thrombocytopenic purpura (ITP).
 - Gullian-Barré syndrome.
 - Chronic demyelinating neuropathy of peripheral nerves and mononeuritis multiplex.
 - Cranial nerve palsies (including Bell's palsy).
 - Sjogren's syndrome.
 - Polymyositis.
- ❖ **Infections:**
 - Herpes zoster.
 - Oral candidiasis.

32. **IgG:** is more persistent.

33. **PGL:** defined as enlarged lymph nodes, involving at least two noncontiguous sites other than inguinal nodes.

34. **CD4 cell count:** the normal CD4 cell count is 600–1500 in adults.

35. **ARC:** not to be confused with ARS.

- Oral hairy leucoplakia.
- Pulmonary tuberculosis.

Investigations

- ❖ **Serological and virological markers:** Both virological and immunological markers are present.
- ❖ **CD4/CD8 cell counts.**

AIDS

Definition

The WHO case definition for AIDS surveillance is shown in Table 15.14.

Table 15.14. Expanded WHO Case Definition for AIDS Surveillance³⁶

An adult or adolescent (>12 years of age) is considered to have AIDS if:
❖ A test for HIV antibody gives positive result and one or more of the following conditions are present:
➤ >10% body weight loss or cachexia, with diarrhea, fever, or both, intermittent or constant for at least 1 month, not known to be due to conditions unrelated to HIV infection.
➤ Cryptococcal meningitis.
➤ Pulmonary or extrapulmonary tuberculosis.
➤ Candidiasis of the esophagus (which may be presumptively diagnosed based on the presence of oral candidiasis accompanied by dysphagia).
➤ Clinically diagnosed life threatening or recurrent episodes of pneumonia, with or without etiological confirmation.
➤ Neurological impairment that is sufficient to prevent independent daily activities, not known to be due to a condition unrelated to HIV infection (e.g., trauma or cerebrovascular accident).
➤ Invasive cervical cancer.
➤ Kaposi's sarcoma.

Clinical Features

From a dermatologist's point of view, the clinical manifestations of this stage can be classified as:

- ❖ Nondermatological.
- ❖ Dermatological.

Nondermatological manifestations

The nondermatological manifestations of AIDS can be:

Constitutional disease (subgroup A disease)

- ❖ Fever for >1 month.

- ❖ >10% weight loss.
- ❖ Diarrhea lasting >1 month.

With no other condition to explain these findings.

Neurological disease (subgroup B disease)

- ❖ Dementia.
- ❖ Myelopathy.
- ❖ Peripheral neuropathy.

With no other condition to explain these findings.

Secondary infections (subgroup C disease)

- ❖ **C₁:** One of 12 specified symptomatic or invasive diseases, which define AIDS (Table 15.15).
- ❖ **C₂:** Symptomatic or invasive disease with additional infections.

Table 15.15. Infections frequently seen in AIDS patients

<i>Pneumocystis jiroveci</i> pneumonia
Chronic cryptosporidiosis
Toxoplasmosis
Extraintestinal strongyloidosis
Isosporiasis
Candidiasis (esophageal, bronchial, pulmonary)
Cryptococcosis
Histoplasmosis
<i>Mycobacterium avium intracellulare</i> complex or <i>M. kansasii</i> infection
Cytomegalovirus infection
Chronic mucocutaneous or disseminated herpes infection
Progressive multifocal leucoencephalopathy

Secondary neoplasms (subgroup D disease)

- ❖ Kaposi's sarcoma.
- ❖ Non-Hodgkin's lymphoma.
- ❖ Primary lymphoma of brain.

Miscellaneous (subgroup E disease)

Other clinical findings which may be attributable to HIV disease not meeting subgroup A, B, C, D requirements.

Dermatological manifestations of HIV infection

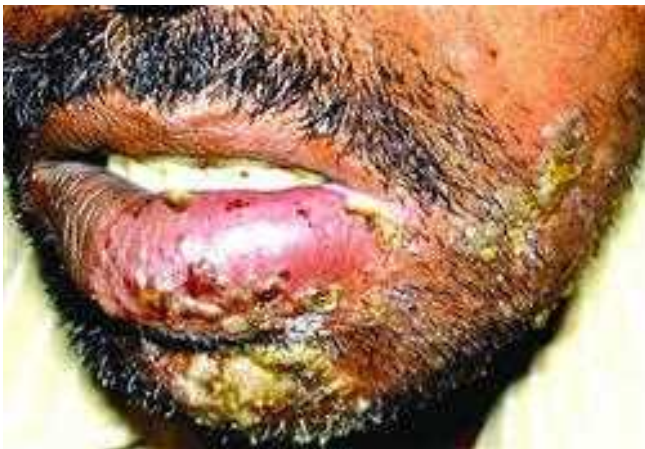The cutaneous lesions in HIV infection can broadly be classified into:

Infectious manifestations (Table 15.16)

36. To be used as case definition of AIDS and not for clinically staging HIV infection.

Table 15.16. Cutaneous infections in HIV infected individuals

Infections	Manifestations	Treatment
Dermatophytosis	Very common. Chronic, recurrent, multiple lesions. Typical manifestations/tinea incognito. Proximal subungual onychomycosis ³⁷ typical	Routine treatment
Candidiasis	Most common cutaneous infection. Manifests in oropharynx, esophagus, bronchi genitalia, and nail folds.	Difficult to treat. Antifungal resistance. Weekly fluconazole as prophylaxis.
Staph infection	<i>S. aureus</i> infections; severe, recurrent.	Resistant to treatment
Bacillary angiomatosis	Indicates advanced HIV disease.	Erythromycin
Herpes genitalis	Normal course initially. Later becomes chronic	Suppressive therapy with acyclovir. May be resistant to acyclovir
Herpes zoster (Fig. 15.26)	Initially normal course. Later recurrent, multidermatomal involvement and dissemination. Also severe postherpetic neuralgia.	Acyclovir needed in late stages. Also to prevent postherpetic neuralgia
Molluscum contagiosum (Fig. 15.27)	Larger numerous lesions. Atypical lesions.	Routine therapy
Human papilloma virus (Fig. 15.28)	Larger, more numerous. Atypical morphology. Watch for malignant transformation in anogenital warts	Routine therapy
Epstein–Barr virus	Oral hairy leucoplakia. Resembles leucoplakia but has vertical corrugations. Located on lateral aspect of tongue.	

**Fig. 15.26.** Herpes zoster in AIDS patient: necrotic lesions, often multidermatomal.**Noninfectious manifestations**❖ **Seborrheic dermatitis (Fig. 15.29):**

- Most common dermatosis in AIDS patients.
- May be due to proliferation of *Malassezia furfur*.
- Florid lesions with intense erythema, thick scales and involving unusual sites.

❖ **Psoriasis:**

- Can present as severe psoriasis or Reiter's syndrome. Or as atypical lesions (Fig. 15.30)
- Difficult to treat. May need oral retinoid therapy; methotrexate should not be given because it is an immunosuppressive.

❖ **Other rashes:** In HIV-infected individuals:

- Skin-colored papules on the head, neck, and upper trunk.
- Eosinophilic pustular folliculitis of HIV. Appears as itchy follicular papules and pustules on head, neck and upper trunk (Fig. 15.31).

❖ **Kaposi's sarcoma:**

- Kaposi's sarcoma (KS) is probably caused by human herpes virus 8, which is sexually transmitted; most frequently seen in HIV infection acquired homosexually.
- Asymptomatic brownish or violaceous macules or plaques.
- Lower extremities, (especially around ankles) face, trunk and mucosae involved.
- Several treatment modalities tried, including

37. **Proximal subungual onychomycosis:** is seen only in HIV infection.

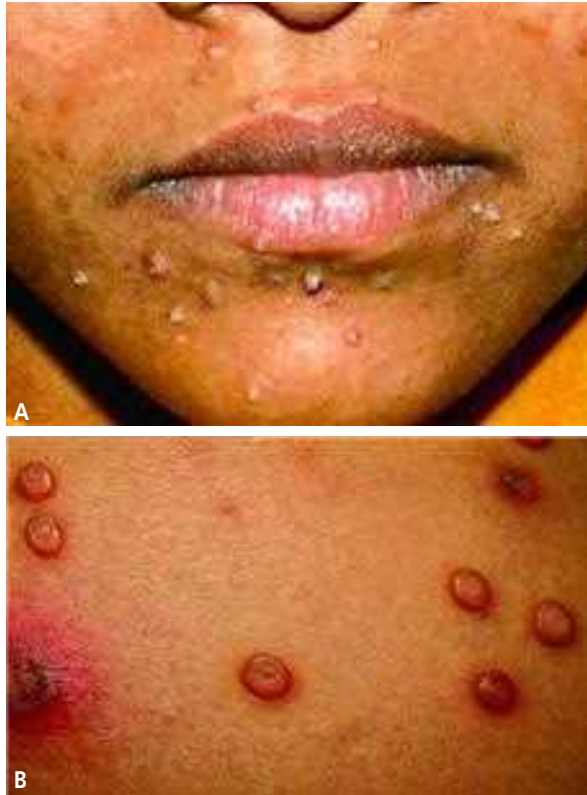

Fig. 15.27. Molluscum contagiosum in an AIDS patient. Multiple lesions on the face of an adult patient suggestive. Lesions often numerous and large.

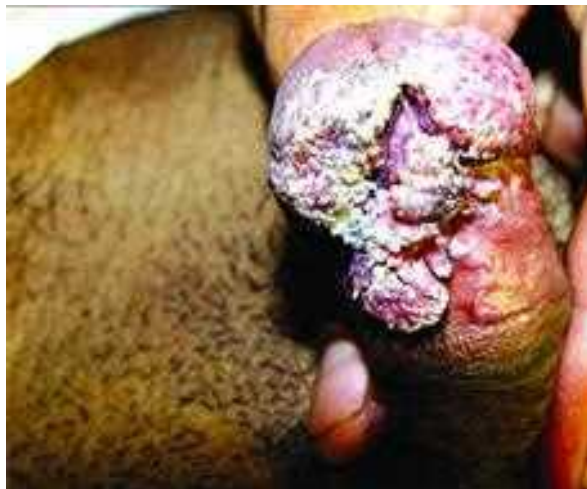

Fig. 15.28. Condyloma acuminata in an AIDS patient: larger, recurrent lesions.

electrodesiccation, curettage, surgical excision, interferon therapy, radiotherapy, and chemotherapy.

Sexually transmitted diseases (STDs)

STDs and HIV make a lethal combination and have several interactions:

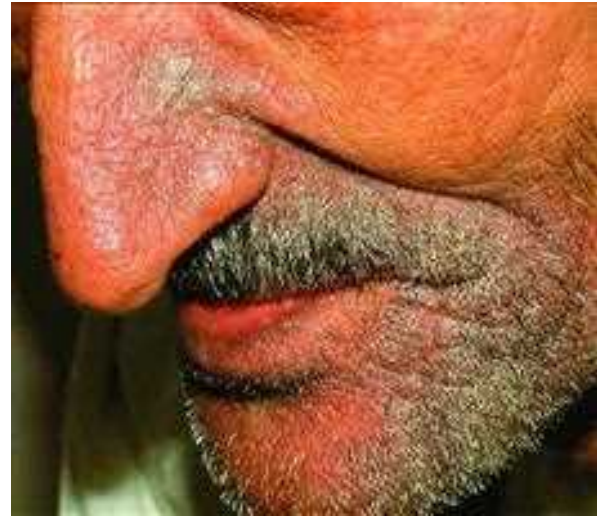

Fig. 15.29. Seborrheic dermatitis in a patient with AIDS: scaly erythematous plaques.

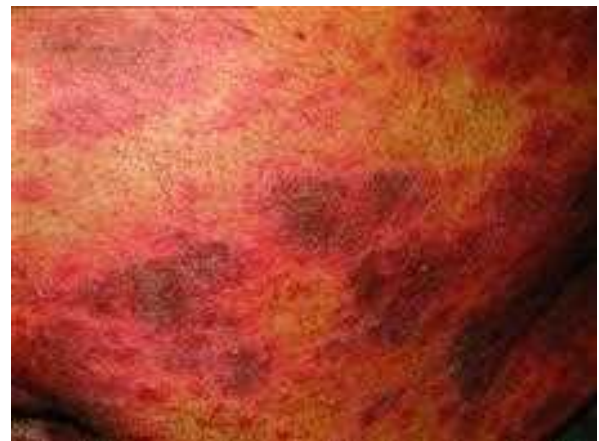

Fig. 15.30. Psoriasis in a patient with AIDS: atypical inflammatory plaques.

- ❖ Presence of STDs amplifies the risk of transmission of HIV. The ulcerative STDs (syphilis, herpes genitalis, and chancroid) increase the transmission of HIV almost ten times, while the STDs associated with discharges (gonorrhea, chlamydial infection) amplify the transmission of HIV by four to five times.
- ❖ In the early phase of HIV infection, the course of STDs is normal but as the immunosuppression progresses, the STDs may present atypically, run a fulminant course and may be resistant to conventional treatment.
- ❖ Presence of STDs may modify the course of HIV, *e.g.*, human papilloma virus may have a higher oncogenic potential in presence of HIV infection.

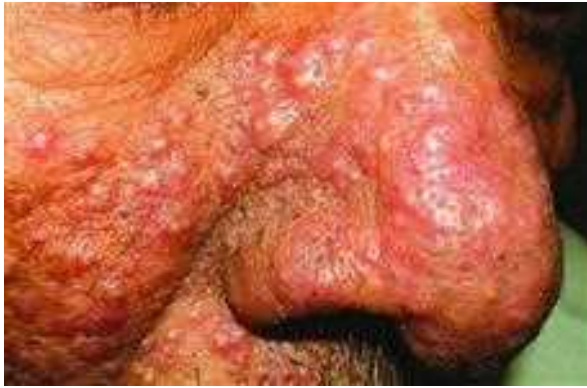

Fig. 15.31. Eosinophilic pustular folliculitis of HIV: appears as itchy follicular papules and pustules on head, neck and upper trunk.

Investigations

The laboratory tests that should be done in a patient suspected of having an HIV infection are shown in Table 15.17.

Table 15.17. Laboratory tests in a patient suspected of having HIV infection

Tests to diagnose HIV infection
Tests for HIV-specific antibodies
<i>Screening tests</i>
❖ ELISA
❖ Rapid tests
<i>Supplemental tests</i>
❖ Western Blot assay
❖ Immunofluorescence test
Tests to identify HIV (Confirmatory tests)
❖ Viral isolation
❖ HIV-specific core antigen (p24)
❖ PCR for RNA copies
Tests to assess disease progression
❖ Measurement of number of HIV-RNA copies
❖ CD4 counts
Diagnosis of complications
❖ Ruling out of opportunistic infections
❖ Surveillance for neoplasia

Tests to Diagnose HIV Infection

Serological tests

There are two types of serological tests:

- ❖ Screening tests.
- ❖ Supplemental test.

Screening tests

- ❖ Screening tests are rapid and inexpensive serological tests. They are highly sensitive but may

not be very specific (*i.e.*, false positives occur), so they are presumptive and not confirmatory tests.

- ❖ **Types of screening tests:** Screening tests are of two types (Table 15.18).
 - **ELISA or EIA:** which are the most frequently used tests.
 - **Rapid tests:** which are point of care tests and include **oraquick** and **orasure** done on oral fluids.

Table 15.18. Screening tests for detection of HIV infection

	ELISA*	Rapid tests
Principle	Use enzymes as indicator system	Use color as indicator system
Initial cost	High initial investment	Do not require complicated apparatus
Running cost	Low cost/test	High cost/test
Use	Useful screening tests	Useful in emergency clinics, casualties and trauma centers where immediate screening of blood donors have to be done.
Time required	60–90 min	<30 min

*Some ELISA tests incorporate a color indicator.

- ❖ **Indications for screening test:** The screening tests for HIV are done in the following situations:

- Screening donors (of blood, blood products, tissues, organs, sperms, and ova).
- Unlinked and anonymous testing for sentinel surveillance (*e.g.*, in STD patients).
- Voluntary testing for diagnosis of HIV infection in suspected asymptomatic patients or testing in patients suspected to have immunosuppression.
- Voluntary testing of serum from persons participating in clinical research.

- ❖ **Interpretation of screening tests:** This depends on the purpose of the screening test. National AIDS Control Organization (NACO) has recommended implementation of three testing algorithms for HIV testing.

- Testing algorithm I (Fig. 15.32)
 - Used in blood banks to screen donors.
 - Unlinked, anonymous sampling, so pretest counseling not needed.
 - Uses a single, highly sensitive, reliable, cheap enzyme immunoassay (EIA) for HIV-1 and HIV-2.

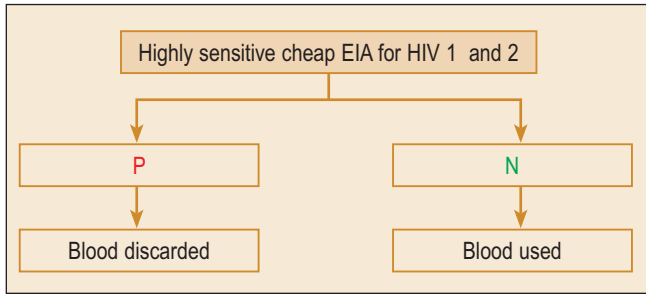


Fig. 15.32. Testing algorithm I: done in blood banks for screening. Done without pretest counseling. P: Positive; N: Negative.

- If the sample is positive, the blood is discarded without doing any further tests. If sample is negative it is used for transfusion.
- *Testing algorithm II*
 - For serosurveillance.
 - Unlinked, anonymous sampling, so pretest counseling not needed.
 - Testing strategy is shown in Fig. 15.33.
- *Testing algorithm III*
 - Used for diagnostic purposes.
 - Pretest counseling mandatory.
 - Algorithm used depends on clinical status of patient.
 1. For asymptomatic persons, all samples are first tested with a sensitive EIA; positive samples are then tested with second specific EIA based on a different antigen preparation or principle. Samples reactive with second test are subjected to a third EIA (both specific and sensitive) based on different antigen/principle. The samples positive after 3rd test are taken as positive (Fig. 15.34).
 2. For patients with clinical signs and symptoms of HIV infection/AIDS, the strategy for serosurveillance should be used (Fig. 15.33).

Supplemental tests

- ❖ Are also serological tests for detection of antibodies against HIV.
- ❖ Done to validate the positive tests of screening.
- ❖ Two types of tests have been used.
 - Western blot (WB) assay.
 - Immunofluorescence test.
- ❖ Are expensive (Western blot) and sometimes difficult to interpret (both). Studies have shown that combination of two or more EIAs (using different principles/antigens) may provide as

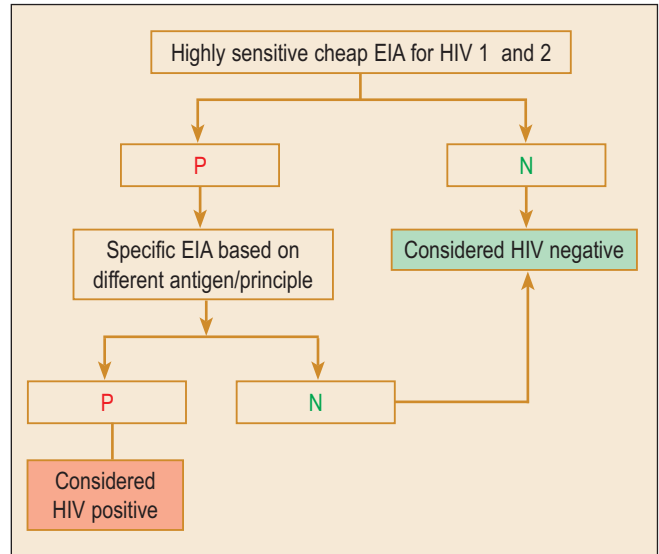


Fig. 15.33. Testing algorithm II: done for serosurveillance. Done without pretest counseling. P: Positive; N: Negative.

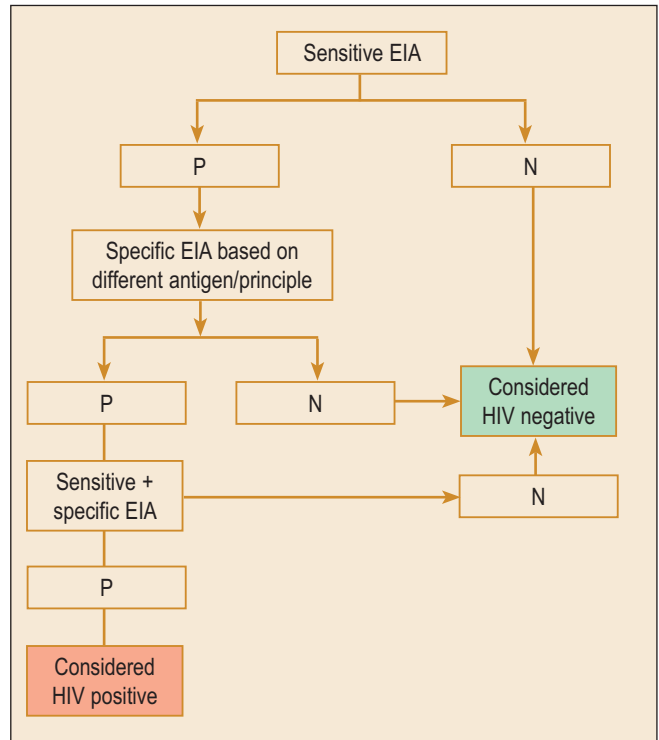


Fig. 15.34. Testing strategy III: done for diagnosis of HIV infection in asymptomatic patients. Done after pretest counseling. P: Positive; N: Negative.

reliable (sometimes even more reliable) information than the ELISA/WB combination and that too at a lower cost.

Confirmatory tests

These tests confirm the presence of virus in an individual who is either positive or has equivocal results to HIV-specific antibodies.

Detection of viral RNA

- ❖ Uses PCR.
- ❖ Is the first test to become positive.
- ❖ Can be modified to quantify the result (expressed as number of viral copies/ml).
- ❖ Expensive and demanding.

Detection of HIV specific core antigen (p24)

- ❖ Detection of p24 antigen is useful in the following situations:
 - *Window period*: detection of p24 antigen is possible before detection of antibodies in 30% of patients.
 - Detection of HIV infection in newborn, because just presence of antibodies in the newborn may be due to transplacental transfer of maternal antibodies.
 - Detection of HIV in CSF.
- ❖ The test is not very sensitive because the antigen is complexed with p24 antibody, but this can be overcome by preliminary acid hydrolysis of the serum sample.

Virus isolation

- ❖ Takes 4–8 weeks for virus isolation.
- ❖ Assay is 100% specific.

- ❖ Sensitivity depends on stage of HIV infection.
- ❖ Labor intensive and dangerous.

Diagnosis of Disease Progression and Complications

The following tests help to guide the initiation of antiretroviral therapy as also prophylaxis/therapy for opportunistic infections:

- ❖ Measurement of number of HIV-RNA copies.
- ❖ CD4+ counts.
- ❖ Tests to rule out:
 - Opportunistic infections.
 - Development of neoplasia.

Treatment

The treatment given to a person infected with HIV depends on the stage of the disease. The treatment options available include:

- ❖ Counseling.
- ❖ Specific treatment.
- ❖ Treatment of opportunistic infections.
- ❖ Treatment of malignancies.

Specific Treatment**Drugs available**

Based on mechanism of action, two classes of antiretroviral drugs are available (Table 15.19).

- ❖ **Reverse transcriptase inhibitors**: Which are of two types:

Table 15.19. Antiretroviral drugs with dosages for adults

Class of drug	Mode of action	Examples	Dose
Reverse transcriptase inhibitors			
Nucleoside group (NRTIs)³⁸	Compete with cellular nucleosides for incorporation into HIV DNA strands	Zidovudine ³⁹ Didanosine (ddl) Zalcitabine (ddc) Stavudine (d4t) Lamivudine (3TC) Abacavir	200 mg tds 125 mg bds 0.75 mg tds 30 mg bds 150 mg bds 300 mg bds
Non-nucleoside group (NNRTIs)⁴⁰	Bind to reverse Transcriptase	Nevirapine Delavirdine Efavirenz	200mg bds 400 mg tds 600 mg ods
Protease inhibitors	Inhibit protease, producing immature defective virus particles	Saquinavir Indinavir Ritonavir Nelfinavir	1200 mg tds 800 mg tds 600 mg bds 750 mg tds

38. **Side effects of NRTIs**: pancreatitis, painful peripheral neuropathy (ddc and d4T), and other side effects include lactic acidosis and skin rash.

39. **Side effects of zidovudine**: bone marrow suppression, gut intolerance, myopathy, fatigue, headache, and pigmentation.

40. **Side effects of NNRTIs**: skin rash, hepatitis, nausea, vomiting, neuropsychiatric side effects.

Table 15.20. Recommended combinations for anti-retroviral agents for initial treatment

NNRTI-based regimens
<i>Preferred regimens</i>
Efavirenz + lamivudine + zidovudine or stavudine (not in women with pregnancy potential)
<i>Alternative regimens</i>
Efavirenz + lamivudine + didanosine (not in women with pregnancy potential)
Nevirapine + lamivudine + zidovudine or stavudine or didanosine
PI-based regimens
<i>Preferred regimen</i>
Lopinavir + ritonavir + lamivudine + zidovudine or stavudine
<i>Alternative regimens</i>
Indinavir + lamivudine + zidovudine or stavudine
Indinavir + ritonavir + lamivudine + zidovudine or stavudine

- Nucleoside reverse transcriptase inhibitors (NRTIs).
- Non-nucleoside reverse transcriptase inhibitors (NNRTIs).

❖ *Protease inhibitors.*

Drug regimens

- ❖ Use of a single drug often results in resistance, so monotherapy should be avoided.
- ❖ Studies using two to three antiretroviral drugs have shown encouraging results (lowering of HIV-RNA to <50 copies/ml, *i.e.*, not detectable).
- ❖ The use of highly active antiretroviral therapy (HAART) involves use of two NRTI along with one NNRTI or PI (Table 15.20).

Table 15.21. Indications for starting antiretroviral therapy

Clinical Manifestations	CD4 counts/ mm ³	Plasma HIV RNA copies/ mm ³	HAART
Asymptomatic	>350	<100,000	Defer
	>350	>100,000	Can be started
	200–350	Any value	Offer HAART
	<200	Any value	Start HAART
Symptomatic HIV disease	Any value	Any value	Start HAART

Indications for antiretroviral therapy

Eradication of HIV infection cannot be achieved with currently available regimens because a pool of latently infected CD4+ cells is established very early in the infection and this persists in the body. However, antiretroviral therapy is helpful because it:

- ❖ Restores immune function.
- ❖ Reduces morbidity and mortality in HIV patients.
- ❖ Improves the quality of life.

HAART can be started as indicated in Table 15.21.

Drugs for Opportunistic Infections

Various regimens have been devised for prophylaxis and therapy of opportunistic infections (Table 15.22).

Table 15.22. Management of opportunistic infection in HIV patients

Infections	Treatment (daily)	Prophylaxis	
		Indications	Drug regimen (daily)
Pneumocystis jiroveci pneumonia	TMP (15 mg/kg) + SMZ (75 mg/kg) × 3 weeks	CD4+ <200/mm ³	TMP (2.5 mg/kg) + SMZ (12.5 mg/kg)
Toxoplasma encephalitis	Sulfadiazine (4–8 g) + Pyrimethamine (200–400 mg) × 6 weeks	Toxoplasma seropositive CD4+ <100/mm ³	Sulfadiazine (2–4 g) + Pyrimethamine (100 mg)
Herpes simplex virus	Acyclovir 400 mg × 5 times × 2 weeks	> 6 recurrences/year	Acyclovir 400 mg bd (suppressive therapy)
Herpes zoster	Acyclovir 800 mg × 5 times × 2 weeks		
M. tuberculosis	Standard therapy Look for MDR tuberculosis ⁴¹		
Candidiasis	Fluconazole 100–200 mg daily × 3 weeks		Fluconazole 150 mg weekly

*TMP–SMZ: trimethoprim–sulfamethoxazole.

41. **MDR tuberculosis:** TB that is resistant at least to isoniazid and rifampicin.

Skin Diseases Caused by Arthropods, Worms, and Protozoa

16

Chapter Outline

Arthropods

- Insect bites[•]
- Paederus dermatitis[•]
- Myiasis[◦]
- Pediculosis[•]
- Scabies[•]

Parasitic Worms

- Filariasis[◦]
- Larva migrans[◦]
- Pinworm infestation[◦]
- Cysticercosis[◦]

Protozoal Diseases

- Leishmaniasis[•]

Skin Diseases Due to Arthropods

Introduction

Cause

Several arthropods can affect skin in different ways (Table 16.1).

Table 16.1. Skin changes caused by arthropods

Arthropods	Manifestations
Insects	
Mosquitoes	Bites
Bed bugs	Bites
Fleas	Bites
Beetles	Paederus dermatitis
Flies	Myiasis
Bees, wasps, ants	Stings, bites
Butterflies	Caterpillar dermatitis
Lice	Infestation
Mites	
<i>Sarcoptes scabiei</i>	Scabies
<i>Demodex folliculorum</i>	Normal inhabitant of hair follicles on face
Food mites	Grain itch, grocer's itch
Harvest mites	Harvest itch
House dust mite	? Role in atopic eczema and asthma
Ticks	
	Tick bites
	Vector-borne diseases like rickettsial infections and erythema migrans

Pathogenesis

Arthropods cause skin diseases by different pathogenic mechanisms (Table 16.2).

[•]Should know
[◦]Good to know

Table 16.2. Pathogenesis of skin diseases caused by arthropods

Infestation	When arthropod lives on the skin
Irritation	When arthropod bites. Or when body fluids of arthropod irritate the skin
Hypersensitivity	When skin immunologically reacts to either the bite/sting of arthropod or presence of arthropod in skin.

Insect Bite Hypersensitivity (IBH)

Etiology

- ❖ Causative insect varies from region to region and includes mosquitoes, bugs, fleas, *etc.*
- ❖ When an insect bites, the skin reaction could be due to:
 - *Pharmacologically active substances*: chemicals like histamine and proteases injected by arthropods cause immediate reaction.
 - *Antigens*: cause a delayed immunological reaction.
 - *Microorganisms*: introduced into the skin during the bite or due to scratching may result in:
 - Pyoderma.
 - Vector-borne diseases.
- ❖ **Predisposing factors**:
 - Most frequently seen in children, who generally outgrow the hypersensitivity in a few years.
 - Also seen in patients with reticuloendothelial malignancies, those on chemotherapy and HIV-positive patients.

Clinical Features

Onset

Lesions appear in recurrent crops, most frequently in summer and rainy season.

Morphology

- ❖ **Prototype lesion**: Is called **papular urticaria** which has two components:
 - *Immediate reaction*:
 - Is due to direct action of pharmacologically active substances injected.
 - A wheal (Fig. 16.1A) which appears within a few minutes of insect bite.
 - Lasts few minutes—couple of hours. May evolve into a papule.

- *Delayed reaction*:

- Is due to hypersensitivity to injected antigens.
- A firm, itchy, persistent papule, surmounted by a vesicle or a hemorrhagic crust (Fig. 16.1B) develops in about 24 h.
- Lasts for a few days and heals with barely perceptible scar, which has a hyperpigmented areola.

- ❖ **Variants**:

- *Bullous papular urticaria*:

- Seen in children.
- Frank vesicles and bullae, which frequently get secondarily infected.
- Most frequently occur on legs.

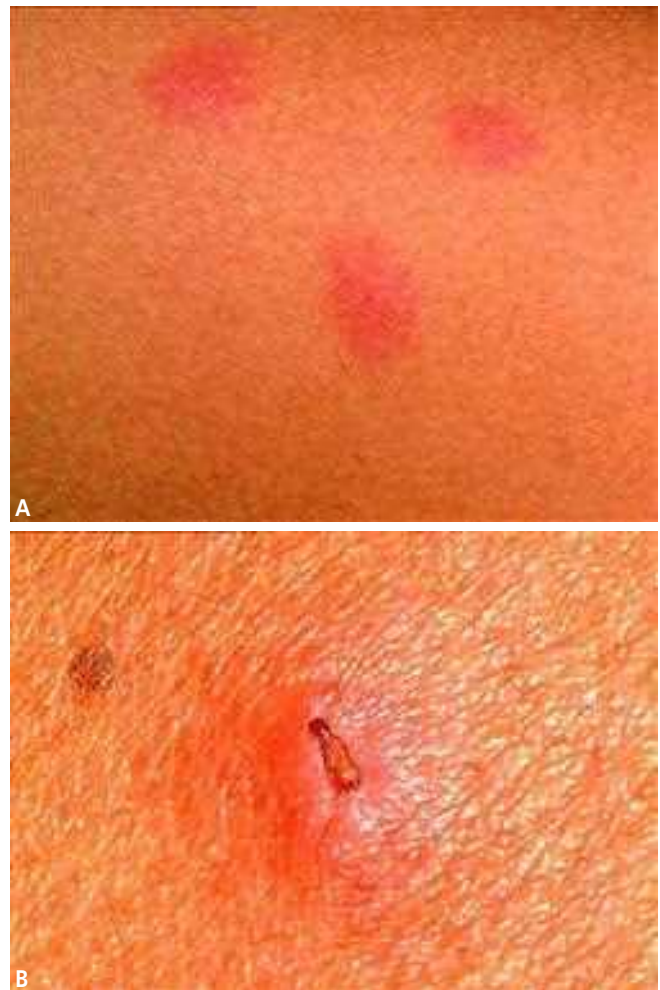

Fig. 16.1. Insect bite hypersensitivity: A: wheal appears within a few minutes. B: persistent papule with elongated hemorrhagic crusts at site of bite on the lower extremity.

➤ *Bed bug bites:*

- Wheals, which evolve into firm, grouped papules. And linear purpuric lesions.
- Usually on covered parts of the body like trunk (*cf.*, insect bites, which occur on exposed parts).

Sites

Exposed parts, especially arms, legs, and sometimes face.

Complications

Secondary infection is frequent.

Diagnosis

Points for diagnosis

Diagnosis of insect bite hypersensitivity (IBH) is based on:

- ❖ Aggravation of lesions during summer.
- ❖ Itchy persistent papules surmounted with a vesicle/central punctum/hemorrhagic crust.
- ❖ Presence of lesions on exposed parts.

Differential diagnosis

IBH and papular urticaria should be distinguished from:

a. Scabies

Scabies	IBH
Age: any age	Children; if adults, rule out underlying neoplastic disease or HIV infection
Morphology: burrows pathognomonic. Other lesions include papules, vesicles	Papule surmounted with vesicle or hemorrhagic crust
Distribution: webs of fingers, wrists, periumbilical area and genitalia, thighs	Exposed parts
Family history: present	Absent

b. Atopic prurigo

Atopic prurigo	IBH
Age: usually adults	Children; if adults, rule out underlying neoplastic disease or HIV infection
Morphology: pruritic papulonodules	Papule surmounted with vesicle or hemorrhagic crust
Distribution: typical distribution	Exposed parts
Other features: of atopic dermatitis.	–
Family/self-history of atopy: is often present.	Not relevant

Treatment

- ❖ Protection from insect bites by:
 - Keeping body covered.
 - Insect repellents and insecticides: insecticides may need to be used on walls and furniture because during the day, the insects hide in crevices in walls and in joints of furniture.
 - Treating infested domestic animals appropriately.
- ❖ Topical steroid-antibiotic combination.
- ❖ Oral antihistamines.
- ❖ Systemic antibiotics, if secondary bacterial infection is present.

Paederus Dermatitis

Etiology

- ❖ Beetles do not bite or sting, but their bodies contain chemicals which can induce blistering of skin.
- ❖ These chemicals are:
 - Either squirted out by the beetle.
 - But more frequently exudes out, when the beetle is crushed against the skin.

Clinical Features

- ❖ Manifests typically as bizarre linear vesicles and sterile pustules on an erythematous skin. A characteristic feature of the lesions is “**kissing or touching lesions**” due to crushing of the beetle (Fig. 16.2). Subside with hyperpigmentation.
- ❖ Exposed parts, *e.g.*, face and cubital fossae.

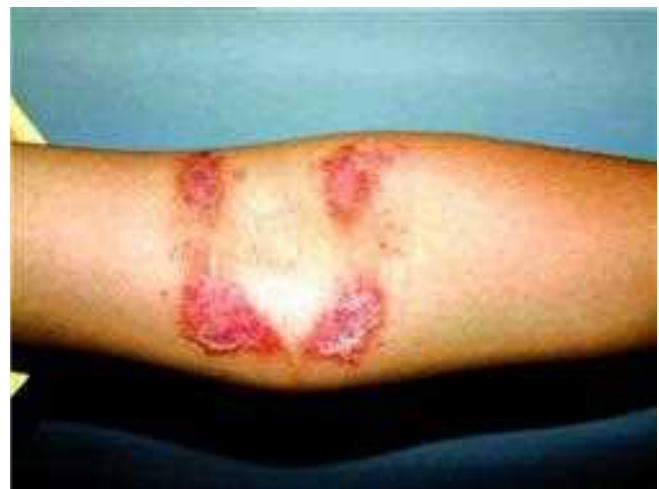

Fig. 16.2. Paederus dermatitis: kissing lesions on cubital fossa.

Treatment

- ❖ Washing affected area immediately after contact reduces blistering.
- ❖ Symptomatic treatment with topical steroid-antibiotic combination hastens recovery and prevents pigmentation and scarring.
- ❖ Single dose of oral steroids (prednisolone, 40 mg equivalent, in an adult) may reduce chances of sequelae in lesions on the face.

Myiasis

Myiasis is infestation of body tissues of humans and animals by maggots (larvae) of *Diptera* (flies).

Etiology

- ❖ Larvae of some species of flies (*Diptera*) develop in normal/injured tissues.
- ❖ **Predisposing factors:** Wounds, traumatic, or surgical.

Clinical Features

Two forms of myiasis recognized:

- ❖ **Traumatic/wound myiasis:** Seen as a complication of neglected suppurating wounds. The eggs and moving larvae are seen in foul smelling wounds.
- ❖ **Furuncular myiasis:** The skin lesions look like boils but movement of larvae can be appreciated. Diagnosis is proved by incising the nodule and extracting the larva.

Treatment

- ❖ Applying chloroform or ether (to anesthetize the larvae) and mechanically removing anesthetized larvae. Also topical or systemic ivermectin.
- ❖ Antibiotic therapy (including metronidazole to cover anaerobes) because the lesions are invariably secondarily infected.

Pediculosis (Louse Infestation)

Synopsis

Etiology: Two species: *Pediculus humanus capitis* (causing scalp infestation), *Pediculus humanus corporis* (causing body and clothing infestation), and *Phthirus pubis* (causing infestation of pubic area, axillae, and eyelashes).

Epidemiology: *Prevalence:* Pediculosis extremely common. *Transmission:* Direct contact. Fomites less important. *P. pubis* also sexually.

Clinical features: Itching universal. Secondary infection, eczematization. *P. capitis:* Look for nits in scalp. *P. corporis:* Look for nits, louse in seams of clothes. *P. pubis:* Look for nits, louse in pubic region, axillae.

Treatment: Permethrin 1% is the treatment of choice. Others include gamma benzene hexachloride 1%.

Introduction

- ❖ Lice are flat, wingless blood-sucking insects, which live as parasites on hairy skin. Their eggs (called **nits**) are attached to hair (of scalp and other parts of body) or seams of clothing.
- ❖ Two species of louse are obligate parasites in man:
 - *Pediculus humanus* (with its two varieties, *P. humanus capitis*, the head louse and *P. humanus corporis*, the body louse).
 - *Phthirus pubis* (pubic louse).
- ❖ All louse infestations characterized by severe itching. Often complicated by secondary infection and eczematization.

Pediculosis Capitis

Etiology

P. humanus capitis, measures 3–4 mm in length, is gray and is flattened dorsoventrally.

Epidemiology

- ❖ **Prevalence:** Very common. Affects 50% of human race.
- ❖ **Age:** Affects children more than adults.
- ❖ **Transmission:** Spreads by:
 - Head-to-head contact.
 - And through fomites (shared combs).

Clinical features

Symptoms

- ❖ Severe itching, initially around the sides and back and then all over the scalp.
- ❖ Patient may complain of crusted lesions on the scalp, due to secondary infection and eczematization.

Signs

- ❖ Adults of lice are difficult to find in the scalp. Nits are easily seen, especially in the occipital area. They are attached firmly to the hair shafts (*i.e.*, cannot be flicked off) on which they can be freely glided (Fig. 16.3).



Fig. 16.3. Pediculosis capitis: nits attached to hair shaft.

Complications

- ❖ Secondary infection is frequent. In heavy infestation, hair may become matted and there is foul smelling discharge. As a rule, in all patients with recurrent pyoderma of scalp, pediculosis should be ruled out.
- ❖ Occipital lymphadenopathy, often persistent even after disinfestation.

Diagnosis

Points for diagnosis

Diagnosis of pediculosis capitis is based on:

- ❖ Presence of nits. Most easily seen in the occipital area. Nits need to be differentiated from scales. Scales can easily be flicked off the hair while nits can be glided along the length of the hair.
- ❖ Futile to look for adults.

Treatment

❖ Specific measures:

- *Drugs used:*

- *Permethrin*, 1%: effective against nits and adults.
- *Gamma benzene hexachloride (GBH)*, 1%: effective against nits, larvae, and adults.
- *Benzyl benzoate*, 25%: effective against larvae and adults.
- *Malathion*, 0.5%: Has residual effect and prevents reinfestation.

➤ Applications:

- Overnight application for benzyl benzoate and malathion. Repeat after 7 days.
- Short contact rinse (10–15 min) with permethrin and GBH.

➤ Problems with treatment:

- Resistance to benzyl benzoate and GBH is known.
- Except for malathion, no residual effect. As reinfestation common, repeat treatment necessary.

❖ Other measures:

- A fine toothed comb helps to remove empty cases of nits, after treatment.
- Important to treat contacts.

❖ Treatment of complications:

- Systemic antibiotics to treat secondary infection.
- Occasionally, matting is so severe that hair has to be clipped.

Pediculosis Corporis

Uncommon infestation.

Etiology

- ❖ *P. humanus corporis*. Resembles head louse except for being larger and lays its eggs in the seams of clothing.
- ❖ **Transmission** via infested bedding or clothing.
- ❖ **Predisposing factors:**

- Poor hygiene.
- Social deprivation.
- Mental retardation.
- Unhygienic, socially deprived (so called **Vagabond's¹ disease**), and mentally challenged.

Clinical features

Symptoms

- ❖ Severe and widespread itching on the trunk.
- ❖ Pus discharge and eczematization.

1. **Vagabond:** leading an unsettled, irregular or disreputable life; good for nothing.

Signs

- ❖ Self-neglect is striking.
- ❖ Linear excoriations often covered with hemorrhagic crusts.
- ❖ Secondary infection and eczematization frequent. Persistent pigmentation and lymphadenopathy sometimes seen in chronic cases.
- ❖ Nits (frequently) and adults (less frequently) are found on the inner seams of clothings.

Investigations

Inner seams of clothings should be examined for presence of nits and adults.

Diagnosis

Pediculosis corporis should be differentiated from:

a. Scabies

Scabies	Pediculosis corporis
<i>Morphology:</i> burrows pathognomonic. Other lesions include papules and vesicles	Linear excoriations often covered with hemorrhagic crusts. Nits and adults in seams of clothes
<i>Distribution:</i> webs of fingers, wrists, periumbilical area, and genitalia	Trunk

b. Others: Like endogenous eczema and pruritus due to internal malignancies.

Treatment

- ❖ Treatment of the infested clothing and bedding by tumble drying, by high temperature laundering, and by dry cleaning (kills both adults and nits). Ironing of seams is a cost-effective alternative.
- ❖ **Specific treatment:** 1% GBH lotion or permethrin 1% cream applied for 8–10 h, after treatment of infection and eczema.
- ❖ **Treatment of infections/eczema:** Antibiotics and topical steroids.

Pubic Lice**Etiology**

Phthirus pubis (pubic louse or crab louse) is broader than scalp and body louse and its second and third pairs of legs are modified to cling on to hair (Fig. 16.4A).

Transmission

- ❖ **Sexual and direct transmission:** Commonly in young adults, spreading most extensively in hairy males.

- ❖ **Fomite transmission:** From contaminated “clothing”, towels and bedding.

Clinical features

- ❖ Severe itching in the pubic area; patient may even have seen the louse.
- ❖ **Morphology:**
 - Shiny, translucent nits are less easily recognized than nits of the head louse, but the adults are frequently seen as yellowish-brown specks clinging close to the base of the hair (Fig. 16.4B).

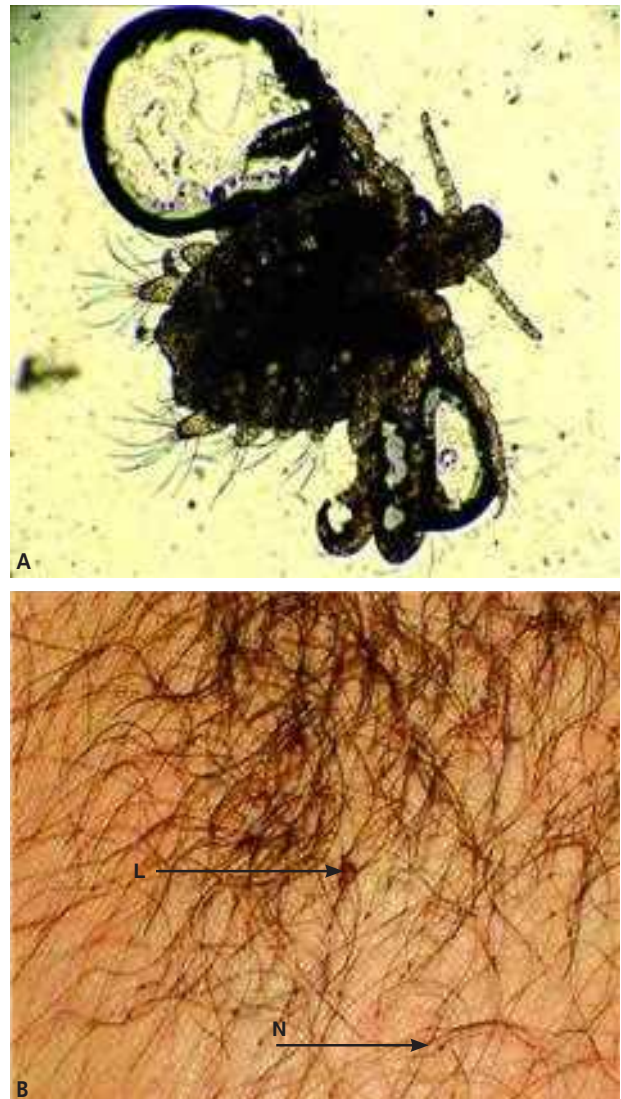


Fig. 16.4. Pediculosis pubis: A: *Phthirus pubis* (pubic louse or crab louse) is broader than scalp and body louse and its second and third pairs of legs are modified to cling on to hair. B: louse (L) attached to skin and nits (N) to hair.

- Excoriations along with small blue-grey macules (**maculae ceruleae**) of altered blood develop at site of bites on the trunk.
- ❖ **Sites of predilection:** Pubic region, thighs, axillae, and even eyelashes².
- ❖ **Complications:** Secondary infection and eczematization.

Diagnosis

Points for diagnosis

Diagnosis of pediculosis pubis is based on:

- ❖ Severely itchy dermatosis.
- ❖ Presence of yellow-brown specks (adult louse), close to the hair in the pubic region, thighs, and axillae. Nits may also be seen.

Investigations

Rule out co-existing sexually transmitted diseases.

Treatment

- ❖ Shaving the area is not necessary.
- ❖ Affected areas³ should be treated with:
 - Permethrin, 1% rinse.
 - GBH, 1% lotion.
 - Malathion, 0.5% solution.
- ❖ Treatment should be repeated after one week and infected sexual partners should also be treated.

Scabies

Synopsis

Etiology: *Sarcoptes scabiei*; spreads by prolonged and intimate contact.

Morphology: Burrow (thin, serpentine lesion) is characteristic lesion. Papulovesicles and nodules.

Site: Webs, wrists, ulnar aspect of forearms, breasts, scrotum, and penis. Face, soles, and palms spared in adults but characteristically involved in infants.

Complications: Secondary pyoderma and eczematization.

Treatment: Permethrin 5%, gamma benzene hexachloride 1%, benzyl benzoate 25%; single application of the first two medications while three applications of the last. Ivermectin, single oral dose.

Etiology

- ❖ Usually caused by *Sarcoptes scabiei var hominis*, an acarus (mite) specific for humans.
- ❖ Rarely caused by animal mite.

Transmission

- ❖ Intimate prolonged contact, e.g., as within the household.
- ❖ Sexual transmission important, in sexually active individuals.
- ❖ Fomite transmission⁴ (clothing and bedding) may occur but unimportant.

Pathogenesis

- ❖ Once on the skin, mites burrow through the stratum corneum and copulation occurs in the burrow.
- ❖ Each female mite lays 40–50 eggs during life span of 4–6 weeks.
- ❖ Eggs hatch in 3–4 days, the larvae leave the original burrow to make a new home.
- ❖ The number of mites normally present in an individual patient varies, being less than 7–8 in an adult. Most lesions in scabies are due to hypersensitivity.

Epidemiology

- ❖ **Age:** Though it can occur at any age, scabies is essentially a disease of children. There is a decreasing prevalence with advancing age.
- ❖ **Sex:** No gender predilection.
- ❖ **Predisposing factors:**
 - Lower socioeconomic strata, crowding, and poor hygiene.
 - Immunosuppression predisposes to Norwegian scabies.

Clinical Features

Symptoms

- ❖ Asymptomatic for the first 4 weeks.
- ❖ Severe itching, “worse at night”. Similar symptoms may be present in several family members/close contacts.

Morphology

Primary lesions

Two types of primary lesions are seen:

- ❖ **Burrows:**
 - Is the pathognomonic lesion of scabies but may be difficult to discern in dark-skinned patients.

2. **Eye lashes:** head louse does not descend to the lashes but the pubic louse ascends to them.

3. **Affected areas:** best to treat all areas which can be affected—pubic region, thighs, and axillae.

4. **Fomite transmission:** overemphasized and hyped up, resulting in over zealous (albeit unnecessary) recommendation of vigorous laundering of linen and clothes.

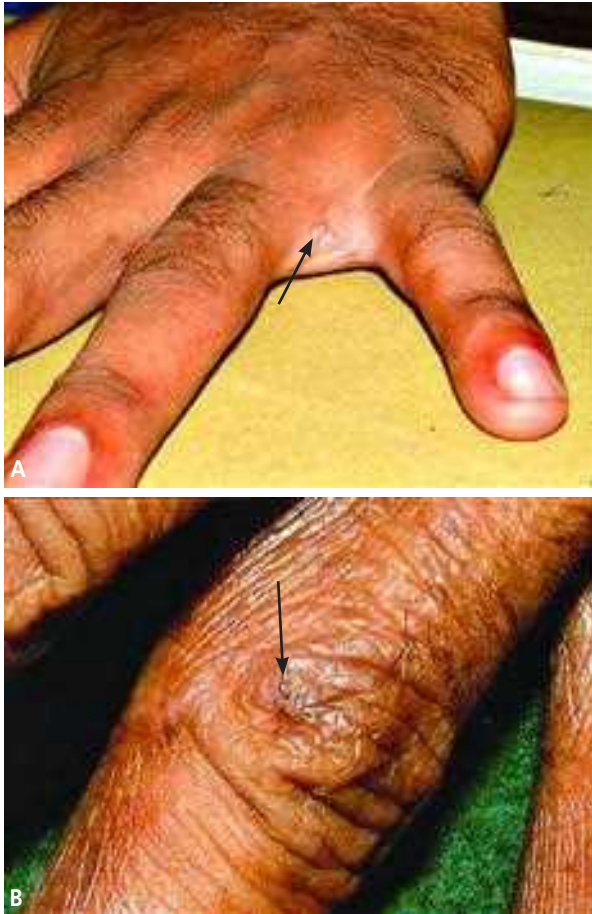

Fig. 16.5. A: Scabies: presents as lesions at characteristic sites. B: burrow, presents as a curvilinear lesion, often difficult to discern in a dark skinned.

➤ Appears as a serpentine, thread-like, grayish or darker line, varying in length from a few mm to a cm. The open end is marked by a papule (Fig. 16.5A and B).

❖ **Papules and papulovesicles:** Are due to hypersensitivity to the mite and appear as small erythematous papules or papulovesicles, which may be excoriated.

Secondary lesions

❖ **Pustules:** Pustular lesions, due to secondary infection, at the characteristic sites is one of the commonest presentations.

❖ **Eczematized lesions:** In infants and children, the predominant lesions are eczematized and crusted (Fig. 16.6).

❖ **Nodular lesions:** Persistent nodular lesions are seen on the scrotal and penile skin, anterior axillary folds, and in groins (Fig. 16.7A and B).

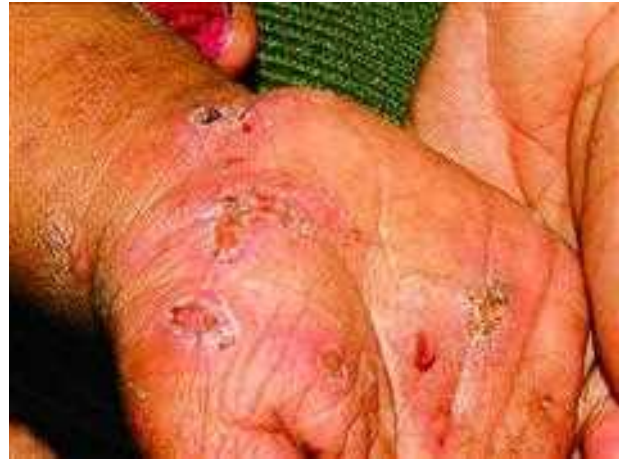

Fig. 16.6. Scabies in infant: multiple papulovesicular lesions on palms. Many lesions eczematous.

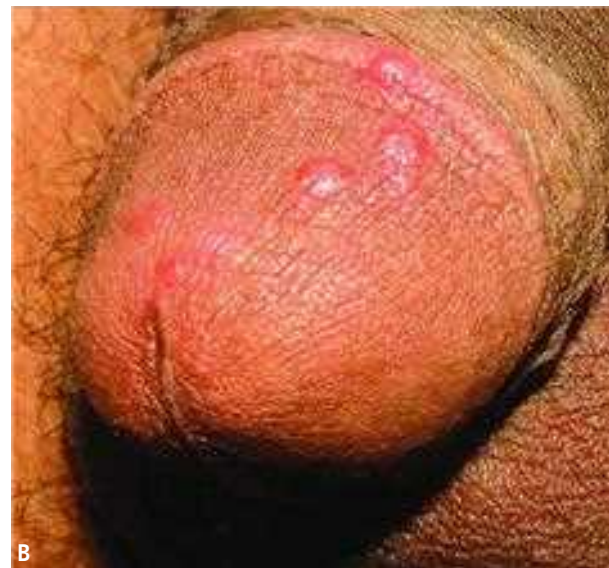
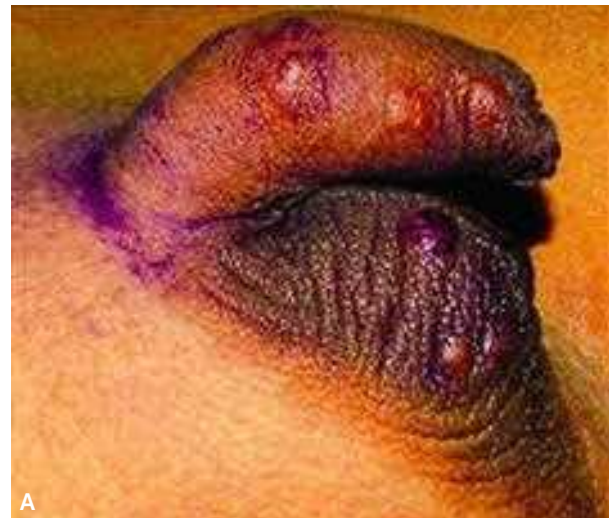
Fig. 16.7. Scabies: A: nodular lesions of genitalia. B: nodules on glans.

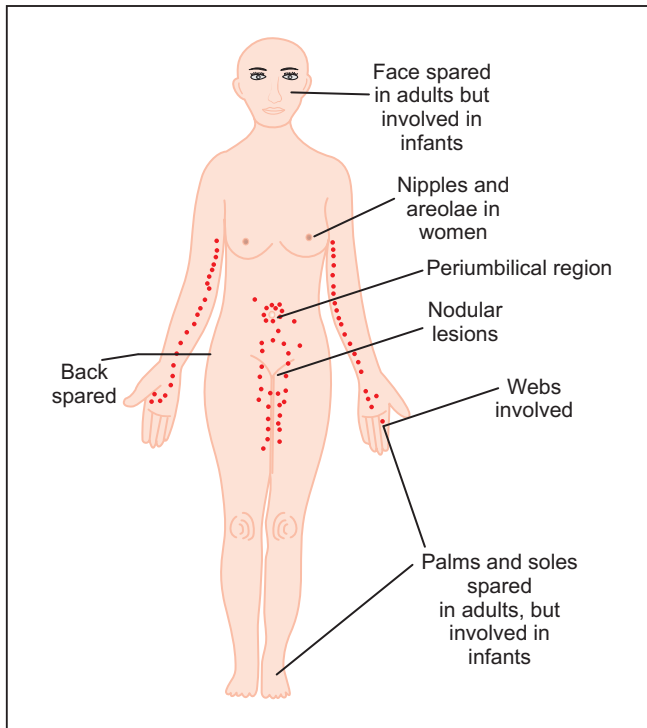


Fig. 16.8. Scabies: distribution of lesion.

Sites of predilection

The distribution of lesions of scabies is pathognomonic (Fig. 16.8).

❖ Adults

- **Sites involved:** webs of fingers, flexural aspects of wrists, ulnar aspect of forearms, anterior axillary folds, umbilicus and periumbilical region, genitalia and upper thighs, lower part of buttocks, and natal cleft are common sites of involvement. Nipples and areolae are involved in women.
- **Sites spared:** in uncomplicated scabies in adults, the scalp, face, palms, and soles are characteristically spared and the back only minimally involved.

❖ **Infants:** Apart from the above sites, scalp, face, palms, and soles are typically involved in infants.

Variants

Norwegian or crusted scabies

- ❖ Seen in immunocompromised patients (with lymphoreticular or other malignancies, HIV infection, and those on immunosuppressives) and those who are mentally challenged.
- ❖ Characterized by the presence of widespread

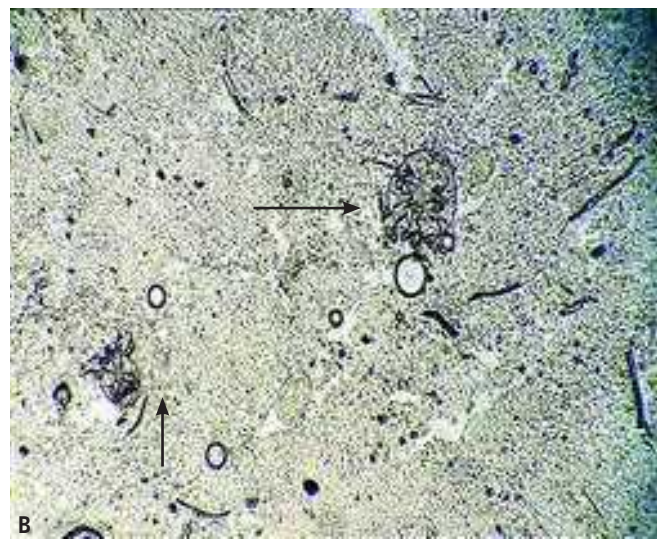
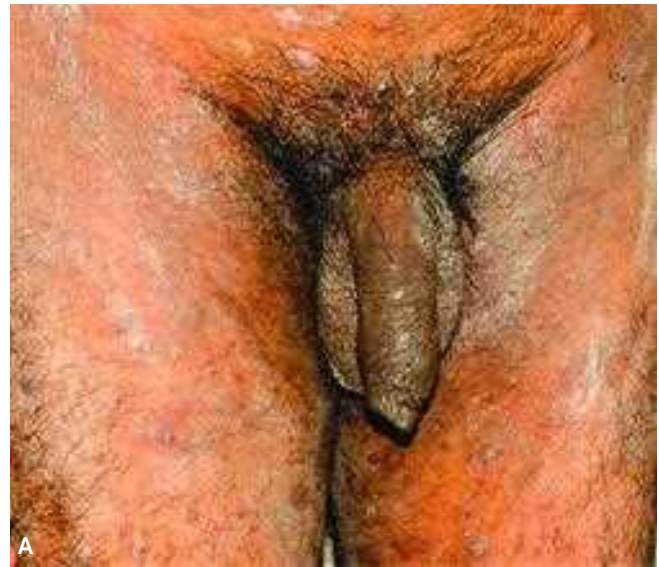
Fig. 16.9. Norwegian scabies: A: crusted, hyperkeratotic lesions in an HIV-positive patient. B: potassium hydroxide mount showing multiple mites.

crusted and hyperkeratotic lesions (Fig. 16.9A) teeming with innumerable mites (Fig. 16.9B).

❖ May cause epidemics of ordinary scabies in contacts because of high load of mites.

Complications

- ❖ Secondary infection with *S. aureus* and *Strep. pyogenes* is frequent.
- ❖ Acute poststreptococcal glomerulonephritis following streptococcal pyoderma in scabies is not uncommon (about 10%).
- ❖ Eczematization is a frequent in infants.

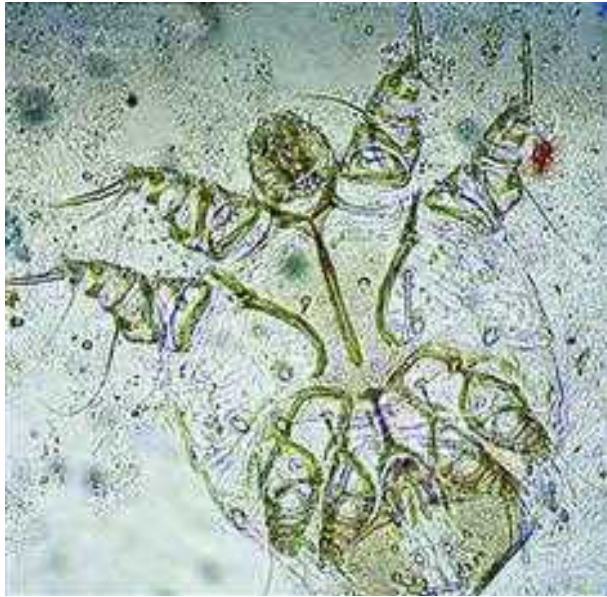


Fig. 16.10. *Sarcoptes scabiei* var *hominis*: adult mite.

Investigations

- ❖ Usually none are required.
- ❖ **Identification of acarus:** Mite can be picked up from the end of a burrow or a papule. Scrapings so made are mounted in potassium hydroxide and the mite visualized (Fig. 16.10).

Diagnosis

Points for diagnosis

Diagnosis of scabies is made on the basis of:

- ❖ Intensely itchy eruption, itching being worse at night.
- ❖ History of similar itchy eruption in close contacts.
- ❖ Presence of burrow (thread-like serpentine lesion), especially in web spaces and on penis. Nodular lesions on scrotum and penile shaft.
- ❖ Characteristic distribution of lesions; sparing of face, palms, and soles in adults but not in infants.

Differential diagnosis

Scabies should be differentiated from:

a. Infantile or atopic eczema

Infantile eczema	Scabies
Palms and soles spared, though may show hyperlinearity	Papulovesiculation on palms and soles
History of atopy	Not relevant
Family members give history of atopy	Close contacts have typical lesions of scabies

b. Animal scabies:

Similar itchy eruption.

Animal scabies	Human scabies
Burrows: absent	Present
Family history: absent	Close contacts have typical lesions of scabies
Other history: history of contact with animals	Not relevant

c. Insect bite hypersensitivity (P. 337)

d. Pediculosis corporis (P. 340)

Treatment

General principles

- ❖ Give a printed sheet with clear-cut instructions to the patient, because success of therapy depends on correct application of medication.
- ❖ Scabicides should be applied effectively to the whole body (below the jaw line in adults) including genitals, soles of feet and skin under the free edge of the nails. Should be reapplied on hands, if washed.
- ❖ Treat all members of the family simultaneously, even if asymptomatic.
- ❖ Ordinary laundering is adequate for bed linen. All clothing need not be treated because the mites anyway die in unworn clothes in about 7 days.
- ❖ Itching may last for several days and does not require retreatment with scabicides. Symptomatic treatment with antihistamines is usually adequate.

Specific treatment (Table 16.3)

Table 16.3. Use of scabicides

Scabicide	Method of use	Comments
Permethrin, 5%	One application of 8–12 hours	Scabicide of choice
Benzyl benzoate, 25%	Three applications, at 12 hourly intervals	Irritation
Gamma benzene hexachloride, 1%	One application	<ul style="list-style-type: none"> ❖ Seizures (so avoid in those with seizures) ❖ Avoid in infants, as large surface area, so greater absorption ❖ Resistance
Crotamiton, 10%	Two applications daily × 14d	<ul style="list-style-type: none"> ❖ Useful in children ❖ Mild antipruritic
Precipitated sulphur, 10%	Two applications daily × 14d	❖ Useful in children
Ivermectin	Single oral dose 200 µg/kg body weight. Repeat after 2 weeks	Indicated in: <ul style="list-style-type: none"> ❖ Epidemics in orphanages ❖ Norwegian scabies

Parasitic Worms

Filariasis (Lymphatic Elephantiasis)

Etiology

- ❖ Caused by infestation with filarial worms *Wuchereria bancrofti* (most frequent), *Brugia malayi*, and *Brugia timori* (less frequent).
- ❖ Mosquitoes are vectors for human-to-human transmission of microfilaria, which circulates in peripheral blood at night.
- ❖ Adult filarial worms inhabiting the lymphatics and lymph nodes incite an inflammatory response leading to obstruction and subsequent clinical manifestations.

Clinical Features

- ❖ Fever and recurrent lymphangitis, lead to lymphatic obstruction.
- ❖ Lymphedema, usually of the legs, scrotum, and vulva.
- ❖ Secondary cutaneous changes (Fig. 16.11A) in the form of elephantiasis, hypertrophic, and verrucous skin with redundant skin folds, which may show fissuring, maceration, and ulceration in late cases with massive lymphedema.

Treatment

- ❖ Diethylcarbamazine is the treatment of choice.
- ❖ Ivermectin, as a single dose.
- ❖ Lymphedema may need surgical intervention.

Larva Migrans (Creeping Eruption)

Etiology

- ❖ Larva of hookworm is most frequent cause.
- ❖ Normally, larva goes through its life cycle in cats and dogs but may occasionally penetrate skin of humans (act as aberrant hosts) especially of children walking barefoot on soil contaminated with feces of these animals.

Clinical Features

- ❖ Itchy or painful, serpiginous erythematous lesions, which move at the rate of a couple of mm a day.
- ❖ Excoriations and impetiginization are frequent.
- ❖ Eruption is self-limiting because the larva eventually dies.

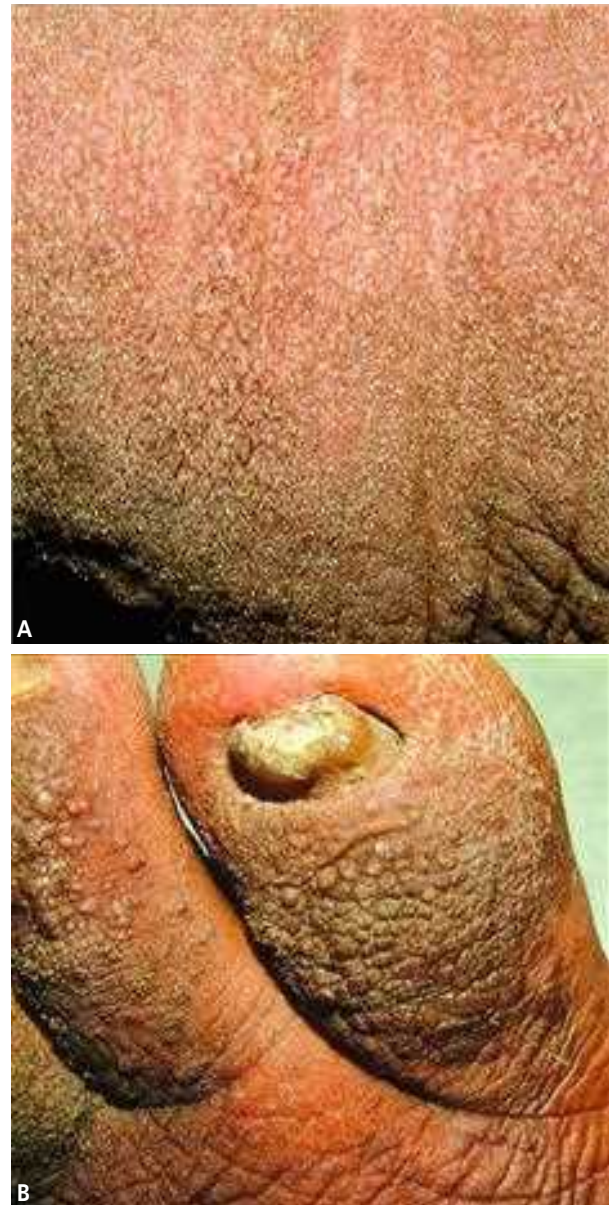


Fig. 16.11. Filarial lymphedema: A: in late stages, hypertrophic and verrucous skin with redundant skin folds. B: close up.

Treatment

The death of the larva can be hastened by:

- ❖ Systemic ivermectin (single dose) or albendazole (for 3 days).
- ❖ Topical 10% thiabendazole (prepared extemporaneously).

Pinworm Infestation

- ❖ Severe nocturnal perianal itch and in female patients vulval pruritus.

- ❖ Scratching may lead to secondary eczematization and bacterial infection.
- ❖ Treat with single dose of secnidazole.

Cysticercosis

- ❖ Due to larval stage of pork tapeworm.
- ❖ Multiple, elongated, firm nodules in the skin.
- ❖ May be associated with seizures due to intracranial lesions.
- ❖ Treatment with praziquantel.

Protozoal Diseases

Leishmaniasis

Synopsis

Etiology: Protozoa, belonging to genus *Leishmania*. Spread by sandfly.

Cutaneous leishmaniasis: On “bite prone” exposed areas. Asymptomatic, edematous, deeply erythematous nodules. Ulcerate and heal with scarring.

Mucocutaneous leishmaniasis: Edematous, erythematous cutaneous plaques, which spread to involve mucosae; cutaneous lesions heal spontaneously but mucosal lesions persist.

Post kala-azar dermal leishmaniasis (PKDL): Occurs 1–5 years after kala-azar (untreated and even incompletely treated). Manifests as juicy nodules, hypopigmented macules and photosensitivity.

Diagnosis: Tissue smear; serology.

Treatment: Sodium stibogluconate injections (intralesional for cutaneous variety and intramuscular or intravenous for PKDL). Miltefosine promising new oral drug for PKDL.

Etiology

Etiological agent(s)

Leishmaniasis is caused by intracellular protozoa belonging to genus *Leishmania* (Table 16.4).

Transmission

Human-to-human transmission takes place through bite of infected sand flies (Table 16.4).

Clinical Features

The different manifestations include:

- ❖ Cutaneous leishmaniasis.
- ❖ Diffuse cutaneous leishmaniasis.
- ❖ Mucocutaneous leishmaniasis.
- ❖ Post kala-azar dermal leishmaniasis.

Table 16.4. Leishmaniasis: etiological agents, vector and diseases caused

Etiological agent	Vector	Cutaneous Manifestation
<i>Leishmania major</i> <i>Leishmania tropica</i>	<i>P. papatasi</i>	Cutaneous leishmaniasis
<i>Leishmania aethiops</i>	<i>P. sergenti</i>	Disseminated cutaneous leishmaniasis
<i>Leishmania braziliensis</i>	<i>Lu. umbratilis</i>	Mucocutaneous leishmaniasis
<i>Leishmania donovani</i>	<i>Phlebotomus argentipes</i>	Post kala-azar dermal leishmaniasis

Cutaneous leishmaniasis (oriental sore)

- ❖ Incubation period varies from weeks to months.
- ❖ Acute cutaneous leishmaniasis:
 - Frequently occurs on face and hands.
 - Asymptomatic, solitary (usually) edematous and erythematous nodule (Fig. 16.12), which ulcerates (referred to as **crateriform ulcer**⁵) and ultimately heals (within 2 years) with a depressed scar.
- ❖ Chronic leishmaniasis.
 - Lesions last longer than 2 years.
 - Do not usually ulcerate.

Mucocutaneous leishmaniasis

- ❖ Seen in Brazil.
- ❖ Starts on the skin as edematous, erythematous plaques, which secondarily involve nasal mucosa after several years.

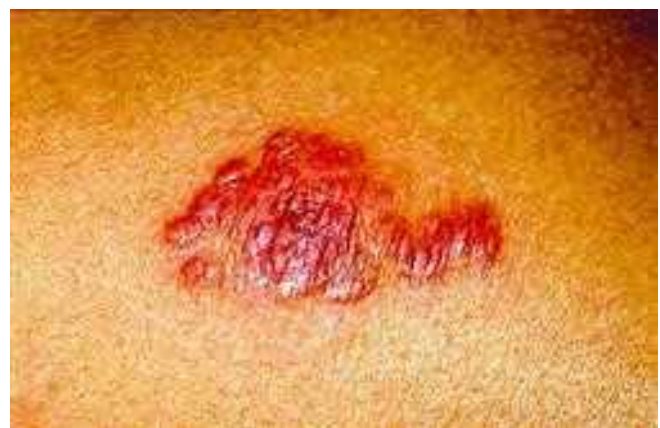

Fig. 16.12. Cutaneous leishmaniasis: asymptomatic, edematous and erythematous nodule.

5. **Crateriform ulcer:** due to resemblance to crater of volcano when seen from above.

- ❖ Cutaneous lesions heal with scarring while the mucosal lesions show no tendency to spontaneous healing and may extend into the nasopharynx causing mutilation.

Post kala-azar dermal leishmaniasis (PKDL)

- ❖ Endemic in Bihar (India), Sudan (Africa).
- ❖ Late cutaneous manifestation (1–5 years later) after untreated or incompletely treated kala-azar (visceral leishmaniasis).
- ❖ Characterized by presence of three types of skin lesions:
 - Erythematous juicy nodules on the central part (periorificial area) face (Fig. 16.13A).

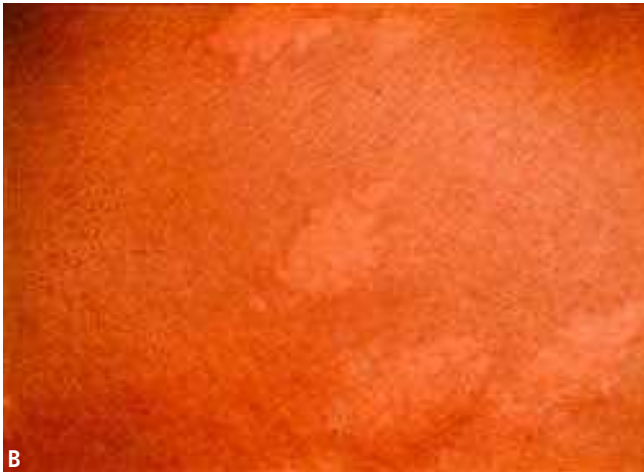
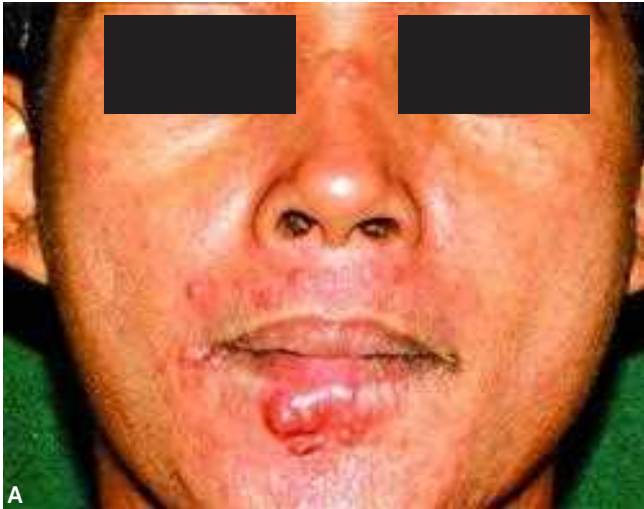
Fig. 16.13. Post kala-azar dermal leishmaniasis: A: infiltrated erythematous nodules on the central part of the face. B: infiltrated hypopigmented macules on the trunk.

- Hypopigmented macules on the trunk (Fig. 16.13B).
- Photosensitivity.

Investigation

Demonstration of organisms

- ❖ Specimen taken using a tissue smear preferably a nodule/plaque.
- ❖ Stained with Giemsa stain or accridine orange.

Serology

- ❖ Antibodies to RK 39.

Diagnosis

Cutaneous leishmaniasis

Points for diagnosis

Diagnosis of cutaneous leishmaniasis is based on:

- ❖ Presence of solitary edematous nodule often with crateriform ulcer, which heals spontaneously with scarring.
- ❖ Lesions on exposed parts (bite-prone areas).

Differential diagnosis

Cutaneous leishmaniasis (CL) should be differentiated from:

a. *Lupus vulgaris* (LV)

LV	CL
Course: chronic	Self-healing
Morphology: annular plaque(s) with nodules and central scar. Nodules may develop in scars.	Very edematous nodule with dusky erythema
Sites: face, buttocks	Bite-prone areas

PKDL

Points for diagnosis

Diagnosis of PKDL is based on:

- ❖ History of kala-azar in the past (1–5 years ago)/ living in endemic area.
- ❖ Presence of “juicy” erythematous nodules on the central part of the face.
- ❖ Hypopigmented macules on the central part of the trunk.
- ❖ No nerve involvement

Differential diagnosis

PKDL should be differentiated from:

a. Borderline lepromatous (BL) and lepromatous leprosy (LL)

BL/LL	PKDL
<i>History:</i> sensory deficit and reactions	Kala-azar in past
<i>Macules:</i> atrophic hypopigmented macules all over the body	Hypopigmented macules on central part of trunk
<i>Nodules:</i> erythematous nodules on the body and face	Erythematous nodules on the central part of the face
<i>Facial lesions:</i> facial and ear lobe infiltration characteristic. Lateral madarosis	Not characteristic
<i>Nerves:</i> thickened/tender ± motor and sensory deficit	Not involved

Treatment

Cutaneous leishmaniasis

- ❖ **Sodium stibogluconate:** Given intralesionally.
- ❖ **Other drugs:** Ketoconazole and rifampicin.

Post kala-azar dermal leishmaniasis

- ❖ **Sodium stibogluconate:** Up to 120 injections in dose of 20 mg/kg body weight intravenously or intramuscularly. Resistance reported, and such patients treated with amphotericin.
- ❖ **Miltefosine:** Oral antileishmania drug, given as 100 mg daily.
- ❖ **Others:** Ketoconazole and rifampicin.

Nevi and Skin Tumors

17

Chapter Outline

Introduction

Definitions

Etiogenesis

Classification

Epidermal Tumors

Benign epidermal tumors and nevi•

Premalignant lesions•

Malignant epidermal tumors•

Tumors of Skin Appendages

Benign tumors of skin appendages

Tumors of Dermis

Benign tumors and nevi of dermis•

Malignant tumors of dermis•

Introduction

Skin lesions characterized by abnormal proliferation of one or more tissues present in skin will be discussed in this chapter.

Definitions

- ❖ **Nevus:** Circumscribed, non-neoplastic skin or mucosal lesion, usually present at or soon after birth. Term should always be qualified according to the cell or tissue of origin, for example “connective tissue nevus” or “vascular nevus”. Nevi generally represent clones of genetically altered cells arising from mosaicism.
- ❖ **Hamartoma:** Is used when there are more than one type of tissues in a nevus.
- ❖ **Benign tumor:** A localized proliferation of cells of one type, which has some degree of autonomous control of growth, but a normal differentiation.
- ❖ **In situ tumor:** A localized collection of morphologically malignant epidermal cells, which have still not invaded the basement membrane—so it essentially applies to epidermal tumors.
- ❖ **Malignant tumor:** A collection of morphologically malignant cells with full capacity to metastasize to lymph nodes and other organs.

Etiogenesis

Nevi

- ❖ Most nevi are due to genetic mosaicism resulting from somatic mutations.
- ❖ Embryo is normal at conception, but during early embryogenesis a mutation gives rise to a clone of cells in which the genetic change manifests as a nevus.

•Should know

Tumors

Several factors are implicated in carcinogenesis (Table 17.1). Often, the etiology of a tumor is multifactorial. For instance, in the presence of a human immunodeficiency virus infection, the oncogenic potential of human papilloma virus is greatly enhanced.

Table 17.1. Factors in etiogenesis of skin tumors

Chemicals	Arsenic
	Coal tar
Ultraviolet rays	UVB rays
	Psoralens + UVA
Viruses	Human papilloma virus 16 and 18
	Human T-cell lymphoma/leukemia virus
Oncogenes	p53 ras genes
	Tumor suppressor gene expression

Classification

Based on the source of origin, tumors, and nevi¹ of skin can be classified as (Table 17.2):

- ❖ Epidermal.
- ❖ Appendageal.
- ❖ Dermal.

Epidermal Tumors and Nevi

Benign Epidermal Tumors and Nevi

Seborrheic Keratosis (SK)

Synopsis

Epidemiology: Benign epidermal tumor, seen after age of 50.

Morphology: Multiple, well-defined, hyperpigmented papules with a “stuck on” appearance, a greasy surface, and keratinous plugs.

Sites: Face, trunk, and upper extremities.

Treatment: Can be left alone, remove if cosmetically disfiguring. Biopsy if diagnosis is in doubt (to rule out malignant melanoma).

Etiology

Unknown; May be familial.

Epidemiology

- ❖ **Prevalence:** One of the commonest epidermal tumors.
- ❖ **Age:** Seen after the age of 50 years, but may be seen earlier, as flat inconspicuous lesions. Lesions usually increase in number with age.
- ❖ **Gender:** No predilection.

Table 17.2. Tumors and nevi of the skin

Source	Epidermal	Appendageal	Dermal
Benign	Seborrheic keratoses Skin tags Melanocytic nevi Verrucous epidermal nevi Becker’s nevus Epidermoid and trichelermal cysts Milia	Trichoepithelioma Syringoma Nevus sebaceous	Vascular malformations Vacular tumors Keloids Leiomyoma Lipoma Dermatofibroma
Premalignant	Cutaneous horn Bowen’s disease Actinic keratoses Arsenical keratoses	Keratoacanthoma	Large plaque parapsoriasis
Malignant	Basal cell carcinoma Squamous cell carcinoma Malignant melanoma	Paget’s disease	Cutaneous T-cell lymphoma Langerhans cell histiocytosis Reticuloendothelial malignancies Kaposi’s sarcoma Cutaneous metastases

1. Some “nevi”-like epidermal nevi may have sebaceous gland or apocrine gland components, in addition to proliferation of keratinocytes.

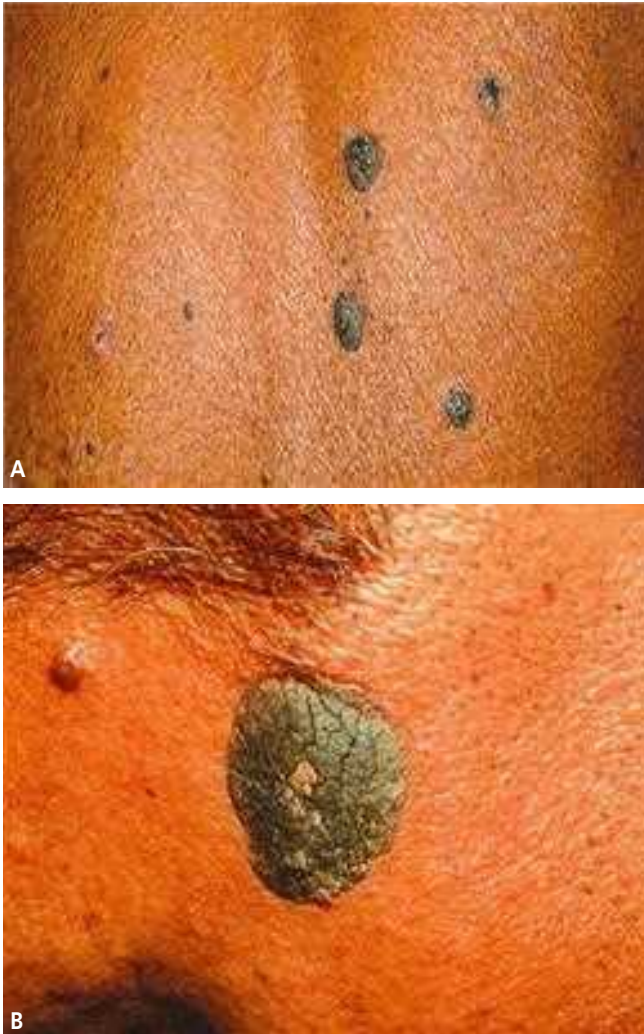

Fig. 17.1. Seborrheic keratosis: A: early lesions are sharply demarcated macules. B: older lesions are brown black papules with distinct “stuck on” appearance.

Clinical features

Morphology

- ❖ Multiple lesions; less frequently single lesion.
- ❖ Begin as skin-colored, sharply demarcated brown macules. Progress to dark brown or black papules with a distinctive “stuck on” appearance (Fig. 17.1).
- ❖ Surface appears greasy and may have scattered keratin plugs (“**currant bun**” appearance).

Sites of predilection

Most frequently seen on the face, upper trunk, and upper extremities (acral parts) but can be present

anywhere (except palms, soles, and mucous membranes).

Investigations

Biopsy is rarely necessary, but when done shows:

- ❖ Hyperkeratosis².
- ❖ Papillomatosis³.
- ❖ **Horn cysts** in the thickened epidermis.

Diagnosis

Points for diagnosis

Diagnosis of SK is based on:

- ❖ Distinctive “stuck on” appearance of hyperpigmented papules with a greasy surface and keratinous plugs.
- ❖ Face, upper trunk, and upper extremities.

Differential diagnosis

SK needs to be distinguished from:

a. *Verruca vulgaris* (VV)

VV	SK
Age: any age	Usually after 50 years of age
Location: trauma prone sites	Face, upper trunk, upper extremities
Morphology: verrucous, firm papules with dry surface	Hyperpigmented, greasy papules with keratinous plugs; appear “stuck on”

b. *Dermatosis papulosa nigra*

- ❖ Familial.
- ❖ Seen in darker races.
- ❖ Smaller, black, flat lesions (Fig. 17.2), which appear after second decade.

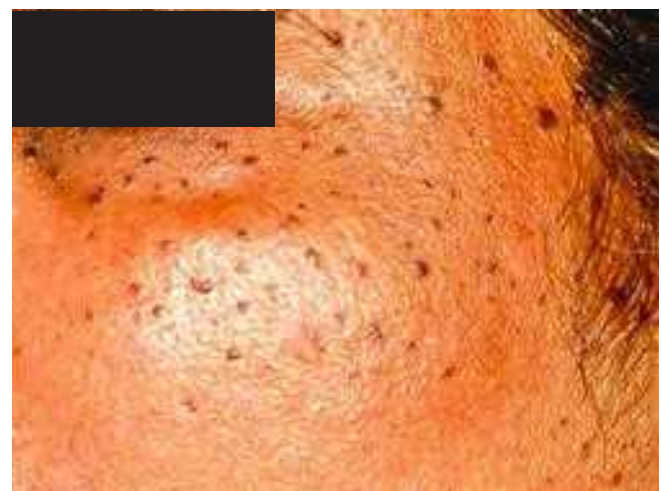

Fig. 17.2. Dermatitis papulosa nigra: small black papules, limited to the upper part of face.

2. **Hyperkeratosis:** thickened stratum corneum.

3. **Papillomatosis:** increase in size and concomitant branching of dermal papillae.

- ❖ Upper part of face; rarely on other parts of the face, neck, chest, and back.

c. Malignant melanoma

Usually easily differentiated.

Treatment

- ❖ Best left alone.
- ❖ Cryotherapy or chemical cauterization advocated for cosmetic reasons (unsightly lesions on exposed parts).
- ❖ Excision and histopathological examination (if doubt of malignant melanoma).

Skin Tags

Etiology

Etiology of skin tags is unknown, but skin tags may be:

- ❖ Familial.
- ❖ Associated with obesity.

Clinical features

Morphology

Soft, skin-colored or pigmented, pedunculated papules (Fig. 17.3).

Sites of predilection

Neck, axillae, and groins.

Associated features

- ❖ Obesity.
- ❖ Acanthosis nigricans.
- ❖ Diabetes.

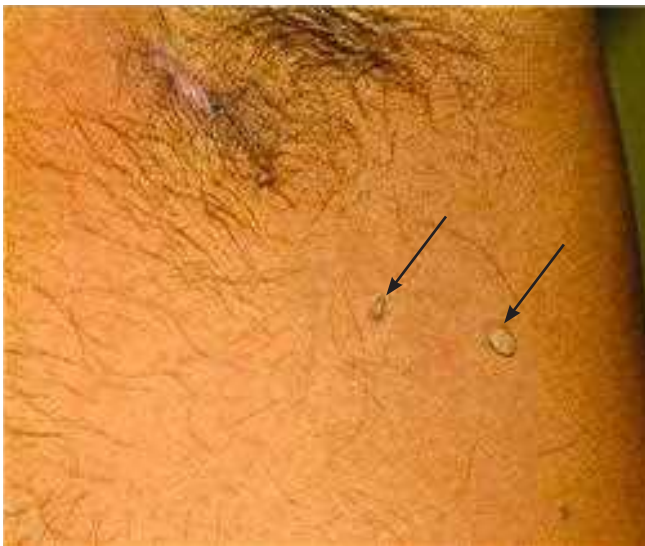

Fig. 17.3. Skin tags: in an obese individual, seen in major flexures, as soft papules.

Treatment

- ❖ **Small lesions:** Snip with curved scissors.
- ❖ **Larger lesions:** Cryotherapy (with liquid nitrogen), electrocautery or radiofrequency ablation.

Melanocytic Nevus

Synopsis

Etiology: Benign localized proliferation of melanocytes.

Classification: Congenital melanocytic nevi and acquired melanocytic nevi, which may be junctional, compound, and intradermal.

Congenital melanocytic nevus: Appears at birth. May be large and hairy. Malignant potential, especially if large.

Junctional melanocytic nevus: Hyperpigmented macule which shows color variation.

Compound melanocytic nevus: Pigmented papule, which shows color variation and may have hair.

Intradermal melanocytic nevus: Skin-colored papule.

Treatment: Excision, only if cosmetically disfiguring or suspicion of malignant transformation.

- ❖ **Synonyms:** Nevomelanocytic nevus.
- ❖ Is a benign clustered proliferation of melanocytes.

Etiology

- ❖ Occurs in families, suggesting a genetic factor.
- ❖ Sharp increase in number during adolescence, during pregnancy or in patients on estrogen therapy indicating a hormonal influence.

Classification (Table 17.3)

- ❖ **Congenital melanocytic nevi (CMN):** Congenital melanocytic nevi are present at birth and its nevus cells have a propensity for deeper penetration. They have been classified into:

Table 17.3. Classification of melanocytic nevi

Congenital melanocyte nevi
Acquired melanocytic nevi
Junctional nevus
Compound nevus
Intradermal nevus
Less common nevi
Spitz nevus
Mongolian spot
Nevus of Ota
Speckled and lentiginous nevus
Dysplastic nevus

- *Small lesions:* <1.5 cm.
 - *Intermediate lesions:* 1.5–20 cm.
 - *Giant lesions:* >20 cm.
- ❖ **Acquired melanocytic nevi:** Acquired melanocytic nevi appear after first 6–12 months of age, enlarge with growth of body and regress in later life. The proliferating melanocytes are present in clumps (**nevus cells**) and based on the location of nevus cells, they are classified into:
- *Junctional melanocytic nevus:* in which nevus cells are present at dermoepidermal junction (Fig. 17.4A).
 - *Compound melanocytic nevus:* in which nevus cells are present at dermoepidermal junction and some have entered the dermis (Fig. 17.4B).
 - *Intradermal melanocytic nevus:* in which nevus cells are present only in dermis (Fig. 17.4C).

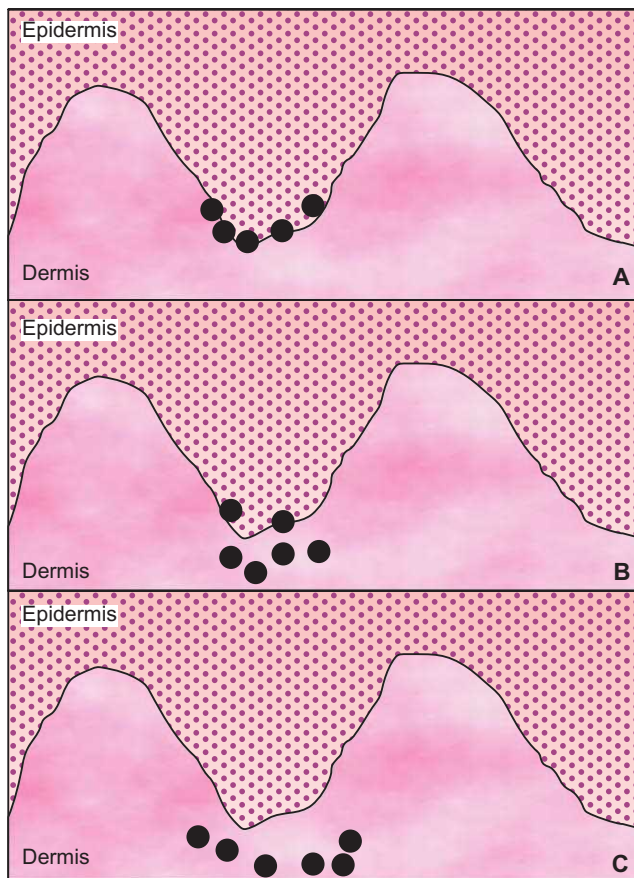


Fig. 17.4. Melanocytic nevi: histologically melanocytic nevi are characterized by nests of nevus cells. Location of the nevus cells determines the type of clinical lesion. A: junctional nevus. B: compound nevus. C: intradermal nevus; ● nevus cells.

Clinical features

Congenital melanocytic nevi

- ❖ **Etiogenesis:** Derived from epidermal melanocytes and nevus cells have a predilection for deeper penetration.
- ❖ **Onset:** Present at birth.
- ❖ **Morphology:**
 - May be single, but are often multiple.
 - Color varies from brown to black and the lesions darken and enlarge as the child grows.
 - With age, the lesions also become raised and develop rugosities (**cerebriform** appearance). Coarse hair (Fig. 17.5) develops in 90% of lesions and may have a vortex distribution. Larger lesions may have satellite papules at the periphery.
 - Can occur anywhere on body. Giant lesions are usually seen on the trunk and because they may cover large areas of the trunk, are called “**bathing trunk nevi**”.
- ❖ **Complications:**
 - The potential for malignant transformation is definitely more in giant congenital melanocytic nevi (bathing trunk nevi).
 - Meningeal involvement and spina bifida, seen in lesions located over vertebral column.

Junctional melanocytic nevi

- ❖ Commonest in children.
- ❖ **Morphology:** Moderately brown to dark brown, circular-oval macules, which show marked color

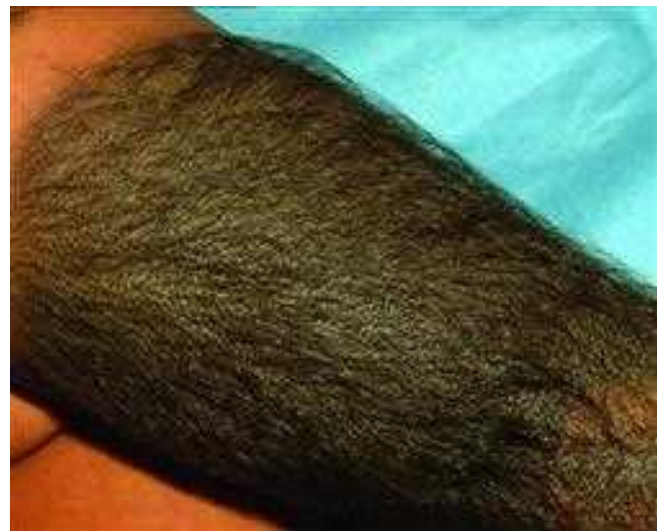

Fig. 17.5. Giant congenital melanocytic nevus: large, hairy hyperpigmented plaque.

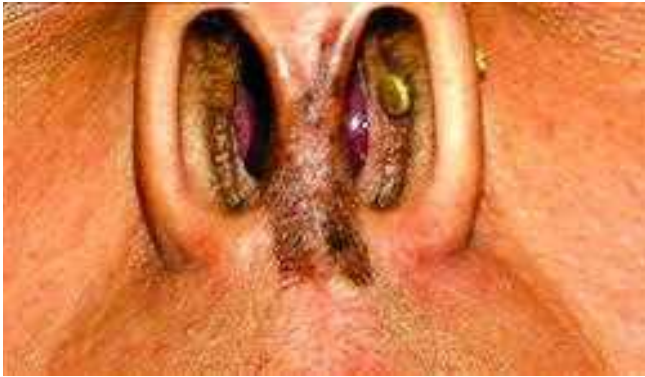

Fig. 17.6. Junctional melanocytic nevus: dark brown macule that shows color variation even within the lesion.

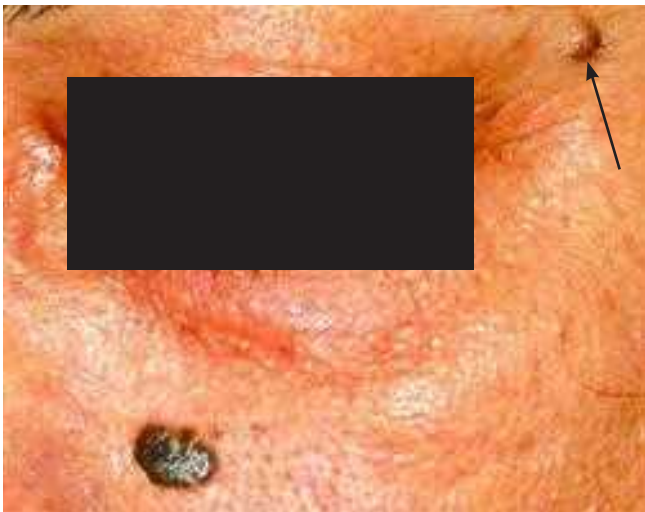

Fig. 17.7. Compound melanocytic nevi: brown pigmented dome-shaped nodules, which has developed irregularity of surface. The one on temple bears hair.

variation even within a single lesion (Fig. 17.6), because the pigment follows skin markings.

❖ **Sites of predilection:** Palms, soles, and genitals.

Compound melanocytic nevi

❖ Is a stage in evolution of melanocytic nevus.

❖ **Morphology:**

- Dome-shaped pigmented nodules.
- Most have a smooth surface but larger lesions have an irregular surface due to irregular hyperkeratosis and papillomatosis (Fig. 17.7). Often bear few terminal hair.
- Color varies⁴ from brown to black, center being darker than the periphery.

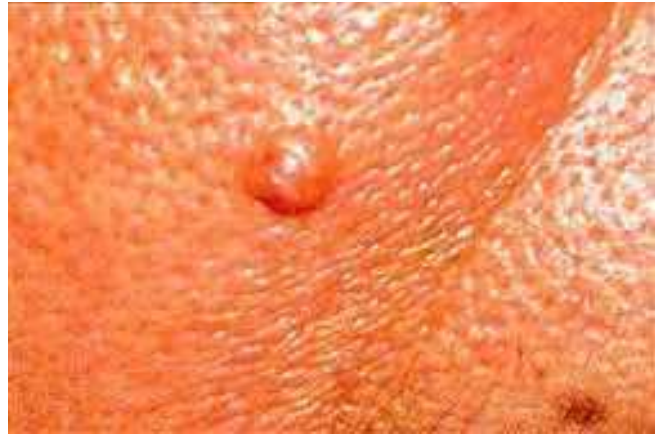

Fig. 17.8. Intradermal melanocytic nevus: skin-colored nodule with telangiectasia.

Intradermal melanocytic nevi:

- ❖ Adults and elderly.
- ❖ **Morphology:** Skin-colored or slightly pigmented nodules with telangiectasia (Fig. 17.8).

Variants

Some of the conditions described below may not be true melanocytic nevi.

❖ **Spitz nevus:**

- Predominantly seen in children, so it is also called **juvenile melanoma**.
- Appears as a solitary erythematous nodule, which grows rapidly over a period of 1–2 months and then becomes stationary.
- Seen on the face and lower extremities.
- Though benign, these lesions are often excised because of their rapid growth.

❖ **Mongolian spots:**

- Seen commonly in Mongoloid and Negroid infants.
- Bluish ill-defined macules (Fig. 17.9).
- Lumbosacral region.
- Regress by age of 4 years.

❖ **Speckled and lentiginous nevus:**

- Is a relatively uncommon entity.
- Consists of two components (Fig. 17.10):
 - A flat, macular component, slightly darker than the normal skin.
 - Within this background macule are darker flat (lentigo-like) and elevated lesions (melanocytic nevi).

4. Color variation in compound nevus, less than in junctional nevus.

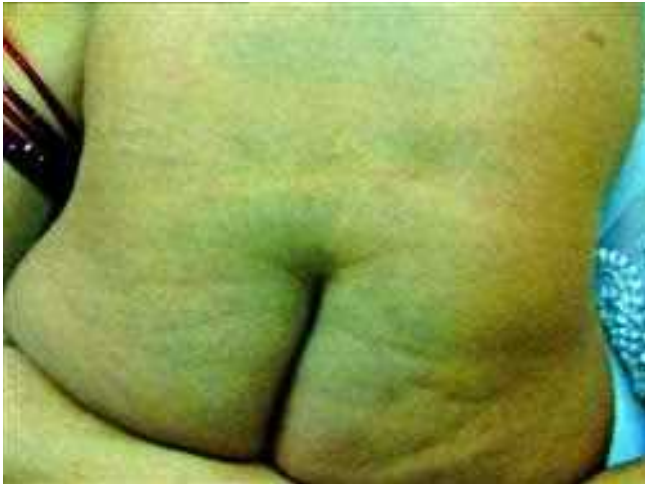

Fig. 17.9. Mongolian spot: blue ill-defined macules on the lumbosacral region.

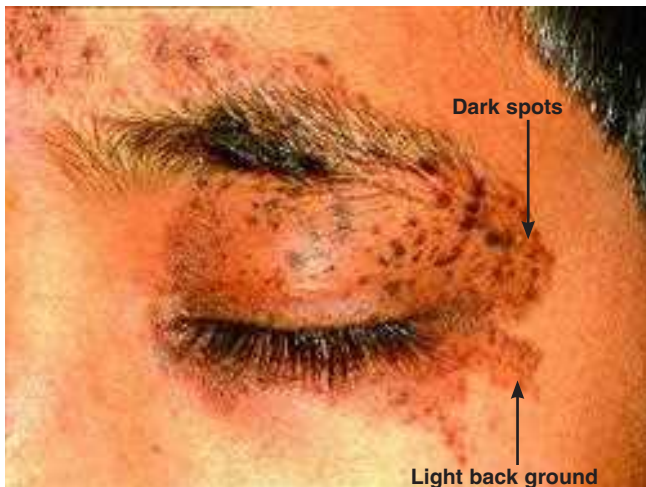

Fig. 17.10. Speckled and lentiginous nevus: consists of two components, a flat macular component, slightly darker than the normal skin and within this background macule are darker flat (lentigo-like) and elevated lesions (melanocytic nevi).

- Rarely (really rarely) malignant transformation.

❖ *Nevus of Ota*

- Present at birth. Or appears in infancy.
- Macular pigmentation, which has two components:
 - More prominent slate grey hyperpigmentation due to dermal melanocytes (Fig. 17.11A).
 - Brownish epidermal pigmentation.
- Distribution along the maxillary division of the trigeminal nerve. Pigmentation of sclera

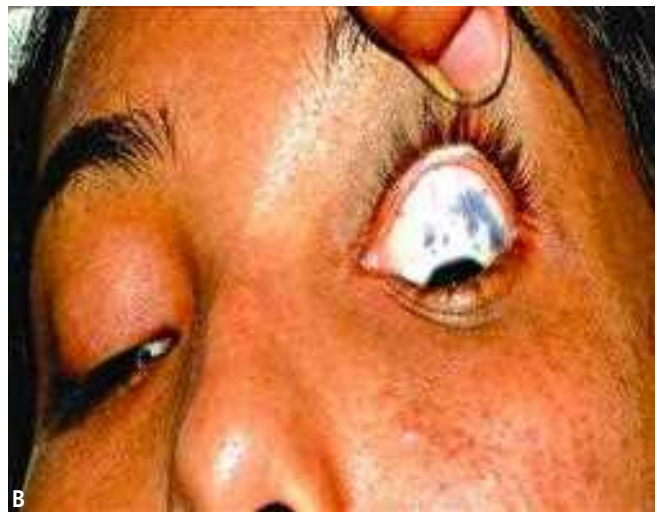
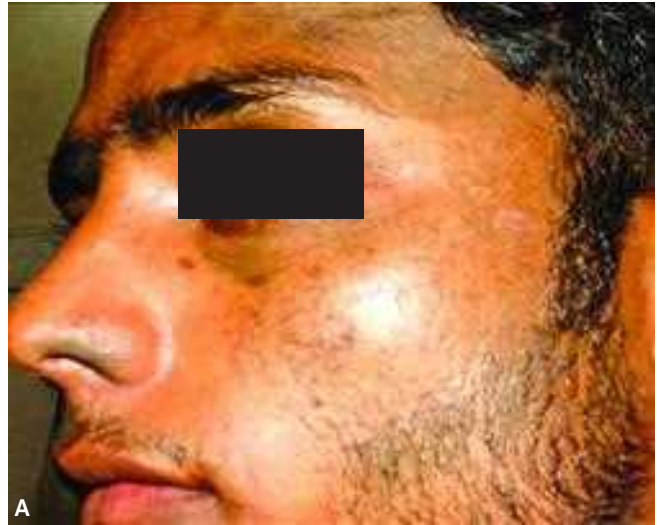
Fig. 17.11. Nevus of Ota. A: slate gray hyperpigmentation of skin. B: pigmentation of sclera.

(slate gray) and conjunctiva (brown) often present (Fig. 17.11B).

Complications

- ❖ ***Halo nevus or Sutton's nevus:*** Melanocytic nevus which develops a halo of depigmentation (Fig. 17.12) and over period of many years, the nevus involutes and the depigmented halo regiments.
- ❖ ***Inflammation:*** Usually occurs in response to plucking of hair from nevus. Manifests as pain and swelling and histologically shows a foreign body granuloma.
- ❖ ***Malignant change:***
 - Malignant transformation is rare (extremely rare!) and occurs mainly in the following situations:

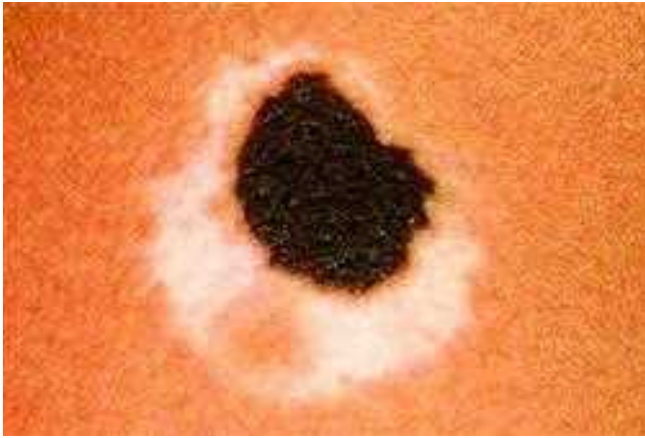

Fig. 17.12. Halo nevus: depigmented halo around a melanocytic nevus.

- *Congenital melanocytic nevi*: six percent of lesions undergo malignant change; risk of malignant transformation is greater in giant lesions.
- *Dysplastic nevus syndrome*⁵: in melanoma prone families.
- The following changes in a melanocytic nevus are suspect and warrant a biopsy:
 - Change in size and pigmentation.
 - Change in shape and contour.
 - Itching, inflammation, ulceration, and bleeding.

Investigations

- ❖ Not usually required.
- ❖ Biopsy a doubtful nodule (Table 17.4).

Table 17.4. Histopathology of pigmented nevi

Congenital melanocytic nevus	Nevus cells ⁶ which extend deep into dermis
Acquired melanocytic nevus	Orderly nests of benign nevus cells (Fig. 17.4)
Mongolian spot	Melanocytes in dermis
Nevus of Ota	Melanocytes in dermis

Treatment

- ❖ Most lesions can be left alone.
- ❖ Some lesions need to be excised:
 - If cosmetically disfiguring (face).
 - In a trauma-prone area.
 - If malignancy suspected.

Verrucous Epidermal Nevus

Etiology

Somatic mosaicism.

Clinical features

Onset

Frequently present at birth; less frequently develops later.

Morphology

- ❖ Multiple brown papules arranged linearly (Fig. 17.13A). Lesions either localized or generalized (Fig. 17.13B).

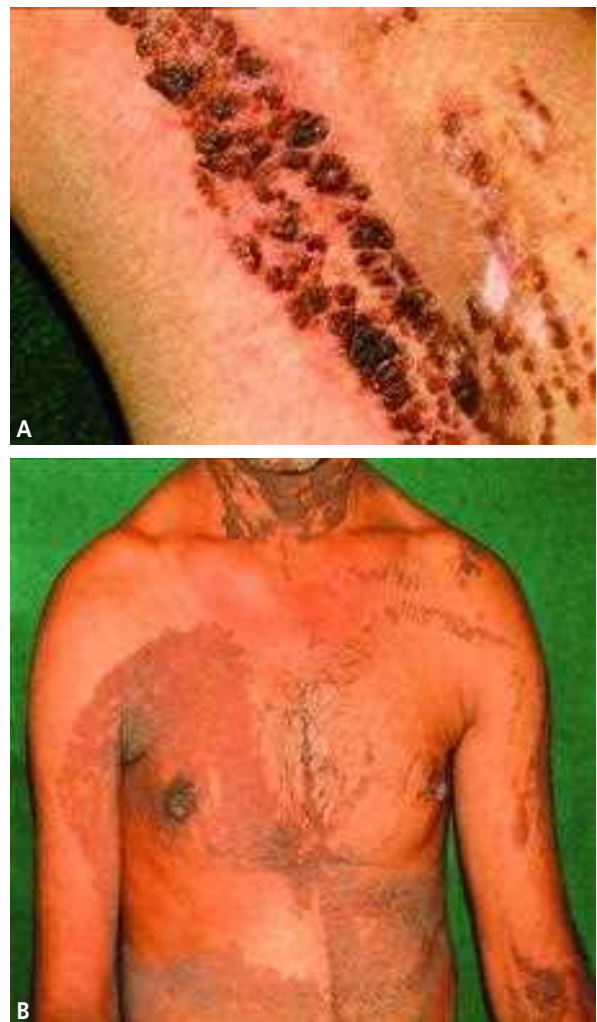

Fig. 17.13. Verrucous epidermal nevus: A: verrucous papules arranged linearly. B: patient with generalized involvement.

5. **Dysplastic nevus syndrome:** autosomal dominant disorder. Multiple irregularly pigmented nevi on trunk with predisposition to turn malignant.
 6. **Nevus cells:** cells with abundant cytoplasm containing melanin granules.

- ❖ Develop varicosity over a period of time.
- ❖ Flexural lesions may macerate.

Variants

- ❖ **Inflammatory linear verrucous epidermal nevus:** Extremely itchy. Various morphological variants—**lichenoid** (violaceous) **psoriasiform** (scaly) or **eczematous** (dermatitis) papules arranged linearly (Fig. 17.14A). Usually on limbs.
- ❖ **Nevus comedonicus:** Grouped open (numerous) and closed (fewer) comedones and sometimes inflammatory papules arranged linearly (Fig. 17.14B). Usually on face, trunk, and neck.
- ❖ **Nevus sebaceous:** Well-demarcated, yellowish-brown greasy plaque (Fig. 17.14C). Scalp or forehead. Present at birth, enlarges at puberty.

Associations

Several syndromes associated with verrucous epidermal nevus.

- ❖ **Proteus syndrome:** Consists of asymmetrical hypertrophy of limbs, verrucous epidermal nevi, vascular malformations and lipoma-like lesions.
- ❖ **CHILD nevus:** Which is an acronym for **c**ongenital **h**emidysplasia, **i**chthyosiform nevus, and **l**imb **d**efects.
- ❖ **Epidermal nevus syndrome:** Consists of verrucous epidermal nevi and central nervous system, eye, and skeletal defects.

Treatment

- ❖ Topical retinoic acid (0.025–0.1%) flattens the lesions. Should be used carefully in flexures. Recur, if treatment stopped.
- ❖ Dermabrasion may help.

Becker's Nevus

- ❖ Common condition. More frequent in men. Begins shortly before, at or after puberty.
- ❖ Appears as a hyperpigmented (light-dark brown) patch, which has a characteristic splashed appearance. Over period of time, coarse dark hairs appear on the lesion (Figs. 17.15A and B) and sometimes skin texture is altered.
- ❖ Chest and shoulders.
- ❖ Best left alone.

Epidermoid and Trichilemmal Cysts

Nomenclature

Histologically, cysts in skin are classified as:

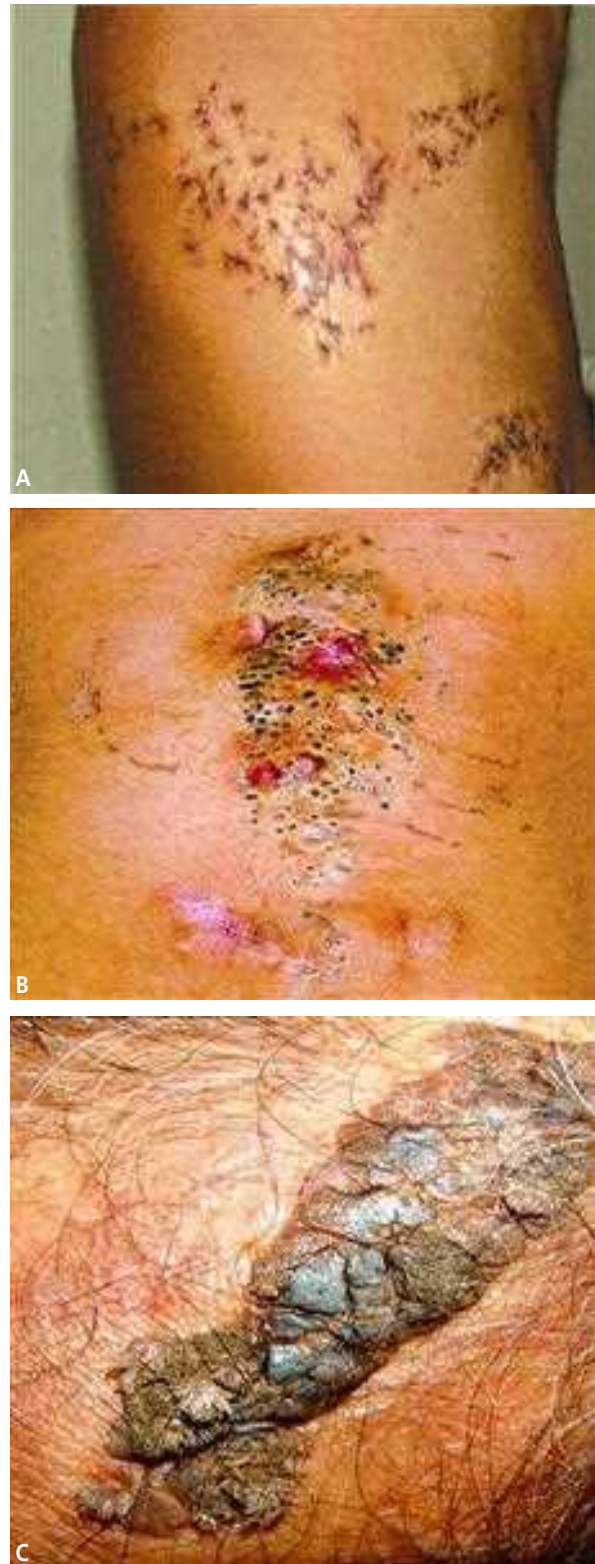

Fig. 17.14. Variants of epidermal nevus: A: inflammatory linear verrucous epidermal nevus: excoriated violaceous papules arranged linearly. B: nevus comedonicus: open and closed comedones in a linear arrangement. C: nevus sebaceous: yellowish, greasy oval plaque.

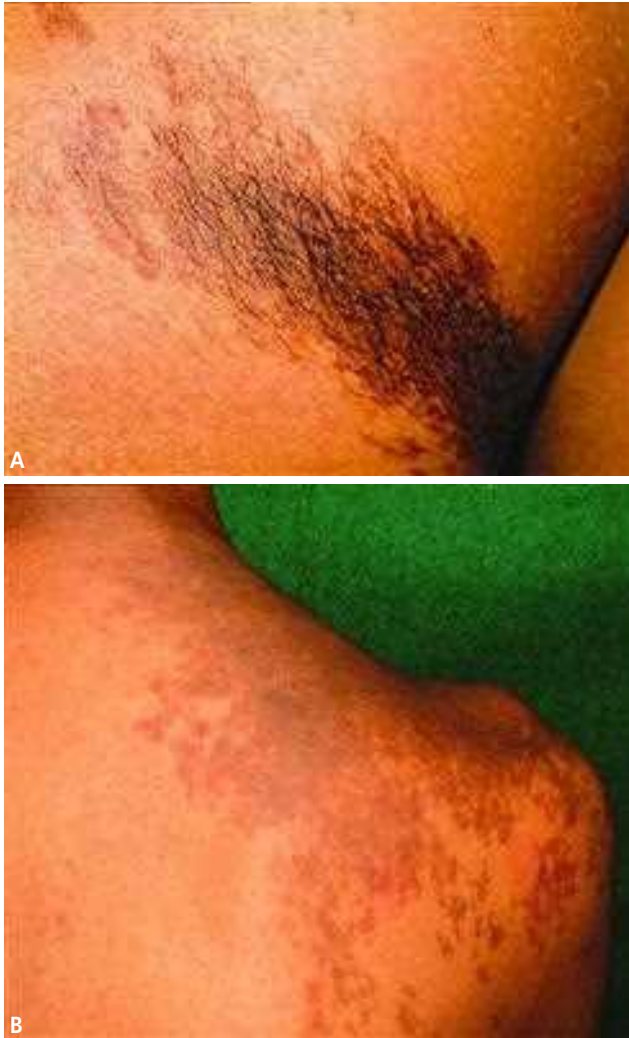

Fig. 17.15. Becker's nevus: A: splashed brown hyperpigmentation with hypertrichosis. B: splashed brown hyperpigmentation, on the shoulder, a typical site.

- ❖ **Keratinous cyst:** In which the lining of cyst is keratinous. And depending on the lining, keratinous cysts are further classified into:
 - *Epidermoid cysts:* in which lining of cyst resembles normal epidermis.
 - *Trichilemmal cysts:* in which lining of cyst resembles external root sheath.
- ❖ **Sebaceous cyst:** Term should be restricted to steatocystoma multiplex.

Clinical features

Morphology

- ❖ Small-to-medium-sized cyst, which may be skin colored or yellowish.
- ❖ Usually, freely mobile over underlying structures but is tethered to the skin. Characteristically,

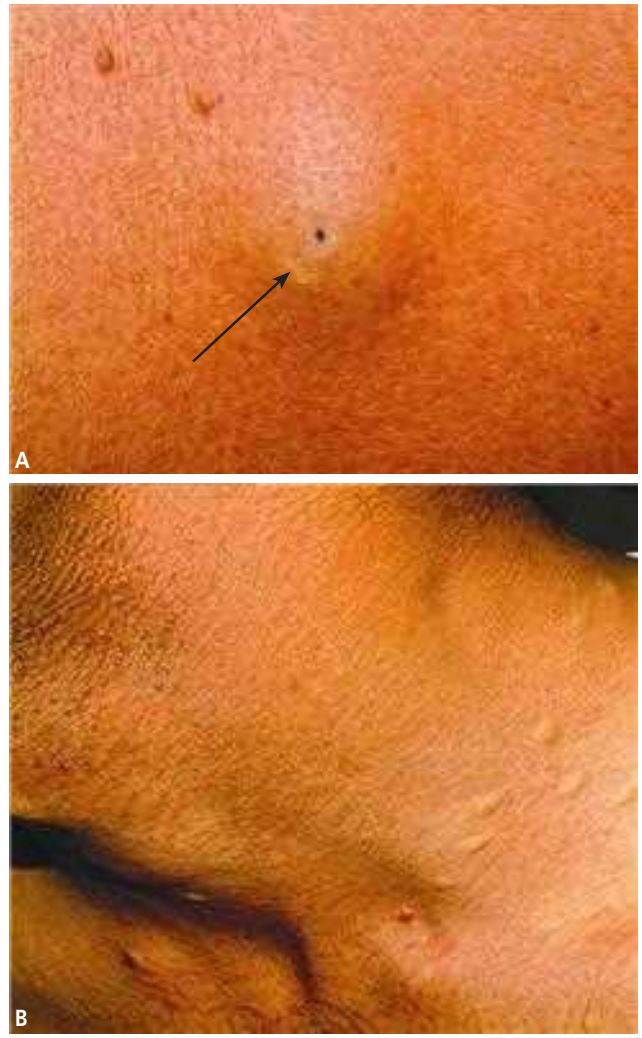


Fig. 17.16. Cysts in the skin. A: epidermoid cyst: note the punctum. Cheesy material extruded. B: steatocystoma multiplex: multiple smooth nodules on the neck. Oily fluid extruded.

have a central punctum through which cheesy material can be expressed (Fig. 17.16A).

Sites

- ❖ **Epidermoid cyst:** Face, upper back, and retroauricular region.
- ❖ **Trichilemmal cyst:** Most frequent on the scalp.

Complications

- ❖ Secondary infection.
- ❖ Rupture in the dermis and induce a foreign body reaction.
- ❖ Dystrophic calcification.

Differential diagnosis

Epidermoid cysts should be differentiated from:

a. *Steatocystoma multiplex* (Fig. 17.16B)

<i>Steatocystoma multiplex</i>	<i>Epidermoid cyst</i>
Always multiple	Single or multiple
Smooth nodule with no punctum but comedones seen	Punctum present
Pressure expresses only fluid	Pressure expresses cheesy material
Presternal region, proximal part of limbs, neck	Face, upper back and retroauricular region

Treatment

- ❖ Excision *in toto*.
- ❖ Incision followed by expression of the contents and destruction of the lining.
- ❖ **Inflamed cyst:** Intralesional triamcinolone acetonide under cover of antibiotics.

Milia

These are small subepidermal keratin cysts.

Clinical features

- ❖ Appear as small, firm, white papules, which are less than 2 mm in diameter.
- ❖ Occur in two situations:
 - *De novo* on the face (Fig. 17.17A).
 - At sites of healed subepidermal blisters, e.g., bullous pemphigoid, dystrophic type of epidermolysis bullosa (Fig. 17.17B).

Treatment

- ❖ If few, lesions can be removed with needle.
- ❖ Topical retinoic acid (0.025%) can be tried if there are many lesions. Should be avoided near the eyes.

Premalignant Lesions

Synopsis

Several premalignant conditions recognized: cutaneous horn, keratoacanthoma, Bowen's disease, actinic keratoses, and arsenical keratoses.

Cutaneous horn: Morphological diagnosis, not necessarily premalignant. Hard, yellow-brown horn, often with collar.

Keratoacanthoma: Rapidly growing nodule, with central horny plug. Usually resolves spontaneously, rarely becomes malignant.

Bowen's disease: Slowly expanding, psoriasiform plaque with irregular projections. Very small risk of malignancy.

Actinic keratoses: Pink, rough scaly macules or papules on photo-exposed parts.

Arsenical keratoses: Corn-like papules on palms and soles; associated with pigmentary changes on trunk.

Treatment: Cryotherapy, curettage or excision; 5-FU when several lesions; biopsy and excision, if malignant change suspected.

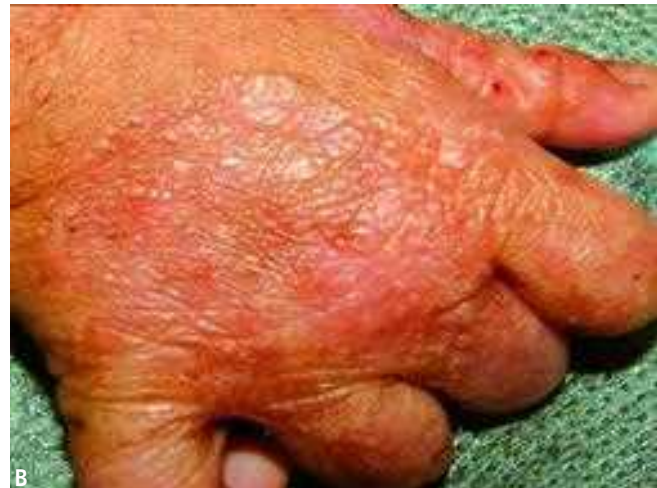
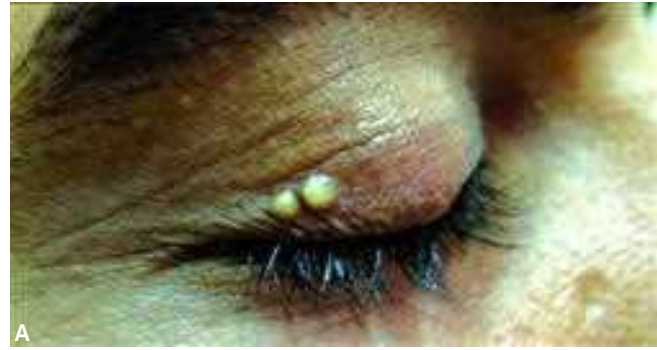
Fig. 17.17. Milia: A: small, firm, white papules on the upper lid. Lesions on face occur *de novo*. B: lesions occurring at site of subepidermal bullae in dystrophic epidermolysis bullosa.

Cutaneous Horn

Etiology

- ❖ Is a morphological diagnosis.
- ❖ Occurs secondary to:
 - Epidermal nevus.
 - Warts.
 - Seborrheic keratoses.
 - Rarely, underlying squamous cell carcinoma.

Clinical features

Morphology

- ❖ Hard yellow-brown horny projection, often curved. Sometimes has a collar (Fig. 17.18A and B).
- ❖ Underlying inflammation and induration suggests malignant change.

Sites of predilection

Hands and face.

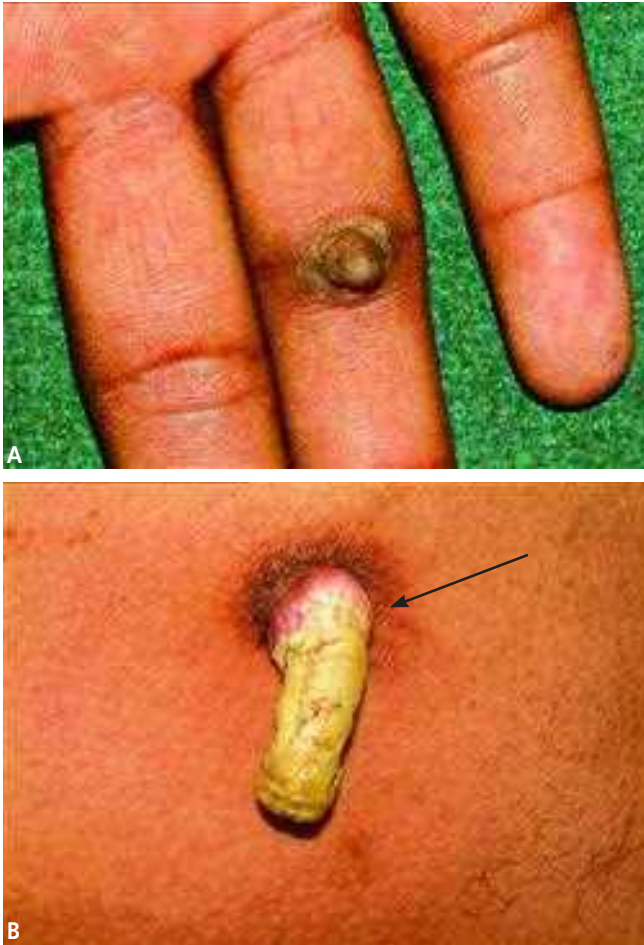

Fig. 17.18. Cutaneous horn: A: hard yellow-brown horn. Note the collar. B: this one had underlying squamous cell carcinoma. Note the inflammation.

Treatment

Excision. Always send for biopsy.

Keratoacanthoma

Etiology

Keratoacanthoma can be caused by:

- ❖ Photosensitizing chemicals (such as tars) and radiation (like ultraviolet radiation and X-rays).
- ❖ Immunosuppression, as given after renal transplant.

Clinical features

Morphology

- ❖ Rapidly growing, skin-colored nodule, which develops a central horny plug (Fig. 17.19); the plug falls off to leave a crater.

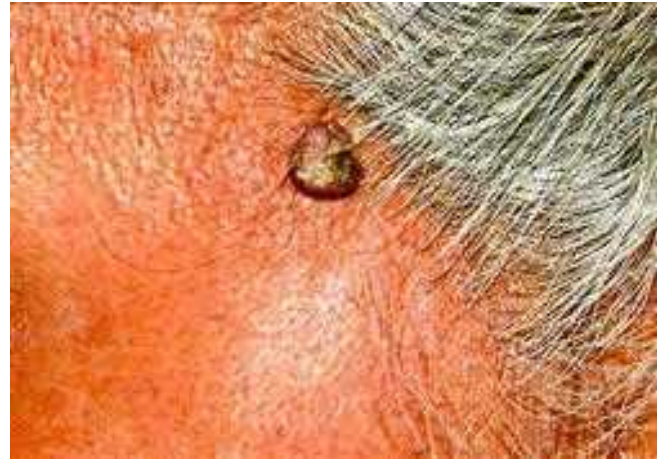

Fig. 17.19. Keratoacanthoma: keratotic papule with central horny plug.

- ❖ Most lesions resolve spontaneously, leaving a depressed (cosmetically unacceptable) scar. Few (very few!!) transform into squamous cell carcinoma.

Sites of predilection

Most frequently on the photo-exposed parts.

Treatment

Lesion preferably excised or curetted because:

- ❖ Spontaneous regression leaves cosmetically unacceptable scar.
- ❖ Lesion may be malignant.

Bowen's Disease

Etiology

- ❖ **On photo-exposed skin:** Ultraviolet rays are important.
- ❖ **On covered skin:** Chronic arsenic poisoning (from drinking water or indigenous medicines) should be suspected.

Clinical features

- ❖ Single, slowly enlarging psoriasiform plaque with sharply defined border which may have indentations (reniform margin) and projections (Fig. 17.20A). Infiltration of the lesion indicates development of squamous cell carcinoma (Fig. 17.20B).
- ❖ Face and trunk.

Treatment

Excision, cryotherapy, or topical 5-fluorouracil (5-FU).

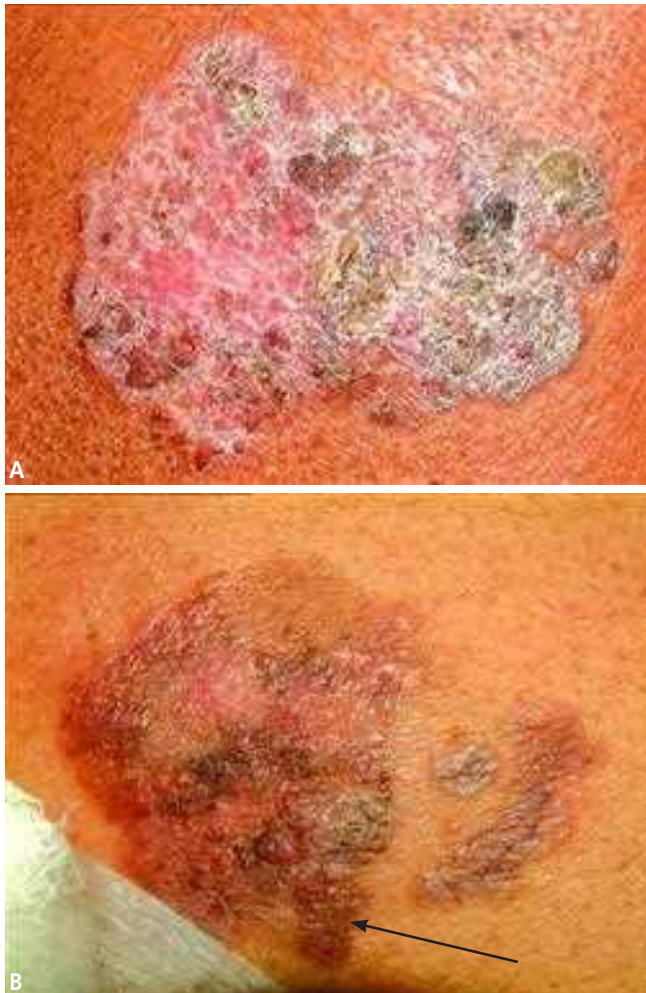

Fig. 17.20. Bowen's disease: A: psoriasiform plaque, showing irregular indentations. B: infiltration of the lesion indicates development of squamous cell carcinoma.

Actinic Keratoses

Etiology

- ❖ Ultraviolet rays acting on fair-complexioned skin.
- ❖ In dark-skinned individuals, vitiligo may predispose.

Clinical features

- ❖ In middle aged and elderly.
- ❖ Multiple, pink or grey irregular, rough macules or papules, with dry and adherent scales (Fig. 17.21).
- ❖ Face, scalp, and dorsae of hand.
- ❖ Suspect transformation into squamous cell carcinoma (a rare occurrence), if the lesion enlarges rapidly, ulcerates or bleeds.

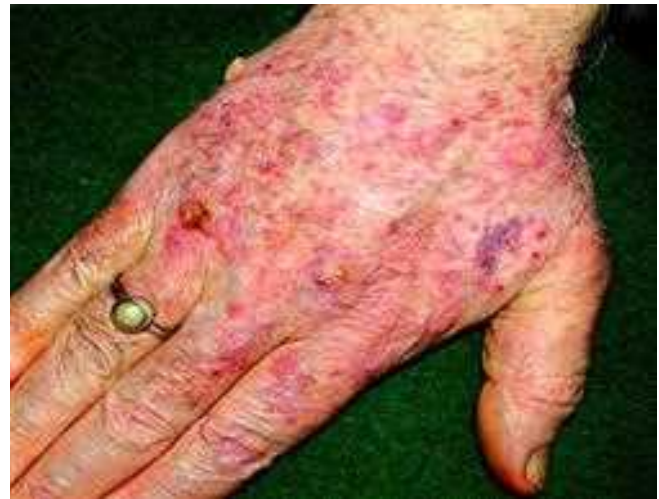

Fig. 17.21. Actinic keratoses: pink irregular macules and papules with dry adherent scales.

Treatment

- ❖ **Photoprotection.**
- ❖ **Specific therapy:**
 - Small lesions: cryotherapy.
 - Large lesions: curette.
 - Multiple lesions: topical 5-FU, imiquimod.

Arsenical Keratoses

Etiology

Several causes of chronic exposure to arsenic.

- ❖ **Medicinal exposure:** Oral Fowler's solution for psoriasis; Asiatic pills for asthma.
- ❖ **Contaminated drinking water.**
- ❖ **Others:** Burning of plywood as firewood.

Clinical features

Chronic arsenic poisoning has protean manifestations:

- ❖ **Arsenic keratoses:** Multiple, punctate, hard, symmetrical corn-like papules (Fig. 17.22A); when removed, the keratosis do not leave behind pits.
- ❖ **Pigmentary changes:** Rain drop pigmentation (Fig. 17.22B). On trunk.
- ❖ **Bowen's disease:** Well-defined scaly plaques; edge shows indentations (Fig. 17.20). On covered parts.
- ❖ **Nail changes.**
- ❖ **Associations:** Visceral neoplasms.

Treatment

- ❖ **Small lesions:** Cryotherapy.
- ❖ **Large lesions:** Curette.
- ❖ **Multiple lesions:** Topical 5FU cream.

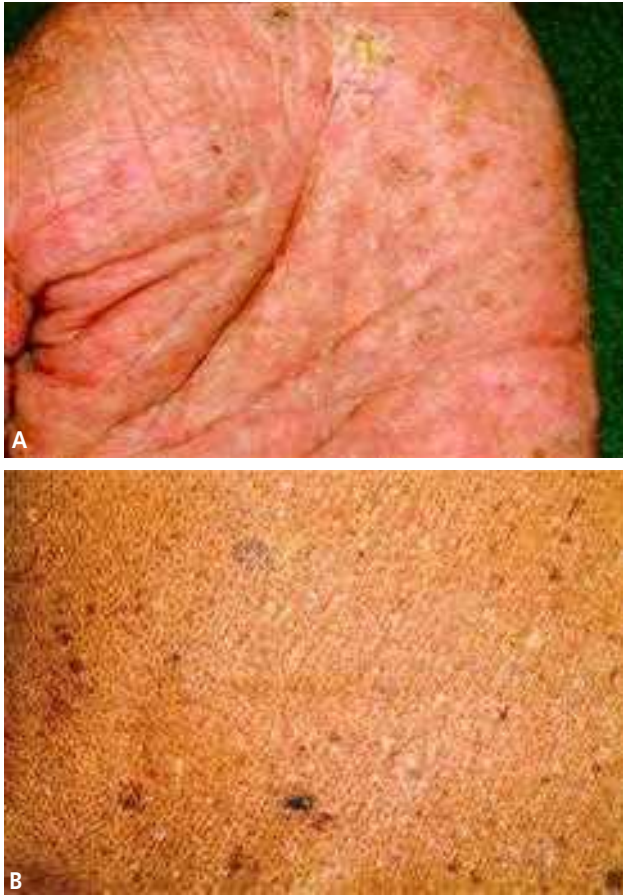

Fig. 17.22. Chronic arsenic poisoning: A: arsenic keratoses: multiple corn-like papules. B: rain drop pigmentation.

Malignant Epidermal Tumors

Basal Cell Carcinoma (BCC)

Synopsis

Etiology: Ultraviolet rays, chemicals and rarely a genetic predisposition.

Morphology: Translucent nodule with telangiectasia. May ulcerate. Has a pearly, beaded edge, which is diagnostic. Many variants (classical or noduloulcerative BCC, superficial BCC, morpheic BCC and any of these may be pigmented). Locally invasive, does not metastasize. No lymphadenopathy.

Sites: Face. Superficial variant on trunk.

Diagnosis: Based on characteristic edge; histopathology diagnostic.

Treatment: Surgical excision mainstay of treatment. Use Moh's micrographic surgery in recurrent lesions and radiotherapy in elderly.

BCC is a locally invasive epidermal tumor made up of cells similar to basal cells and which never metastasizes.

Etiology

Ultraviolet radiation (UVR)

UV radiation (UVA and UVB), an important factor in development of BCC. Related more to acute episodes of sunburn rather than to cumulative dose of UVR. Role of UVR is supported by:

- ❖ Occurrence mostly on face.
- ❖ Increased incidence in Whites living in the Tropics.
- ❖ Higher incidence in patients with increased exposure to UVR due to recreational/occupational reasons.

Chemicals

- ❖ **Topical agents:** Incriminated include photosensitizing pitch tar.
- ❖ **Systemically ingested agents:**
 - Psoralens + UVA.
 - Arsenic predisposes to development of multiple BCCs after a long latent period.

Genetic

- ❖ In individuals with light skin, red hair, and freckles.
- ❖ Multiple BCC are inherited as an autosomal dominant genodermatosis in **nevroid BCC syndrome**⁷.
- ❖ **Xeroderma pigmentosum** predisposes, due to defective DNA repair, after UVR exposure.
- ❖ **Albinism** predisposes, due to pigment dilution.

Epidemiology

- ❖ **Age:** Middle aged and elderly.
- ❖ **Sex:** More common in males.
- ❖ **Race:** In Whites, it is the commonest malignant tumor; infrequent in Blacks.

Clinical features

Morphology

Several morphological variants of BCC are recognized:

- ❖ **Noduloulcerative BCC (rodent ulcer)**⁸: A small shiny, translucent papule often with telangi-

7. **Nevroid BCC syndrome:** associated with palmoplantar pits and skeletal abnormalities.

8. **Rodent ulcer:** noduloulcerative lesions are locally invasive, *i.e.*, gnaw into the adjoining tissue like a rodent, so the apt name.

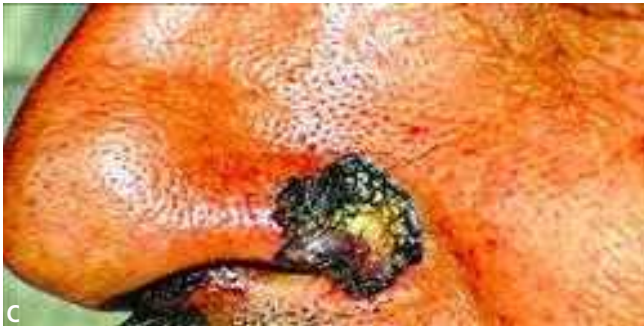
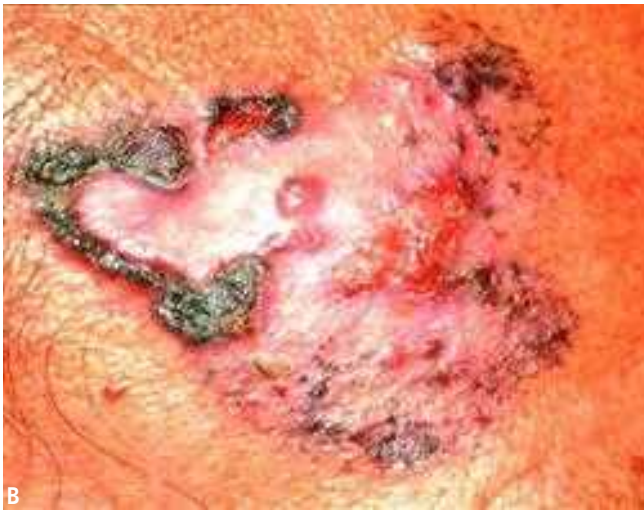
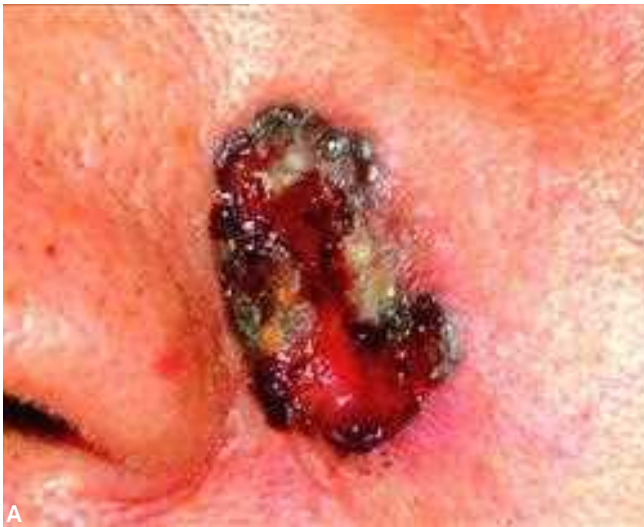Fig. 17.23. Basal cell carcinoma: A: noduloulcerative lesion showing rolled, pearly edge and central ulceration. B: superficial spreading BCC showing thready margin (on trunk). C: pigmented BCC.

ectasia. Enlarges slowly, and ulcerates in the center. The edge is rolled, pearly and beaded while the center has an adherent crust

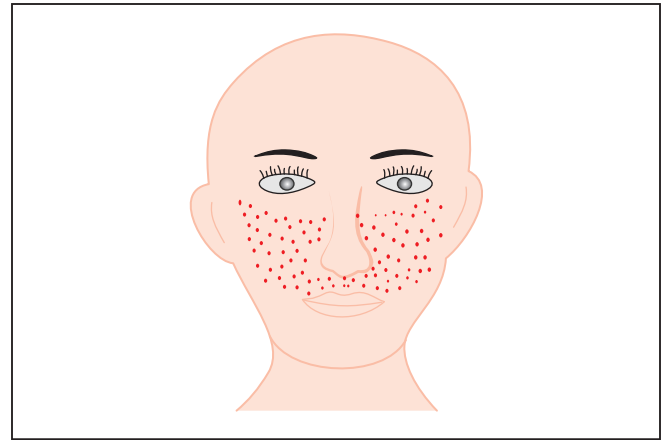


Fig. 17.24. Basal cell carcinoma: location of lesions (except superficial BCC).

(Fig. 17.23A). Some nodular lesions may develop cystic changes. Seen on face. Locally invasive.

- ❖ **Superficial BCC:** Multiple, superficial, slowly enlarging, scaly plaques with a thin, thread-like edge (Fig. 17.23B). May attain a large size but is not locally destructive. Seen most frequently on trunk and limbs.
- ❖ **Morphoeic BCC:** Yellow, waxy, ill-defined nodule which initially closely resembles a scar. As it expands slowly, it may ulcerate (a late occurrence). Seen usually on face.
- ❖ **Pigmented BCC:** Any of the above variants of BCC may be pigmented (Fig. 17.23C).

Sites of predilection

- ❖ All variants of BCC, except superficial BCC, occur on the face (Fig. 17.24).
- ❖ Superficial BCC occurs on trunk and limbs.

Course

- ❖ Slowly progressive, locally invasive (especially noduloulcerative variant) neoplasm, eating into underlying structures like cartilage or bone, if left untreated.
- ❖ Lymphadenopathy and distant metastasis do not occur.

Diagnosis

Points for diagnosis

Diagnosis of BCC is based on:

- ❖ Characteristic appearance of ulcerated nodule with a pearly, beaded margin, and telangiectasia.

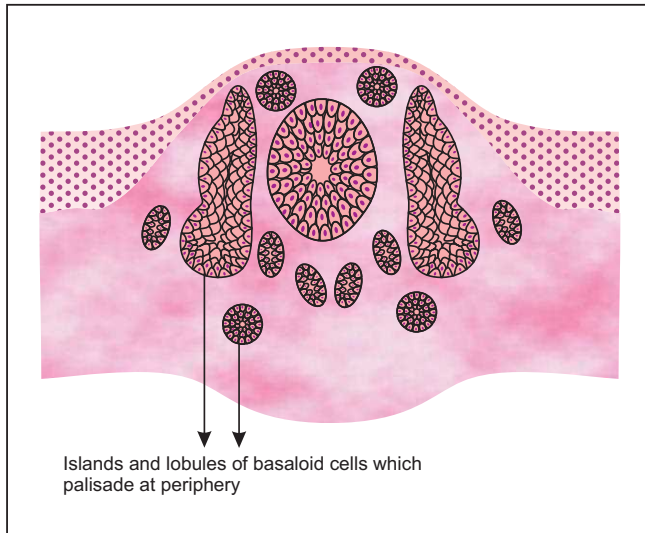


Fig. 17.25. Basal cell carcinoma: histologically diagnostic islands and lobules of basaloid cells in a palisading arrangement.

- ❖ Slow growth.
- ❖ Distinctive sites of occurrence.
- ❖ Pathognomonic histology (Fig. 17.25).

Differential diagnosis

BCC should be distinguished from:

a. Squamous cell carcinoma (SCC)

SCC	BCC
<i>Pre-existing disease:</i> occurs on damaged skin (scars, radiodermatitis, photodamaged skin). Can also develop in mucosa (leucoplakia)	Occurs on photodamaged skin. Mucosal lesions not seen.
<i>Morphology:</i> fungating, indurated lesion with everted margin	Well-defined, firm lesion with waxy beaded margin
<i>Growth:</i> rapid/slow growing	Slow growing
<i>Sites:</i> anywhere on body including mucosae	Upper part of face. Superficial variant on trunk.
<i>Metastases:</i> lymphadenopathy frequent. Visceral metastasis infrequent	Only local invasion

b. Melanocytic nevus (MN)

MN	BCC
<i>Morphology:</i> pigmented or skin colored papule with smooth or hyperkeratotic surface; does not ulcerate	Noduloulcerative lesion with a pearly, beaded edge
<i>Growth:</i> not destructive	Locally invasive, so called rodent ulcer

c. Malignant melanoma (MM)

MM	Pigmented BCC
<i>Morphology:</i> nodule with irregular edge and irregular pigmentation.	Pearly, beaded edge
<i>Growth:</i> rapidly progressive with lymph node and distant metastasis.	Locally invasive.

Treatment

- ❖ BCC is not life threatening but is locally destructive.
- ❖ Goal of treatment is complete removal of tumor with optimal cosmetic result.
- ❖ A variety of options are available and the 5-year cure rate is comparable (>90%) for most forms of treatment.
- ❖ Regular close surveillance is necessary to detect recurrences in all patients.

Surgery

- ❖ **Indications:** Surgical excision is treatment of choice in most cases.
- ❖ **Technique:** All variants of BCC except the morphoeic variant are excised with a 0.5 cm of skin margin. Morphoeic variant is excised with wider margin (up to 2 cm) because the lateral extent is often indistinct.

Moh's micrographic surgery

- ❖ **Indications:** BCCs at high-risk sites (nasolabial fold, periocular, and nose), large BCCs (>2 cm diameter), morphoeic variant, and recurrent BCCs.
- ❖ **Technique:** Involves microscopically controlled surgical removal of tumors, ensuring careful histological excision of malignant cells in all planes during surgery itself.

Radiotherapy

- ❖ **Indications:**
 - Elderly patients.
 - Patients in whom surgery is contraindicated.

Miscellaneous modalities of therapy

Small superficial lesions can be treated with:

- ❖ Electrocautery after curetting the lesion.
- ❖ Cryotherapy.
- ❖ Topical 5-FU.
- ❖ Intralesional interferon.
- ❖ Topical imiquimod, 5% cream.

Squamous Cell Carcinoma (SCC)

Synopsis

Etiology: Damaged skin (photodamaged/scarred/ulcerated skin), topical and systemic carcinogens, human papilloma virus, and immunosuppression predispose.

Clinical features: Plaque or ulcer with everted edges. Induration and fixity to underlying tissue. Look for evidence of damaged skin. Lymph node metastasis frequent in SCC arising in scarred skin.

Diagnosis: Biopsy any suspect lesion.

Treatment: Surgical excision (with margin of at least 0.5 cm) treatment of choice. Radiotherapy in patients unfit for surgery (elderly, widespread disease).

SCC is a malignant neoplasm arising from keratinocytes of the epidermis and contiguous mucous membranes, occurring usually in damaged skin/mucosa.

Etiology

SCC usually develops in damaged skin, though it can also occur *de novo*. Several factors have been implicated in pathogenesis of SCC.

Damaged skin

- ❖ **In Whites:** Most frequent cause of skin damage is actinic damage due to prolonged, cumulative exposure to sunlight (manifesting as actinic keratoses).
- ❖ **In non-Whites:** SCC occurs at sites of chronic inflammation and irritation due to:
 - **Scars:** burns.
 - **Dermatitis:** radiodermatitis, erythema ab igne, friction dermatitis.
 - **Nonhealing ulcers:** stasis ulcer.
 - **Chronic granulomas:** lupus vulgaris and granuloma inguinale.
 - **Leukoplakia:** in oral mucosa.
 - **Erythroplasia of Queyrat:** on genital mucosa.

Carcinogens

Pitch tar, mineral oils, and inorganic arsenic are established carcinogens.

Genetic disorders

Certain rare genetic disorders, with defective DNA repair mechanisms, such as **xeroderma pigmentosum** lead to multiple cutaneous neoplasia including SCC, BCC, and malignant melanoma.

Infections

- ❖ **Human papilloma virus (HPV):** HPV-related diseases like Buschke–Lowenstein tumor, verrucous carcinoma, and epidermodysplasia verruciformis predispose. HIV infection increases the oncogenic potential of HPV virus.

- ❖ **Infectious granulomas:** Like lupus vulgaris and granuloma inguinale, by virtue of the scars present in the lesions.

Immunosuppression

- ❖ Probably related to defective immunosurveillance of neoplastic cells.
- ❖ Iatrogenic immunosuppression (as in the patients who have had a renal transplant) and acquired immunodeficiency syndrome.

Clinical features

Morphology

- ❖ Frequently arises in already damaged skin.
- ❖ SCC manifests as (Fig. 17.26A and B):

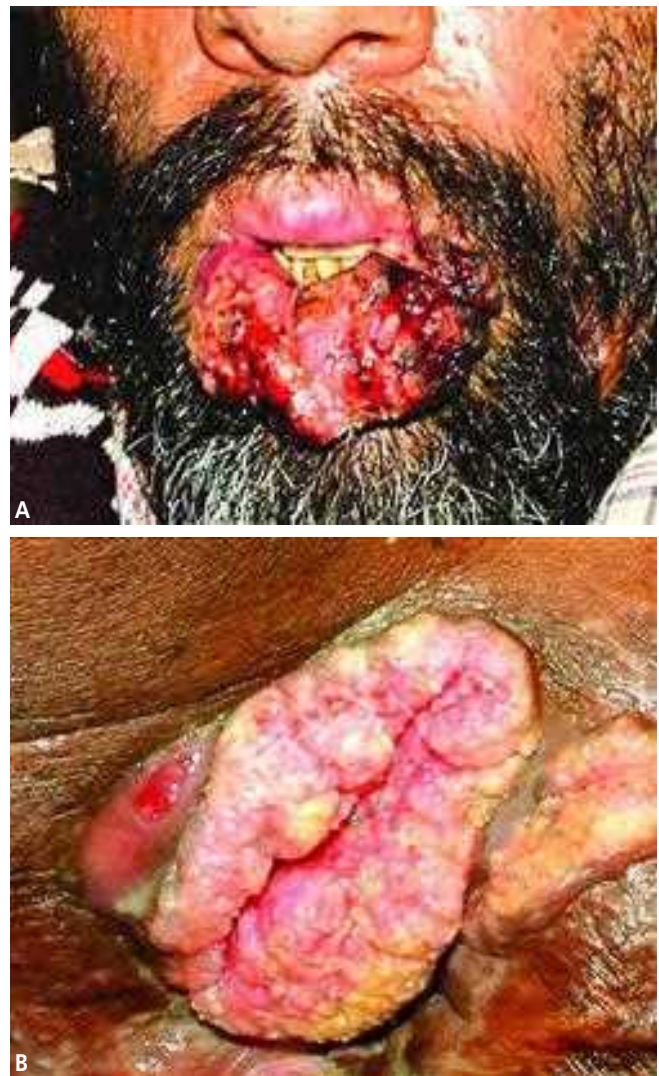

Fig. 17.26. Squamous cell carcinoma: A: raised ulcer with indurated base and everted margin (cauliflower-like) on the lower lip. B: raised ulcer with indurated base and everted margin at site of radiation dermatitis.

- Thickened indurated verrucous plaque.
- Raised ulcer, with an indurated base, everted broad margin (fungating or cauliflower-like growth) and a red granular floor.
- ❖ Often the induration is irregular and extends beyond the visible lesion.
- ❖ Lesion often attached to underlying structures eventually destroying them.

Sites

Photo-exposed sites. Also in already damaged sites.

Metastases

- ❖ **Lymphadenopathy:** Regional lymphadenopathy. Nodes hard and sometimes fixed to underlying structures and tethered to skin.
- ❖ **Visceral metastases:** Infrequent.

Course

- ❖ SCC arising in actinic keratoses seldom metastasizes.
- ❖ SCC arising in scars, radiation dermatitis, and mucosae often metastasizes to regional lymph nodes. Visceral metastasis is infrequent.

Diagnosis

Points for diagnosis

Diagnosis of SCC is based on:

- ❖ Presence of predisposing factors and damaged skin: photo-exposed sites, underlying scars, and radiodermatitis, *etc.*
- ❖ Verrucous plaque or shallow ulcer with red granular floor, surrounded by a wide, elevated, often everted, and indurated border. Base indurated, often attached to underlying structures.
- ❖ Regional lymphadenopathy. Nodes hard and sometimes fixed to underlying structures and tethered to skin.
- ❖ Characteristic histology (Fig. 17.27).

Differential diagnosis

SCC should be differentiated from:

- a. BCC (P. 364)
- b. Pseudoepitheliomatous hyperplasia.

Conditions with massive epidermal proliferation may clinically mimic SCC but the process is not invasive histologically.

Pseudoepitheliomatous hyperplasia	SCC
<i>Morphology:</i> verrucous plaque/ulcer. No/minimal induration. If present, regular and limited to lesion.	Plaque/ulcer with distinct irregular hard induration which extends beyond visible lesion.
<i>Underlying disease:</i> diseases like tuberculosis verrucosa cutis, chromoblastomycosis.	Radiodermatitis erythema ab igne, friction dermatitis
<i>Course:</i> of underlying disease	Progressive with lymph node metastasis.
<i>Histology:</i> not invasive and no mitosis and atypical cells	Invasive, mitosis and atypical cells

Treatment

Aim of treatment is to ensure complete removal/destruction of the primary tumor and to prevent metastases.

Surgery

- ❖ **Indications:** Surgical excision of tumor is the treatment of choice.
- ❖ **Margin of excision:**
 - *Lesion <2 cm diameter:* 0.5 cm margin of normal skin all around.
 - *Larger lesions:* larger margin.

Radiotherapy

Though radiotherapy is effective, it is generally reserved for frail elderly patients.

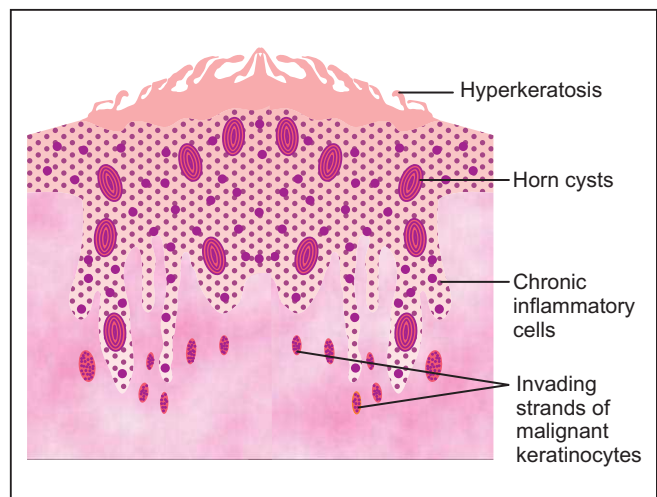


Fig. 17.27. Squamous cell carcinoma: characteristic histology.

Malignant Melanoma (MM)

Etiology: Multifactorial. Actinic damage important. Evidence of nevi in 25% of patients with MM.

Clinical features: A variety of clinical variants described: lentigo maligna melanoma, superficial spreading melanoma (SSM), acral lentiginous melanoma, and nodular malignant melanoma (NMM). SSM is the most frequent while NMM is the most aggressive. Remember ABCDE: **A**symmetrical pigmented nodule, **B**order irregularity, **C**olor variability, **D**iameter >0.5 cm, **E**levation irregularity.

Investigations: Biopsy any doubtful lesion.

Treatment: Surgery with wide, adequate margin (0.5–3 cm) depending on depth of tumor.

Etiology

Following factors predispose to development of MM:

- ❖ **Actinic damage:** Ultraviolet radiation (UVR) is an important factor as supported by:
 - Occurrence mostly on sun-exposed parts of the body.
 - Increased incidence in Whites living in the Tropics.
 - Higher incidence in patients with increased exposure to UVR due to recreational/occupational reasons.
- ❖ **Genetic:** MM is most commonly seen in:
 - Patients who are fair skinned with red hair and freckles.
 - Patients with dysplastic nevus syndrome (autosomal dominant with incomplete penetrance).
 - Patients of xeroderma pigmentosum.
- ❖ **Melanocytic nevi:** Histological evidence of a nevus is seen in about 25% of MM. Some types of melanocytic nevi are at an increased risk of developing MM:
 - Congenital melanocytic nevi, especially the giant variety.
 - Individuals with many melanocytic nevi.
 - Dysplastic nevus syndrome.

Clinical features

Several morphological variants of MM are described:

Superficial spreading melanoma

- ❖ Most frequent type of MM.
- ❖ Elevated plaque with color variation; may ulcerate.
- ❖ Mostly seen on covered parts (legs in females, back in males).

Lentigo maligna melanoma

- ❖ Most frequently seen in elderly.
- ❖ Infiltrated nodule develops in a pre-existing irregularly pigmented (brown to black) macule (**lentigo maligna**), which has been present for several years (Fig. 17.28A).
- ❖ Seen on photo-exposed parts.

Acral lentiginous melanoma (Fig. 17.28B and C)

- ❖ Most frequent type of MM in the dark skinned.
- ❖ Uneven pigmentation, nodulation, and ulceration.
- ❖ Has an aggressive course with early metastases.
- ❖ Palms, soles, and around the nails.

Nodular malignant melanoma

- ❖ Most aggressive type of MM.
- ❖ Well-demarcated, smooth or nodular tumor, which is usually pigmented, but can sometimes be amelanotic.

Less frequent variants

- ❖ **Metastatic melanomas:** Are secondaries in the skin (Fig. 17.28D), lymph nodes, and viscera.
- ❖ **Subungual melanoma:** Presents as painless pigmentation appearing subungually and spilling on to the nail fold (**Hutchinson's sign**, Fig. 17.29).

Course

Most MM grow in two phases:

- ❖ **Phase of radial growth:** Lesion expands superficially and the neoplastic cells are confined to the epidermis.
- ❖ **Phase of vertical growth:** Lesion expands vertically and malignant cells invade dermis and deeper tissues.

Staging

There are several methods of staging MM.

TNM classification (Table 17.5)

Investigations

Histology

- ❖ Doubtful lesions should always be biopsied. Ideally an excisional biopsy should be done.
- ❖ Biopsy shows atypical melanocytes (diagnostic findings) invading dermis (Fig. 17.30).
- ❖ **Markers:** Antibodies to S100, HMB45, and melan A/MART-1 for confirmation.

Dermatoscopy (epiluminescence microscopy)

- ❖ Involves visualizing the distribution of melanin in

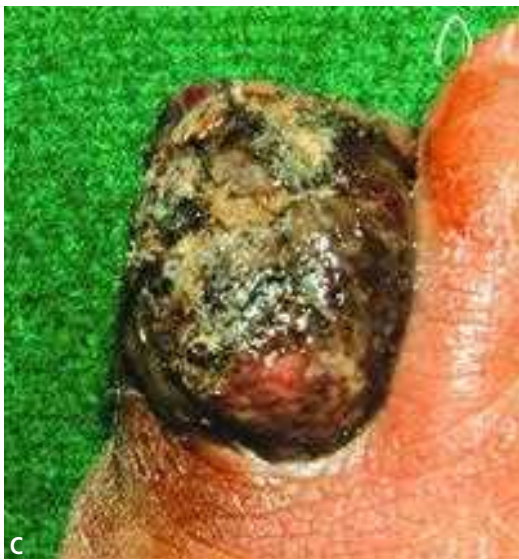
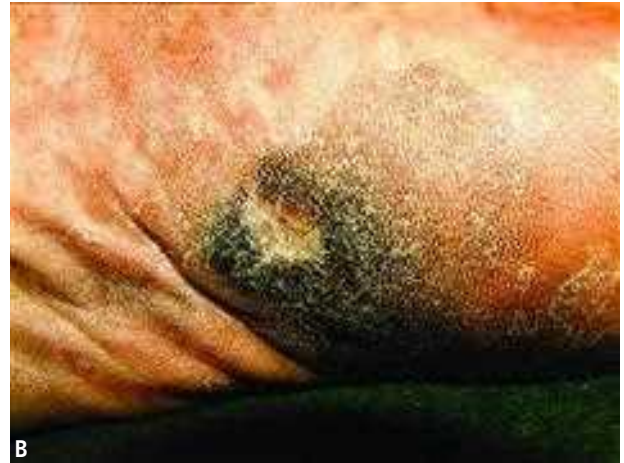
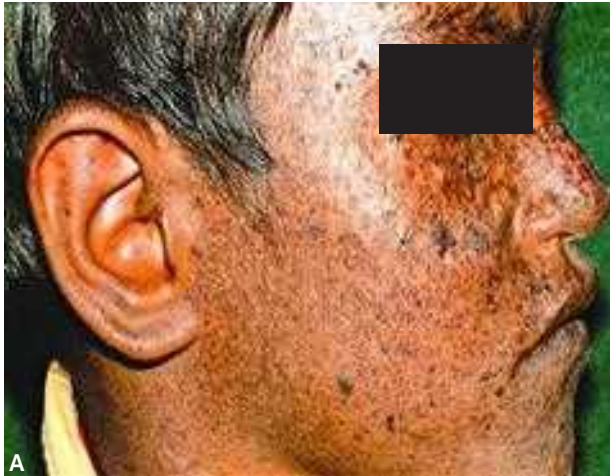Fig. 17.28. Malignant melanoma. A: ulcerated hyperpigmented nodule which shows variegation of color. This patient had xeroderma pigmentosum. B: acral lentiginous melanoma on sole. C: acral lentiginous melanoma on toe. D: meta-static melanoma.

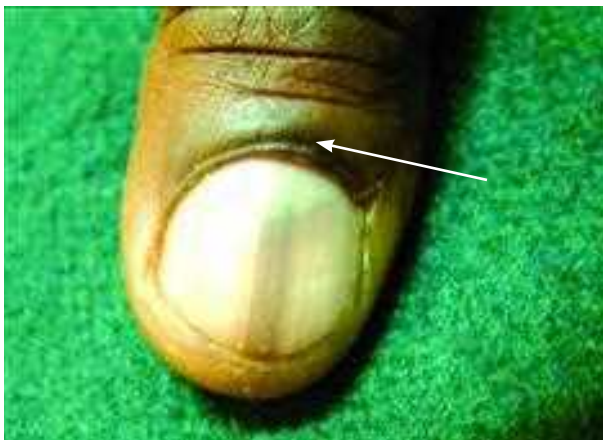

Fig. 17.29. Malignant melanoma: Hutchinson's sign.

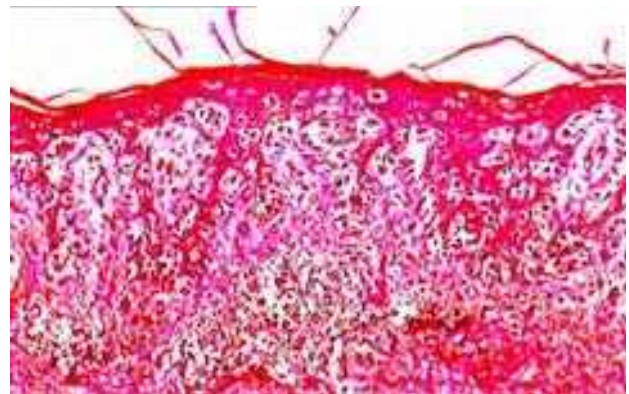
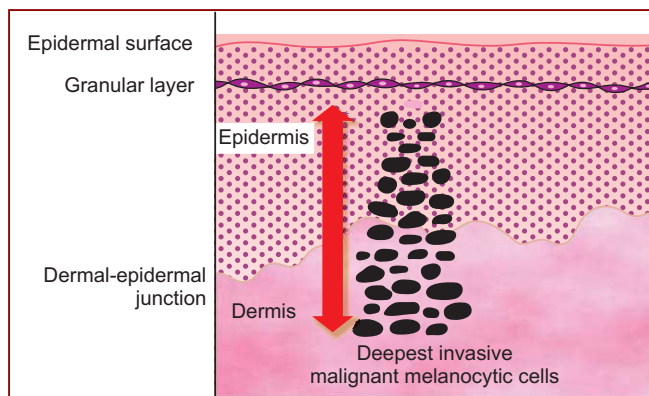


Fig. 17.30. Malignant melanoma: the essential histological feature for diagnosis of malignant melanoma is presence of cytologically malignant melanocytes invading the dermis.

Table 17.5. TNM classification of malignant melanoma

Tumor classification (T)	
T ₁ < 1 mm	a: no ulceration
T ₂ 1.01–2.00 mm	b: ulcerated
T ₃ 2.01–4.00 mm	
T ₄ > 4 mm	
Node classification (N)	
N ₁ 1 lymph node	a: micrometastases
N ₂ 2–3 lymph nodes	b: macrometastases
N ₃ ≥ 4 lymph nodes	
Metastases classification (M)	
M ₁ Skin and subcutaneous metastases	
M ₂ Lung metastases	
M ₃ Other visceral metastases ± elevated LDH	

**Fig. 17.31.** Malignant melanoma: histological grading using Breslow's method.

epidermis and dermis of a pigmented lesion using a hand held dermatoscope (magnifying lens) after covering the surface of lesion with oil.

- ❖ Features on dermatoscopy, characteristic of MM include:
 - Peripherally situated black dots.
 - Irregular pseudopods of pigment.
 - Radial streaming of pigment.
- ❖ **Histological staging:** Histological depth of involvement can be helpful in predicting prognosis. Two systems of grading have gained acceptance (Fig. 17.31):
 - *Breslow's method:* measures the vertical distance (in mm) from granular cell layer to the deepest part of tumor, using a microscopic micrometer. More frequently used as a prognostic predictor.

- *Clark's method:* assesses depth of penetration of melanoma in relation to different layers of dermis.

Sentinel node biopsy

- ❖ **<1 mm thick MM:** Sentinel node biopsy **not needed**.
- ❖ **1 or >1 mm thick MM:** Sentinel node biopsy should be done, if facilities available.

Prognostic predictors in MM (Table 17.6)

Table 17.6. Prognostic predictors in malignant melanoma

Predictor	Stage	5 year survival
Clinical stage	Stage I	75%
	Stage II	25%
	Stage III	0–5%
Histological staging*	<1.5 mm	90%
	1.5–3.5 mm	75%
	>3.5 mm	50%
Gender	Males have worse prognosis	
Age of patient	Patients >50 years of age have worse prognosis	
Site of lesion	Tumors of neck, scalp, trunk, and upper arms have poor prognosis	
Morphology	Nodular variant: poor prognosis	
	Ulceration: poor prognosis	

*Breslow's method

Diagnosis

Points for diagnosis

Diagnosis of MM is based on characteristics easily memorized as **ABCDE** of MM:

- ❖ **A**symmetrical pigmented nodule.
- ❖ **B**order irregularity: Nodule shows scallops and notches.
- ❖ **C**olor variability: This is very striking.
- ❖ **D**iameter: Size >5 mm.
- ❖ **E**levation irregularity.

Always excise all doubtful lesions for histopathological examination.

Differential diagnosis

MM should be differentiated from:

a. Melanocytic nevi

- ❖ Malignant change is extremely rare except in giant congenital melanocytic nevi and dysplastic nevi.
- ❖ Any lesion with one of the following **major features** in an adult should be considered for removal and the presence of an **additional**

minor feature should add to the clinical suspicion.

➤ *Major features*

1. Change in size.
2. Change in shape.
3. Change in color.

➤ *Minor features*

1. Diameter > 5 mm.
2. Inflammation.
3. Oozing or bleeding.
4. Mild itch or altered sensation.

b. Seborrheic keratosis

A distinctive “stuck on” flat or raised lesion with color varying from yellow to dark brown. The surface is greasy and shows keratotic plugs (currant bun appearance).

c. Other lesions

Pigmented BCC, a pigmented actinic keratosis, and a pyogenic granuloma may sometimes need to be differentiated.

Treatment

Prevention

Prevention of MM is easier than treating it:

- ❖ Avoid excess exposure to sunlight, especially in fair individuals.
- ❖ Appropriate protection from sunlight including use of sun shades and broad-spectrum sunscreens⁹.
- ❖ Self-examination especially by those at risk (patients with congenital melanocytic nevi, dysplastic nevi and xeroderma pigmentosum).

Specific treatment

Surgical excision is the treatment of choice. Excision biopsy with a 2–5 mm margin is recommended for suspicious lesions. If the histology confirms the diagnosis of malignancy, then a wider excision is performed depending on the thickness of the tumor:

- ❖ **Very thin tumors** (Breslow <0.5 mm or *in situ* MM): Excision with 5 mm margin (an adequate biopsy).
- ❖ **Thin tumors** (Breslow 0.5–1 mm): 1 cm clearance is advisable and the wound of biopsy is included in excision.
- ❖ **Deeper tumors**

- *Breslow 1–2 mm*: 2 cm clearance is advisable and tissue is removed up to deep fascia.
- *Breslow > 2 mm*: 3 cm margin of excision is needed and a skin graft may be needed to cover the defect. An elective regional lymph node dissection is also advocated unless the sentinel node biopsy is negative.

❖ **Disseminated tumors**

- Chemotherapy with dacarbazine may be used.
- Radiotherapy is again being recognized as an effective form of palliative therapy for metastatic and recurrent cutaneous melanoma.

Tumors of Skin Appendages

Benign Tumors of Skin Appendages

Syringoma

Benign tumor of eccrine sweat glands.

Clinical features

- ❖ Common tumor.
- ❖ Multiple, skin colored-yellow, flat topped, angulated papules (Fig. 17.32). Milia frequently associated.
- ❖ Upper and lower eyelids.

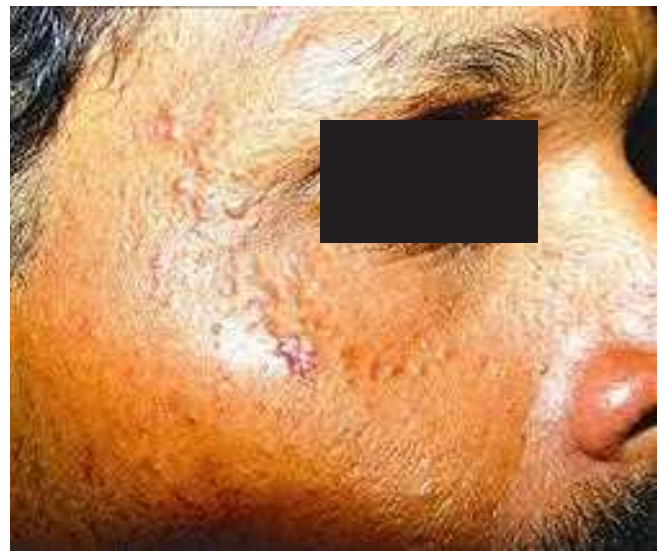

Fig. 17.32. Syringoma: flat topped, angulated yellow papules around the eyes.

9. **Use of sunscreens:** for photoprotection, an adequate amount of broad-spectrum sunscreen needs to be applied every 3–4 h, on all sun-exposed surfaces.

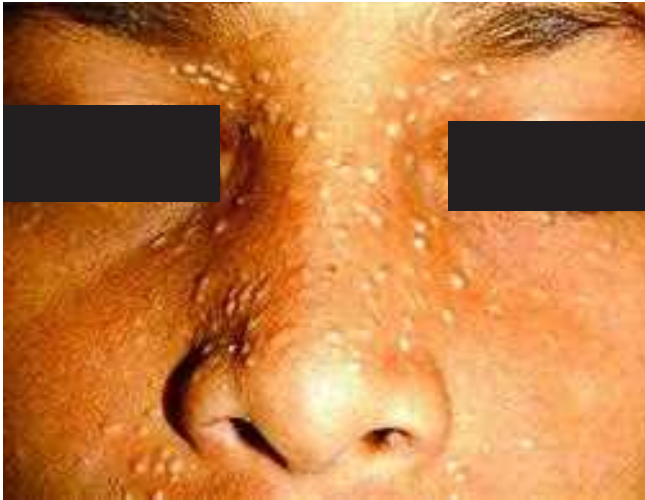

Fig. 17.33. Trichoepithelioma: multiple, dome-shaped translucent papules.

Treatment

- ❖ Can be left alone, as lesions are asymptomatic.
- ❖ If cosmetically disfiguring, electrocauterize (or radiofrequency ablate) the lesions.

Trichoepithelioma

Clinical features

- ❖ Single or multiple dome-shaped, translucent, skin-colored papules and nodules (Fig. 17.33).
- ❖ On nose and nasolabial folds.

Treatment

- ❖ Electrocauterize, (or radiofrequency ablate) if cosmetic disfigurement.

Malignant Tumors of Skin Appendages

Paget's Disease

- ❖ Uncommon disease.
- ❖ Occurs in two forms:
 - Paget's disease of the breast.
 - Extramammary Paget's disease.
- ❖ **Paget's disease of the breast** (Fig. 17.34):
 - *Demographics*: most patients are women, in fourth decade.
 - *Etiogenesis*: arises from ductal carcinoma of breast.
 - *Symptoms*: itching is prominent.
 - *Morphology*: unilateral. Begins as moist area on areola, which evolves into a sharply

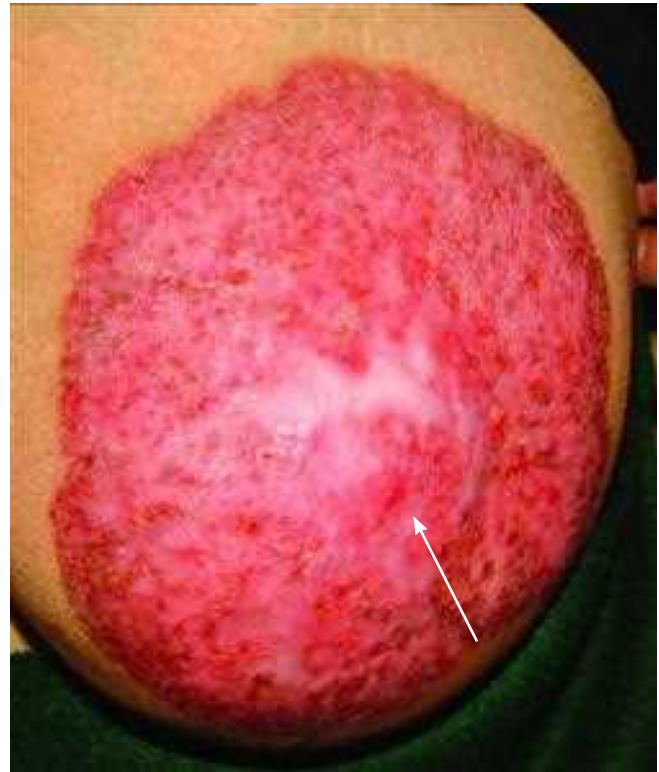

Fig. 17.34. Paget's disease of breast: sharply marginated plaque with a slightly raised edge and an irregular outline. If the crusts are removed, a red, glazed, moist surface is revealed. Note destruction of nipple.

marginated plaque with a slightly raised edge and an irregular in outline. If crusts are removed, a red, glazed, moist or vegetating surface is revealed.

- *Associated features*: underlying breast mass may be present. Lymphadenopathy, if mass is present.
- *Treatment*: as for carcinoma of breast.
- ❖ **Extramammary Paget's disease**:
 - *Demographics*: most patients are women, in fifth decade.
 - *Etiogenesis*: arises from apocrine gland duct.
 - *Symptoms*: itching is prominent.
 - *Site*: vulva, perianal area.
 - *Morphology*: sharply marginated crusted erythematous plaque with a slightly raised edge and an irregular outline. If the crusts are removed, a red, glazed, moist or vegetating surface is revealed.
 - *Treatment*: surgical excision; photodynamic therapy.

Tumors of Dermis

Benign Tumors and Nevi of Dermis

Vascular Malformations and Tumors

Synopsis

Nomenclature: Two types of lesions recognized: vascular malformations (present at birth and persistent) and tumors or hemangiomas (appear at birth or later and reduce/disappear over period). Further classified based on the type of blood vessel component (capillary, venous, arteriovenous, and lymphatic).

Capillary malformation (CMport wine stain): Pink-deep red telangiectatic macules which develop nodularity over time. Treated with pulsed tunable dye laser.

Venous malformation (VM): Bluish soft compressible lesion. Sclerotherapy and surgery.

Arteriovenous malformation (AVM): Erythematous warm lesion with thrill and bruit. Embolization

Lymphatic malformation (LM): Cluster of thin-walled vesicles. Surgery, CO₂ laser, RFA.

Mixed malformations: Combination of CM, VM, AVM and LM. *Prototype:* Klippel–Trenaunay.

Infantile hemangioma: Soft bright red nodule of variable size. May ulcerate. Spontaneously involutes completely/partially. Oral steroids and propranolol used in complicated cases.

Benign acquired hemangioma: Bright red pedunculated lesion with collar at base. Often ulcerates. Radiofrequency ablation.

Based on etiogenesis two types of lesions are recognized (Tables 17.7, 17.8).

- ❖ Vascular malformations.
- ❖ Tumors or hemangiomas.

Salmon patch

- ❖ Is a capillary malformation (CM).
- ❖ Commonest vascular malformation present at birth.
- ❖ Unlike other vascular malformations, which persist, salmon patch involutes by the age of one.

Clinical features

- ❖ Presents as telangiectatic macules.
- ❖ Nape of neck, forehead, and eyelids.

Treatment

None required.

Port-wine stain

- ❖ **Synonym:** Telangiectatic nevus/nevus flammeus.

Table 17.7. Types of vascular nevi

Malformations	Hemangiomas
Capillary (CM) ❖ Salmon patch ❖ Port-wine stain	Capillary
	Cavernous
	Mixed
Venous (VM)	
Arteriovenous (AVM)	
Lymphatic (LM)	
Mixed	

Table 17.8. Differences between vascular malformations and hemangiomas

	Malformations	Hemangiomas
Onset	Always present at birth	Usually develop after birth
Evolution	Growth proportionate to growth of child and then persists (except salmon patch)	Initial growth and then involution
Skeletal defects	Frequent	Infrequent

- ❖ Is a CM.

Clinical features

- ❖ Present at birth.
- ❖ Light pink to deep red telangiectatic macules, which become darker and may develop nodularity over period of time.
- ❖ Face is the commonest site (Fig. 17.35).

Variants

- ❖ **Sturge–Weber syndrome:**
 - Trigeminal port-wine stain.
 - Associated with vascular hamartomas of the central nervous system (manifesting as seizures) and eyes (manifesting as glaucoma).
- ❖ **Phakomatosis¹⁰ pigmentovascularis:** Combination of:
 - CM.
 - Pigmented nevi of various types.

Treatment

- ❖ **Cosmetic camouflage.**
- ❖ **Lasers:** Pulsed tunable dye laser gives satisfactory result.

10. **Phakomatosis:** refers to a developmental malformation simultaneously affecting eye, skin, and central nervous system.

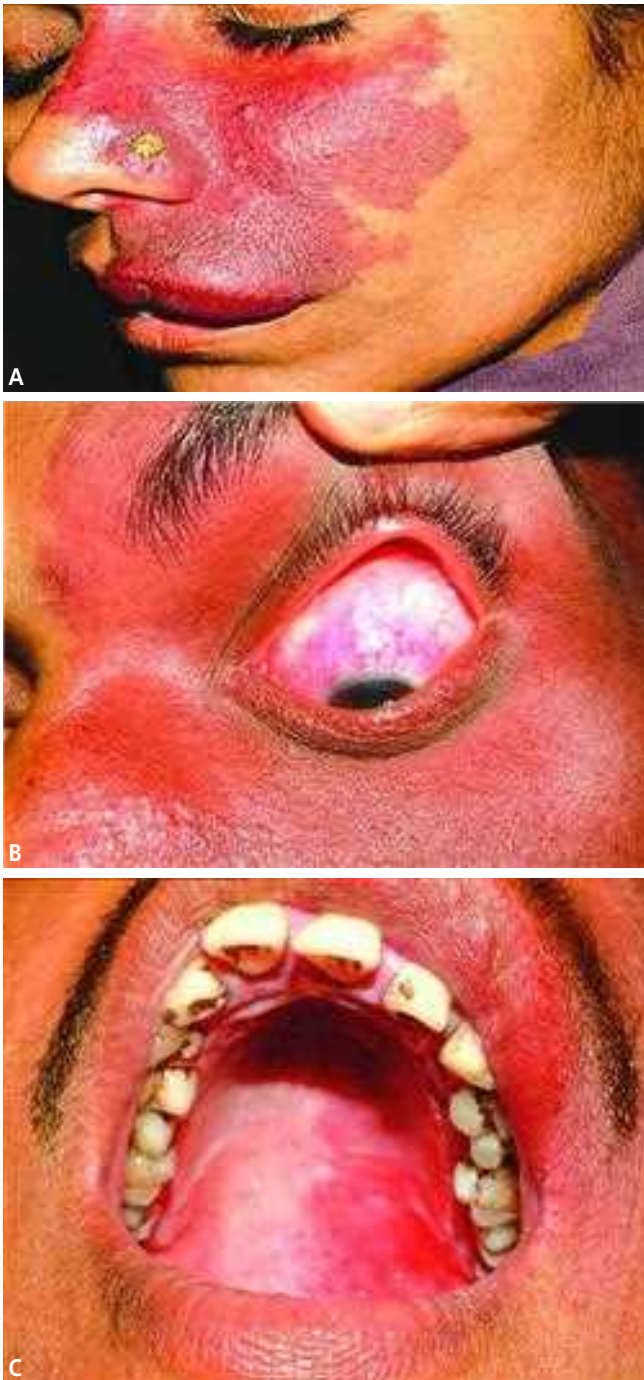

Fig. 17.35. Port-wine stain: A: deeply erythematous, telangiectatic slightly bosselated lesion on the face. Usually present at birth. B: involvement of eyes. C: mucosal lesions.

Venous malformations (VM)

- ❖ Are slow-flow anomalies due to presence of abnormal venous network.
- ❖ **Symptoms:** Include pain, swelling, and cosmetic disfigurement. Larger malformations lead to differences in limb girth.

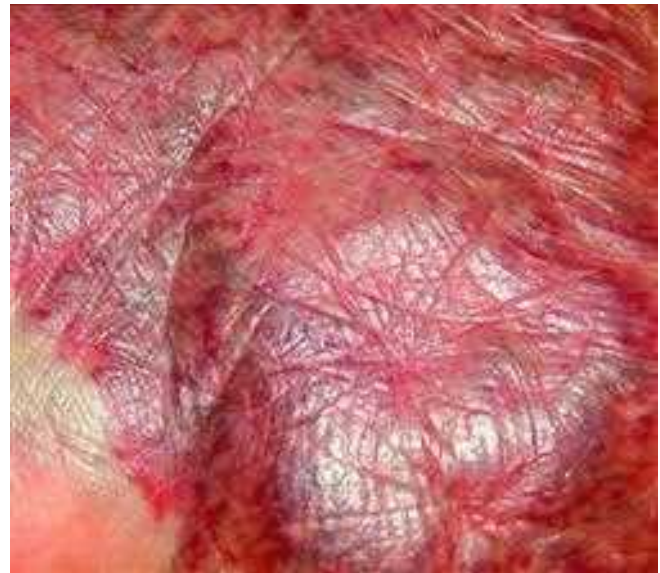

Fig. 17.36. Venous malformation: a soft compressible bluish swelling, which increases in size when dependent.

- ❖ **Morphology:** Characterized by a soft, compressible skin colored or bluish, flat or elevated lesion, which increases in size when dependent or during exercise (Fig. 17.36). No thrill/bruit; not warm to touch.
- ❖ **Sites:** Usually segmental in distribution. May occur at multiple sites.
- ❖ **Associations:** An important association is intravascular coagulopathy. So coagulation studies are routinely recommended in extensive VM.
- ❖ **Syndromes:**
 - *Maffucci's syndrome:* association of cutaneous VM with enchondromas.
- ❖ **Treatment:** Sclerotherapy and surgery.

Arteriovenous malformations (AVM)

- ❖ Most common high-flow vascular malformation, but still uncommon.
- ❖ Composed of direct communication between arteries and veins.
- ❖ **Onset:** Present at birth may remain stable for years. Common triggers for expansion include trauma, puberty, and pregnancy.
- ❖ **Morphology:** Warm, erythematous or skin colored, flat or elevated lesion with a palpable thrill, and audible bruit.
- ❖ **Sites:** Head commonest site.
- ❖ **Complications:** Ulceration and deformities.
- ❖ **Treatment:** Embolization.

Lymphatic malformations

Etiology

- ❖ **Onset:** Usually present at birth.
- ❖ **Morphology:** Characterized by a cluster of thin-walled vesicles (resembling frog spawn). Many have a deeper subcutaneous or a hemangioma-tous component (Fig. 17.37A).
- ❖ **Sites:** Trunk. Sometimes mucosal lesions (Fig. 17.37B).
- ❖ **Differential diagnosis:** Lymphangiectasis secondary to lymphedema should be differentiated.
- ❖ **Treatment:** Surgery, CO₂ laser, and radio frequency ablation.

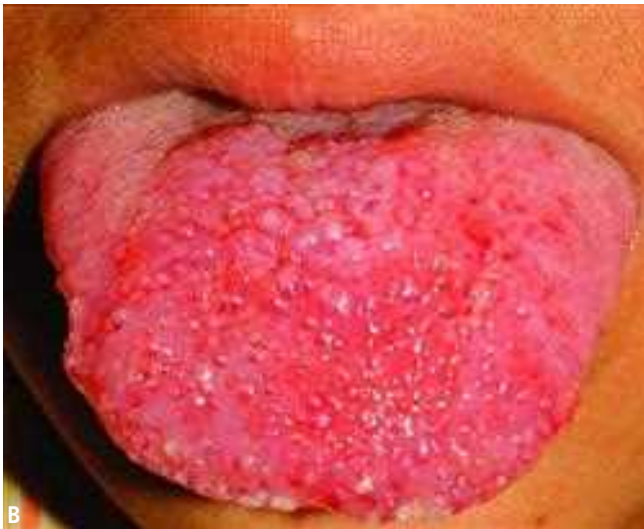
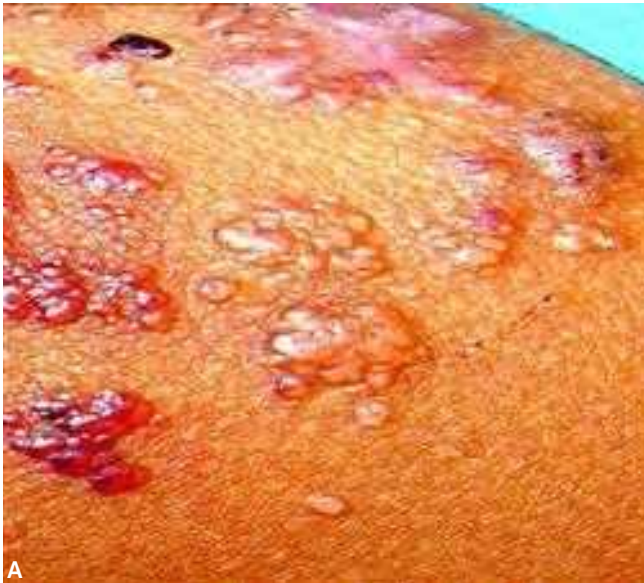
Fig. 17.37. Lymphangioma circumscriptum: A: cluster of thin-walled vesicles. Note some vesicles are filled with blood. B: lesions in buccal mucosa.

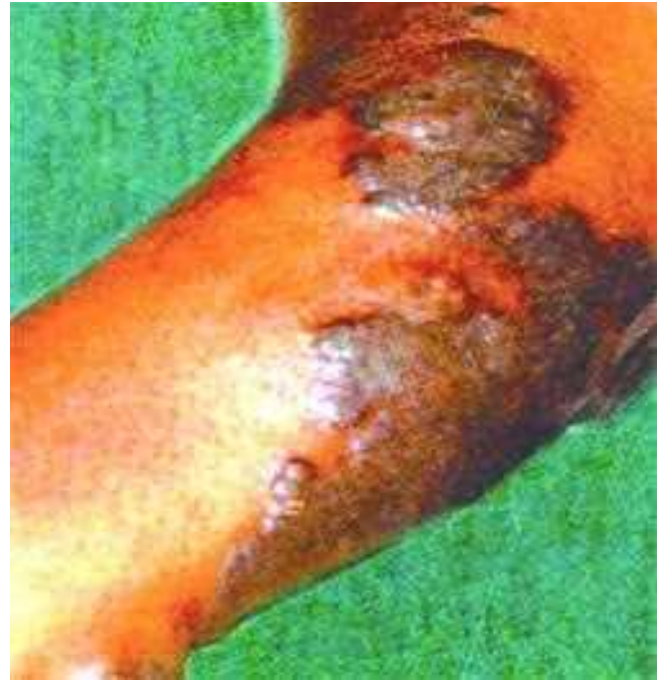

Fig. 17.38. Klippel-Trenaunay syndrome: vascular malformation, venous varicosities with soft-tissue hypertrophy.

Mixed malformations

- ❖ Combination of CM, VM, and AVM.
- ❖ Several syndromes recognized:
 - *Klippel-Trenaunay syndrome:* consists of:
 - Port-wine stain, less frequently other vascular malformations.
 - Venous varicosities.
 - Arteriovenous fistulae (sometimes microscopic connections in the long bones).
 - Soft tissue and occasionally bone hypertrophy may develop over period of time (Fig. 17.38).
 - *Parkes-Weber syndrome:* may be associated with a variety of vascular changes.
- ❖ Lower extremities; less frequently upper extremities.

Verrucous hemangioma

- ❖ Are congenital vascular anomalies which develop a rough and warty surface.
- ❖ Are usually present at birth but may appear in adulthood.
- ❖ In early phase of evolution, lesions are non-keratotic, soft, blue/red plaques, but gradually become increasingly hyperkeratotic.
- ❖ Commonly found on legs (Fig. 17.39). May be linear, multiple or disseminated and sometimes confined to digits.

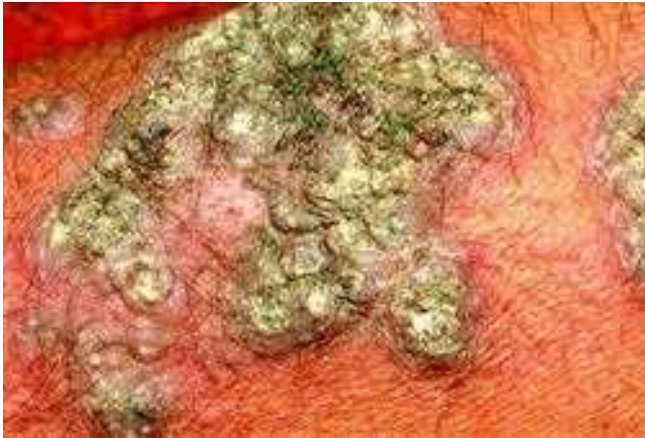

Fig. 17.39. Verrucous hemangioma: hyperkeratotic red plaques.

Infantile hemangioma

- ❖ **Synonym:** Nevus vasculosus.
- ❖ Is a capillary hemangioma.

Clinical features

- ❖ **Morphology:** Soft, brightly red (strawberry colored) nodule with pale stippling indicating resolution (Fig. 17.40A). When the lesion has involuted completely, it leaves an area of normal skin or slight atrophy.
- ❖ **Site:** Face and neck.
- ❖ **Complications:** Frequent:
 - Large swellings near orifices (oral, nasal, anogenital) interfere with function.
 - Bleeding may follow trauma.
 - Ulceration especially in large lesions (Fig. 17.40B) and in intertriginous area.
- ❖ **Course:** Lesion appears within a few weeks of birth and grows for a few months. Spontaneous regression¹¹ occurs with minimal atrophy in most patients.

Treatment

- ❖ **Small lesions:** Resolve spontaneously.
- ❖ **Large symptomatic lesions:** Lesions which interfere with feeding, breathing, vision, etc. or if they sequestrate platelets need to be treated.
 - *Systemic steroids:* help in the proliferative phase.
 - *Propranolol:* response dramatic in proliferative phase.

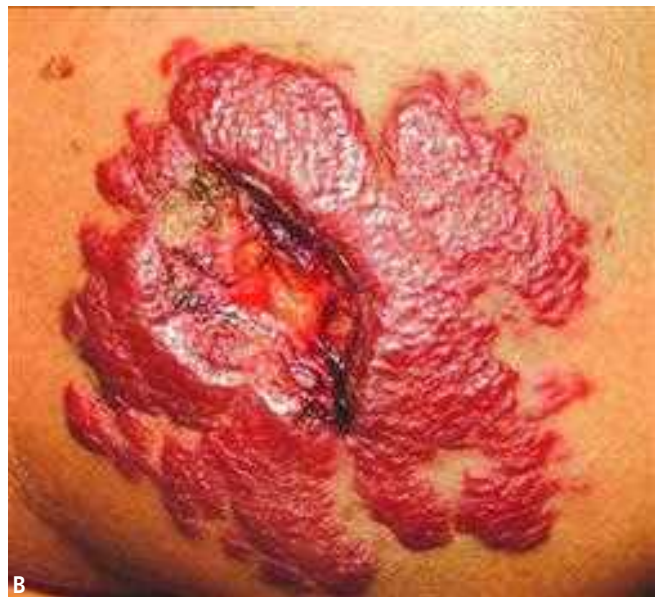
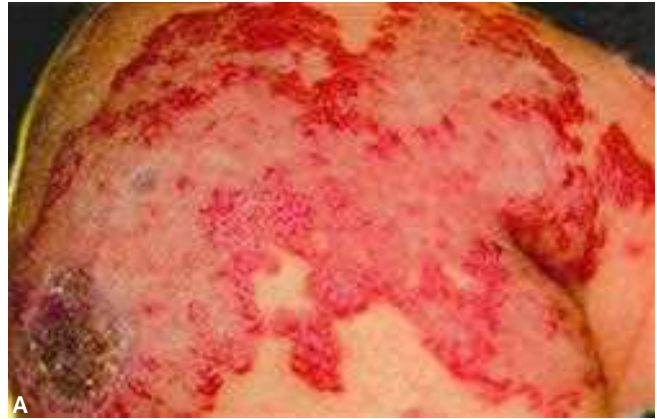
Fig. 17.40. Infantile hemangioma: A: large erythematous plaque that shows stippling and areas of spontaneous resolution. B: This one has ulcerated.

- **Lasers:** pulsed tunable dye laser in residual lesions.

Benign acquired hemangioma

- ❖ **Synonym:** Granuloma pyogenicum¹²

Clinical features

- ❖ **Morphology:** Characterized by a bright red, raised, sometimes pedunculated lesion which bleeds easily. A distinct collar is usually present at the base of the pedicle (Fig. 17.41A).
- ❖ **Sites:** Sites of trauma.

11. **Regression:** rule of the thumb: by 5 years of age, 50% of the lesion would have regressed and by 9 years of age, 90% of the lesion would have involuted.

12. **Granuloma pyogenicum:** is a misnomer because it is neither a granuloma nor is it pyogenic in origin.

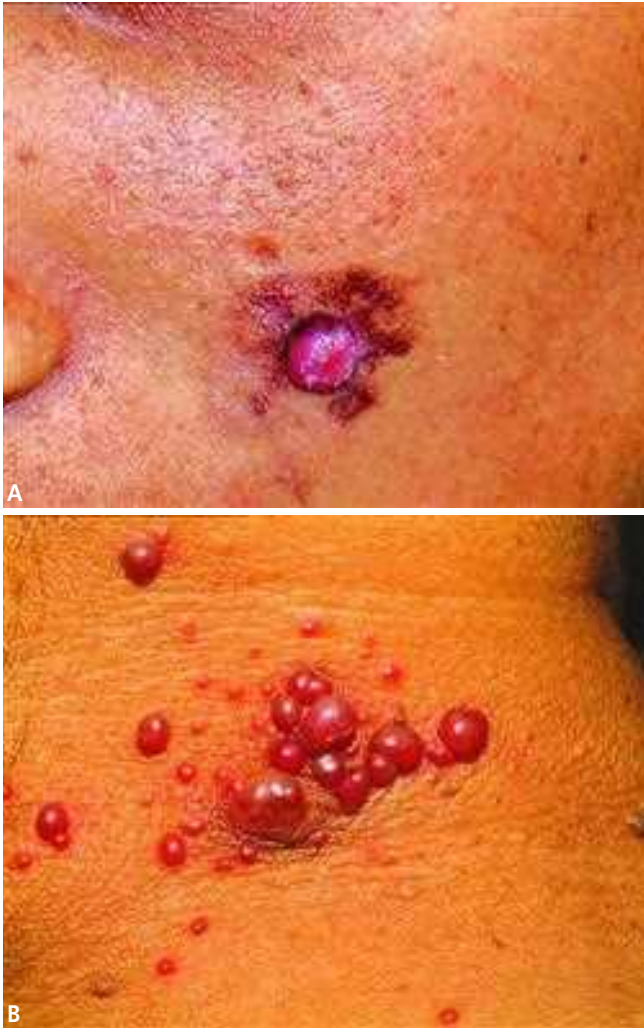

Fig. 17.41. Granuloma pyogenicum: A: bright red nodule with a short pedicle which has a collar at the base. B: multiple satellite lesions occurring around a cauterized granuloma pyogenicum.

Treatment

Curette the lesion and cauterize the base. Sometimes may recur at the same site or as satellite lesions (Fig. 17.41B).

Keloid

Etiology

Abnormal response of skin to trauma (sometimes trivial and forgotten) in predisposed individuals.

Predisposing factors

- ❖ **Ethnic background:** More in Negroids.
- ❖ **Type of wound:** Infected traumatic wounds. Surgical wounds not along skin creases.

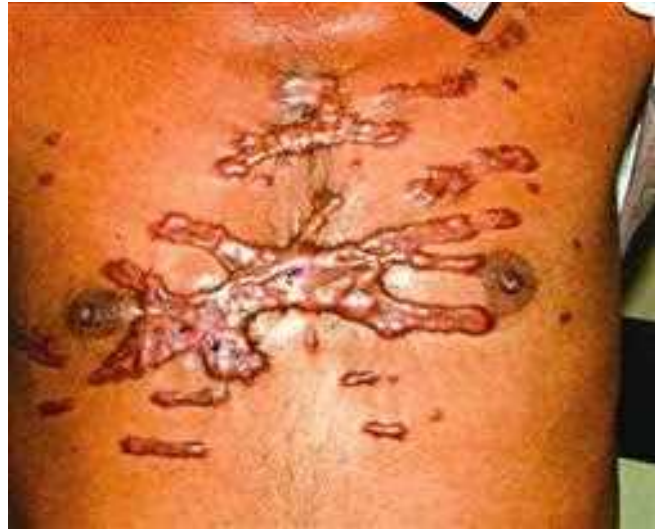

Fig. 17.42. Keloid: irregular firm-hard nodule with claw-like projections in presternal area; patient denied history of trauma.

- Insect bites.
- Acne lesions.

Clinical features

Morphology

Itchy, irregular firm nodules and plaques, often with claw-like projections (Fig. 17.42).

Sites

Presternal area, neck, upper back, and deltoid region.

Treatment/Intralesional

- ❖ Topical steroids.
- ❖ Cryotherapy, an effective alternative.
- ❖ Surgical removal, usually associated with relapses.

Leiomyoma

- ❖ Tumor of smooth muscles.
- ❖ Uncommon.
- ❖ Familial.
- ❖ Usually multiple, may be single.
- ❖ Painful and tender; erythematous or skin colored nodules (Fig. 17.43). Pain on exposure to cold and touch.
- ❖ Trunk and extremities.
- ❖ Excision. Pain relief with nifedipine.

Lipoma

- ❖ Tumor of adipose tissue.

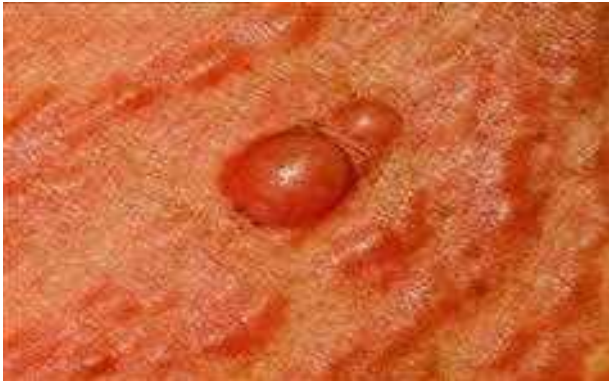

Fig. 17.43. Leiomyoma: painful, erythematous soft-firm nodule. Note the multiplicity of lesions.

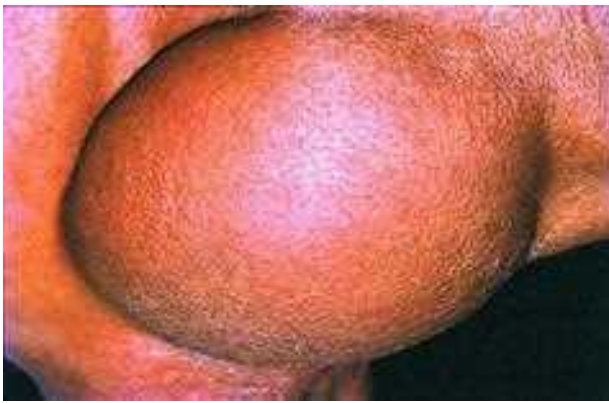

Fig. 17.44. Lipoma: soft, lobulated subcutaneous nodule.

- ❖ Common.
- ❖ Usually multiple sporadic or hereditary. Or single (Fig. 17.44).
- ❖ Asymptomatic, soft slippery, lobulated subcutaneous nodules. Better felt than seen. Angiolipoma is painful.
- ❖ Remove symptomatic lesions.

Dermatofibroma

- ❖ Benign tumor of fibrous tissue.
- ❖ Uncommon.
- ❖ Single, firm (button-like), well-defined dermal nodule (Fig. 17.45A), which appears larger on palpation than on inspection. Typical dimpling on pinching (Fig. 17.45B).
- ❖ Most frequently seen on limbs.
- ❖ Best left alone (treatment of choice). Excise if in doubt.

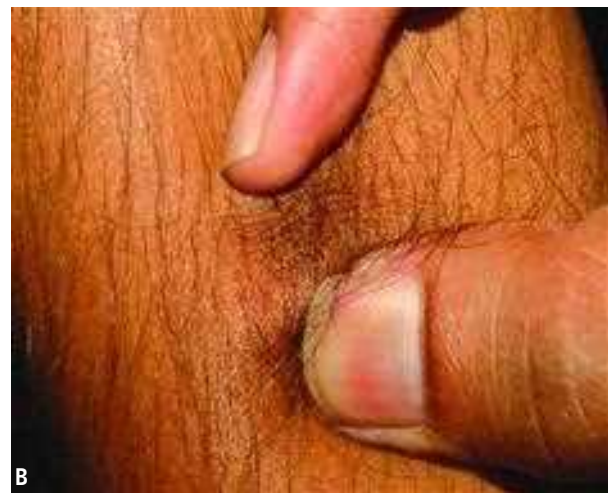
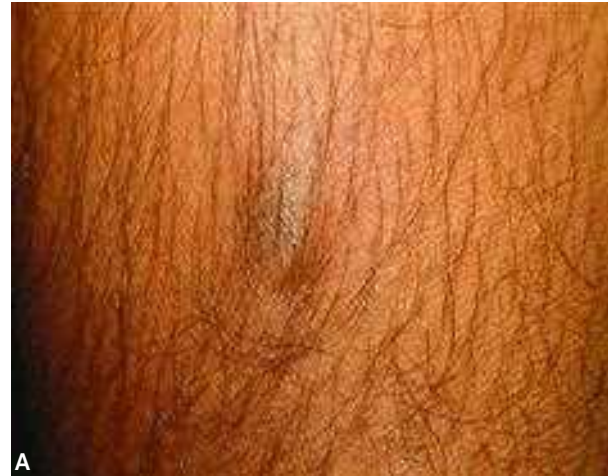
Fig. 17.45. Dermatofibroma: A: well-defined, firm nodule which appears larger on palpation than on inspection. B: dimpling on pinching.

Malignant Tumors of Dermis

Cutaneous T Cell Lymphoma (*Mycosis Fungoides*)

Synopsis

Etiology: Lymphoma of helper T cells.

Clinical features: Initial *patch stage* of well-defined, bizarre shaped, atrophic patches; later infiltrated *plaque stage* and then *tumor stage* with aggressive course. Sometimes *de novo*¹³ appearance of tumors.

Histology: Characteristic histology with presence of atypical cells; epidermotropism¹⁴ may be marked.

Treatment: *Early stage:* Topical steroids, topical nitrogen mustard, PUVA, acitretin and electron beam treatment. *Tumor stage:* Chemotherapy.

13. **De novo:** from the beginning.

14. **Epidermotropism:** migration of malignant cells into the epidermis.

Mycosis fungoides (MF) is a lymphoma (of helper T lymphocytes) of skin.

Etiology

The exact etiology of cutaneous T-cell lymphoma is not known, but infection with human T-cell lymphoma-leukemia virus, (HTLV-I) is associated with clinically aggressive cutaneous T-cell lymphoma.

Clinical features

Morphology

Three clinical stages of MF are recognized:

- ❖ **Patch stage:** Barely palpable, minimally erythematous, pigmented, well-defined “patches”. May have geographic shapes. There may be cigarette paper atrophy and **poikiloderma**¹⁵.
- ❖ **Plaque stage:** Some areas of lesion become infiltrated and this may be associated with itching (Fig. 17.46A).
- ❖ **Tumor stage:** Firm to hard nodules usually appear on the plaques (Fig. 17.46B), but may arise *de novo* (**tumor d’emblée**). Nodules may ulcerate. The tumor stage is usually rapidly progressive.

Sites of predilection

Covered parts.

Lymph node involvement

Lymphadenopathy in cutaneous T-cell lymphoma could be:

- ❖ Reactive (less sinister).
- ❖ Or due to infiltration with T cells (more sinister).

Variants

- ❖ **Sezary syndrome:** Is erythrodermic variant of MF. Consists of a triad of:
 - Generalized cutaneous erythema (erythroderma) and edema with extreme pruritus.
 - Lymphadenopathy.
 - **Sezary cells** (abnormal lymphocytes with large convoluted nuclei) circulating in blood.

Investigations

To establish the diagnosis

- ❖ **Biopsy:** Histopathology shows collection of atypical lymphocytes (**Pautrier’s microabscesses**) in epidermis (a feature of epidermo-

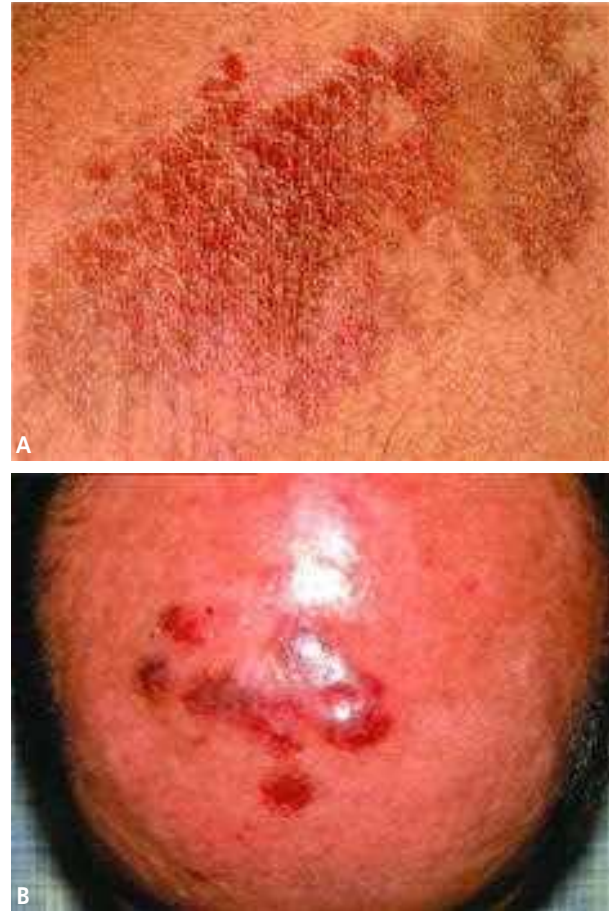

Fig. 17.46. Mycosis fungoides: A: plaque stage: erythematous plaques. B: tumor stage: firm to hard nodules which often ulcerate.

tropism) and band of lymphoid (some atypical) cells in the upper dermis.

- ❖ **Immunophenotyping:** Of skin biopsy.

To stage the disease (Table 17.9)

- ❖ Complete hemogram.
- ❖ Evaluation of lymph node involvement.
- ❖ Evaluation of visceral involvement.

Diagnosis

Points for diagnosis

Diagnosis of MF is based on:

- ❖ Chronicity of lesions and poor response to conventional therapy.
- ❖ Lesions predominantly on covered parts.
- ❖ **Characteristic stages:** Well-defined patches of bizarre shapes with cigarette paper atrophy;

15. **Poikiloderma:** triad of atrophy, pigmentation and telangiectasia.

Table 17.9. TNM staging of MF

Classification	Description
T: Skin	
T ₀	Patches clinically and histologically suggestive of MF
T ₁	Papules/plaques/patches involving <10% of BSA*
T ₂	Papules/plaques/patches involving >10% of BSA*
T ₃	Tumors
T ₄	Erythroderma
N: Lymph nodes (LN)	
N ₀	No palpable LN, histopathology negative
N ₁	Palpable LN, histopathology negative
N ₂	No palpable LN, histopathology positive
N ₃	Palpable LN, histopathology positive
B: Peripheral blood	
B ₀	Atypical cells in circulation, absent or <5%
B ₁	Atypical cells in circulation >5%
M: Visceral involvement	
M ₀	Visceral involvement negative
M ₁	Visceral involvement positive

*BSA: body surface area.

indurated itchy plaques and nodules which often ulcerate.

❖ **Typical histology:** Intraepidermal collection of atypical lymphocytes (**Pautrier's microabscesses**) a feature of epidermotropism and a band of lymphoid cells, some atypical, in the upper dermis.

Differential diagnosis

The early stages of MF need to be differentiated from tinea corporis (fungal infection) and psoriasis.

Treatment (Table 17.10)

Table 17.10. Basics of treatment of MF

Patch stage (Good response)	Potent topical corticosteroids Ultraviolet B Psoralens + UVA (PUVA)
Plaque stage (Moderate response)	Electron beam therapy PUVA Acitretin Topical nitrogen mustard
Tumor stage (Poor response)	Low-dose radiation for individual lesions Chemotherapy

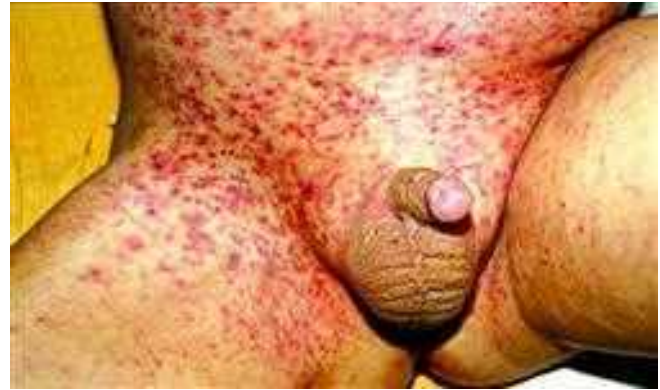

Fig. 17.47. Langerhans' cell histiocytosis: erythematous and purpuric papules in seborrheic distribution.

Langerhans' Cell Histiocytosis

- ❖ Also called **Letterer Siwe disease**.
- ❖ Uncommon.
- ❖ Single organ. Or multiple organ disease.
- ❖ Infants.
- ❖ **Skin lesions:**
 - **Morphology:** greasy, yellow-brown scaly papules, often purpuric (Fig. 17.47).
 - **Distribution:** seborrheic distribution (scalp, major flexures, and trunk).
- ❖ **Systemic features:** Diabetes insipidus, osteolytic bone lesions, and otitis media.
- ❖ **Treatment:** Chemotherapy.

Reticuloendothelial Malignancies

Leukemias

- ❖ Leukemic deposits in skin are rare. They appear as deeply erythematous (plum colored in fair individuals) papules, nodules, and plaques.
- ❖ Nonspecific cutaneous manifestations of leukemia may be seen in the form of pruritus, ichthyosis, and infections (herpes zoster).

Hodgkin's disease

- ❖ Most frequent manifestations of Hodgkin's disease in skin are nonspecific in the form of generalized pruritus (frequent) and acquired ichthyosis (less frequent).
- ❖ Rarely, cutaneous involvement is seen as small papules and ulcers.

B cell lymphoma

- ❖ Infrequent tumor.
- ❖ Rarely presents in the skin. Plum-colored nodules.

Kaposi's Sarcoma (KS)

Synopsis

Etiology: Role of human herpes virus 8 suggested.

Clinical features: Several variants described, the most well-known being epidemic KS seen in HIV-positive homosexual patients. Bruise-like lesions should always be biopsied in HIV-positive patients. Poor prognosis due to associated opportunistic infections.

Treatment: Radiotherapy, cryotherapy.

Etiology

- ❖ Is a multifocal malignant tumor of proliferating capillaries and lymphatics.
- ❖ Recent evidence suggests a role of Human herpes virus 8 in pathogenesis of KS.

Clinical features

Four clinical variants (Table 17.11):

- ❖ **Classical KS.** } in immunocompetent.
- ❖ **Endemic KS.** }
- ❖ **KS in iatrogenically immunosuppressed patients.** } in immunosuppressed.
- ❖ **Epidemic HIV-associated KS.** }

Table 17.11. Clinical features of Kaposi's sarcoma

	<i>KS in immunocompetent</i>	<i>KS in immunosuppressed</i>
Epidemiology	Elderly Jews (classical KS), Africans (endemic KS)	Most frequent in HIV-positive homosexuals (epidemic KS)
Site	Cold parts (ankles, feet, hands, ears, and nose)	Anywhere; frequent on upper trunk, head, and neck. Oral mucosal lesions frequent
Morphology	Dark blue to purple macules; tumors ulcerate and fungate	Bruise-like macules, nodules and plaques
Prognosis	Not too bad!	Poor, as associated opportunistic infections present

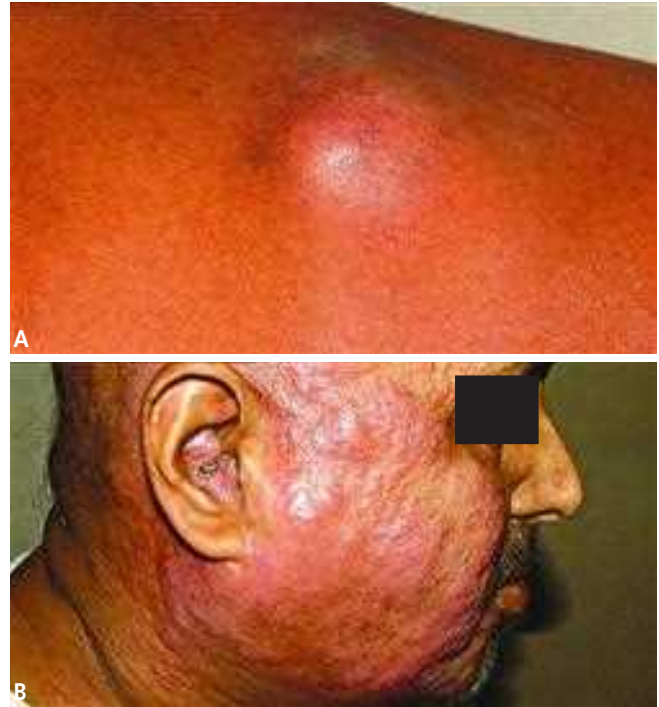

Fig. 17.48. Metastases in skin: A: skin colored to erythematous firm-hard single nodule. B: erythematous firm-hard multiple nodules and plaques.

Treatment

- ❖ **Single lesion:** Radiotherapy.
Cryotherapy.
Intralesional vinblastine.
- ❖ **Multiple lesions:** α interferon.

Cutaneous Metastases

- ❖ Less than 5% of internal cancers reach the skin, usually in terminal stages, indicating a grave prognosis.
- ❖ Malignancies which deposit secondaries in skin are breast (which may spread directly to skin also), lungs, gastrointestinal tract (colon, then stomach), uterus, prostate, and kidneys.
- ❖ Manifests as single (more frequent)/multiple (less frequent) skin-colored/erythematous nodules (Fig. 17.48A) and plaques (Fig. 17.48B).
- ❖ Scalp, face, and umbilicus¹⁶ are the most frequent sites of metastatic deposits.

16. **Umbilicus:** Sister Joseph's nodule related to bowel tumors.

Cutaneous Manifestations of Internal Diseases

18

Chapter Outline

Skin and Endocrine Disease

- Diabetes mellitus
- Thyroid disorders
- Pituitary disorders
- Adrenal disorders
- Skin and renal diseases
- Skin in liver disease

Skin and Metabolic Diseases

- Porphyrias
- Xanthomas

Skin Changes, Malnutrition, and Malabsorption

- Protein-energy malnutrition
- Vitamin A deficiency
- Riboflavin deficiency
- Nicotinic acid deficiency
- Vitamin C deficiency
- Zinc deficiency
- Essential fatty acid deficiency

Skin and Internal Malignancies

- Cutaneous metastases
- Genodermatoses and internal malignancies
- Exposure to carcinogens
- Paraneoplastic diseases

Introduction

This very important aspect of Dermatology can only be scanned in this book. It may, however, be worthwhile to remember that patients with internal disease sometimes first present to the Dermatologist who may on suspicion (and sometimes confirmation) of the systemic disease refer the patient to the appropriate department.

The cutaneous manifestations of internal disease will be briefly discussed in this chapter under the heads:

- ❖ Skin and endocrine disease.
- ❖ Skin and renal disease.
- ❖ Skin and liver disease.
- ❖ Skin and metabolic disease.
- ❖ Skin and malnutrition and malabsorption.
- ❖ Skin and internal malignancies.

Skin and Endocrine Disease

Diabetes Mellitus

There are several cutaneous manifestations of diabetes (Table 18.1).

Table 18.1. Cutaneous manifestations of diabetes

Infections: Pyogenic, candidal
Diabetic dermopathy
Acanthosis nigricans
Necrobiosis lipoidica
Granuloma annulare
Other dermatoses: <i>xanthomas, neuropathic foot ulcers, sclerodactyly</i>

Infections

Infections are a feature of poorly controlled or undiagnosed diabetes and respond to appropriate therapy.

◦ Good to know

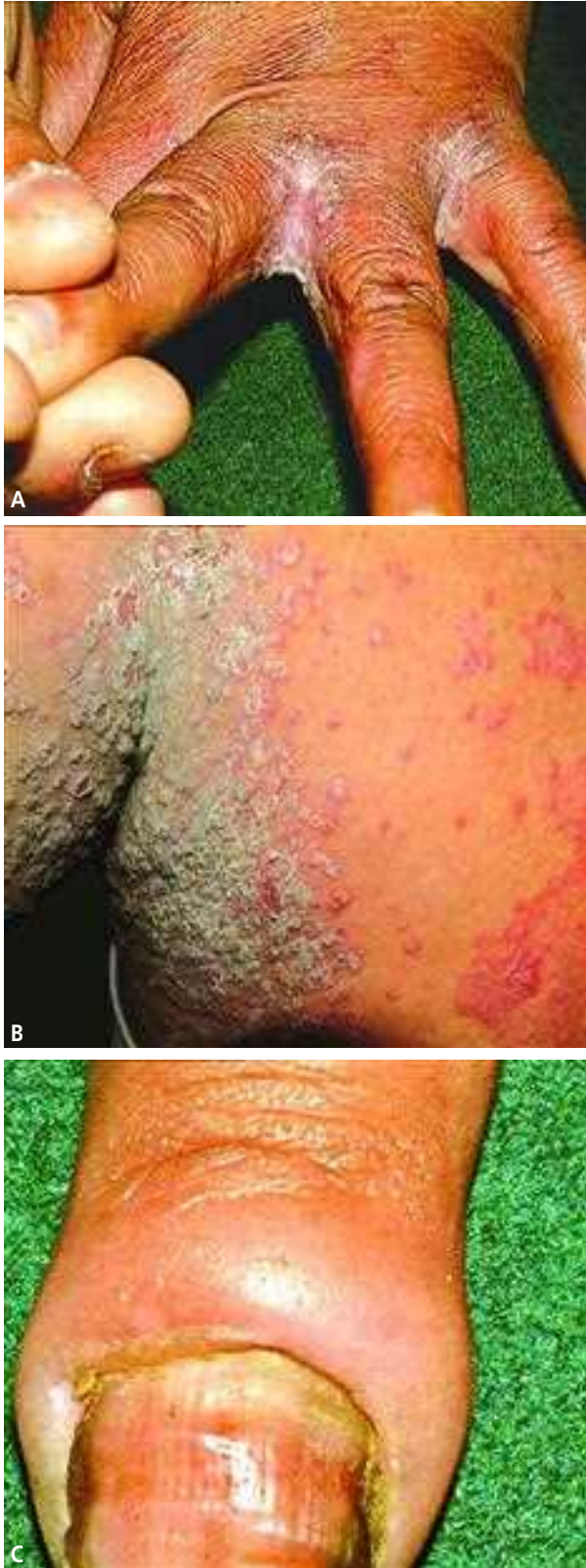

Fig. 18.1. Candidal infection in diabetes: A: candidal intertrigo, in between the fingers. B: candidal intertrigo, in axilla. C: candidal paronychia: rolling of proximal nail fold.

Candidal infection

- ❖ Candidal infection is more frequent in diabetics, especially in women. It also tends to be recurrent and more extensive in patients with diabetes.
- ❖ Candidal intertrigo (groins, interdigital, and inframammary), paronychia, vulvovaginitis, and balanoposthitis may be the presenting manifestations of undiagnosed diabetes (Fig. 18.1).
- ❖ May require oral therapy with weekly fluconazole, especially if recurrent.

Pyodermas

- ❖ Staphylococcal pyodermas, like recurrent furuncles and carbuncles (Fig. 18.2) are commonly present. Also *Strep. hemolyticus* infections.
- ❖ Furuncles most frequently on the shins, forearms, and gluteal region. Carbuncle on the back.
- ❖ Infections tend to be recurrent and more extensive.
- ❖ Require aggressive treatment with systemic antibiotics.

Diabetic Dermopathy

- ❖ Most common dermatosis associated with diabetes.
- ❖ Begins as small, dull red papules with a superficial scales; slowly resolve to leave small, brown, depressed scars (Fig. 18.3).
- ❖ Shins.

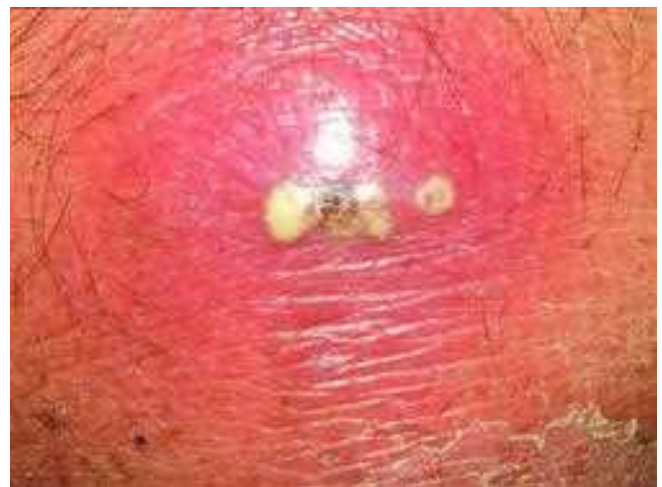

Fig. 18.2. Carbuncle: staphylococcal infection of contiguous hair follicles, about to rupture at several points.

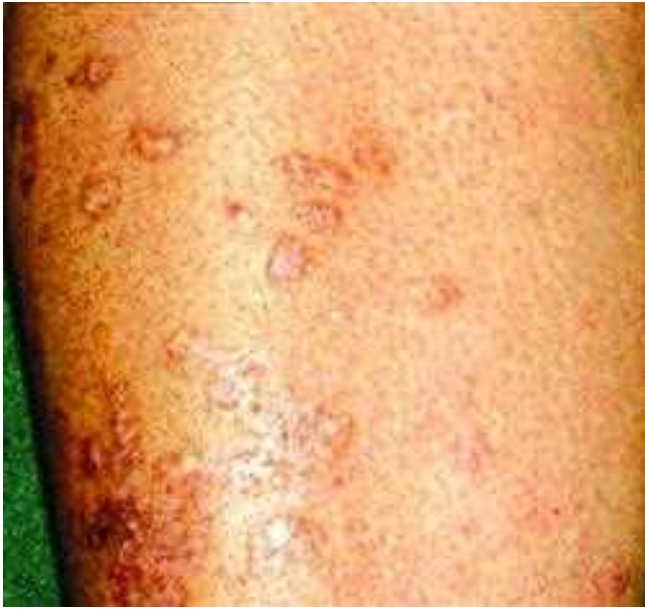

Fig. 18.3. Diabetic dermopathy: small, dull, red papules with superficial scales; resolve to form superficial pigmented scars.

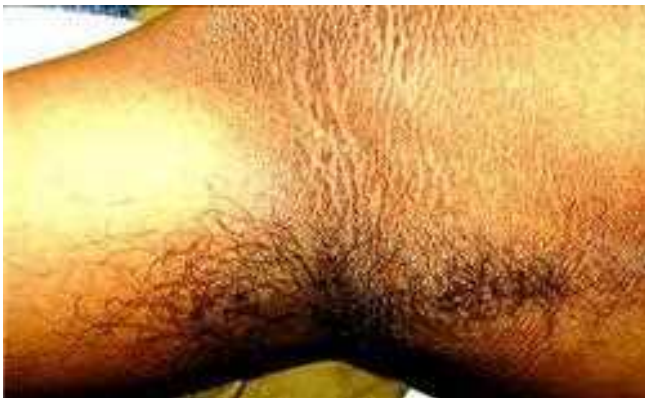

Fig. 18.4. Acanthosis nigricans in diabetes: velvety, hyperpigmented plaques in major flexures.

Acanthosis Nigricans¹

- ❖ Manifestation of insulin-resistant diabetes.
- ❖ Characterized by presence of velvety, hyperpigmented plaques with a feathered edge (Fig. 18.4).
- ❖ Axillae, inguinal region, and inframammary folds.

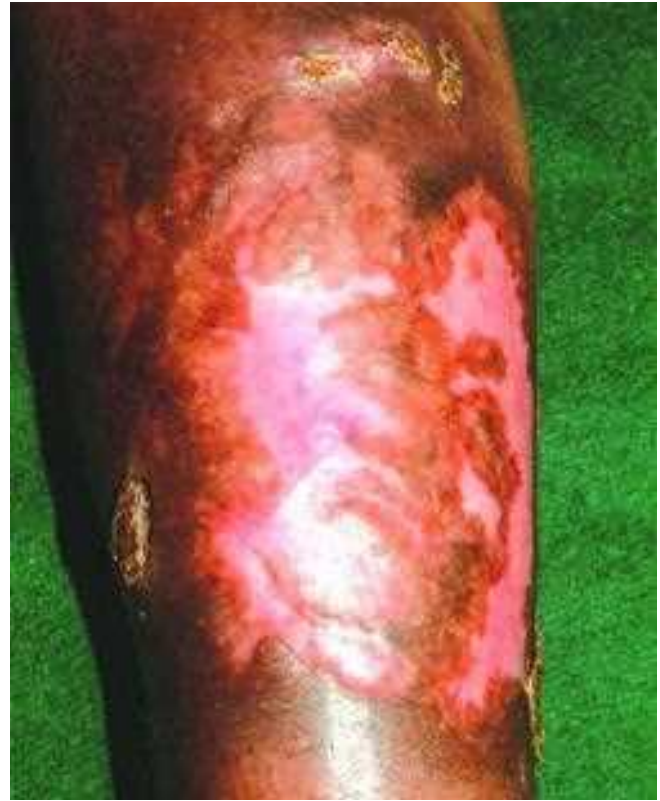

Fig. 18.5. Necrobiosis lipoidica: asymptomatic, indurated annular, yellowish brown plaque(s). Center is atrophic with ectatic blood vessels visible through the thinned skin. May ulcerate.

Necrobiosis Lipoidica

- ❖ Most patients with necrobiosis have diabetes, but less than 2% of diabetics develop necrobiosis lipoidica.
- ❖ Presents as single or multiple, asymptomatic, indurated annular, yellowish brown plaque(s). Center is atrophic with ectatic blood vessels visible through the thinned skin (Fig. 18.5).
- ❖ Shins.

Granuloma Annulare

- ❖ Association of diabetes and granuloma annulare is controversial.
- ❖ Skin colored or erythematous dermal papules arranged in an annular pattern (Fig. 18.6).
- ❖ Most frequently seen on pressure points, like knuckles and dorsal aspect of hands.

1. **Acanthosis nigricans:** the commonest cause of acanthosis nigricans is obesity, when it is associated with skin tags and was earlier called pseudacanthosis nigricans. Other causes of acanthosis nigricans include endocrinopathies (acromegaly, polycystic ovary disease) and internal malignancies (malignant acanthosis nigricans).

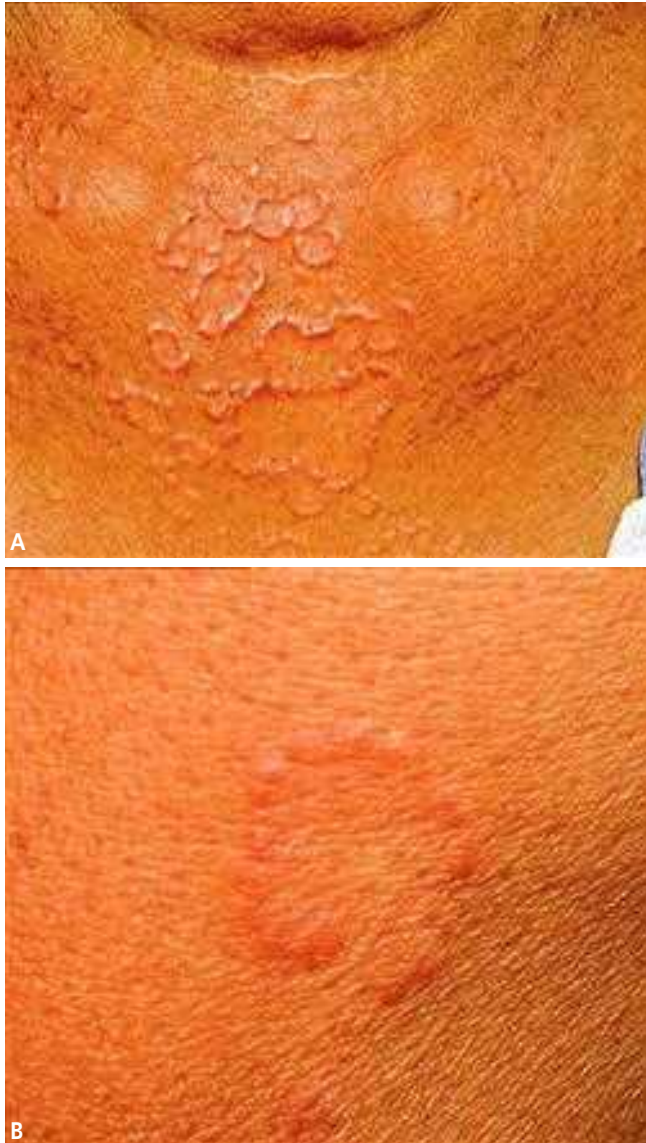

Fig. 18.6. Granuloma annulare: A: erythematous dermal papules, arranged in an annular configuration. B: close up view

Thyroid Disorders

Hypothyroidism

Hypothyroidism has the most striking cutaneous manifestations amongst all endocrine disorders:

- ❖ **Ichthyotic skin:** Resembles ichthyosis vulgaris (Fig. 18.7). Skin also dry, cold, and pale. May be first clinical manifestation of hypothyroidism.
- ❖ **Facies:** Broad nose, thick lips, and large, thick tongue. Upper lid may droop and the face appears expressionless.
- ❖ **Myxedema:** Podgy, nonpitting edema, which is generalized.

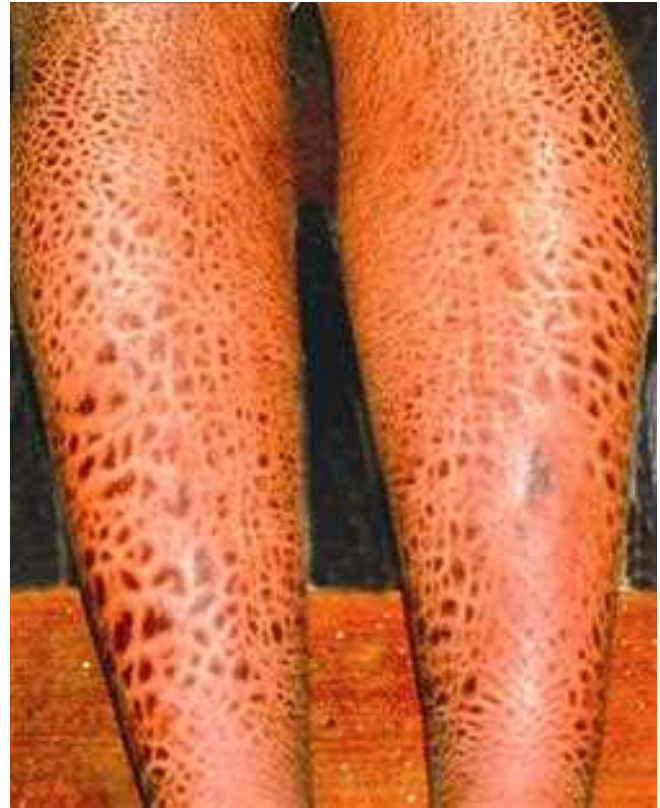

Fig. 18.7. Hypothyroidism: dry ichthyotic skin.

- ❖ **Hair:** Dry, coarse brittle hair. Follicular keratoses. Alopecia of scalp can be patchy or diffuse. Supraciliary madarosis of lateral third of eyebrows is typical.

Hyperthyroidism

- ❖ **Skin:** Cold, moist, smooth skin, best made out on palms and soles. Palmoplantar hyperhidrosis.
- ❖ **Flush:** Persistent flush of the face and palmar erythema.
- ❖ **Pigmentary changes:** Both hyperpigmentation of face and vitiligo are common associations.
- ❖ **Pretibial myxedema:** Asymmetric firm plaques with a “peau d’orange” appearance (Fig. 18.8).

Pituitary Disorders

Acromegaly

- ❖ **Etiology:** Acromegaly is due to excess secretion of growth hormone and is almost always due to a pituitary adenoma.
- ❖ **Cutaneous manifestations:** Cutaneous manifestations of acromegaly include:

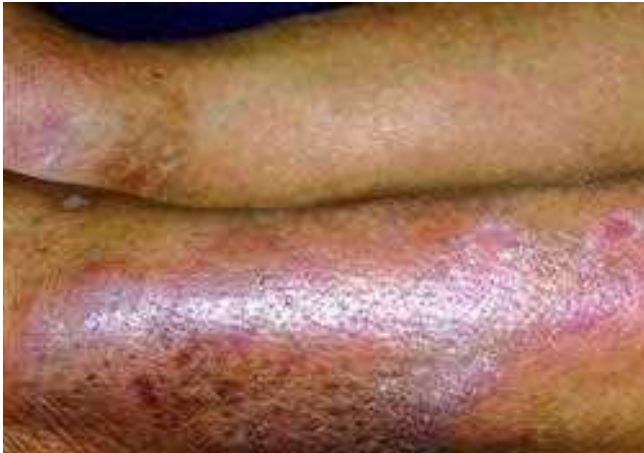

Fig. 18.8. Pretibial myxedema: asymmetric, firm plaques with a 'peau d'orange appearance.

- Coarsening of facial features, often resulting in corrugated appearance of forehead and scalp (**cutis verticis gyrata**).
 - Seborrhea.
 - Macroglossia.
 - Spade-like hands.
- ❖ These features need to be differentiated from **pachydermoperiostosis** (Figs. 18.9A and B).

Adrenal Disorders

Cushing's Disease/Syndrome

- ❖ **Cause:** Is due to chronic glucocorticoid excess and can be due to:
- Increased secretion of adrenocorticotrophic hormone (ACTH) by pituitary gland, *e.g.*, pituitary adenoma.
 - Increased secretion of corticosteroids by adrenal gland independent of adrenocorticotrophic hormone.
 - Iatrogenic, due to intake of steroids.
- ❖ **Cutaneous manifestations:** Seen include:
- **Central obesity:** manifesting as moon facies, buffalo hump, and pot belly. Usually associated with peripheral wasting.
 - **Striae distensae** (Fig. 18.10A): linear, erythematous atrophic lesions, seen most frequently on abdomen. Steroid-induced striae are typically wide and red.
 - **Skin atrophy:** with fragility, bruising, and poor healing.
 - **Facial changes:** moon facies, facial flushing, telangiectasia, and hypertrichosis/hirsutism.
 - **Hirsutism and hypertrichosis:** downy facial

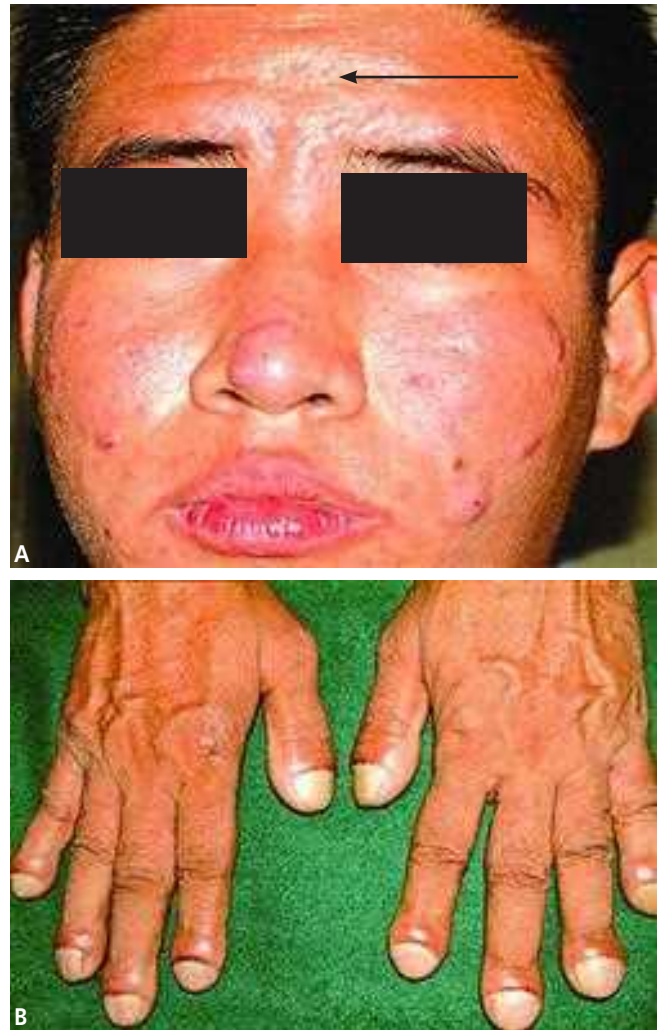

Fig. 18.9. Pachydermoperiostosis: A: typical facies with coarse features. Note beginning of folds on the forehead, B: clubbing and typical spade-like hands.

- hair in iatrogenic hypercorticism.
- **Acneiform eruption:** common. Steroid-induced acne are monomorphic with absence of comedones and cysts (Fig. 18.10B).
- **Addisonian pigmentation.**
- **Alopecia:** male-pattern baldness in women.
- **Infections:** like dermatophytic infections and candida. Often atypical (**tinea incognita**).

Adrenal Insufficiency

- ❖ **Cause:** Adrenal insufficiency can be:
- **Primary adrenal insufficiency:** also called **Addison's disease**, can be due to:
 - Autoimmune adrenalitis.
 - Genetic enzyme deficiencies.
 - Tuberculosis.

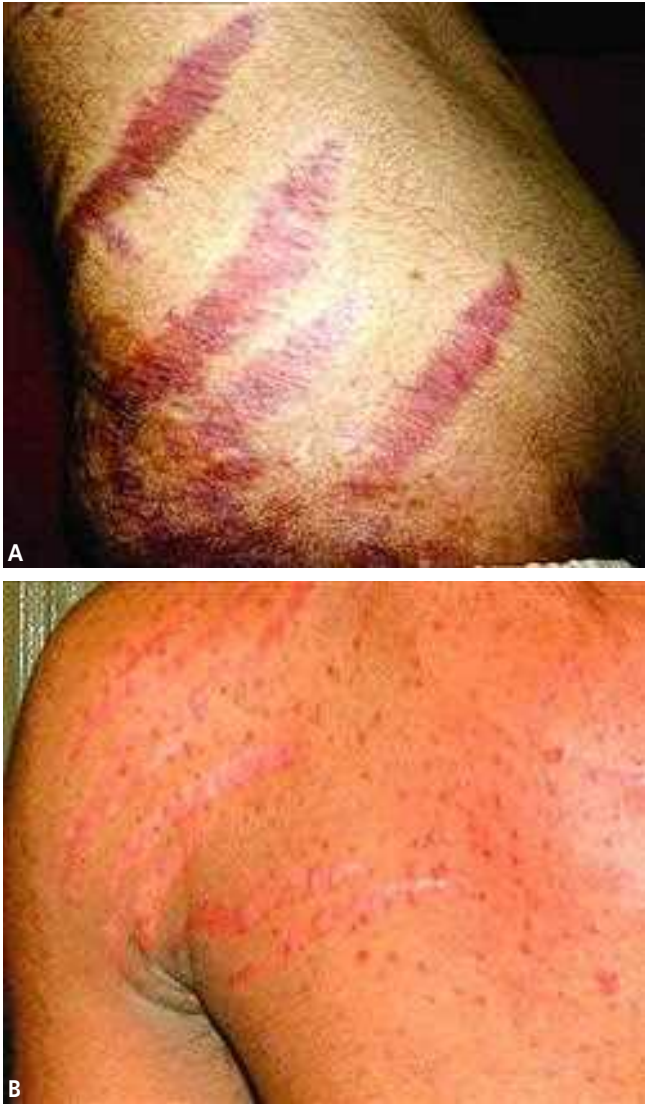

Fig. 18.10. Cushing's syndrome: A: striae: steroid-induced striae are typically wide and red. B: acneiform eruption: steroid-induced acne are monomorphic with absence of comedones and cysts.

- *Secondary adrenal insufficiency:* may occur due to hypothalamic or pituitary disease, leading to insufficient secretion of ACTH and consequently adrenal insufficiency.
- ❖ **Cutaneous manifestations: Pigmentation** of the skin is the most notable change.
 - May be the presenting feature in a third of patients.
 - Is due to excess ACTH secretion and so occurs in primary adrenal insufficiency.
 - Pigmentation reverses on institution of steroid therapy.

- Pattern of pigmentation could be:
 - An exaggeration of the normal pigmentation, seen especially on the photo-exposed areas and at sites of trauma—pressure points and areas of friction (**Addisonian pigmentation**).
 - Sometimes, chloasma-like pigmentation may be seen.
 - Mucosal pigmentation.
 - Pigmentation of nails

Skin and Renal Diseases

The main cutaneous changes in renal disorders are:

Skin

❖ *Nonspecific features:*

- *Pruritus:* responds to narrow band UVB, oral cholestyramine, and activated charcoal.
- Generalized xerosis of the skin.
- Sallow appearance of the skin, due to anemia.
- Purpura.

❖ **Perforating keratoses** (Fig. 18.11A): A variety of perforating keratotic lesions are seen. The central core falls off, leaving a crater.

❖ *Nephrogenic systemic fibrosis:*

- *Cause:* may be related to use of use of radio-contrast agents that contain gadolinium in patients with renal failure.
- *Cutaneous manifestations:* erythematous/yellowish indurated plaques with finger-like projections.
- *Systemic manifestations:* involvement of the diaphragm leading to death.

Nails

❖ **Half-and-half nails** (Fig. 18.11B): Pigmentation of distal half of the nail, while the proximal part remains pale.

Skin in Liver Disease

Hepatic diseases, especially when the patient has hepatic failure, is associated with:

- ❖ **Pruritus:** Due to accumulation of bile salts, when there is obstructive jaundice.
- ❖ **Yellowish pigmentation:** Due to accumulation of bile pigments.

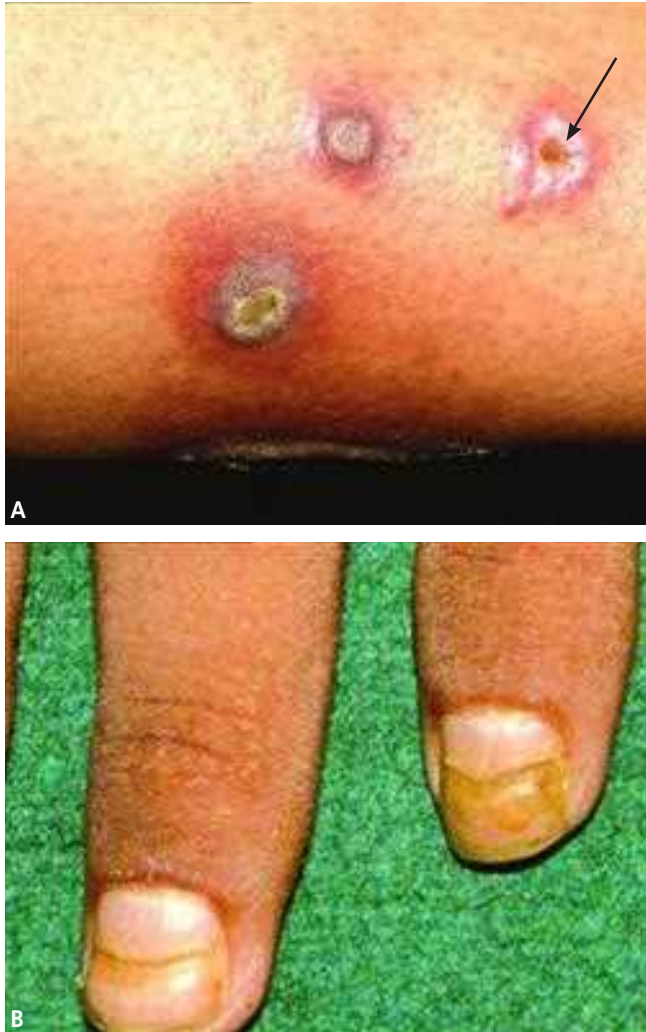


Fig. 18.11. Renal failure: A: perforating keratoses: hyperkeratotic papules with central core. Note crater where the central core has fallen. B: half-and-half nails.

- ❖ **Spider nevi and palmar erythema:** Due to accumulation of estrogen and progesterone.
- ❖ **White nails:** Due to hypoproteinemia.

Skin and Metabolic Diseases

Porphyrias

Porphyrias are heterogeneous group of disorders characterized by a partial deficiency of one of the many enzymes required for biosynthesis of haem.

Etiology

- ❖ Porphyrins are important intermediates in biosynthesis of heme from glycine and succinyl

CoA. Each step in the pathway is controlled by specific enzymes.

- ❖ Deficiency (inherited or acquired) of the enzymes leads to accumulation of substrate (intermediary porphyrins), many of which cause photosensitivity induced by light of wave length 400 nm (**Soret band**).

Classification

Based on clinical and biochemical parameters, porphyrias are classified into:

- ❖ **Erythropoietic porphyria:**
 - Congenital erythropoietic porphyria.
 - Erythropoietic protoporphyria.
- ❖ **Hepatic porphyria:**
 - Porphyria cutanea tarda.
 - Acute intermittent porphyria.
 - Variegate porphyria.

Clinical Features

Congenital erythropoietic porphyria (CEP)

- ❖ Rare.
- ❖ **Etiology:** Autosomal recessively inherited disorder of porphyrin synthesis.
- ❖ **Cutaneous manifestations:**
 - Begins soon after birth.
 - Severe photosensitivity, manifesting as sun-induced blisters on photo-exposed areas (Fig. 18.12A).
 - Lesions heal with scarring and photo-exposed parts eventually mutilate (Fig. 18.12B). Hypertrichosis conspicuous on face.
- ❖ **Teeth:** Brown teeth, which show fluorescence under Wood's lamp.
- ❖ **Systemic manifestations:** Hemolytic anemia.
- ❖ **Urine:** History of passing red-colored urine, which shows fluorescence under Wood's lamp (Fig. 18.12C).
- ❖ **Red cells:** Show stable fluorescence.

Erythropoietic protoporphyria (EPP)

- ❖ **Etiology:** Autosomal dominantly inherited disorder of porphyrin synthesis.
- ❖ **Cutaneous manifestations:**
 - Develops in infancy or early childhood.
 - Manifests as burning, edema, and urticaria on sun exposure.
 - Thickening of the skin and superficial scarring develop over period of time.
- ❖ **Urine:** Normal color.

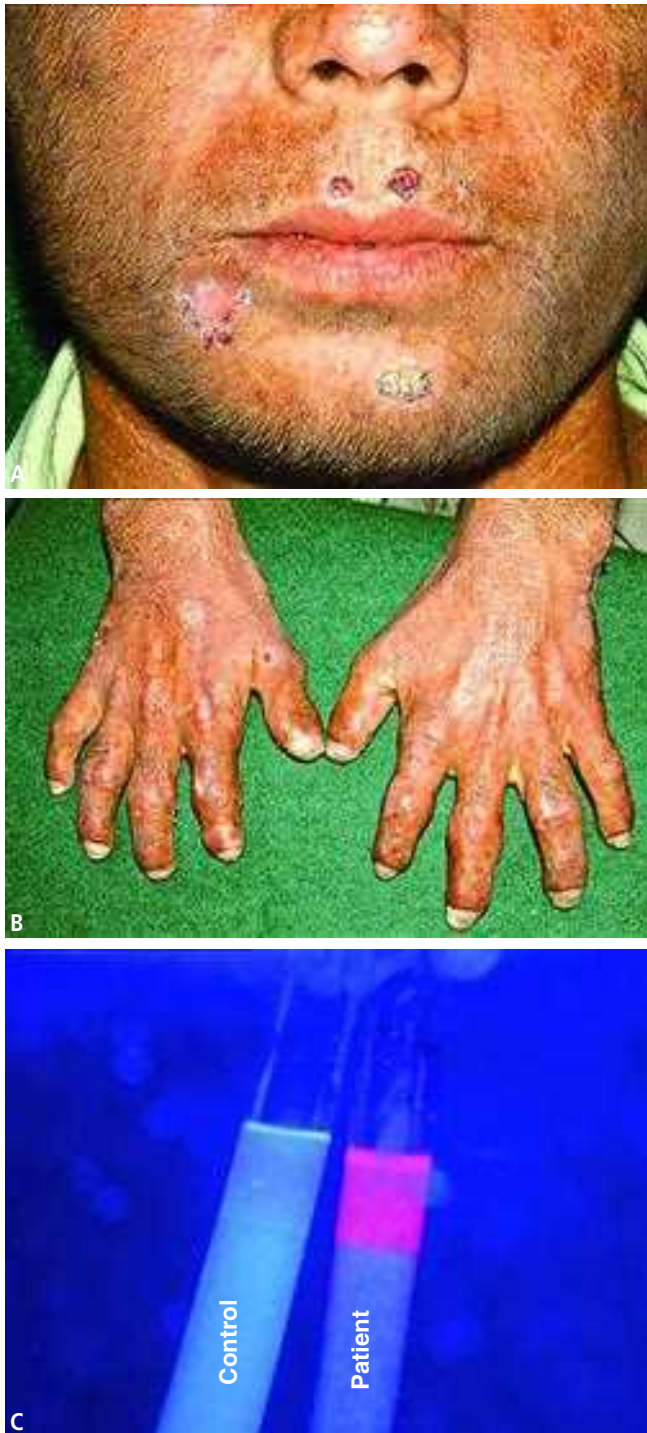

Fig. 18.12. Congenital erythropoietic porphyria: A: facial features with blistering, hypertrichosis and scarring. B: hands: showing scarring and mutilation. C: patients give history of passing red-colored urine, which shows fluorescence under Wood's lamp.

- ❖ **Systemic manifestations:** Liver disease: May be fatal; gall stones may be present.
- ❖ **Erythrocytes:** Show unstable fluorescence.

Porphyria cutanea tarda (PCT)

- ❖ **Etiology:** Two main forms of disease are recognized:
 - *Sporadic form:* which is the commoner variety, occurs in adulthood, in patients with damaged liver (due to alcoholism, hepatitis C virus infection).
 - *Familial variety:* occurs at an earlier age, is an autosomal dominant disorder of porphyrin synthesis.
- ❖ **Cutaneous manifestations:**
 - Blisters occur on the photo-exposed parts. Develop on exposure to sun and in response to minor trauma (Fig. 18.13A).
 - Over period of time, the skin become thickened, sclerodermoid, and scarred. Hypertrichosis may be conspicuous (Fig. 18.13B).
- ❖ **Urine:** Is pink and shows a bright coral pink fluorescence under Wood's light.

Variegate porphyria (VP)

- ❖ Many patients asymptomatic. Many patients only have cutaneous manifestations, some have both skin and systemic manifestations.
- ❖ Presents after puberty.
- ❖ **Cutaneous lesions:** Like those in **PCT**:
 - Blisters in photo-exposed parts on sun exposure.
 - Sclerodermoid changes.
 - Hypertrichosis.
- ❖ **Systemic symptoms:** Precipitated by drugs (barbiturates, griseofulvin, sulfonamides, and estrogens) like in **acute intermittent porphyria**²:
 - Abdominal pain.
 - Neuropsychiatric symptoms.
 - Passage of red-colored urine during acute attacks.

Management

General measures

General measures are very important, because specific measure are available mainly for PCT and CEP.

2. **Acute intermittent porphyria:** no cutaneous lesions in this Porphyria.

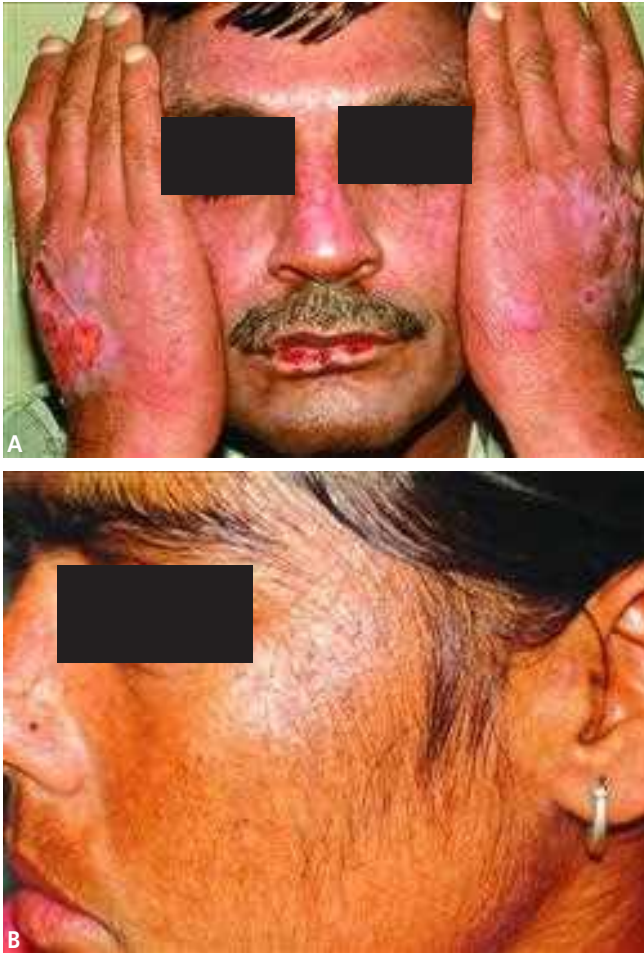

Fig. 18.13. Porphyria cutanea tarda: A: blisters occur on the photo-exposed parts. Develop on exposure to sun and in response to minor trauma. B: sclerodermoid changes, hypertrichosis, and scarring.

- ❖ **Photoprotection:** Using broad-spectrum sunscreens to reduce effect.
- ❖ **Genetic counseling.**

Specific therapy

- ❖ **Congenital erythropoietic porphyria:**
Treatment unsatisfactory:
 - Bone marrow transplantation.
 - Gene therapy, an imminent possibility.
- ❖ **Erythropoietic protoporphyria:**
 - **Beta carotene** used empirically.
- ❖ **Porphyria cutanea tarda:**
 - Avoidance of “triggers” like alcohol.
 - Venesection till hemoglobin falls below 12 g/dl.
 - Low-dose therapy with hydroxychloroquine (100 mg twice a week).

❖ **Variegate porphyria:**

- Avoidance of “triggers” like barbiturates, griseofulvin, sulfonamides, and estrogens.
- Avoidance of low-calorie diet and alcohol.

Xanthomas

Classification

Disorders of lipid metabolism are classified into:

- ❖ **Primary hyperlipidemias:** Genetic diseases which are classified into six types on the basis of fasting blood lipids and electrophoresis of plasma lipoproteins.
- ❖ **Secondary hyperlipidemia:** Seen in a number of diseases like:
 - Diabetes mellitus.
 - Primary biliary cirrhosis.
 - Nephrotic syndrome.
 - Hypothyroidism.

Cutaneous Manifestations

- ❖ First manifestation of disorders of lipid metabolism often are yellowish deposits in skin called **xanthomas**.
- ❖ A number of clinical variants of xanthomas are recognized:
 - Xanthelasma palpebrarum (Fig. 18.14A).
 - Tuberosus xanthoma (Fig. 18.14B).
 - Tendinous xanthomas.
 - Eruptive xanthomas (Fig. 18.14C).
 - Plane xanthomas (Fig. 18.14D).
- ❖ The clinical patterns of xanthomas correlate well with the underlying cause (Table 18.2).

Skin Changes and Malnutrition and Malabsorption

Usually, a combined deficiency of several nutrients occurs and it is only rarely that an isolated deficiency of a single nutrient occurs.

Protein-Energy Malnutrition

Occurs commonly in children in developing countries.

Clinical Features

- ❖ Cracked, parchment-like skin (**crazy pavement skin**).
- ❖ Alternating bands of light and dark colors in the hair (**flag sign**).

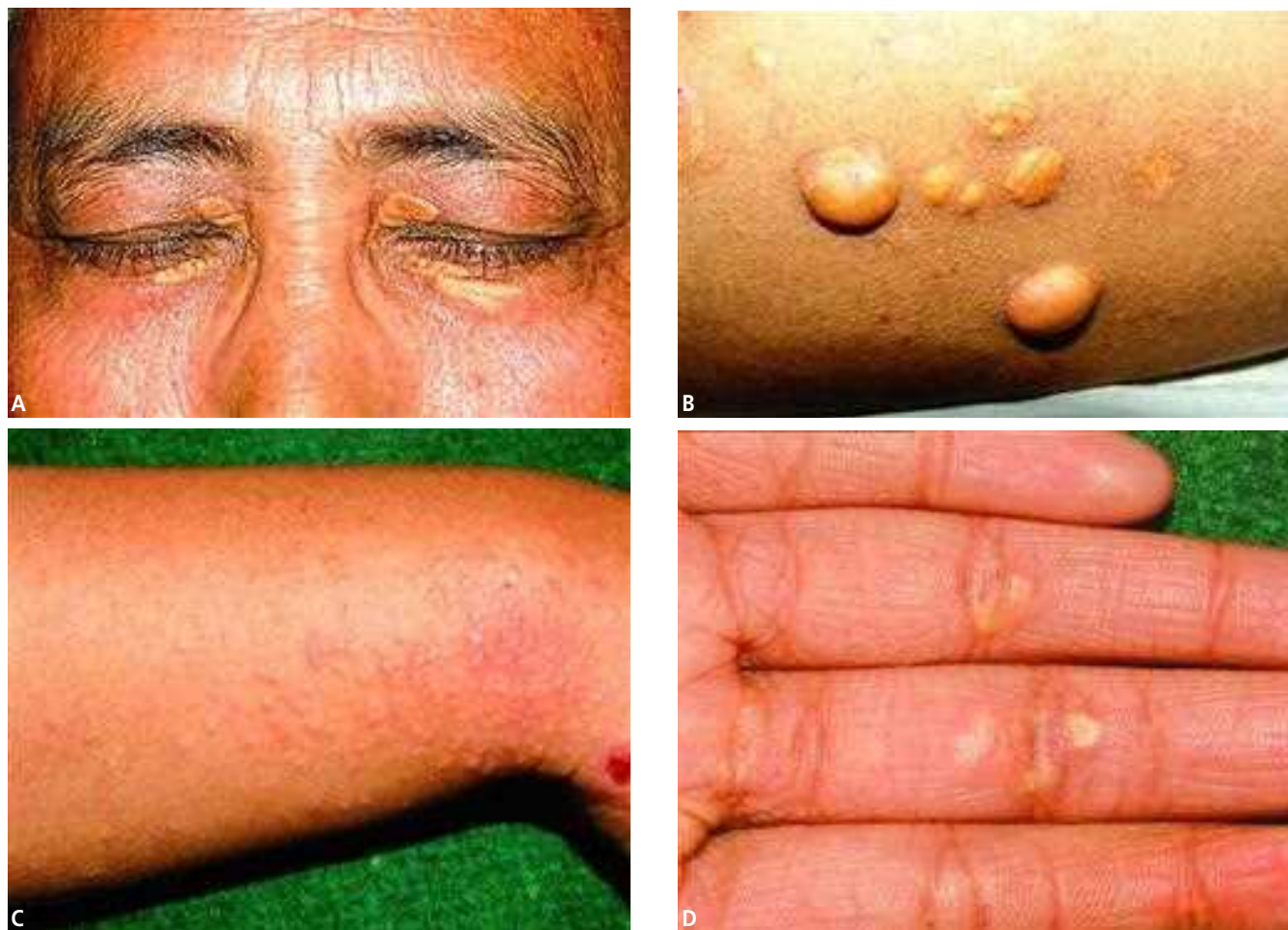

Fig. 18.14. Xanthoma: A: xanthelasma palpebrarum: soft, yellow, flat, oblong plaques most frequently seen on medial part of lids. B: tuberous xanthomas: yellow-colored nodules on pressure points. C: eruptive xanthomas: small, multiple papules lesions appearing in crops. D: plane xanthomas; yellow lesions along palmar creases.

Table 18.2. Xanthomas: clinical patterns and associated hyperlipidemia

Type	Morphology	Sites	Associated hyperlipidemia
Xanthelasma palpebrarum	Soft, yellow, flat ovoid plaques (Fig. 18.14A)	Eyelids	Idiopathic, Types II, III Secondary
Tuberous xanthomas	Firm/soft, yellow, nodules (Fig. 18.14B)	Elbows, knees	Types II, III Secondary
Tendinous xanthomas	Subcutaneous swellings along tendons	Fingers and Achilles tendon	Types II, III Secondary
Eruptive xanthomas	Shower of small, multiple, yellow papules (Fig. 18.14C)	Buttocks, shoulders	Types I, II, IV, V Secondary
Plane xanthomas	Yellow macules (Fig. 18.14D)	Palmar creases	Type III Secondary

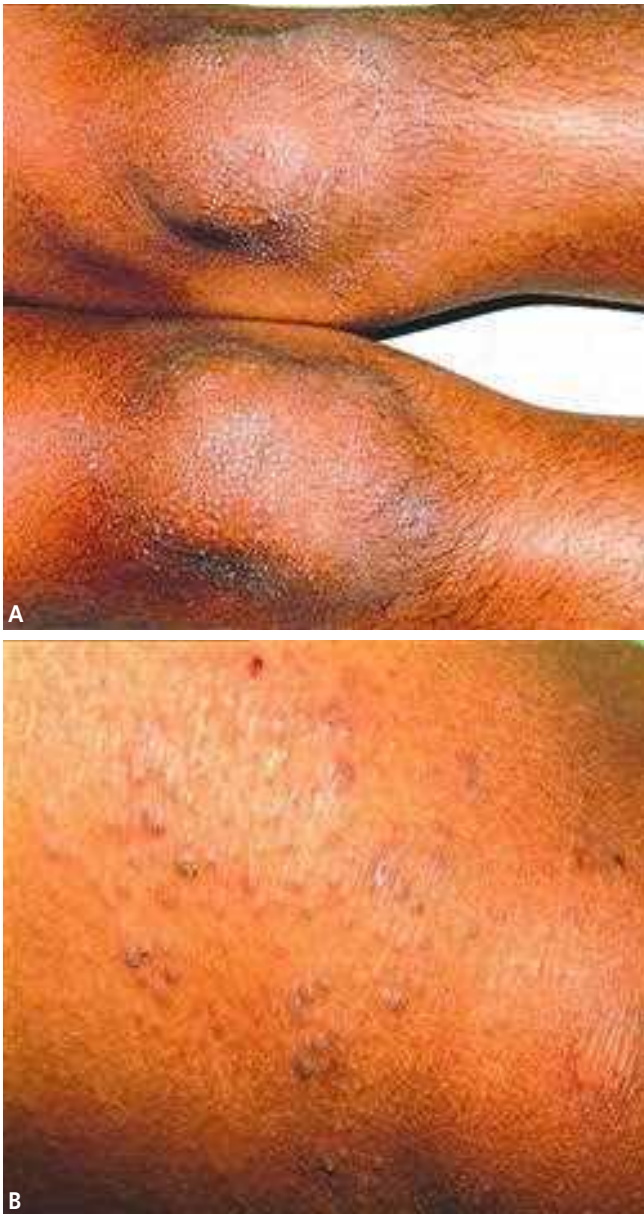

Fig. 18.15. Phrynoderma: A: rough hyperkeratotic follicular papules around knees. B: close up view.

Treatment

High protein/carbohydrate diet.

Vitamin A Deficiency

Seen in malabsorption syndromes and often associated with deficiency of vitamin D.

Clinical Features

- ❖ Night blindness and Bitot's spots.
- ❖ Xerosis of skin is usually the first manifestation.

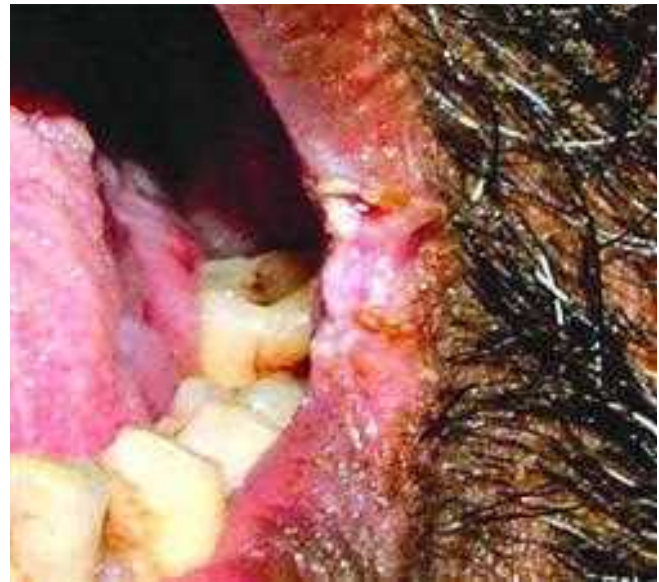

Fig. 18.16. Angular stomatitis: fissuring at angle of mouth.

❖ *Phrynoderma* (toad-skin disease):

- May be a manifestation of vitamin A deficiency, though it may also be due to deficiency of essential fatty acids and even **vitamin B**.
- Manifests as rough, hyperkeratotic follicular papules around elbows and knees (Fig 18.15).

Treatment

Vitamin A supplementation, with 1–3 million IU/day. Eye symptoms respond dramatically. Skin changes respond slowly.

Riboflavin Deficiency

Clinical manifestations develop several months after deprivation.

Clinical Features

- ❖ **Angular stomatitis:** Maceration of angles of mouth. There may be superadded candidal infection (Fig. 18.16).
- ❖ **Cheilitis:** Erythema, dryness and fissuring of the lips.
- ❖ **Glossitis:** Smoothness of tongue, due to atrophy of the papillae.
- ❖ **Skin lesions:** Seborrheic dermatitis-like rash.

Treatment

Daily therapeutic dose is 10–20 mg for adults and 1–2 mg for infants.

Nicotinic Acid Deficiency (Pellagra)

Etiology

Nicotinic acid deficiency occurs due to:

- ❖ Dietary deficiency of nicotinic acid, as occurs in alcoholics.
- ❖ Dietary deficiency of tryptophan.
- ❖ An imbalance of tryptophan and leucine/isoleucine in the diet (as present in jowar-based diet) or when niacin is present in bound form (as in a maize-based diet).
- ❖ Metabolic derangements, as caused by certain drugs, like isoniazid.

Clinical Features

- ❖ Weakness and fatigue are frequent.
- ❖ **Dermatitis:** Sharply demarcated area of erythema develops on dorsa of hands, wrists, forearms, the face and V of the neck (photo-exposed parts of the skin). This is followed by well-demarcated area of pigmentation (Figs. 18.17A and B). The sharply demarcated lesions on the neck and upper central part of the chest are known as **Casal's necklace**. Face shows erythema and **dyssebacia** (Figs. 18.17C).
- ❖ **Diarrhea:** Bloody diarrhea occurs due to hyperemia of the intestines.
- ❖ **Dementia:** Neuropsychiatric symptoms include impairment of memory, depression, and psychosis.
- ❖ **Mucosal involvement:** Cheilitis and characteristically **magenta tongue** are seen.

Treatment

Niacinamide³, 300–500 mg daily.

Vitamin C Deficiency (Scurvy)

Etiology

Deficiency of vitamin C occurs in:

- ❖ People consuming diets poor in fresh vegetables and fruits, like the elderly.
- ❖ Patients on an ulcer-diet.
- ❖ Patients with diarrhea and malignancies.

Clinical Features

- ❖ **Spongy gums:** Which bleed easily, *e.g.*, on brushing.

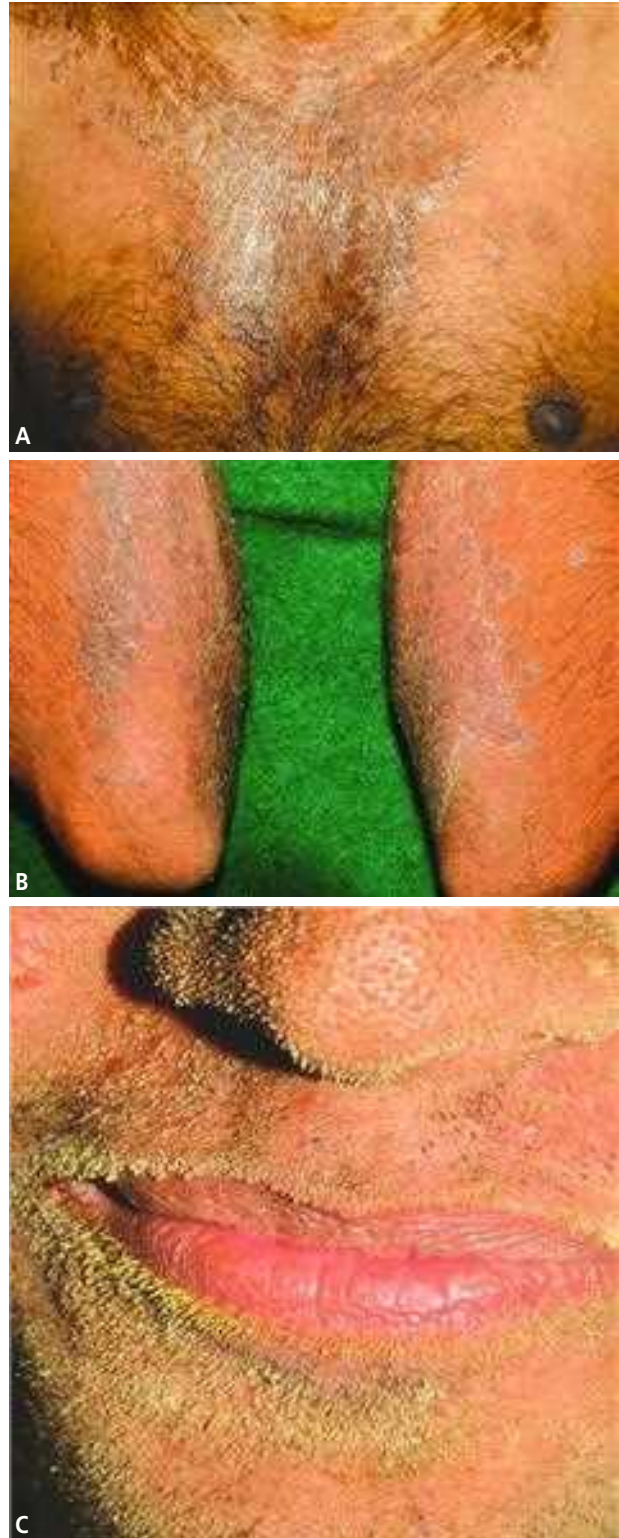


Fig. 18.17. Pellagra: A: sharply demarcated area of erythema on photo-exposed areas (Casal's necklace). B: similar lesions on forearms. C: dyssebacia.

3. **Niacinamide:** preferred to nicotinic acid, because it usually does not cause flushing.

- ❖ **Follicular hyperkeratosis:** With corkscrew hair and perifollicular hemorrhages are characteristic. These changes are more frequently seen in flexures.
- ❖ **Bleeding tendency:** Ecchymosis on feet and ankles. And subconjunctival, subungual, intramuscular and subperiosteal hemorrhages.

Treatment

Vitamin C, 150 mg daily to infants and 800 mg daily to adults.

Zinc Deficiency

Etiology

- ❖ **Acrodermatitis enteropathica**, an autosomal recessive trait, is the prototype zinc deficiency syndrome.
- ❖ Zinc deficiency also occurs during parenteral hyperalimentation, *e.g.*, after intestinal surgery.

Clinical Features

Acrodermatitis enteropathica is seen in infants being weaned off mother's milk and is characterized by:

❖ Cutaneous lesions:

- Scaly eczematous plaques (Fig. 18.18) in the periorificial region (around mouth, nose, genitals, and anus), acral areas, and bony prominences (occiput, malleoli, and buttocks).
- Pustular and hemorrhagic paronychia.
- Nonscarring alopecia of the scalp.

❖ Systemic manifestations:

- Apathetic look and irritability.
- Growth retardation.
- Diarrhea.

Treatment

Zinc supplementation (30–50 mg of elemental zinc, given as 220 mg of zinc sulfate). The response is dramatic. The treatment needs to be given up to adulthood.

Essential Fatty Acid Deficiency

- ❖ Uncommon deficiency.
- ❖ Cereals and vegetable oils are rich sources of essential fatty acids.
- ❖ Dryness of skin and eczematous dermatitis.

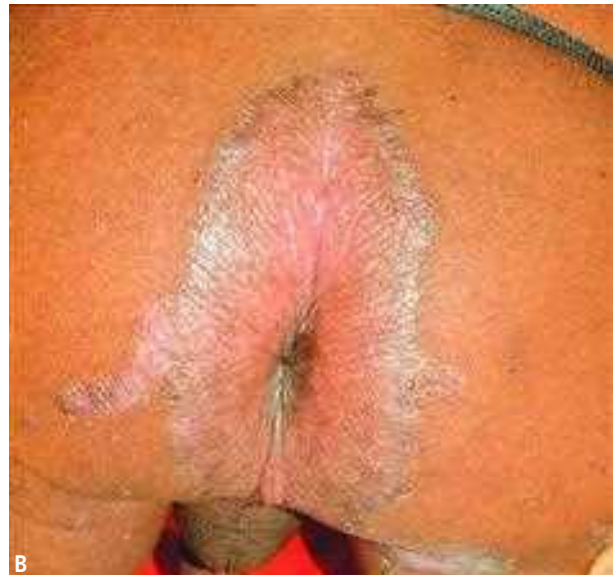
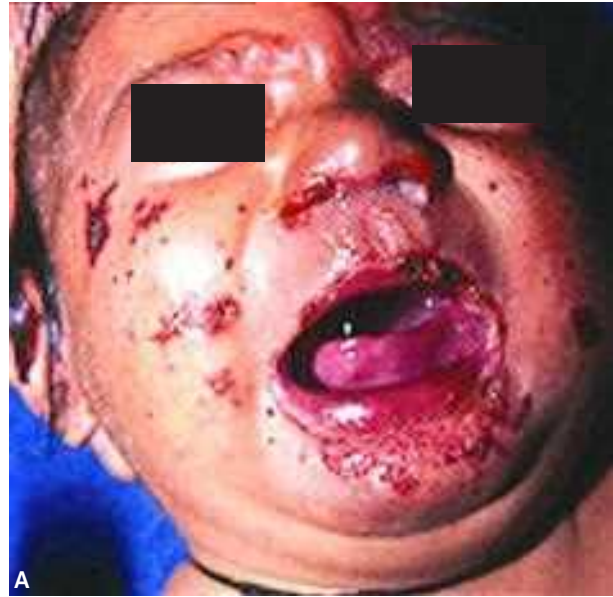
Fig. 18.18. Acrodermatitis enteropathica: A: eczematous periorificial lesions in a highly irritable infant who also had diarrhea. B: perianal scaly lesions.

- ❖ **Phrynoderma** (toad skin): Characterized by spiny hyperkeratotic follicular papules around knees and elbows (Fig. 18.17).

Skin and Internal Malignancies

Cutaneous markers of internal malignancies could be due to:

- ❖ **Metastases** to skin.
- ❖ **Genodermatoses** with an increased predisposition to internal neoplasia.

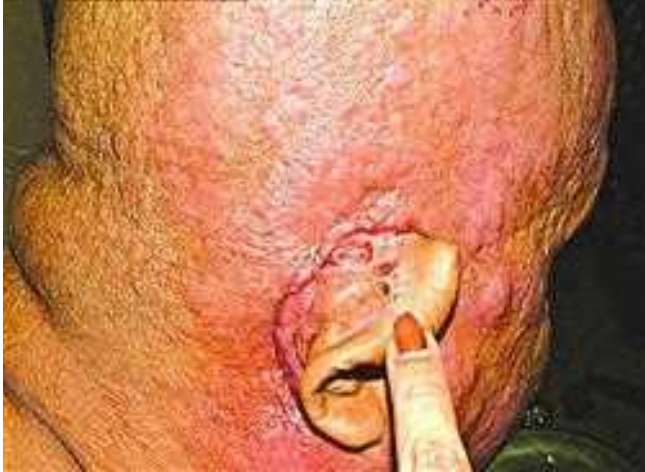

Fig. 18.19. Cutaneous metastasis: hematogenous spread from adenocarcinoma of stomach. Manifests as erythematous, rapidly growing plaques.

- ❖ **Exposure to carcinogens**, which result in skin changes as well as internal neoplasia.
- ❖ **Paraneoplastic syndromes** are cutaneous reaction patterns associated with internal neoplasia.

Cutaneous Metastases

Cutaneous metastases could be due to:

- ❖ Direct spread of tumor to skin, as in case of carcinoma of breast or oral cavity.
- ❖ Hematogenous spread from distant sites, *e.g.*, adenocarcinoma of stomach, large bowel, ovaries, kidneys, and lungs (Fig. 18.19).

Genodermatoses and Internal Malignancies

Genodermatoses associated with an increased predisposition to internal malignancies are:

- ❖ Palmoplantar keratoderma and carcinoma of esophagus.
- ❖ Peutz–Jegher's syndrome and adenocarcinoma of intestine.

Exposure to Carcinogens

- ❖ Exposure to arsenic induces pigmentation, keratoses, skin carcinomas (Fig. 18.20), and internal carcinoma.

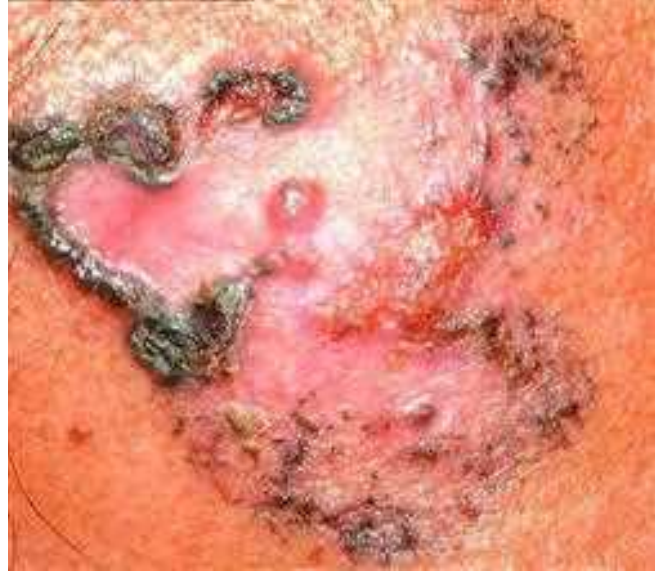

Fig. 18.20. Chronic arsenic exposure: basal cell carcinoma on the trunk.

- ❖ Nicotine staining of fingers indicates predisposition to tobacco-linked neoplasia like bronchial carcinoma.
- ❖ Radiation dermatitis and increased risk of neoplasia of underlying tissues such as thyroid carcinoma.

Paraneoplastic Diseases

❖ **Acanthosis nigricans:**

- Associated with malignancies of gut, especially gastric adenocarcinoma.
- Itchy, velvety thickening of the skin of flexures of neck, axillae, and groins. Mucosal involvement seen.

❖ **Dermatomyositis:**

- Associated with bronchogenic carcinoma (males), carcinoma of breast and ovaries (females).
- Adult variety of dermatomyositis.

❖ **Paraneoplastic pemphigus (Fig. 18.21):**

- Associated internal malignancies, *e.g.*, thymoma and lymphoma.
- Polymorphic skin lesions (erythema multiforme like, lichenoid or polycyclic lesions)

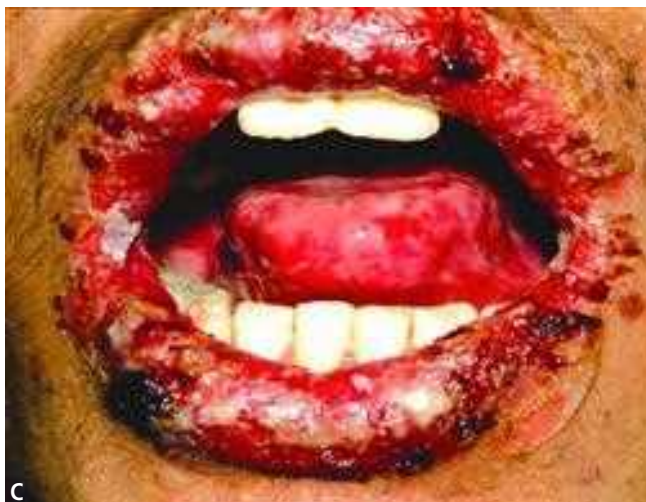
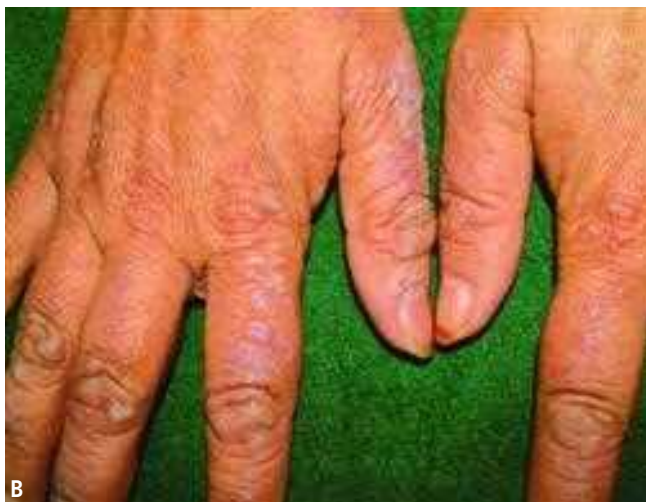
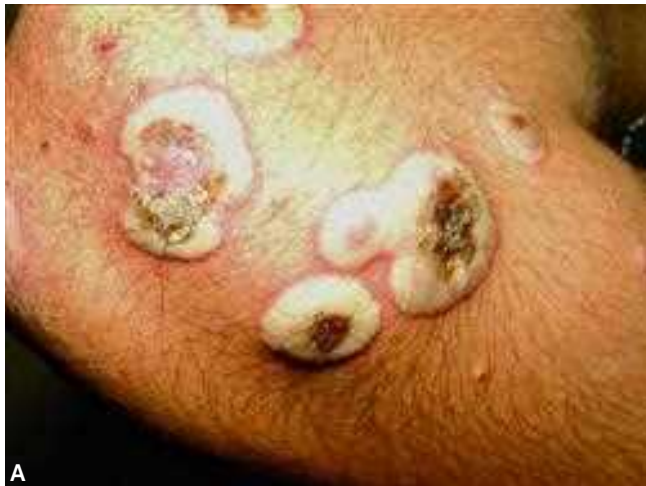Fig. 18.21. Paraneoplastic pemphigus: A: erythema multiforme-like lesions in acral parts. B: lichenoid lesions on acral parts. C: recalcitrant oral lesions.

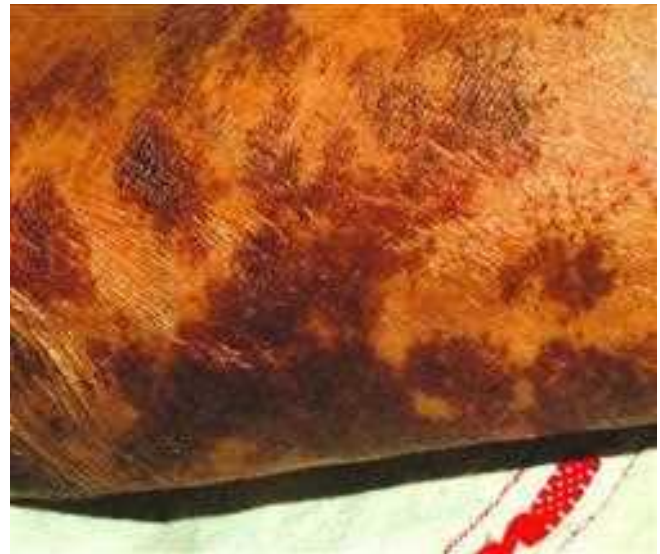

Fig. 18.22. Necrolytic migratory erythema: erythematous annular, polycyclic/geographic plaques on lower abdomen, groins and thighs.

and painful, indolent mucosal (especially oral) lesions.

❖ **Migratory thrombophlebitis:**

- Associated with malignancies of pancreas and lung.
- Multiple superficial and deep venous thromboses.

❖ **Necrolytic migratory erythema:**

- Strongly associated with glucagonoma.
- Characterized by erythematous annular, polycyclic/geographic plaques on lower abdomen, groins, and thighs (Fig. 18.22).
- Associated features include anemia and weight loss.

"This page intentionally left blank"

Treatment of Skin Diseases

19

Chapter Outline

Medical Treatment

Topical treatment[•]

Systemic therapy[•]

Physical Modalities

Surgery[•]

Electrosurgery[•]

Radiofrequency ablation[•]

Cryotherapy[•]

Chemosurgery[•]

Phototherapy/chemotherapy[•]

Laser and intense pulse light therapy[•]

Radiotherapy[•]

Introduction

An accurate (or at least a working) diagnosis, based on proper history and examination, is imperative before any rational treatment for a disease can be instituted in any field of medicine, and the same holds true for dermatology.

Treatment of no skin disease can be generalized; it needs to be individualized in all cases, depending on several factors:

- ❖ Severity and extent of disease.
- ❖ Site of disease, *e.g.*, whether on exposed parts or on covered parts.
- ❖ Impact of disease on patient's **quality of life**¹.
- ❖ Age and sex of patient.
- ❖ Presence of complications of disease.
- ❖ Compounding factors like systemic diseases.
- ❖ Financial constraints.

The main steps in treatment of any disease are:

- ❖ Explanation of condition, its cause and prognosis to the patient.
- ❖ Discussion of expectations.
- ❖ Choice of treatment and instructions about it.
- ❖ Follow-up, if necessary.

Some of the treatment options available in Dermatology are listed in Table 19.1.

Medical Treatment

Medical therapy in Dermatology can be topical or systemic. Some drugs can only be used topically (*e.g.*, permethrin for scabies), while others work only systemically (*e.g.*, dapsone for leprosy and griseofulvin for fungal infection) and some can be used both topically as well as systemically (*e.g.*,

[•]Should know
[◦]Good to know

1. **Quality of life (QOL):** this is a new measure, of how much disability (not only physical but mental as well) the disease is causing.

Table 19.1. Treatment options in dermatology

Medical options	Topical therapy Systemic therapy
Physical options	Surgery Electrosurgery Radiofrequency ablation Cryotherapy Chemosurgery Phototherapy/photochemotherapy Laser therapy Radiotherapy

psoralens in vitiligo). When a choice exists (e.g., psoralens in vitiligo) and both topical and systemic therapies are equally effective, then topical treatment should be used, unless the disease is extensive.

Topical Treatment

Components of Topical Agents

Topical agents contain the following ingredients:

- ❖ Active agent.
- ❖ Vehicle.
- ❖ Additives.

Active agents

- ❖ These are the most important components of topical medication and include agents like steroids, tar, dithranol, antibiotics, antifungal and antiviral agents, benzoyl peroxide, retinoic acid, etc.
- ❖ Action of active ingredient depends on:
 - Intrinsic properties of the ingredients.
 - Concentration of the ingredients.
 - Vehicle used, e.g., steroids in ointment base have higher potency than in cream base, even at the same concentration.

Vehicle

- ❖ Also called **base**.
- ❖ Most vehicles are a mixture of water and oils/greases (usually obtained from petroleum).
- ❖ Vehicles have the following effects:
 - Optimize the delivery of topical drugs, e.g., vehicles may enhance penetration.
 - Have useful therapeutic properties by themselves.
- ❖ Choice of base depends on:
 - *Site of application*: lotions are used on the scalp while ointments on palms and soles.

- *Type of lesion*: water-based lotions are used on exudative lesions while ointments are used on scaly lichenified lesions.
- *Action desired*: ointments are used when occlusive action is needed.
- *Ease of application*: lotions are easy to apply on scalp while ointments are not.
- *Financial implications*: sprays are expensive.
- ❖ Used indiscriminately, bases can have adverse effects.

Additives

These are added to:

- ❖ Enhance effect of active agent.
- ❖ Increase stability of preparation.
- ❖ Increase patient acceptance/compliance.

Formulation of Topical Preparations

Several formulations of topical preparations are available (Tables 19.2 and 19.3, Fig. 19.1):

Table 19.2. Classification of topical preparations

	<i>Common types</i>	<i>Special types</i>
Liquids	Lotions	Shake lotions Gels
	Solutions	Paints Tinctures
Semisolids	Creams Ointments	
Solids	Pastes Powders	
Miscellaneous delivery systems	Collodion Microsponges Liposomes	

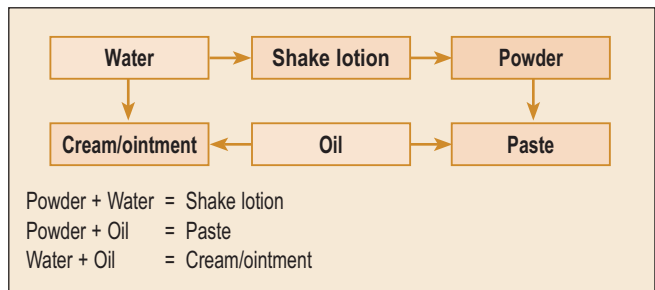


Fig. 19.1. Topical preparations: ingredients of common formulations.

Liquids

Lotions

- ❖ **Contain**: Active ingredient suspended in a liquid (usually alcohol, water, and glycerol).

❖ **Types:**

- *Water-based lotions:* used in acutely inflamed lesions.
- *Alcohol-based lotions:* used on scalp.

❖ **Effect:** When liquid evaporates:

- Film of medication is deposited on skin.
- Skin is cooled.

❖ **Special lotions:**

- **Shake lotions:** *e.g.*, calamine lotion.
 - Are suspension of powders² in water.
 - Are watery lotions which require shaking prior to each application, so cumbersome to use.
 - Useful in exudative lesions. But on drying, clumped powder particles may abrade the skin. Minimized by adding oil or glycerol to retain some moisture.

➤ **Gels:**

- Are thickened lotions containing high-molecular-weight polymers like methylcellulose.
- Useful for hairy areas (ease of use) and face (cosmetically acceptable because non-greasy).

❖ **Use:** Suitable for treating scalp and hairy areas of skin.**Solutions**❖ **Contain:** Active ingredients dissolved in a liquid (so clear).❖ **Effect:** When liquid evaporates:

- Film of medication deposited on skin.
- Cools skin.

❖ **Used as:**

- *Wet dressings:* aluminum acetate or Burrow's solution.
- *Soaks:* saline compresses.
- *Baths:* coal tar bath.
- *Aerosols.*

❖ **Special solutions:**

- *Paints:* are hydroalcoholic solutions, which are usually applied with a brush to skin or mucous membranes. May contain astringent or antiseptic agents and act as cooling agents and *e.g.*, Castellani's paint.
- *Tinctures:* are alcoholic solutions; applied with a swab.

Table 19.3. Which formulation to use—when and where?

Indications	Formulation
Based on morphology of lesions	
Acutely inflamed, exudative skin	Water-based/shake lotions
Dry, scaly lesions	Ointments
Dry, lichenified lesions	Pastes, ointments
Combination (moist and dry) lesions	Creams
Based on site of lesions	
Scalp	Alcohol-based lotions
Face, scalp	Gels
Flexures	Dusting powders
Oral	Pastes

Semisolids**Creams**❖ **Contain:** Both lipid, water, and an emulsifying agent³ to form semi-solid emulsions.

❖ They can be either:

➤ *Vanishing creams:*

- Are oil-in-water (O/W) emulsions.
- Are water-miscible, cooling, and soothing.
- Are well absorbed by skin.

➤ *Cold creams:*

- Are water-in-oil (W/O) emulsions.
- Are water immiscible, so difficult to wash off.
- Are emollient, lubricant, and mildly occlusive (but less so than ointments).
- Are used for cooling, moisturizing, and emollient effects.

Ointments

❖ Ointments are semisolid, soft to firm, greasy preparations.

❖ **Advantages:**

- Can carry active ingredient in high concentrations (up to 40%).
- Due to their occlusive nature:
 - They provide better penetration for drugs than creams.
 - They prevent evaporation of water from horny layer and make skin supple (emollient effect).

2. **Powders in shake lotions:** increase the surface area to hasten evaporation.3. **Emulsifying agents:** are added to increase stability of creams.

- Since they contain no (minimal) water, they do not sustain growth of microorganisms. This results in:
 - Use of fewer preservatives, so low sensitization potential.
 - Longer shelf life.

❖ **Disadvantages:** Greasy and sticky, so uncomfortable to use in hot humid weather. Overcome by incorporating emulsifying agents making them less greasy and are easily washed off.

Solids

Pastes

- ❖ Are semi-solid preparations containing a high concentration of a powder (e.g., zinc oxide) in grease (oil) or liquid.
- ❖ Are of two types:
 - **Protective pastes:**
 - Contain powder in grease (oil)
 - Are hydrating (as occlusive)⁴
 - Are difficult to apply, but can be localized accurately (as stiff).
 - **Drying pastes:**
 - Contain powder in liquid.
 - Are drying.
 - Are easy to apply.
- ❖ Are no longer popular though earlier they were used for their protective and emollient properties.

Powders

- ❖ **Use:** Powders applied directly to the skin are also known as **dusting powders**.
- ❖ **Indications:**
 - Reduce friction (talc).
 - Reduce moisture (starch).
 - Deliver drugs such as antifungals to feet.
- ❖ **Disadvantages:** Are best avoided in moist lesions, as they tend to cake and abrade skin.

Miscellaneous

Collodion

- ❖ Are liquid preparations⁵, which evaporate to deposit flexible thin film containing medicines on skin.

❖ Use:

- To apply salicylic and lactic acids to warts.
- To seal minor cuts and abrasions.

❖ **Advantages:** Easy to apply.

Newer preparations

❖ Microsponges:

- Drug to be delivered is loaded in porous beads, which then act as a reservoir of drug. Provide sustained release of drug, whilst reducing irritation.
- Used for cosmetics, sunscreens, and to deliver drugs (benzoyl peroxide and retinoids).

❖ Liposomes:

- Consist of an aqueous phase surrounded by a multilayered⁶ lipid capsule.
- Filled with drugs which are released into target cells⁷.
- Used for cosmetics and to deliver drugs (tretinoin, benzoyl peroxide, and dithranol to reduce irritation). Can be formulated into creams and gels.

Percutaneous Absorption

The penetration of drugs in topical preparations depends on several factors:

- ❖ **Concentration:** Of the active ingredient.
- ❖ **Vehicle:** Some vehicles enhance penetration. Ingredients dispensed in an ointment base have a better penetration than when dispensed in a cream.
- ❖ **Partition coefficient of agent:** Relative solubility of the drug in the vehicle *vis a vis* skin.
- ❖ **Diffusion constant of agent:** Nonpolar substances penetrate the skin better.
- ❖ **Thickness of the horny layer:** Thick horny layer retards penetration, so less penetration from palms and soles.
- ❖ **Hydration of the horny layer:** Hydrated stratum corneum enhances penetration.
- ❖ **Temperature:** Warmer skin has higher penetration.
- ❖ **Occlusion:** Occlusion enhances penetration because of:
 - Increased hydration.
 - Higher temperature.

4. **Occlusive effect of pastes:** less than ointments as powder decreases occlusive effect of the oil because it breaks the continuity of oil-phase.

5. **Collodion:** contains cellulose nitrate in organic solvent.

6. **Multilayered:** like layers of onion.

7. **Delivery into target cells:** fuse with the cell membrane or are endocytosed by cell.

- Creation of reservoir of drug in stratum corneum.

Methods of Use

Topical agents can be used in different ways:

Simple application

- ❖ Ointments and creams are usually applied as such. Lotions and solution are also often used as such.
- ❖ **Frequency of application:** Depends on:
 - Nature and severity of disease.
 - Sites involved.
 - Preparation of drug.
 - Reservoir effect.

Application under occlusion

- ❖ **Indications:** Best reserved for the short-term treatment of stubborn, thickened, localized lesions like lichen simplex chronicus.
- ❖ **Method:** After application of medicine (usually in ointment base), the lesion is covered with polythene sheet⁸ cut to size.
- ❖ **Basis:** Occlusion increases penetration and efficacy by almost 10–100 times by:
 - Increasing duration of contact by forming a reservoir of drug in the stratum corneum.
 - Increasing hydration and temperature.
- ❖ **Disadvantages:**
 - Increases local and systemic side effects⁹, especially with topical steroids¹⁰.
 - Increases bacterial growth.

Baths and soaks

- ❖ **Method:**
 - Solutions are used for baths and soaks¹¹.
 - For lesions on hands and feet, soaks are advisable. For generalized lesions, baths are used. The solution to be used is placed in a large enough container and the part to be treated immersed in it.
- ❖ **Functions:**
 - Help to remove crusts and scales, especially if pretreated with soaps and oil.
 - Help in hydrating skin, especially if followed

immediately by application of an occlusive ointment.

- Increase penetration of active ingredients due to hydration.
- Deliver medicines, using **medicated baths** (e.g., coal tar baths are useful in psoriasis).

Wet dressings (compresses)

- ❖ **Method:** Several layers of any soft linen or pad, soaked in solution to be used are applied to the skin. Compresses, so applied, can be used as:
 - **Open dressings:** dressing is changed frequently every 15 min or so for an hour. Open dressings cool the skin as the water evaporates, thereby removing exudation.
 - **Closed dressings:** soaked dressing is covered with polythene sheets so that it does not dry out quickly. Unlike open dressings it is changed once or twice a day. Closed dressings aid in removing adherent crusts from infected and crusted ulcers.
- ❖ **Functions:**
 - Clean skin in weeping, crusted, and infected lesions. They help in removing crusts (closed dressing) and help in reducing exudation because of vasoconstriction (open dressing).
 - Deliver topical medications like antiseptics and astringents.

Sprays

- ❖ Lotions and solutions may be delivered as an aerosol or spray.
- ❖ **Indications:** Is useful when the degree of inflammation makes direct application painful.
- ❖ **Disadvantages:**
 - Expensive.
 - Environmental degradation.

Quantity of Application

Several factors determine the amount of medication required:

- ❖ Extent of the disease.
- ❖ Type of preparation: Lotions spread better than creams, which go further than ointments and pastes.
- ❖ Site of application (Table 19.4 and Fig. 19.2).

8. **Polythene sheet:** retained on skin by adhesive.

9. **Increases side effects:** due to enhanced penetration.

10. **Topical steroids:** e.g., when applied under water-proof diapers in infants.

11. **Soaks:** are localized baths.

Table 19.4. Minimum amount of cream required for single application in an adult

Site	Amount
Face	1.0 g
Arm	1.5 g
Hand	0.5 g
Trunk	7.0 g
Leg	3.0 g
Foot	1.0 g

The amount of topical medication needed can be measured:

- ❖ Accurately, using pump dispensers which have recently become available but are cumbersome to use.
- ❖ Approximately, using the **finger tip unit (FTU)**. As a rough guide, one FTU in an adult male from a standard nozzle of a tube provides 0.5 g of ointment. So if the whole face is involved, then 2 FTUs would be required.

Pros and Cons of Topical Therapy

Advantages

- ❖ Delivery onto the target organ at an optimal concentration.
- ❖ Rapid onset of action, *e.g.*, topical PUVA in vitiligo.
- ❖ Systemic effects are less, since vital organs such as the bone marrow, liver, and kidneys are exposed to much (much!) lower concentrations of the drug after topical therapy.

Disadvantages

- ❖ Topical application of medicaments is often time consuming and depends largely on patient's compliance and patience. So it is often inadequately used.
- ❖ More expensive, if used over large areas.

Topical Agents

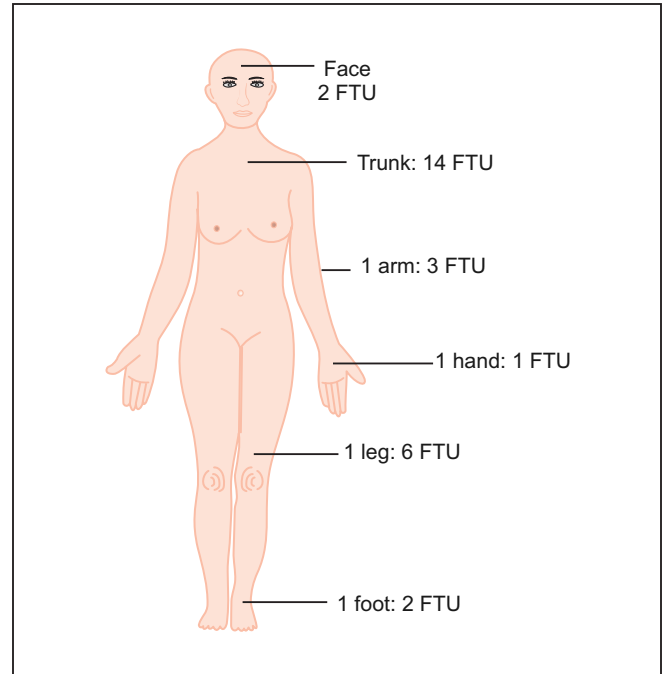
- ❖ The common topical agents used in dermatology are discussed in Table 19.5.

Systemic Therapy

Indications

Systemic treatment is used when:

- ❖ Skin disease is wide-spread, making topical therapy expensive and impractical.
- ❖ There is intolerance to topical therapy.

**Fig. 19.2.** Finger tip units of topical agent required.

- ❖ Drug is inactive topically, *e.g.*, dapsone in leprosy.
- ❖ Skin disease has a systemic component and topical therapy is not likely to be effective, *e.g.*, in systemic lupus erythematosus.

Drugs Used in Systemic Therapy

The common agents used in systemic therapy are shown in Table 19.6.

Physical Modalities

Many skin diseases are responsive to physical modalities of treatment (Table 19.1). Some broad principles and indications of treatment by these modalities will be discussed here.

Surgery

Biopsy

- ❖ Biopsy, done to confirm clinical diagnosis, is one of the most frequently done surgical procedures in dermatology.
- ❖ It can be incisional or punch biopsy. Sometimes, for small lesions an excisional biopsy may be done.
- ❖ Biopsy is taken for:
 - Histopathology.

Table 19.5. Topical agents used in dermatology

Types of preparation/constituents	Indications	Action	Comments
General agents			
Emollients ❖ Petrolatum ❖ Cetyl alcohol ❖ Stearyl alcohol ❖ Isopropyl myristate ❖ Glycerine ¹² ❖ Propylene glycol ¹²	❖ Dry scaly dermatoses: > Psoriasis > Ichthyosis > Keratodermas > Atopic dermatitis ❖ Atopic dermatitis ❖ Before light therapy	Increases moisture content of skin by: ❖ Occlusive effect: decreasing evaporation ❖ Hygroscopic effect: drawing moisture onto skin	❖ Petrolatum: messy to use. Folliculitis (chemical and bacterial)
Use: Apply after hydration, so as to retain moisture			
Keratolytics ❖ Urea, 5–40% ❖ Hydroxy acids, <i>e.g.</i> , glycolic acid, lactic acid ❖ Retinoic acid, 0.025–0.1% ❖ Salicylic acid, 4–12% ❖ Propylene glycol, 40–60%	❖ Ichthyoses ❖ Palmoplantar keratoderma ❖ Palmoplantar warts: salicylic acid (40%)	Increases shedding of stratum corneum because of increased dehiscence of dead keratinocytes.	❖ All: irritation & photoirritation due to thinning of stratum corneum ❖ Salicylates: salicylism, if excess used (>6%; on large areas; over prolonged periods; in infants)
Keratoplastic agents ❖ Salicylic acid, (2–4%) ❖ Coal tar, 6% ❖ Urea, 20%	❖ Ichthyoses ❖ Acne ❖ Psoriasis ❖ Keratodermas	Normalize defective stratum corneum	
Cleansing agents ❖ Normal saline, 0.9% ❖ Iodinated compounds, <i>e.g.</i> , povidone iodine ❖ Cetrimide, 1% ❖ Chlorhexidine 0.25% ❖ Hydrogen peroxide, 20 volumes (H ₂ O ₂)	❖ To clean wounds ❖ Antiseptic hand scrub ❖ Preparation of surgical sites	❖ All except saline: have antimicrobial action ❖ H₂O₂: debrides wounds, due to effervescence	❖ Iodinated compounds: inactivated in presence of serum. Irritation ❖ Chlorhexidine: keratitis, ototoxicity, so avoid on face.
Use: Apply before dressing wounds, surgery			
Astringents ❖ Aluminum acetate, 5% diluted 1:10–1:40 ❖ Potassium permanganate, (KMnO ₄) 1:10,000 ❖ Silver nitrate (AgNO ₃), 0.5–1%	❖ Exudative ulcers, <i>e.g.</i> , stasis ulcer ❖ Exudative eczema	Precipitate proteins to seal moist weeping lesions	❖ KMnO₄: irritates skin, stains clothes ❖ AgNO₃: stains skin
Use: Apply after cleansing; as wet dressings, compresses or soaks			
Shampoos ❖ Normal shampoos > Detergents > Foaming agents > Thickeners > Conditioners ❖ Conditioning shampoos > Cationic surfactants ❖ Antidandruff shampoos > Selenium sulfide, 2.5% > Ketoconazole, 2% ❖ Antipsoriasis shampoos > Coal tar, 2–5%	❖ Normal and conditioning shampoos: > Cleaning of scalp > Give bounce, body and shine to hair ❖ Medicated shampoos: > Pityriasis capitis > Seborrheic dermatitis > Pityriasis versicolor > Psoriasis of scalp	❖ Detergents help to remove debris and scales ❖ Conditioning shampoos: coat hair, smoothening roughness of cuticular scales. ❖ Antidandruff shampoos: anti-fungal effect ❖ Antipsoriasis shampoos: keratoplastic agent	❖ Selenium sulfide: irritation, so dilute ❖ Coal tar shampoo: may be ineffective because of short time of contact.

12. **Glycerine and propylene glycol** are humectants, *i.e.*, they draw moisture on to the skin.

Types of preparation/constituents	Indications	Action	Comments
Depigmenting agents			
<ul style="list-style-type: none"> ❖ Hydroquinone (HQ), 2–5% ❖ Azelaic acid (AA), 10–20% ❖ Retinoic acid (RA), 0.025–0.1% ❖ Kojic acid (KA), 1% ❖ Glycolic acid (GA), 6–12% ❖ Monobenzyl ether of HQ (MBEHQ), 20% 	<ul style="list-style-type: none"> ❖ Chloasma ❖ Freckles ❖ Postinflammatory hyperpigmentation ❖ MBEHQ: to remove residual normal pigmentation in patients with extensive vitiligo 	<ul style="list-style-type: none"> ❖ All: inhibit tyrosinase activity ❖ MBEHQ: toxic to melanocyte 	<ul style="list-style-type: none"> ❖ All: irritant and allergic dermatitis ❖ HQ: ochronosis with prolonged use ❖ MBEHQ: permanent depigmentation
Sunscreens			
<p>Inorganic sunscreens</p> <ul style="list-style-type: none"> ❖ Zinc oxide, 25% ❖ Titanium dioxide, 25% <p>Organic sunscreens</p> <ul style="list-style-type: none"> ❖ UVA sunscreens <ul style="list-style-type: none"> ➢ Avobenzone, 3% ➢ Benzophenones, 3–6% ❖ UVB sunscreens <ul style="list-style-type: none"> ➢ PABA¹³ derivatives, 8% ➢ Cinnamates, 3% ➢ Salicylates, 5–10% ❖ Broad spectrum <ul style="list-style-type: none"> ➢ Tinosorb, 10% ➢ Mexoryl, 15% 	<ul style="list-style-type: none"> ❖ Photodermatoses ❖ Collagen vascular diseases <ul style="list-style-type: none"> ➢ Lupus erythematosus ➢ Dermatomyositis ❖ Genetic dermatoses <ul style="list-style-type: none"> ➢ Xeroderma pigmentosum ➢ Freckles ❖ Disorders of pigmentation <ul style="list-style-type: none"> ➢ Chloasma 	<ul style="list-style-type: none"> ❖ Inorganic sunscreens <ul style="list-style-type: none"> ➢ Broad spectrum ➢ Reflect and scatter light of all wavelengths, due to opaque particulate matter ❖ Organic sunscreens <ul style="list-style-type: none"> ➢ Narrow spectrum ➢ Absorb specific wavelengths 	<ul style="list-style-type: none"> ❖ Inorganic: Cosmetically unacceptable, but inert ❖ Organic: <ul style="list-style-type: none"> ➢ Narrow spectrum ➢ Contact dermatitis (e.g., PABA, so PABA infrequently used)
Use:			
<ul style="list-style-type: none"> ❖ Apply frequently at 4–6 h intervals. ❖ Apply all over photo-exposed skin, ½ h before photo exposure. ❖ Combine with life style modifications like protective clothing, avoidance of mid-day sun etc. 			
Corticosteroids			
<p>Classified based on potency¹⁴</p> <ul style="list-style-type: none"> ❖ Class 1 (super potent) <ul style="list-style-type: none"> ➢ Clobetasol propionate, 0.05% ➢ Halobetasol, 0.05% ➢ Betamethasone dipropionate, 0.05% ointment ❖ Class 2 (potent) <ul style="list-style-type: none"> ➢ Betamethasone dipropionate, 0.05% cream ➢ Mometasone furoate, 0.1% ointment ➢ Halcinonide, 0.1% ❖ Class 3 (upper mid strength) <ul style="list-style-type: none"> ➢ Fluticasone propionate, 0.005% ➢ Betamethasone valerate, 0.17% ❖ Class 4 (mid strength) <ul style="list-style-type: none"> ➢ Mometasone furoate, 0.1% cream ➢ Fluocinolone acetonide, 0.2% ❖ Class B (lower mid strength) <ul style="list-style-type: none"> ➢ Hydrocortisone valerate, 0.2% ❖ Class 6 (mild) <ul style="list-style-type: none"> ➢ Desonide, 0.05% ❖ Class 7 (least potent) <ul style="list-style-type: none"> ➢ Hydrocortisone, 0.5% 	<ul style="list-style-type: none"> ❖ Highly steroid responsive dermatoses <ul style="list-style-type: none"> ➢ Atopic dermatitis ➢ Seborrheic dermatitis ➢ Nummular dermatitis ➢ Irritant dermatitis ➢ Lichen simplex chronicus ➢ Psoriasis ❖ Less responsive dermatoses <ul style="list-style-type: none"> ➢ Palmoplantar psoriasis ➢ Lupus erythematosus ➢ Pemphigus ➢ Lichen planus 	<ul style="list-style-type: none"> ❖ Anti-inflammatory action <ul style="list-style-type: none"> ➢ Cause vasoconstriction and decrease permeability of blood vessels ➢ Decrease migration and activity of phagocytes ➢ Decrease fibrin and kinin formation ➢ Inhibit phospholipase activity ➢ Stabilize lysosomal membranes ❖ Immunosuppressive action <ul style="list-style-type: none"> ➢ Suppress inflammatory sequelae of antigen–antibody reactions. ➢ Lympholytic 	<ul style="list-style-type: none"> ❖ Atrophy and striae ❖ Telangiectasis ❖ Hirsutism ❖ Folliculitis and acneiform eruptions ❖ May mask infections, e.g., tinea incognito ❖ Tachyphylaxis¹⁵ ❖ Rebound (worsening of disease) on withdrawal, e.g., in pustular psoriasis ❖ Systemic absorption (especially in infants)
Use:			
<ul style="list-style-type: none"> ❖ Avoid use of potent steroids on face, in flexures & in infants ❖ Do not use >200 g of mild, 50 g of moderately potent, and 30 g of potent steroid for adult/month. ❖ Avoid using class 1, 2 for prolonged periods. ❖ Can be combined with antibiotics (infected lesions), antifungals (flexures) salicylic acid (thick lesions). Can be used under occlusion (thick lesions, but with care!). 			

13. **PABA**: PABA itself not used now and most sunscreens marketed as PABA free. PABA derivatives like padimate used frequently.

14. Overall potency would depend also on concentration of the steroid preparation. And whether in ointment or cream base.

15. **Tachyphylaxis**: reduced clinical response.

Types of preparation/constituents	Indications	Action	Comments
Antibacterial agents			
Chlorhexidine	<ul style="list-style-type: none"> ❖ To clean wounds ❖ Antiseptic hand scrub ❖ Preparation of surgical sites 	<ul style="list-style-type: none"> ❖ Bacteria (Gram-positive and -negative), fungi (cidal) but not spores and <i>M. tuberculosis</i> ❖ Rapid and persistent effect 	Keratitis and ototoxicity, so avoid on face
Dyes <ul style="list-style-type: none"> ❖ <i>Gentian violet</i> ❖ <i>Brilliant green</i> 	<ul style="list-style-type: none"> ❖ Superficial bacterial infections ❖ Oral candidiasis 	<ul style="list-style-type: none"> ❖ Gram-positive bacteria ❖ Yeasts 	<ul style="list-style-type: none"> ❖ Stain clothes and skin ❖ Can cause skin necrosis
Iodinated compounds <ul style="list-style-type: none"> ❖ <i>Povidone iodine</i> 	<ul style="list-style-type: none"> ❖ Preoperative cleaning ❖ Cleaning wounds 	<ul style="list-style-type: none"> ❖ Gram-positive and -negative bacteria ❖ Fungicidal 	<ul style="list-style-type: none"> ❖ Inactivated by serum
Antibiotics <ul style="list-style-type: none"> ❖ <i>Fusidic acid</i>, 2% ❖ <i>Mupirocin</i>, 2% ❖ <i>Nadifloxacin</i>, 1% 	<ul style="list-style-type: none"> ❖ Impetigo ❖ Staph colonization ❖ Atopic dermatitis 	<ul style="list-style-type: none"> ❖ Gram-positive bacteria 	<ul style="list-style-type: none"> ❖ Cost
Antifungal agents			
Allylamines and related compounds <ul style="list-style-type: none"> ❖ <i>Terbinafine</i>¹⁶, 2.5% ❖ <i>Butenafine</i>, 1% ❖ <i>Amroline</i>, 5% nail lacquer 	<ul style="list-style-type: none"> ❖ Tinea corporis, cruris, manuum and pedis. Amroline nail lacquer for single, distal <i>T. unguium</i> ❖ Pityriasis versicolor 	<ul style="list-style-type: none"> ❖ Fungicidal against dermatophytes ❖ Fungistatic against yeasts 	<ul style="list-style-type: none"> ❖ Local burning, redness and dryness ❖ Expensive
Use: Available as cream and amroline as nail lacquer <ul style="list-style-type: none"> ❖ Creams: One to two times/d × 1–4 w, depending on type of infection ❖ Amroline nail lacquer: 1 application/w × 48 w 			
Azoles <ul style="list-style-type: none"> ❖ <i>Clotrimazole</i>, 1% ❖ <i>Miconazole</i>, 2% ❖ <i>Econazole</i>, 1% ❖ <i>Sulconazole</i>, 1% ❖ <i>Bifonazole</i>, 1% 	<ul style="list-style-type: none"> ❖ Tinea corporis, cruris, manuum, pedis ❖ Candidal intertrigo, paronychia, genital infections ❖ Pityriasis versicolor ❖ Erythrasma 	<ul style="list-style-type: none"> ❖ Dermatophytes ❖ Candida ❖ <i>Malassezia furfur</i> ❖ Corynebacteria 	<ul style="list-style-type: none"> ❖ Local irritation
Use: Available as cream, lotion, gel, ovules, mouth paint, and powder <ul style="list-style-type: none"> ❖ Skin infection/intertrigo: use creams 2/d × 1–4 w, depending on type of infection. Powders to prevent recurrent intertriginous infection ❖ Paronychia: use lotion ❖ Vaginal infection: use gel/ovules/pessaries ❖ Oral mucosa: use mouth paint/lotion/lozenges 			
Ciclopirox olamine , 1–8%	<ul style="list-style-type: none"> ❖ Tinea corporis, cruris, manuum, pedis ❖ Candidal intertrigo, paronychia, genital infections ❖ Pityriasis versicolor ❖ Erythrasma 	<ul style="list-style-type: none"> ❖ Dermatophytes ❖ Candida ❖ <i>Malassezia furfur</i> ❖ Corynebacteria 	<ul style="list-style-type: none"> ❖ Contact dermatitis ❖ Absorption through inflamed skin
Use: Available as cream, lotion, and nail lacquer <ul style="list-style-type: none"> ❖ Skin/intertrigo: use creams 2/d × 4 w, depending on type of infection. ❖ Nails: use nail lacquer daily × 48 w 			
Selenium sulfide , 1.25–2.5%	<ul style="list-style-type: none"> ❖ Pityriasis versicolor ❖ Seborrheic dermatitis 	<ul style="list-style-type: none"> ❖ <i>Malassezia furfur</i> 	<ul style="list-style-type: none"> ❖ Irritation
Use: Apply as is. Or diluted × 15 min			

16. **Terbinafine:** topical (but not oral) effective in pityriasis versicolor.

Types of preparation/constituents	Indications	Action	Comments
Polyenes ❖ <i>Nystatin</i> , 1–500,000 IU	❖ Oral candidiasis ❖ Candidal vulvovaginitis, especially if resistance to azoles or <i>C. glabrata</i> infection suspected	<i>Candida albicans</i> , <i>C. glabrata</i>	❖ Unstable in heat, light, and moisture
Antiviral agents			
❖ Podophyllin , 10–40% ❖ Podophyllotoxin , 5 mg/ml	❖ Anogenital warts Use: ❖ Podophyllin: Once a week application by physician. Protect surrounding skin with petrolatum and apply on lesion. Ask patient to wash off after 4 h ❖ Podophyllotoxin: Self-applied, 3–4 consecutive days/week	Cytotoxic	❖ Podophyllin: irritation ❖ Both: teratogenic
Wart paint (salicylic acid, 40% in collodion base)	❖ Palmoplantar warts in children ❖ Periungual warts ❖ Corns Use: Soak feet in water. Protect surrounding skin with petrolatum and apply on lesion. Repeat daily. Can occlude on palms and soles.	Keratolytic	❖ Irritation
Imiquimod , 5%	❖ Anogenital warts ❖ Actinic keratosis ❖ BCC ❖ Bowen's disease ❖ Keloids Use: Applied for 8–10 h for 3d/week × 16 weeks	Immunomodulator	❖ Cost ❖ Irritation
Acyclovir , 5%	❖ Topical of little value.	–	Usefulness suspect
Trifluridine , 1%	❖ Resistant genital herpes	Cytotoxic	
Antiparasitic agents			
Permethrin , 1%, 5%	❖ Head louse ❖ Body louse ❖ Pubic louse ❖ Scabies	❖ Pediculosis: Effective against nits and adults of louse ❖ Sarcoptes scabies	❖ Safe in children
Use: Available as 1% cream rinse and lotion. And 5% cream. ❖ Pediculosis: One application of 1% cream rinse, left for 10–15 min and shampooed. Repeat after 1 week. 5% used for pubic louse. ❖ Scabies: One application of 5% is left for 12 h. Applied all over body excluding face. In infants face treated. Treat whole family simultaneously.			
Gamma benzene hexachloride , 1%	❖ Head louse ❖ Body louse ❖ Pubic louse ❖ Scabies	❖ Pediculosis: Effective against adults of louse but not nits. ❖ Sarcoptes scabies	❖ Should not be used in children <5 years and pregnant women ❖ Can cause seizures in infants
Use: Available as lotion ❖ Pediculosis: Apply overnight and repeat after 1 week because ineffective against nits. ❖ Scabies: Overnight application. Treat whole family simultaneously.			
Benzyl benzoate , 25%	Scabies Use: Available as emulsion. ❖ Three applications, at 12 hourly intervals ❖ Treat whole family		❖ Irritation

Types of preparation/constituents	Indications	Action	Comments
Crotamiton, 10% Use: ❖ Twice daily application for 14 days ❖ Treat family with permethrin	Scabies in infants	❖ Mild antiscabetic ❖ Antipruritic	❖ Lower cure rates, but safe
Antiacne agents			
Retinoids ❖ <i>Retinoic acid (RA)</i> , 0.025%, 0.05%, 0.1% gel/cream ❖ <i>Adapalene (A)</i> , 0.1% gel ❖ <i>Tazarotene (T)</i> , 0.05%, 0.1% cream	❖ <i>Acne vulgaris</i> : stand alone use in mild; combined with systemic agents in all grades ❖ <i>Others</i> : Rosacea, acanthosis nigricans, epidermolytic hyperkeratosis, plane warts, psoriasis (mainly T)	❖ Keratolytic and keratoplastic agents	❖ Irritation ❖ Photosensitivity ❖ Dryness ❖ Do not use in pregnancy
Use: ❖ RA, A: Apply over acne prone skin at night, avoiding periorificial areas. Some erythema and scaling desirable. ❖ T: Used as short contact therapy, at night. Applied for 5 min and washed.			
Antibiotics ❖ <i>Erythromycin</i> , 2–4% lotion/cream/gel ❖ <i>Clindamycin</i> , 1–2% gel	❖ Acne vulgaris, moderately severe Use: ❖ Always combine with benzoyl peroxide to reduce resistance.	❖ Antibacterial ❖ Anti-inflammatory	❖ Resistance common
Benzoyl peroxide, 2.5–10% gel Use: ❖ Start with lower concentrations, applied for short periods of time (3–4 hours).	❖ Mild–moderate acne	❖ Antibacterial ❖ Keratolytic	❖ Dryness during first few weeks. Settles with continued use. ❖ Useful to prevent resistance
Azelaic acid, 20% cream	❖ Acne associated with pigmentation ❖ Can be combined with retinoids/benzoyl peroxide	❖ Antimicrobial ❖ Comedolytic ❖ Anti-inflammatory ❖ Reduces pigmentation	❖ Dryness, irritation
Antipsoriasis agents			
Coal tar, 3–6% in petrolatum	Psoriasis, body surface area <20%	❖ Keratoplastic ❖ Anti-inflammatory	❖ Cruder and blacker best ❖ Messy to use
Use: Psoriasis ointment (3% salicylic acid, 6% coal tar in petrolatum), two applications/d.			
Dithranol 0.05%/0.25–2% paste/ointment	❖ Psoriasis, few large lesions	❖ Reduces DNA synthesis	❖ Stains normal skin and clothing ❖ Irritant (so start with low concentration)
Use: ❖ Lower concentration for overnight application. ❖ Higher concentration for short contact therapy.			
Calcipotriol, 0.05% ointment Use: ❖ Two applications/d	❖ Localized lesions (in rich patients!!)	❖ Antiproliferative action ❖ Promotes differentiation ❖ Immunosuppressive activity.	❖ Should not exceed 100 g ❖ May be irritant initially ❖ Prohibitive cost
Tazarotene 0.05% and 0.1% cream/gel	❖ Localized lesions Use: ❖ One application/d carefully on lesions	❖ Keratolytic and keratoplastic	❖ Teratogenic ❖ Irritant

Types of preparation/constituents	Indications	Action	Comments
Miscellaneous			
5-fluorouracil , 1–5% cream	❖ Actinic keratosis ❖ Genital warts	❖ Antimetabolite	❖ Inflammation and soreness after a few days
Minoxidil , 2%, 5% solution, twice a day application	❖ Androgenetic alopecia ❖ Alopecia areata	❖ Not established	❖ Hair regained will fall, if treatment stops ❖ Headache ❖ Hypertrichosis
Capsaicin , 0.025% cream	❖ Postherpetic neuralgia	❖ Depletes substance P in sensory receptors	
Immunomodulators ❖ <i>Tacrolimus</i> , 0.03% and 0.1% ointment ❖ <i>Pimecrolimus</i> , 1% cream	❖ Atopic dermatitis ❖ Vitiligo ❖ Rosacea	❖ Immunomodulator (calcineurin inhibitor)	❖ Local burning with tacrolimus; less with pimecrolimus
Antiperspirants ❖ <i>Aluminium chloride hexahydrate</i> , 20% ❖ <i>Formaldehyde</i> , 5–10% ❖ <i>Glutaraldehyde</i> , 2–10%	❖ Axillary hyperhidrosis ❖ Palmoplantar hyperhidrosis	❖ ? block sweat ducts Use: ❖ Apply on dry skin.	❖ Thickening of skin ❖ Contact dermatitis ❖ Irritation, if used on recently shaved skin
Antipruritic agents ❖ <i>Menthol</i> , 0.5% ❖ <i>Phenol</i> , 1% ❖ <i>Crotamiton</i> , 10%	❖ Not used frequently ❖ <i>Crotamiton</i> : scabies in infants	❖ Cooling and soothing	❖ Contact dermatitis ❖ Seldom used

Table 19.6. Agents used in systemic therapy

Group/indication/adult dose	Side effects (SEs)	Drug interactions	Comments
Antibiotics			
Penicillins (P)			
Crystalline penicillin ❖ <i>Cellulitis</i> : 3–4 million U 4 hourly × 7–10 d ❖ <i>Neurosyphilis</i> : above dose × 14 d	❖ Anaphylaxis ❖ Urticaria ❖ Morbilliform eruptions ❖ Arthralgia	❖ <i>Probenecid</i> : increases level of P	❖ Always use after skin sensitivity testing ❖ Accumulates in renal and hepatic failure
Benzathine penicillin ❖ <i>Syphilis</i> : 2.4 mega units 1M, 1 dose (early), 3 doses (late benign) at weekly intervals ❖ <i>Recurrent cellulitis</i> : 1.2 mega units 1M, every 3 w			
Cloxacillin, flucloxacillin, dicloxacillin ❖ <i>Folliculitis, furuncles, and carbuncle</i> : 250 mg, four-times/d	❖ Gastrointestinal SEs ❖ Morbilliform rashes ❖ Anaphylaxis	❖ <i>Probenecid</i> : increases level of C ❖ C: decreases excretion of methotrexate	Effective against penicillinase producing Staph.
Amoxicillin, ampicillin (A) ❖ <i>Folliculitis, furuncles, and carbuncle</i> : 250 mg combined with clavulanic acid 125 mg, four-times/d	❖ Gastrointestinal SEs ampi > amox. ❖ Morbilliform rashes especially in patients with HIV and Epstein-Barr infection	❖ <i>Probenecid</i> : increases level of A ❖ A: reduces efficacy of oral contraceptives	❖ Limited stand alone use in dermatology. ❖ Used effectively in combination with beta-lactamase inhibitors like clavulanic acid and sulbactam against penicillinase producing Staph.

Group/indication/adult dose	Side effects (SEs)	Drug interactions	Comments
Tetracyclines (T)			
Tetracycline, oxytetracycline ❖ <i>Acne and rosacea</i> : 250–500 mg, BD** ❖ <i>Bullous pemphigoid</i> : 250–500 mg, BD** in combination with niacinamide (1500 mg/d)	❖ Gastrointestinal SEs ❖ Candidiasis ❖ Rashes ❖ Deposition in bones and teeth of fetus and children ❖ Rare phototoxic reactions ❖ Benign intracranial hypertension	❖ Food, antacids, and iron : decrease absorption of T ❖ T : decrease absorption of OCs, increase effect of warfarin	❖ To be taken on empty stomach ❖ Less used now, due to availability of doxy and mino. ❖ Avoid in pregnancy and in children <12 years ❖ Should not be used in renal/hepatic insufficiency
Doxycycline ❖ <i>Acne, rosacea</i> : 100 mg, OD* ❖ <i>Syphilis</i> : 200 mg × 14 d (early), 28 d (late) in patients sensitive to penicillin ❖ <i>Chlamydial infections</i> : 200 mg/d × 7–28 d ❖ <i>Bullous pemphigoid</i> : 100 mg, BD** in combination with niacinamide (1500 mg/d)	❖ As for tetracyclines. Most significant photosensitizer of all Ts, so avoid excessive sun exposure		❖ As for tetracycline
Minocycline ❖ <i>Acne and rosacea</i> : 50–100 mg, OD* ❖ <i>Sarcoidosis</i>	❖ As for tetracyclines + ❖ Dizziness and vertigo ❖ Blue-grey pigmentation ❖ Rarely, systemic LE	❖ Minocycline : decreases effectiveness of OC containing estrogens	❖ Can be taken with meals ❖ Cost a limiting factor ❖ Remissions in acne longer because lipophilic
Macrolides			
Erythromycin ❖ <i>Acne vulgaris</i> : 250–500 mg, BD** ❖ <i>Impetigo contagiosa and ecthyma</i> : 2 g/d ❖ <i>Chlamydia trachomatis infection</i> : 2g/d × 7 d ❖ <i>Syphilis in pregnant women sensitive to penicillin</i> : 2 g/d × 14 (early), 28 (late) d	❖ Gastrointestinal SEs ❖ Myalgias ❖ Cholestatic hepatitis ❖ (reversible) with estolate salt, if treatment prolonged	❖ Macrolides : increase toxicity of theophylline, carbamazepine, warfarin, ergotamine, cyclosporine A, digoxin	❖ Pyodermas which can be due to both Staph. and Strep. in penicillin-sensitive patients. ❖ Avoid estolate salt in liver disease and pregnant women.
Azithromycin ❖ <i>Acne vulgaris</i> : 250 mg, 1–3 times a week ❖ <i>Cellulitis and superficial cutaneous infections</i> : 500 mg, OD* ❖ <i>Sexually transmitted infections</i> : both genital ulcer disease and discharges: 1–2 g, single dose	❖ Gastrointestinal SEs ❖ Headache ❖ Dizziness and vertigo	❖ Digoxin : decreases levels of azithro	❖ Special precautions in hepatic and renal impairment
Quinolones			
Ciprofloxacin ❖ <i>Skin and soft tissue infections</i> : 500 mg, BD** × 7–10 d ❖ <i>Chancroid</i> : 500 mg, BD** × 3 d	❖ Nausea, vomiting		❖ Gram-negative (especially <i>Pseudomonas</i>) and Gram-positive infections.
Ofloxacin ❖ <i>Leprosy</i> : 400 mg, OD*			

Group/indication/adult dose	Side effects (SEs)	Drug interactions	Comments
Metronidazole (M)			
<ul style="list-style-type: none"> ❖ <i>Anaerobic infections</i> 200–400 mg, TD*** × 7 d ❖ <i>Stubborn rosacea</i>: 200 mg, BD** ❖ <i>Trichomoniasis</i>: 200 mg, TD*** × 7 d 	<ul style="list-style-type: none"> ❖ Gastrointestinal SEs ❖ Metallic taste ❖ Candidiasis, especially vulvovaginitis ❖ Ataxia and sensory neuropathy 	<ul style="list-style-type: none"> ❖ <i>M</i>: decreases levels of warfarin, phenytoin, and lithium ❖ <i>Drugs that induce liver enzymes</i>: (rifampicin, barbiturates, griseofulvin, phenytoin, carbamazepine): decrease levels of M 	<ul style="list-style-type: none"> ❖ Avoid alcohol
Cephalosporins			
Cephalexin, cefadroxil <ul style="list-style-type: none"> ❖ <i>Skin and soft tissue infections</i>: 500 mg, TD*** × 7 d 	<ul style="list-style-type: none"> ❖ Skin rashes, similar to penicillins. 10% of penicillin allergic patients sensitive to cephalosporins. ❖ Diarrhea 		<ul style="list-style-type: none"> ❖ 1st generation cephalosporin. ❖ Active against Gram-positive (less against penicillinase producing <i>Staph</i>) and some Gram-negative bacteria.
Ceftriaxone <ul style="list-style-type: none"> ❖ <i>Gonococcal infection</i>: 125 mg, IM single dose for uncomplicated and OD* × 7 d for complicated infection ❖ <i>Chancroid</i>: 250 mg, IM single dose. 	<ul style="list-style-type: none"> ❖ Injection site pain ❖ Skin rashes, rarely SJS–TEN ❖ Pseudomembranous colitis, candidiasis ❖ Bleeding disorder due to hypoprothrombinemia 	<ul style="list-style-type: none"> ❖ Aminoglycosides and frusemide increase nephrotoxicity of ceftriaxone 	<ul style="list-style-type: none"> ❖ 3rd generation cephalosporin. Long half life. Resistant to Gram-negative β-lactamase. ❖ Avoid in presence of renal and hepatic insufficiency ❖ Not as first line or blind therapy
Cefuroxime <ul style="list-style-type: none"> ❖ <i>Skin and soft tissue infections</i>: 250 mg, BD** × 7–10 d 	<ul style="list-style-type: none"> ❖ Gut upsets ❖ Transient hepatotoxicity ❖ Rarely nephrotoxic 	<ul style="list-style-type: none"> ❖ Probenecid: increases level of cefuroxime 	<ul style="list-style-type: none"> ❖ For Gram-positive and negative infections resistant to penicillin and erythromycin. Resistant to Gram-negative β-lactamase.
Antifungal agents			
Terbinafine¹⁷ (T) <ul style="list-style-type: none"> ❖ <i>Dermatophytic infections</i>: 250 mg, OD*. <div style="border: 1px solid black; padding: 5px; margin-top: 5px;"> <p>Dose Systemic drug of choice in:</p> <ul style="list-style-type: none"> ❖ <i>Tinea pedis</i>: 1–2 weeks ❖ <i>Tinea corporis</i>: 2 weeks ❖ <i>Tinea unguium</i>: finger nails: 6 wks; toe nails: 12 weeks. </div>	<ul style="list-style-type: none"> ❖ Gut upsets ❖ Headache ❖ Rashes ❖ Taste disturbance ❖ Liver toxicity (rarely) 	<ul style="list-style-type: none"> ❖ Rifampicin: increases levels of T ❖ Cimetidine: decreases levels of T 	<ul style="list-style-type: none"> ❖ Fungicidal. Remains in nails for 8–12 weeks after stopping drug ❖ Accumulates in renal failure ❖ Atopics at an increased risk of hypersensitivity reactions
Griseofulvin (G) <ul style="list-style-type: none"> ❖ <i>Tinea capitis</i>: drug of choice. Given as 10 mg/kg of ultramicrosized × 4–8 weeks ❖ <i>Other dermatophytic infections</i>: T has replaced G 	<ul style="list-style-type: none"> ❖ Gut upsets ❖ Headaches ❖ Rashes, photosensitivity 	<ul style="list-style-type: none"> ❖ G: increases level of warfarin and phenobarbitone. due to induction of microsomal liver enzymes 	<ul style="list-style-type: none"> ❖ Absorbed better when taken with fatty food ❖ Not for use in pregnancy, liver failure, porphyria or systemic lupus erythematosus

17. **Terbinafine**: DOC for onychomycosis due to dermatophytes diagnosed by culture.

Group/indication/adult dose	Side effects (SEs)	Drug interactions	Comments
Azoles: Broad spectrum ❖ Fluconazole (F) <ul style="list-style-type: none"> ➢ Candidiasis <ul style="list-style-type: none"> ● Acute vaginal: 150 mg, single dose. ● Recurrent vaginal: 150 mg, 1/wk × 6 wks. ● Oropharyngeal: 100 mg, OD* × 7–14 d ● Esophageal: 200 mg, OD* × 14–28 d ➢ Pityriasis versicolor: 300 mg, single oral dose ➢ Systemic mycoses: second-line treatment 	<ul style="list-style-type: none"> ❖ Rarely rashes, angioedema/anaphylaxis ❖ Liver toxicity (especially in AIDS patients) 	<ul style="list-style-type: none"> ❖ F: increases level of terfenadine and astemizole causing serious arrhythmias ❖ Rifampicin, warfarin, cyclosporine, phenytoin and sulfonylurea: decrease level of fluconazole 	Avoid in: <ul style="list-style-type: none"> ❖ Pregnant and lactating women ❖ Patients with renal damage ❖ Infants
Itraconazole (I) <ul style="list-style-type: none"> ❖ Candidiasis <ul style="list-style-type: none"> ➢ Vulvovaginal: 200 mg, BD** × 7 d ➢ Oropharyngeal: 100 mg, OD* × 14 d ❖ Pityriasis versicolor: 200 mg, OD* × 7 d ❖ Onychomycosis: 200 mg, BD** × 7 d every month, for 2 cycles (finger nails), 3 cycles (toe nails) 	<ul style="list-style-type: none"> ❖ Gastrointestinal SEs ❖ Headache 	<ul style="list-style-type: none"> ❖ Antacids: decrease absorption of I ❖ Rifampicin & phenytoin: decrease levels of I ❖ I: increases effect of warfarin, digoxin cyclosporine 	<ul style="list-style-type: none"> ❖ To be taken after food. ❖ Avoid in: hepatic impairment, children, and in pregnant and lactating mothers
Antiviral agents			
Acyclovir (A) <ul style="list-style-type: none"> ❖ HSV infection: <ul style="list-style-type: none"> ➢ First episode: 200 mg, five times × 7 d ➢ Recurrent: <ul style="list-style-type: none"> ● Episodic: 200 mg, five times × 5 d ● Suppressive: 400 mg, BD** × 12 m ❖ Zoster: when severe; 800 mg, five times/d × 7–10 d ❖ Chickenpox: in immunocompromised and in adults. 	<ul style="list-style-type: none"> ❖ Gastrointestinal SEs ❖ Transient rise in urea and creatinine in 10% of patients after intravenous use. ❖ Raised liver enzymes ❖ Reversible neurological reactions ❖ Decreases in hematological indices 	<ul style="list-style-type: none"> ❖ Probenecid: increases level of A due to delayed excretion ❖ Zidovudine: lethargy when IV is given 	<ul style="list-style-type: none"> ❖ To be given within 48 h of lesions ❖ ? safe in pregnancy ❖ Adequate hydration necessary
Famciclovir <ul style="list-style-type: none"> ❖ HSV infection: <ul style="list-style-type: none"> ➢ Episodic: 250 mg, TD*** × 7 d ➢ Suppressive: 250 mg, BD** × 12 m ❖ Herpes zoster: 500 mg, TD*** × 7 d 	<ul style="list-style-type: none"> ❖ Diarrhea, nausea, and headache 		<ul style="list-style-type: none"> ❖ Better gut absorption than acyclovir ❖ Less frequent dosing than acyclovir
Valacyclovir <ul style="list-style-type: none"> ❖ HSV infection: 1 g, BD** × 7 d 	<ul style="list-style-type: none"> ❖ Headache, nausea, and vomiting 		<ul style="list-style-type: none"> ❖ Derivative of acyclovir ❖ Better gut absorption ❖ Less frequent dosing
Foscarnet <ul style="list-style-type: none"> ❖ HSV infection in AIDS patients: 60 mg/kg IV, TD***, 14 d 	<ul style="list-style-type: none"> ❖ Electrolyte imbalance ❖ Nephrotoxic ❖ Neutropenia 		<ul style="list-style-type: none"> ❖ Used in acyclovir-resistant HSV infections

Group/indication/adult dose	Side effects (SEs)	Drug interactions	Comments
Cidofovir ❖ HSV infection: 5 mg/kg I.V. ❖ Cytomegalovirus infection			❖ Used in acyclovir-resistant HSV infections
Antihistamines			
Nonsedating antihistamines			
❖ <i>Urticaria and type 1 hypersensitivity reactions</i> Dose Loratadine: 10 mg, OD* Cetirizine: 10 mg, OD* Fexofenadine: 120/80 mg, OD* Levocetirizine: 5–10 mg, OD*	❖ Nausea, headache ❖ Sedation with cetirizine ❖ Fatigue, slowing of reflexes	❖ Ketoconazole and erythromycin: increase levels of loratadine. ❖ Cetirizine: increases effect of CNS depressants	❖ All: long-acting, so single daily dose sufficient. Avoid in pregnancy and lactation. ❖ Cetirizine: avoid driving and operating heavy machinery. Use 1/2 dose, in renal impairment ❖ Fexofenadine: derivative of terfenadine with minimal sedation/cardiac effects ❖ Levocetirizine: derivative of cetirizine with minimal sedation
Sedating antihistamines			
❖ <i>Urticaria, type-1 hypersensitivity</i> including anaphylaxis (intravenous use) ❖ Also used as <i>antipruritic</i> ⁷ agents in atopic dermatitis, lichen planus, contact allergic dermatitis, etc. Dose Chlorpheniramine: 12–16 mg/d Diphenhydramine: 10–120 mg/d Hydroxyzine: 40–100 mg/d Cyproheptadine: 8–16 mg/d Promethazine: 10–25 mg/d Trimeprazine: 2.5–10 mg/d	❖ Sedation (promethazine > trimeprazine > hydroxyzine > chlorpheniramine = diphenhydramine = cyproheptadine) ❖ Anticholinergic effects: dry mouth, blurred vision, urinary retention, and tachycardia	❖ Antihistamines increases effect of alcohol, CNS depressants, and anticholinergic drugs	❖ Avoid driving or operating dangerous machinery ❖ Chlorpheniramine may be used in pregnancy ❖ Sedation may be useful in atopic patients ❖ Increased rate of elimination in children.
Antiandrogens			
Cyproterone acetate (CA) ❖ <i>Acne vulgaris:</i> severe and unresponsive to systemic antibiotics, only in women: ❖ <i>Hirsutism</i> Dose CA 2 mg + ethinyl estradiol 35 µg OD* × 21 d, starting on 5th day of menstrual cycle. Repeat after 7 d × at least 6 m	❖ Same as OCs	Do not give with other OCs	Contraindications: ❖ Males and children ❖ Pregnancy (may feminize male fetus) ❖ Liver disease ❖ Hyperlipidemia ❖ Past or present endometrial carcinoma
Finasteride ❖ <i>Androgenetic alopecia in males:</i> 1 mg, OD*	❖ Decreased libido ❖ Impotence ❖ Lip swelling ❖ Gut upsets	❖ Avoid alcohol intake	❖ 5 α reductase inhibitor ❖ Contraindications: ➢ Children ➢ Pregnancy (may feminize male fetus) ➢ Past or present endometrial carcinoma
Flutamide ❖ <i>Hirsutism:</i> 250 mg, BD**	❖ Methemoglobinemia ❖ Hemolytic anemia ❖ Hepatotoxicity	❖ Decreases effect of theophylline	

Group/indication/adult dose	Side effects (SEs)	Drug interactions	Comments
Immunosuppressive drugs			
Azathioprine (A) <ul style="list-style-type: none"> ❖ <i>Autoimmune collagen vascular diseases</i>: systemic LE ❖ <i>Autoimmune bullous diseases</i>: bullous pemphigoid, pemphigus gp ❖ <i>Dermatitis</i>: atopic dermatitis, airborne contact dermatitis, chronic actinic dermatitis ❖ <i>Dose</i>: 1–2.5 mg/kg/d 	<ul style="list-style-type: none"> ❖ GI upset ❖ Marrow suppression—thrombocytopenia commonest ❖ Leucocyte function more depressed than numbers ❖ Hepatotoxicity: characteristically alkaline phosphatase elevation 	<div style="border: 1px solid black; padding: 5px; background-color: #f9e79f;"> Monitoring <ul style="list-style-type: none"> ❖ Hemogram: 4 weekly × 8 weeks, 4 weekly thereafter ❖ LFT: 4 weekly </div>	<ul style="list-style-type: none"> ❖ Contraindicated in pregnancy ❖ Reduce dose, if severe renal impairment
Cyclosporine (C) <ul style="list-style-type: none"> ❖ Psoriasis: severe or when conventional treatment ineffective: 2.5–4.0 mg/kg/d, in two divided doses ❖ Atopic dermatitis: severe for short-term treatment when conventional treatment ineffective 	<ul style="list-style-type: none"> ❖ Hepatic and renal impairment ❖ Hypertension ❖ Gut upset ❖ Hypertrichosis ❖ Gum hyperplasia ❖ Tremors ❖ Hyperkalemia ❖ Facial edema, fluid retention ❖ Seizures 	<ul style="list-style-type: none"> ❖ Drugs that increases nephrotoxicity: aminoglycosides, cotrimoxazole and NSAIDs ❖ Drugs that interact with cytochrome P450: antibiotics: (erythromycin, amphotericin B, cephalosporins, doxycycline, acyclovir), hormones (corticosteroids, sex hormones), anticonvulsants (phenytoin, phenobarbitone, carbamazepine, sodium valproate) 	Contraindications: <ul style="list-style-type: none"> ❖ Abnormal renal function ❖ Uncontrolled hypertension ❖ Concomitant premalignant or malignant condition <div style="border: 1px solid black; padding: 5px; background-color: #f9e79f; margin-top: 10px;"> Monitoring <ul style="list-style-type: none"> ❖ Baseline: Hemogram, LFT, RFT, serology for HIV, hepatitis A, B, C, and CX-ray ❖ Follow up: BP (weekly), serum creatinine (2 weekly × 8 weeks, then 4 weekly). Reduce C dose if serum creatinine >30% baseline </div>
Methotrexate (M) <ul style="list-style-type: none"> ❖ Psoriasis: <ul style="list-style-type: none"> ➢ Extensive, unresponsive to local treatment ➢ Pustular psoriasis ➢ Erythrodermic psoriasis ➢ Palmoplantar psoriasis, recalcitrant ❖ <i>Autoimmune bullous diseases</i>: pemphigus vulgaris ❖ <i>Connective tissue diseases</i>: dermatomyositis, systemic sclerosis <div style="border: 1px solid black; padding: 5px; background-color: #f9e79f; margin-top: 10px;"> Dose Test dose (often skipped) of 2.5–5 mg. Then 7.5–25 mg/w (for an adult) orally as a single dose or in three divided doses at 12 hourly intervals. </div>	<ul style="list-style-type: none"> ❖ Bone marrow suppression ❖ Hepatotoxicity ❖ Ulcerative stomatitis 	<ul style="list-style-type: none"> ❖ Aspirin, probenecid, thiazide diuretics, NSAIDs: increases toxicity of M ❖ Antiepileptics, cotrimoxazole: decreases effect of M ❖ Cyclosporine and acitretin: decreases toxicity <div style="border: 1px solid black; padding: 5px; background-color: #f9e79f; margin-top: 10px;"> Monitoring <ul style="list-style-type: none"> ❖ Baseline: Hemogram LFT, RFT, serology of HIV, hepatitis A, B, C, C X-ray ❖ Follow up: <ul style="list-style-type: none"> ➢ Hemogram weekly × 4 weeks; 4 weekly × 8 weeks, 12 weekly thereafter. ➢ LFT: 12 weekly. ➢ Liver biopsy: after 4.5 g cumulative dose. </div>	<p>Do not use in pregnancy Reduces dose, if renal or hepatic impairment Folic acid, given weekly reduce bone marrow suppression</p>
Cyclophosphamide <ul style="list-style-type: none"> ❖ <i>Vesiculobullous disorders</i>: pemphigus vulgaris ❖ <i>Connective tissue diseases</i>: SLE with renal involvement, dermatomyositis, system sclerosis (lung involvement) 1–2 mg/kg/daily. Or 8–10 mg/kg/monthly bolus dose 	<ul style="list-style-type: none"> ❖ Myelosuppression ❖ Bladder toxicity ❖ Gut upsets ❖ Alopecia ❖ Pigmentation of skin ❖ Sterility 	None of significance	<p>Do not use in patients of reproductive age</p> <div style="border: 1px solid black; padding: 5px; background-color: #f9e79f; margin-top: 10px;"> Monitoring <ul style="list-style-type: none"> ❖ Baseline: Hemogram LFT, urine for RBCs. ❖ Follow up: Hemogram, urine for RBCs. </div>

OD*: once daily; BD**: twice daily; TD***: thrice daily

Group/indication/adult dose	Side effects (SEs)	Drug interactions	Comments
Corticosteroids (C)			
<p>Prednisone, prednisolone, methylprednisolone, dexamethasone, betamethasone</p> <ul style="list-style-type: none"> ❖ <i>Acute and severe allergic drug reactions</i> ❖ <i>Contact dermatitis</i>: extensive ❖ <i>Stevens-Johnson syndrome- toxic epidermal necrolysis</i> (may be useful) ❖ <i>Connective tissue disorders</i>: SLE, dermatomyositis, systemic sclerosis ❖ <i>Bullous disorders</i>: pemphigus, pemphigoid ❖ <i>Vasculitis</i> <div style="border: 1px solid black; padding: 5px; margin-top: 10px;"> <p>Dose <i>Daily/A/D****: 5–80 mg of prednisolone equivalent daily/A/D**** for acute conditions and acute episodes of chronic conditions.</i> <i>Pulse therapy: dexamethasone intravenous/betamethasone, oral, 100 mg. Given monthly as 1–3 doses.</i> <i>Oral mini pulse (OMP): betamethasone, 5 mg. Given weekly, as single dose or on two consecutive days.</i></p> </div>	<p>Systemic side effects</p> <ul style="list-style-type: none"> ❖ Reactivation of tuberculosis ❖ Infections ❖ Impaired glucose tolerance ❖ Hypertension ❖ Sodium and water retention, potassium loss ❖ Redistribution of fat (centripetal) ❖ Muscle wasting, proximal myopathy ❖ Osteoporosis and vertebral collapse, avascular necrosis of head of femur ❖ Growth retardation in children ❖ Peptic ulceration ❖ Euphoria, psychosis or depression ❖ Cataracts and precipitation of glaucoma ❖ Cushing's syndrome <p>Mucocutaneous side effects</p> <p>Common</p> <ul style="list-style-type: none"> ❖ Acneiform eruption ❖ Fungal and bacterial infections ❖ Skin atrophy and striae ❖ Capillary fragility 	<ul style="list-style-type: none"> ❖ Liver enzyme inducers (e.g., phenytoin, griseofulvin, rifampicin): decrease effect of C ❖ Diuretics: increase K+ loss ❖ C: decrease effect of anti-hypertensives and antidiabetic agents 	<ul style="list-style-type: none"> ❖ Long-term treatment to be tapered slowly to avoid adrenal insufficiency ❖ Do not use for psoriasis or long-term for atopic eczema. ❖ Add following if long-term treatment planned: <ol style="list-style-type: none"> 1. Vit D, calcium, and bisphosphonates to reduce osteoporosis. 2. A drug to reduce acid peptic disease. 3. Potassium supplement 4. Exercise regimen 5. Restriction on salt/sugar and oil intake
Retinoids (R)			
<p>Acitretin</p> <ul style="list-style-type: none"> ❖ <i>Psoriasis</i>: pustular responds rapidly, erythrodermic less rapidly, while plaque slowly. May be combined with PUVA (RePUVA) ❖ <i>Palmoplantar pustulosis</i> ❖ <i>Ichthyoses</i>: <ul style="list-style-type: none"> ➢ Severe lamellar ichthyosis ➢ Severe epidermolytic hyperkeratosis ❖ <i>Others</i>: Darier's disease, pityriasis rubra pilaris <div style="border: 1px solid black; padding: 5px; margin-top: 10px;"> <p>Dose 0.2–1.0 mg/kg, daily after food.</p> </div> <p>Isotretinoin</p> <ul style="list-style-type: none"> ❖ Severe acne vulgaris, unresponsive to systemic antibiotics ❖ Moderately severe acne, in patients who are distressed ❖ Acne excoriee <div style="border: 1px solid black; padding: 5px; margin-top: 10px;"> <p>Dose 0.5–1 mg/kg, daily after food × 12–16 w</p> </div>	<ul style="list-style-type: none"> ❖ All patients develop dryness of lips, skin, and eyes ❖ Teratogenic, so contraception mandatory ❖ Atrophy of skin and nails ❖ Diffuse thinning of hair ❖ Exuberant granulation tissue (especially toe nail folds) ❖ Photosensitivity ❖ Disseminated interstitial skeletal hyperostosis (DISH) ❖ Arthralgia, myalgia, and headache ❖ Benign intracranial hypertension <p>Laboratory abnormalities</p> <ul style="list-style-type: none"> ❖ Hematology: increases WBC, increases ESR ❖ LFTs: increases bilirubin, transaminases, alkaline phosphatase ❖ Serum lipids: increases triglycerides 	<ul style="list-style-type: none"> ❖ Methotrexate: increases toxicity of R ❖ Avoid tetracyclines 	<ul style="list-style-type: none"> ❖ Women of childbearing age must use effective contraception (by two methods) for 1 month before Rx, during Rx and for at least 1 m (for isotretinoin) and 3 years (for acitretin) after Rx. ❖ Should not donate blood during and for 1 m (for isotretinoin), 3 years (for acitretin) after Rx. ❖ Avoid if renal or hepatic impairment <div style="border: 1px solid black; padding: 5px; margin-top: 10px;"> <p>Monitoring</p> <ul style="list-style-type: none"> ❖ Baseline: LFT, lipid profile, pregnancy test, X-ray spine ❖ Follow up: <ul style="list-style-type: none"> ➢ Pregnancy test: monthly ➢ LFT/lipid profile: 2 monthly ➢ X-ray spine: 6 monthly </div>

Group/indication/adult dose	Side effects (SEs)	Drug interactions	Comments
OD*: once daily; BD**: twice daily; TD***: thrice daily			
Miscellaneous			
Adrenaline (epinephrine) injection ❖ <i>Anaphylaxis</i> ❖ <i>Acute urticaria</i> : with respiratory distress ❖ <i>Surgical procedures</i> : is added to local anesthetics.	❖ Tachycardia and cardiac arrhythmias ❖ Anxiety and tremor ❖ Headache ❖ Hypertension ❖ Hyperglycemia ❖ Hypokalemia ❖ Hemolytic anemia, ❖ Methemoglobinemia	❖ β -blockers: may lead to hypertension	❖ Do not confuse the different strengths ❖ Give slowly, subcutaneously or intramuscularly, but never <i>intravenously</i> , except in cardiac arrest
Dapsone			
❖ <i>Leprosy</i> ❖ <i>Immunobullous disorders</i> : dermatitis herpetiformis, chronic bullous dermatosis of childhood, pemphigus group ❖ <i>Vasculitis</i> : pyoderma gangrenosum ❖ <i>Oral lichen planus</i> <div style="border: 1px solid black; padding: 5px; width: fit-content;"> Dose 50–150 mg daily </div>	❖ Skin rashes: Exfoliative dermatitis, TEN ❖ Headache, lethargy ❖ Hepatitis ❖ Peripheral neuropathy ❖ Hemolytic anemia, ❖ Methemoglobinemia, ❖ Agranulocytosis, aplastic anemia		❖ Component of MDT in leprosy
Chloroquine/hydroxychloroquine			
<i>Systemic and discoid lupus erythematosus (LE)</i> <i>Polymorphous light eruption</i> <i>Porphyria cutanea tarda (PCT)</i> <div style="border: 1px solid black; padding: 5px; width: fit-content;"> Dose ❖ 6.5 mg/kg. day (200–400 mg) daily in LE ❖ Lower dose in PCT </div>	❖ Retinopathy, which may cause permanent blindness ❖ Corneal deposits ❖ Headaches ❖ Gut upsets ❖ Pruritus and rashes ❖ Worsening of psoriasis	<div style="border: 1px solid black; padding: 5px; width: fit-content;"> Monitoring ❖ Baseline: Ophthalmic examination: visual acuity, ophthalmoscopy, visual fields with red target mandatory before treatment. ❖ Follow up: Ophthal (6 months). Discontinue drug if any change occurs. </div>	❖ Avoid in elderly and children ❖ Prefer intermittent short courses to continuous treatment ❖ Reduce dose, if poor renal or liver function ❖ Use small doses in PCT
Psoralens: Used with UVA lamps as PUVA therapy. Or with sunlight, as PUVA sol			

Group/indication/adult dose	Side effects (SEs)	Drug interactions	Comments
<ul style="list-style-type: none"> ❖ <i>Vitiligo</i>: extensive. ❖ <i>Psoriasis</i>: extensive plaque. ❖ <i>Cutaneous T-cell lymphoma</i> ❖ <i>Lichen planus</i>: extensive ❖ <i>Atopic dermatitis</i>: extensive <div style="border: 1px solid black; padding: 5px; margin-top: 10px;"> <p>Dose</p> <ul style="list-style-type: none"> ❖ 8 methoxypsoralen, 0.6–0.8 mg/kg taken as a single dose after food on A/D****. ❖ 1–2 hours later, gradually increasing, monitored exposure to UVA, either using UVA lamps or sunlight (best between 11 AM–1 PM). Scaly lesions covered with emollient (like oil/cold cream/petrolatum) before exposure. ❖ Photoprotection especially of eyes necessary for 8–12 h after photo exposure. </div>	<ul style="list-style-type: none"> ❖ Nausea, giddiness ❖ Itching ❖ Phototoxicity ❖ Lentigines, hyperpigmentation ❖ Aging of skin, neoplasia ❖ Cataracts 	<ul style="list-style-type: none"> ❖ Avoid other photosensitisers 	<ul style="list-style-type: none"> ❖ Not to be used in children and pregnancy ❖ Avoid in patients with hepatic, renal dysfunction <div style="border: 1px solid black; padding: 5px; margin-top: 10px;"> <p>Monitoring</p> <ul style="list-style-type: none"> ❖ Baseline: hemogram, LFT, RFT, and ANA. ❖ Follow up: R/o cataract (yearly). </div>
<p>OD*: once daily; BD**: twice daily; TD***: thrice daily; A/D****: alternate day</p>			

- Special stains.
- Culture.
- Immunopathology.
- Electron microscopy.

Shave Excision

Indications

- ❖ Used for small benign lesions.

Technique

- ❖ Done by shaving the lesion off at the base with a scalpel blade.
- ❖ Not recommended in case of tumors as some neoplastic cells may be left behind at the base, resulting in recurrence.

Surgical Excision

Indications

Surgical excision can be used to remove small nevi and tumors.

Technique

The lesion is removed and gap is either sutured or a skin graft is used to cover the defect.

Moh's Microscopic Surgery

- ❖ Moh's microscopic surgery is specialized surgical technique.

- ❖ Though time-consuming and expensive, it gives a higher rate of cure and better cosmetic results than either excision or curettage.

Indications

Though it can be used for any malignant or pre-malignant tumor, it is most frequently used to treat a basal cell carcinoma:

- ❖ With a poorly defined edge.
- ❖ Which has recurred.
- ❖ Which is close to a vital organ (like eye) where excessive margins of skin cannot be sacrificed to achieve complete removal.

Technique

- ❖ Tumor is initially removed with a narrow margin, which is histologically examined immediately in horizontal and vertical planes.
- ❖ If tumor cells are present in any of the margins, further tissue is removed in that plane and this is repeated until all margins are clear of tumor.
- ❖ The resulting wound can then either be sutured, or covered with a split thickness skin graft or allowed to heal by secondary intention.

Curettage

Indications

Used to remove:

- ❖ Benign exophytic lesions.
 - Seborrheic keratosis.
 - Viral warts.
- ❖ Small BCCs in combination with electrodesiccation.

Technique

- ❖ Curettage is a minimally invasive procedure and is done under local anesthesia.
- ❖ The lesion is scraped off using a sharp curette.
- ❖ Any bleeding at the base is stopped by using electrocautery or a cauterizing chemical like trichloroacetic acid.
- ❖ The wound heals by secondary intention over 2–3 weeks with good cosmetic results.

Combination with electrodesiccation

- ❖ In combination with electrodesiccation, it can be used to treat basal cell carcinoma (BCC).
- ❖ Lesion is scraped carefully and firmly along the sides and bottom. The bleeding bed is then electrodesiccated completely. In experienced hands, the cure rate is good.

Advantages

- ❖ Histological examination can be carried out on the curettings, if required.
- ❖ Curettage can be combined with electrodesiccation to even treat malignant conditions like small BCCs.

Electrosurgery

Electrosurgery is a simple, quick, and effective technique for treating both benign and small malignant lesions of the skin using alternating current (AC) and less frequently direct current (DC).

Indications

Electrosurgery is used for treating small cutaneous lesions:

- ❖ **Benign lesions:** Skin tags, viral warts, granuloma pyogenicum.
- ❖ **Malignant tumors:** Small (<1 cm) BCC and SCC (usually in combination with curettage).

Techniques

Several techniques are used in electrosurgery.

Electrocoagulation

Tissue is destroyed using low-voltage high-amperage AC, *e.g.*, to remove trichoepithelioma.

Electrodesiccation

Tissue is destroyed using a high-voltage, low-amperage AC. It is less tissue destructive than electrocoagulation, *e.g.*, to remove seborrheic keratoses, warts, and molluscum contagiosum.

Electrofulguration

Tissue is destroyed using low-voltage, high-amperage AC with a spark without the electrode making direct contact with the skin. It is used for superficial lesions, *e.g.*, to remove dermatosis papulosa nigra.

Electrocautery

Tissue is destroyed by heat generated in a filament using low-voltage, high-amperage DC. Most useful in patients with pacemaker/defibrillator. And also in tissues which do not conduct electricity, *e.g.*, nails.

Radiofrequency Ablation (RFA)

Basis

RFA is a form of electrosurgery, where source of AC which is converted into very high-frequency (500–4000 kHz), high-voltage low-amperage current.

Indications

Indications are similar to those of electrocautery but in RFA the operator has choice of selecting treating mode.

Advantages

- ❖ Cosmetically more acceptable scar.
- ❖ Lower rate of bacterial infection.
- ❖ Bleeding more easily controlled.

Cryotherapy

Basis

Cryotherapy is controlled destruction of tissues with the help of **cryogens** like liquid nitrogen and carbon dioxide snow. Liquid nitrogen (–196°C) is used more frequently than carbon dioxide snow or ‘dry ice’ (–79°C). Cryogens produce cell death by:

- ❖ Intracellular and extracellular crystallization of water.
- ❖ Freezing of blood vessels, causing tissue ischemia.

Indications

Cryotherapy is effective for treating:

- ❖ Viral warts.
- ❖ Keloids.
- ❖ Seborrheic keratoses.
- ❖ Actinic keratoses.
- ❖ Superficial skin malignancies (*e.g.*, BCC, intra-epidermal carcinoma, and lentigo maligna).

Technique

- ❖ Cryogens are applied either using a cotton bud or using closed or open ended spray method or using probes. For thick lesions, intralesional cryotherapy may be used.
- ❖ The lesion is frozen until it turns white, with a halo of 1–2 mm.
- ❖ Multiple short freeze-thaw cycles destroy tissue more effectively than a single long freeze-thaw cycle.
- ❖ Application of a potent local steroid, after therapy, may lessen postoperative pain and prevent blistering.
- ❖ Scab which is formed sloughs off in about a fortnight, taking with it all dead tissue.

Disadvantages

- ❖ Blistering, scarring, and depigmentation.
- ❖ Postoperative pain.
- ❖ Slow healing.
- ❖ Nonavailability of tissue for histopathological evaluation.

Chemosurgery

Basis

Chemical causes destruction of portion of epidermis and/or dermis with subsequent regeneration (*i.e.*, a controlled wound is produced and it re-epithelializes).

Techniques

Two important techniques in chemosurgery are:

- ❖ **Chemical cauterization:** A high concentration of the chemical, *e.g.*, 100% trichloroacetic acid is applied to small skin lesions, *e.g.*, warts.
- ❖ **Chemical peeling:** A lower concentration of the chemical is applied to a larger area to produce a controlled wound and this is allowed to heal.

Chemicals Used

Several chemicals have been used in chemo-surgery:

- ❖ Trichloroacetic acid (25–100%).
- ❖ Phenol.
- ❖ α -hydroxy acids, *e.g.*, glycolic acid and lactic acid.
- ❖ Kojic acid.
- ❖ Salicylic acid.

Indications

- ❖ **Chemical cauterization:** Is used to treat:
 - Viral warts.
 - Molluscum contagiosum.
 - Skin tags.
 - Granuloma pyogenicum.
- ❖ **Chemical peeling:** Is used to treat:
 - Acne scars.
 - Photoaging.
 - Chloasma.

Phototherapy/Photochemotherapy

Ultraviolet (UV) rays can be either used to treat the skin directly (**phototherapy**) or to treat skin which has been primed with some chemical/drug (**photochemotherapy**).

Indications

Phototherapy and photochemotherapy are useful in:

- ❖ **Psoriasis:**
 - Narrow band UVB (NB UVB)
 - Psoralens + UVA; labeled **PUVA** when artificial source of light is used and **PUVA sol** when sunlight is used.
- ❖ **Vitiligo:** PUVA, PUVA sol, and NB UVB form mainstay of therapy.
- ❖ **Atopic dermatitis:** NB UVB, PUVA, PUVA sol in adults, and NB UVB therapy in children.
- ❖ **Alopecia totalis and universalis.**
- ❖ **Others:** Pityriasis lichenoides chronica, pityriasis rosea, morphea, and mycosis fungoides.

Technique

Photochemotherapy

- ❖ 8-methoxypsoralen, (0.6 mg/kg) or trimethylpsoralen (0.6 mg/kg) after breakfast on alternate days.

- ❖ 1–2 hours later, (after topical application of petroleum in scaly dermatosis), patient exposes lesions to UVA, supplied by special chambers though a more cost effective method is using the sun.
- ❖ The initial exposure depends on the skin type, being much less for the fair skinned individuals (0.5 J/cm^2) than for the dark skinned (2.0 J/cm^2). A more accurate estimation of the initial exposure is made by determining the patient's minimal phototoxic dose¹⁸.
- ❖ The UVA dose is gradually increased depending on the erythema produced and therapeutic response.

Phototherapy

- ❖ Narrow band UVB (311 nm) used is supplied by special chambers.
- ❖ Initial exposure and increments depend on skin type.

Advantages

UVB

UVB has the following advantages:

- ❖ Can be used in pregnancy.

- ❖ Can be used in children.
- ❖ Does not require psoralens, which cause nausea and vomiting.
- ❖ Does not require postexposure eye protection.

Disadvantages

PUVA

PUVA has the following disadvantages:

- ❖ Phototoxicity (intense erythema) due to excessive exposure to UVR can be minimized by careful dosimetry and photoprotection.
- ❖ Nausea and giddiness common after taking psoralens. Avoided by splitting dose of psoralens and using antiemetics.
- ❖ Premature aging of the skin; appears as mottled skin pigmentation, wrinkling, and atrophy.
- ❖ Cutaneous malignancies in patients exposed to large doses of PUVA (controversial!).
- ❖ Cataract. Can be prevented by using UV blocking sun glasses for 12 h after psoralen ingestion.

UVB

UVB has the following disadvantages:

- ❖ Burns.

Table 19.7. Laser: types and uses

Lesions	Lasers used	Comments
Vascular nevi Port-wine stain	Pulsed dye laser Intense pulsed light (IPL)	<ul style="list-style-type: none"> ❖ Number of treatments needed: 2–12 or more at 6–8 week intervals. ❖ Response often incomplete.
Pigmentary disorders Chloasma Cafe-au-lait macules Lentiginos Nevus of Ota	QS-ruby laser QS-Alexandrite laser QS-Nd:YAG laser	<ul style="list-style-type: none"> ❖ Lasers with short wavelengths (QS-ruby laser) do not penetrate deep, so used for epidermal pigmentation. Lasers with long wavelengths (QS-Nd:YAG) penetrate deep, so used for dermal pigmentation. ❖ Epidermal pigmentation requires 1–2 sessions; dermal pigmentation 4–6 sessions ❖ Treatment intervals: 6–8 weeks; longer for dermal pigmentation
Tattoos	QS-ruby laser QS-Alexandrite laser QS-Nd:YAG laser	<ul style="list-style-type: none"> ❖ Amateur tattoos need fewer sessions than professional tattoos. ❖ Treatment interval 5–6 months, as pigment removed by macrophages in interim.
Hair reduction	Diode laser Long-pulsed Nd: YAG laser Long-pulsed Alexandrite	<ul style="list-style-type: none"> ❖ Is long-term hair reduction not removal ❖ Multiple (3–6) treatments at 6–8 week intervals. ❖ Optimal results in thick dark hair in fair individuals.
Resurfacing	Nd: YAG laser Alexandrite laser Erbium laser	<ul style="list-style-type: none"> ❖ Used for wrinkles, acne scars etc. ❖ Newer laser systems used include fractional lasers.

18. **Minimal phototoxic dose:** the least dose of UVA, which after ingestion of psoralens produces a barely perceptible erythema at 72 h.

- ❖ Cumulative UVB radiation dose increases the risk of skin cancer.
- ❖ Prolonged UVB radiation leads to photoaging.

Laser and Intense Pulse Light Therapy

- ❖ Laser (**Light Amplification by Stimulated Emission of Radiation**) technology has advanced rapidly and many types of lasers are now available for clinical use in dermatology (Table 19.7).
- ❖ Intense pulse light (IPL) is filtered light of specific band of wavelengths, which has some features of long-pulsed lasers.

Principle of Use

- ❖ Photons are absorbed by a target **chromophore** (melanin, oxyhemoglobin, tattoo pigment). Wavelength absorbed depends on chromophore and results in **photothermolysis**.
- ❖ Tissue damage depends on:
 - Energy of photon.
 - Duration of pulse.
 - Thermal relaxation time.

Advantages

- ❖ Cosmetically acceptable results.
- ❖ Previously untreatable conditions like port-wine stain can now be treated (Table 19.7).

Disadvantages

- ❖ Expensive equipment. No single instrument which can cover most needs.
- ❖ Technical expertise needed.

Radiotherapy

- ❖ Radiotherapy should never be used for inflammatory skin diseases or for benign conditions because of associated side effects.
- ❖ Indications for use of radiotherapy in dermatology include:
 - Biopsy-proven skin cancers in the elderly or in those who are too frail to tolerate surgery.
 - Electron beam therapy to treat cutaneous T-cell lymphomas.
- ❖ The usual dose is 3000 cGy, given in fractions over a week.

Index

A

- Abnormal skin pigments, 146
- Abscess, 7
- Acantholysis, 71
- Acanthosis, 85
- Acanthosis nigricans, 37, 383, 394
- Acitretin, 51, 414
- Acne after facial massage, 115
- Acne conglobata, 114
- Acne excoriee, 115
- Acne fulminans, 115
- Acne keloidalis, 249
- Acne vulgaris, 110, 122
 - clinical features, 111
 - diagnosis, 116
 - differential diagnosis, 116
 - etiology, 110
 - factors modifying acne, 111
 - scars, 112
 - treatment, 116
 - variants, 114
- Acneiform eruption, 211
- Acquired or secondary lymphangioma, 171
- Acquired PPKD, 29
- Acquired ichthyosis, 28
- Acrocyanosis, 201
- Acrodermatitis enteropathica, 393
- Acrofacial vitiligo, 152
- Acromegaly, 384
- Actinic cheilitis, 198
- Actinic keratoses, 359, 361
- Actinic reticuloid, 198
- Actinic, 57
- Acute effects of radiation, 202
- Acute generalized exanthematous pustulosis, 209
- Acute gingivostomatitis, 279
- Acute intermittent porphyria, 388
- Acute mucocutaneous candidiasis, 293
- Acute paronychia, 141
- Acute pseudomembranous candidiasis (thrush), 294
- Acute radiation dermatitis, 203
- Acute retroviral syndrome, 326
- Acute thermal injury, 201
- Acyclovir, 314, 334, 406, 411
- Adapalene, 407
- Addison's disease, 385
- Addisonian pigmentation, 386
- Adrenal disorders, 385
- Adrenaline, 415
- Agents of systemic therapy, 408
- AIDS, 323, 328
- Allergic contact dermatitis (ACD), 101
- Alopecia, 129, 212
 - Alopecia areata, 130
 - clinical features, 130
 - diagnosis, 131
 - etiology, 130
 - treatment, 133
 - Alopecia totalis, 130, 418
 - Alopecia universalis, 130
- Aluminium chloride hexahydrate, 125, 408
- α -hydroxy acids, 118, 403
- Amorolfine, 289
- Androgenetic alopecia, 133
- Angioedema, 8, 181, 210
- Angiofibromas, 33
- Angular stomatitis, 294, 391
- Annular erythema, 55, 174
- Anogenital warts, 270, 272, 318
- Antiacne agents, 407
- Antiandrogens, 135, 138, 412
- Antibacterials, 405
- Antibiotics, 118, 123, 213, 405, 407, 408
- Antibodies to double-stranded DNA (dsDNA), 226
- Anticonvulsants, 213
- Antifungal agents, 405, 410
- Antihistamines, 182, 412
- Antinuclear antibodies (ANA), 236
- Antiparasitic agents, 406
- Antiperspirants, 408
- Antipruritic agents, 408
- Antipsoriasis agents, 407
- Antiretroviral drugs with dosages for adults, 333
- Antitubercular drugs, 207
- Antiviral agents, 406, 411
- Aphthous ulcers, 238
- Apocrine acne, 127
- Apocrine glands, 127
- Apple jelly nodules, 253
- Arsenical keratoses, 361
- Arteriovenous malformation, 372
- Arthropods, 335
- Ash leaf macule, 33
- Aspirin, 213
- Asteatotic eczema, 107
- Astringents, 403
- Asymptomatic shedding, 312, 314
- Atherosclerosis, 163
- Atopic dermatitis, 91
- Atrophy, 11
- Auspitz sign, 42
- Autoimmune urticaria, 179, 182
- Autosomal dominant dystrophic FB, 31
- Autosomal recessive dystrophic FB, 32
- Azathioprine, 76, 413
- Azelaic acid, 118, 404, 407
- Azithromycin, 318, 409

B

- Bacterial infections, 243
- Basal cell carcinoma, 362
- Bathing trunk nevi, 353
- Baths and soaks, 401
- Bazin's disease, 188
- BB leprosy, 262
- Beau's lines, 144
- Becker's nevus, 357
- Beetles, 337
- Behcet's disease, 239
- Benign acquired hemangioma, 372, 375
- Benign tumors of skin appendages, 370

- Benzoyl peroxide, 118, 407
 Benzyl benzoate, 406
 Betamethasone, 404
 Betamethasone dipropionate, 404
 Black head, 111
 Blaschko's lines, 20
 Bleomycin, 159
 Blisters, 7
 BL leprosy, 261
 Boils, 250
 Bowen's disease, 360
 Breslow's method, 369
 BT leprosy, 261
 Bubo, 308
 Bulla, 7, 67
 Bulla spread sign, 73
 Bullous disorders, 67–84
 diagnosis, 68
 differential diagnosis, 75
 investigations, 69
 treatment, 76
 variants of pemphigus, 75
 Bullous impetigo, 246
 Bullous pemphigoid, 77
 Burkley's membrane, 42
 Burrow, 9, 341
 clinical features, 336–37
 diagnosis, 339
 etiology, 339
 treatment, 340–41
 Busulfan, 159
 Butenafine, 289
 Button hole sign, 34
- C**
- Café-au-lait macules, 34, 419
 Calcinosis cutis, 229, 233
 Calcipotriol, 50, 407
 Callosities, 30
 Candida albicans, 293
 Candidal balanoposthitis, 294
 Candidal genital infection, 319
 Candidal intertrigo, 293, 295, 382, 405
 Candidal skin infection, 319
 Candidal vulvovaginitis, 294, 296, 406
 Capillary malformation, 372
 Capsaicin, 408
 Carbamazepine, 213
 Carbuncle, 250, 408
 Cardiovascular syphilis, 304
 Carpet tack sign, 219
 Casal's necklace, 392
 Cayenne pepper spots, 187
 Ceftriaxone, 410
 Cefuroxime, 410
 Cellulitis, 251
 Cephalosporins, 410
 Cetirizine, 412
 Chancroid, 306
 Chemosurgery, 418
 Chilblains, 200
 Chlamydial genital tract infection, 317
 Chloasma melasma, 156
 Chloracne, 114
 Chlorhexidine, 403, 405
 Chloroquine, 200, 415
 Cholinergic urticaria, 180
 Chromoblastomycosis, 298
 Chronic actinic dermatitis, 198
 Chronic bullous disease of childhood, 79
 Chronic effects of radiation, 203
 Chronic paronychia, 142
 Chronic thermal injury, 202
 Cicatricial alopecia, 129, 133, 136
 Ciclopirox olamine, 405
 Cidofovir, 412
 Ciprofloxacin, 409
 Clark's method, 369
 Cleansing agents, 403
 Clobetasol propionate, 404
 Clofazimine, 159
 Clotrimazole, 268
 Coal tar, 50, 403, 407
 Cold urticaria, 180
 Collagen vascular diseases, 217, 404, 413
 Collodion, 400
 Collodion baby, 28
 Comedones, 9, 111
 Complement fixation test, 311
 Compound melanocytic nevi, 354
 Condyloma lata, 302
 Congenital erythropoietic porphyria, 387
 Congenital hypertrichosis lanuginosa, 129, 139
 Congenital melanocytic nevi, 352, 353
 Congenital syphilis, 304, 307
 Contact dermatitis, 87, 100, 413, 414
 Corns, 30, 273, 406
 Corps ronds, 38
 Corticosteroids, 76, 183, 227, 404, 414
 Cosmetic acne, 114
 Crazy pavement skin, 389
 Creams, 399
 CREST syndrome, 233
 Cronkhite–Canada syndrome, 158
 Crotamiton, 344, 407–08
 Crust, 10
 Cryotherapy, 120, 273, 417
 Curettage, 416
 Currant bun appearance, 351, 370
 Cutaneous horn, 359
 Cutaneous infections in HIV infected individuals, 329
 Cutaneous leishmaniasis (oriental sore), 346
 Cutaneous manifestations of diabetes, 381
 Cutaneous neurofibromas, 34
 Cutaneous tuberculosis, 252
 Cutis verticis gyrata, 385
 Cyclophosphamide, 76, 413
 Cyclosporine, 51, 413
 Cyproterone acetate, 119, 412
 Cysticercosis, 346
- D**
- Dapsone, 415
 Darier's disease, 38
 Decubitus ulcer, 163
 Deep folliculitis, 249
 Deep vein thrombosis (DVT), 164
 Delayed pigmentation, 193
 Delayed pressure urticaria, 180
 Depigmenting agents, 155, 404
 Dermal atrophy, 11
 Dermatitis herpetiformis, 80
 Dermatitis, 85
 Dermatofibroma, 377
 Dermatomyositis, 227–29
 Dermatophytic infections, 88, 283, 288, 410
 Dermatophytide reaction, 287
 Dermoscopy, 367
 Dermographic urticaria, 8, 180, 182
 Dermoscopy, 15
 Desmogleins, 72
 Dexamethasone, 414
 Diabetes mellitus and skin, 381
 Diabetic dermopathy, 382
 Diaper dermatitis, 107
 Diascopy, 13, 14
 Diffuse systemic sclerosis, 231
 Direct immunofluorescence, 69, 70, 75, 238
 Discoid eczema, 48, 104
 Discoid lupus erythematosus, 218
 Disorders of apocrine gland, 127
 Disorders of eccrine sweat glands, 123
 Disorders of hyperpigmentation, 156
 Disorders of nails, 138
 Disorders of veins, 164
 Dithranol, 50, 407
 Donovanosis (Granuloma venereum, Granuloma inguinale), 309
 Doxycycline, 409
 D-penicillamine, 235
 Drug-induced acne, 114
 Drug-induced pemphigus, 74
 Drug reactions, 205
 Dyes, 405

Dysplastic nevus syndrome, 256
Dyssebacia, 392

E

Early syphilis, 307
EB simplex, 31
Ecchymosis, 5
Econazole, 405
Ecthyma, 248
Eczema, 70, 85
Eczema herpeticum, 94, 280, 281
Electric cautery, 273
Electrocoagulation, 417
Electrodesiccation, 417
Electrofulguration, 417
Electromagnetic radiation, 191
Electrosurgery, 417
Emollient, 403
Epidermal atrophy, 11
Epidermal melanin unit, 145
Epidermal necrolysis, 82
Epidermal tumors, 350
Epidermodysplasia verruciformis, 271
Epidermoid cysts, 358
Epidermolysis bullosa, 30
Epidermolysis bullosa acquisita, 32
Epidermolytic hyperkeratosis, 27
Epidermotropism, 377
Epiloia, 33
Erosion, 10
Erysipelas, 251
Erythema, 173
Erythema ab igne, 202
Erythema multiforme syndrome, 174
Erythema multiforme, 174–75
 target lesion, 175
Erythema nodosum, 188
Erythema nodosum leprosum, 263
Erythrasma, 242
Erythrocyanosis, 169
Erythroderma, 63, 207
Erythrodermic psoriasis, 46
Erythromelalgia, 169
Erythromycin, 407, 409
Erythropoietic protoporphyria, 387
Essential fatty acid deficiency, 393
Esthiomene, 311
Ethinyl estradiol, 412
Eumelanin, 145, 146
Exanthematous eruptions, 207
Exanthematous reactions, 215
Exclamation mark hair, 130
Excoriation, 11
Exfoliative dermatitis, 64, 207
Expressivity, 19
Extramammary Paget's disease, 371

F

Famciclovir, 314, 411
Favus, 285
Fexofenadine, 412
Filaggrin, 21
Filariasis, 345
Filiform warts, 271
Finasteride, 412
Fissure, 11
Fixed drug eruption, 209
Flag sign, 389
Flexural psoriasis, 43
Fluconazole, 292, 320, 334, 411
5-Fluorouracil, 408
Flutamide, 412
Follicular occlusion syndrome, 114
Fordyce's spots, 123
Formaldehyde, 102, 408
Formalin soaks, 274
Foscarnet, 411
Freckles, 157
Frei test, 311
Furuncles, 250
Fusidic acid, 405

G

Gamma benzene hexachloride, 339, 344, 406
Garter, 166
Gels, 399
Generalized hyperhidrosis, 124
Generalized vitiligo, 152
Genotype, 19
German measles, 282
Gold, 56, 208, 211, 212
Gonococcal infection, 315
Gottron's papules, 228
Gottron's sign, 228
Grains, 38
Granuloma annulare, 383
Granuloma inguinale, 309
Granuloma pyogenicum, 375–76
Granuloma venereum, 309
Grattage test, 42
Griseofulvin, 290, 410
Gumma, 301
Guttate psoriasis, 43

H

Hailey Hailey disease, 76
Hair, 128
 anatomy, 128
 hair cycle and growth, 129
 types of, 128
HAIR-AN syndrome, 37

Hair bulb test, 148
Halcinonide, 404
Half and half nails, 144, 386
Halobetasol, 404
Halo nevus, 355
Hamartoma, 300
Hand, foot and mouth disease, 282
Hanifin and Rajka's criteria, 94
Harlequin fetus, 28
Heliotrope erythema, 228
Hematoma, 9
Henoch Schönlein purpura, 185
Herald patch, 54
Hereditary angioedema, 181
Herpes genitalis, 311
Herpes gestationis, 82
Herpes simplex virus infection, 278
Herpes zoster, 277
Hidradenitis suppurativa, 127
Hirsutism, 129, 137
Histoid leprosy, 260
HIV infection and AIDS, 323
 clinical features, 327
 diagnosis, 331
 etiology, 323
 treatment, 327
Homan's sign, 164
Horn cysts, 351
House wives dermatitis, 101
Hunterian chancre, 301
Hydrocortisone, 216
Hydroxychloroquine, 200,
Hypergammaglobulinemia, 415
Hyperhidrosis, 124
Hyperkeratosis, 27, 39, 85
Hypersensitivity urticaria, 179
Hypersensitivity vasculitis, 184
Hypertrichosis, 130, 138
Hypohidrosis and anhidrosis, 125
Hypohidrotic ectodermal dysplasia, 125
Hystrix, 27

I

Ichthyosis vulgaris, 21
Ichthyosis, 21
 types, 21
Ide eruption, 87, 105
Imiquimod, 318, 406
Immediate pigmentation, 146, 193
Immunological drug reactions, 205
Immunosuppressive agents, 227
Immunosuppressive drugs, 413
Impetigo contagiosa, 245
Incontinentia pigmenti, 36
Indeterminate leprosy, 258
Indirect immunofluorescence (IIF), 70

Infantile acne, 115
 Infantile hemangioma, 372, 375
 Infantile seborrheic dermatitis, 95
 Infectious eczematoid dermatitis, 108
 Inflammatory linear verrucous epidermal nevus, 357
 Ingrowing toe nail, 140
 Inherited PPKD, 29
 Inorganic sunscreens, 200, 404
 Insect bites, 336
 Intradermal melanocytic nevi, 354
 Intralesional corticosteroids, 120
 Iodinated compounds, 403, 405
 Iontophoresis, 125
 Irritant CD, 100
 Isomorphic phenomenon, 41, 57
 Isoniazid, 214
 Isotretinoin, 119, 123, 414
 Itraconazole, 290, 411

J

Jarisch–Herxheimer reaction, 206
 Junctional epidermolysis bullosa, 32
 Junctional melanocytic nevi, 353

K

Kaposi's sarcoma (KS), 380
 Kaposi's varicelliform eruption, 93
 Kawasaki syndrome (mucocutaneous lymph node syndrome), 282
 Keloid, 376
 Keratoacanthoma, 360
 Keratoderma blennorrhagicum, 43
 Keratodermas, 28
 Keratodermic sandals, 62
 Keratoplastic agents, 403
 Keratolytics, 403
 Keratosis pilaris, 22
 Kerion, 284
 Ketoconazole, 292, 412
 Kissing or touching lesions, 337
 Koebner's or isomorphic phenomenon, 41
 Koebner's phenomenon, 41, 153
 Koilocytes, 273

L

LAMB syndrome, 158
 Lamellar ichthyosis (LI), 25, 26
 Lamina lucida, 31
 Langerhans' cell histiocytosis, 379
 Larva migrans, 345
 Laser therapy, 120, 138

Late onset acne, 115
 Late syphilis, 301
 Latent syphilis, 302
 Leiomyoma, 376
 Leishmaniasis, 346
 Lentiginosities, 158
 LEOPARD syndrome, 158
 Lepromatous leprosy (LL), 259
 Lepromin test, 265
 Leprosy vaccines, 268
 Leprosy, 256
 Leucocytoclastic vasculitis, 184
 hypersensitivity vasculitis, 184
 Leucoderma, 153
 Levamisole, 155
 Levocetirizine, 412
 Lichen nitidus, 60
 Lichen planus (LP), 56
 associations, 57
 diagnosis, 59
 differential diagnosis, 59
 treatment, 61
 variants, 57
 Lichen sclerosus et atrophicus, 236
 Lichen simplex chronicus, 105
 Lichenification, 11
 Lichenoid eruptions, 206
 Limited SSc (lSSc), 234
 Linear scleroderma, 235
 Linear, 57
 Lip-tip vitiligo, 152
 Lipodermatosclerosis, 106
 Lipoma, 376
 Livedo reticularis, 169
 Localized hyperhidrosis, 125
 Localized scleroderma (Morphea), 235
 Loratadine, 412
 Lotions, 398
 Lupus band test, 225
 Lupus erythematosus (LE), 218
 Lupus hair, 223–24
 Lupus vulgaris, 221, 252–55, 347
 Lymphangiectasis, 171
 Lymphangioma, 374
 Lymphatic malformation, 372, 374
 Lymphedema, 170
 elephantiasis nostras verrucosa, 170
 Lymphogranuloma venereum (LGV), 310

M

Macules, 5
 Magenta tongue, 392
 Malignant melanoma (MM), 367
 Malignant syphilide, 302
 Malignant tumor, 349

Management of opportunistic infection in HIV patients, 334
 Max Joseph's spaces, 60
 Measles (Rubeola), 282
 Mechanic's hand, 229
 Melanocytic nevus (nevomelanocytic nevus), 352
 Melanopenic hypopigmentation, 147
 Melanosomes, 145
 Menthol, 408
 Methotrexate, 51, 413
 Metronidazole, 410
 Miconazole, 405
 Milia, 32
 Miliaria, 126
 Minocycline, 159, 409
 Minoxidil, 408
 Mitten hands, 32
 Mixed connective tissue disease (MCTD), 237
 Mixed malformations, 372
 Moh's microscopic surgery, 416
 Moisturizers, 96
 Molluscum contagiosum (MC), 272, 274, 319
 Molluscum fibrosum, 34
 Mongolian spots, 354
 Morphea profundus, 236
 Mucocutaneous leishmaniasis, 346
 Munro's micro-abscesses, 48
 Mupirocin, 405
 Mycetoma, 296
 Mycosis fungoides, 377
 Myiasis, 338

N

Nadifloxacin, 405
 Nail changes due to trauma, 140
 Natural protection against sunlight, 199
 Necrobiosis lipoidica, 383
 Necrolytic migratory erythema, 395
 Neurodermatitis, 105
 Neurofibromatosis, 34
 Neurosyphilis, 304
 Nevus, 349
 Nevus achromicus, 153
 Nevus comedonicus, 357
 Nevus of Ota, 355–56, 419
 Nevus sebaceous, 350, 357
 NF1, 34
 NF2, 35
 Nicotinic acid deficiency (Pellagra), 392
 Nikolsky sign, 73
 Nipple dermatitis, 93
 Nodular vasculitis, 187, 188, 190
 Nodule, 6

Nonbullous ichthyosiform erythroderma, 26
 Non-immunological drug reactions, 206
 Non-melanopenic hypopigmentation, 147
 Nonsedating antihistamines, 412
 Norwegian or crusted scabies, 343
 Nummular (discoid) eczema, 104
 Nystatin, 406

O

Occupational acne, 114
 Oculocutaneous albinism (OCA), 147
 Ofloxacin, 409
 Ointments, 399
 Onychogryphosis, 140
 Onycholysis, 140
 Onychomycosis, 141, 411
 Ophiasis, 130
 Oral candidiasis, 294, 405, 406
 Oral mini pulse, 133
 Organic sunscreens, 192, 200, 404
 Orthokeratosis, 39

P

Pachydermoperiostosis, 385
 Pachyonychia congenita, 139
 Paederus dermatitis, 337
 Paget's disease, 371
 Paget's disease of the breast, 371
 Palm and sole lesions, 302
 Palmoplantar keratodermas, 28
 Palmoplantar warts, 270, 403, 406
 Panniculitis, 187, 239
 Papular syphilide, 302
 Papules, 6
 Parakeratosis, 39, 47
 Paraneoplastic diseases, 394
 Paraneoplastic pemphigus, 74, 394
 Parapsoriasis, 63
 Paronychia, 141
 Pastes, 338
 Patch test, 16
 Pathogenesis of drug reactions, 206
 Pautrier's microabscesses, 378
 Pediculosis (louse infestation), 338
 Pediculosis capitis, 338
 Pediculosis corporis, 339
 Pemphigus, 71
 Pemphigus erythematosis, 73
 Pemphigus foliaceus, 73
 Pemphigus vegetans, 73
 Pemphigus vulgaris, 72
 Penetrance, 19
 Penicillins, 207, 213, 408

Penile psoriasis, 44
 Percutaneous absorption, 400
 Perforating keratoses, 386
 Perioral dermatitis, 122
 Periungual fibromas (Koenen's tumors), 33
 Permethrin, 339, 344, 406
 Petechiae, 5, 8
 Peutz-Jegher's syndrome, 158
 Phakomatoses, 32
 Phakomatosis pigmentovascularis, 372
 Phenol, 408
 Phenotype, 19
 Phenytoin, 214
 Pheomelanin, 126
 Photoaging, 193
 Photoallergic reactions, 195–98
 Photocarcinogenesis, 194
 Photochemotherapy, 52, 154, 418
 Photodermatoses, 194
 Photopatch test, 17, 89, 197
 Photoprotection, 199
 Photosensitive eruption, 209
 Photosensitive lichenoid eruption, 195
 Phototherapy, 52, 155, 418
 Phototoxic reactions, 195–96
 Phototoxicity, 155
 Phrynoderma, 391, 393
 Physical urticaria, 179
 Piebaldism, 149
 Pigmented BCC, 363
 Pigmentation, 211
 Pigmentation of pregnancy, 159
 Pigmented purpuric dermatosis, 187
 Pimecrolimus, 408
 Pinworm infestation, 345
 Pitted keratolysis, 242
 Pitting, 45, 142
 Pituitary disorders, 384
 Pityriasis alba, 267
 Pityriasis amiantacea, 44, 45
 Pityriasis lichenoides chronica (PLC), 56
 Pityriasis lichenoides et varioliformis acuta (PLEVA), 61
 Pityriasis lichenoides, 51
 Pityriasis rosea (PR), 53
 Pityriasis rubra pilaris (PRP), 62
 nutmeg grater, 62
 Pityriasis versicolor (PV), 290
 Plane warts (verruca plana), 271
 Plaques, 6
 Podophyllin, 318, 406
 Podophyllotoxin, 406
 Poikiloderma, 9, 64, 228, 378
 Point of care tests (POCT), 313
 Polyarteritis nodosa (PAN), 185

Polymorphic light eruption (PMLE), 194
 Pompholyx, 104
 Porphyria cutanea tarda (PCT), 388, 415
 Porphyrias, 387
 Port-wine stain, 372, 419
 Post kala-azar dermal leishmaniasis (PKDL), 347
 Postherpetic neuralgia, 277
 Potassium hydroxide mount, 15
 Powders, 398
 Prednisone, 414
 Premalignant lesions, 359
 Prick tests, 90
 Primary syphilis, 301, 306
 Provocation test, 83
 Pseudoepitheliomatous hyperplasia, 366
 Pseudo-isomorphic phenomenon, 41
 Pseudoparalysis of Parrot, 304
 Pseudopelade, 137
 Psoralens, 154, 159
 Psoriasiform lesions, 302
 Psoriasis, 40
 associations, 44
 biological response modifiers, 53
 complications, 46
 definition, 40
 diagnosis, 48
 differential diagnosis, 48
 minimal phototoxic dose, 52
 morphology, 41
 pathogenesis of psoriasis, 41
 photochemotherapy and phototherapy in the treatment of psoriasis, 52
 PUVA, 54
 PUVA sol, 54
 rotational and sequential therapy, 53
 systemic agents to treat psoriasis, 51
 topical agents to treat psoriasis, 50
 treatment, 49
 variants, 43
 Psoriasis of palms and soles, 44
 Pterygium, 58, 143
 Pubic lice, 340
 Purpura, 8
 Pustular psoriasis, 46
 Pustule, 7, 342
 Pyoderma gangrenosum, 190
 Pyodermas, 243, 382

Q

Quinolones, 409

R

Radiofrequency ablation (RFA), 417
 Radiotherapy, 420
 Rapamycin, 34
 Rapid test, 331
 Raynaud's phenomenon, 161
 Reactions in leprosy (lepra reactions), 262
 Recurrent genital herpes, 312
 Reiter's syndrome, 43
 Resident flora, 241
 Retinoic acid (RA), 123, 157, 273, 403, 404, 407
 Retinoids, 117, 407, 414
 Rheumatoid arthritis, 240
 Rheumatoid nodules, 240
 Riboflavin deficiency, 391
 Ridley Jopling classification, 258
 Rifampicin, 215
 Rodent ulcer, 362
 Roentgen erythema, 202
 Rosacea, 116, 120,
 Roseolar syphilide, 302
 Rupoid psoriasis, 43

S

Safety pin or telephone handle appearance, 309
 Salicylic acid, 273
 Salmon patch, 372
 Salt-pepper dyschromatosis, 233
 Scabies, 341
 Scale, 9
 Scalp psoriasis, 44
 Scars, 112
 Sclerema neonatorum, 201
 Scleroderma, 231
 Sclerosis, 12
 Scrofuloderma, 253
 Seborrheic dermatitis, 48, 97, 329, 404, 405
 Seborrheic keratosis (SK), 350
 Secondary syphilis (SS), 49, 56, 302, 306
 Sedating antihistamines, 412
 Segmental vitiligo, 151
 Selenium sulfide,
 Serological tests for syphilis (STS), 305
 Sexually transmitted diseases (STDs), 330
 Sezary syndrome, 378
 Shagreen patch, 33
 Shampoos, 403
 Shave excision, 416
 Shawl sign, 229
 Sign of groove, 310
 Sinus, 11

Skin and internal malignancies, 393
 Skin and metabolic diseases, 387
 Skin and renal diseases, 386
 Skin biopsy, 17, 229
 Skin in liver disease, 386
 Skin tags, 352
 Slit smear, 264
 Solar urticaria, 180, 182
 Spaghetti and meat ball appearance, 290, 291, 292
 Speckled and lentiginous nevus, 354
 Spider nevi and palmar erythema, 387
 Spitz nevus, 354
 Splints, 269
 Spongiosis, 85
 Sporotrichosis, 297
 Sprays, 401
 Squamous cell carcinoma (SCC), 365
 Staphylococcal scalded skin syndrome (SSSS), 71, 84, 247
 Staphylococcus aureus, 242, 245
 Stasis eczema (gravitational eczema), 106
 Stasis eczema and stasis ulcer, 165
 Steatocystoma multiplex, 359
 Steroids, 213
 Stevens–Johnson syndrome–toxic epidermal necrolysis (SJS-TEN) complex, 82, 174, 216, 414
 Streptococcus pyogenes, 245
 Striae distensae, 385
 Striate, 29
 Striate palmar keratoderma, 29
 String of pearl appearance, 79
 Stuck on appearance, 351
 Sturge–Weber syndrome, 372
 Subacute cutaneous lupus erythematosus (SCLE), 222
 Subcorneal pustular dermatosis, 71
 Subcutaneous phycomycosis, 298
 Sublamina densa, 31
 Subungual hyperkeratosis, 45, 142
 Sulfonamides, 207
 Sunburn, 192
 Superficial BCC, 363
 Superficial folliculitis, 248
 Surgical excision, 416
 Sutton's nevus, 355
 Sweet's syndrome, 190
 Sycosis barbae, 249
 Sympathetic hyperhidrosis, 124
 Syndromic management of STDs, 320
 Syphilis, 300
 Syringoma, 370
 Systemic antibiotics, 96
 Systemic lupus erythematosus (SLE), 122, 223

Systemic sclerosis (SSc), 231
 clinical features, 231
 diagnosis, 234
 etiology, 231
 investigations, 234
 treatment, 234
 Systemic steroids, 230
 Systemic sunscreens, 200

T

Tacrolimus, 408
 Tacrolimus and pimecrolimus, 155
 Tanning, 193
 Tazarotene, 50, 407
 Telangiectasia, 169
 Telogen effluvium, 135
 Terbinafine, 290, 405, 410
 Tertiary syphilis, 303
 Tests to diagnose HIV infection, 331
 Tetracyclines, 119, 213, 409
 Thrombophlebitis, 164
 Thyroid disorders, 384
 Tic dystrophy, 140
 Tinea capitis (tinea of scalp), 283
 Tinea corporis (tinea of trunk and limbs), 285
 Tinea cruris (tinea of groin), 285
 Tinea incognito, 285
 Tinea manuum (tinea of hands), 286
 Tinea pedis, 286
 Tinea unguium, 286
 Tinea unguium (T. unguium), 141
 Topical agents used in dermatology, 403
 Topical calcineurin inhibitors (TCI), 96
 Topical corticosteroids, 53
 Topical imidazoles, 243
 Topical metronidazole, 122
 Topical minoxidil, 134
 Topical sunscreens, 199
 Topical treatment, 90, 398
 Traction alopecia, 135
 Transgradiens, 29
 Transient flora, 241
 Treatment of skin diseases, 397
 Trichilemmal cysts, 358
 Trichoepithelioma, 371
 Trichogram, 129
 Trichomycosis axillaris, 243
 Trichotillomania, 136
 Trifluridine, 406
 Tuberculides, 254
 Tuberculoid leprosy (TT), 259
 Tuberculosis verrucosa cutis, 252–55
 Tuberos sclerosus, 32
 Tumors, 6
 Tumors of dermis, 372

Tylosis, 29
Tyndall effect, 5, 147
Types of alopecia, 129
Tzanck smear, 15, 69, 74

U

Ulcer, 11, 163
Ultraviolet radiation, 146, 224, 362, 367
Urethritis, 317
Urticaria and angioedema, 178

V

Vagabond's disease, 339
Valacyclovir,
Varicella (chicken pox), 275
Variegate porphyria, 389
Vascular nevi, 372
Vasculitis, 184, 190, 210, 414, 415

Venous malformation, 372
Verruca vulgaris (common warts), 270
Verrucous epidermal nevus, 356
Verrucous hemangioma, 374
Vitamin A deficiency, 391
Vitamin C deficiency (Scurvy), 392
Vitiligo, 149
 diagnosis, 152
 differential diagnosis, 153
 etiology, 149
 medical treatment, 155
 morphology, 150
 patterns, 151
 treatment, 153
Vitiligo universalis, 132
Vitiligo vulgaris, 151

W

Wart paint, 273, 406
Warts (verruca), 269

Wegener's granulomatosis, 187
Wet dressings, 401
Wheal, 7
White head, 9
WHO staging for HIV infection (2006), 326
Wickham's striae, 57, 60
Window period, 323, 333
Wood's lamp, 14

X

Xanthomas, 389
Xeroderma pigmentosum (XP), 36
Xerosis and ichthyosis, 212
X-linked ichthyosis (XLI), 23

Z

Zinc deficiency, 393